

Progression and treatment of experimental peri-implantitis

Jean-Pierre Albouy

Department of Periodontology

Institute of Odontology

Sahlgrenska Academy

University of Gothenburg



UNIVERSITY OF GOTHENBURG

2011

Permission for reprinting the papers published in *Clinical Oral Implants Research* and *Journal of Clinical Periodontology* was given by John Wiley & Sons Inc.

Printed by Intellecta infolog AB, Göteborg, Sweden 2011.

ISBN 978-91-628-8236-5

Cover illustration: Histological ground sections of experimental peri-implantitis.

To Laura Kneefel, Niels, Eva and Justin

To my father, Dr. Jean G. Albouy

To my mother, Pierrette Albouy

To Charlotte Albouy and Michel Palahi

To my friends, Drs. Laurent Arbona and Mathieu Crevel

To my mentors, Drs. Ingemar Abrahamsson, William Becker, Tord Berglundh, Winston Chee and Terry Donovan

Table of Contents

Abstract	7
Preface	9
Introduction	10
Considerations on the dog model	13
The dog model in periodontitis	14
Experimental studies on peri-implant mucositis and peri-implantitis	15
Spontaneous progression of peri-implantitis in the dog model	16
Effect of surface characteristics on experimental peri-implantitis	17
Treatment of experimental peri-implantitis	18
Aims	21
Materials and methods	22
Animal groups	22
Outline of experiments	23
Preparatory period	23
Active breakdown period	24
Spontaneous progression of experimental peri-implantitis (Studies I, II and III)	24
Treatment of experimental peri-implantitis (Study IV)	24
Radiographic and clinical examinations	25
Histological preparation and landmarks	25
Data analysis	26
Results	27
Clinical findings (Study I, II, III and IV)	27
Radiographic findings (Study I, III and IV)	28
Histological findings (Study II, III and IV)	29
Main findings	32
Concluding remarks	33
Validity of the experimental model	33
Spontaneous progression of experimental peri-implantitis occurred in all implants (Study I, II and III)	34
Bone loss is a consequence of large inflammatory cell infiltrates associated with biofilm accumulation on the implant surfaces (Study II, III)	35
Surface characteristics of implants influenced the amount of spontaneous progression (Study I and III)	35
Spontaneous progression of experimental peri-implantitis was more pronounced at implants with a TiUnite surface than at implants with a turned surface (Study I, II and III)	36
Resolution of experimental peri-implantitis following surgical treatment without systemic antibiotics or local antiseptics is possible (Study IV)	37
Outcome of the therapy is influenced by the surface characteristics of the implants (Study IV)	37
Clinical implications	40
References	41
Appendix	50
Study I to IV	50

Abstract

Progression and treatment of experimental peri-implantitis.

Jean-Pierre Albouy

Department of Periodontology, Institute of Odontology, the Sahlgrenska Academy at University of Gothenburg

Peri-implantitis is characterized by inflammatory lesions in peri-implant tissues and loss of supporting bone. The aims of the present series of studies were to analyze (i) spontaneous progression and (ii) the effect of surgical treatment of experimental peri-implantitis at different types of implants.

Labrador dogs were used. Implants representing 4 different implant systems; group A (turned; Biomet 3i), B (TiOblast; Astra Tech AB), C (SLA; Straumann) and D (TiUnite; Nobel Biocare) (*Study I, II and IV*) or with similar geometry and with different surface characteristics (turned/TiUnite; Nobel Biocare AB) (*Study III*) were placed in the mandible 3 months after tooth extraction. Experimental peri-implantitis was initiated by placement of ligatures and plaque accumulation. The ligatures were removed when about 40-50% of the supporting bone was lost. Plaque formation continued for 6 months in *Study I, II and III*, while in *Study IV* surgical therapy including mechanical cleaning of implant surfaces was carried out. Radiographic and clinical examinations were performed. Block biopsies containing implants and their surrounding tissues were obtained and prepared for histological analysis.

The bone loss that occurred during the plaque formation period after ligature removal was 1.84 (A), 1.72 (B), 1.55 (C) and 2.78 mm (D). Specimens from all types of implants exhibited extensive inflammatory cell infiltrates and large crater-formed osseous defects (*Study I and II*).

The bone loss that occurred after ligature removal in *Study III* was significantly larger at TiUnite implants than at turned surface implants. The vertical dimensions of the ICT and the pocket epithelium and the apical extension of the biofilm were significantly larger at TiUnite implants than at turned surface implants (*Study III*).

While bone gain occurred at implants with turned, TiOblast and SLA surfaces, TiUnite implants demonstrated bone loss after treatment of peri-implantitis. Resolution after treatment was achieved in tissues surrounding implants with turned and TiOblast surfaces (*Study IV*).

Keywords: animal experiment, bone loss, dental implants, histology, infection, inflammation, ICT, inflammatory lesion, peri-implant disease, peri-implantitis, plaque, radiographs, titanium, treatment

ISBN 978-91-628-8236-5

Preface

The present thesis is based on the following publications, which will be referred to in the text by their Roman numerals.

I Albouy, J.-P., Abrahamsson, I., Persson, L. G. & Berglundh, T. (2008) Spontaneous progression of peri-implantitis at different types of implants. An experimental study in dogs. I: clinical and radiographic observations. *Clinical oral implants research* **19**, 997-1002.

II Albouy, J.-P., Abrahamsson, I., Persson, L. G. & Berglundh, T. (2009) Spontaneous progression of ligature induced peri-implantitis at implants with different surface characteristics. An experimental study in dogs. II: histological observations. *Clinical oral implants research* **20**, 366-371.

III Albouy, J. P., Abrahamsson, I. & Berglundh, T. (2011) Spontaneous progression of peri-implantitis at implants with different surface characteristics. An experimental study in dogs. Submitted.

IV Albouy, J. P., Abrahamsson, I., Persson, L. G. & Berglundh, T. (2011) Implant surface characteristics influence the outcome of treatment of peri-implantitis: an experimental study in dogs. *J Clin Periodontol* **38**, 58-64.

Introduction

Early reports have set the standards by which dental implants and their reconstructions were clinically monitored (Brånemark et al. 1977, Adell et al. 1981, Adell et al. 1990). These historical data report on implant loss and mean bone loss, which are expressed at the implant level. However complications such as peri-implantitis may not lead to early or rapid implant loss and may have only a minor impact on mean bone levels. For example, Åstrand et al. (2004) performed a prospective randomized controlled trial in a group of 28 patients needing posterior reconstructions on implants in both sides of the jaws. The patients were randomly allocated with either ITI or Brånemark System implants on either side of the jaws. Two implants were lost in each group resulting in the same success rate of 97.3% at 3 years. No statistical significant difference was found in the marginal bone levels with values of 1.3 mm for the ITI group and 1.8 mm for the Brånemark System group at 3 years. However, the ITI group demonstrated a statistically significant higher occurrence of peri-implantitis with 7 implants, without any influence on the overall success rate of 97.3% or the mean marginal bone levels. Berglundh et al. (2002) reported in a systematic review on biological and technical complications that information on peri-implantitis was recorded in only 35 - 45% of studies relating to overdentures, fixed complete dentures or partial dentures. The authors further reported that implant level analysis does not take into consideration the impact of a complication at the patient level.

A definition for peri-implantitis was proposed in a consensus report from 2008 (Lindhe & Meyle 2008). Two distinct clinical entities can be recognized; peri-implant mucositis which describes the presence of inflammation in the mucosa at an implant with no signs of loss of supporting bone, while peri-implantitis demonstrates loss of supporting bone in addition to inflammation in the mucosa (Zitzmann & Berglundh 2008). Clinical features for peri-implant mucositis are “redness and swelling of the soft tissue, but bleeding on probing is recognized as the important feature” while, in the case of peri-implantitis, suppuration in the mucosa is frequent and deepened pockets are associated with marginal bone loss (Lindhe & Meyle 2008).

The prevalence of peri-implantitis was reviewed by Zitzmann & Berglundh (2008) and was found to be ranging between 28 and 56% at the subject level based on large cross-sectional studies (Fransson et al. 2005, Roos-Jansåker et al. 2006). However, it is important to point out that these studies provide an estimation of the prevalence of peri-implantitis around screw

shaped implants ad modum Brånemark with turned surfaces. The surface topography of this type of implants is resulting from the machining procedures of the titanium rod. Yet, today, these surfaces are not in the mass market since implants implementing various surface modifications have been introduced to achieve enhanced hard tissue responses (Gotfredsen et al. 1992, Ericsson et al. 1994, Wennerberg et al. 1998, Ivanoff et al. 2003, Dohan Ehrenfest et al. 2010). Surface modifications of implants most often used today are topographic and chemical. An anodized surface in a galvanic cell that contains phosphoric acid (TiUnite, Nobel Biocare) represents approximately 30% of the world market share while the Sand-blasted Large grid and Acid etched surfaces (SLA, Straumann) represents a global market share of approximately 25% (Wennerberg & Albrektsson 2010). A recent modification of the SLA surface was obtained by rinsing the titanium surface after the etching procedure under N₂ protection and continuous storage in an isotonic NaCl solution. This modification resulted in a hydroxylated/hydrated and highly hydrophilic surface, the SLActive (Buser et al. 2004, Zhao et al. 2005, Schwarz et al. 2008). The third common type of surface modification is an acid etching that can be found on the Osseotite implant (Osseotite, Biomet 3i). AstraTech uses a blasting procedure with micron size titanium dioxide particles to obtain a moderately rough surface (TiOblast, AstraTech) (Wennerberg & Albrektsson 2010). The TiOblast surface was further modified by a treatment with fluoride ions for improved bone to implant response (OsseoSpeed, AstraTech) (Ellingsen et al. 2004, Berglundh et al. 2007a, Abrahamsson et al. 2008). Finally the TPS surface (ITI Bonefit) was produced by a plasma spray technique that adds titanium particles to the surface at a high temperature. This surface is considered to be rough (Gotfredsen et al. 2000). A commonly used parameter to describe surface roughness is the Sa value that is an arithmetic mean deviation of a surface based on a the three dimensional profilometry of the surface. The different surfaces can be compared in terms of increasing roughness expressed in Sa values; Osseotite at 0.68 µm, TiOblast at 1.1 µm, TiUnite at 1.1 µm, OsseoSpeed at 1.4 µm, SLA and SLActive at 1.75 µm and TPS at 3.54 µm (Gotfredsen et al. 2000, Wennerberg & Albrektsson 2010).

Because historical data did not consider peri-implantitis and because of the recent developments in surface alterations, the prevalence of peri-implantitis at implants with various surface characteristics has not been studied extensively. Esposito et al. (2005) concluded from a meta-analysis that rougher implant surfaces have a 20% higher risk of being affected by peri-implantitis in a period of 3 years (Åstrand et al. 1999, Moberg et al. 2001, Åstrand et al. 2004). Moberg et al. (2001) in a 3-year prospective randomized controlled trial compared ITI (Titanium Plasma Spray) and Brånemark system implants in the treatment of mandibular edentulism.

While not specifically measuring the frequency of peri-implantitis, the authors mentioned that no statistical difference could be found in terms of bleeding on probing or marginal bone levels between the two types of implants. However, only 1 implant in the turned surface group (Brånemark) was lost at one year due to progressing bone loss while 3 implants of the ITI group demonstrated progressing bone loss, one of which had been removed after two years. Åstrand et al. (2004) in a 3-year prospective study found a higher incidence of peri-implantitis at ITI implants with a TPS surface than at Brånemark implants with a turned surface while the 1-year report did not show any difference (Åstrand et al. 1999). On the other hand Gotfredsen et al. (2001) reported on a 5-year randomized clinical trial with fixed partial prosthesis supported by at least 1 turned and 1 TiOblast AstraTech implant. The survival rates at 5 years were 100 and 95.1% respectively, for the TiOblast and turned implants without any statistical difference. There was no statistical difference when considering marginal bone levels at 5 years between the two surfaces. Wennström et al. (2004), in a 5-year prospective randomized controlled clinical trial, also compared AstraTech implants with either a turned surface or TiOblast surface in a group of 51 periodontitis-susceptible patients. No significant differences in marginal bone level changes around turned or TiOblast AstraTech implants could be detected during this 5-year period. Baelum et al. (2004) reported a higher failure rate at 10 years for one stage ITI against two stage TiOblast implants. However, the study was not intended, as mentioned by the authors, as a comparison between two types of implants but as a prospective longitudinal study in which two implant types were inserted. In effect, 57 TiOblast and 201 ITI implants were inserted in 32 and 108 patients, and observed for a mean follow-up time of 5.68 and 6.13 years, respectively. Reports at 10-year were based on a Kaplan-Meier estimates. For example, at 10 years, bone loss of more than 3.5 mm was estimated higher in the ITI group (14 vs 5%) while bleeding on probing was estimated lower in the ITI group (9.5 Vs 31%). Finally, the regression analyses did not correlate the differences in results between the two implant types to the implant type as such. Zetterqvist et al. (2010) performed a 5-year randomized clinical trial to compare hybrid implants with a surface modification made by a dual acid-etching process (Osseotite) extending from the apex to the third coronal thread with implants with full length dual acid-etching preparation. Both implants groups demonstrated similar clinical behavior without differences in terms of reports of peri-implantitis. A more recent cross-sectional study reported on four different brands of implants (Brånemark System, AstraTech, Straumann, Biomet 3i) inserted in 99 subjects in a clinical center but not monitored in supportive therapy within this center. The mean functional loading time was 8.4 years. A prevalence ranging from 11 to 47%

was reported without analyses regarding the different implant types (Koldslund et al. 2010). The variation between studies and results call for further knowledge on the behavior of tissues around implants with different surface characteristics.

Considerations on the dog model

The need for experimental models is fundamental in medicine. It has been suggested that model organisms are central in biology as “Almost everything we know about the fundamental properties of living cells... has come from the study of model organisms” (Fields & Johnston 2005). A model is selected from its similarities with the object to be studied, its homogeneity to reduce confounding variables, practical advantages and the desired endpoint to be studied.

The dog is a large animal model of choice, useful in medicine from several aspects. It shares the same environment as the human. Breeds of dogs have been selected from the wolf gene pool by human intervention over the last 15000 years. However, the difference in DNA between the gray wolves and the domestic dogs is only 0.2%, which suggests that the inter-breed differences are resulting from a relatively small number of mutations. Breed selection, which transmits recessive disease traits, associated to a high degree of genetic homogeneity within breeds increase the proportion of individuals affected by a genetic disorder in certain breeds (Ostrander & Giniger 1997, Ostrander et al. 2000). This permits the dog to be a model for the study of several genetic disorders caused by the same gene mutations as in humans such as, the canine X-linked hemophilia A, the X-linked combined severe immune deficiency, adult onset insulin dependent diabetes, early onset systemic lupus erythematosus (Parker et al. 2010). Leber congenital amaurosis (LCA) is a heterogeneous early-onset retinal dystrophy associated to a defect on the RPE65 gene, which causes congenital blindness. In 2001, a naturally occurring dog disease model, the RPE65⁻, was treated by gene therapy and the first reports of human treatment trial for this condition were published in 2008 (Acland et al. 2001, Maguire et al. 2008, Bainbridge et al. 2008).

Furthermore, the dog also shares common features with the human in terms of development and aging of the immune system. It is immunologically competent at or before birth, unlike rodents. Furthermore, its post-natal immunoglobulin development pattern and the descriptive parameters of its immune system are similar to that of humans. It is a major model in immune system related studies such as toxicity trials, effects of drugs on the immune system, bone marrow

transplantation and, specifically, the X-Linked Severe Combined Immuno Deficiency (Felsburg 2002, Holsapple et al. 2003). When considering cancer and autoimmune diseases “the dog often recapitulates human disorders so closely that they become models for the development of new therapies”. Compared to humans, cancer in dogs often presents with similar clinical and histological features, similar disease progression and response to treatment. This is true for non-Hodgkin’s lymphoma, chronic myelogenous leukemia, osteosarcoma or melanoma (Parker et al. 2010). Furthermore, specific dog breeds present a strong genetic predisposition for specific cancers with underlying genetics very similar to that of humans. It is the case of breast cancer in the English springer spaniels from Sweden that shows an association with the BRCA1 and BRCA2 loci (Rivera et al. 2009, Parker et al. 2010).

The dog model in periodontitis

The dog model has also been used to study various aspects of periodontal disease. In an “epidemiological” study by Gad (1968), a close relationship between age, plaque, and loss of attachment was established. Thus in a sample of 62 dogs ranging from 3 months to 12 years of age, periodontal tissue destruction occurred in 97% of the animals and was related to age, debris index (DI) and calculus index (CI). In an experimental study in beagle dogs (Saxe et al. 1967) it was demonstrated that animals who accumulated plaque and calculus over a 5-year period developed destructive periodontitis, while dogs that were maintained in an oral hygiene regimen remained periodontally healthy. Similar results were presented by Lindhe et al. (1973, 1975), emphasizing the central role played by plaque and calculus in the etiology of periodontal disease in the dog. From the above data it is obvious that periodontitis in dogs as in humans is a slowly progressing disorder. Hence, various attempts, including the use of sub-gingivally placed copper bands and ligatures, were made to facilitate and enhance periodontal tissue destruction (Swenson 1947, Rovin et al. 1966, Kennedy & Polson 1973, Ericsson et al. 1975, Lindhe et al. 1975, Lindhe & Ericsson 1978). Swenson (1947) proposed a technique based on the surgical creation of a deep lesion and the cementation of a copper band to maintain the pocket open. Rovin et al. (1966) utilized sub-gingivally applied silk ligatures in rats to promote plaque formation and tissue destruction. Kennedy and Polson (1973) implemented the same method in monkeys. A modification of this method was utilized by Ericsson et al. (1975) who used a combination of a surgically created narrow bone defects, which was kept open by a copper band cemented to the root for 21 days. After removal of the copper band, cotton floss ligatures were placed in the

defect and maintained until 230 days after the initial surgical intervention. This model resulted in large plaque accumulation, clear clinical signs of inflammation and an infiltration of inflammatory cells in the periodontal tissues. The average bone loss thereby obtained was 2.4 mm.

In a 12-month clinical and histological study (Lindhe & Ericsson 1978) cotton ligatures were placed in a sub-gingival location in dogs that were allowed to form plaque and calculus. In one group of animals (IB) the ligatures remained in place for 12 months, while in a second group (IIA) the ligatures were removed after 6 months. In biopsy samples from the 12-month ligature period group (IB), a large infiltrate in the connective tissue (69% of gingival tissue) was observed and was associated with pronounced attachment loss (46% of the root length). Corresponding biopsies sampled from the dogs in group IIA harbored significantly smaller infiltrates (22%) and significantly less attachment loss (36%). This demonstrates the critical role of ligatures for the progression of periodontal tissue destruction.

Experimental studies on peri-implant mucositis and peri-implantitis

In an approach to study the tissue behavior around implants facing a bacterial challenge, the dog model was first used in a 3-week plaque accumulation study in dogs by Berglundh et al. (1992). It was reported that an infiltrated connective tissue (ICT) of similar size and composition developed in tissues around teeth and implants. When extending the plaque formation period to 3 months Ericsson et al. (1992) found that the apical extension of the ICT was larger around implants than around teeth. Further observations were made in a study on dogs with a 5-month period of plaque accumulation around 3 different implants (AstraTech, Brånemark System, Straumann) demonstrating the presence of an ICT that was located within the limits of the junctional epithelium (Abrahamsson et al. 1998). These initial studies demonstrating the inflammatory soft tissue reactions around implants in response to plaque accumulation were followed with ligature induced experimental peri-implantitis observations.

One of the first experimental peri-implantitis dog studies was published in 1992 (Lindhe et al. 1992). Sub-gingival ligatures were placed around teeth and implants in 5 beagle dogs for a 6-week period. Then they were removed 1 month before clinical and radiographic examinations and biopsies. A larger infiltrated connective tissue and more bone loss were found around implants than around teeth. It was also observed that inflammatory lesions extended into the bone marrow around 8 out of 10 implants, while the lesions around teeth were consistently separated from the bone crest by a zone of healthy connective tissue. Other studies on different

animals (Hickey et al. 1991, Lang et al. 1993, Schou et al. 1993b, Schou et al. 1993a) provided observations of tissue behavior in response to sub-gingival ligatures that were maintained in place during the whole observation period. Schou et al (1993b, 1993a) compared a 7-week period of ligature-induced breakdown around implants, ankylosed and non-ankylosed teeth in monkeys. While only small differences in clinical indexes were found radiographic bone loss was limited to implants and ankylosed teeth. In addition, bone loss was greater around implants than ankylosed teeth. Lang et al. (1993) compared, in a 4 monkey split-mouth study with 8 implants on each side of the jaws, ligated and non-ligated sites around implants and teeth. Clinical parameters such as gingival index (GI), plaque index (PI), pocket Depth (PD) and Loss of Attachment (LA) were monitored for 8 months on the ligated sites and 9 months on the non-ligated sites. Loss of attachment was more pronounced around ligated sites (3.8 mm) than non-ligated ones (1mm). Nociti et al. (2001), in a study in dogs, observed ligature breakdown during a 30-day period of plaque accumulation and found no difference in loss of attachment between implants and teeth.

Spontaneous progression of peri-implantitis in the dog model

Further studies were designed to observe tissue behavior after the removal of the ligatures. Marinello et al. (1995) used 5 dogs to observe ligature induced peri-implantitis. After 25% destruction of the initial bone level was achieved the ligatures were removed and plaque accumulation continued. Two dogs were biopsied at 1 month and 3 dogs at 3 months. At 1 month a large ICT was found in contact with the bone crest, while at 3 months 5 out of 8 implants in 2 dogs exhibited encapsulation of the ICT. In the remaining sites representing 3 months, however, active tissue destruction was evident with additional bone loss. These findings indicated that a ligature-induced peri-implantitis lesion could progress also after the removal of the ligatures. This finding was challenged in a subsequent study by Zitzmann et al. (2004) who performed ligature-induced breakdown around implants in 5 dogs. Following one year of plaque accumulation after the removal of the ligatures, the authors observed a progression of bone loss in 16 out of 21 implants, 12 of the implants demonstrated a progression from 0 to 2 mm and 4 implants exhibited a progression of more than 2 mm. These observations provided a model to study spontaneous progression of experimental peri-implantitis.

Effect of surface characteristics on experimental peri-implantitis

Implants with different surface modifications are commercially available and represent a wide range of surface characteristics and geometries. Therefore, studies were designed to observe tissue behavior around different types of implants exposed to ligature-induced peri-implantitis. In some studies the ligatures were left in place during the whole observation period. In a study in 14 beagle dogs Tillmanns et al. (1997, 1998) compared three different implants, a titanium-aluminum-vanadium alloy (Ti-6Al-4V) turned screw, a Calcitite hydroxy apatite (HA) coated cylinder and a commercially pure TPS cylinder. The ligatures were left in place during the whole experimental period and no differences were detected between the different implant types after 3 or 6 months. Shibli et al. (2003c) and Martins et al. (2004) reported on a 60-day ligature-induced breakdown study in dogs and could not demonstrate any clinical and radiographic differences between implants with 4 different surface characteristics (TPS, HA, Turned in the top 3 threads, Etched). In these experiments, ligatures stayed in place during the whole observation period.

In a subsequent study on the same material Martins et al. (2005) reported on the clinical and radiographic findings for the following 12-month period after ligature removal. All animals were provided with an oral hygiene regimen by “scrubbing” with 0.12% chlorhexidine daily and “scaling the abutment surface” monthly. 17 out of 36 implants were lost during the observation period due to “bone loss and mobility” and were excluded from the analyses. Despite continuous bone loss, no difference was observed between the different surface groups among the remaining implants.

In 2007, Berglundh et al. (2007b) implemented the model proposed by Zitzmann et al. (2004) to report on tissue reactions after removal of the ligatures around custom made implants of similar geometry exposed to experimental peri-implantitis in dogs. The implants utilized were produced to provide with large differences in terms of surface roughness with Sa values of 0.35 μm (polished) and 2.29 μm (SLA) respectively (Sennerby et al. 2005). Analyses were performed 5 months after the removal of the ligatures. Radiographic observations demonstrated a larger amount of bone loss around the SLA than around the polished titanium surface implants. The ICT and biofilm area were larger around the implants with the rough surface.

The results from the study by Berglundh et al. (2007b) clearly indicated the importance of surface characteristics on peri-implantitis and pointed to the need to further study the

spontaneous progression of experimental peri-implantitis around commercially available implants.

Treatment of experimental peri-implantitis

It was stated in a the Consensus report on peri-implant diseases of the 6th European Workshop in Periodontology that successful surgical treatment of peri-implantitis “must include parameters that describe resolution of inflammation and preservation of the supporting bone” (Lindhe & Meyle 2008). More specifically, the primary objective of surgical treatment of peri-implantitis is to “get access to the implant surface for debridement and decontamination...” (Lindhe & Meyle 2008). Therefore the histological outcome variables related to bone fill or reosseointegration are of less relevance in this discussion.

Studies on the treatment of experimental peri-implantitis have demonstrated the resolution of the soft tissue inflammation under various conditions (Grunder et al. 1993, Ericsson et al. 1996, Persson et al. 1996, Persson et al. 1999, Persson et al. 2001b). Ericsson et al (1996) in a dog experiment compared open flap debridement combined with decontamination of the implant surface by means of Delmopinol HCl and sterilization of the abutments with an un-treated control side. A 3-week regimen of systemic antibiotics was given. Histological results demonstrated the resolution of the inflammatory component in the treated side while a plaque associated infiltrate remained at the control side. Systemic antibiotics alone were not sufficient to treat experimental peri-implantitis.

The decontamination of implant surfaces can be performed with various techniques (Claffey et al. 2008) but authors have shown that decontamination could be achieved, even on rough implants, by cleaning the implant surface with cotton pellets impregnated in saline solution (Persson et al. 1999, Persson et al. 2004, Kolonidis et al. 2003, Schou et al. 2003). In a study in dogs Persson et al. (1999) evaluated the treatment outcomes of two decontamination protocols around turned implants previously exposed to experimental peri-implantitis. They compared the use of a rotating brush with abrasive paste (Pumice) with the use of saline impregnated cotton pellets in a submerged surgical approach. Both techniques provided for complete resolution of the inflammatory lesions with a dense connective tissue capsule separating the bone from the implant surface. In 2004, Persson et al. compared decontamination with a carbon dioxide laser and hydrogen peroxide against the use of cotton pellets soaked in saline solution in a submerged

surgical technique around rough SLA and polished implants. Histometric measurements could not demonstrate any difference between the two decontamination protocols. Schou et al. (2003) in a study in monkeys evaluated 4 different decontamination methods around TPS implants previously exposed to experimental peri-implantitis. The decontamination procedures were; Air Powder Abrasive (APA) unit and citric acid (CA), APA alone, Saline rinsing (S) and CA, rinsing with chlorhexidine and saline alternatively. Clinical outcome variables and histological observations revealed good results with all methods. However, no difference could be found between the decontamination methods.

Experiments have been performed to evaluate the response to surgical treatment of experimental peri-implantitis at different types of implants. Some of these have not demonstrated differences between different implants (Wetzel et al. 1999, Shibli et al. 2003b, Shibli et al. 2006). Wetzel et al. (1999) compared surgical treatment with open flap debridement or guided bone regeneration (ePTFE membrane) in association with systemic and local antimicrobial therapy. No difference was found in terms of bone fill or reosseointegration between SLA, TPS, and machined implants despite a trend for the rougher implants to demonstrate better results in terms of reosseointegration. The authors did not evaluate clinical and radiographic outcomes or inflammation related histological endpoints. Shibli et al. (2003b) found a similar trend when comparing HA, TPE, etched and machined implants treated with laser and guided bone regeneration. Bone regeneration ranged from 27% for machined implants to 48% for TPS and reosseointegration from 16% for HA to 25% for TPS and machined implants. Clinical and radiographic outcomes or inflammation related histological endpoints were not mentioned. Finally Shibli et al. (2006) did not find differences in terms of bone fill or reosseointegration when comparing treatment around commercially pure titanium (CP), TPS, acid etched and oxide-sandblasted surfaces. Mention was made that “The peri-implant soft and hard tissues appeared healthy soft and hard tissues” but no clinical and radiographic outcomes or inflammation related histological endpoints were evaluated.

On the other hand, Persson et al. (2001a) evaluated a surgical treatment around custom made rough SLA and polished titanium implants of similar geometry. An open flap debridement approach with decontamination of the implant surfaces with saline impregnated cotton pellets was implemented. A submerged healing was planned for 6 months but all implants had perforated the mucosa one month after the surgeries. Results were similar for the radiographic and clinical parameters but the rough SLA surface allowed for more re-osseointegration than the

polished surface. Furthermore Persson et al. (2004) performed a similar experiment, mentioned earlier, with the same two type of implants (polished and rough SLA) in which they treated the implant surface with two decontamination methods in a submerged surgical approach. Clinical outcomes were similar between the two types of implants. The histological examination demonstrated a resolution of the inflammatory lesions around both implants with more bone to implant contacts around the SLA implant. These studies performed on experimental implants presenting with extreme Sa values (0.35 μm and 2.29 μm) provided evidence for the importance of surface roughness in terms of the osseous response in relation to the implant surface. This leads to the need for further analyses to compare the tissue behavior at commercially available implants subjected to treatment of experimental peri-implantitis.

Aims

The main objectives of the present series of experiments were:

To analyze tissue reactions to plaque formation following ligature removal at different types of implants exposed to experimental peri-implantitis (Study I and II).

To study the spontaneous progression of ligature induced peri-implantitis at dental implants with similar geometry but different surface characteristics (Study III).

To observe the effect of surgical treatment of ligature induced peri-implantitis without systemic antibiotics at different types of implants (Study IV).

Materials and methods

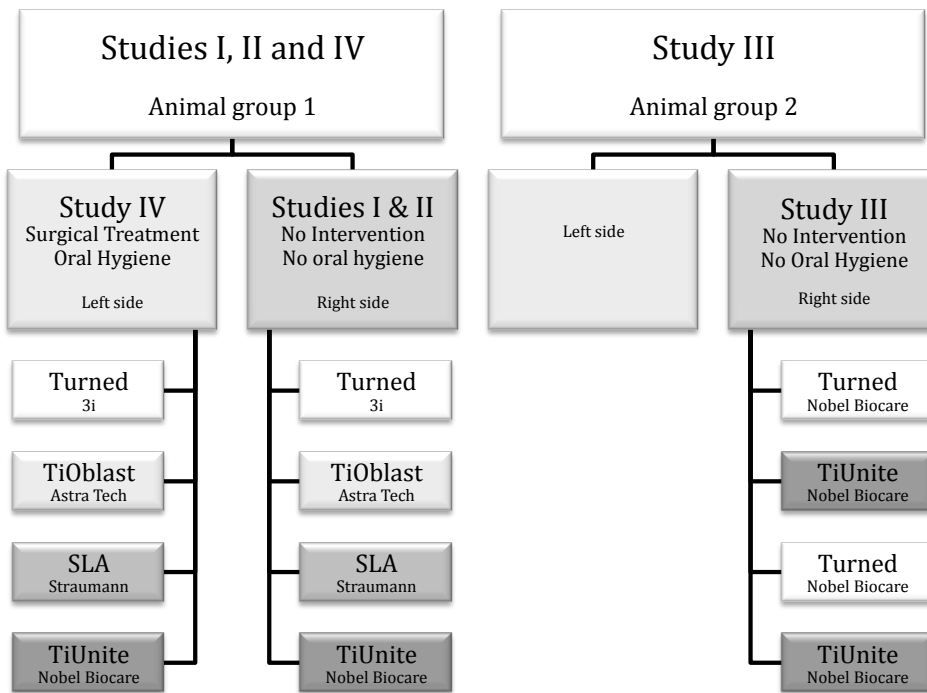
Animal groups

Two groups (Fig. 1) of six Labrador dogs about 1 year old were used for these experiments. The regional Ethics Committee for Animal Research, Göteborg, Sweden, approved the study protocols.

Studies I, II and IV utilized both sides of the jaws in animal group 1.

Study III utilized the right side of the jaws in animal group 2 (Fig. 1).

Figure 1: Schematic view of the outline of the studies.

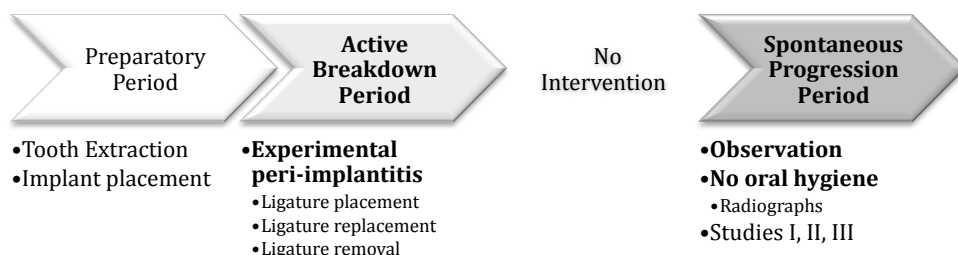


Outline of experiments

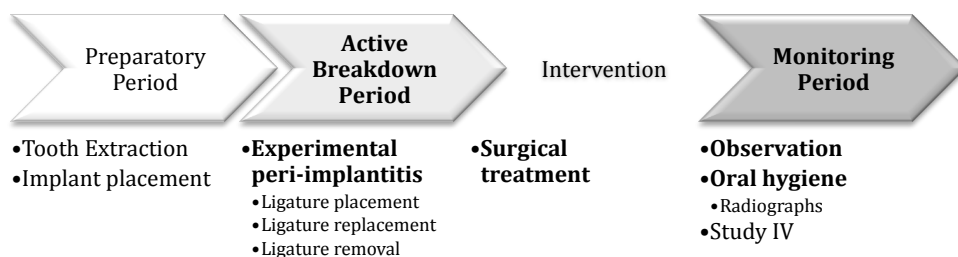
Studies I, II and III were comprised of a preparatory, an active breakdown and a spontaneous progression period (Fig. 2). The intervention represents the surgical treatment performed after the active breakdown period in study IV.

Figure 2: Schematic view of the different phases of the experiments

Studies I, II and III



Study IV



Preparatory period

During all surgical procedures general anaesthesia was induced with intravenously injected Propofol (10 mg/ml, 0.6 ml/kg) and sustained with N₂O:O₂ (1: 1.5–2) and Isoflurane employing endo-tracheal intubation.

All mandibular premolars and the three anterior premolars in both sides of the maxilla were extracted in animal group 1. In animal group 2 the mandibular premolars and the three anterior maxillary premolars were extracted on the right side.

After 3 months mucoperiosteal flaps were elevated on all of the mandibular extraction sites.

In the animal group 1, four implants representing four different implant systems with different surface characteristics were placed in a randomized order on each side of the mandibles (A:

Turned , B: TiOblast, C: SLA, D: TiUnite. Table 1 in study I). The implants type A, B and D were provided with healing abutments, while a healing cap was placed on the implants type C. The flaps were adjusted and sutured around the neck of all implants.

In the animal group 2, four implants with similar geometry and with two different surface characteristics (implant type A: Turned and B: TiUnite. Table 1 in study III) were placed pair-wise in a randomized order. All implants were provided with healing abutments and the flaps were adjusted and sutured around the neck of all implants.

In both animal groups the sutures were removed after 2 weeks and a plaque control program including daily cleaning of implants and teeth was initiated.

Active breakdown period

Three months after implant installation experimental peri-implantitis was initiated around all implants in both animal groups. Thus, the oral hygiene procedures were abandoned, cotton ligatures were placed in a submarginal position around the neck portion of the implants (Lindhe et al. 1992). The ligatures were replaced at week 3, 6, and 9. At week 12, when about 40–50% of the supporting bone was lost, the ligatures were removed.

Spontaneous progression of experimental peri-implantitis (Studies I, II and III)

After ligature removal, no oral hygiene procedures were performed. Thus, 24 and 26-week periods of plaque accumulation were allowed in the animal group 1 (study I and II) and 2 (study III), respectively.

Treatment of experimental peri-implantitis (Study IV)

After ligature removal oral hygiene procedures including daily cleaning of implants using toothbrush were implemented on the left side of the jaws in animal group 1. Four weeks later, surgical therapy was performed. No systemic antibiotics or local chemical antimicrobial therapy were provided before, during or after the surgical treatment. Full-thickness flaps were raised on the buccal and lingual aspects of the implants and inflamed tissue was removed by curettes. Mechanical cleaning of the implant surfaces was performed using gauzes impregnated with a sterile saline solution. Calculus on implant surfaces was chipped off with curettes. Profuse saline irrigation of the implants and the adjacent tissues was performed before adjustment and

suturing of the flaps around the neck portion of the implants. The sutures were removed 10 days after surgery and oral hygiene procedures were re-instituted and maintained during the subsequent 5-month period of the experiment.

Radiographic and clinical examinations

For all animals, radiographic and clinical examinations of the implant sites were performed during the pre-experimental period, during the active breakdown period (weeks 3, 6, 9 and 12) and during the spontaneous progression period (week 18, 26 and 36 for animal group 1) or the monitoring period (weeks 22, 28, 38 for animal group 2).

The clinical examination included assessments of plaque and visible signs of soft tissue inflammation (redness and swelling).

For each animal, standardized radiographs were obtained by creating an individual customized film holder (Hawe Super Bite, Hawe Neos Dental, Bioggio, Switzerland) with bite registration in a closed mouth position using a silicon material as previously described by Persson et al. (1999).

In the radiographs different landmarks were identified for each implant type. In animal group 1 (study I and IV), the abutment fixture junction was used as a reference point for implant categories A, B and D, while at the implants of type C the most apical point of the abutment screw was identified. In animal group 2 (study III), the abutment fixture junction was used as a reference point for both implant categories.

The radiographs were analyzed using an Olympus SZH10 stereo microscope (Tokyo, Japan) and digital images were obtained using a Leica DFC280 camera (Wetzlar, Germany). The vertical distance between the landmark and the marginal bone level was assessed at the mesial and distal aspects of each implant using the Leica QWin software (Leica Imaging Systems Ltd., Cambridge, UK).

In study I double assessments were made by two examiners with a 2-month interval.

Histological preparation and landmarks

At week 36 (study I, II and IV) and at week 38 (study III) the dogs were euthanized with a lethal dose of Sodium-Pentothal® (Hospira Enterprises B. V., Hoofddorp, Netherlands) and perfused through the carotid arteries with a fixative consisting of a mixture of 5% glutaraldehyde and 4% formaldehyde buffered to a pH of 7.2 (Karnovsky 1965). The mandibles were retrieved and

stored in the fixative. Tissue blocks containing the implant and the surrounding soft and hard tissues were dissected using a diamond saw (Exakt, Kulzer, Germany) and processed for ground sectioning according to the methods described by Donath & Breuner (1982). Each block was cut in a bucco-lingual plane using a cutting–grinding unit (Exakt, Apparatebau, Norderstedt, Germany). From each implant site, two central sections (buccal–lingual plane) were obtained and further reduced to a final thickness of about 20 µm using a micro- grinding unit (Exakt, Apparatebau). The remaining mesial and distal portions were remounted and cut in a perpendicular (mesio-distal) direction and two central sections were prepared from each unit. The sections were stained in toluidine blue or fibrin stain of Ladewig (Donath & Breuner 1982).

The histological examinations were performed in a Leica DM-RBE microscope (Leica, Heidelberg, Germany) equipped with the Leica QWin software imaging system (Leica Imaging Systems Ltd., Cambridge, UK).

The following landmarks were identified and used for the linear measurements. The marginal position of the peri-implant mucosa (PM), the abutment–fixture (A/F) junction (implant groups A, B, D in study II and IV and implant groups A, B in study III) or the border between the polished and the sandblasted large grit acid etched (SLA) surface (implant group C in study II and IV), the apical termination of the plaque/biofilm on the implant surface (aPlaque), the apical termination of the pocket epithelium (aPE), the marginal position of bone-to-implant contact (B), the bone crest (Bc), the most coronal and apical extension of the infiltrated connective tissue (cICT and aICT). The shortest distance between the ICT and the lateral bone wall of the intra-bony defects (ICT–B) was also measured. The surface areas of the ICT (area ICT) and the biofilm (Biofilm area) in the pocket compartment were evaluated by outlining their circumferences with a cursor.

Data analysis

Mean values for all variables were calculated for each implant in each animal. Differences were analyzed using analysis of variance (ANOVA) and the Student– Newman–Keuls test. The null hypothesis was rejected at $P < 0.05$.

Results

Clinical findings (Study I, II, III and IV)

In all studies healing after implant placement was uneventful with the exception of the loss of one type D implant 2 months after placement in animal group 1 (study IV). One dog in animal group 2 developed Addison's disease and was euthanized 2 months after implant installation.

Plaque formation during the active breakdown period resulted in overt signs of inflammation in the peri-implant mucosa of all implants. In animal group 2 (Study III), signs of inflammation persisted in the peri-implant mucosa during the spontaneous progression period.

In animal group 1 (Study I and II), one implant of type A and one implant of type D were lost during the spontaneous progression period. The implant of group A was lost on week 26 and the implant of group D was lost week 35 of the experiment.

In animal group 1 (Study IV), two implants of type D were lost following surgical therapy due to continuous loss of supporting bone. These implants were lost on weeks 26 and 33, respectively, i.e. at 10 and 18 weeks after surgical therapy.

At sites exposed to plaque control after ligature removal, plaque was virtually absent, while signs of inflammation in the peri-implant mucosae remained at the examination performed before surgical therapy. The plaque control exercised during the post-surgical treatment period resulted in an improvement of clinical signs of inflammation at implants of types A, B and C, while at implants of type D swelling and redness in the peri-implant mucosa persisted.

Radiographic findings (Study I, III and IV)

Spontaneous progression of experimental peri-implantitis at implants with different surface characteristics (Study I)

The amount of bone loss that occurred during the active breakdown period varied between 3.53 and 4.69mm.

The additional bone loss that occurred during the plaque accumulation period after ligature removal, i.e. between baseline and week 24, was 1.84 mm for implants in group A, 1.72 mm for implants in group B, 1.55 mm for the category C implants and 2.78 mm for the implants in group D. The difference between the type C and D implants was statistically significant. For the two implants that were lost during the experiment at week 26 (type A) and 35 (type D) respectively, the radiographic bone loss was judged to encompass the entire remaining intra-osseous portion of the implants. Thus for these implants additional bone loss of 3.09 mm for implant A and 2.05 mm for implant D were recorded at weeks 26 and 36 respectively.

The results from the reproducibility assessments of the radiographic measurements regarding intra-examiner variation revealed small differences between the two assessments. The variance and standard deviation (SD) were 0.09 and 0.29 for examiner 1 and 0.04 and 0.21 mm for examiner 2, respectively. The inter-examiner variance and SD were 0.05 and 0.23, respectively.

Spontaneous progression of experimental peri-implantitis at implants with similar geometry and different surface characteristics (Study III)

The amount of bone loss that occurred during the active breakdown period was 3.00 mm at implants of type A and 3.27 mm at implants of type B.

The mean bone loss during the period between ligature removal and biopsy (26 weeks) was 0.03 ± 0.50 mm for type A implants and 1.47 ± 0.65 mm for type B implants. This difference was statistically significant.

Treatment of experimental peri-implantitis at implants with different surface characteristics (Study IV)

The amount of bone loss that occurred during the active breakdown period, varied between 3.81 and 3.92 mm.

For the two implants that were lost after surgical therapy and before the final examination, the

radiographic bone loss at the following examination interval was judged to encompass the entire remaining intra-osseous portion of the implant.

Radiographic bone gain was observed between baseline (start of plaque control) and week 36 (final examination) at implants of type A (2.22 ± 1.49 mm), type B (1.59 ± 1.51 mm) and type C (0.89 ± 1.50 mm). At implants of type D, however, additional bone loss of 1.58 ± 2.61 mm occurred during the corresponding period. The difference between implant type D and implant type A was statistically significant.

Histological findings (Study II, III and IV)

Spontaneous progression of experimental peri-implantitis at implants with different surface characteristics (Study II and III)

The histological observations presented similar features with different degrees around all implants in study II and III.

Hence, extensive bone loss and large inflammatory cell infiltrates were visible in study II and III with PM-B values ranging between 7.44 ± 2.93 mm (implant A) and 8.67 ± 2.92 mm (implant D) in study II and between 4.69 ± 0.98 mm (implant A) and 6.04 ± 1.74 mm (implant B) in study III. Bone loss extended to the apical third of all implants and the lateral bone walls that lined the lesion formed a crater-like osseous defect.

Facing the osseous lesions the implant surfaces were colonized with varying amounts of plaque and calculus that extended from the supra-marginal portion of the implant to the apical compartment of the pocket. The distance between the abutment fixture junction and the most apical extension of the biofilm (A/F-aPlaque) ranged from 4.45 ± 0.72 mm (implant A) to 5.31 ± 1.40 mm (implant D) in study II and from 1.92 ± 1.14 mm (implant A) to 3.71 ± 1.39 mm (implant B) in study III. The difference between implants A and B in study III was statistically significant. The area of the pocket occupied by the biofilm (Plaque area) in study III was 0.06 ± 0.07 mm² (implant A) and 0.46 ± 0.45 mm² (implant B).

A wide zone of pus containing necrotic tissue and polymorphonuclear (PMN) cells separated the plaque from an ulcerated Pocket Epithelium (PE) and an ICT. The PE exhibited large rete peg formations and extended from the mucosal margin to a position of about 40–60% of the vertical dimension of the pocket. The PM-aPE were found between 3.10 ± 1.64 mm (implant A) and 4.70 ± 1.19 mm (implant C) in study II and between 3.23 ± 0.77 mm (implant A) and 5.06 ± 1.56 mm (implant B) in study III. The difference between implants A and B in study III was

statistically significant. The measured values for PM-B were consistently larger than the ones of PM-aPE, which demonstrates that no epithelial barrier was present between the ICT and the implant-borne biofilm in the most apical compartment of the lesions.

The vertical dimensions of the ICT (aICT-cICT) were ranging from 6.39 ± 1.69 mm (implant A) to 7.85 ± 2.81 mm (implant D) in study II and from 3.05 ± 1.02 mm (implant A) to 4.92 ± 1.81 mm (implant B) in study III. The difference between implants A and B in study III was statistically significant. In the lateral portion of ICT, which was facing the PE or the zone of pus, PMN cells were found in large numbers, while in the profound compartments of the ICT lymphocytes and plasma cells dominated. Multinucleated giant cells were also frequently found in the ICT area that was in direct contact with the biofilm or the layer of pus. The vascular density was high in the entire ICT and the majority of the vascular units were surrounded by a dense accumulation of emigrated leukocytes. In the lateral and apical zones of the ICT that was close to the bone walls of the defect, considerably large amounts of osteoclasts were found. Most of the osteoclasts resided in Howship's lacunae, while, occasionally, large multinucleated cells were also identified in the connective tissue compartment immediately lateral to the osseous surface. Thus, all sections revealed obvious signs of active tissue destruction including bone resorption.

Treatment of experimental peri-implantitis at implants with different surface characteristics (Study IV)

The histological analysis revealed different treatment outcomes between implant types. Thus, in sections representing implant types A (turned surface) and B (TiOblast surface), no biofilm was detected on the implant surface. A thin barrier epithelium lined the marginal portion of the peri-implant mucosa next to the turned or TiOblast surface of these implants. Apical to the barrier epithelium, a zone of connective tissue that was rich in collagen but poor in vascular structures and cells faced the threaded portion of the implant. Small clusters of inflammatory cells were occasionally found in the marginal portion of the connective tissue around the implant types A and B. The results from the histometric measurements revealed that the size of the remaining inflammatory cell infiltrate (ICT) in the peri-implant soft tissues varied between 0.30 ± 0.45 and 0.49 ± 0.65 mm² in sites representing implant types A and B.

The peri-implant mucosa formed around implants of type C (SLA surface) after surgical therapy contained inflammatory lesions of varying size. While few sites demonstrated clusters of inflammatory cells residing in the marginal portion of the connective tissue, the majority of

specimens representing implant type C exhibited well defined, moderately large inflammatory lesions that occupied a connective tissue compartment lateral to a barrier/pocket epithelium. The finding of inflammatory lesions in the soft tissues around implants of type C was consistently associated with the detection of a biofilm.

No signs of resolution following surgical treatment of peri-implantitis could be seen in sections representing the remaining sites of implant type D (TiUnite surface). Thus, the implant surface in this group was consistently covered by calculus and a biofilm and the adjacent mucosa harbored a large inflammatory cell infiltrate that extended from the margin of the soft tissue to the peri-implant bone. A pocket epithelium separated the inflammatory lesion from the biofilm in the marginal part of the mucosa, while in the apical portion the inflammatory cell infiltrate was in direct contact with the biofilm.

In this study, implants type C and D had larger ICT than implants type A and B. The respective areaICT values for implants type A, B, C and D amounted to $0.30 \pm 0.45 \text{ mm}^2$ (implant A), $0.49 \pm 0.65 \text{ mm}^2$ (implant B), 1.89 ± 2.33 (implant C) and $3.01 \pm 1.34 \text{ mm}^2$ (implant D). The distance between the apical border of the ICT and the peri-implant bone was 0.99 ± 0.11 and $0.87 \pm 0.51 \text{ mm}$ at implant types A and B. In sites representing implant type C and D, the distances were shorter and measured 0.52 ± 0.71 and $0.14 \pm 0.16 \text{ mm}$, respectively.

Main findings

Spontaneous progression of experimental peri-implantitis occurred after the removal of the ligatures (Study I, II and III)

Implant surface characteristics influenced the amount of spontaneous progression (Study I and III)

Spontaneous progression of experimental peri-implantitis resulted in large inflammatory cell infiltrates and associated crater-formed osseous defects (Study II, III)

Resolution of experimental peri-implantitis following treatment without systemic antibiotics or local antimicrobial therapy is possible (Study IV)

Surface characteristics of implants influenced the outcome of therapy (Study IV)

Concluding remarks

Despite the fact that most implants today present with different surface modifications, there is still no evidence indicating that such modifications are superior to implants with no modification in terms of marginal bone preservation (Abrahamsson & Berglundh 2009). Therefore, comparisons between modified surfaces and non-modified surfaces showing better outcomes appear to be based on results from animal experiments where surrogate endpoints (e.g. bone to implant contact % or removal torque values) were used. In this context, the findings from the present series of studies appear relevant as they indicate that tissue reactions under different disease models are different between implants with varying surface characteristics and as they provide with clinically relevant endpoints.

Validity of the experimental model

The experimental model used in the present series of studies is developed from previous experimental protocols on periodontitis with ligatures. Thus, Lindhe et al. (1978) used ligatures to induce experimental periodontitis for 6 months in 4 different groups of dogs. The areas of infiltrated connective tissue (ICT) in sites where ligatures were left in place without oral hygiene for 6 or 12 months occupied about 72% and 69%, respectively, of the total gingival area. At sites where the ligatures were removed and free plaque accumulation allowed for 6 months, the corresponding ICT area was 22%. Attachment loss at sites with and without ligatures during the last 6 months was 46% and 36% respectively, of the total root length, thus demonstrating the role of ligatures in the promotion of attachment loss around teeth. Ligatures can play a similar role around implants to induce rapid experimental peri-implantitis characterized by large ICT and bone loss (Lindhe et al. 1992). In the present series of studies ligatures were placed in a “sub-gingival” position. The ligatures disrupted the mechanical soft tissue barrier and allowed biofilm formation in a profound position of the pocket. By keeping the pocket open for plaque accumulation an inflammatory reaction developed in the soft tissue followed by bone loss. The repeated replacement of ligatures in an apical position leads to an apical migration of the inflammatory soft tissue lesion and further bone loss. The bone level alteration values for the “active breakdown” phase in study I ranged from 3.53mm to 4.69mm, from 3.00mm to 3.27mm in study III and from 3.81mm to 3.92mm in study IV. The objective in the “active breakdown” phase is to perform rapid loss of attachment that is measured on radiographs. This procedure is

performed by ligature placement, evaluation of the attachment loss and ligature replacement every two weeks. The position of each new ligature depends on the amount of bone destruction achieved with the previous one. Considering that the ligatures are interposed between the implant surface and the soft tissue barrier, it is not surprising that they contribute to biofilm formation and thereby influence the tissue response. Therefore the active breakdown is operator- and ligature dependent and not likely influenced by surface characteristics of the implant. Other studies reporting on the active phase of ligature-induced peri-implantitis at implants with different surface characteristics could not demonstrate differences between the implant types (Tillmanns et al. 1997, Tillmanns et al. 1998, Shibli et al. 2003c, Martins et al. 2004).

Spontaneous progression of experimental peri-implantitis occurred in all implants (Study I, II and III)

We found in studies I, II and III that bone loss could progress spontaneously over a 6-month period after removal of the ligatures. This is in agreement with observations made by Marinello et al. (1995) who in an experimental study in dogs, observed tissue reactions after ligature removal around screw shape turned titanium implants. At 1 month after ligature removal, a consistent presence of large infiltrated connective tissue in contact with the bone was found in 5 out of 8 implants. At 3 months after ligature removal, one of the three dogs had lost 3 out of 4 implants due to spontaneous progression of the disease. In a similar experiment Zitzmann et al. (2004) performed ligature induced peri-implantitis around 21 screw shape turned titanium implants in 5 dogs. After ligature removal, a 12-month period of free plaque accumulation continued. 16 out of 21 implants demonstrated additional bone loss; 10 implants lost up to 1mm, 2 implants between 1 and 2mm and 4 implants lost more than 2 mm. The data from the studies by Marinello et al. (1995) and Zitzmann et al. (2004) should be analyzed in regards to amount of bone loss found around implants with a similar type of surface (turned) in studies I and III (1.84mm and 0.03mm respectively). The differences in the degree of spontaneous progression between the studies may be host related or influenced by the length of the observation period. The difference in bone loss during the spontaneous progression period between implants with TiUnite and turned surfaces in study I was comparable to the corresponding difference in study III.

Bone loss is a consequence of large inflammatory cell infiltrates associated with biofilm accumulation on the implant surfaces (Study II, III)

In studies II and III the tissues around the implants exhibited large inflammatory cell infiltrates and bone loss. Biofilm was consistently found along the surface of the implants facing the pocket area. Often, the apical extension of the biofilm was located more apically than the termination of the pocket epithelium, which was kept at a distance from the implant surface by the interposition of biofilm and pus. Therefore, an area of open wound was observed facing the biofilm in the most apical part of the pocket area. The inflammatory cell infiltrate in the connective tissue was in very close proximity to the bone.

Lindhe and Ericsson (1978) in a study in dogs reported that a residual ICT was present in the tissues around teeth 6 months after the removal of the ligatures. Furthermore, previous studies on spontaneous progression of bone loss around implants after ligature removal have also reported on associated large areas of infiltrated connective tissue (Marinello et al. 1995, Zitzmann et al. 2004, Berglundh et al. 2007b). Other studies have observed spontaneous progression over a 12-months period despite an oral hygiene regimen (Shibli et al. 2003a, Martins et al. 2005).

Surface characteristics of implants influenced the amount of spontaneous progression (Study I and III)

Our first two studies demonstrated a more extensive spontaneous progression of disease around TiUnite implants than around the other three groups. Berglundh et al. (2007b) however, induced experimental peri-implantitis around implants with similar geometry but large differences in surface roughness (Sa values of 0.35 μ m and 2.29 μ m). 5 months after removal of the ligatures the rougher implants has lost 1.12mm of bone while only 0.07mm were lost at the polished ones.

Two studies (Shibli et al. 2003a, Martins et al. 2005) reporting on the same group of dogs, demonstrated spontaneous bone loss after ligature removal around four different implant types in 6 dogs. The implant surfaces were, TPS, HA coated, Acid etched and Acid etched with turned surface in the first 3 threads. Each specific surface was represented by 9 implants. One year after ligature removal 17 out of 36 implants had been lost due to continuous bone loss. The lost implants were 5 HA coated, 4 etched, 4 turned and 3 TPS. The implants were lost despite

daily scrubbing with 0.12% chlorhexidine and monthly scaling of the abutments. This clinical result in itself is in agreement with findings from study I, II and III of the present series and previous publications (Marinello et al. 1995, Zitzmann et al. 2004, Berglundh et al. 2007b).

Spontaneous progression of experimental peri-implantitis was more pronounced at implants with a TiUnite surface than at implants with a turned surface (Study I, II and III)

Studies I and II are reports on screw shaped implants that were commercially available at the time of the studies. To further reduce possible confounding variables due to differences in implant geometry, study III compared two implants of the same design from the same system but with different surface characteristics, both commercially available. In accordance with findings in studies I and II, study III demonstrated the difference between the TiUnite surface and the turned surface in spontaneous progression of experimental peri-implantitis. It is clear that the observed bone loss was a response to the bacterial challenge and that the surfaces which demonstrated more plaque also demonstrated a larger ICT and more bone loss. These findings are in agreement with Berglundh et al. (2007b)

Turned surface implants are considered minimally rough, while the TiOblast, SLA and TiUnite surfaces are classified as moderately rough (Albrektsson & Wennerberg 2004). One roughness parameter is the Sa value, which provides 3D information about the surface and is more consistent and reliable than the average roughness (Ra) value because it is not influenced by measurement direction. In addition, a spatial parameter is necessary for proper analysis (Wennerberg & Albrektsson 2010). The developed surface area ratio (Sdr) is a measurement that gives information about the enlargement of a surface area as if a given surface was to be flattened out. It is dependant on the Sa value as well as on the density and height of peaks on a given surface. The respective Sa and Sdr values are 0.46 μm and 11.6% for the turned implants, 1.1 μm and 31% for the TiOblast, 1.5 μm and 34% for SLA implants and for 1.1 μm and 37% TiUnite implants (Wennerberg & Albrektsson 2010). Based on these values the 4 surface characteristics are very similar except for lower values for the Turned implant. Therefore, the different behavior in our experiments may be related to other characteristics than roughness, such as the presence of porosities for example. A recent codification is proposed in order to give a more complete description of a given implant surface (Dohan Ehrenfest et al. 2010). It is based on five characteristics: the core material, its chemical modification, its micro topography,

its nano topography and its global architecture. However, the codification for current implant systems has not been published at this date.

Resolution of experimental peri-implantitis following surgical treatment without systemic antibiotics or local antiseptics is possible (Study IV)

Study IV in the present series, demonstrated successful surgical treatment results without the use of systemic antibiotics, which is in agreement with previous studies. Gründer et al. (1993) compared four surgical techniques in 10 dogs with 2 implants per jaw. The surgical procedures performed were: debridement with submerged or non-submerged flap closure and regenerative techniques with ePTFE membranes in a submerged or non-submerged situation. The implant surfaces were prepared with an airflow powder instrument without local antimicrobial agents. Topical applications of chlorhexidine were provided post operatively but no systemic antibiotics were used. All treatments were successful. Shibli et al. (2003a) performed laser treatment. No systemic antibiotics were used in this experiment and the surface of the implants and of the osseous defects were treated with toluidine blue before laser irradiation. A similar protocol was used by the same group in a dog experiment designed to compare laser treatment of experimental peri-implantitis around five different implant surfaces (Shibli et al. 2006). Both reports presented successful clinical and histological outcomes without the use of systemic antibiotics.

Outcome of the therapy is influenced by the surface characteristics of the implants (Study IV)

It was stated in the Consensus report on peri-implant diseases of the 6th European Workshop in Periodontology that successful surgical treatment of peri-implantitis “must include parameters that describe resolution of inflammation and preservation of the supporting bone” (Lindhe & Meyle 2008). More specifically, the primary objective of surgical treatment of peri-implantitis is to “get access to the implant surface for debridement and decontamination...” (Lindhe & Meyle 2008).

In study IV the treatment protocol was based on an open flap debridement surgical approach associated to the decontamination of the implant surfaces with cotton pellets impregnated with

saline solution. The flaps were sutured around the implants in a non-submerged approach. Our protocol did not consider any reconstructive or regenerative effect.

However, successful clinical and radiographic endpoints for treatment were achieved for the turned, Tioblast and SLA surfaces implants, while the TiUnite surface implants demonstrated persisting clinical signs of soft tissue inflammation and continuous progression of bone loss.

From a histological standpoint, TiOblast implants consistently demonstrated similar findings as the turned implants, which were devoid of biofilm and of ICT. Resolution of inflammation at SLA implants, however, was less consistent with various amounts of biofilm on the implant surfaces and remains of inflammatory lesions in the connective tissue. TiUnite surfaces were contaminated with large amounts of biofilm and associated with large ICT in the tissue and continuous bone destruction.

As previously mentioned it is difficult to speculate on the reasons for the finding of different outcomes between the implant groups. However, one experiment demonstrated that previously contaminated TiUnite surfaces can osseointegrate. Alhag et al. (2008) demonstrated in a dog study the ability for previously contaminated TiUnite surfaces to osseointegrate in pristine bone. Implants were partially inserted in the bone and left to protrude in the oral environment to allow for contamination for a period of 5 weeks. Three surface treatments were provided; citric acid for 30 seconds plus saline impregnated cotton pellets, saline impregnated toothbrush for 1min, and 10% H₂O₂ impregnated cotton pellet for 1 minute plus saline rinse. Finally the implants were removed and inserted to their full lengths in a freshly drilled pristine bone site. Despite less amounts of bone to implant contact in the previously contaminated areas, osseointegration was observed at the implants without differences between the decontamination methods. Kolodinis et al (2003) achieved similar findings in a similar experiment around turned surface implants. However, it should be mentioned, as the authors report in their discussion, that this experimental model was designed as a “proof of principle” and is not intended to provide direct information on the treatment of experimental peri-implantitis.

The surgical procedure utilized in study IV is a non-submerged approach similar to that of Ericsson et al (1996), who successfully treated turned implants after experimental peri-implantitis. Gründer et al. (1993) could not demonstrate any differences in clinical or histological outcome parameters when comparing submerged and non-submerged techniques with or without ePTFE membranes in the treatment of experimental peri-implantitis around turned implants.

While studies have demonstrated that surface decontamination is a prerequisite for treatment of experimental peri-implantitis, different means can be used to achieve an acceptable degree of decontamination to obtain histological resolution of the inflammatory lesions. Persson et al. (2001b) demonstrated that the replacement of a contaminated implant part with a pristine sterile component led to reosseointegration thereby emphasizing the importance of surface decontamination. Persson (1999) et al. compared the results of treatment of experimental peri-implantitis in a submerged approach around machined titanium screw shape implants. The implants were decontaminated by the means of cotton pellets impregnated in saline solution or a rotating brush and an abrasive compound (pumice). Both techniques gave similar clinical outcomes and no differences could be demonstrated in terms of amount of reosseointegration. The histological observations made by Persson et al. (1999) are consistent with our findings around turned and TiOblast implants in study III presenting the absence of biofilm on the implant surface and a thin barrier epithelium and dense connective tissue facing the surface of the implants.

The question remains, however, if the other moderately rough surfaces used in study IV were properly decontaminated. In a series of studies Persson et al. (2001a, 2004) provided evidence for the use of saline impregnated cotton pellets around rough implants (experimental SLA with Sa value of 2.29 μ m) (Sennerby et al. 2005). In the studies by Persson et al. (2001, 2004), the effect of cleaning with saline impregnated cotton pellets were compared to rubber cups with an abrasive paste (pumice) or to carbon dioxide laser in combination with hydrogen peroxide. In both studies the saline impregnated cotton pellets gave similar clinical, radiographic and histological results as the other treatment protocols.

Wetzel et al. (1999) compared guided bone regeneration (GBR) and a sham procedure on TPS, SLA and machined implants. The “sham” procedure consisted of an open flap debridement with decontamination of the implant surfaces by the means of curettes and chlorhexidine with a submerged healing. Clinical and radiographic parameters were not reported. No difference could be demonstrated in terms of procedure (“sham” or GBR) or surface characteristics when observing reosseointegration. Furthermore, Schou et al. (2003) compared four different methods for decontamination of TPS surface implants. No difference in terms of clinical radiographic outcomes or amount of reosseointegration could be demonstrated between the different techniques. The authors recommended the use of saline solution and chlorhexidine.

Taken together, these results are in agreement with the findings in study IV that saline impregnated cotton pellets could provide efficient decontamination also on moderately rough surfaces.

Clinical implications

Clinical conclusions may not be directly inferred from this series of studies.

However, the findings point to important questions regarding implant surface characteristics, soft tissue behavior and response to treatment. Current descriptive features of surface characterization of implants do not seem to correlate entirely with biofilm formation/removal and tissue response.

Furthermore, new implants should not only be evaluated in terms of bone to implant contact or removal torque values, but also in relation to their behavior when exposed to bacterial challenge. For that purpose, the dog model and its clinical, radiographic and histological endpoints are suitable. Various decontamination methods and treatment protocols can also be approached via the dog model.

From a clinical perspective it seems as if the first line of observation would be cross-sectional studies on the prevalence of peri-implantitis among the most commonly used implant types. Finally controlled clinical studies regarding prevention and treatment of peri-implantitis in the light of surface characteristics would also be of interest.

References

- Abrahamsson, I., Albouy, J. P. & Berglundh, T. (2008) Healing at fluoride-modified implants placed in wide marginal defects: an experimental study in dogs. *Clinical Oral Implants Research* **19**, 153-159.
- Abrahamsson, I., Berglundh, T., Glantz, P. O. & Lindhe, J. (1998) The mucosal attachment at different abutments. An experimental study in dogs. *Journal of Clinical Periodontology* **25**, 721-727.
- Acland, G. M., Aguirre, G. D., Ray, J., Zhang, Q., Aleman, T. S., Cideciyan, A. V., Pearce-Kelling, S. E., Anand, V., Zeng, Y., Maguire, A. M., Jacobson, S. G., Hauswirth, W. W. & Bennett, J. (2001) Gene therapy restores vision in a canine model of childhood blindness. *Nature Genetics* **28**, 92-95.
- Adell, R., Eriksson, B., Lekholm, U., Brånemark, P. I. & Jemt, T. (1990) Long-term follow-up study of osseointegrated implants in the treatment of totally edentulous jaws. *The International Journal of Oral & Maxillofacial Implants* **5**, 347-359.
- Adell, R., Lekholm, U., Rockler, B. & Brånemark, P. I. (1981) A 15-year study of osseointegrated implants in the treatment of the edentulous jaw. *The International Journal of Oral Surgery* **10**, 387-416.
- Albrektsson, T. & Wennerberg, A. (2004) Oral implant surfaces: Part 1--review focusing on topographic and chemical properties of different surfaces and in vivo responses to them. *The International Journal of Prosthodontics* **17**, 536-543.
- Alhag, M., Renvert, S., Polyzois, I. & Claffey, N. (2008) Re-osseointegration on rough implant surfaces previously coated with bacterial biofilm: an experimental study in the dog. *Clinical Oral Implants Research* **19**, 182-187.
- Åstrand, P., Engquist, B., Anzén, B., Bergendal, T., Hallman, M., Karlsson, U., Kvint, S., Lysell, L. & Rundcranz, T. (2004) A three-year follow-up report of a comparative study of ITI Dental Implants and Brånemark System implants in the treatment of the partially edentulous maxilla. *Clinical Implant Dentistry and Related Research* **6**, 130-141.
- Åstrand, P., Engquist, B., Dahlgren, S., Engquist, E., Feldmann, H. & Gröndahl, K. (1999) Astra Tech and Branemark System implants: a prospective 5-year comparative study. Results after one year. *Clinical Implant Dentistry and Related Research* **1**, 17-26.

- Baelum, V. & Ellegaard, B. (2004) Implant survival in periodontally compromised patients. *Journal of Periodontology* **75**, 1404-1412.
- Bainbridge, J. W., Smith, A. J., Barker, S. S., Robbie, S., Henderson, R., Balaggan, K., Viswanathan, A., Holder, G. E., Stockman, A., Tyler, N., Petersen-Jones, S., Bhattacharya, S. S., Thrasher, A. J., Fitzke, F. W., Carter, B. J., Rubin, G. S., Moore, A. T. & Ali, R. R. (2008) Effect of gene therapy on visual function in Leber's congenital amaurosis. *The New England Journal of Medicine* **358**, 2231-2239.
- Berglundh, T., Abrahamsson, I., Albouy, J.-P. & Lindhe, J. (2007a) Bone healing at implants with a fluoride-modified surface: an experimental study in dogs. *Clinical Oral Implants Research* **18**, 147-152.
- Berglundh, T., Gotfredsen, K., Zitzmann, N. U., Lang, N. P. & Lindhe, J. (2007b) Spontaneous progression of ligature induced peri-implantitis at implants with different surface roughness: an experimental study in dogs. *Clinical Oral Implants Research* **18**, 655-661.
- Berglundh, T., Lindhe, J., Marinello, C., Ericsson, I. & Liljenberg, B. (1992) Soft tissue reaction to de novo plaque formation on implants and teeth. An experimental study in the dog. *Clinical Oral Implants Research* **3**, 1-8.
- Berglundh, T., Persson, L. & Klinge, B. (2002) A systematic review of the incidence of biological and technical complications in implant dentistry reported in prospective longitudinal studies of at least 5 years. *Journal of Clinical Periodontology* **29 Suppl 3**, 197-212; discussion 232-193.
- Brånemark, P. I., Hansson, B. O., Adell, R., Breine, U., Lindström, J., Hallén, O. & Öhman, A. (1977) Osseointegrated implants in the treatment of the edentulous jaw. Experience from a 10-year period. *Scandinavian Journal of Plastic and Reconstructive Surgery Supplement* **16**, 1-132.
- Buser, D., Broggin, N., Wieland, M., Schenk, R., Denzer, A., Cochran, D., Hoffmann, B., Lussi, A. & Steinemann, S. (2004) Enhanced bone apposition to a chemically modified SLA titanium surface. *Journal of Dental Research* **83**, 529-533.
- Claffey, N., Clarke, E., Polyzois, I. & Renvert, S. (2008) Surgical treatment of peri-implantitis. *Journal of Clinical Periodontology* **35**, 316-332.
- Dohan Ehrenfest, D. M., Coelho, P. G., Kang, B. S., Sul, Y. T. & Albrektsson, T. (2010) Classification of osseointegrated implant surfaces: materials, chemistry and topography. *Trends in Biotechnology* **28**, 198-206.

- Donath, K. & Breuner, G. (1982) A method for the study of undecalcified bones and teeth with attached soft tissues. The Sage-Schliff (sawing and grinding) technique. *Journal of Oral Pathology* **11**, 318-326.
- Ellingsen, J. E., Johansson, C. B., Wennerberg, A. & Holmen, A. (2004) Improved retention and bone to implant contact with fluoride-modified titanium implants. *The International Journal of Oral & Maxillofacial Implants* **19**, 659-666.
- Ericsson, I., Berglundh, T., Marinello, C., Liljenberg, B. & Lindhe, J. (1992) Long-standing plaque and gingivitis at implants and teeth in the dog. *Clinical Oral Implants Research* **3**, 99-103.
- Ericsson, I., Johansson, C. B., Bystedt, H. & Norton, M. R. (1994) A histomorphometric evaluation of bone-to-implant contact on machine-prepared and roughened titanium dental implants. A pilot study in the dog. *Clinical Oral Implants Research* **5**, 202-206.
- Ericsson, I., Lindhe, J., Rylander, H. & Okamoto, H. (1975) Experimental periodontal breakdown in the dog. *The Scandinavian Journal of Dental Research* **83**, 189-192.
- Ericsson, I., Persson, L. G., Berglundh, T., Edlund, T. & Lindhe, J. (1996) The effect of antimicrobial therapy on periimplantitis lesions. An experimental study in the dog. *Clinical Oral Implants Research* **7**, 320-328.
- Esposito, M., Coulthard, P., Thomsen, P. & Worthington, H. V. (2005) Interventions for replacing missing teeth: different types of dental implants. *Cochrane database of systematic reviews (Online)*, CD003815.
- Felsburg, P. J. (2002) Overview of immune system development in the dog: comparison with humans. *Human & Experimental Toxicology* **21**, 487-492.
- Fields, S. & Johnston, M. (2005) Cell biology. Whither model organism research? *Science* **307**, 1885-1886.
- Fransson, C., Lekholm, U., Jemt, T. & Berglundh, T. (2005) Prevalence of subjects with progressive bone loss at implants. *Clinical Oral Implants Research* **16**, 440-446.
- Gad, T. (1968) Periodontal disease in dogs. 1. Clinical investigations. *Journal of Periodontal Research* **3**, 268-272.
- Gotfredsen, K., Berglundh, T. & Lindhe, J. (2000) Anchorage of titanium implants with different surface characteristics: an experimental study in rabbits. *Clinical Implant Dentistry and Related Research* **2**, 120-128.

- Gotfredsen, K. & Karlsson, U. (2001) A prospective 5-year study of fixed partial prostheses supported by implants with machined and TiO₂-blasted surface. *Journal of Prosthodontics* **10**, 2-7.
- Gotfredsen, K., Nimb, L., Hjorting-Hansen, E., Jensen, J. S. & Holmen, A. (1992) Histomorphometric and removal torque analysis for TiO₂-blasted titanium implants. An experimental study on dogs. *Clinical Oral Implants Research* **3**, 77-84.
- Grunder, U., Hürzeler, M., Schüpbach, P. & Strub, J. (1993) Treatment of ligature-induced peri-implantitis using guided tissue regeneration: a clinical and histologic study in the beagle dog. *The International Journal of Oral & Maxillofacial Implants* **8**, 282-293.
- Hickey, J., O'Neal, R., Scheidt, M., Strong, S., Turgeon, D. & Van Dyke, T. (1991) Microbiologic characterization of ligature-induced peri-implantitis in the microswine model. *Journal of Periodontology* **62**, 548-553.
- Holsapple, M. P., West, L. J. & Landreth, K. S. (2003) Species comparison of anatomical and functional immune system development. *Birth Defects Research (Part B)* **68**, 321-334.
- Ivanoff, C., Widmark, G., Johansson, C. & Wennerberg, A. (2003) Histologic evaluation of bone response to oxidized and turned titanium micro-implants in human jawbone. *The International Journal of Oral & Maxillofacial Implants* **18**, 341-348.
- Karnovsky, M. J. (1965) A formaldehyde-glutaraldehyde fixative of high osmolarity for use in electron microscopy. *Journal of Cell Biology*, 137A-138A.
- Kennedy, J. E. & Polson, A. M. (1973) Experimental marginal periodontitis in squirrel monkeys. *Journal of Periodontology* **44**, 140-144.
- Koldslund, O. C., Scheie, A. A. & Aass, A. M. (2010) Prevalence of peri-implantitis related to severity of the disease with different degrees of bone loss. *Journal of Periodontology* **81**, 231-238.
- Kolonidis, S. G., Renvert, S., Hämmerle, C. H. F., Lang, N. P., Harris, D. & Claffey, N. (2003) Osseointegration on implant surfaces previously contaminated with plaque. An experimental study in the dog. *Clinical Oral Implants Research* **14**, 373-380.
- Lang, N., Brägger, U., Walther, D., Beamer, B. & Kornman, K. (1993) Ligature-induced peri-implant infection in cynomolgus monkeys. I. Clinical and radiographic findings. *Clinical Oral Implants Research* **4**, 2-11.

- Lindhe, J., Berglundh, T., Ericsson, I., Liljenberg, B. & Marinello, C. (1992) Experimental breakdown of peri-implant and periodontal tissues. A study in the beagle dog. *Clinical Oral Implants Research* **3**, 9-16.
- Lindhe, J. & Ericsson, I. (1978) Effect of ligature placement and dental plaque on periodontal tissue breakdown in the dog. *Journal of Periodontology* **49**, 343-350.
- Lindhe, J., Hamp, S. & Löe, H. (1973) Experimental periodontitis in the beagle dog. *Journal of Periodontal Research* **8**, 1-10.
- Lindhe, J., Hamp, S. E. & Löe, H. (1975) Plaque induced periodontal disease in beagle dogs. A 4-year clinical, roentgenographical and histometrical study. *Journal of Periodontal Research* **10**, 243-255.
- Lindhe, J. & Meyle, J. (2008) Peri-implant diseases: Consensus Report of the Sixth European Workshop on Periodontology. *Journal of Clinical Periodontology* **35**, 282-285.
- Maguire, A. M., Simonelli, F., Pierce, E. A., Pugh, E. N., Jr., Mingozi, F., Bennicelli, J., Banfi, S., Marshall, K. A., Testa, F., Surace, E. M., Rossi, S., Lyubarsky, A., Arruda, V. R., Konkle, B., Stone, E., Sun, J., Jacobs, J., Dell'Osso, L., Hertle, R., Ma, J. X., Redmond, T. M., Zhu, X., Hauck, B., Zeleniaia, O., Shindler, K. S., Maguire, M. G., Wright, J. F., Volpe, N. J., McDonnell, J. W., Auricchio, A., High, K. A. & Bennett, J. (2008) Safety and efficacy of gene transfer for Leber's congenital amaurosis. *The New England Journal of Medicine* **358**, 2240-2248.
- Marinello, C., Berglundh, T., Ericsson, I., Klinge, B., Glantz, P. & Lindhe, J. (1995) Resolution of ligature-induced peri-implantitis lesions in the dog. *Journal of Clinical Periodontology* **22**, 475-479.
- Martins, M. C., Abi-Rached, R. S. G., Shibli, J. A., Araujo, M. W. B. & Marcantonio, E. (2004) Experimental peri-implant tissue breakdown around different dental implant surfaces: clinical and radiographic evaluation in dogs. *The International Journal of Oral & Maxillofacial Implants* **19**, 839-848.
- Martins, M. C., Shibli, J. A., Abi-Rached, R. S. G. & Marcantonio, E. (2005) Progression of experimental chronic peri-implantitis in dogs: clinical and radiographic evaluation. *Journal of Periodontology* **76**, 1367-1373.

- Moberg, L., Kondell, P., Sagulin, G., Bolin, A., Heimdahl, A. & Gynther, G. (2001) Branemark System and ITI Dental Implant System for treatment of mandibular edentulism. A comparative randomized study: 3-year follow-up. *Clinical Oral Implants Research* **12**, 450-461.
- Nociti, F. H., Jr., Cesco De Toledo, R., Machado, M. A., Stefani, C. M., Line, S. R. & Goncalves, R. B. (2001) Clinical and microbiological evaluation of ligature-induced peri-implantitis and periodontitis in dogs. *Clinical Oral Implants Research* **12**, 295-300.
- Ostrander, E. A., Galibert, F. & Patterson, D. F. (2000) Canine genetics comes of age. *Trends in Genetics* **16**, 117-124.
- Ostrander, E. A. & Giniger, E. (1997) Semper fidelis: what man's best friend can teach us about human biology and disease. *American Journal of Human Genetics* **61**, 475-480.
- Parker, H. G., Shearin, A. L. & Ostrander, E. A. (2010) Man's best friend becomes biology's best in show: genome analyses in the domestic dog. *Annual Review of Genetics* **44**, 309-336.
- Persson, L. G., Araujo, M. G., Berglundh, T., Gröndahl, K. & Lindhe, J. (1999) Resolution of peri-implantitis following treatment. An experimental study in the dog. *Clinical Oral Implants Research* **10**, 195-203.
- Persson, L. G., Berglundh, T., Lindhe, J. & Sennerby, L. (2001a) Re-osseointegration after treatment of peri-implantitis at different implant surfaces. An experimental study in the dog. *Clinical Oral Implants Research* **12**, 595-603.
- Persson, L. G., Ericsson, I., Berglundh, T. & Lindhe, J. (1996) Guided bone regeneration in the treatment of periimplantitis. *Clinical Oral Implants Research* **7**, 366-372.
- Persson, L. G., Ericsson, I., Berglundh, T. & Lindhe, J. (2001b) Osseointegration following treatment of peri-implantitis and replacement of implant components. An experimental study in the dog. *Journal of Clinical Periodontology* **28**, 258-263.
- Persson, L. G., Mouhyi, J., Berglundh, T., Sennerby, L. & Lindhe, J. (2004) Carbon dioxide laser and hydrogen peroxide conditioning in the treatment of periimplantitis: an experimental study in the dog. *Clinical Implant Dentistry and Related Research* **6**, 230-238.
- Rivera, P., Melin, M., Biagi, T., Fall, T., Haggstrom, J., Lindblad-Toh, K. & von Euler, H. (2009) Mammary tumor development in dogs is associated with BRCA1 and BRCA2. *Cancer Research* **69**, 8770-8774.

- Roos-Jansåker, A.-M., Lindahl, C., Renvert, H. & Renvert, S. (2006) Nine- to fourteen-year follow-up of implant treatment. Part II: presence of peri-implant lesions. *Journal of Clinical Periodontology* **33**, 290-295.
- Rovin, S., Costich, E. R. & Gordon, H. A. (1966) The influence of bacteria and irritation in the initiation of periodontal disease in germfree and conventional rats. *Journal of Periodontal Research* **1**, 193-204.
- Saxe, S. R., Greene, J. C., Bohannon, H. M. & Vermillion, J. R. (1967) Oral debris, calculus, and periodontal disease in the beagle dog. *Periodontics* **5**, 217-225.
- Schou, S., Holmstrup, P., Jørgensen, T., Skovgaard, L. T., Stoltze, K., Hjørting-Hansen, E. & Wenzel, A. (2003) Implant surface preparation in the surgical treatment of experimental peri-implantitis with autogenous bone graft and ePTFE membrane in cynomolgus monkeys. *Clinical Oral Implants Research* **14**, 412-422.
- Schou, S., Holmstrup, P., Reibel, J., Juhl, M., Hjørting-Hansen, E. & Kornman, K. (1993a) Ligature-induced marginal inflammation around osseointegrated implants and ankylosed teeth: stereologic and histologic observations in cynomolgus monkeys (*Macaca fascicularis*). *Journal of Periodontology* **64**, 529-537.
- Schou, S., Holmstrup, P., Stoltze, K., Hjørting-Hansen, E. & Kornman, K. S. (1993b) Ligature-induced marginal inflammation around osseointegrated implants and ankylosed teeth. *Clinical Oral Implants Research* **4**, 12-22.
- Schwarz, F., Sager, M., Ferrari, D., Herten, M., Wieland, M. & Becker, J. (2008) Bone regeneration in dehiscence-type defects at non-submerged and submerged chemically modified (SLActive) and conventional SLA titanium implants: an immunohistochemical study in dogs. *Journal of Clinical Periodontology* **35**, 64-75.
- Sennerby, L., Persson, L., Berglundh, T., Wennerberg, A. & Lindhe, J. (2005) Implant stability during initiation and resolution of experimental periimplantitis: an experimental study in the dog. *Clinical Implant Dentistry and Related Research* **7**, 136-140.
- Shibli, J., Martins, M., Nociti, F., Garcia, V. & Marcantonio, E. (2003a) Treatment of ligature-induced peri-implantitis by lethal photosensitization and guided bone regeneration: a preliminary histologic study in dogs. *Journal of Periodontology* **74**, 338-345.

- Shibli, J., Martins, M., Theodoro, L., Lotufo, R., Garcia, V. & Marcantonio, E. (2003b) Lethal photosensitization in microbiological treatment of ligature-induced peri-implantitis: a preliminary study in dogs. *Journal of Oral Sciences* **45**, 17-23.
- Shibli, J. A., Martins, M. C., Lotufo, R. F. M. & Marcantonio, E. (2003c) Microbiologic and radiographic analysis of ligature-induced peri-implantitis with different dental implant surfaces. *The International Journal of Oral & Maxillofacial Implants* **18**, 383-390.
- Shibli, J. A., Martins, M. C., Ribeiro, F. S., Garcia, V. G., Nociti, F. H. & Marcantonio, E. (2006) Lethal photosensitization and guided bone regeneration in treatment of peri-implantitis: an experimental study in dogs. *Clinical Oral Implants Research* **17**, 273-281.
- Swenson, H. M. (1947) Experimental periodontal pockets in dogs. *Journal of Dental Research* **26**, 273-275.
- Tillmanns, H. W., Hermann, J. S., Cagna, D. R., Burgess, A. V. & Meffert, R. M. (1997) Evaluation of three different dental implants in ligature-induced peri-implantitis in the beagle dog. Part I. Clinical evaluation. *The International Journal of Oral & Maxillofacial Implants* **12**, 611-620.
- Tillmanns, H. W., Hermann, J. S., Tiffée, J. C., Burgess, A. V. & Meffert, R. M. (1998) Evaluation of three different dental implants in ligature-induced peri-implantitis in the beagle dog. Part II. Histology and microbiology. *The International Journal of Oral & Maxillofacial Implants* **13**, 59-68.
- Wennerberg, A. & Albrektsson, T. (2010) On implant surfaces: a review of current knowledge and opinions. *The International Journal Oral & Maxillofacial Implants* **25**, 63-74.
- Wennerberg, A., Hallgren, C., Johansson, C. & Danelli, S. (1998) A histomorphometric evaluation of screw-shaped implants each prepared with two surface roughnesses. *Clinical Oral Implants Research* **9**, 11-19.
- Wennström, J. L., Ekstubbe, A., Gröndahl, K., Karlsson, S. & Lindhe, J. (2004) Oral rehabilitation with implant-supported fixed partial dentures in periodontitis-susceptible subjects. A 5-year prospective study. *Journal of Clinical Periodontology* **31**, 713-724.
- Wetzel, A. C., Vlassis, J., Caffesse, R. G., Hämmerle, C. H. & Lang, N. P. (1999) Attempts to obtain re-osseointegration following experimental peri-implantitis in dogs. *Clinical Oral Implants Research* **10**, 111-119.

- Zetterqvist, L., Feldman, S., Rotter, B., Vincenzi, G., Wennström, J. L., Chierico, A., Stach, R. M. & Kenealy, J. N. (2010) A prospective, multicenter, randomized-controlled 5-year study of hybrid and fully etched implants for the incidence of peri-implantitis. *Journal of Periodontology* **81**, 493-501.
- Zhao, G., Schwartz, Z., Wieland, M., Rupp, F., Geis-Gerstorfer, J., Cochran, D. L. & Boyan, B. D. (2005) High surface energy enhances cell response to titanium substrate microstructure. *Journal of Biomedical Material Research Part A* **74**, 49-58.
- Zitzmann, N. U. & Berglundh, T. (2008) Definition and prevalence of peri-implant diseases. *Journal of Clinical Periodontology* **35**, 286-291.
- Zitzmann, N. U., Berglundh, T., Ericsson, I. & Lindhe, J. (2004) Spontaneous progression of experimentally induced periimplantitis. *Journal of Clinical Periodontology* **31**, 845-849.

Appendix

Study I to IV