

**On healing after periapical surgery and
different retrograde root-filling materials.
A clinical and histological study.**

by

Dan-Åke Wälivaara



UNIVERSITY OF GOTHENBURG

Department of Biomaterials, Institute of Clinical Sciences
The Sahlgrenska Academy at Gothenburg University
Sweden

and

Maxillofacial Unit
Halmstad Hospital Halland
Sweden

2011

© Dan-Åke Wälivaara 2011

All rights reserved. No part of this publication may be reproduced or transmitted, in any form or by any means, without written permission.

ISBN 978-91-628-8243-3

Printed by Geson Hylte Tryck, Göteborg, Sweden 2011



ABSTRACT

On healing after periapical surgery and different retrograde root-filling materials.
A clinical and histological study.

Aims: The outcome from conventional endodontic therapy does not always result in a healing of the periapical area, thus leaving a remaining lesion with or without symptoms. The primary treatment alternative is a revision of the orthograde root-filling if applicable. A second treatment alternative might be a periapical surgery procedure. The overall aim of this research project was to analyze the healing after a defined periapical surgical technique and commonly used retrograde root-filling materials in teeth with periapical periodontitis. Specific aims were to evaluate any difference in the healing outcome and tissue response from the used materials. The influence on healing from three variables; lesion size, lesion type and orthograde root-filling quality, were also analyzed.

Materials and methods: Clinical studies: 422 teeth in 358 consecutive patients referred for a periapical surgery procedure to the Maxillofacial Unit, Halmstad Hospital, Halland, were included in three different consecutively implemented studies. All referred teeth were included except teeth with advanced periodontal disease with apical marginal communication and obvious root-fractures. The surgical technique and cleaning of the root-canals followed the same protocol in the 3 clinical studies, but the type of retrograde materials used differed. IRM was used in all studies as a control, due to its long-term use as a root-end seal, in the unit since before. The clinically compared materials were Super-EBA and thermoplasticized gutta-percha (Ultrafil®) with a sealer (AH-Plus®). All operated teeth were reviewed clinically and radiographically after minimum 12 months.

Experimental model: The three tested materials from the clinical studies and a fourth material, mineral trioxide aggregate, MTA (Angelus®), were analyzed in an animal model. The periapical tissue response to the retrograde materials and bone healing after the osteotomy was evaluated. Radiographic examination, descriptive and morphometric histological analyses and SEM analysis were performed as evaluation techniques.

Results: The results from the clinical studies revealed an overall successful healing outcome between 80-91%. There was no statistical significance in the healing between the materials when comparing IRM to the two other clinically tested materials. The healing result in teeth treated with IRM had an increasing success throughout the different study series. The three evaluated pre- and perioperative variables had no significant influence on the treatment outcome after 12 months follow-up.

The histological results revealed a better healing after the osteotomy in cases treated with IRM and MTA. New formed cement-like tissue was seen over all resected dentine surfaces in all healed cases regardless of the used retrograde material. The only material with signs of new cement-like tissue formation directly on the material surface was MTA.

Conclusions: The success rates regarding healing after 12 months is high for all tested materials and show that these materials can serve as a root-end seal in periapical surgery with ultrasonic preparation. The outcome figures might be altered after a longer follow-up period. There is a difference in the perioperative handling of the tested materials, which could be an explanation to the slight variation of the healing figures. The radiographic status of the orthograde root-filling, type and size of the periapical lesion do not have a significant influence on the treatment outcome after a one-year follow-up. Regardless material used by the surgical team, they must be confident in its handling and management. The MTA material seems to be more biocompatible compared to the other tested materials and should because of this be the first material of choice, but from the clinical results in this study, the other materials are suitable as retrograde root-fillings as well.

Keywords: periapical surgery, ultrasonic preparation, IRM, thermoplasticized gutta-percha, Super-EBA, mineral trioxide aggregate, root-filling status, lesion size, lesion type

ISBN 978-91-628-8243-3
Göteborg 2011

Correspondence: Dan-Åke Wälivaara, Maxillofacial Unit, Specialisttandvården, Plan 1, Halmstad Hospital, S-30185 Halmstad, Sweden. Email: dan-ake.valivaara@regionhalland.se

To Anna, Ellen and Julia

Preface

This thesis is based on the following studies, which will be referred to in the text by their Roman numerals (I-IV)

- I. Wälivaara DÅ, Abrahamsson P, Isaksson S, Blomqvist JE, Sämfors KA.
Prospective study of periapically infected teeth treated with periapical surgery including ultrasonic preparation and retrograde intermediate restorative material root-end fillings. *J Oral Maxillofac Surg.* 2007 May;65(5):931-5.
- II. Wälivaara DÅ, Abrahamsson P, Sämfors KA, Isaksson S.
Periapical surgery using ultrasonic preparation and thermoplasticized gutta-percha with AH Plus sealer or IRM as retrograde root-end fillings in 160 consecutive teeth: a prospective randomized clinical study. *Oral Surg Oral Med Oral Pathol Oral Radiol Endod.* 2009 Nov;108(5):784-9.
- III. Wälivaara DÅ, Abrahamsson P, Fogelin M, Isaksson S.
Super-EBA and IRM as root-end fillings in periapical surgery with ultrasonic preparation. A prospective randomized clinical study of 206 consecutive teeth. *Oral Surg Oral Med Oral Pathol Oral Radiol Endod.* 2011, Accepted
- IV. Wälivaara DÅ, Abrahamsson P, Sennerby L, Salata L, Isaksson S, Dahlin C.
Periapical tissue responses after use of IRM, Gutta-percha, Super-EBA and MTA as retrograde root-filling materials. A histological study in dogs.
Submitted

Contents

Preface	4
Introduction	7
History	7
Etiology to apical periodontitis and radicular cyst formation	7
Inflammatory host response and bone metabolism	8
Conventional endodontic treatment outcome	9
Radiographic techniques	9
Periapical surgery procedures	10
<i>Periapical surgery outcome</i>	10
<i>Perioperative magnification aids</i>	10
<i>Flap design</i>	11
<i>Direction of the root-end resection</i>	11
<i>Length and depth of the root-end resection</i>	11
<i>Retrograde root-canal preparation technique</i>	12
<i>Peri- and postoperative haemostasis</i>	12
Retrograde root-end obturation	13
<i>Height of the retrograde material</i>	13
<i>Retrograde root-filling materials used in this study</i>	14
Aims	15
Materials and methods	16
Clinical studies – Paper I-III	16
<i>Patient selection</i>	16
<i>Preoperative examination</i>	16
<i>Surgical procedure</i>	17
<i>Clinical and radiographic follow-up</i>	20
<i>Statistics</i>	21
Experimental model - Paper IV	21
<i>Animal selection and general anaesthesia</i>	21
<i>Surgical procedure</i>	21
<i>Postoperative care</i>	22
<i>Sacrifice procedure and ground sectioning</i>	23
<i>Histological descriptive and morphometric analyses</i>	23
<i>Radiographic analysis</i>	23
<i>SEM analysis</i>	24
<i>Statistics</i>	24
Results	25
Clinical studies – Paper I-III	25
<i>Paper I</i>	25
<i>Paper II</i>	25
<i>IRM group</i>	25
<i>GP group</i>	25
<i>Overall treatment results</i>	27
<i>Paper III</i>	27
<i>IRM group</i>	27

<i>Super-EBA group</i>	27
<i>Overall treatment results</i>	27
<i>Distribution and influence of pre-/perioperative variables</i>	27
<i>Statistics</i>	29
<i>Paper II</i>	29
<i>Paper III</i>	29
Experimental model - Paper IV	29
<i>Histology</i>	29
<i>Guttapercha (GP)</i>	29
<i>Super-EBA</i>	30
<i>MTA</i>	30
<i>IRM</i>	31
<i>SEM analysis</i>	31
<i>Statistics</i>	31
Discussion	35
Clinical studies – Paper I-III	35
<i>General outcome</i>	35
<i>Preoperative status of the root-filling</i>	37
<i>Type and size of the periapical lesion</i>	38
<i>Ultrasonic root-end preparation</i>	39
<i>Root-canal anatomy and isthmuses</i>	40
<i>Retrograde material consistency and height of the retrograde root-filling</i>	41
<i>Aspects on the clinical handling of the retrograde materials</i>	42
<i>Aspects on adverse reactions from the tested materials</i>	42
<i>Endodontic and periapical surgery outcomes dependent on the coronal restoration</i>	43
Experimental model - Paper IV	44
<i>Aspects on the experimental model design</i>	44
<i>Sealing ability and antibacterial properties</i>	44
<i>Height of the retrograde root-filling</i>	46
<i>Inflammatory infiltration and re-establishment of the alveolar bone</i>	46
<i>Regeneration of cemental tissue and periodontal ligament</i>	47
<i>Osteoblasts and material surfaces</i>	48
<i>Physicochemical properties of MTA and hard-tissue formation</i>	48
<i>Influence on fibroblasts</i>	49
General discussion (Paper I-IV)	49
Conclusions	51
Acknowledgements	52
References	54
Paper I-IV	

Introduction

History

The treatment of periapically infected roots with a surgical approach is a well known procedure and has been practiced for more than hundred years. Different techniques and obturating materials have been used. One of the early published cases was an apical root amputation in combination with a root-filling in gutta-percha of a maxillary canine, which had caused a long time problem with an extraoral fistula in the cheek region¹.

The technique of root amputation was also described in more detail around the same time². A publication of the raising of acute and chronic abscesses originating from teeth and their surgical treatments was also published in the late 19th century³. Literature published from Germany resulted in a more wide spread use of the root-end resection technique in Europe from the first half of the 20th century⁴. The use of a root-end seal in conjunction with a root amputation has not always been used, in which the treatment result not always become successful. During the years investigators and therapists have become more enlightened about the biological principles around the periapical surgery procedure and developed the technique as well.

Etiology to apical periodontitis and radicular cyst formation

The cause of apical periodontitis or periapical osteitis (older nomenclature) emerges from a pulpal inflammation that exceeds to a necrotic pulp which gives opportunity for bacterias from the oral environment to enter the pulpchamber and the root-canal^{5,6}. This colonization inside the tooth results in a leakage of bacterial products, toxins or/and bacteria's through the apical foramen causing an inflammatory reaction in the periapical tissue⁷.

The reaction due to the microbial attacks and host response events, results in an apical granulation tissue i.e. periradicular bone resorption and degradation of the apical periodontal ligament. Some of the apical granulomas turn into cysts. The reported incidence of periapical cyst formation varies from 6-54%⁸. A true periapical cyst will not regress after an orthograde endodontic treatment, why a surgical intervention is indicated⁹.

The cyst formation has been described to be a 3-stage event¹⁰. During the second stage, there are two advocated theories explaining this part of the development of a radicular cyst¹¹. The first one, the abscess theory is that the cyst is believed to arise from a previous apical abscess where the proliferating epithelium, derived from the cell rests of Malassez, surrounds a secondary abscess or necrotic connective tissue.

The second theory is the nutritional deficiency theory, which postulates that the central cells of epithelial strands lose their nutrition and a subsequent necrosis and liquefactive process occurs. The abscess theory has acquired strong evidence support from experimental studies¹².

The most common form of an apical periodontitis is the chronic form, which is asymptomatic and the diagnosis is normally set from a radiographic observation. A wide range of appearances from a slight widening of the periodontal ligament to an extended radiolucent area can be seen on the radiograph. This state of balance between the host's immune response and the bacterial irritants is persistent until either the leaking of bacterial contents terminate or the chronic balanced state turns into an acute situation, in case of sudden decline in the host response.

The defence systems of the body can not reach the microbial contents inside the tooth and in that aspect the apical periodontitis is not self-healing. This can only be achieved by either removal of the whole tooth or a root-canal cleaning and obturation of the root-canal from the coronal and/or the apical direction as a retrograde root-end seal.

Inflammatory host response and bone metabolism

The composition of cells, both inflammatory and epithelial, infiltrating an apical lesion differs with the type of lesion. In an apical chronic granuloma the dominating cells consist of lymphocytes, plasma cells and macrophages, whilst the acute phase consists of high levels of neutrophils, mainly polymorphonuclear leukocytes (PMN) and some macrophages^{11, 13}. Quantification of these cells in granulomas has been outlined by morphometric techniques^{14, 15} but the composition can be altered due to microbial and host factors. In addition to these cells there are also cytokines such as interleukins, interferons, cytotoxic factors and growth factors involved in the process through direct or indirect influence on the inflammatory cells¹¹.

A main part of the development of an apical periodontitis is the degradation event of the hard tissue and this is executed by the osteoclastic cells. This includes bone like dental hard tissue as well. The osteoclasts are derived from pro-osteoclasts migrating through blood as monocytes into the affected periapical area. They will be passive until a given signal from the osteoblasts which turn them into an active phase and start of the osteolytic process¹⁶.

The osteoclastic activity is an ongoing action in the normal bone metabolism, where there is a balance between the osteoblastic bone formation and osteoclastic bone resorption¹⁷. The osteoclastic activity is enhanced in a pathologic condition such as an apical periodontitis.

The bone resorption process can even be pathologically decreased thus giving excessive bone formation like in osteopetrotic diseases¹⁶. An example of such a hard tissue production situation can be found in a periapical condensing osteitis. The affected tooth in this situation can be vital

or chronically inflamed and in the end become necrotic. A sequelae of an endodontic procedure or extraction of such affected tooth, can be remaining signs of condensed bone in the apical area on a radiograph.

Conventional endodontic treatment outcome

A remaining apical lesion can also be the fact despite a previous conventional endodontic treatment. Failures from primary orthograde endodontic treatment occur in 4-21%^{18, 19}. This is mostly due to technical issues to get infection control in the main root-canal, during the conventional endodontic treatment including anatomical causes such lateral root-canals. In that case the solution is primarily a revision of the orthograde root-filling.

Sometimes, however, conventional revision is not possible due to previous prosthodontic treatment i.e. a crown or a core anchored in the root canal. In such cases the coronal access to the root canal is highly limited. Removal of the prosthodontic construction could be complicated and attempts to do so may even cause a root fracture. In such circumstances periapical surgery is the treatment of choice.

In cases when revision of conventional endodontic treatment is possible, the infection sometimes remains, caused by the anatomy of the root canals i.e. canal bifurcations. In such cases there is an indication for periapical surgery.

Other considerations for periapical surgery could be complications following the orthograde endodontic treatment such as extruded material past the apex causing an infection in the apical area or broken instruments lodged in the apical third of the canal with a concomitant infection.

A revision of an orthograde endodontic treatment succeeds in 62%¹⁹. Less than 5% of the chronic apical periodontitis lesions exacerbate into a periapical abscess²⁰.

Radiographic techniques

Conventional two-dimensional radiographic techniques has been the diagnostic tool for primary diagnosis of the periradicular tissues and outcome evaluation from conventional endodontic treatment²¹ and periapical surgery methods^{22, 23} for many years. Comparing of different evaluation models after periapical surgery is also published²⁴.

Technological advances have recently developed new forms of digital radiographic techniques, cone beam computer tomography (CBCT), which expands the diagnostic window tool from a two-dimensional view into a three-dimensional visualisation. The use of CBCT has a great advantage in the periradicular preoperative planning especially in maxillary molars and in postoperative healing control, compared to traditional periapical radiography²⁵⁻²⁷. The CBCT

technique has shown to be very helpful in treatment planning of mandibular molars and the relation to the inferior alveolar nerve²⁸.

When comparing intraoral periapical radiography with 3D images, a greater number of roots with periapical lesions will be detected with the latter technique^{29,30}.

Periapical surgery procedures

The term apicectomy is by definition since early days the actual resection and removal of the apical portion of the root. It has been suggested to use the term “periapical surgery” or “periradicular surgery” just to define that the treatment aim is to gain a regeneration of the whole periapical tissue apparatus. The treatment includes removal of periapical pathology, cleaning and obturation of the apical part of the root-canal³¹.

Periapical surgery outcome

The outcome after periapical surgery has changed to a general higher level in terms of success figures, after the introduction of new treatment modalities such as ultrasonic retrograde root-canal preparation, use of magnification aids and modified surgical techniques. Older figures presents success rates varying between 44% to 95%³²⁻³⁵ were the use of a retrograde preparation in many publications, is not defined. Studies describing the use of ultrasonic preparation technique in conjunction with a root-end seal³⁶⁻³⁸, show more steady success figures around 90%.

Perioperative magnification aids

The introduction of magnification aids into the periapical surgery equipment arsenal, has raised the quality of the treatment³⁹. All steps of the surgical procedure benefits from the increased inspection possibility. This is among others removal of infection related soft-tissues, good view of the resected dentin surface with ability to detect untreated root-canals, isthmuses between canals and microfractures. The isthmuses positioned just coronally of the resected dentin surface should always be prepared with the ultrasonic device⁴⁰. This is almost impossible without the help of a magnification aid. Endoscopically assisted periapical surgery has also been suggested and method descriptions and smaller clinical series are published^{41,42}.

A randomized, clinical study from Taschieri et al⁴³ compared the use of either endoscope or microscope as magnification aid in periapical surgery and there was no significant difference in the treatment outcome. A similar study from Taschieri et al⁴⁴ showed no significant difference between the endoscope and microscope.

Del Fabbro et al published a review article⁴⁵, where the use of magnification aids such as loupes, microscope or endoscopy in periapical surgery in three prospective studies revealed no significant difference in the outcome. The use of loupes in periapical surgery at least is a start, but the microscope has the ability for higher magnification levels thus extending the inspection potential⁴⁶.

Flap design

The incisions in periapical surgery procedures could be either through a vestibular or a sulcular incision. The sulcular incision is supplemented with two diverging releasing incisions thus creating a wide base ensuring a good blood supply to the flap during the healing phase.

The sulcular full-thickness approach allows for a good inspection of the buccal marginal bone which is a drawback in the vestibular technique. The main disadvantage from the sulcular technique is purported to be a possible shrinkage or recession of the papilla⁴⁷.

Direction of the root-end resection

The older apical resection technique recommended a bevelling of the root-end resection of about 45 degrees^{48,49}, thus giving a good access and direct vision of the resected dentin surface. It is also a prerequisite for the micro-handpiece to get access into the retrograde root-canal. The high bevelled resection direction also results in a greater exposure of dentinal tubules⁵⁰ and thus a concomitant increased risk of leaking⁵¹ bacterial contents from the main root-canal through the tubules into the periradicular tissue region.

The new technique with smaller retrotips render a better access to the root-canal without performing an excessive osteotomy and the bevelling of the resection could in the maxillary front and premolar areas be kept to almost a right degree angle to the long-axis of the roots. The recommended maximum bevel degree to be performed is about 10 degrees, to keep the number of exposed dentinal tubules as low as possible⁴⁶.

Length and depth of the root-end resection

The root-end resection should be at least 3 mm in length to achieve a sufficient removal of lateral canals in the apical portion of the root. Up to 93% of the lateral canals will be removed at a 3 mm resection length⁴⁶. If the depth of the resection is not enough a small lingual part will be left hence causing continuous remaining infection.

This could often be the case in teeth with fused roots e.g. the upper premolar area, where the resection surface form is often presented as an oval or kidney-shape. The majorities of canal

isthmuses is also positioned in apical 3-5 mm portion of the roots and are present in 100% of roots with two canals at the 4 mm level⁵².

Retrograde root-canal preparation technique

Before the introduction of ultrasonic root-end preparation during the start of 1990s, the root-ends were prepared by the use of a micro-handpiece with small round-burs or inverted cone burs. This preparation technique has some disadvantages such as inconsistent centering of the canal preparation, insufficient depth of the preparation and a demanding amount of osteotomy to get access to the root-canal. The unsafe centering of the preparation also increases the risk of a perforation outside the root.

Retrotips, mostly diamond coated, are used together with the ultrasonic devices and they give a deeper preparation and stay more to the original direction of the root-canal. The two techniques are compared in a in-vitro study⁵³, where the findings showed more well-centered and cleaner preparations after the use of ultrasonic technique.

A clinical comparing study from de Lange et al⁵⁴, revealed a higher outcome result, when using ultrasonic retrograde preparation of the root-canals. This was significantly better in molars. The depth of the root-canal preparations is significantly greater after ultrasonic preparation compared to traditional round-bur approach⁵⁵.

Peri- and postoperative haemostasis

To have the most favourable starting point when performing the retrograde root-end seal, a dry operating field i.e. a sufficient perioperative haemostasis is mandatory. The ability to function in more or less a moisture environment varies between the commonly used retrograde materials. To achieve the haemostasis there are some surgical haemostats options suggested such as bone wax, epinephrine cotton pellet, ferric sulphate and thrombin⁴⁶.

Vickers et al compared the use of epinephrine cotton pellets with 20% ferric sulphate regarding a dry field in root-end filling procedures, without finding any significant difference. Local anaesthesia containing epinephrine also contributes to the perioperative and postoperative haemostasis.

As postoperative haemostasis the normal compression procedures such as cotton gauze is enough for healthy patients. Patients on anticoagulants e.g. warfarin, should have a postoperative haemostasis supplemented with tranexamic acid local treatment⁵⁶.

Retrograde root-end obturation

The aim of the obturation of the apical part of the root-canal is to seal the canal with its assumed bacterial contents to stop the leaking causing the periapical lesion. Suggested requirements⁵⁷ of a retrograde root-filling material are listed in Table 1.

Commonly used materials which are published in both clinical and animal studies regarding healing outcome, sealing ability and tissue response are IRM, Super-EBA and mineral trioxide aggregate, MTA^{33, 35, 36, 38, 54, 58-79}. Less frequent used materials are light-cured compomer, dentine-bonded composite, guttapercha and glass ionomer cement⁸⁰⁻⁹¹. Studies on amalgam as root-end fillings are also published^{32, 34, 68, 72, 76, 83, 85, 89, 91}, but the material is rarely used nowadays.

Table 1. The requirements of an ideal root-end filling material⁵⁷

Root-end filling materials should:
Adhere or bond to tooth tissue and “seal” the root-end three dimensionally
Not promote, and preferably inhibit, the growth of pathogenic microorganisms
Be dimensionally stable and unaffected by moisture in either the set or unset state
Be well tolerated by periradicular tissues with no inflammatory reactions
Stimulate the regeneration of normal periodontium
Be nontoxic both locally and systemically
Not corrode or be electrochemically active
Not stain the tooth or the periradicular tissues
Be easily distinguishable on radiographs
Have a long shelf life, be easy to handle

Height of the retrograde material

The depth of the retrograde root-canal preparation and the following obturation ought to be at least 3 mm or more to achieve a satisfactory seal⁵¹. This is even more accomplished through keeping the resection angle as close as 90 degrees to the long axis of the root⁹².

Valois and co-workers published a study where they evaluated the ability of different thicknesses of MTA to prevent leakage and they concluded the optimum thickness to be 4 mm⁹³.

Retrograde root-filling materials used in this study

IRM - intermediate restorative material (DENTSPLY International Inc.) is reinforced zinc-oxide eugenol cement. The powder is a mix by 80% zinc-oxide and 20% polymethylmethacrylate. The liquid is 99% eugenol and 1% acetic acid. The setting time is 5 minutes and should be mixed for 60 seconds with 1:1 P/L ratio⁹⁴.

Super-EBA (Bosworth's) is zinc-oxide eugenol cement modified with ethoxybenzoic acid, which increase the strength of the material. The composition of the powder is 60% zinc-oxide, 37% alumina and 3% natural resin and is mixed with the liquid composed by 37.5% eugenol and 62.5% orthoethoxybenzoic acid. The mixing P/L ratio is 2:1. The setting time is increased compared to normal ZOE due to the addition of ethoxybenzoic acid. It has good sealing ability and biocompatibility⁹⁵.

Thermoplasticized gutta-percha - GP (Ultrafil®, Coltène/Whaledent Inc) is a α -form of GP which has better flow properties compared to the β -form used in GP cones. The used GP in this study has a composition of approx. 25% compound gutta-percha, 65% zinc-oxide, 10% barium sulphate and <1% coloring agents. The material is suited in cannules and heated in low temperature of 70 degrees Celsius.

MTA - mineral trioxide aggregate is a further development of Portland cement with addition of bismuth oxide for radiopacity. MTA was developed 1993 at Loma Linda University, USA⁹⁶. The powder contents are 75% Portland cement, which consist of tricalcium silicate, tricalcium aluminate, dicalcium silicate, tetracalcium aluminoferrite and an addition of 20% bismuth oxide and 5% calcium sulphate dehydrate (gypsum).

The powder is mixed to a hydro gel with distilled water. The gel is solidified during approximately 3 hours for the original form of the material (ProRoot MTA®, Maillefer, Dentsply, Switzerland). An alternative brand to ProRoot MTA have changed the setting to 10 minutes (Angelus®, Londrina, PR, Brazil), by removing the calcium sulphate dehydrate (gypsum) and add another 5% of the Portland cement. Initially the pH is 10.2 which rises to 12.5 three hours after mixing⁹⁷.

Aims

The overall aim of the present thesis was to analyze the healing after a defined periapical surgical technique and commonly used retrograde filling materials.

Specific aims

- 1) To evaluate periapical surgery including ultrasonic preparation and use of IRM as retrograde root-filling material.

- 2) To evaluate the difference of the healing in relation to the sort of used retrograde root-filling material.

- 3) To evaluate the healing success-rate after periapical surgery in relation to the quality of the orthograde root-filling, lesion type and lesion size.

- 4) To analyze tissue responses for four different retrograde root-filling materials around the apical area, through histological investigations in an animal model.

Materials and Methods

Clinical studies – Paper I-III

Patient selection

Paper I-III

A number of 422 consecutive teeth in 358 patients (144 men and 214 women) referred for a periapical surgery intervention, were included in three different after one another coming clinical series. The majority of the patients were settled in the south half of the county of Halland about 40 kilometres from the Hospital. All teeth were included in the studies except teeth with obvious root-fractures or advanced periodontal disease e.g. apicomarginal communications.

Paper I

Fifty-six teeth in 55 patients (21 men and 34 women, median age 54 years) were included in the study. All teeth received IRM as a retrograde root-filling.

Paper II

One hundred and sixty teeth in 139 patients (58 men and 81 women, median age 59 years) were included in the study. The patients were randomly allocated into two groups according to the date of birth. Odd birth date numbers received IRM (Dentsply®) (77 teeth) and even birth dates thermoplasticized gutta-percha, GP (Ultrafil®), with a sealer (AH-Plus®) (83 teeth) as a retrograde root-end seal.

Paper III

Two hundred and six teeth in 164 patients (65 men and 99 women) were included in the study. The patients were randomly allocated into two groups using a standard randomization table. The two groups received either IRM (99 teeth) or Super-EBA (Bosworth's) (107 teeth) as a retrograde root-end seal.

Ethical approval

Paper II and III

The studies were approved by the human ethical committee at the University of Lund, Sweden.

Preoperative examination

Paper I-III

Preoperatively a radiographic examination was performed with 2 intraoral radiographs in different angles, together with a clinical examination. The quality of the orthograde root-filling

judged from radiographs was not an inclusion criteria for participating in the study, but rather all teeth were included. No financial compensation was given to the patients except a free-of-charge 1-year follow-up.

Paper I and II

There were no classification of the teeth regarding the presence of apical granulomas and radicular cysts and consequently no analysis of potential differences in the treatment outcome due to these two pathologic conditions were performed.

Paper III

Pre- and perioperative variables were noted as follow: type of coronal restoration, presence and type of post in the root-canal, presence of periodontal pockets exceeding 5 millimetres, type of lesion – cyst or granuloma set from a perioperative assessment, presence of intact buccal cortical bone and the status of the root-filling judged from the radiograph.

Paper I

All included patients were preoperatively informed about the study and the 12 months follow-up postoperatively. All patients were free to participate in the review.

Paper II and III

All included patients were preoperatively informed about the study and the randomization procedure and could at any time terminate their participation in the study.

Surgical procedure

Paper I-III

All surgical procedures were performed by two surgeons using 2.3 X magnification operating loupes. Local anaesthesia 3.6-5.4 mL 2% lidocaine with adrenaline was injected into the operating field both as infiltration and/or ID nerve blocks depending on the region. A full-thickness mucoperiosteal buccal flap was raised over the affected tooth.

The bony periapical area was exposed using a round-bur. Enucleation of the granuloma or cyst from the periapical area was followed by a 3-4 mm slightly oblique resection of the root with a fissure bur. The root-canal was prepared and cleaned with ultrasonic root-end cavity preparation of 3 mm in depth with stainless steel (Paper I-II) retrotip or a diamond coated retrotip (Fig. 1).



Figure 1. Diamond coated retro-tip for ultrasonic device.



Figure 2. Mandibular molar with ongoing ultrasonic root-end preparation.

All preparations in the alveolar bone, the apicectomies and the ultrasonic preparation (Fig. 2) were performed under constant saline irrigation. To achieve haemostasis in the operating field, a small gauze soaked with 1% adrenaline was packed into the bone cavity for 2-3 minutes. The canal was then thoroughly dried with 70% alcohol and endodontic paper points.

Paper I-III

The IRM filling material was hand-spatulated on glass (Fig. 3) and inserted and condensed into the prepared canal (Fig. 4).

Paper II

In the cases using gutta-percha, the material was prepared in a heater extraorally (Fig. 5), and the operator had to load the syringe with the gutta-percha canula before injecting the material into the cavity. During the loading, the operator left the control of the operating area to the assistant. The AH-Plus sealer was applied into the canal with a small probe before the gutta-percha insertion.

Paper III

For the group of teeth receiving Super-EBA, the prepared canals were filled with handspatulated Super-EBA (Bosworth's) as retrograde fillings.



Figure 3. The intermediate restorative material – IRM, was handspatulated on a glass plate.

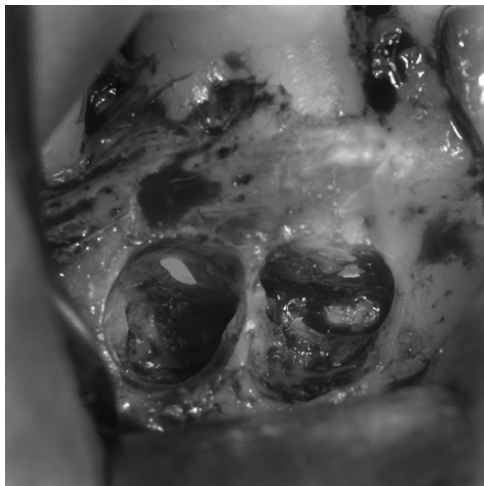


Figure 4. Finished retrograde IRM root-fillings in situ in a mandibular molar.



Figure 5. The syringe with a mounted Ultrafil® canulae positioned in the gutta-percha heater.

Paper I-III

The flap was sutured with Vicryl 4-0 sutures. Two intraoral radiographs were taken immediately after the operation.

Clinical and radiographic follow-up

Paper I-III

After a minimum of 12 months a radiographic and a clinical examination were performed. The clinical reviews of the patients were made by one of four independent surgeons according to a protocol. Registration of clinical findings such as tenderness on percussion, tenderness on palpation of the crown or/and in the apical area, gingival swelling, presence of a fistula or an apico-marginal communication were recorded as a failure.

All radiographs were reviewed independently by the two operating surgeons and a maxillo-facial radiologist, with a subsequent joint discussion, where there was any disagreement about the findings.

Measurements and classifications according to previously reported models for healing after periapical surgery²² were performed. The following four different classifications were used:

- 1) Complete healing (Figure 1, Paper III), 2) Incomplete healing (scar tissue) (Figure 2, Paper III),
- 3) Uncertain healing (Figure 3, Paper III) and 4) Unsatisfactory healing.

Group 1 and 2 were recorded as success and group 3 and 4 as failures. The second group, incomplete healing (scar tissue) could be regarded as success at the one year follow-up⁹⁸. For a successful outcome no clinical or radiographic findings showing signs of remaining infection should be present.

The collected and registered information was analyzed. Success and failure rates for each material and the results between different areas in the mouth were calculated.

Paper III

The possible influence on the treatment outcome depending on three pre-/perioperative parameters: lesion size, lesion type and orthograde root-filling quality was also analyzed.

Statistics

Paper II

Fisher's exact test ($p=0.05$) was used for a statistical analysis regarding any difference in the outcome between the materials, as groups and specific types of teeth.

Paper III

Fisher's exact test ($p=0.05$) was used for a statistical analysis regarding the differences in healing between the retrograde materials. The three variables, lesion size, lesion type and quality of the orthograde root-filling, were statistically analyzed with Z-test at a significance level of 5% regarding their possible influence on the treatment outcome.

Experimental model - Paper IV

The experimental study was approved by the Brazilian Institute for Protection of the Environment (IBAMA) and approved by the Animal Ethic Committee at the Faculty of Dentistry of the University of the State of São Paulo – UNESP, Aracatuba, Brazil.

Animal selection and general anaesthesia

Six healthy adult mongrel dogs were used in this study. Their weight differed between 19.250 and 22.850 kg. All animals were anaesthetized with Acepran 0.2%, 1 ml/10kg (Acepromazin). Induction was performed with Zoletil 50, 0.12 ml/kg (Tiletamin, zolazepan). For the maintenance Isothane (Isoflurane) was given via an endotracheal tube with oxygen in the volume of 30 ml/kg.

Surgical procedure

As a local haemostasis, 1.8 ml Xylocaine 2% with adrenaline was injected into the operating area. The roots of the third and fourth premolars in the right mandible were used for the apicectomy procedures. A mucoperiosteal buccal flap was raised over the area of the third and fourth premolars. The apical area of the roots was exposed by osteotomy with a round-bur together with a concomitant apicectomy. The root-canals were prepared with an ultrasonic preparation technique about 3 mm up in the root canals. All preparations were performed under constant saline irrigation. The bone cavities were packed with 1% adrenaline soaked gauze to

achieve haemostasis. The root-canals were cleaned and dried with paper points soaked in 70% alcohol. IRM, mineral trioxide aggregate, MTA (Angelus®) and Super-EBA (Bosworth's®) were handspatulated on glass plates before applying it into the canal. The heated GP material (Ultrafil®) was injected into the prepared canal after applying a sealer (AH-Plus®). All cases received the same root-end filling material in the similar root (Fig. 6), IRM in 3rd mesial, MTA in 3rd distal, Super-EBA in 4th mesial and GP in 4th distal root. The flap was sutured with a resorbable suture, Vicryl® 4-0.

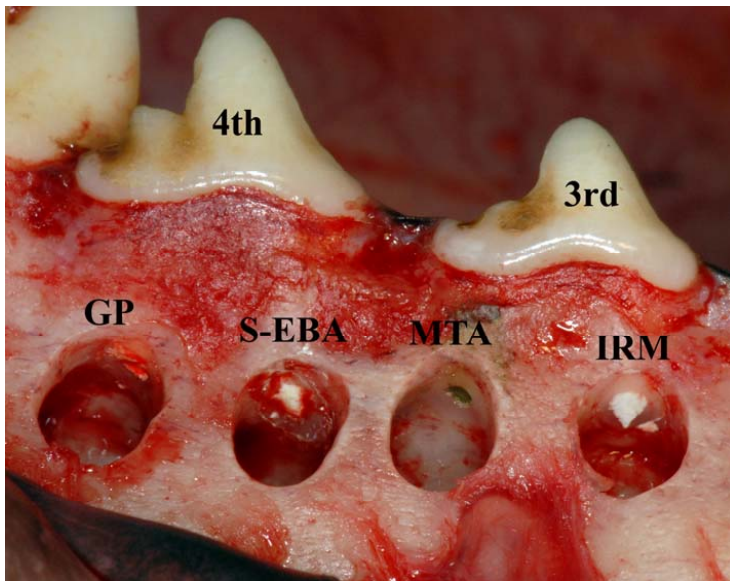


Figure 6. The retrograde materials Guttapercha (GP), Super-EBA (S-EBA), mineral trioxide aggregate (MTA) and intermediate restorative material (IRM) in situ in the 3rd and 4th premolar.

Postoperative care

Postoperatively the animals received antibiotics, Stomorgil 10 (spiramycin, metronidazol) 1 tablet for each 10 kg, every 24 hours for 10 days. Anti-inflammatory drugs, Maxican 2 mg (Meloxicam), 1 tablet for each 20 kg, every 24 hours for 5 days and analgesics Tramal 50 (tramadol hydrochloride), 1 to 4 mg/kg, subcutaneously for 8 hours during 3 days.

Sacrifice procedure and ground sectioning

After 120 days the animals were sacrificed. They were anesthetized with intravenously administered sodium thiopental at a dose of 25 mg/kg. After confirmation of a fully anesthetized animal, perfusion of potassium chloride to 19.1% at a dose of 1 ml/kg was performed until there was no pupilar reflex and cardio respiratory arrest.

The mandibles were then harvested as whole and kept in formalin for 1 month and in a later session the mandibles were sectioned, so each root was resected as a block. The blocks were dehydrated in a graded series of ethanol and embedded in plastic resin (Technovit 7200 VCL, Kulzer, Wehrheim, Germany) during 60 days.

The plastic blocks with the embedded roots had radiographs performed in both mesial-distal and buccal-lingual projection. One central section was cut through the long axis of the root by means of Exact cutting and grinding equipment (Exact Apparatebau, Norderstedt, Germany). The sections were ground to a final thickness of about 10 μm and stained with 1% toluidine blue and 1% pyronin-G⁹⁹.

Histological descriptive and morphometric analyses

The sections were viewed and analyzed in a light-microscope (Leica® DMD108). A description of the tissue morphology in the apical area around the retrograde material, the dentin and soft tissue was performed. The amount of inflammatory infiltration was assessed according to a three degree scale: none or a few areas with inflammatory cells (+), inflammatory cells within the whole apectomized apical area (++) or a major infiltration in the whole area (+++).

The distance from the surface of the retrograde material to the adjacent apical bone was measured at its maximum and minimum height (Fig. 7) and a mean distance was calculated at two occasions.

The height of the retrograde seal was also measured (Fig. 8) and a mean value was calculated. In addition, the presence of newly formed bone and closure of the buccal osteotomy was also noted from the sections.

Radiographic analysis

The density/outlining of the retrograde seal were estimated on the radiographs of each case and the presence of a re-established buccal cortical plate was noted.

SEM analysis

Selected specimens from all retrograde materials which were possible to evaluate were analyzed by scanning electron microscopy (SEM), regarding hard-tissue formation around the resected root surface and the retrograde materials where applicable. The interface between the retrograde materials and the dentinal walls was also evaluated and described. The specimens were polished with diamonds (particle size down to 1 μ m) and coated with a carbon layer prior to the scanning procedure. Backscattered pictures were produced by the SEM equipment, JEOL JSM-840A.

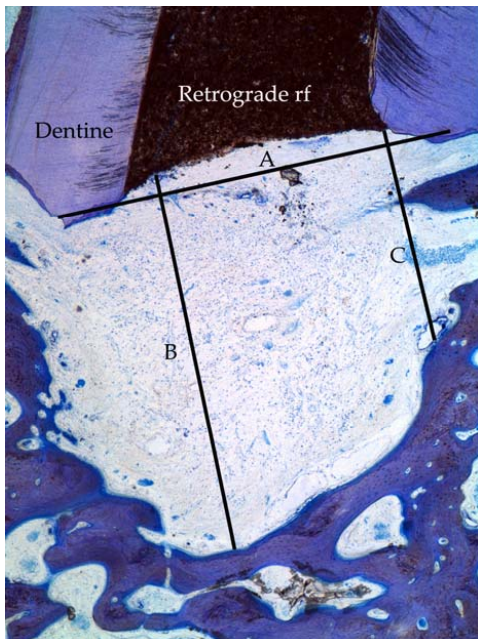


Figure 7. A parallell line to the apicectomy direction (A) was estimated. The measuring lines for the maximum (B) and minimum (C) distance from the retrograde material to the adjacent bone were drawn perpendicular to A. (Leica® DMD108 4X)

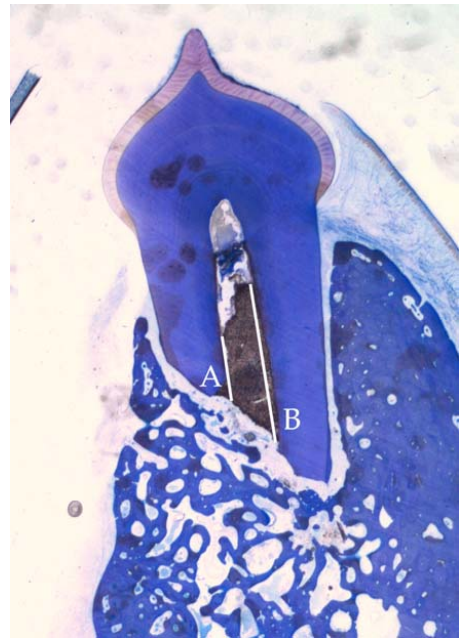


Figure 8. The height of the retrograde root-filling was measured at the minimum (A) and maximum (B) distance and the mean value was calculated. (Leica® DMD108 4X)

Statistics

Fisher's exact test with the p-value set to 0.05, was used for a statistical analysis between the retrograde materials, regarding the differences in re-establishment of the buccal cortical layer and presence of major inflammatory infiltration.

Results

Clinical studies – Paper I-III

Paper I

Fifty-four patients out of 55 took part in the follow-up control. A total number of 55 teeth were examined at follow-up. 44 teeth (80%) had no clinical or radiographic signs of pathology (group 1 and 2) at follow-up and were stated as successful. 11 teeth (20%) were stated as failures according to the clinical and radiographic examination. Five of these teeth were extracted due to a remaining fistula or a root fracture that had not been detected at the time of surgery. Two teeth had tenderness on palpation in the apical region. The remaining four teeth had signs of failure on the follow-up radiographs. There were no failures among the incisors. One canine, 4 premolars (one lower and three upper) and 6 molars (two upper and four lower) were among the failures (Table 2).

Paper II

One hundred forty-seven teeth in 131 patients were able to be reviewed. The drop-outs were 13 teeth in 8 patients. The drop-outs were represented in all types of teeth.

IRM group

Sixty-nine teeth in the IRM group were followed. The radiologic assessment result was 56 teeth in group 1, complete healing, 4 teeth in group 2, incomplete healing (scar tissue), 5 teeth in group 3, uncertain healing, and 4 teeth in group 4, unsatisfactory healing. After the clinical and radiologic examination results, there were 13 failures, of which 3 were root fractures. Those 3 teeth were excluded. The success and failure rates were calculated on 66 teeth, with 56 successful teeth (84.8%) and 10 failures (15.2%) (Table 2).

GP group

Seventy-eight teeth in the GP group were followed. The radiologic assessment result was 61 teeth in group 1, complete healing, 15 teeth in group 2, incomplete healing (scar tissue), 1 tooth in group 3, uncertain healing, and 1 tooth in group 4, unsatisfactory healing. After the clinical and radiologic examination results, there were 9 failures, of which 1 was a root fracture. That tooth was excluded. The success and failure rates were calculated on 77 teeth, with 69 successful teeth (89.6%) and 8 failures (10.4%) (Table 2).

Table 2. Outcome for different types of teeth in the maxilla and mandible in all material groups (Paper I-III) and statistical results of the difference in healing between the two material groups (Paper II and III).

	IRM		GIP		Super-EBA		p-value (p=0.05)
	success n(%)	failure n(%)	success n(%)	failure n(%)	success n(%)	failure n(%)	
Paper I							
Incisor	11 (100)	-					
Canine	3 (75)	1 (25)					
Premolar	9 (69)	4 (31)					
Upper	7 (70)	3 (30)					
Lower	2 (67)	1 (33)					
Molar	21 (78)	6 (22)					
Upper	11 (85)	2 (15)					
Lower	10 (71)	4 (29)					
Total	44 (80)	11 (20)					
Paper II							
Incisor	15 (100)	0	26 (86.7)	4 (13.3)			0.285
Canine	6 (85.7)	1 (14.3)	4 (100)	0			1.000
Premolar	15 (78.9)	4 (21.1)	18 (90.0)	2 (10.0)			0.407
Molar	20 (80.0)	5 (20.0)	21 (91.3)	2 (8.7)			0.419
Total	56 (84.8)	10 (15.2)	69 (89.6)	8 (10.4)			0.453
Paper III							
Incisor							
Upper	16 (94.1)	1 (5.9)			15 (93.8)	1 (6.2)	1.000
Lower	4 (66.7)	2 (33.3)			0	1 (100)	0.429
Canine							
Upper	5 (83.3)	1 (16.7)			5 (100)	0	1.000
Lower	3 (100)	0			1 (50.0)	1 (50.0)	0.400
Premol							
Upper	17 (89.5)	2 (10.5)			15 (83.3)	3 (16.7)	0.660
Lower	9 (90.0)	1 (10.0)			8 (80.0)	2 (20.0)	1.000
Molar							
Upper	16 (100)	0			14 (70.0)	6 (30.0)	0.024 *
Lower	17 (89.5)	2 (10.5)			22 (84.6)	4 (15.4)	1.000
Total	87 (90.6)	9 (9.4)			80 (81.6)	18 (18.4)	0.096

Overall treatment results

The overall results for different types of teeth in both material groups are listed in Table 2.

Paper III

One hundred ninety-four teeth (96 IRM and 98 Super-EBA) in 153 patients were assessed. The drop-outs were 8 teeth (2 IRM and 6 Super-EBA) in 7 patients. Four teeth (1 IRM and 3 Super-EBA) were excluded due to root-fractures discovered during the follow-up period.

IRM group

Of the 96 followed teeth in the IRM group, the radiological assessment placed 82 teeth in group 1, complete healing; 8 teeth in group 2, incomplete healing (scar tissue); 5 teeth in group 3, uncertain healing and 1 tooth in group 4, unsatisfactory healing.

Following the final clinical and radiological examination a total of 9 failures were recognised. The success and failure rates were calculated on 96 teeth with success in 87 teeth (90.6%) and 9 failures (9.4%) (Table 2).

Super-EBA group

Of the 98 followed teeth in the Super-EBA group the radiological assessment placed 72 teeth in group 1, complete healing; 10 teeth in group 2, incomplete healing (scar tissue); 12 teeth in group 3, uncertain healing and 4 teeth in group 4, unsatisfactory healing. After the clinical and radiological examination results there were a total of 18 failures. The success and failure rates were calculated on 98 teeth with 80 successful teeth (81.6%) and 18 failures (18.4%) (Table 2).

Overall treatment results

The distribution of success and failure numbers among different types of teeth, retrograde material type and upper and lower jaw are presented in Table 2.

Distribution and influence of pre-/perioperative variables

The results of the number of different lesion size, lesion type and quality of the orthograde root-filling for the reviewed teeth are presented in Table 3-5.

Table 3. Distribution of granulomas and cystic lesions in relation to the treatment outcome.

		IRM	Super-EBA	Total
Success	Cystic lesion	11	8	19
	Granuloma	76	72	148
Failure	Cystic lesion	4	1	5
	Granuloma	5	17	22

Material groups together, Z-test with CI=95%: $p=0.465$

Table 4. Distribution of the preoperative quality of the ortograde root-filling in relation to the treatment outcome.

		IRM	Super-EBA	Total
Success	Complete	20	11	31
	Insufficient	67	69	136
Failure	Complete	3	2	5
	Insufficient	6	16	22

Material groups together, Z-test with CI=95%: $p=0.795$

Table 5. Distribution of the lesion-size in relation to the treatment outcome for IRM and Super-EBA.

		IRM	Super-EBA	Total
Success	Group 1 (< 5 mm)	32	16	48
	Group 2 (5-9 mm)	43	47	90
	Group 3 (> 9 mm)	12	17	29
Failure	Group 1 (< 5 mm)	2	6	8
	Group 2 (5-9 mm)	5	7	12
	Group 3 (> 9 mm)	2	5	7

Z-test with CI=95%:
 Material groups together Group 1 vs Group 2 $p=0.841$
 Group 2 vs Group 3 $p=0.390$
 Group 1 vs Group 3 $p=0.719$

Statistics

Paper II

There was no statistical significance between the 2 groups, IRM and GP, when counting all types of teeth; $p = 0.453$. When looking at different types of teeth, the following p values were calculated with the same analysis: incisors 0.285, canines 1.000, premolars 0.407, and molars 0.419. There was no statistical significance between the materials regarding different types of teeth (Table 2).

Paper III

There was no statistical significance between the two groups (IRM and Super-EBA) regarding the healing outcome as it applied to all types of teeth, $p = 0.096$. When looking for different types of teeth and the breakdown into maxillary and mandibular teeth, there was a significant difference in the healing result between the material groups (IRM and Super-EBA) for maxillary molars, $p = 0.024$ (Table 2). There was no statistical significance for the influence on the healing result, either counting for both materials together or each material separately, when looking at the lesion type, lesion size or the orthograde root-filling quality (Table 3-5).

Experimental model - Paper IV

A total of 23 sections were included in the analysis process, six for each material except for MTA, where five sections were available for analysis after the ground sectioning.

Histology

Guttapercha (GP):

The mean distance from the GP surface to the adjacent apical bone was 1403 μm . In this non-bony area there was mainly connective tissue with a moderate (++) or major (+++) infiltration of inflammatory cells for the majority of the sections. Complete healing of the buccal cortical bone after the osteotomy was seen in 2 of the cases. The other 4 cases showed signs of a non-healing situation according to the lack of cortical buccal bone and together with a high level of inflammatory infiltration. No hard-tissue formation adjacent to the retrograde material could be seen in any of the specimens. Summary of the histological findings are listed in Table 6.

Super-EBA:

The mean distance from the Super-EBA surface to the adjacent apical bone was 1216 μm . The majority of the cases showed a moderate to major (++ or +++) infiltration in the connective tissue and close to the material surface. Buccal cortical bone healing after the osteotomy preparation was seen in 4 of the cases. No hard-tissue formation adjacent to the retrograde material could be seen in any of the specimens. Summary of the histological findings are listed in Table 7.

MTA:

The mean distance from the MTA surface to the adjacent apical bone was 398,7 μm . Mild (+) inflammatory infiltration were seen for the majority of the MTA sections inside the connective tissue and adjacent to the material. In all sections there were signs of new hard tissue formation progressing from the periphery and into the centre over the MTA surface. This was interpreted as formation of new root cement and in all sections there were hard tissue formations in the periodontal space in the area nearby the MTA surface (Fig. 9). No signs of mature bone attachment to the material surface were seen. All 5 specimens revealed a re-establishment of the buccal cortical plate. Summary of the histological findings are listed in Table 8.

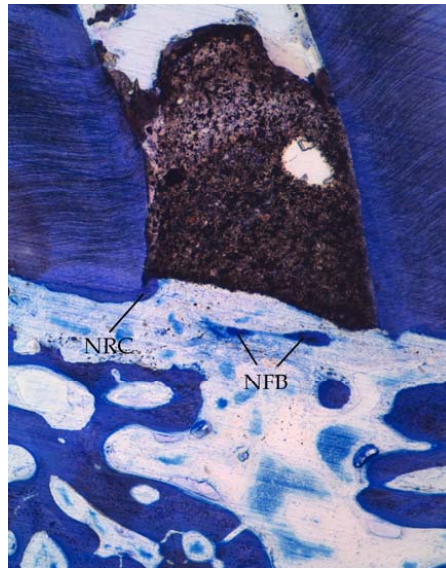


Figure 9. Specimen showing new formation of cement (NRC), growing from the periphery over the MTA surface and islands of new formed bone (NFB) in the close vicinity of the MTA surface. (Leica® DMD108 4X)

IRM:

The mean distance from the IRM surface to the adjacent apical bone was 571,7 μm . The cases displayed only mild (+) to moderate (++) inflammatory infiltration. In the non-bony periapical area mainly connective tissue was seen. No hard-tissue formation adjacent to the retrograde material could be seen in any of the specimens. All cases showed re-establishment of the buccal cortical plate. Summary of the histological findings are listed in Table 9.

Summary of an estimation of the radiographic appearance for all tested materials, regarding the density of the retrograde seal are listed in Table 10.

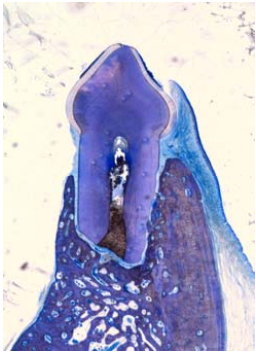
In all cases with signs of re-establishment of the buccal cortical bone, regardless the type of retrograde material, there was new root cement over the resected root surfaces. In the unhealed cases there was a very limited or absence of a new root-cement lining. Example of three different levels of outcome is showed in Fig 10.

SEM analysis

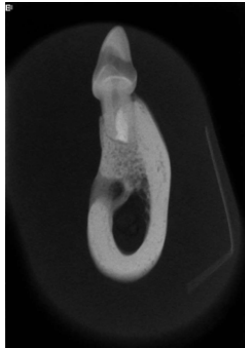
Cementum repair was noted on the resected root surfaces in all SEM analyzed specimens, where intact buccal cortical layer was established. Fragment of cementum repair on the resected root surface in analyzed specimens with a defect in the buccal cortical bone was also noted. The only material showing direct new hard tissue development on the material surface was MTA. The relation between the retrograde materials and the dentin surface and tubules, showed a variation between the materials.

Statistics

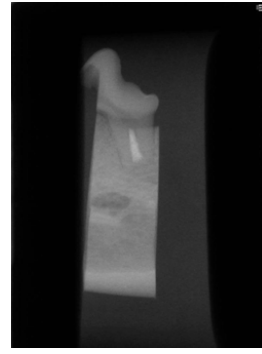
The tested outcome values were extracted from Table 6-9. There was no statistical significant difference between the materials regarding the tested parameters.



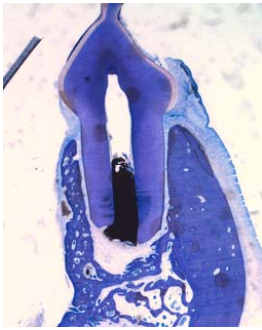
10a



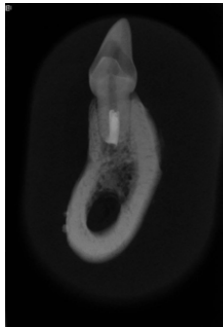
10b




10c



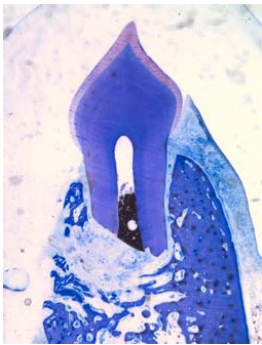
10d



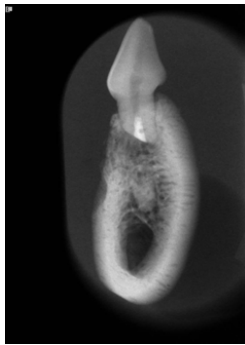
10e



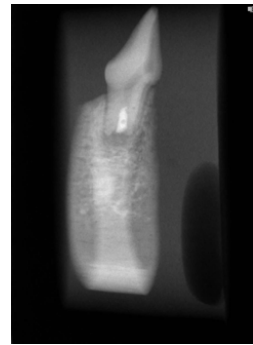
10f



10g



10h



10i

Figure 10. Three different outcome levels presented with a histological section and radiographs, showing a variety of buccal cortical bone re-establishment, periapical healing and inflammatory infiltration. Complete healed case with MTA (a-c). A case treated with GP showing a re-established buccal cortical bone, but with a widening of the apical periodontal ligament space with a mild inflammatory infiltration (d-f). A case treated with Super-EBA showing unhealed buccal cortical bone and periapical tissue with a severe inflammatory infiltration (g-i).

Table 6. Data from the histological findings in the periapical tissue for all analyzed Guttapercha sections. Maximum (max), minimum (min) average height (mean) of the retrograde material for each case.

No.	max (mm)	min (mm)	mean (mm)	inflammation	mean bone-material distance (µm)	buccal cortical bone re-established
1	5.5	4.7	5.10	+	1095	yes
2	2.5	1.4	1.95	+++	1975	no
3	3.8	3.2	3.50	++	998.8	yes
4	1.4	0.5	0.95	+++	2645	no
5	3.2	2.8	3.00	++	1550	no
6	3.9	3.2	3.55	+++	1550	no
Mean			3.00		1403	

Table 7. Data from the histological findings in the periapical tissue for all analyzed Super-EBA sections. Maximum (max), minimum (min) and average height (mean) of the retrograde material for each case.

No.	max (mm)	min (mm)	mean (mm)	inflammation	mean bone-material distance (µm)	buccal cortical bone re-established
1	2.1	2.0	2.05	+	634.5	yes
2	1.9	1.0	1.45	+++	1625	yes
3	2.0	1.1	1.55	+	368.1	yes
4	2.8	2.1	2.45	+++	2150	no
5	4.0	3.6	3.80	++	1450	no
6	2.1	1.4	2.25	+++	1068	yes
Mean			2.26		1216	

Table 8. Data from the histological findings in the periapical tissue for all analyzed MTA sections. Maximum (max), minimum (min) and average height (mean) of the retrograde material for each case.

No.	max (mm)	min (mm)	mean (mm)	inflammation	mean bone-material distance (µm)	buccal cortical bone re-established
1	2.2	1.9	2.05	++	822.8	yes
2	1.4	1.0	1.20	+	308.5	yes
3	1.9	1.6	1.75	+	282.7	yes
4	3.2	1.5	2.35	+	419.9	yes
5	2.7	1.5	2.10	++	1600	yes
Mean			1.89		398.7	

Table 9. Data from the histological findings in the periapical tissue for all analyzed IRM sections. Maximum (max), minimum (min) and average height (mean) of the retrograde material for each case.

No.	max (mm)	min (mm)	mean (mm)	inflammation	mean bone-material distance (µm)	buccal cortical bone re-established
1	2.4	1.8	2.10	++	621.3	yes
2	1.9	0.8	1.35	++	796.3	yes
3	2.7	1.6	2.15	+	304.2	yes
4	2.7	1.7	2.20	+	685.2	yes
5	3.3	2.8	3.05	+	231.5	yes
6	2.8	1.7	2.25	++	791.4	yes
Mean			2.18		571.7	

Table 10. Material density and root-canal outlining results from the radiographic analysis

Material	GP	Super-EBA	IRM	MTA
Density/outlining of the material				
Porous/poor	1	2	3	2
Dense/good	5	4	3	3
Total	6	6	6	5

Discussion

Clinical studies - Paper I-III

General outcome

The success rates presented in this thesis are high considering the entry protocol of the included patients. No preoperative exclusion of teeth with doubtful root-filling status evaluated on two-dimensional radiographs was performed (paper I-III). Only teeth with obvious fractures or advanced periodontal tissue loss i.e. apico-marginal communications were excluded.

The outcome from the three tested materials in the prospective clinical series; IRM 80-91% (paper I-III), gutta-percha, GP 90% (paper II) and Super-EBA 82% (paper III) are well comparable to other published studies. In two of the operated series of teeth (paper II and III) we used a randomization of IRM either to GP or Super-EBA. The difference in the outcome of the tested materials was not significant in any of the trials when looking at all types of teeth. This is explained by the number of included teeth. An approximate doubling of the number of included teeth had been required to obtain a significant difference in the treatment outcome.

The follow-up time in our studies was set to minimum 12 months which is enough to see effects of a periapical surgery treatment performed as the state of the art today i.e. use of ultrasonic preparation technique in combination with a root-end obturation. The long-term result is probably dependent on the type of material used, but in a short-term perspective all tested materials seems to be suitable from a clinical point of view.

Rubinstein et al¹⁰⁰ followed 59 roots treated with retrograde root-end fillings in Super-EBA for 5-7 years, which have had signs of complete healing at a one-year control. 8.5% of the previous healed cases showed regress of the periapical pathology at the long-term follow-up. Evidence for both complete healed cases turning into unhealed status and uncertain healed cases becoming healed or incomplete healed (scar) after a follow-up to 8 years, are also reported by Yazdi et al⁹⁰. However, the periapical obturation technique in their study differed from ours, while they used a dentin-bonded system together with Retroplast.

In a retrospective study from Dorn et al³³ with a follow-up of 6 months to 10 years, the results showed a success of 91% for IRM and 95% for Super-EBA. The preparation technique is not described and due to the retrospective design of the study, there is no defined preoperative protocol. Nevertheless the figures for IRM and Super-EBA presented in that study, are good in a long-term perspective. The same study evaluated also the use of amalgam for the same purpose, but the success was only 75%.

Another retrospective long-term healing analysis of amalgam was published by Frank et al³². The success rate was 57.7% after at least 10 years follow-up. Amalgam has also shown a higher rate of leakage in in-vitro studies compared to IRM and Super-EBA⁶⁴ and glass-ionomer cement¹⁰¹. Due to these figures and other environmental and health guide lines, the use of amalgam is not advisable.

Super-EBA has been used in conjunction with ultrasonic preparation technique in a clinical prospective series of 25 molars with 96% success after one year follow-up³⁷. The result is high but the study is only evaluating one type of retrograde material in a rather small number of treated teeth. Previously published data from larger clinical studies on heated gutta-percha, before we presented our result (paper II), is almost entirely lacking. A small material of only 29 teeth revealed a success of 84.2% after 12-41 months follow-up⁸¹.

The success figures for the IRM material in this thesis (paper I-III) have varied between 80 to 91% after 12 months follow-up (Fig. 11). This increase of the success figures for IRM, we believe is probably due to mainly by the learning curve for the performing surgeons. The success figures of IRM from paper II and III (85% and 91%) are both higher after 12 months follow-up, compared to a prospective study from Chong et al³⁸ where the 12 months success was 76% (n=44 of 58 reviewed cases) for IRM. At a second follow-up after 24 months the success was 87% for IRM. A questionable flaw could be that they reviewed only 39 teeth treated with IRM at 24 months and added 8 cases from the 12 months follow-up, which failed to attend for the 24 months control. These 8 cases were stated as complete healed at the 12 months review and were so assumed to be even at the 24 months control. In their study, a comparison of MTA and IRM was performed. MTA showed an increasing success from 84% at 12 months to 92% at 24 months.

There was no significant difference in the outcome result between the tested materials. This study included only single rooted teeth, one premolar or the mesio-buccal root of the first molar in the patients. That distinction is not used in our clinical studies, where we rather included all types of teeth.

Zuolo and co-workers³⁶ reported 91.2% success after following 102 teeth after periapical surgery with ultrasonic root-end preparation and IRM as a root-end filling material. In that study, the inclusion criteria differed somewhat from our protocol, in the sense that they also excluded teeth with missing buccal and lingual/palatal cortical bone plate and they included teeth that had an adequate final restoration without signs of coronal leakage. Only one tooth from each participating patient was included in their study.

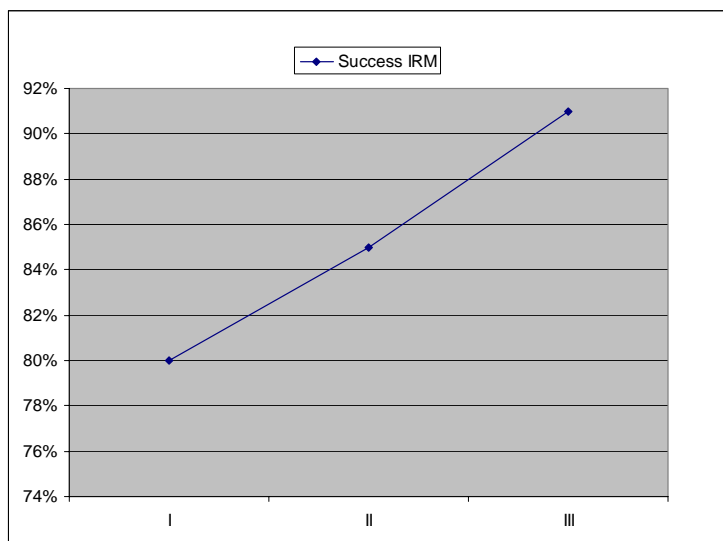


Figure 11. Alteration of the IRM success rates through paper I, II and III.

Preoperative status of the root-filling

One aim of this thesis was to evaluate the influence on the periapical surgery healing outcome regarding the preoperative status of the orthograde root-filling, judged from the preoperative radiograph (Paper III). It is previously advocated that a thorough cleaning and obturation of the root-canal prior to surgery is mandatory for the long-term result¹⁰².

A revision of the orthograde root-filling as a treatment alternative is the first consideration if applicable, but in many situations it is not possible and surgery is the treatment of choice. As we have performed surgery on teeth with a wide difference in the preoperative root-filling status, we have to assume that there are treated teeth with root-canals harbouring bacterial contents, which we have stopped from leaking into the periapical area using a root-end obturation. There is a report stating a better outcome after periapical surgery on teeth with dense orthograde root-fillings positioned 2 mm or shorter from apex¹⁰³. Nevertheless, our study did not reveal any significant influence from the preoperative root-filling status on the healing outcome after 12 months follow-up (Table 4).

In a longer perspective this result can change and that is dependent on the sealing ability over time of the material used as a retrograde seal. Late failures after periapical surgery are reported¹⁰⁴ and thereby it is advocated to perform the follow-up more than 12 months.

The importance to perform a periapical root-end seal together with the root-end resection, especially in teeth with insufficient orthograde root-fillings is previously stated³⁴. There is a

significant difference in the treatment outcome when comparing the treatment of performing only a root-end resection followed by a smoothing of the gutta-percha surface compared to prepare the root-canal with an ultrasonic technique followed by a retrograde root-end seal with MTA¹⁰⁵ with a favour of the latter procedure.

Type and size of the periapical lesion

The present thesis also evaluates the influence of the size and type of peripical lesion on the treatment outcome after the periapical procedure (paper III). We did not find any significant impact on the result from these two tested variables (Table 3 and 5). The lesion size was measured peri-operatively and the lesion type was decided at the same time from a clinical assessment of the removed periapical tissue in conjunction with the preoperative radiographic findings.

The optimal way to obtain the diagnosis of granulomas or cystic lesions is to perform a histological examination of all lesions, which was not undertaken in the present study. The main difficulty was probably to distinguish an acute stage, ie, apical abscess from a cyst. However, the distribution of the number of cysts and granulomas in our material corresponds well with other published results¹⁰⁶ and the incidence of cysts increase with increased size of the lesion^{8, 107}, which was confirmed in our study as well (Table 11).

Table 11. Distribution of lesion size and lesion type amongst the 194 followed teeth (paper III).

Lesion size	n	n cysts (%)	n granulomas (%)
< 5 mm	56	1 (1.8)	55 (98.2)
5-9 mm	102	11 (10.8)	91 (89.2)
> 9 mm	36	12 (33.3)	24 (66.7)
Total	194	24 (12.4)	170 (87.6)

Contrary to our results there are published data suggesting a worse outcome with larger lesions¹⁰⁸. In a prospective study on a patient cohort which had periapical surgery procedures performed by graduate students in Toronto, Canada, they found the preoperative lesion size (>5 mm in diameter) to be a significant negative predictor for the treatment outcome ($p=0.020$)¹⁰⁹.

The same cohort was followed another 4-10 years, where they lost 37% of the samples¹¹⁰. This second follow-up revealed a significant better prognosis on the outcome (healing in 74%) independent of the length of the orthograde root-fillings, in patients older than 45 years and in lesions not exceeding 10 mm in diameter.

In a meta-analysis of 140 papers on periapical surgery, von Arx et al evaluated a number of prognostic factors and found a higher number of healed cases with good preoperative root-fillings and absence of lesions not exceeding 5 mm in diameter¹¹¹. The results reported in the two previous articles referred to, are in contrast to our results. The follow-up time is longer in these papers and therefore a prolonged follow-up time might change our results.

Ultrasonic root-end preparation

The advantage of the ultrasonic retrograde root-end preparation is the ability to stay more centred into the canal and obtain a good depth of the preparation¹¹². The ultrasonic preparation technique compared to the classical round-bur technique, has also shown to improve the outcome in clinical randomized trials with a significant difference in treatment of molars⁵⁴.

The use of retrotips on the ultrasonic device eases the access to the root-canals of molars, resulting in a better preparation and position for a successful treatment outcome. In our study, the treatment outcome follows the type of tooth and position in the mouth (paper I-III). The success rates were slightly lower in more posterior teeth (Table 2). In any way the access and ability to prepare the canals in a limited space is helped by using the retrotips on ultrasonic devices.

In the first series of teeth, we used only stainless steel retrotips (paper I), in the second series (paper II) we used both stainless steel and diamond coated retrotips and in the third study (paper III) we only used diamond coated retrotips. The possible influence of the treatment outcome from this alteration through the series is not evaluated. However, a contributing factor to the increase of the success figures, could be a result of the progressive transition of using diamond coated retrotips, which is shown to result in better preparations of the root-canals¹¹³.

There are some drawbacks reported such as an increased amount of smear-layer on the canal walls, when using diamond coated retro-tips, which may affect the apical seal. This study also concluded that the same type of retro-tips did not significantly increase the risk of causing cracks on the dentinal walls¹¹⁴. However, an improper use of the ultrasonic preparation technique together with diamond coated retro tips compared to the use of stainless steel has shown an increased risk of over-preparation and events of perforations.

The diamond-coated retro-tip also obtains a better preparation surface in less time compared to stainless steel, which in turn resulted in fewer crack formations¹¹³. The intensity effect on the ultrasonic device is crucial for the emergence of dentinal cracks and should be kept as low as possible¹¹⁵ and the use of diamond coated retrotips allow for a lower power setting of the ultrasonic device.

Root-canal anatomy and isthmuses

The root-canal anatomy has a complex appearance and does not look like a long straight tube in cross section. The shape may take a wide variety of different forms, for example, oval or kidney-shaped and this may complicate the cleaning and filling of the canal during the endodontic treatment (Fig. 12).

The majority of the apical delta is expected to be removed during the root-end resection, but there may still be some aberrant apical canals in roots with more than one canal, so-called isthmuses. These shall be prepared and completed at the procedure, to prevent future leakage from the coronal direction of the root canal. Isthmuses often appear in the mesio-buccal root of the first maxillary molar and are present in 60%⁵². The preparation of the isthmuses is more precise with the use of the ultrasonic retrotips.

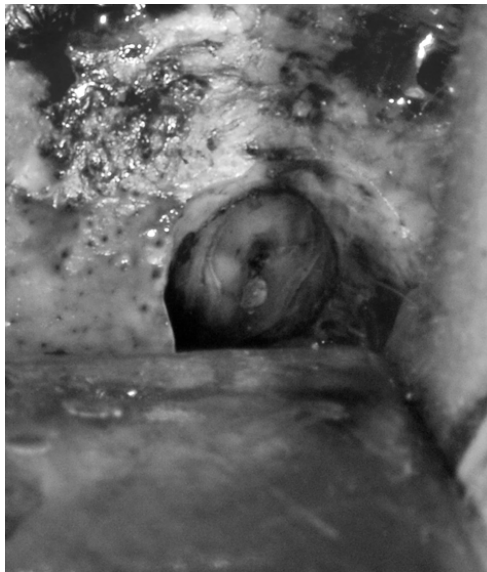

Figure 12. A resected distal root of a mandibular molar showing the cross section of the circular gutta-percha cone centrally placed in the kidney/bean shaped canal.

Retrograde material consistency and height of the retrograde root-filling

The handling of the material and the ability to place it properly into the canal is highly dependent on the texture of the material, which in turn affects the obturation height. We found that the Super-EBA material was more difficult to use due to the slight softer consistency (paper III), which made it difficult to condense and achieve a sufficient height.

We believe this is one of the explanations of the slight lower success number for Super-EBA, 82%, compared to IRM, 91% (paper III). The time, during the team had been using Super-EBA, was also shorter compared to IRM, which also can effect the outcome result in terms of being accustomed to using the material. We mixed the Super-EBA material according to the manual with a P/L ratio of 2:1. The consistency and the handling could probably be improved by an altered mixing ratio including more powder.

The advantage of using the heated gutta-percha, GP together with a sealer (AH-Plus®) is the injection of the gutta-percha resulting in a good height of the obturation in general, which could be seen on the postoperative radiographs (paper II). The use of a sealer is important to get an adherence to the dentinal wall of the obturation material.

A negative aspect of using thermo-plasticized GP could be the long-term stability of the root-end seal, when it is known that there is an initial shrinkage of the material during the cooling of the material^{116, 117}. This might concomitantly affect the adherence of the material to the dentinal wall (Fig. 13).

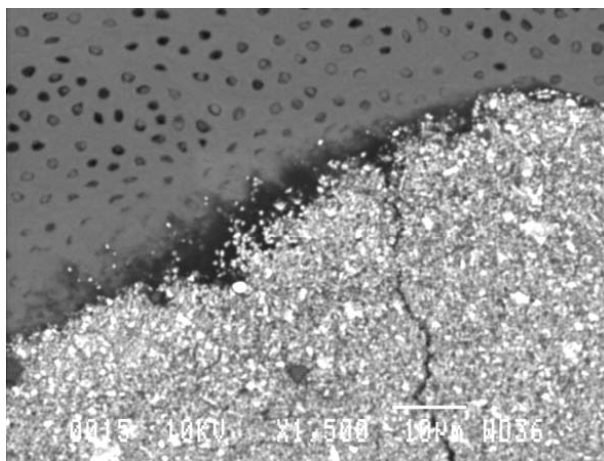


Figure 13. The GP material and the sealer could be seen in the closest dentinal tubules but there are some porosities (darker areas in the center) at the material-dentin border which might be an indication of the shrinking of the GP material (SEM 1500X).

Aspects on the clinical handling of the retrograde materials

GP

One drawback of using GP is the two-stage obturation procedure, where the sealer has to be placed into the canal first, followed by the injection of the thermo-plasticized GP. The time elapsing in between is critical when the operator is preparing the GP injection device and hand over the operating field to the assistant in terms of keeping it dry. However, the injection technique allows a good primary filling of the prepared canal.

IRM

The material is mixed by hand on a glass-plate (Figure 3) to achieve a plastic consistency, thus easing the insertion and condensation of the material into the prepared canal. The majority of the powder should be mixed into the liquid from the start to get sufficient working time.

If the temperature and humidity level in the operating theatre is high, the material tends to set too fast. The powder is sensitive to moisture and should be kept in a tight seal too prevent the material from solidifying too quickly.

Super-EBA

The material comes in two different setting modules, fast and soft setting. We used the fast setting formula for all cases. The P/L mixing ratio is 2:1 and is performed by hand on a glass-plate. The material is stickier and not as plastic in its consistency as IRM, why the insertion and condensation is made more difficult.

MTA

The mixing of the MTA powder into the sterile water should result in a hydro gel which then can be inserted into the canal. The mixing procedure is sensitive and the material should not become too dry or too moist. The material then sets in a moist environment and should be kept from becoming too dry and from blood contamination during the setting time.

Due to these features the material is technically hard to handle both for the assistant and the operating surgeon.

Aspects on adverse reactions from the tested materials

Considering the presence of allergic or systemic effects of the tested materials in this thesis, there are no contraindications to use them as retrograde root-fillings⁵⁰. However, in patients with known hypersensitivity to any components, alternative materials should be used.

The materials which are mixed are often more prone to give adverse effects in the fresh mixed state due to high concentrations of the components. Examples of that is eugenol released from IRM and Super-EBA¹¹⁸⁻¹²¹ and the formaldehyde or epoxy monomer, released from the epoxy resin based sealer (AH-Plus®) immediately after mixing¹²².

After the initial setting, the AH plus sealer seems to be more stable¹²³. Adverse reactions from GP are rare, but in patients with known hypersensitivity to latex, allergic reaction to gutta-percha together with chloroform might occur¹²⁴.

MTA have no signs of allergic reactions reported but has revealed a lower cytotoxic influence on cell culture compared to IRM and Super-EBA, but for all materials there were an increased level of cytotoxicity in the fresh state¹²⁵.

Endodontic and periapical surgery outcomes dependent on the coronal restoration

Conventionally endodontic treatment outcome is dependent on the following coronal restoration. Previously endodontically treated teeth with temporary fillings are lost more often compared with teeth treated with permanent coronal restorations (cast restorations, amalgam and composite)¹²⁶. It is advocated to have a permanent restoration performed as soon as possible after finishing the endodontic treatment¹²⁷.

The survival of endodontically treated molars up to 5 years is 36% when not covered with a crown restoration and the extent of remaining tooth substance seems to affect the survival rate amongst of endodontically treated teeth without crown restorations¹²⁸.

According to these publications, the reason for failure in previously root-filled teeth with conventional crown fillings could depend on an increased leaking load of bacterial contents from the coronal direction, which might be decreased with a completed crown restoration.

In a large population study of 1.4 million teeth from Sahlerabi et al¹²⁹, they reported a successful outcome of 97% after conventional endodontic treatment after 8 years. The other 3% were re-treatments, periapical surgery procedures and extractions which in majority occurred during the first 3 years. The majority (85%) of the extracted teeth rendered a missing full crown restoration.

The presence of an adequate coronal restoration with no clinical signs of coronal leakage was used as an inclusion criterion in a study on periapical surgery by Zuolo et al³⁶. In our study we recorded the type of coronal restoration preoperatively (Table 1 in paper III) and regarding our cases with a filling restoration, there are indications of an influence on the treatment outcome also after periapical surgery regarding the above discussion.

Experimental model - Paper IV

Aspects on the experimental model design

Two of the 4 tested retrograde root-filling materials, IRM and MTA revealed better outcome results compared to Super-EBA and GP, regarding the established investigation protocol. The amount of inflammatory infiltration in the periapical area and re-establishment of the periodontal structures and alveolar bone were evaluated.

The fact that all materials were obturated against remnants of a vital pulp i.e. a liquid phase, there is an impact on the setting of the materials by the moistures environment in the coronal part of the material and we must assume that the pulp has become necrotic during the 4 months between the surgery and the sacrifice procedure.

In the most common clinical situations we have a previous obturated root-canal which is not giving these conditions. However, this situation was the same for all tested materials thus testing the ability of the material to perform in the presence of moisture. This must be counted for when looking at the results of the evaluated parameters.

The root-canals of the 3rd and 4th right mandibular molars (Fig. 6), were all provided with the same material in the same root-canal in each animal. This organized distribution of the materials is a weakness in the experiment model and might have a possible influence on the outcome.

A randomized distribution would have been beneficial and might have changed the resulting figures. The number of 6 included dogs with a total of 24 treated teeth is too small to obtain statistical significant difference in the results and could probably been altered by increasing the number of treated animals.

Sealing ability and antibacterial properties

All 4 tested materials have to accept some moisture during setting, why they would not otherwise have been able to function as a retrograde root-end seal. In this particular situation with the liquid phase, the setting of the used epoxy based sealer AH-Plus might have been affected¹³⁰, which also can be the fact for the Super-EBA material because of its chemical composition¹³¹. Evidence that IRM and MTA are good inhibitors of bacterial growth^{132, 133} and that they hold a good sealing ability^{64, 134}, could be an explanation for the better outcome for these materials. Despite that, there are published data indicating worse sealing results for IRM¹³¹. The antibacterial ability of IRM can probably largely be attributed to the contents and leaking of eugenol in the material^{118, 120}.

This antibacterial ability of MTA and IRM should also give effect on the coronal side of the retrograde root-filling, thus preventing bacterial leakage in the apical direction. Several leakage study models investigating the sealing ability of different proposed retrograde root-filling materials have been published. The problem is that a model similar to an in vivo situation can not be created in vitro.

Gondim and co-workers published a dye leakage study¹³⁵ on IRM, Super-EBA and MTA (ProRoot®) where MTA showed significant less mean leakage compared to the other tested materials. Super-EBA revealed the greatest mean dye leakage in that study. The overall conclusion was that neither of the materials could avoid leakage totally which then indicates the importance of the orthograde root-canal seal.

Super-EBA and IRM have shown increased leakage in other publications compared to compomers (Dyract and Geristore)^{63, 136} and MTA versus Super-EBA and amalgam¹³⁷. However, compomers are more difficult to handle regarding the sensitivity to moisture in the setting phase compared to IRM, Super-EBA and MTA.

The ability to withstand dye and bacterial leakage from two in-vitro studies^{96, 134} showed a superior result for MTA compared to IRM and Super-EBA. During the testing period of 90 days, MTA did not show any signs of leakage¹³⁴. When using the GP material as a retrograde root-end filling it is advocated to combine the obturation with a root-canal sealer, to obtain a significant better sealing of the root-canal^{185, 88}.

The difference in contraction and expansion of the tested materials is also an influencing factor for the sealing result, primary in the short-term perspective, due to that these events mainly occur during the setting phase^{117, 138-140}. A longer setting time is giving less contraction and vice versa in general. IRM has a setting time of 5 min⁹⁴, while there is a slight contraction initially of the material.

Results of long-term dimensional changes in IRM of 0.05% the first 8 hours and 0.15% after 30 hours after in-vitro dry-heating in 37 degrees Celsius have been published¹³⁸. This alteration in material volume can affect the long time sealing properties of IRM, but it still a difference in vivo and in vitro.

In our trial it seems that Super-EBA is less dense than IRM according to the results. The supposed increased leakage around Super-EBA might depend on the softer consistency followed by a greater contraction of the material. MTA has a slight expansion during its longer setting-time. The setting time and the amount of expansion differ with different types of MTA¹³⁹. The expansion is in the size to obtain a good seal and enough not to cause a fracture of the root.

The AH-Plus sealer and the GP material also undergo dimensional changes during the setting. The shrinkage of the Ultrafil® thermo-plasticized GP is 2.2%¹¹⁷ and the AH Plus sealer is expanding up to 0.9% after 4 weeks¹⁴⁰. This should indicate that these materials are complementary to each other in terms of its dimensional changes.

Height of the retrograde root-filling

The mean heights of the retrograde root-fillings among the materials was in descending order GP (3.00 mm), Super-EBA (2.26 mm), IRM (2.18 mm) and MTA (1.89 mm). The evidence and message that the height of the retrograde filling should be 3-4 mm in height^{51, 93}, put the above results into contradiction. The explanation to this might be the design of the trial model, as discussed above, with the materials setting against the vital remnants of the pulp and the difference in shrinkage/expansion of the materials.

Inflammatory infiltration and re-establishment of the alveolar bone

The degree of inflammatory infiltration in the periapical area for the treated teeth correlated generally to the healing of the buccal cortical bone plate (Table 6-9), except two cases treated with Super-EBA (no.2 and 6, Table 7), which showed a major inflammatory infiltration despite healing of the buccal bone. The cases showing moderate inflammation and signs of a remaining defect but with a healing of the buccal osteotomy (Fig. 10 d-f), could be signs of ongoing healing events.

The time between surgery and sacrifice of the animals is similar as 6 months in man and we can expect not fully healed cases after that time. This can be an explanation to the possible signs of ongoing healing, which also can be prolonged by the greater chewing forces in the dogs causing a greater mobility of the teeth.

The distance from the resected dentin surface to the adjacent alveolar bone varied with the healing and the mean distance were higher for GP and Super-EBA compared to IRM and MTA (Table 6-9), thus revealing a greater proportion of healed alveolar bone for the latter materials.

This periapical bone healing event is also presented in a recent study from Baek et al, where they treated teeth with earlier induced apical periodontitis¹⁴¹. They found a significant better healing for MTA when compared to amalgam but not to Super-EBA. The mean distance for MTA was 0.397 mm, which is in line with our result for MTA (0.399 mm) and this resemble the normal periodontal width of beagle dogs¹⁴².

However, according to our results it seems that all tested materials are well accepted by the periapical tissue in terms of the inflammatory infiltration and buccal cortical bone healing, due to the presence of successful cases in all material groups.

Regeneration of cemental tissue and periodontal ligament

All cases, regardless what material we used, with complete healing of the buccal cortical bone plate, revealed signs of a new cement-like tissue over the resected dentin surface. This appearance could not be detected on the unhealed cases.

This finding is consistent with a publication from Andreasen¹⁴³, who reported evidence of cementum repair over previous resected dentin surfaces in connection with periapical surgery. He also described an arrangement of new periodontal fibers in the new cemental tissue in different appearances.

The healed specimens of the present study, showed arrangement of new periodontal fibers in close contact of the new cement-like tissue as well (Fig. 14), indicating a regeneration of the periodontal ligament. The absence of cementum repair in unhealed cases was also reported by Andreasen.

A prerequisite for a cementogenesis is the allowance and ability for cementoblasts to attach and grow on the surface of the dentine and the retrograde material. MTA is the only material in this study, which has shown to harbour the right surface conditions and compositions to allow this event^{65, 144, 145}. However, the concentrations of the MTA material influence the cementogenesis, in the way that high levels are toxic for the cementoblasts¹⁴⁶.




Figure 14. Formation of new periodontal fibers (PF) parallel to the MTA material surface, indicating reformation of the periodontal ligament close to the retrograde material.

Osteoblasts and material surfaces

In a situation where the infection source has been eliminated and the healing event of the periapical tissues continues, the presences of osteoblasts are important. Attachment and growth of osteoblasts, similar to cementoblasts, to different retrograde root-filling materials are also studied.

Zhu and co-workers published a study where the influence on the osteoblast activity from IRM and MTA was studied¹⁴⁷. In this in-vitro model the MTA surface allowed attachment and spread of the osteoblasts, while the cells looked rounded and with no spread on the IRM surface. The same result for MTA has been published in another study¹⁴⁸, where Super-EBA also was tested and shown to inhibit cell growth. This impairment of cell growth by IRM and Super-EBA may probably be attributed to the leaking of eugenol from these materials.

This statement explains the result from the MTA specimens in our study, which show signs of new cement-like tissue growing on the material surface and new bone in the very close vicinity of the MTA material (Figure 9), which is absent for the other tested materials.

The same capability of osteoblasts in relation to the MTA material is presented by Koh et al¹⁴⁹, where they also reported that MTA stimulates the cytokine production in the osteoblasts and thereby promoting the bone healing.

Physicochemical properties of MTA and hard-tissue formation

The main elements in MTA are calcium and phosphorous⁹⁷ and these ions are components in dental hard tissue as well, which can explain the favorable biocompatibility of MTA in the periapical tissue region. It has been found that MTA is releasing calcium ions which react with phosphates in synthetic fluid resembling tissue fluid, resulting in a hard-tissue formation of hydroxyapatite¹⁵⁰ and this might explain the ability of MTA to allow new hard tissue formation on its surface in vivo.

The interface event in the MTA-dentine contact and the sealing ability of the material is also believed to arise from this apatite formation. The gradual formation of hydroxyapatite crystals in the MTA-dentine interface leads to an initial mechanical bond and gradually becomes a chemical bond¹⁵⁰. This formation of a mechanical and chemical bonding interface layer between MTA and dentin also results in increased push-out bond strength of the MTA material¹⁵¹.

Influence on fibroblasts

The attachment of and influence on both periodontal ligament, PDL and gingival fibroblasts regarding different retrograde materials are reported. In a study where five retrograde root-filling materials were compared regarding the influence on human PDL fibroblasts¹⁵², the results showed little negative effect on the cells from MTA, while the eugenol containing materials IRM and Super-EBA revealed a decreased number of viable PDL fibroblasts in higher eugenol concentrations in this study model.

The authors stated that the amount of eugenol diffused from in vivo set IRM and Super-EBA retrograde root-fillings is still unknown. The MTA material was suggested to be biocompatible according to their results.

Many retrograde root-filling materials are initially more cytotoxic to viable cells and are so also reported for fibroblasts¹⁵³. After the setting period and washing of the tested materials, MTA, amalgam and composite resin for 2 weeks, the PDL fibroblasts showed an increased proliferation on the MTA material surface. That study also reported the ability of MTA to induce alkaline phosphatase expression and activity in both PDL and gingival fibroblasts, which has a role in cementum deposition and bone healing.

The cytotoxicity on human PDL fibroblasts from MTA compared to amalgam and super-EBA after 24 hours setting is lower for the first material, thus suggesting the favour of using MTA in the root-end environment¹⁵⁴.

General discussion (Paper I-IV)

According to our experimental results in terms of cortical bone healing and amount of inflammatory response, IRM and MTA seems to be more suitable materials as retrograde root-filling materials compared to GP and Super-EBA. Nevertheless we have to emphasize the fact that the GP material with the sealer and Super-EBA might have been influenced by the moist environment in the experimental model, which is not the case in most of the clinical situations.

When considering the results from a biocompatible point of view, MTA is the optimal material to use in periapical surgery procedures. IRM used as a retrograde root-filling has also a good prognosis according to our clinical outcomes. This is in line with published review data from Tang et al, who suggests the use of MTA and IRM as retrograde root-fillings before amalgam and pure gutta-percha¹⁵⁵.

Another question which should be stated is how long time a periapically affected tooth, after a treatment surgically or conventionally, is supposed to be in function? If we can extend the functioning time for a supporting tooth in a prosthodontic construction by performing a periapical surgery procedure, this treatment is an excellent alternative compared to an extraction and loss of occlusal contacts and probably bigger costs to rehabilitate the patient. This issue needs to be discussed with all patients in such situations.

Conclusions

- The success rates regarding healing after 12 months is high for all tested materials and show that these materials can serve as a root-end seal in periapical surgery with ultrasonic preparation.
- The radiographic status of the orthograde root-filling, type and size of the periapical lesion, do not have a significant influence on the treatment outcome after a one-year follow-up.
- Formation of new root-cement on resected dentine surfaces in the periapical region is seen in healing situations, regardless of the used retrograde material.
- The MTA material allows formation of new cement-like hard tissue in direct contact with the material surface.
- The MTA material seems to be more biocompatible compared to the other tested materials and should because of this be the first material of choice, but from the clinical results in this study, the other materials are suitable as retrograde root-fillings as well.

Clinical considerations

- The success figures in this study might be altered after a longer follow-up period.
- There is a difference in the perioperative handling of the tested materials, which could be an explanation to the slight variation of the healing figures.
- Regardless what retrograde material used by the surgical team, they must be confident in its handling and management.
- Periradicular surgery together with ultrasonic root-end preparation is an excellent treatment method for a wide range of teeth with remaining periapical periodontitis and should be used in modern surgical dentistry.

Acknowledgements

I would like to express my sincere appreciation and gratitude to all who have made this thesis possible, in particular:

My supervisors:

Sten Isaksson, for inspiration, encouragement and guiding through the thesis, through my surgical training years and for sharing all your scientific knowledge and never-ending enthusiasm. I will always be grateful to you.

Lars Sennerby, for sharing your great research experience, for all your help and guiding through the experimental study. I have learned a lot from you.

Christer Dahlin, for all your inputs and discussions and especially for all help with the planning of the dissertation defense.

My co-authors:

Peter Abrahamsson, my friend already since dental school, for your help and work with the clinical and experimental trials and for inspiring discussions. I will always remember our adventure in Brazil! I am looking forward to work with you in the future as well.

John-Eric Blomqvist, for your help with the clinical reviews and for sharing your great experience and guiding me during the early years especially in my orthognatic surgical training.

Kjell-Arne Sämfors and Maria Fogelin, for your help with the radiographic evaluation procedures.

Luiz Salata, for your enormous hospitality and help with the experimental trial in Brazil.

Per Herrström, for your inputs and discussion in the writing of Paper I.

Johan Malmström, for all help with the clinical reviews and the SEM procedure.

Tony Axéll, Jonas Anderud, Ali Amini and Fredrik Widar, for your help with the clinical reviews.

Svante Twetman, for your enthusiastic encouragement in everything and valuable input.

Amir Baigi, for helping and guiding me through the statistical work.

Andy Brown, for sharing your great surgical skills and knowledge and for your help with reading through paper III, IV and inputs in the thesis.

Jan Gottlow, for providing your radiographic equipment and help in the experimental study.

Petra Hammarström and co-workers at Biomaterials for an excellent work with the specimens.

Ingrid Olsson and Anki Skoglund, for all help with the files and patients in the clinical studies.

All nurses at the Maxillofacial Unit in Halmstad for your excellent assistance in the surgical procedures.

My lovely parents, Eva and Roland, for all support during my life and for that you encouraged me to stay in natural science during the high school years.

Finally and most of all, Anna, my lovely and loving wife, for your never-ending patience and encouragement. My two wonderful and lovely daughters, Ellen and Julia, who have promised to read daddy's book when they grown up.

This thesis has been supported by grants from the Scientific Board of the County Council of Halland.

References

- [1] Brophy TW. Caries of the superior maxilla. *Chicago Medical Journal and Examiner* 1880;41:582-6.
- [2] Farrar JN. Radical and heroic treatment of alveolar abscess by amputation of roots of teeth. *Dental Cosmos* 1884;26:79-81.
- [3] Rhein ML. Cure of acute and chronic alveolar abscess. *Dental Items of Interest* 1897;19:688-702.
- [4] Partsch C. Dritter Bericht der Poliklinik für Zahn- und Mundkrankheiten des zahnärztlichen Instituts der Königl. Universität Breslau. *Deutsche Monatsschritte für Zahnheilkunde* 1896;14:486-99.
- [5] Kakehashi S, Stanley HR, Fitzgerald RJ. The Effects of Surgical Exposures of Dental Pulps in Germ-Free and Conventional Laboratory Rats. *Oral Surg Oral Med Oral Pathol* 1965 Sep;20:340-9.
- [6] Bergenholtz G. Pathogenic mechanisms in pulpal disease. *J Endod* 1990 Feb;16(2):98-101.
- [7] Sundqvist G. Bacteriological studies of necrotic dental pulps. Umeå University Odontological Dissertation ed. Umeå: University of Umeå; 1976.
- [8] Mortensen H, Winther JE, Birn H. Periapical granulomas and cysts. An investigation of 1,600 cases. *Scand J Dent Res* 1970;78(3):241-50.
- [9] Nair PN. New perspectives on radicular cysts: do they heal? *Int Endod J* 1998 May;31(3):155-60.
- [10] Shear M, Speight, P. Cysts of the oral and maxillofacial regions. 4th ed. Oxford: Blackwell Mansard: 2007.
- [11] Nair PN. Apical periodontitis: a dynamic encounter between root canal infection and host response. *Periodontol* 2000 1997 Feb;13:121-48.

- [12] Nair PN, Sundqvist G, Sjogren U. Experimental evidence supports the abscess theory of development of radicular cysts. *Oral Surg Oral Med Oral Pathol Oral Radiol Endod* 2008 Aug;106(2):294-303.
- [13] Nair PN. Pathogenesis of apical periodontitis and the causes of endodontic failures. *Crit Rev Oral Biol Med* 2004;15(6):348-81.
- [14] Bergenholtz G, Lekholm U, Liljenberg B, Lindhe J. Morphometric analysis of chronic inflammatory periapical lesions in root-filled teeth. *Oral Surg Oral Med Oral Pathol* 1983 Mar;55(3):295-301.
- [15] Kontiainen S, Ranta H, Lautenschlager I. Cells infiltrating human periapical inflammatory lesions. *J Oral Pathol* 1986 Nov;15(10):544-6.
- [16] Lerner UH. Osteoclast formation and resorption. *Matrix Biol* 2000 May;19(2):107-20.
- [17] Garg AK. *Bone Biology, Harvesting, Grafting for Dental Implants. Rationale and Clinical Applications*: Quintessence Publishing Co, Inc: 2004.
- [18] Kojima K, Inamoto K, Nagamatsu K, Hara A, Nakata K, Morita I, et al. Success rate of endodontic treatment of teeth with vital and nonvital pulps. A meta-analysis. *Oral Surg Oral Med Oral Pathol Oral Radiol Endod* 2004 Jan;97(1):95-9.
- [19] Sjogren U, Hagglund B, Sundqvist G, Wing K. Factors affecting the long-term results of endodontic treatment. *J Endod* 1990 Oct;16(10):498-504.
- [20] Orstavik D. *PFTR. Essential Endodontology, Prevention and Treatment of Apical Periodontitis*. 1 ed: Blackwell Science Ltd: 1998.
- [21] Kerekes K, Tronstad L. Long-term results of endodontic treatment performed with a standardized technique. *J Endod* 1979 Mar;5(3):83-90.
- [22] Rud J, Andreasen JO, Jensen JE. Radiographic criteria for the assessment of healing after endodontic surgery. *Int J Oral Surg* 1972;1(4):195-214.
- [23] Molven O, Halse A, Grung B. Observer strategy and the radiographic classification of healing after endodontic surgery. *Int J Oral Maxillofac Surg* 1987 Aug;16(4):432-9.

- [24] Penarrocha Diago M, Ortega Sanchez B, Garcia Mira B, Marti Bowen E, von Arx T, Gay Escoda C. Evaluation of healing criteria for success after periapical surgery. *Med Oral Patol Oral Cir Bucal* 2008 Feb;13(2):E143-7.
- [25] Low KM, Dula K, Burgin W, von Arx T. Comparison of periapical radiography and limited cone-beam tomography in posterior maxillary teeth referred for apical surgery. *J Endod* 2008 May;34(5):557-62.
- [26] Tanomaru-Filho M, Lima RK, Nakazone PA, Tanomaru JM. Use of computerized tomography for diagnosis and follow-up after endodontic surgery: clinical case report with 8 years of follow-up. *Oral Surg Oral Med Oral Pathol Oral Radiol Endod* 2010 Apr;109(4):629-33.
- [27] de Paula-Silva FW, Santamaria M, Jr., Leonardo MR, Consolaro A, da Silva LA. Cone-beam computerized tomographic, radiographic, and histologic evaluation of periapical repair in dogs' post-endodontic treatment. *Oral Surg Oral Med Oral Pathol Oral Radiol Endod* 2009 Nov;108(5):796-805.
- [28] Bornstein MM, Lauber R, Sendi P, von Arx T. Comparison of periapical radiography and limited cone-beam computed tomography in mandibular molars for analysis of anatomical landmarks before apical surgery. *J Endod* 2011 Feb;37(2):151-7.
- [29] Lofthag-Hansen S, Huumonen S, Grondahl K, Grondahl HG. Limited cone-beam CT and intraoral radiography for the diagnosis of periapical pathology. *Oral Surg Oral Med Oral Pathol Oral Radiol Endod* 2007 Jan;103(1):114-9.
- [30] Jorge EG, Tanomaru-Filho M, Goncalves M, Tanomaru JM. Detection of periapical lesion development by conventional radiography or computed tomography. *Oral Surg Oral Med Oral Pathol Oral Radiol Endod* 2008 Jul;106(1):e56-61.
- [31] von Arx T. Failed root canals: the case for apicoectomy (periradicular surgery). *J Oral Maxillofac Surg* 2005 Jun;63(6):832-7.
- [32] Frank AL, Glick DH, Patterson SS, Weine FS. Long-term evaluation of surgically placed amalgam fillings. *J Endod* 1992 Aug;18(8):391-8.

- [33] Dorn SO, Gartner AH. Retrograde filling materials: a retrospective success-failure study of amalgam, EBA, and IRM. *J Endod* 1990 Aug;16(8):391-3.
- [34] Hirsch JM, Ahlstrom U, Henrikson PA, Heyden G, Peterson LE. Periapical surgery. *Int J Oral Surg* 1979 Jun;8(3):173-85.
- [35] Tsisis I, Rosen E, Schwartz-Arad D, Fuss Z. Retrospective evaluation of surgical endodontic treatment: traditional versus modern technique. *J Endod* 2006 May;32(5):412-6.
- [36] Zuolo ML, Ferreira MO, Gutmann JL. Prognosis in periradicular surgery: a clinical prospective study. *Int Endod J* 2000 Mar;33(2):91-8.
- [37] von Arx T, Gerber C, Hardt N. Periradicular surgery of molars: a prospective clinical study with a one-year follow-up. *Int Endod J* 2001 Oct;34(7):520-5.
- [38] Chong BS, Pitt Ford TR, Hudson MB. A prospective clinical study of Mineral Trioxide Aggregate and IRM when used as root-end filling materials in endodontic surgery. *Int Endod J* 2003 Aug;36(8):520-6.
- [39] Rubinstein RA. Magnification and illumination in apical surgery. *Endodontic Topics* 2005;11:56-77.
- [40] Stropko JJ, Doyon GE, Gutmann JL. Root-end management: resection, cavity preparation, and material placement. *Endodontic Topics* 2005;11:131-51.
- [41] von Arx T, Hunenbart S, Buser D. Endoscope- and video-assisted endodontic surgery. *Quintessence Int* 2002 Apr;33(4):255-9.
- [42] Taschieri S, Del Fabbro M, Testori T, Weinstein R. Endoscopic periradicular surgery: a prospective clinical study. *Br J Oral Maxillofac Surg* 2007 Apr;45(3):242-4.
- [43] Taschieri S, Del Fabbro M, Testori T, Weinstein R. Microscope versus endoscope in root-end management: a randomized controlled study. *Int J Oral Maxillofac Surg* 2008 Nov;37(11):1022-6.

- [44] Taschieri S, Del Fabbro M, Testori T, Francetti L, Weinstein R. Endodontic surgery using 2 different magnification devices: preliminary results of a randomized controlled study. *J Oral Maxillofac Surg* 2006 Feb;64(2):235-42.
- [45] Del Fabbro M, Taschieri S. Endodontic therapy using magnification devices: a systematic review. *J Dent* Apr;38(4):269-75.
- [46] Kim S, Kratchman S. Modern endodontic surgery concepts and practice: a review. *J Endod* 2006 Jul;32(7):601-23.
- [47] Velvart P, Ebner-Zimmermann U, Pierre Ebner J. Papilla healing following sulcular full thickness flap in endodontic surgery. *Oral Surg Oral Med Oral Pathol Oral Radiol Endod* 2004 Sep;98(3):365-9.
- [48] Rud J, Andreasen JO. Operative procedures in periapical surgery with contemporaneous root filling. *Int J Oral Surg* 1972;1(6):297-310.
- [49] Gutmann JL, Pitt Ford TR. Management of the resected root end: a clinical review. *Int Endod J* 1993 Sep;26(5):273-83.
- [50] Bergenholtz G, Hörsted-Bindslev, P., Reit, C. *Textbook of Endodontology* Second edition ed: Wiley-Blackwell: 2010.
- [51] Gilheany PA, Figdor D, Tyas MJ. Apical dentin permeability and microleakage associated with root end resection and retrograde filling. *J Endod* 1994 Jan;20(1):22-6.
- [52] Weller RN, Niemczyk SP, Kim S. Incidence and position of the canal isthmus. Part 1. Mesiobuccal root of the maxillary first molar. *J Endod* 1995 Jul;21(7):380-3.
- [53] Khabbaz MG, Kerezoudis NP, Aroni E, Tsatsas V. Evaluation of different methods for the root-end cavity preparation. *Oral Surg Oral Med Oral Pathol Oral Radiol Endod* 2004 Aug;98(2):237-42.
- [54] de Lange J, Putters T, Baas EM, van Ingen JM. Ultrasonic root-end preparation in apical surgery: a prospective randomized study. *Oral Surg Oral Med Oral Pathol Oral Radiol Endod* 2007 Dec;104(6):841-5.

- [55] Mehlhaff DS, Marshall JG, Baumgartner JC. Comparison of ultrasonic and high-speed-bur root-end preparations using bilaterally matched teeth. *J Endod* 1997 Jul;23(7):448-52.
- [56] Sindet-Pedersen S, Ramstrom G, Bernvil S, Blomback M. Hemostatic effect of tranexamic acid mouthwash in anticoagulant-treated patients undergoing oral surgery. *N Engl J Med* 1989 Mar 30;320(13):840-3.
- [57] Chong BS, Pitt Ford TR. Root-end filling materials: rationale and tissue response. *Endodontic Topics* 2005; 2005. p. 114-30.
- [58] Apaydin ES, Shabahang S, Torabinejad M. Hard-tissue healing after application of fresh or set MTA as root-end-filling material. *J Endod* 2004 Jan;30(1):21-4.
- [59] Aqrabawi J. Sealing ability of amalgam, super EBA cement, and MTA when used as retrograde filling materials. *Br Dent J* 2000 Mar 11;188(5):266-8.
- [60] Baek SH, Plenk H, Jr., Kim S. Periapical tissue responses and cementum regeneration with amalgam, SuperEBA, and MTA as root-end filling materials. *J Endod* 2005 Jun;31(6):444-9.
- [61] Bernabe PF, Gomes-Filho JE, Rocha WC, Nery MJ, Otoboni-Filho JA, Dezan-Junior E. Histological evaluation of MTA as a root-end filling material. *Int Endod J* 2007 Oct;40(10):758-65.
- [62] Bernabe PF, Holland R, Morandi R, de Souza V, Nery MJ, Otoboni Filho JA, et al. Comparative study of MTA and other materials in retrofilling of pulpless dogs' teeth. *Braz Dent J* 2005;16(2):149-55.
- [63] Bohsali K, Pertot WJ, Hosseini B, Camps J. Sealing ability of super EBA and Dyract as root-end fillings: a study in vitro. *Int Endod J* 1998 Sep;31(5):338-42.
- [64] Bondra DL, Hartwell GR, MacPherson MG, Portell FR. Leakage in vitro with IRM, high copper amalgam, and EBA cement as retrofilling materials. *J Endod* 1989 Apr;15(4):157-60.

- [65] Economides N, Pantelidou O, Kokkas A, Tziafas D. Short-term periradicular tissue response to mineral trioxide aggregate (MTA) as root-end filling material. *Int Endod J* 2003 Jan;36(1):44-8.
- [66] Lindeboom JA, Frenken JW, Kroon FH, van den Akker HP. A comparative prospective randomized clinical study of MTA and IRM as root-end filling materials in single-rooted teeth in endodontic surgery. *Oral Surg Oral Med Oral Pathol Oral Radiol Endod* 2005 Oct;100(4):495-500.
- [67] Mangin C, Yesilsoy C, Nissan R, Stevens R. The comparative sealing ability of hydroxyapatite cement, mineral trioxide aggregate, and super ethoxybenzoic acid as root-end filling materials. *J Endod* 2003 Apr;29(4):261-4.
- [68] Pantshev A, Carlsson AP, Andersson L. Retrograde root filling with EBA cement or amalgam. A comparative clinical study. *Oral Surg Oral Med Oral Pathol* 1994 Jul;78(1):101-4.
- [69] Pichardo MR, George SW, Bergeron BE, Jeansonne BG, Rutledge R. Apical leakage of root-end placed SuperEBA, MTA, and Geristore restorations in human teeth previously stored in 10% formalin. *J Endod* 2006 Oct;32(10):956-9.
- [70] Regan JD, Gutmann JL, Witherspoon DE. Comparison of Diaket and MTA when used as root-end filling materials to support regeneration of the periradicular tissues. *Int Endod J* 2002 Oct;35(10):840-7.
- [71] Saunders WP. A prospective clinical study of periradicular surgery using mineral trioxide aggregate as a root-end filling. *J Endod* 2008 Jun;34(6):660-5.
- [72] Schwartz-Arad D, Yarom N, Lustig JP, Kaffe I. A retrospective radiographic study of root-end surgery with amalgam and intermediate restorative material. *Oral Surg Oral Med Oral Pathol Oral Radiol Endod* 2003 Oct;96(4):472-7.
- [73] Tanomaru-Filho M, Luis MR, Leonardo MR, Tanomaru JM, Silva LA. Evaluation of periapical repair following retrograde filling with different root-end filling materials in dog teeth with periapical lesions. *Oral Surg Oral Med Oral Pathol Oral Radiol Endod* 2006 Jul;102(1):127-32.

- [74] Taschieri S, Del Fabbro M, Testori T, Francetti L, Weinstein R. Endodontic surgery with ultrasonic retrotips: one-year follow-up. *Oral Surg Oral Med Oral Pathol Oral Radiol Endod* 2005 Sep;100(3):380-7.
- [75] Tawil PZ, Trope M, Curran AE, Caplan DJ, Kirakozova A, Duggan DJ, et al. Periapical microsurgery: an in vivo evaluation of endodontic root-end filling materials. *J Endod* 2009 Mar;35(3):357-62.
- [76] Testori T, Capelli M, Milani S, Weinstein RL. Success and failure in periradicular surgery: a longitudinal retrospective analysis. *Oral Surg Oral Med Oral Pathol Oral Radiol Endod* 1999 Apr;87(4):493-8.
- [77] Torabinejad M, Hong CU, Pitt Ford TR, Kaiyawasam SP. Tissue reaction to implanted super-EBA and mineral trioxide aggregate in the mandible of guinea pigs: a preliminary report. *J Endod* 1995 Nov;21(11):569-71.
- [78] Trope M, Lost C, Schmitz HJ, Friedman S. Healing of apical periodontitis in dogs after apicoectomy and retrofilling with various filling materials. *Oral Surg Oral Med Oral Pathol Oral Radiol Endod* 1996 Feb;81(2):221-8.
- [79] Yaccino JM, Walker WA, 3rd, Carnes DL, Jr., Schindler WG. Longitudinal microleakage evaluation of Super-EBA as a root-end sealing material. *J Endod* 1999 Aug;25(8):552-4.
- [80] Rud J, Rud V, Munksgaard EC. Periapical healing of mandibular molars after root-end sealing with dentine-bonded composite. *Int Endod J* 2001 Jun;34(4):285-92.
- [81] Goldberg F, Torres MD, Bottero C, Alvarez AF. [Use of thermoplasticized gutta-percha in retrograde obturation]. *Rev Asoc Odontol Argent* 1991 Jul-Sep;79(3):142-6.
- [82] Amagasa T, Nagase M, Sato T, Shioda S. Apicoectomy with retrograde gutta-percha root filling. *Oral Surg Oral Med Oral Pathol* 1989 Sep;68(3):339-42.
- [83] Jesslen P, Zetterqvist L, Heimdahl A. Long-term results of amalgam versus glass ionomer cement as apical sealant after apicectomy. *Oral Surg Oral Med Oral Pathol Oral Radiol Endod* 1995 Jan;79(1):101-3.

- [84] MacPherson MG, Hartwell GR, Bondra DL, Weller RN. Leakage in vitro with high-temperature thermoplasticized gutta-percha, high copper amalgam, and warm gutta-percha when used as retrofilling materials. *J Endod* 1989 May;15(5):212-5.
- [85] Olson AK, MacPherson MG, Hartwell GR, Weller RN, Kulild JC. An in vitro evaluation of injectable thermoplasticized gutta-percha, glass ionomer, and amalgam when used as retrofilling materials. *J Endod* 1990 Aug;16(8):361-4.
- [86] Platt AS, Wannfors K. The effectiveness of compomer as a root-end filling: a clinical investigation. *Oral Surg Oral Med Oral Pathol Oral Radiol Endod* 2004 Apr;97(4):508-12.
- [87] Sauveur G, Sobel M, Boucher Y. Utilization of gutta-percha for retrograde root fillings. *Endod Dent Traumatol* 2000 Jun;16(3):128-31.
- [88] Woo YR, Wassell RW, Foreman PC. Evaluation of sealing properties of 70 degrees C thermoplasticized gutta-percha used as a retrograde root filling. *Int Endod J* 1990 Mar;23(2):107-12.
- [89] Wu MK, Kean SD, Kersten HW. Quantitative microleakage study on a new retrograde filling technique. *Int Endod J* 1990 Sep;23(5):245-9.
- [90] Yazdi PM, Schou S, Jensen SS, Stoltze K, Kenrad B, Sewerin I. Dentine-bonded resin composite (Retroplast) for root-end filling: a prospective clinical and radiographic study with a mean follow-up period of 8 years. *Int Endod J* 2007 Jul;40(7):493-503.
- [91] Zetterqvist L, Hall G, Holmlund A. Apicectomy: a comparative clinical study of amalgam and glass ionomer cement as apical sealants. *Oral Surg Oral Med Oral Pathol* 1991 Apr;71(4):489-91.
- [92] Gagliani M, Taschieri S, Molinari R. Ultrasonic root-end preparation: influence of cutting angle on the apical seal. *J Endod* 1998 Nov;24(11):726-30.
- [93] Valois CR, Costa ED, Jr. Influence of the thickness of mineral trioxide aggregate on sealing ability of root-end fillings in vitro. *Oral Surg Oral Med Oral Pathol Oral Radiol Endod* 2004 Jan;97(1):108-11.

- [94] DENTSPLY International Inc. Germany. IRM Caps data sheet.
- [95] Oynick J, Oynick T. A study of a new material for retrograde fillings. *J Endod* 1978 Jul;4(7):203-6.
- [96] Torabinejad M, Watson TF, Pitt Ford TR. Sealing ability of a mineral trioxide aggregate when used as a root end filling material. *J Endod* 1993 Dec;19(12):591-5.
- [97] Torabinejad M, Hong CU, McDonald F, Pitt Ford TR. Physical and chemical properties of a new root-end filling material. *J Endod* 1995 Jul;21(7):349-53.
- [98] Molven O, Halse A, Grung B. Incomplete healing (scar tissue) after periapical surgery--radiographic findings 8 to 12 years after treatment. *J Endod* 1996 May;22(5):264-8.
- [99] Donath K, Breuner G. A method for the study of undecalcified bones and teeth with attached soft tissues. The Sage-Schliff (sawing and grinding) technique. *J Oral Pathol* 1982 Aug;11(4):318-26.
- [100] Rubinstein RA, Kim S. Long-term follow-up of cases considered healed one year after apical microsurgery. *J Endod* 2002 May;28(5):378-83.
- [101] Chong BS, Ford TR, Kariyawasam SP. Tissue response to potential root-end filling materials in infected root canals. *Int Endod J* 1997 Mar;30(2):102-14.
- [102] Danin J, Linder LE, Lundqvist G, Ohlsson L, Ramskold LO, Stromberg T. Outcomes of periradicular surgery in cases with apical pathosis and untreated canals. *Oral Surg Oral Med Oral Pathol Oral Radiol Endod* 1999 Feb;87(2):227-32.
- [103] Lustmann J, Friedman S, Shaharabany V. Relation of pre- and intraoperative factors to prognosis of posterior apical surgery. *J Endod* 1991 May;17(5):239-41.
- [104] Kvist T, Reit C. Results of endodontic retreatment: a randomized clinical study comparing surgical and nonsurgical procedures. *J Endod* 1999 Dec;25(12):814-7.
- [105] Christiansen R, Kirkevang LL, Horsted-Bindslev P, Wenzel A. Randomized clinical trial of root-end resection followed by root-end filling with mineral trioxide aggregate or smoothing of the orthograde gutta-percha root filling--1-year follow-up. *Int Endod J* 2009 Feb;42(2):105-14.

- [106] Ramachandran Nair PN, Pajarola G, Schroeder HE. Types and incidence of human periapical lesions obtained with extracted teeth. *Oral Surg Oral Med Oral Pathol Oral Radiol Endod* 1996 Jan;81(1):93-102.
- [107] Carrillo C, Penarrocha M, Ortega B, Marti E, Bagan JV, Vera F. Correlation of radiographic size and the presence of radiopaque lamina with histological findings in 70 periapical lesions. *J Oral Maxillofac Surg* 2008 Aug;66(8):1600-5.
- [108] Carrillo C, Penarrocha M, Bagan JV, Vera F. Relationship between histological diagnosis and evolution of 70 periapical lesions at 12 months, treated by periapical surgery. *J Oral Maxillofac Surg* 2008 Aug;66(8):1606-9.
- [109] Wang N, Knight K, Dao T, Friedman S. Treatment outcome in endodontics-The Toronto Study. Phases I and II: apical surgery. *J Endod* 2004 Nov;30(11):751-61.
- [110] Barone C, Dao TT, Basrani BB, Wang N, Friedman S. Treatment outcome in endodontics: the Toronto study--phases 3, 4, and 5: apical surgery. *J Endod* 2010 Jan;36(1):28-35.
- [111] von Arx T, Penarrocha M, Jensen S. Prognostic factors in apical surgery with root-end filling: a meta-analysis. *J Endod* 2010 Jun;36(6):957-73.
- [112] Wuchenich G, Meadows D, Torabinejad M. A comparison between two root end preparation techniques in human cadavers. *J Endod* 1994 Jun;20(6):279-82.
- [113] Peters CI, Peters OA, Barbakow F. An in vitro study comparing root-end cavities prepared by diamond-coated and stainless steel ultrasonic retrotips. *Int Endod J* 2001 Mar;34(2):142-8.
- [114] Brent PD, Morgan LA, Marshall JG, Baumgartner JC. Evaluation of diamond-coated ultrasonic instruments for root-end preparation. *J Endod* 1999 Oct;25(10):672-5.
- [115] Layton CA, Marshall JG, Morgan LA, Baumgartner JC. Evaluation of cracks associated with ultrasonic root-end preparation. *J Endod* 1996 Apr;22(4):157-60.
- [116] Lee CQ, Chang Y, Cobb CM, Robinson S, Hellmuth EM. Dimensional stability of thermosensitive gutta-percha. *J Endod* 1997 Sep;23(9):579-82.

- [117] Grassi MD, Plazek DJ, Michanowicz AE, Chay IC. Changes in the physical properties of the Ultrafil low-temperature (70 degrees C) thermoplasticized gutta-percha system. *J Endod* 1989 Nov;15(11):517-21.
- [118] Lindqvist L, Otteskog P. Eugenol: liberation from dental materials and effect on human diploid fibroblast cells. *Scand J Dent Res* 1980 Dec;88(6):552-6.
- [119] Hensten-Pettersen A, Jacobsen N. Perceived side effects of biomaterials in prosthetic dentistry. *J Prosthet Dent* 1991 Jan;65(1):138-44.
- [120] Hume WR. In vitro studies on the local pharmacodynamics, pharmacology and toxicology of eugenol and zinc oxide-eugenol. *Int Endod J* 1988 Mar;21(2):130-4.
- [121] Markowitz K, Moynihan M, Liu M, Kim S. Biologic properties of eugenol and zinc oxide-eugenol. A clinically oriented review. *Oral Surg Oral Med Oral Pathol* 1992 Jun;73(6):729-37.
- [122] Cohen BI, Pagnillo MK, Musikant BL, Deutsch AS. Formaldehyde evaluation from endodontic materials. *Oral Health* 1998 Dec;88(12):37-9.
- [123] Schweikl H, Schmalz G, Federlin M. Mutagenicity of the root canal sealer AHPlus in the Ames test. *Clin Oral Investig* 1998 Sep;2(3):125-9.
- [124] Gazelius B, Olgart L, Wrangsjo K. Unexpected symptoms to root filling with gutta-percha. A case report. *Int Endod J* 1986 Jul;19(4):202-4.
- [125] Torabinejad M, Hong CU, Pitt Ford TR, Kettering JD. Cytotoxicity of four root end filling materials. *J Endod* 1995 Oct;21(10):489-92.
- [126] Lynch CD, Burke FM, Ni Riordain R, Hannigan A. The influence of coronal restoration type on the survival of endodontically treated teeth. *Eur J Prosthodont Restor Dent* 2004 Dec;12(4):171-6.
- [127] Willershausen B, Tekyatan H, Krummenauer F, Briseno Marroquin B. Survival rate of endodontically treated teeth in relation to conservative vs post insertion techniques -- a retrospective study. *Eur J Med Res* 2005 May 20;10(5):204-8.

- [128] Nagasiri R, Chitmongkolsuk S. Long-term survival of endodontically treated molars without crown coverage: a retrospective cohort study. *J Prosthet Dent* 2005 Feb;93(2):164-70.
- [129] Salehrabi R, Rotstein I. Endodontic treatment outcomes in a large patient population in the USA: an epidemiological study. *J Endod* 2004 Dec;30(12):846-50.
- [130] Roggendorf MJ, Ebert J, Petschelt A, Frankenberger R. Influence of moisture on the apical seal of root canal fillings with five different types of sealer. *J Endod* 2007 Jan;33(1):31-3.
- [131] Fischer EJ, Arens DE, Miller CH. Bacterial leakage of mineral trioxide aggregate as compared with zinc-free amalgam, intermediate restorative material, and Super-EBA as a root-end filling material. *J Endod* 1998 Mar;24(3):176-9.
- [132] Eldeniz AU, Hadimli HH, Ataoglu H, Orstavik D. Antibacterial effect of selected root-end filling materials. *J Endod* 2006 Apr;32(4):345-9.
- [133] Torabinejad M, Hong CU, Pitt Ford TR, Kettering JD. Antibacterial effects of some root end filling materials. *J Endod* 1995 Aug;21(8):403-6.
- [134] Torabinejad M, Rastegar AF, Kettering JD, Pitt Ford TR. Bacterial leakage of mineral trioxide aggregate as a root-end filling material. *J Endod* 1995 Mar;21(3):109-12.
- [135] Gondim E, Jr., Kim S, de Souza-Filho FJ. An investigation of microleakage from root-end fillings in ultrasonic retrograde cavities with or without finishing: a quantitative analysis. *Oral Surg Oral Med Oral Pathol Oral Radiol Endod* 2005 Jun;99(6):755-60.
- [136] Greer BD, West LA, Liewehr FR, Pashley DH. Sealing ability of Dyract, Geristore, IRM, and super-EBA as root-end filling materials. *J Endod* 2001 Jul;27(7):441-3.
- [137] Wu MK, Kontakiotis EG, Wesselink PR. Long-term seal provided by some root-end filling materials. *J Endod* 1998 Aug;24(8):557-60.
- [138] Gilles JA, Huget EF, Stone RC. Dimensional stability of temporary restoratives. *Oral Surg Oral Med Oral Pathol* 1975 Dec;40(6):796-800.

- [139] Parirokh M, Torabinejad M. Mineral trioxide aggregate: a comprehensive literature review--Part I: chemical, physical, and antibacterial properties. *J Endod* 2010 Jan;36(1):16-27.
- [140] Orstavik D, Nordahl I, Tibballs JE. Dimensional change following setting of root canal sealer materials. *Dent Mater* 2001 Nov;17(6):512-9.
- [141] Baek SH, Lee WC, Setzer FC, Kim S. Periapical bone regeneration after endodontic microsurgery with three different root-end filling materials: amalgam, SuperEBA, and mineral trioxide aggregate. *J Endod* 2010 Aug;36(8):1323-5.
- [142] Lindhe J, Ericsson I. The influence of trauma from occlusion on reduced but healthy periodontal tissues in dogs. *J Clin Periodontol* 1976 May;3(2):110-22.
- [143] Andreasen JO. Cementum repair after apicoectomy in humans. *Acta Odontol Scand* 1973 Oct;31(4):211-21.
- [144] Thomson TS, Berry JE, Somerman MJ, Kirkwood KL. Cementoblasts maintain expression of osteocalcin in the presence of mineral trioxide aggregate. *J Endod* 2003 Jun;29(6):407-12.
- [145] Torabinejad M, Pitt Ford TR, McKendry DJ, Abedi HR, Miller DA, Kariyawasam SP. Histologic assessment of mineral trioxide aggregate as a root-end filling in monkeys. *J Endod* 1997 Apr;23(4):225-8.
- [146] Hakki SS, Bozkurt SB, Hakki EE, Belli S. Effects of mineral trioxide aggregate on cell survival, gene expression associated with mineralized tissues, and biomineralization of cementoblasts. *J Endod* 2009 Apr;35(4):513-9.
- [147] Zhu Q, Haglund R, Safavi KE, Spangberg LS. Adhesion of human osteoblasts on root-end filling materials. *J Endod* 2000 Jul;26(7):404-6.
- [148] Pelliccioni GA, Ciapetti G, Cenni E, Granchi D, Nanni M, Pagani S, et al. Evaluation of osteoblast-like cell response to Proroot MTA (mineral trioxide aggregate) cement. *J Mater Sci Mater Med* 2004 Feb;15(2):167-73.

- [149] Koh ET, Torabinejad M, Pitt Ford TR, Brady K, McDonald F. Mineral trioxide aggregate stimulates a biological response in human osteoblasts. *J Biomed Mater Res* 1997 Dec 5;37(3):432-9.
- [150] Sarkar NK, Caicedo R, Ritwik P, Moiseyeva R, Kawashima I. Physicochemical basis of the biologic properties of mineral trioxide aggregate. *J Endod* 2005 Feb;31(2):97-100.
- [151] Reyes-Carmona JF, Felipe MS, Felipe WT. The biomineralization ability of mineral trioxide aggregate and Portland cement on dentin enhances the push-out strength. *J Endod* 2010 Feb;36(2):286-91.
- [152] Lin CP, Chen YJ, Lee YL, Wang JS, Chang MC, Lan WH, et al. Effects of root-end filling materials and eugenol on mitochondrial dehydrogenase activity and cytotoxicity to human periodontal ligament fibroblasts. *J Biomed Mater Res B Appl Biomater* 2004 Nov 15;71(2):429-40.
- [153] Bonson S, Jeansonne BG, Lallier TE. Root-end filling materials alter fibroblast differentiation. *J Dent Res* 2004 May;83(5):408-13.
- [154] Keiser K, Johnson CC, Tipton DA. Cytotoxicity of mineral trioxide aggregate using human periodontal ligament fibroblasts. *J Endod* 2000 May;26(5):288-91.
- [155] Tang Y, Li X, Yin S. Outcomes of MTA as root-end filling in endodontic surgery: a systematic review. *Quintessence Int* 2010 Jul-Aug;41(7):557-66.