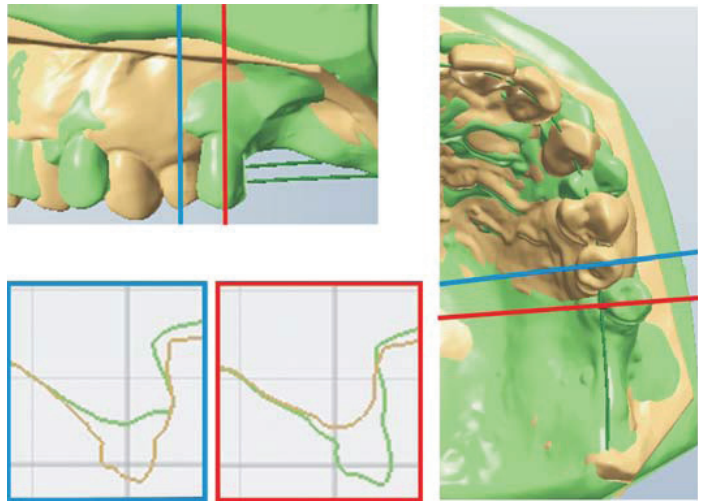


On tooth movements and associated tissue alterations related to edentulous areas and bone defects



Birgitta Lindskog Stokland

Institute of Odontology
at Sahlgrenska Academy
University of Gothenburg

On tooth movements and associated
tissue alterations related to
edentulous areas and bone defects

Birgitta Lindskog Stokland

Departments of Orthodontics and Periodontology

Institute of Odontology

Sahlgrenska Academy



UNIVERSITY OF GOTHENBURG

2011

The cover page illustration: 3D image of superimposed, scanned dental casts (3Shape, Copenhagen, Denmark).

© Birgitta Lindskog Stokland

All rights reserved. No part of this publication may be reproduced or transmitted, in any form or by any means, without written permission.

The linguistic revision of this thesis was made by Janet Vesterlund

Permission for reprinting the papers published was given by the publishers

Printed at Intellecta Infolog AB, Göteborg, Sweden 2011

Swedish Dental Journal Supplement 214, 2011

ISBN 978-91-628-8294-5,

http://hdl.handle.net/2077/25486

To Frida, Emma and Kristin

Äntligen.....

Contents

| | |
|----------------------------------------------------|-----|
| Abstract | 7 |
| Preface | 9 |
| List of abbreviations: | 11 |
| Introduction | 13 |
| Orthodontic and periodontal aspects | 14 |
| Orthodontic movement and infrabony pockets | 18 |
| Orthodontic tooth movement and edentulous areas | 24 |
| Physiological tooth movement into edentulous areas | 27 |
| Conclusions of the literature review | 38 |
| Aims | 39 |
| Material and methods | 41 |
| Animal studies (Studies I and II) | 41 |
| Human studies (Studies III and IV) | 43 |
| Statistical methods | 46 |
| Results | 49 |
| Study I | 49 |
| Study II | 50 |
| Study III | 50 |
| Study IV | 53 |
| Main findings | 57 |
| Discussion | 59 |
| Methodological considerations | 59 |
| Orthodontic tooth movement and infrabony pockets | 60 |
| Orthodontic tooth movement and edentulous areas | 61 |
| Physiological tooth movement into edentulous areas | 64 |
| Conclusion and future considerations | 67 |
| References | 69 |
| Acknowledgements | 83 |
| Appendix | 85 |
| Study I | 87 |
| Study II | 97 |
| Study III | 107 |
| Study IV | 119 |

Abstract

On tooth movements and associated tissue alterations related to edentulous areas and bone defects

Birgitta Lindskog Stokland

Department of Orthodontics and Periodontology, Institute of Odontology, the Sahlgrenska Academy at University of Gothenburg, Box 450, SE 405 30 Göteborg, Sweden

The aim of the thesis was to study orthodontic tooth movement in relation to edentulous areas and infrabony pockets as well as the physiological movement of teeth facing an edentulous area.

A dog model was used in Studies I and II. Teeth were orthodontically moved into and out from inflamed, infrabony periodontal pockets (*Study I*) and into areas of reduced bone height (*Study II*). Clinical, radiographic and histometric analyses were made with respect to changes in tooth-supporting tissues. *Study III* involved clinical, radiographic and 3D model assessments of changes in periodontal conditions and alveolar ridge dimensions in adult patients subjected to tooth movement into areas with reduced ridge dimensions. In *Study IV*, panoramic radiographs of 292 subjects, taken at an interval of 12 years, were analyzed with regard to changes in the elongation of unopposed molars and tipping of molars facing a mesial edentulous space.

In the animal study orthodontic bodily movement of teeth with inflamed, infrabony pockets caused an enhanced rate of progression of the periodontal lesion (*Study I*), particularly when the tooth movement was directed towards the infrabony defect. Teeth with healthy periodontium that were orthodontically moved into areas of markedly reduced bone height maintained their periodontal tissue support (*Study II*). Corresponding orthodontic tooth movement in humans (*Study III*) resulted in minor dimensional alterations of the periodontal tissues and an increased bucco-lingual width of the alveolar ridge in the area into which the tooth had been moved, whereas a decreased width of the newly established edentulous area was noted. All teeth that were moved showed lateral root resorption at the level of the bone crest on the pressure side, but signs of repair were noticed 1-year post-treatment. In the 12-year radiographic study (*Study IV*) unopposed molars showed a significant increase in elongation over the 12 years of follow-up. The degree of elongation increased with decreased bone support. Neither edentulous space nor alveolar bone level were found to have a significant effect on tipping. In the presence of both conditions, unopposed molars and molars facing a mesial edentulous space, an increase in elongation was associated with tipping.

Keywords: Orthodontics, periodontics, interdisciplinary treatment, infrabony pockets, edentulous areas, dimensional changes, elongation, continuous eruption, overeruption, tipping.

Swedish Dental Journal Supplement 214, 2011

ISBN 978-91-628-8294-5,

<http://hdl.handle.net/2077/25486>

Preface

The thesis is based on the following papers, which will be referred to in the text by their Roman numerals (I-IV):

- I. Wennström JL, Lindskog Stokland B, Nyman S, Thilander B (1993) Periodontal tissue response to orthodontic movement of teeth with infrabony pockets. *American Journal of Orthodontics and Dentofacial Orthopedics* 103; 4: 313-319
- II. Lindskog-Stokland B, Wennström JL, Nyman S, Thilander B (1993) Orthodontic tooth movement into edentulous areas with reduced bone height. An experimental study in the dog. *European Journal of Orthodontics* 15: 89-96
- III. Lindskog-Stokland B, Hansen K, Ekestubbe A, Wennström JL (2011) Orthodontic tooth movement into edentulous ridge areas – a case series. *European Journal of Orthodontics* (In press)
- IV. Lindskog-Stokland B, Hansen K, Tomasi C, Hakeberg M, Wennström JL (2011). Changes in molar position associated with missing opposed and/or adjacent tooth: A 12-year study in women. *Journal of Oral Rehabilitation*. (In press)

List of abbreviations:

| | |
|-----------|-----------------------------------------------|
| aJE | apical level of junctional epithelium |
| AL | coronal level of connective tissue attachment |
| BC | alveolar bone crest |
| BES | bounded edentulous space |
| BDX | bovine-derived bone xenograft |
| CAL | clinical attachment level |
| CEJ | cemento-enamel junction |
| DBT | distance between the teeth |
| DFDBA | demineralized freeze-dried bone allograft |
| EMD | enamel matrix derivate |
| GM | gingival margin |
| GTR | guided tissue regeneration |
| JE | junctional epithelium |
| N | notch |
| n | number |
| ns | not significant |
| p | level of significance |
| PD | probing depth |
| PDL | periodontal ligament |
| PPD | probing pocket depth |
| RCP | retruded contact position |
| RCT | randomised clinical trial |
| REC | gingival recession |
| SD | standard deviation |
| TMD | temporo mandibular disorder |
| \bar{x} | mean |

Introduction

Orthodontics is often considered to be restricted to children and adolescents, but an increasing number of adults desire orthodontic treatment to correct problems that were not treated in the past, to improve function and esthetics. The orthodontic treatment period may however, be longer in adults compared to young individuals due to a delayed initial tissue response (Melsen 1991; Ren et al. 2003; Ren et al. 2008). Furthermore, the adult patient may often show periodontal tissue breakdown, including bony defects, as well as loss of teeth and reduced alveolar ridges. Although there is a trend toward a decrease in periodontal disease in the Swedish population, the number of individuals with advanced periodontitis including angular defects remains unchanged (Hugoson et al. 2008).

The number of patients with partial edentulousness and edentulous spaces has increased, above all in older age groups (Ahlqwist et al. 1999; Hugoson et al. 2005; Hugoson et al. 2008) and, with that, new problems arise, especially when the desire for esthetics and function increases. The possibilities for treatment vary and depend on both general and oral health as well as socioeconomic conditions. The treatment modalities vary and may consist of restorative, prosthodontic, implant and orthodontic treatment procedures as well as a combination of these.

Functional aspects of partial edentulousness are contradictory. Several reviews have shown that evidence is lacking for that occlusal issues being causative factors to temporo-mandibular disorders, TMD (Gesch et al. 2004; Rinchuse and Kandasamy 2005; Mohlin et al. 2007). A more recent study has however shown that the number of missing posterior teeth and the number of quadrants with missing posterior teeth had a statistically significant relationship with TMD (Wang et al. 2009).

Orthodontic tooth movement results from connective tissue remodeling,

brought about by cells from the alveolar bone and from the neighboring periodontal ligament (Thilander et al. 2000). Teeth not exposed to orthodontic forces also sometimes have a capacity for physiological tooth movement or tooth migration (Moss and Picton 1972; Kaplan 1985; Witter et al. 1987). The erupting tooth will erupt until it reaches occlusal contact and the final positioning of the teeth depends on the equilibrium between forces e.g. forces from the occlusion, tongue, lips and eruption (Weinstein 1967; Proffit 1978). Changes in the head, jaw and tongue posture may also influence the equilibrium and cause tooth migration. Furthermore, the teeth in the maxilla will gradually move in a mesial direction until they are in contact with each other. In the mandible the mesial migration is not so obvious, although variations exist. Loss of teeth and loss of periodontal tissue support, due to plaque-induced inflammation, periodontitis, may also cause tooth migration (Martinez-Canut et al. 1997).

The majority of clinical studies evaluating the effects of orthodontic treatment on the supporting tissues have been carried out in children or adolescents, with no bony defects and rarely any signs of destructive periodontal disease. A recent systematic review suggests that orthodontic therapy results in small detrimental injuries on the periodontium, but the number of studies that focus on the adult population is small (Bollen et al. 2008).

This thesis thus focuses on tooth movements and associated tissue alterations related to edentulous areas and bone defects in adults.

Orthodontic and periodontal aspects

Tippling and bodily tooth movement occurs in most orthodontic treatments. Other orthodontic tooth movements are intrusion, extrusion, torque and rotation. Tippling of a tooth is the result of a one-point contact force application, which causes a concentration of *pressure* in limited areas of the periodontal ligament. As a consequence of the *pressure*, a hyalinization process will start. Since a fulcrum is created, the apical portion of the root will move in the opposite direction, and hyalinization will be observed in this area as well

(Thilander et al. 2000). Areas of *tension* are formed on the opposite side of the root, with deposition of new bone, osteoid, on the alveolar surface. Bodily or parallel tooth movement, on the other hand, is the result of the application of a pair of forces along parallel lines. This kind of tooth movement is most frequent in the mesio-distal direction. However, in the clinical situation where bodily movement frequently is the aim, small elements of tipping, rotation, torque, intrusion and extrusion can also be found. The same surface of a root may not only be a *pressure* or *tension* side but rather has different zones with strains of both. The strain-stress response of the periodontium to orthodontic loading has been studied in the three-dimensional finite element method (Cattaneo et al. 2005; Cattaneo et al. 2008; Cattaneo et al. 2009; Field et al. 2009).

Experimental studies reveal that hyalinization on the *pressure* side prevents tooth movement, occurs at any time during the experimental period and seems not to have a clear relationship with the orthodontic forces (Von Böhl et al. 2004; von Böhl and Kuijpers-Jagtman 2009). Experimental studies have also shown that the necrotic cell-free zones of hyalinization must be resorbed by osteoclasts before the proliferation of osteoblasts and fibroblasts can take place (Kvam 1972). The elimination of the hyalinized periodontal tissue and later the alveolar bone is a complex mechanism, however, which is mediated by cellular activity and molecular regulation (Meikle 2006). Root resorption, which is an adverse effect in orthodontics (SBU 2005, Weltman et al. 2010) is also a result of the cellular activity associated with the removal of necrotic hyalinized tissue and alveolar bone (Kvam 1972; Rygh 1973, 1977; Brudvik and Rygh 1994; Brudvik and Rygh 1994).

Both experimental and human studies have shown that, 30 to 40 hours after force application, cell proliferation takes place in the marginal area of the periodontal ligament on the *tension* side (Thilander et al. 2000). Soon after the initiation of cell proliferation an unmineralized tissue, osteoid, will be formed. In addition, Rygh et al (Rygh et al. 1986) showed that an increase in vascular activity was concomitant with the remodeling of the fibrous system, and recent experimental research points out a complex system with several chemical mediators being involved in the remodeling process (Meikle 2006).

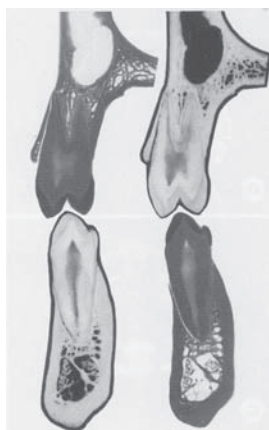

Figure 1. Bucco-lingual tooth /bone relationship for the upper and lower first premolar (Schroeder, Handbook of microscopic anatomy: The Periodontium. 1986)

The tissue response differs according to the *direction* of the tooth movement. The bone is more spongy in the sagittal direction, and the orthodontic tooth movement does not as easily result in adverse effects. On the buccal and lingual side of the root, the bone is more lamellar in nature and usually thin particularly on the buccal side and especially in adults, quite dense (Figure 1). If the root of the tooth is forced against this thin, dense bone, adverse effects such as root resorption, fenestrations or dehiscences of the

buccal alveolar plate (Batenhorst et al. 1974; Thilander et al. 1983; Odenrick et al. 1991; Vardimon et al. 1991; Thilander 1992; Owman-Moll et al. 1996) may occur. If the root is moved back to its original position, however, the buccal bone will reform (Karring et al. 1982; Nyman et al. 1982; Thilander et al. 1983), but if the root is left outside the boundaries of the jaw, no remineralization of bone will occur (Steiner et al. 1981; Engelking and Zachrisson 1982; Karring et al. 1982; Thilander et al. 1983; Wennström et al. 1987; Bondemark 1998).

The effects of orthodontic treatment on the periodontal tissues have been evaluated in a number of clinical and experimental studies; for reviews see Bollen et al. 2008 and Gkantidis et al. 2010. The results of clinical studies have revealed that, provided proper oral hygiene standards are maintained during the phase of orthodontic therapy, no or only clinically insignificant injuries to the supporting tissues will occur (Zachrisson and Alnaes 1973; Alstad and Zachrisson 1979; Lundström et al. 1980; Eliasson et al. 1982; Hamp et al. 1982; Polson and Reed 1984; Boyd et al. 1989; Owin and Diedrich 1990; Topoll et al. 1990). However, other clinical studies have shown a risk of losing attachment even if the tooth movement is performed in plaque-infected dentitions (Zachrisson 1976; Zachrisson and Brobakken 1978;

Artun and Urbye 1988). Still, whether the probing attachment loss reported in these studies in young individuals represents a true loss of connective tissue attachment can be questioned as it is well known that factors such as the presence of inflammatory lesions in the gingiva and increased tooth mobility results in reduced resistance to probing (Listgarten 1980; Fowler et al. 1982; Ericsson and Lindhe 1993). The recorded loss may hence be due to deeper probe tip penetration into the supracrestal connective tissue rather than a true loss of fiber attachment. It has been demonstrated experimentally that orthodontic movements per se do not result in gingival inflammation, neither in regions with normal nor in regions with reduced periodontal support (Ericsson et al. 1978; Ericsson and Thilander 1980). Experimental studies involving histological analysis also show that orthodontic forces do not convert gingivitis into a destructive periodontitis (Lindhe and Svanberg 1974; Ericsson et al. 1978). This may be explained by the fact that the plaque-induced inflammatory lesion in individuals with gingivitis is limited to the supraalveolar connective tissue, while the tissue reactions of the orthodontic tooth movements occur in the intraalveolar area.

Infrabony pockets may form as a result of a destructive periodontal disease (Bartold and Narayanan 2006) including apical migration of junctional epithelium and formation of pocket epithelium. An infrabony pocket is an angular defect with inflamed connective tissue and dento-gingival epithelium situated apical to the crest of the alveolar bone (Waerhaug 1979). Experimental studies in dogs have shown an aggravating effect on the progression of periodontal destruction when trauma, caused by jiggling forces, was superimposed on infrabony pockets (Lindhe and Svanberg 1974; Ericsson and Lindhe 1982). However, a similar experiment carried out in monkeys did not reveal additional loss of connective tissue attachment (Polson and Zander 1983). It is likely that the disparity of these results was due to differences in the duration of the jiggling trauma. In the experimental studies performed in the dog, the jiggling forces were maintained for an extended period, while the jiggling trauma in the monkey was of a comparatively short duration.

Orthodontic movement and infrabony pockets

Infrabony pockets may be created by orthodontic tipping or intrusion of teeth harboring plaque (Ericsson et al. 1977). Table 1 gives a summary of studies on orthodontic tooth movement and infrabony pockets. There are few human studies concerning infrabony pockets and orthodontic treatment, and most are limited to case reports or case series without control groups (Brown 1973; Ingber 1974; Wagenberg et al. 1980; Miyajima 1985; Nevins and Wise 1990; Corrente et al. 2003; Re et al. 2004; Ghezzi et al. 2008; Iino et al. 2008; Modoni et al. 2009; Rotundo et al. 2011). Human studies concerning tooth movements towards infrabony defects combined with intrusion and surgical therapy showed a clinical attachment gain (Modoni et al. 2009) and radiographic bone fill (Corrente et al. 2003; Re et al. 2004; Gkantidis et al. 2010). Clinical reports and an animal study have also shown that orthodontic extrusion can be used to eliminate angular periodontal defects (Ingber 1974; Ingber 1976; Wagenberg et al. 1980; van Venrooy and Yukna 1985; Iino et al. 2008; Ogihara and Wang 2010; Rotundo et al. 2011).

In the majority of the animal studies of orthodontic tooth movement into infrabony defects, in the absence of inflammation and with adequate hygiene measures, the histological analysis revealed no attachment gain but a long epithelial junction as well as elimination of the endosseous defect, (Polson et al. 1984; Cirelli et al. 2003; Nemcovsky et al. 2004; Nemcovsky et al. 2007). On the other hand, Geraci et al. (1990) reported that new connective tissue attachment was formed in two monkeys after orthodontic tooth movement into infrabony pockets. The different results may be explained by the different ways the infrabony defects were created. It could be expected that newly and artificially created two or three-wall pockets have a greater potential for regeneration, depending on greater opportunities for in-growth of connective tissue from the lateral walls.

Studies of infrabony defects in combination with regenerative periodontal therapy (membrane procedure and/or application of enamel matrix proteins) and orthodontic movement showed no or minor additional beneficial effects of the bony defect by the orthodontic treatment (Diedrich et al. 2003; Cardaropoli et al. 2006; Ogihara and Marks 2006; Ghezzi et al. 2008; Ogihara and Wang 2010).

Table 1. Orthodontic movement and infrabony pockets (Type of clinical studies categorized according to Grimes and Schulz, 2002)

| Authors | Type of study | Subjects | Aim | Methods | Findings | Authors conclusions | Comments |
|-----------------------|-------------------------|-----------------------------------------------------------------------------------------------------|--------------------------------------------------------------------------------------------------------------------------------------------------------------------------------------------------------|----------------------------------------------------------------------------------------------------------------------------------------------------------------------------------------------------------------------------------------------------|---------------------------------------------------------------------------------------------------------------------------------------------------------------------------------------------------------------------------------------------------------------------------------------|--------------------------------------------------------------------------------------------------------------------------------------------------------------------------------------------------------|-----------------------------------------------------------------------------------------------------------------------------------------------------------------------------------------|
| Gkantidis et al. 2010 | Systematic review | | To highlight the relationship between orthodontics and periodontics in clinical practice. | Human studies: 2076 articles screened 88 included Animal studies: 552 articles screened 17 included | Evidence from human studies: orthodontic tooth movement towards the infrabony defect combined with intrusion and surgical periodontal therapy results in significant clinical attachment gain and radiographic bone fill. Certain animal studies agree with the evidence from humans. | Orthodontic treatment along with patient's compliance and absence of periodontal inflammation can provide satisfactory results without causing irreversible damage to periodontal tissues. | Many studies excluded regarding the treatment of infrabony-pockets as case reports and studies with less than 4 cases not included, Not a critical systematic review. |
| Rotundo et al. 2011 | Systematic review | | To investigate the efficacy of the orthodontic treatment for the correction of periodontal effects. | 197 articles screened 29 articles included | 22 studies dealing with infrabony pockets 7 on animal and 15 on humans. The majority of the included studies are referred to in this table. Treatment with extrusion and bodily movement showed clinically and radiographically positive results. | No meta analysis due to lacking of Systematic Reviews and Randomized Clinical Trial (RCT). | The majority of the included studies are referred to in this table. The authors reported that no studies were found about intrusion and infrabony pockets. This is however not correct. |
| Brown 1973 | Descriptive Case series | 5 subjects 4 experimental 1 control | To study uprighting of molars on existing periodontal defects. | Thorough scaling and root planning once before orthodontic treatment with fixed appliance. Clinical, radiographic and cast measurements. | Reduction of the defect (clinical measurement): \bar{x} =3.5mm Reduction in bone height: \bar{x} =1mm | An appropriate therapeutic regimen, to be routinely included, where indicated in the sequence of therapy of periodontal disease | Few patients and only one control. Not described if 1-, 2- or 3-wall pockets. <i>Uprighting/extrusion</i> |
| Corrente et al. 2003 | Descriptive Case series | 10 adult subjects Extruded upper central incisor with an infrabony defect (PPD) > or = 6 mm. | To evaluate the periodontal tissue alterations following periodontal surgery and orthodontic intrusion. | At baseline and at the end of treatment, clinical measurement of PPD and CAL as well as radiographic assessment of vertical and horizontal dimensions of the defects on standardized radiographs. Intrusion into the defects after surgery, | At the end of treatment, reduction PPD \bar{x} = 4.35 mm, CAL gain \bar{x} = 5.50 mm. Radiological vertical and horizontal bone fills \bar{x} = 1.35 mm respectively \bar{x} = 1.40 mm. All differences were statistically significant. | The combined orthodontic and periodontal therapy resulted in significant probing depth reduction, clinical attachment gain, and radiological bone fill. | 1-, 2- and 3-wall pockets. Bad quality of radiographs, no histology. No control group. <i>Intrusion</i> |
| Re et al. 2004 | Descriptive Case series | 28 subjects Age 29–60, Extruded upper central incisor with an infrabony defect | To evaluate the combined effect of periodontal surgery with orthodontic intrusion to reduce the REC around the maxillary incisors and to see the differences between thick and thin gingival biotypes. | Periodontal flap surgery: Fixed appliances after surgery, migrated incisors intruded and realigned. At baseline, end of treatment and 1 year post-treatment PPD and REC were assessed on the mesial and buccal aspects Hygiene maintenance program | Baseline PPD \bar{x} = 7 mm, End of treatment \bar{x} = 2.5 mm Statistically significant. Stable at the follow-up evaluation. | Results presented in this clinical paper show a positive outcome of all parameter examined and both PPD and REC remained stable at the 1 year follow-up in patients with thin as well as wide gingiva. | No radiographic assessments that show the infrabony pockets.No control group. <i>Intrusion</i> |

| Authors | Type of study | Subjects | Aim | Methods | Findings | Authors conclusions | Comments |
|-------------------------|-------------------------|-----------------------------------------------------------------------------------------------------|---------------------------------------------------------------------------------------------------------------------------|-------------------------------------------------------------------------------------------------------------------------------------------------------------------------------------------------------------------------------------------------------|---------------------------------------------------------------------------------------------------------------------------------------------------------------------------------------------------------|---------------------------------------------------------------------------------------------------------------------------------------------------------------------------------------|-----------------------------------------------------------------------------------------------------------------------|
| Cardaropoli et al. 2006 | Descriptive Case series | 3 adult subjects migrated maxillary incisor with an infrabony pocket | To evaluate if it is possible to orthodontically move migrated teeth into infrabony defects augmented with a biomaterial. | Full thickness flap surgery, defect filled with collagen bovine mineral (Bio-Oss Collagen, Geistlich). After 2 weeks Orthodontic bodily movement with light continuous forces, two patients also intrusion, strict oral hygiene during the treatment. | All patients showed a decrease in PPD \bar{x} = 3.67 and CAL gain \bar{x} = 4.67. Radiographs showed a vertical reduction of 3.17 and a horizontal 2.0 or a resolution of more than 70%. | Within the small number of cases the described approach resulted in effective outcome as reduction in clinical probing depth, gain of clinical attachment and radiographic bone fill. | Few cases, no control sites <i>Bodily movement and Intrusion</i> |
| Ingber 1974 | Case report | 50 year old female mandibular second premolar with isolated one wall osseous defect | To alter one and 2-wall infrabony defects with forced eruption. | Periodontal therapy: plaquecontrol, root planning, curettage. Reduction of occlusal surface by 2-3mm before orthodontic extrusion and after 15 days further 2-3mm reduction, A notch indicator for movement. After extrusion a crown. | Total extrusion 4-6mm. Reduction of PPD \bar{x} =5mm (Range 8 - 3mm). | In selected cases forced eruption may be useful in treating isolated 1 or 2 wall infrabony pockets. | Case-report <i>Extrusion</i> |
| Wagenberg et al. 1980 | Case reports | 5 case-reports | Forced eruption and uprighting of mesially tipped teeth were discussed. | Case 1 to 3: Uprighting of mesially tipped molars, Case 4 and 5: Forced eruption of a premolar. | Improvement of the crown-to-root ratio, which results in forces of occlusion in the long axis of the tooth and reduction or elimination of infrabony defects. | Basic biologic concept that is applied in these techniques was that the attachment will follow movement of tooth if periodontal healthy. | Few cases, no control group. Different projection in radiographs. Only evaluation in radiographs. <i>Extrusion</i> |
| Miyajima 1985 | Case report | 42 year old female Upper first molar with mesial infrabony pocket and furcation involvement. | To study root realignment in furcation involved teeth with an in infrabony pocket. | Plaque control and scaling before periodontal surgery with hemisection of the roots. The mesial root was bodily moved into the infrabony pocket. | Buccal roots were moved mesially. X-rays showed that the bony defect disappeared. It took 6 months after surgery for the periodontal tissue to heal. | Root realignment of furcation-involved teeth can result in that bony defects disappear. | Still a bony defect at x-ray, case-report. The author too positive. <i>Extrusion and bodily movement</i> |
| Nevins and Wise 1990 | Case report | 2 adults with vertical defects. | To study the use of orthodontic therapy to alter infrabony pockets. | Case1: diastema med treated with Hawley bite plane Case2: treated with fixed appliance | Case I: A decrease in volume of the infrabony lesion Case 2: Complete elimination of an osseous defect by orthodontics. | Although there are a limited number of clinical opportunities it should be a part of the Periodontist armamentarium. | Case- report. Tipping and 1-wall pocket case I, bodily and 3- wall pocket case II <i>Tipping/bodily movement</i> |
| Iino et al. 2008 | Case report | 50 year old woman with 1- and 2 wall infrabony defects at 2 incisors and 1 canine. | To study isolated vertical infrabony defects treated by extrusion. | Periodontal treatment, of the infrabony defects then extirpation of pulps, and temporary crowns. Extrusion by a preadjusted edgewise appliance. Assessments. Bone level, PPD, tooth mobility and crown-root ratio: | The patient's anterior crossbite, traumatic occlusion and gingival esthetics were improved. Panoramic and dental radiographs after treatment also showed improvement of the vertical infrabony defects. | Tooth extrusion and periodontal treatment can be effective for improving alveolar bone defects, in patients with 1- or 2-wall isolated vertical infrabony defects. | Case report <i>Extrusion</i> |

| Authors | Type of study | Subjects | Aim | Methods | Findings | Authors conclusions | Comments |
|----------------------------|---------------|----------------------------------------------------------------------------------------------------------------------------------------------------------|----------------------------------------------------------------------------------------------------------------------------------------------------------------------------------------|--------------------------------------------------------------------------------------------------------------------------------------------------------------------------------------------------------------------|-------------------------------------------------------------------------------------------------------------------------------------------------------------------------------------------------------------------|---------------------------------------------------------------------------------------------------------------------------------------------------------------------------------------------------------------|----------------------------------------------------------------------------------------------------------------------------------------------------------------------------------------------------------------------------------|
| Modoni et al. 2009 | Case report | 47 year old female | To study isolated vertical defect treated by intrusion | Non surgical periodontal treatment followed by lingual orthodontic fixed appliance. | After 13 months of treatment the periodontal and orthodontic treatment goals had been achieved. The treatment resulted in 6mm reduction of PPD and 1 year after treatment the PPD was less than 3mm on all sides. | The periodontal results achieved with orthodontic treatment- including improvements in clinical attachment level, probing depth and gingival recession were similar those produced by GTR. | Only one case. The conclusion uncertain. <i>Intrusion</i> |
| Polson et al. 1984 | Animal study | 4 adult rhesus monkeys. 4 test teeth and 4 control teeth. 2 upper incisors and 2 lower incisors in each group. | To study the effect of orthodontic tooth movement on osseous morphology and connective tissue attachment levels of infrabony defects. | Intrabony pockets were produced mesial and distal to test and control teeth. Experimental teeth moved into, and through, the original area of the intrabony pocket, control teeth not moved. | No angular defect after orthodontic movement on the pressure and tension side. No effect on connective tissue attachment. | Orthodontic tooth movement into intrabony periodontal defects was without effect upon the levels of connective tissue attachment. | Plaque control after intrabony pockets was created. 1-wall intrabony pocket? <i>Bodily movement</i> |
| van Venrooy and Yukna 1985 | Animal study | 3 adult female dogs Test and control teeth in the same dog | To evaluate and quantify the special effects of controlled extrusion on root with reduced periodontal support and periodontal inflammation. | Endodontic treatment before periodontal lesions was created. Clinical, radiographic and histological evaluation. Extrusion 14-21 days 3-4mm. | A collar of bone superior to the half distance of the extrusion, and also new bone apical. Significant differences between experimental and control sites. | Favorable clinical, radiographic, and histological changes in supporting tissues resulting from orthodontic extrusion in the presence of extensive periodontal support loss and advanced periodontal disease. | No plaque control measures during the study. Infrabony pocket around the roots <i>Extrusion</i> |
| Geraci et al. 1990 | Animal study | 2 adult rhesus monkeys. 4 two-wall defects, 4 three-wall defects and 4 control in the mandible | To study if it is possible to gain new connective tissue attachment to a root that previously bordered an inflammatory lesion that was orthodontically moved into an infrabony pocket. | 2- and 3- wall infrabony pockets were created. Maxillary molars test and mandibular molars control (without bands). The orthodontic appliance: band on the cuspid and the molar. Closing loop for bodily movement. | There was a renewed gingival connective tissue attachment The 4 control teeth had chronic infrabony defects. | New connective tissue attachment to a root surface that previously bordered an inflammatory lesion. | No mechanical barrier. More tipping than bodily movement? 3- wall pockets have a greater potential for regeneration. Few animals and teeth. No cleaning procedures. No retention period. <i>Tipping or bodily movement</i> |
| Cirelli et al. 2003 | Animal study | 4 adult mongrel dogs. Second premolar in all quadrants, randomly assigned to test and control, 8 test 8 control (4 in the upper and 4 in the lower jaw) | To histological evaluate the periodontal healing of 1-walled intraosseous defects in teeth that were subjected to movement toward the defects. | Test group a controlled tipping root movement, control group received a passive stainless steel wire Lasted 2 months. Daily plaque control. | No difference between the groups. Histometric analysis showed a significant difference in bone height; on average, it was 0.53 mm smaller in the test group. | Orthodontic movement does not interfere with the healing of 1-walled intraosseous defects, with the exception of the linear extent of new bone apposition. | 1-walled intraosseous defect well defined. Randomly assigned test and control. Tipping. No infection, daily plaque control. No plaque sampling before. <i>Tipping</i> |

| Authors | Type of study | Subjects | Aim | Methods | Findings | Authors conclusions | Comments |
|--------------------------------------------------------------------|---------------------------|--------------------------------------------------------------------------------------------------------------------------------------------------------------------|--------------------------------------------------------------------------------------------------------------------------------------------------------|------------------------------------------------------------------------------------------------------------------------------------------------------------------------------------------------------------------------------------------------------------------------------------------------------------------------------------------------------------|---------------------------------------------------------------------------------------------------------------------------------------------------------------------------------------------------------------------------------------------------------------------------------------------------------------------------------------------------------------------------------|----------------------------------------------------------------------------------------------------------------------------------------------------------------------------------------------------------------------------------------------|------------------------------------------------------------------------------------------------------------------------------------------------------------------------------------------------------------------------------------|
| Nemcovsky et al. 2004 | Animal study | 33 adult rats, group 1 (n = 14) with bony defect 2 mm mesial and no root damage group 2 (n = 19) bony defect including root/PDL damage | To evaluate bone healing in surgical defects following orthodontic tooth movement with and without periodontal ligament (PDL) and root surface damage. | One week after the surgical defect was created, orthodontic protraction of the right maxillary first molar was initiated in both groups. | Differences between groups in total area of bone defect and bone apposition were not statistically significant. Bone apposition was significantly greater in group 2 than in group 1. | Following orthodontic movement, periodontal bony defects showed enhanced bony healing compared with alveolar bone defects. | The appliance consisted of 2 elastomeric rings between the first molar and the incisor. No plaque sampling before and during treatment. Group 2) comparable with intrabony defects and group 1 edentulous area. <i>Tippling</i> |
| Nemcovsky et al. 2007 | Animal study | 31 adult rats, group 1) a bony defect mesial to both maxillary first molars, not including the attachment apparatus, group 2) defect included periodontal ligament | To determine whether orthodontic tooth movement influences periodontal healing. | The measurements : 1 Length of the junctional epithelium (JE) 2 Pocket depth 3 Thickness of the supracrestal connective tissue 4 Root length 5 Root resorption | Orthodontic tooth movement shortly after periodontal surgery produced no side-effects on periodontal soft tissue healing. Five animals, out of the 31 root resorption was found only at the orthodontic side. | Orthodontic treatment could not completely avoid formation of a long epithelial attachment. Therefore, periodontal regenerative surgery might be indicated prior to orthodontic tooth movement. | Same rats and design as the study 2004? Conclusion not comparable with the clinical situation. No infection and no plaque sampling before and during treatment, no periodontitis. <i>Tippling</i> |
| Infrabony pockets treated with GTR/ enamel matrix and orthodontics | | | | | | | |
| Ogihara and Wang 2010 | Randomized Clinical Trial | 47 subjects radiographic vertical defect ≥6mm at one or two sites | To compare the clinical efficacy of EMD/DFDBA with or without limited orthodontics in the treatment of 2- or 3-wall infrabony lesions. | Intervention groups: ortho/EMD/DFDBA (n = 24) and EMD/DFDBA (n = 23). <i>Primary outcome:</i> absolute change in probing depth and clinical attachment level from baseline to 1-year follow-up. <i>Secondary outcome:</i> absolute change in open probing attachment level gain and percentage defect resolution from baseline to 6-month reentry surgery. | Both treatment groups showed a significant improvement from baseline no significant difference between the groups except for the 2-wall defects. The ortho/EMD/DFDBA group statistically significant open probing attachment level gain (95% confidence level, 3.18 to 4.36; P = 0.036) compared to the EMD/DFDBA group (95% confidence level, 2.26 to 3.24) in 2-wall defects. | Although both treatment modalities were effective in managing 2-or 3-wall infrabony defects, limited orthodontics provided an additional benefit to EMD/DFDBA in 2-wall defects. | Randomized clinical trial, power analysis before, good design of the study. Short follow-up period, no untreated ctr, no radiographic analysis. <i>Enamel matrix Extrusion</i> |
| Ghezzi et al. 2008 | Descriptive Case series | 14 subjects Intrabony defects and pathologic tooth migration treated with guided tissue regeneration (GTR) and subsequent orthodontic therapy | To evaluate the validity of this multidisciplinary approach. | Radiographs and clinical assessments of PPD, CAL, and gingival recessions at baseline, 1 year after GTR, and at the end of orthodontic therapy. 3-wall infrabony pockets treated with enamel matrix derivate, 2-wall and 1-wall defects treated with a resorbable collagen membrane plus bone graft. | Statistical analyses carried out to compare the data From baseline to 1 year after GTR, PPD reduction \bar{x} = 5.57 mm, with a residual mean PPD of 2.71 mm; CAL gain \bar{x} = 5.86 mm. Both differences were statistically significant. No statistically significant differences between 1 year after GTR and the end of orthodontic therapy. | This study affirms the possibility of a combined orthodontic-periodontal approach that prevents damaging regenerated periodontal apparatus and produces esthetic improvements as a result of realignments and enhancement of papilla height. | Orthodontic treatment did not improve the healing of the infrabony defects. <i>GTR Intrusion and bodily movement</i> |

| Authors | Type of study | Subjects | Aim | Methods | Findings | Authors conclusions | Comments |
|------------------------|---------------|----------------------------------------------------------------------------------------------------------------------------------------------------------------------------------------------------------------|--------------------------------------------------------------------------------------------------------------------------------------------------------------------------------------------|----------------------------------------------------------------------------------------------------------------------------------------------------------------------------------------------------------------------------------------------------------------------------------------------------------------------------------------------------------------|---------------------------------------------------------------------------------------------------------------------------------------------------------------------------------------------------------------------------------------------------------------------------------------------------------------------------------------------|-------------------------------------------------------------------------------------------------------------------------------------------------|------------------------------------------------------------------------------------------------------------------------------------------------------------------------------------------------------------------------------------------------------------------------------------------------------------------------------|
| Ogihara and Marks 2006 | Case report | 45 year old female infrabony pocket of lower second molar | To demonstrate that orthodontic extrusive force can enhance the regenerative potential of guided tissue regeneration (GTR) to eliminate an intrabony defect and augment a ridge deformity. | Regenerative therapy by open debridement with particulate an organic cancellous bovine-derived bone xenograft (BDX), bioabsorbable membrane, and minocycline root conditioning before orthodontic extrusion and uprighting | Radiographs and reentry documentation demonstrated that orthodontic extrusive force could enhance the regenerative potential of GTR. Consequently, the intrabony defect and alveolar ridge were successfully treated. | Orthodontic regenerative combined therapy can resolve complex clinical problems involving several dental disciplines. | Case report: <i>GTR Uprighting and extrusion</i> |
| Diedrich et al. 2003 | Animal study | 4 foxhounds 64 intraosseous defects mesially and distally of 1st and 2nd premolars Control Group (n = 26) Intrusion Group (n = 10) Translation Group (n = 8) (both pressure and tension side) | To examine the relevance of regenerative periodontal therapy (membrane procedure, application of enamel matrix proteins) to subsequent orthodontic tooth movement (Intrusion). | Preparation of 3-wall bony defects, metal strips experimental periodontitis. Periodontal flap surgery; scaling, conditioning with citric acid, application of the enamel matrix derivative Emdogain. Bony pockets distally of the second premolars (pressure side) covered with resorbable polyglactin membrane (Vicryl®) to supplement the effect of Emdogain | Histological findings: extensive periodontal regeneration in the control group, intruded root segments, and on the tension side. Cemento- and osseogenesis \bar{x} = 70-80%, epithelial down-growth low. Bone regeneration on the pressure side markedly reduced; but \approx 70% new formation of root cementum with Sharpey's fibers. | Periodontal regenerative procedures appear to enhance conditions for the movement of teeth with attachment loss; clinical testing is promising. | GTR Emdogain at tension side and membrane at the pressure side. Emdogain only at intruded and control teeth. Orthodontic treatment does not improve the healing of Emdogain. Orthodontic treatment group not as good as the control especially the pressure side. <i>GTR and enamel matrix Intrusion and bodily movement</i> |

Orthodontic tooth movement and edentulous areas

Space closure after extractions carried out as part of an orthodontic treatment plan is often performed in orthodontic treatment and only minimal changes of the height of the supporting bone have been shown in young individuals (Sjölien and Zachrisson 1973; Zachrisson and Alnaes 1974; Wisth 1975; Hollender et al. 1980; Rönnerman et al. 1980; Bondemark 1998; Janson et al. 2003; Bollen 2008).

Experimental and clinical studies have shown that a reduction of the ridge dimensions, both in height and width, will take place following extraction of a tooth (Pietrokovski and Massler 1967; Johnson 1969; Pietrokovski et al. 1976; Atwood 2001; Schropp et al. 2003; Araujo and Lindhe 2005; Nevins et al. 2006; Van der Weijden et al. 2009). The amount of the reduction has been noted to be larger along the buccal surface compared to lingual or palatal surfaces, and as a consequence, the center of the alveolar ridge will be shifted to the lingual or palatal side with a decrease in arch length as a result (Pietrokovski and Massler 1967). Whether dimensional alterations similar to those occurring after extraction occur in an edentulous ridge area established after an orthodontic tooth movement has to our knowledge not been examined.

Studies concerning orthodontic movement into edentulous areas in adults are summarized in Table 2. In adults, a more marked reduction of the bone level was noted after orthodontic space closure in the molar area (Stepovich 1979; Hom and Turley 1984; Goldberg and Turley 1989). In contrast, Diedrich et al. (1996) found only a minimal change in periodontal support when distal movement of premolars into edentulous molar areas was performed. A similar finding was reported by Wehrbein et al. (1990) in an animal study where the intention was to evaluate the extent of bone restructuring in response to different rates of orthodontic tooth movement. However, only one dog was used in the latter study and the conclusions can thus be questioned.

With regard to the bucco lingual dimensional changes after space closure in the molar area in adults an increase in the bucco-lingual width of the alveolar ridge has been shown (Stepovich 1979; Hom and Turley 1984; Goldberg and Turley 1989). All the human studies were descriptive without control groups.

Table 2. Orthodontic movement into edentulous areas in adults (Type of clinical studies categorized according to Grimes and Schulz, 2002)

| Authors | Type of study | Subjects | Aim | Methods | Findings | Authors conclusions | Comments |
|--------------------------|-------------------------|--------------------------------------------------------------------------------------------------------------------------------|-----------------------------------------------------------------------------------------------------------------------------------------------------------------|--------------------------------------------------------------------------------------------------------------------------------------------------------------------------------------------------------------------------------------------------------------------------------------------------------------------------------------------|------------------------------------------------------------------------------------------------------------------------------------------------------------------------------------------------------------------------------------------------------------------------------------------------------------------------------------------------------------------------------------------------------------------------------------------------------------------------------------------------------------------------------------------------------------------------------|-------------------------------------------------------------------------------------------------------------------------------------------------------------------------------------------------------------------------|-------------------------------------------------------------------------------------------------------------------------------------------------------------------------------------------------------------------------------------------------------------------------------------------------------------------------------------------------------------|
| Stepovich 1979 | Case-control study | Group A: 8 subjects age \bar{x} =13.6 years Group B: 8 subjects age \bar{x} =31.5 years 16 edentulous spaces | To study changes in the edentulous ridge and adjacent teeth before and after closure of first molar spaces in the <i>mandible</i> . As well as root resorption. | Casts, lateral head plates, panoramic radiographs. Assessments before and after space closure 1) mandibular ridge width (measured two points 4mm down the slope of the alveolar ridge) and height, 2) Crestal bone height, 3) root resorption, 4) total space closure and 5) mesial migration, uprighting and eruption of the second molar | <i>Bucco-lingual changes of the alveolar ridge</i> Group A: \bar{x} =0.24mm Group B: \bar{x} =0.62mm <i>Changes of crestal bone height</i> , Group A: \bar{x} = -1.1mm Group B: \bar{x} =-2mm, three patients had 3mm bone loss <i>Changes root length</i> : Group A \bar{x} =+1.3 Group B \bar{x} =-0.38 | When closing first molar spaces in the mandible the young adult generated more alveolar bone in the edentulous space and lost less crestal bone than adult patients. Closed spaces are difficult to maintain in adults. | Difficult to measure movement on lateral radiographs. No clinical measurements. Gingival recessions were evident but not evaluated. Different radiographs: panoramic radiographs and periapical radiographs. No radiographs visible in the article only referred to. Only uprighting or bodily-movement. No tipping. |
| Hom and Turley 1984 | Descriptive Case series | 14 adult subjects, Age 20- 39 years 19 edentulous areas | To determine the dental and periodontal changes that occur when mandibular first molar areas are closed in adults. | Pre- and post treatment, cephalometric, panoramic and periapical tracings and study models. Measurement of sagittal length and bucco lingual width of the alveolar ridge Measurement of the bucco-lingual width according to Stepovich 4mm apical to crest. | <i>Crestal bone loss</i> : \bar{x} = 1.3 mm, mesial to the second molar in all but five cases. The higher the bone level pretreatment the greater the bone loss posttreatment. <i>Bucco-lingual width</i> : \bar{x} = 1.2 mm increase(range -1.6- +4.8). <i>Space closure</i> : \bar{x} = 6.2 mm(range 2.7 to 11.5 mm) <i>Treatment time</i> 23 to 52 months. <i>Root resorption</i> \bar{x} = 1.3mm. No correlation with amount of movement. | Space closure is not only possible but may aid the treatment of certain cases. Although every case showed significant space closure only five cases complete space closure. | No control. The values ranged from -1.6mm (decrease) to 4.8mm (increase). 7 cases had a narrower ridge (mean=0.8mm) in the post treatment models indicating a slight bone loss. No correlation between ridge width and change in vertical bone height. No clinical measurements. No control group. |
| Goldberg and Turley 1989 | Descriptive Case series | 18 adult subjects 20 quadrants | To examine the dental and periodontal changes associated with orthodontic space closure of edentulous <i>maxillary</i> first molar areas in adults. | The pretreatment and post treatment records included study casts, lateral cephalometric radiographs, and periapical or panoramic radiographs. Measurement of width according to Stepovich | <i>Space closure</i> \bar{x} =5.3 mm. <i>Bucco-lingual width Bucco-lingual width of the alveolar ridge</i> \bar{x} =0.6 mm. Seven quadrants narrower ridge post treatment. <i>Vertical bone loss</i> \bar{x} =1.2 mm mesial to and distal to the second molar and \bar{x} =0.6 mm distal to the second premolar. The higher the bone level pretreatment the greater the bone loss posttreatment. The longer the treatment period the greater the amount of root resorption. The larger the molar root/crown movement the larger the alveolar width post treatment | Although space closure should be considered a potential solution in the absence of the first permanent molar, alveolar bone loss and space opening can be common sequelae to this procedure. | No information about the age of the patients. The mesial movement of the molar was on the average three times as much as the distal movement of the premolar. Although 60% of the quadrants showed less than or equal to 1.5 mm of bone loss, the maximal bone loss reached 4.0 mm mesial to, and 5.0 mm distal to, the second molar.. No control group. |

| Authors | Type of study | Subjects | Aim | Methods | Findings | Authors conclusions | Comments |
|----------------------|-------------------------|---------------------------------------------------------------------------------------------------------------------------------------------------------------------------------------------------------------------|--------------------------------------------------------------------------------------------------------------------------------|---------------------------------------------------------------------------------------------------------------------------------------------------------------------------------------------------------------|--------------------------------------------------------------------------------------------------------------------------------------------------------------------------------------------------------------------------------------------------------------------------------------------------------------------------------------------------------------------------------------------------------------------------|-------------------------------------------------------------------------------------------------------------------------------------------------------------------------------------------------------|---------------------------------------------------------------------------------------------------------------------------------------------------------------------------------------------------------------------------------------------------------------------------------------------------|
| Diedrich et al. 1996 | Descriptive Case series | 24 subjects 16-52 years (\bar{x} = 31) with missing molar teeth in the upper and/or the lower jaw, 32 premolars distalized. Investigation period 2.5 to 14.1 years, \bar{x} =9.6 years (SD 3.2). | To investigate the long-term functional stability of the distalized premolars and their periodontal and prosthodontic quality. | The clinical examination criteria were sensitivity, mobility, probing depth, sulcus bleeding index; the radiologic criteria were root resorption (lateral and apical) marginal bone level and axial position. | <i>Orthodontic movement</i> \bar{x} =9.4 mm. <i>Probing depths</i> \bar{x} =1.2-2.6mm. 40.6% localized <i>lateral root resorption</i> on the pressure side; depth \bar{x} = 0.7 mm (SD 0.3), and length \bar{x} = 2.3 mm (SD 0.6). At follow-up partial repair of lateral root lesions. Apical root resorption \bar{x} = -0.9 mm (SD 1.1). Bone loss \bar{x} =0.5 mm mesially and 0.2 mm distally. | The distalized premolar should be given preference over the implant abutment in view of its distinctly higher survival rate and the positive periodontal and functional findings. | Mixed adolescents and adults. Varying follow up periods. More bone loss on tension side than pressure side. Maybe depending on distal tipping on a mean 11.8 degrees and difficulty in identifying the cement enamel junction because of prosthetic construction in all cases. No control. |
| Wehrbein et al. 1990 | Animal study | One dog 6 teeth. 2 incisors and second premolars in upper and lower jaw. | To evaluate the extent of bone restructuring after bodily movement of teeth into an area of atrophied alveolar bone. | Extractions and osteotomi in areas adjacent to the test teeth. Orthodontic bodily movement with fixed appliance. Continuous forces until the tooth was moved 1mm. Force 30-50 pond | The measured values as well as the radiographic and histologic data indicate that partial or total bone restructuring occurs depending on the rate of tooth movement. Marked bone formation tooth movement rate of 15 microns/day, no noteworthy bone formation occurred at higher rates of tooth movement (26-40 microns/day). | Improvement in attachment is possible with bodily movement in atrophic alveolar bone. However, it is important to remember the delayed periosteal reaction when planning the mechanics to be applied. | 40 micron comparable with 1mm/month. Only one dog. The author maybe wrong conclusion: as all the "slowmoving" teeth were the incisors in the upper jaw and the "fast moving" teeth, the premolars in the lower jaw. New own conclusion: most remodeling in the upper jaw? Adult dog? |

Physiological tooth movement into edentulous areas

Tipped and/or overerupted molars, as a consequence of loss of adjacent and/or opposed teeth, have been proposed to affect occlusal interferences and changes in the dental equilibrium (Weinstein 1967; Proffit 1978; Ramfjord and Ash 1983).

Overeruption / continuous eruption

The tendency of teeth to move in an occlusal direction even in adulthood has been described as continuous eruption (Heij et al. 2006; Thilander 2009) hyper eruption (Ramfjord and Ash 1983), overeruption (Kiliaridis et al. 2000), supereruption (Craddock et al. 2007) and supraeruption (Kaplan 1985).

Findings reported in the literature of studies regarding the extent and severity of overeruption of posterior teeth due to the lack of an antagonist are presented in Table 3. In summary, the majority of unopposed teeth tend to move more in an occlusal direction than opposed (Compagnon and Woda 1991; Smith 1996; Kiliaridis et al. 2000; Craddock et al. 2007). Maxillary unopposed teeth move more than mandibular (Craddock et al. 2007), the movements are most pronounced during the first years after the opposed tooth is lost (Love and Adams 1971) and periodontally affected teeth move more (Compagnon and Woda 1991 Christou and Kiliaridis 2007; Fujita et al. 2010). Craniofacial growth and continuous eruption of opposed and unopposed teeth have been observed in adults but mainly below the age of 50 (Thompson and Kendrick 1964; Behrents 1985; Forsberg et al. 1991; Tallgren and Solow 1991; Iseri and Solow 1996; Thilander et al. 2001; Bernard et al. 2004; Jemt et al. 2007; Thilander 2009). However, the majority of the human studies are descriptive with no control groups and sometimes only one registration.

Table 3. Continuous eruption/overeruption (Type of clinical studies categorized according to Grimes and Schulz, 2002)

| Authors | Type of study | Subjects | Aim | Methods | Findings | Conclusion | Own Comments |
|-----------------------|---------------|-----------------------------------------------------------------------------------------------------------------------------------------------------------------------------------------------------------------------------------------------------------------|---------------------------------------------------------------------------------------------------------------------------------------------------------------------------------------------------------------------------|----------------------------------------------------------------------------------------------------------------------------------------------------------------------------------------------------------------------------------------------------------------------------------------------------------------------------------------------------------------|---------------------------------------------------------------------------------------------------------------------------------------------------------------------------------------------------------------------------------------------------------------------------------------------------------------------------------------------------------------------------|------------------------------------------------------------------------------------------------------------------------------------------------------------------------------------------------------------------------------------------------------------------------------------|-----------------------------------------------------------------------------------------------------------------------------------------------------------------------------------------------------------------------------------------------------------------------------------------------------------------------------------------|
| Thilander et al. 2001 | Cohort study | 18 subjects with missing teeth followed a 10-year period Initial age 13 -17 years. In 15 patients, 29 single implants to replace premolars, canines, and upper incisors.3 patients with extensive aplasia, 18 implants in various regions. | To evaluate the long-term effect of implants installed in different dental areas in adolescents. | Photographs, study casts, peri-apical radiographs, lateral cephalograms, and body height measurements were recorded at each control. | The results from the present study clearly indicate that there are physiological occlusal changes not only from adolescence into young adulthood, but also into old age. | Due to the continued eruption of the natural teeth, the use of osseointegrated implants with artificial teeth should not be recommended in childhood, adolescence, and early adulthood. | No information about individuals older than 27 years. |
| Bernard et al. 2004 | Cohort study | 28 subjects divided into two groups. A "young adult" group 14 patients, aged from 15.5 to 21 years, and "mature adult" group 14 patients, aged from 40 to 55 years. All patients presented missing anterior teeth, requiring insertion of 40 implant fixtures . | To evaluate the effects of the tooth eruption process on the position of teeth adjacent to implant-borne restorations in adult patients compared to patients in their late adolescence. | Straumann Dental Implant System, clinically and radiologically re-evaluated 1 year or more after the surgical procedure (interval=4.2 years). Assessment of the eruption of the adjacent teeth using the implant as a stable point of reference: measurements of the different reference points compared after implant placement and at follow-up examination. | In the "young adult" group, all patients showed infra-occlusion of the implant-supported crowns: the vertical step varied between 0.1 and 1.65 mm. In the "mature adult" group, all patients showed a vertical difference, step 0.12 - 1.86 mm. No difference amount of vertical eruption between male and female patients, nor according to localization of the implant. | Even if in most adult patients the effect of adult residual growth or aging alterations may be small, the results of our study support the assumption that mature adults can also exhibit major vertical steps after anterior restorations with osseointegrated fixtures. | Small groups Large range of reevaluation period. Shortest 1 year and mean 4.2 years No difference between males and females. No cephalometric evaluation Similar observations in late adolescents and adult patients, a vertical step of the same extent, detected in both groups after short evaluation period |
| Jemt et al. 2007 | Cohort study | <i>Study group:</i> 25 subjects, mean age was 25.4 years final examination \bar{x} =15.9 years <i>Reference group:</i> 134 dental students with a mean age of 22.9 years. | To analyze the prevalence and magnitude of tooth movements adjacent to single-implant crowns in a long-term study, and to discuss these changes in relation to cephalometric changes in a reference group after 10 years. | <i>Study group</i> Clinical photographs and studycasts at implant crown placement and at later final examination an average of 15.9 years. <i>Reference group,</i> Cephalograms and study casts at inclusion and after 10 years. Study casts after 20 years (n = 61). Vertical overbite measurements on study casts. | Male patients presented a clinically stable situation without any signs of vertical tooth movement in 11 of 20 implant sites, compared to none in female patients (P < .05). Both males and females significant increase of anterior and posterior face height (P < .05), only females presented significant increase of the NSL/ML angle. | A possible relationship between significantly higher incidence of tooth movements adjacent to implants in females in the study group and significantly greater increase of anterior face height and posterior rotation of the mandible in the female reference group was observed. | Cephalogram only of reference group and of younger adults up to 33 years, maybe different values if older individuals. Greater differences in the female group. Increase of NSL/ML indicating continuous eruption also of molars. |

| Authors | Type of study | Subjects | Aim | Methods | Findings | Conclusion | Own Comments |
|------------------------------|-----------------------|---------------------------------------------------------------------------------------------------------------------------------------------------------------------------------------------------|------------------------------------------------------------------------------------------------------------------------------|---------------------------------------------------------------------------------------------------------------------------------------------------------------------------------------------------------------------------------------------------------------------------|-----------------------------------------------------------------------------------------------------------------------------------------------------------------------------------------------------------------------------------------------------------------------------------------|-------------------------------------------------------------------------------------------------------------------------------------------------------------------------------------------------------------------------------------------------------|--------------------------------------------------------------------------------------------------------------------------------------------------------------------------------------------------------------------------------------------------------------------------------------------------|
| Smith 1996 | Case-control study | <p><i>Test group:</i> 42 subjects mean age 22 years with a history of upper molar extractions in the last 10 years.</p> <p><i>Control group:</i> 42 subjects without upper molar extractions.</p> | To investigate the presence of any over-eruption in a group of subjects who had upper second permanent molars extracted. | Upper and lower impressions were taken, and the vertical positions of the posterior teeth were objectively assessed from the study models using the travelling microscope. | The lower second permanent molar had over erupted in the experimental group when compared to the control ($P < 0.001$ right, $P < 0.05$ left). Degree of over-eruption influenced on the mesial aspect by the distal position of the upper first permanent molar ($P < 0.01$), | Over-eruption of lower second permanent molars occurred in cases where the upper second permanent molars had been extracted. This problem was mainly confined to the distal aspect of the lower second permanent molars. | In cases with class I, there is a contact at the mesial aspect which may explain the result. The most severe case showed class II relationship between the first molars. |
| Christou and Kiliaridis 2007 | Case-control study | <p><i>Test/control:</i> 12 subjects mean age 45 years</p> <p><i>Test teeth:</i> 22 unopposed maxillary molars</p> <p><i>Control teeth:</i> 14 posterior teeth with antagonists.</p> | To longitudinally examine, changes of position in the three dimensions of maxillary molars unopposed for more than 10 years. | Plaster casts were made at the first and last examination. On three-dimensional scanned plaster casts, changes in the centroid of the occlusal surface were measured in the three dimensions. The changes observed on both occasions were compared with a <i>t</i> -test. | Vertical displacement of unopposed molars $\bar{x}=0.8$ mm, and controls $\bar{x}=0.4$ mm. Periodontally affected molars erupted $\bar{x}=1.97$ mm and periodontally healthy molars $\bar{x}=0.48$ mm. Palatal movement unopposed teeth $\bar{x}=0.9$ mm and controls $\bar{x}=0.5$ mm. | There is displacement of unopposed teeth in the three dimensions in long term, although this is clinically insignificant in periodontally healthy adults. Observed changes either the result of late growth remodeling or altered dental equilibrium. | Only 4 periodontally affected teeth. Variation in amount and type of teeth studied, experimental- unopposed molars (n=22) and control teeth- opposed molars and premolars (n=14). No information about periodontally affected opposed teeth compared to periodontally affected unopposed molars. |
| Thilander 2009 | Case-control study | <p>436 subjects 189 male 247 female age 5 to 31 years, with ideal occlusion</p> <p>no history of orthodontic treatment</p> | To examine dentoalveolar development in subjects with an 'ideal' (normal) occlusion. Maxilla and mandible. | Assessments on dental casts. Student T-test for comparing groups. | The results verified that continuous changes of the dental arches occur from the primary until the adult period, with individual variations. Continuous increase of palatal height between 16 and 31 years of 0.1mm/year. | Continuous increase of palatal height (0.1 mm/year), seems to be effect of slowcontinuouseruption of teeth. This finding is also of significance in explaining the infra-position of implant-supported crowns. | Not the same subjects, few individuals in older age-groups. |
| Tallgren and Solow 1991 | Cross-sectional study | <p>Subjects: 191 dentate Finnish women</p> <p>Three age groups: 20-29 years 30-49 years 50-81 years</p> | To study age differences in dentoalveolar heights of the mandible and the maxilla | Assessments of cephalometric radiographs. 26 variables were calculated from digitized reference points | The differences of the posterior dental height were larger in the maxilla than in the mandible. No significant differences in dentoalveolar morphology were observed between the middle and the old age groups. | The findings seem to indicate that continuous increase in dentoalveolar height during adulthood does not cause any major changes in anterior occlusion at subjects with clinical acceptable occlusion. | Most individuals in the youngest group (n=81) and least in the oldest group (n=46). No control. Only subjects with clinical acceptable occlusion |

| Authors | Type of study | Subjects | Aim | Methods | Findings | Conclusion | Own Comments |
|----------------------|------------------------------|-------------------------------------------------------------------------------------------------------------------------------------------------------------------------------------------------|-----------------------------------------------------------------------------------------------------------------------------------------------------------------------------|----------------------------------------------------------------------------------------------------------------------------------------------------------------------------------------------------------------------------------------------------------------------------------------------------------|------------------------------------------------------------------------------------------------------------------------------------------------------------------------------------------------------------------------------------------------------------------------------------------------|----------------------------------------------------------------------------------------------------------------------------------------------------------------------------------------------------------------------------------------------------------------------------------------------------------------------------------------|---------------------------------------------------------------------------------------------------------------------------------------------------------------------------------------------------------------------------------------------------------------|
| Craddock et al. 2007 | Cross-sectional study | <p><i>Test group:</i> 100 consecutive subjects with an unopposed posterior tooth (at least 5 years) , age 18 years or older</p> <p><i>Control group:</i> 100 age and sex- matched subjects.</p> | To determine the extent and type of supraeruption associated with unopposed posterior teeth and to investigate the relationship between these and oral and patient factors. | Diagnostic casts were scanned and analyzed to record the extent of supraeruption Generalized Linear Models developed to examine associations between the extent and type of supraeruption and patient or dental factors. <i>Periodontal Growth Active Eruption, or Relative Wear</i> | Supraeruption \bar{x} = 1.68 mm (SD 0.79, range 0 to 3.99 mm) and for controls, \bar{x} = 0.24 mm (SD 0.39, range 0 to 1.46 mm). Extent of supraeruption statistically greater in maxillary than mandibular unopposed teeth. Supraeruption found in 92 % of subjects with unopposed teeth. | Supraeruption more prevalent in the maxillary arch and associated with a reduction in periodontal attachment. Three kind of supraeruption: <i>Active eruption:</i> association with attachment loss <i>Periodontal growth:</i> Younger individuals <i>Relative wear:</i> more prevalent with increasing age and in the mandible. | No baseline registration. The study describes changes following posterior tooth loss but not rate of change or relationship to age. Measurement of occlusal curve straight instead of flattened may give an impression of more supra eruption in both groups. |
| Craddock 2008 | Cross-sectional study | <p><i>Test group:</i> 100 consecutive subjects with an unopposed posterior tooth (at least 5 years) , age 18 years or older</p> <p><i>Control group:</i> 100 age and sex- matched subjects</p> | To determine clinical parameters associated with the presence of retruded contact position (RCP) contacts and occlusal interferences associated with posterior tooth loss. | Clinical examinations identified the presence of RCP contacts and occlusal interferences. Five generalized linear models were developed to investigate the parameters associated with presence of RCP contacts, protrusive interferences, working side interferences, and nonworking side interferences. | RCP contacts were associated with the degree of supraeruption of the unopposed tooth and the presence of other types of interference. Incidence of occlusal contacts and interferences. Contact or interference of unopposed tooth: Subjects 53 and control 12 | Unopposed posterior teeth are more likely to be involved in RCP contacts or interferences than their matched controls. Initial RCP contacts have associations with the extent of supraeruption of the unopposed teeth. Many teeth were involved with multiple interferences. | Not only if the tooth is unopposed or not influence the development of interferences but also the presence and position of the teeth distal to the extraction site (protrusive interferences). |
| Love and Adams 1971 | Descriptive Prevalence study | <p>536 subjects</p> <p>median age group 28 to 30 (age from 13-62 years))</p> <p>With an edentulous space with missing tooth five years or longer</p> | To determine incidence of movement in an attempt to validate clinical observations. | Questionary form to dental officers. Three aspects were concerned 1) Movement of the tooth mesial to the space into the space. 2) Movement of the tooth distal to the space into the space.3) Movement of the tooth opposing the space into the space. | Movement of teeth into the edentulous spaces not inevitable. Movement more pronounced in young subjects. In subjects with extraction at least five years ago no statistical relationship between movement and time of extraction was found. | The results indicate that most movement occurs during the first five years after the tooth was removed. No control-group. | No documentation by casts or radiographs only a questionnaire, many different examiners may reduce the reliability. Low value of evidence. No control group. |

| Authors | Type of study | Subjects | Aim | Methods | Findings | Conclusion | Own Comments |
|----------------------------|------------------------------|----------------------------------------------------------------------------------------------------------------------------------------------------------------------------|-------------------------------------------------------------------------------------------------------------------------------------------------------------------|-------------------------------------------------------------------------------------------------------------------------------------------------------------------------------------------------------------------------------------------------------------------------------------------|-----------------------------------------------------------------------------------------------------------------------------------------------------------------------------------------------------------------------------------------------------------------------------|-----------------------------------------------------------------------------------------------------------------------------------------------------------------------------------------------------------------------------------------------------------------------------------------------------------------------------|-------------------------------------------------------------------------------------------------------------------------------------------------------------------------------------------------------------------------------------------------------------------------------------------------------------------------------------------------------------------------------------|
| Compagnon and Woda 1991 | Descriptive Prevalence study | Subjects 18 - 50 years <i>Group 1</i>) ref. n= 25 <i>Group 2</i>) n = 40 <i>Group 3</i>) n= 10 with periodontal inflammation (extraction 5 to 15 years ago) | To study the behavior of the human periodontium following the loss of occlusal contact of the maxillary first molar in the absence of the mandibular first molar. | Measurement on dental casts. Students t-test : to compare the averages obtained Both the migration of the gingival margin and the increase in the crown height were evaluated in relation to length of time the antagonist tooth had been missing. Values compared with a reference group | The results show that in the first years following the loss of the opposing tooth, supraeruption is mainly due to growth of the periodontium. Later or in the case of periodontal pathosis, tooth movement beyond the occlusal plane is due principally to active eruption. | Supraeruption is phenomenon that is divided into groups: periodontal growth and active eruption on. With a normal dentition. Periodontal growth takes place during early years following the extraction. Later, in case of an inflamed periodontium, supraeruption is more pronounced and is mainly due to active eruption. | Unopposed maxillary molars without periodontal disease migration of the periodontal margin took place in occlusal direction during the first years after extraction and reversed then to apical. Passive eruption regression of gingiva and does not lead to supraeruption. This study more focused on the periodontal behavior than amount of occlusal movement. No control group. |
| Craddock and Youngson 2004 | Descriptive Prevalence study | 120 subjects 155 unopposed posterior sites, 81 males and 74 females. Age \bar{x} =50.9 years, SD 13.94 | To determine the incidence and extent of over eruption in unopposed posterior teeth and occlusal interferences associated with unopposed posterior teeth. | A clinical occlusal examination was carried out and the presence of initial retruded contact position (RCP) contacts and excursive interferences were recorded. Study models were made and digitally scanned by using a three-dimensional flat bed scanner | Incidence of overeruption in unopposed teeth 83.9%. The most frequent degree of overeruption was between 1 and 2,5mm. 48.8% of the upper and 61.8 % of lower , unopposed, sites had associated occlusal interferences (most in RP) No control. | High incidence of occlusal interference, associated with the presence of unopposed teeth. However only a weak statistical association between the degree of overeruption and the presence of occlusal interferences. | Measurement of overeruption by measurement of the distance to the curve of Spee. Difficulties to estimate the curve of Spee in cases with many missing teeth. No control group. |
| Petridis et al. 2010 | Descriptive Prevalence stud | 123 subjects 229 edentulous spaces | To study the stability of teeth adjacent to posterior edentulous spaces and correlate it with patient age and time lapse since tooth loss | Dental casts, panoramic radiographs, and questionnaires. Teeth adjacent and opposing posterior edentulous spaces were examined for the following parameters: Supraeruption, rotation, space closure, and axial inclination. | The effect of time lapse since tooth loss was significant regarding the "amount of distal tooth inclination" (P<0.001), the "amount of distal tooth rotation" (P=0.004), and "space closure" (P=0.038). No control. | it was concluded that in the group of patients studied, minor positional changes in teeth opposing or adjacent to posterior edentulous spaces had occurred. The greatest changes in position were recorded for mandibular teeth distal to edentulous spaces. | The way of measuring the inclination can be questioned. Only one registration on radiograph/casts for judging tipping and elongation. No control group. |
| Kiliaridis et al. 2000 | Descriptive prevalence study | 53 subjects. Age \bar{x} 65 years. 84 molars > 10 years without antagonists. 25 molars no antagonist or a mesially adjacent tooth | To examine molars that had been unopposed for a long period both in the upper and the lower jaw. | A qualitative method on dental casts was used to evaluate the position of the molars in the vertical direction: (1) teeth with no sign of overeruption, (2) teeth with slight overeruption (< 2 mm), and (3) teeth with moderate to severe overeruption (> or = 2 mm). | Of the 84 molars examined, 15 teeth (18%) revealed no signs of overeruption, 49 teeth (58%) displayed overeruption of less than 2 mm, and 20 teeth (24%) showed moderate to severe overeruption. | It is concluded that not all molars without antagonists overerupt, not even in a long-term perspective. The existence of adjacent teeth was important for the molar in a mesiodistal or buccolingual direction. | Models from the population study of women in Gothenburg and from the Department of Prosthodontic Dentistry in the region. Two observers independent of each other. In cases of disagreement, discussion between the observers gave the final score. No control group. |

| Authors | Type of study | Subjects | Aim | Methods | Findings | Conclusion | Own Comments |
|----------------------------|------------------------------|-----------------------------------------------------------------------------------------------------------------------------------------------------------------------------------------------------------|-----------------------------------------------------------------------------------------------------------------------|------------------------------------------------------------------------------------------------------------------------------------------------------------------------------------------------------------|-----------------------------------------------------------------------------------------------------------------------------------------------------------------------------------------------------------------------------------------------------------------|------------------------------------------------------------------------------------------------------------------------------------------------------------------------------------------------------------------------------------------|--------------------------------------------------------------------------------------------------------------------------------------------------------------------------------------------------------------|
| Shugars et al. 2000 | Descriptive prevalence study | 111 subjects who had an untreated bounded edentulous space(BES) mean age at the time of extraction was 45.5 years (range 24 to 90 years) median follow-up period 6.9 years. | To estimate extrusion by measuring the change in the position of the opposing tooth. | Radiographs where change in position of opposing teeth were measured. | Extrusion of the opposing tooth was < or = 1 mm in 99 percent of the cases. | Within the follow-up time, this group of patients did not exhibit the expected adverse consequences, with either the frequency or severity generally assumed to be associated with no replacement of a single posterior tooth. | Not optimal with baseline examination six month after extraction. Large range of baseline as well as follow-up examination reduces the possibility to estimate short and longtime changes. No control group. |
| Thompson and Kendrick 1964 | Descriptive Case series | 71 subjects Males Age 22-34 years | To study changes in the vertical dimensions of the human male skull during the third and fourth decades of life | Two identical lateral cephalometric radiographs at baseline and after 1 year | At the end of the first 12 months the mean values of all skull, dimensions Assessed increased except the mean value of anterior cranial height | Longitudinal evaluation with cephalometric radiographs the best way to study growth in adults | Different ages and a short follow-up period. No control group. |
| Behrents 1985 | Descriptive Case series | 153 subjects (from which 113 untreated) a subsample from the Boltonstudy initiated at various young ages and terminated at various older ages (between 16 and over 80 years of age) age \bar{x} = 46.4. | Skeletal changes were described by: measurements of the relationships between the cranial base and the jaws. | Roentgen cephalometric investigation where superimposition on sella and orientation on sella-nasion has been performed. | Individual growth patterns were apparent in early adulthood, while changes in a more vertical direction growth pattern were common to both sexes in older ages. The study indicated that growth occurred at older ages and there may be no cessation of growth. | Growth of the craniofacial skeleton continued into the oldest age spans studied, in decelerating manner. Growth of males differed from that of females but in later adulthood vertical dimensional change appeared common to both sexes. | Few subject between 35 and 50 years and over 60 years. No control group. |
| Kaplan 1985 | Descriptive Case series | 6 cases, with tipping drifting and supraeruption resulting from tooth loss of opposed and/ or adjacent : Clinical photos and study casts | To define the elements of tooth movement and alveolar bone growth that result in a clinically altered tooth position. | No description of the material besides tooth movement of teeth with a missing opposed or adjacent tooth. 6 examples, with tipping drifting and supra eruption from the clinical situation and study casts. | Drifting, tipping, supraeruption, and segmental alveolar bone growth are the four major forms of non orthodontic intraoral tooth movement. | They may occur separately but usually occur in combination at any age but tend to be most devastating in their effects on the dentition of the young adult and the elderly. | More a description of tooth movement close to edentulous areas than a study. No measurements performed.No control group. |

| Authors | Type of study | Subjects | Aim | Methods | Findings | Conclusion | Own Comments |
|----------------------|-------------------------|--------------------------------------------------------------------------------------------------------------------------------|-----------------------------------------------------------------------------------------------------------------------------------------------------|------------------------------------------------------------------------------------------------------------------------------------------------------------------------|--------------------------------------------------------------------------------------------------------------------------------------------------------------------------------------------------|----------------------------------------------------------------------------------------------------------------------------------------------------------------------------------------------------------------------------------|-------------------------------------------------------------------------------------------------------------------------------------------------------------------------------------------------------------------------------------|
| Forsberg et al. 1991 | Descriptive Case series | 30 subjects 15 men and 15 women. 2 cephalograms of each subject, at average ages 25 and 45 years | To study vertical craniofacial changes during 20 years of adult life with special reference to vertical changes in dentoalveolar region. | Roentgen cephalometric investigation of vertical craniofacial and dentoalveolar changes during 20 years of adulthood, Skeletal and dental changes described. | The analysis of the linear variables showed that total anterior face height increased by 1.60 mm on an average between 25 and 45 years. Mainly localized to the lower face. | The present data indicates that increase in face height continues well into the 4 th decade of life. However there is no evidence that the upper age limit used in the present study marks cessation of this process. | Same subjects, but only two measurements, which reduce the information about when the changes had occurred. The average amount/year was 0.08mm. No control group. |
| Iseri and Solow 1996 | Descriptive Case series | 14 subjects (girls) age range 9-25 years from implant study of Bjork (1968) 14 series of lateral cephalometric films | To describe the average and individual patterns of continued eruption of the maxillary incisors and first molars in a longitudinal sample of girls. | All subjects had bilateral posterior maxillary implants and one or two anterior maxillary implants. Data debugged by comprehensive numerical and graphical procedures. | The average cumulative continued eruption from 9-25 years of age was 6 mm downwards and 2.5 mm forwards for the upper incisors, and 8 mm downwards and 3 mm forwards for the upper first molars. | Due to the continued eruption of the natural teeth, the use of osseointegrated implants with artificial teeth should not be recommended in childhood, adolescence, and early adulthood | Not focus on adult changes but more on growth during adolescence. No control group. |
| Heij et al. 2006 | Non Systematic Review | Review of 38 articles | To explain the risk for continuous eruption and to provide recommendations for implant placement. | Study of implants in relation to adjacent teeth and study of growth by superimposition. Anterior/posterior maxilla and mandible were studied. | The cessation for the development of the alveolar process can vary widely, especially in case of long or short facial types. | The risk posed by continuous eruption during adulthood should be considered. | Non-systematic review. Including articles already referred to. |
| Fujita et al. 2009 | Animal study | 20 young and 20 adult rats, | The aim of this study was to investigate the position of the unopposed molar, in young and adult rats | From a 3D image of the rat's head, standardized frontal sections were obtained of the mandible where the measurements were done. | Unopposed molars of the young animals were in supraposition being higher than the position of molars with antagonists. More pronounced in young rats | The overeruption potential of unopposed molars is higher in young than adult rats. | Rodents have a continuous eruption of teeth the whole life which makes the result not entirely comparable with humans. |
| Fujita et al. 2010 | Animal study | 60 adult rats 4 groups (n = 15 in each group) 2 groups, periodontitis induced | To evaluate overeruption pattern of unopposed mandibular molars in rats. | From a 3D image of the rat's head, standardized frontal sections were obtained of the mandible where the measurements were made. | Periodontally affected unopposed molars erupted significantly more ($\bar{x}=1.97$ mm, 0.58 mm) than periodontally healthy teeth (0.48 mm, $P \leq 0.01$) | The loss of antagonists causes overeruption of the unopposed tooth which becomes more prominent in the presence of periodontitis. | More important if the molar was unopposed or not than if it was periodontally affected for the significance. Rodents have a continuous eruption of teeth the whole life which makes the result not entirely comparable with humans. |

Tipping/drift into edentulous areas

Findings reported in the literature from studies regarding the extent and severity of posterior tooth movements, due to the lack of an adjacent tooth, are partly contradictory and are summarized in Table 4

In summary, the degree of tipping of the teeth distal to the edentulous area has been reported to be larger in the mandible than in the maxilla, but with a high degree of variation (Kiliaridis et al. 2000; Craddock et al. 2007; Petridis et al. 2010). Only small changes in the edentulous spaces were evident in cases where lost posterior teeth had not been replaced (Shugars et al. 2000). There was a significant mesial displacement and tipping of unopposed molars with no mesially adjacent teeth (Kiliaridis et al. 2000; Christou and Kiliaridis 2007). Teeth mesial to the extraction site had a tendency to tip or migrate distally (Kaplan 1985; Witter et al. 1987; Craddock et al. 2007) and the movement of the teeth into the edentulous space was largest during the first years and thereafter decreased (Love and Adams 1971; Gragg et al. 2001; Petridis et al. 2010). However, the majority of the studies are descriptive with no control groups and sometimes only one registration.

Table 4. Tipping/drift into edentulous areas (Type of clinical studies categorized according to Grimes and Schulz, 2002)

| Authors | Type of study | Subjects | Aim | Methods | Findings | Conclusion | Own comments |
|------------------------------|-----------------------|---------------------------------------------------------------------------------------------------------------------------------------------------------------------------------------------------------------------------|---------------------------------------------------------------------------------------------------------------|------------------------------------------------------------------------------------------------------------------------------------------------------------------|--------------------------------------------------------------------------------------------------------------------------------------------------------------------------------------------------------------------------------------------------------------------------------------------------|-----------------------------------------------------------------------------------------------------------------------------------------------------------------------------------------------------------------------------------------------------------------------------------------------------|-----------------------------------------------------------------------------------------------------------------------------------------------------------------------------------------------------------------------------------------------------------------------------|
| Christou and Kiliaridis 2007 | Cohort study | 12 subjects (six males, six females); Age \bar{x} = 45 years 11 months. 22 unopposed maxillary molars 14 posterior teeth with antagonists. Followed-up period \bar{x} = 10 years 7 months | To examine changes in 3D and comparing these molars with and without an adjacent tooth. | Scanned plaster casts Changes in the centroid of the occlusal surface were measured in the three dimensions. The changes were compared with a <i>t</i> -test. | There was significant mesial displacement of unopposed molars without mesially adjacent teeth when compared with controls. Palatal movement was observed in the unopposed teeth (0.9 mm, SD 0.6 mm) and was significantly greater than that in the controls (0.5 mm, SD 0.3 mm; $P \leq 0.02$). | 1. There is a change in the position of all teeth. 2. Molars with periodontitis are more prone to overerupt. 3. There is significant mesial displacement of unopposed molars with no mesially adjacent teeth. 4. There is a palatal displacement of all teeth, mainly of unopposed molars. | Only 4 periodontically affected teeth. Variation in amount and type of teeth studied, experimental-unopposed molars (n=22) and control teeth-opposed molars and premolars (n=14). No information about periodontically affected opposed teeth compared to unopposed molars? |
| Witter et al. 1987 | Case control study | <i>Experimental groups</i> n= 60 1) ≤ 40 years 2) ≥ 40 years with SDA (shortened dental arch) <i>Control groups</i> n = 72. 1) ≤ 40 years 2) ≥ 40 years | To describe the pattern of migration of the teeth in subjects with SDA (Shortened Dental Arches) | Measurement of occlusal contact, overbite, interdental contact or spacing and attrition in order to quantify the migration of the remaining teeth. | Subjects ≤ 40 years a significant effect of SDA on the interdental spacing between the lower premolars. Smaller differences for upper premolars. Subjects ≥ 40 years no significant differences between SDA and control group. | A systemic effect of SDA was found on interdental spacing for subjects under 40 years of age but it was concluded that this migration was within acceptable levels. | No significant differences in the older age- group maybe due to distal migration of lower premolars also in the control group? |
| Craddock et al. 2007 | Cross-sectional study | <i>Test group:</i> 100 consecutive subjects with an unopposed posterior tooth (at least 5 years), age 18 years or older <i>Control group:</i> 100 age and sex- matched subjects | To determine the type and extent of non-vertical tooth movement and associations to other clinical parameters | Scanned diagnostic casts Estimation of degree of tipping Generalized Linear Models to examine associations to patient or dental factors. | A statistical significance tipping of teeth both mesial and distal to the extraction site. Upper and lower teeth similar. Lower teeth had a greater likelihood of extreme tipping. | Teeth mesial to the extraction site had a tendency to tip distally. The degree of tipping was increased in upper teeth and in subjects with a cusp-to-cusp I occlusion. Tipping of the distal tooth could be extreme and more prevalent in subjects with a reduced overbite and in the lower arch. | The subject in this study was the same as in part 1 where supra eruption was investigated. Maybe an elongated molar in the opposite jaw will influence the tipping by causing interferences? Not always a mesial edentulous area. |

| Authors | Type of study | Subjects | Aim | Methods | Findings | Conclusion | Own comments |
|------------------------|------------------------------|--------------------------------------------------------------------------------------------------------------------------------------------------|-------------------------------------------------------------------------------------------------------------------------------------------|------------------------------------------------------------------------------------------------------------------------------------------------------------------------------------------------------------------------------------|---------------------------------------------------------------------------------------------------------------------------------------------------------------------------------------------------------------------------|---------------------------------------------------------------------------------------------------------------------------------------------------------------------------------------------------------------------------------------------------------|-------------------------------------------------------------------------------------------------------------------------------------------------------------------------------------------------------------------------------------------------------------------------------------------------------------------------------------------------------|
| Love and Adams 1971 | Descriptive Prevalence study | 536 subject age from 13-62 years (median age group 28 to 30) With an edentulous space with missing tooth five years or longer | To determine incidence of movement in an attempt to validate clinical observations | Questionary: 1) Movement of the tooth mesial to the space into the space. 2) Movement of the tooth distal to the space into the space. 3) Movement of the tooth opposing the space into the space. | Movement of teeth into the edentulous spaces was not inevitable. Movement was more pronounced in young subjects No statistical relationship between movement and time of extraction was found. | The results indicate that most movement occurs during the first five years after the tooth was removed. | No documentation by casts or radiographs only a questionnaire, many different examiners may reduce the reliability. Low value of evidence. No control group. |
| Kiliaridis et al. 2000 | Descriptive prevalence study | 53 subjects. Age \bar{x} 65 years. 84 molars > 10 years without antagonists. 25 molars no antagonist or a mesially adjacent tooth | To examine molars that had been unopposed for a long period. | A qualitative method on dental casts to evaluate the position of the molars in relation to the occlusal plane (0) No sign of tipping (1) slight tipping (2) definite tipping . The same scale was used for elongation. | No tipping was reported in 62% the cases and only 4 out of 84 teeth (5%) demonstrated tipping more than 15 degrees. More frequent in the mandible. | The existence of adjacent teeth was important for the molar in a mesiodistal or buccolingual direction. Tipping was more common in the mandible. | Models from the population study of women in Gothenburg and from the Department of Prosthodontics. Two observers independent of each other. In cases of disagreement, discussion between the observers gave the final score? The majority of the molars had an adjacent tooth. Not always a mesial edentulous area. No control group |
| Petridis et al. 2010 | Descriptive Prevalence study | 123 subjects 229 edentulous spaces | To study the stability of teeth adjacent to posterior edentulous spaces and correlate it with patient age and time lapse since tooth loss | Dental casts, panoramic radiographs, and questionnaires. Teeth adjacent and opposing posterior edentulous spaces were examined for the following parameters: Supraeruption, rotation, space closure, and axial inclination. | The effect of time lapse since tooth loss was significant regarding the "amount of distal tooth inclination" ($P < 0.001$), the "amount of distal tooth rotation" ($P = 0.004$), and "space closure" ($P = 0.038$). | It was concluded that in the group of patients studied, minor positional changes in teeth opposing or adjacent to posterior edentulous spaces had occurred. The greatest changes in position recorded for mandibular teeth distal to edentulous spaces. | The way of measuring the inclination can be questioned? Only one registration on radiograph/casts for judging tipping and elongation. No control group. |
| Kaplan 1985 | Descriptive Case series | 6 subjects with tipping drifting and supraeruption resulting from tooth loss of opposed and/or adjacent . | To define the elements of tooth movement and alveolar bone growth that result in a clinically altered tooth position. | Clinical photos and study casts No description of the material besides tooth movement of teeth with a missing opposed or adjacent tooth. No measurements performed. | Drifting, tipping, supraeruption, and segmental alveolar bone growth are the four major forms of non orthodontic intraoral tooth movement. | Tooth movement may occur separately but usually occur in combination at any age but tend to be most devastating in their effects on the dentition of the young adult and the elderly. | More a description of tooth movement close to edentulous areas than a study. No control group. |

| Authors | Type of study | Subjects | Aim | Methods | Findings | Conclusion | Own comments |
|---------------------|-------------------------|----------------------------------------------------------------------------------------------------------------------------------------------------------------------------------------------|--------------------------------------------------------------------------------------------------------------------------------------------|-----------------------------------------------------------------------------------------------------------------------------------------------------------------------------------------------------------------------------------------------------------------------------------------------------------------------------------------------------------------------------------------|-----------------------------------------------------------------------------------------------------------------------------------------------------------------------------------------------------------------------------------------------------------|---------------------------------------------------------------------------------------------------------------------------------|-----------------------------------------------------------------------------------------------------------------------------------------------------------------------------------------------------------------------------------------------------------------------------------------------------------------------------------------------------------------------------------------------------------------------------------------------------------|
| Shugars et al. 2000 | Descriptive Case series | 111 patients who had an untreated bounded edentulous space(BES) Age at extraction: \bar{x} =45.5 years (range 24 to 90 years) Median follow-up period 6.9 years (1.1 - 9.6 years) | A missing posterior tooth is assumed to result in adverse consequences, which include shifting of teeth and loss of alveolar bone support. | Bite wing where change in distance between adjacent teeth were measured. Baseline radiographs within six months before or after the extraction. Follow-up comparison with most recent radiograph. | 74% of the subjects lost 1 millimeter or less of the space, 13% 1.1-2mm and 13% .2. 1-3 mm Alveolar bone loss < or = 1 mm in 83 percent of the cases. | None of the expected adverse consequences were found. | Earlier studies have reported that most changes occurs during the first six months after extraction, not optimal with baseline examination six month after extraction. Large range in baseline as well as follow-up examination. No control group |
| Gragg et al. 2001 | Descriptive Case series | 116 subjects with bounded edentulous space, or BES, Mean age at extraction: 43.9 years 3 follow –up on 85 patients, 4 follow-up on 49 patients. premolars | To determine the rate of change in distance between teeth adjacent to a BES. | Intra-oral radiographs. Distance between teeth measured. Mandibular molar space reference. DBT was measured distal distance between the height of anterior abutment and the height of the posterior abutment Few cases 4 follow up. Median follow-up period: 6.4 years (> 2years). Extracted teeth 37% maxillary molars, 17% maxillary premolars, 37% mandibular molars, 9% mandibular. | The mean reduction was < 1 mm during the first year and the reduction continued to decrease at a slower rate. In a multivariable model, time since extraction and tooth type were significantly associated with distance between bounding teeth (DBT). | The findings suggest that movement of teeth adjacent to a posterior BES after the first two years is usually gradual and minor. | Time intervals between radiographs not standardized. Possible that some measured space loss is due to mesial movement of the molar as well as distal drift of the premolar. Mandibular molar space chosen as reference!! Limitations of the study: only information about absolute loss of space seen on bite-wing, but no information about translation of molar and premolars as well as tipping and rotation. Few cases 4 follow up. No control group. |

Conclusions of the literature review

The review of the literature on tooth movements and associated tissue alterations related to bone defects and edentulous areas revealed that some additional questions must still be answered. Infrabony pockets are frequently found in patients that have experienced periodontal disease. However, it has not been evaluated whether orthodontic tooth movement of teeth with plaque infected infrabony pockets may have detrimental effect on the supporting periodontal tissues. Furthermore, studies have revealed that, when a tooth is moved in the facial direction and positioned with part of its root outside the boundaries of the alveolar process, a dehiscence will be established. The question that must be addressed is whether there will be a similar occurrence if a tooth is moved into an area of reduced height of the alveolar bone, i.e. within the boundaries of the jaw. The dimensional alterations of the alveolar ridge and tooth-supporting structures, as well as adverse effects, must then be studied. With respect to physiological tooth movement (e.g. overeruption and tipping) the majority of the previous studies are descriptive without control groups and sometimes only one registration. Information in the literature on prevalence and severity in older age groups is also lacking and should be analyzed.

Aims

The aims of the studies included in the present thesis were:

- to evaluate, in an animal model, the effect on the level of connective tissue attachment of orthodontic movement of teeth with infrabony pockets (*Study I*)
- to evaluate, in an animal model, whether a tooth can be moved into an edentulous area of reduced alveolar bone height with maintained periodontal support (*Study II*)
- to analyze, in humans, dimensional alterations of the alveolar ridge and tooth-supporting structures, as well as root resorption, following orthodontic tooth movement into edentulous areas with reduced ridge dimensions (*Study III*)
- to radiographically analyze, in humans, long-term changes in (i) overeruption of unopposed molars and (ii) tipping of molars with a mesial edentulous space, and whether there is an interaction between the two events (*Study IV*)
- to analyze, in humans, whether loss of alveolar bone height might influence overeruption and tipping (*Study IV*)

Material and methods

Animal studies (Studies I and II)

Pre-experimental period

In *Study I*, the 2nd and 4th premolars were extracted in all quadrants, in four 2-year-old beagle dogs, and the extraction sites were allowed to heal for a period of 2 months. An angular bony defect with a depth corresponding to about 50 per cent of the length of the root was prepared at the mesial aspect of all the 3rd premolars and thus a two to three-wall infrabony pocket was created

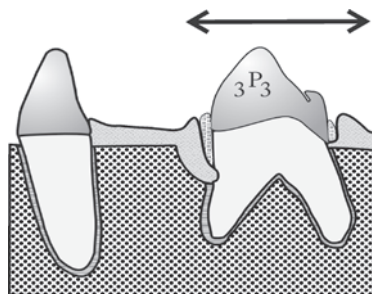


Figure 2. Schematic illustration of the experimental model in *Study I*.

(Figure 2). The exposed root surface was carefully scaled and planed, and a notch was prepared at the bottom of the angular defect. Titanium markers were then placed in the buccal cortical bone, to be used as reference points in radiographic assessments. Finally a plaque-collecting cotton floss ligature was positioned around the neck of the tooth with the ends of the ligature approaching the bottom of the bony defect and was kept for 4 weeks. After removal of the ligatures, the dogs had to accumulate plaque for an additional 2 months before the orthodontic tooth movement began. The mandibular 3rd premolars served as test teeth and the maxillary as controls and were thus not subjected to orthodontic tooth movement. No plaque control measures were carried out during the entire course of the study.

In *Study II*, the 2nd and 4th premolars were extracted in the mandible, in four 2-year-old beagle dogs, and the extraction sites were allowed to heal for a period of 2 months. The bone level was reduced in height in the region of the extracted mandibular 4th premolars, starting 2 mm distal to the 3rd premolars, to

a level corresponding to half the length of the root of the premolar (Figure 3). One tooth in each dog served as a test tooth and was orthodontically moved, while the contra lateral served as a non-moved control tooth. Titanium markers were placed in the buccal cortical bone, to be used as reference points in radiographic assessments. Tooth brushing was performed and 0.2 per cent chlorhexidine was applied twice weekly throughout the study period.

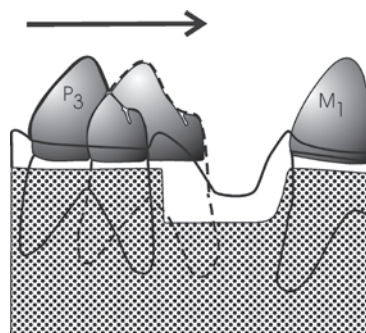


Figure 3. Schematic illustration of the experimental model in *Study II*.

Orthodontic appliance

The canine and the 1st molar on the test sides were fixed with an individually molded silver splint and served as anchorage (Figure 4). A sectional rectangular archwire (0.018 x 0.025 inch) in stainless steel went through standard tubes (0.018 x 0.025) on the 3rd premolar and the 1st molar and was attached to the silver splint distal to the canine. A closed coiled spring was applied for bodily movement of the 3rd premolar. The force used was 30 to 50 g, and activation was performed every 3rd week. The control teeth were not subjected to any orthodontic tooth movement.

Experimental period

A baseline examination including clinical and radiographic assessments was performed before, at the start of the retention period and at the end of the experiment. In *Study I* orthodontic bodily movement was performed either into or away from the angular defect, while in *Study II* movement was performed only in one direction,

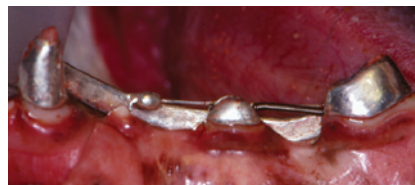

Figure 4. Orthodontic appliance used for bodily movement of the 3rd premolar.

into the area of reduced bone height. After a 5 to 6 month period of active orthodontic tooth movement, the teeth were retained in their new position for 2 months. Biopsy specimens were taken from test and control sites at the termination of the study. Following histological preparation, the biopsy material was analyzed with respect to the level of connective tissue attachment and supporting bone at the approximal sites of the 3rd premolar.

Human studies (Studies III and IV)

In *Study III*, 6 subjects (30–70 years of age, 4 females) with 10 edentulous jaw areas in the premolar/molar region with reduced alveolar ridge dimensions (Figure 5), into which a remaining premolar was planned to be orthodontically

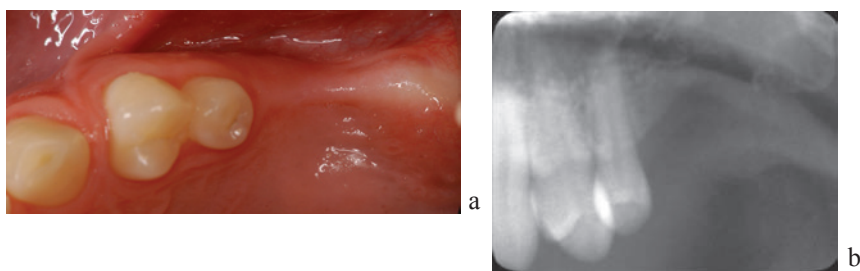


Figure 5. The alveolar ridge distal to 25, in patient 4, was reduced in width (a) as well as in height (b) before treatment.

moved, agreed to participate in the study. Descriptions of the patient sample and treatment are given in Table 5. The design of the orthodontic appliance was created according to the individual (Figure 6), but in all cases the active orthodontic treatment was performed by bodily movement of the premolar

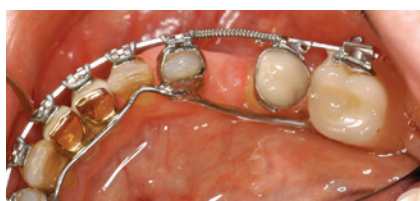

Figure 6. An example of the orthodontic appliance in subject 3. An artificial molar was attached to the lingual arch posterior to the edentulous area and served as anchorage for the buccal preadjusted fixed appliance.

along rectangular stainless steel wires into the edentulous area. The active treatment time varied between 13 and 33 months depending on the overall need of orthodontic treatment and continued until at least half of the premolar was moved into the previously edentulous area. A baseline examination including clinical and radiographic assessments,

Table 5. Patient sample characteristics

| Subject no. | Age | Gender Subj | Tooth | Treatment time (months) | Planned construction |
|-------------|-----|-------------|-------|-------------------------|----------------------|
| 1 | 48 | F | 44 | 13 | Fixed bridge |
| | | | 34 | | Fixed bridge |
| 2 | 39 | F | 45 | 45 | Space closure |
| | | | 35 | | Space closure |
| 3 | 70 | F | 44 | 16 | Fixed bridge |
| 4 | 30 | M | 15 | 35 | Implant |
| | | | 25 | | Implant |
| 5 | 34 | M | 44 | 21 | Implant |
| 6 | 55 | F | 44 | 29 | Space closure |
| | | | 34 | | Fixed bridge |

with periapical, panoramic radiographs, CT examinations and study casts, was performed before the initiation of the orthodontic movement.

The clinical and radiographic assessments were repeated at the start of the retention period and at 1-year follow-up. CT examinations were performed only at baseline and at the time of retention. Study casts were taken at baseline, at the start of the retention period and at the 1-year follow-up and subjected to 3D scanning (3Shape, Copenhagen, Denmark). Two areas were focused upon:

- (i) the edentulous area into which the tooth was orthodontically moved (*Edentulous site*)
- (ii) the newly established edentulous area from which the tooth had been orthodontically moved (*Tooth site*)

Study IV used panoramic radiographs of 292 subjects, originating from a population study of 50-year-old women in Gothenburg. Two radiographs were taken at an interval of 12 years and analyzed with regard to changes in overeruption and tipping of unopposed molars and molars facing a mesial edentulous area.

Based on the first radiographic examination 67 subjects matched the inclusion criteria. A further 35 subjects had lost the opposed and/or the adjacent tooth during the 12-year follow-up period, and the total sample consequently included 102 subjects with 169 molars.

The following assessments were made on scanned digital images of the panoramic radiographs (Agfa Snap Scan 1236 scanner; resolution of 600 dpi) by the use of a cephalometric computer program (FACAD, Illexis AB, Linköping, Sweden):

- overeruption (Figure 7)
- tooth inclination (Figure 7)
- distance of the edentulous space mesial to the molar (Figure 8)
- alveolar bone level (Figure 9)

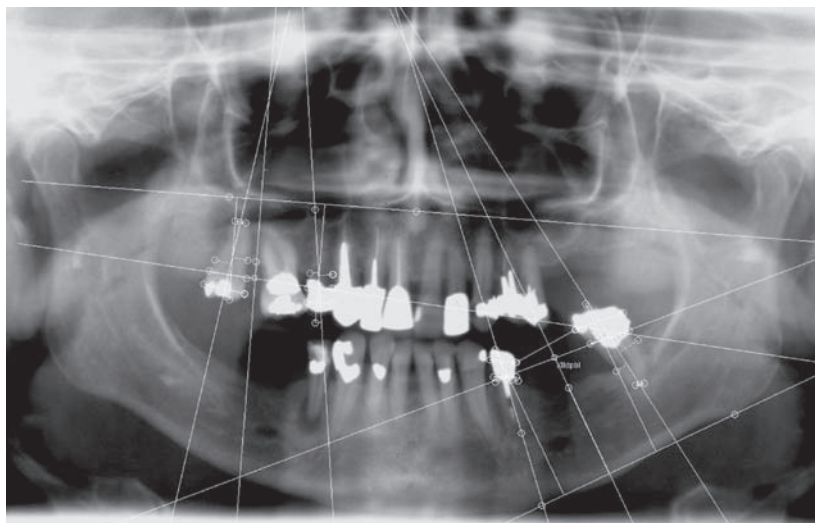


Figure 7. The angles and distances were measured in relation to maxillary and mandibular reference lines. The maxillary right and left reference lines (rciz/sp and/ or lciz/sp) were constructed from the inferior margin of the zygomatic process to the anterior nasal spine. The mandibular left and right reference lines (lgon-tan/lgn and/or rgon-tan/rgn) were constructed as a tangential line of the lower border of mandible (Larheim and Svanaes 1986).

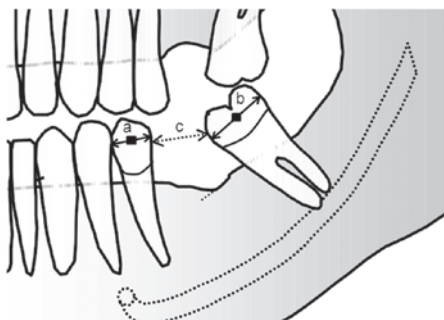


Figure 8. Distance of the edentulous space mesial to the molar; the shortest distance between the molar and the premolar. The distance is expressed in percentage of the sum of the width of the two teeth.

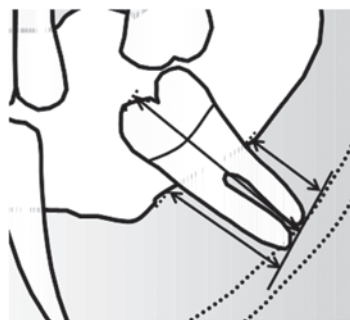


Figure 9. Alveolar bone level; measured as the distance from the marginal bone crest to the root apex at the mesial and distal aspects of the teeth and expressed in percentage of the length of the tooth. The mean values of the mesial and distal assessments were calculated.

Longitudinal changes in linear assessments between the initial and the 12-year follow-up examination were expressed in percentage. Change in tooth inclination, tipping, was calculated as the difference between the angle assessments from the two examinations. Changes in the edentulous space mesial to the molar were calculated as the difference between the ratios from the two examinations.

Statistical methods

Descriptive

Mean values, standard deviation, range and 95 per cent confidence interval were calculated in studies *I*, *II*, *III* and *IV*.

Multivariate, multilevel analysis (*Study IV*)

A regression multivariate, multilevel model (RMM-model) was constructed to analyze alterations in *Study IV* (Snijders and Bosker 1999). The model was based on data for all unopposed and opposed molars as well as molars with and without a mesial edentulous space. The two outcome variables tested in the model were changes in tooth overeruption and in tooth inclination (tipping). For testing the interaction between various variables and multiple molars in individuals, the model was employed in three steps:

- (1) regression analysis: testing covariates e.g. jaw, initial bone level and bone level change.
- (2) multivariate analysis: evaluating tipping and overeruption at the same time.
- (3) multilevel: to control for patients with more than one test tooth.

In the model, the subject represented the higher level and the outcomes the lower level. A null model without covariates was constructed as reference. The final parsimonious model included the covariates that had a statistically significant impact ($p < 0.05$) on one or both of the outcomes.

Risk analysis (*Study IV*)

Overeruption A logistic model was constructed with the probability of an overeruption of more than 10 per cent (approximately 2 mm) and 5 per cent (about 1 mm). Odds ratios were calculated for the thresholds.

Tipping A logistic model was constructed with the probability of a mesial tipping of 5 degrees or more. The odds ratio was calculated for the threshold.

Results

Study I

Probing assessments at the mesial aspect of the 3rd premolars revealed an increased pocket depth as compared with the depth at the other surfaces of the same teeth. The radiographs obtained at the start of orthodontic tooth movement showed an angular osseous defect mesial to all 3rd premolars with a depth corresponding to the probing pocket depth. The orthodontically treated teeth had been sagittally moved on an average of 5 mm.

The orthodontically moved teeth all experienced some increase in pocket depth and a certain loss of clinical attachment (Figure 10). The changes were of similar magnitude, at sites where the tooth had been moved into or away from the infrabony pocket. The variance, however, was high for both the orthodontically moved test teeth and the non moved control teeth.

Only in the case of 1 of the 4 teeth subjected to bodily movement away from the infrabony pocket, and at none of the 4 teeth, moved into and through the infrabony pocket, had the apical level of the junctional epithelium remained at the level of the notch. The amount of loss of connective tissue attachment was statistically significantly larger for the test teeth that were moved into the infrabony pocket than for the control teeth that were not moved.

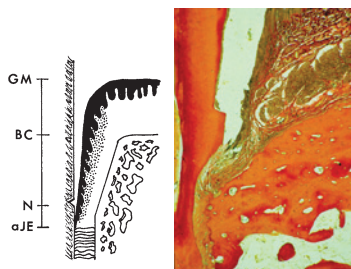


Figure 10. Specimen from a tooth orthodontically moved into the infrabony pocket. Apical level of the junctional epithelium (aJE) apical to the notch (N) indicates additional loss of connective tissue attachment.

Study II

The sagittal distance of root displacement showed a mean movement of 5.0 mm. The histometric assessments, performed at the distal aspect (*pressure* side) of the test and control teeth, revealed that none of the teeth showed a loss of connective tissue attachment. A greater distance could however, be noticed between the cemento-enamel junction and the bone crest in orthodontically moved teeth compared with that at the control (mean difference 1.10 mm). However, in all test teeth, but to a varying degree, the bone level adjacent to the root surface was more coronally positioned than the bone level created during the pre-experimental period in the edentulous area, and into which the test teeth had been orthodontically moved. The thin bone along the *pressure* side of the test teeth was not visualized in the radiographs but in the histology (Figure 11). No changes in bone height were observed on the *tension* side and no differences in pocket depth, compared to the control tooth.

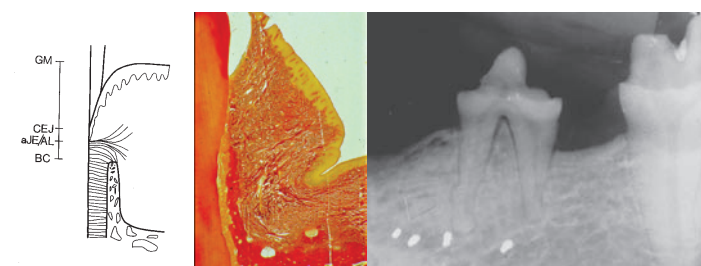


Figure 11. The thin bone on the pressure side of the test tooth was not visualized in the radiograph.

Study III

Clinical assessments

At the time of retention (Figure 12) a mean increase in the probing pocket depth (PPD) was observed at the *pressure* side, while a mean decrease was observed at the *tension* side. The gingival margin (GM) had become displaced coronally at the *pressure* side and apically at the *tension* side as well as on *buccal* and *lingual* sides.

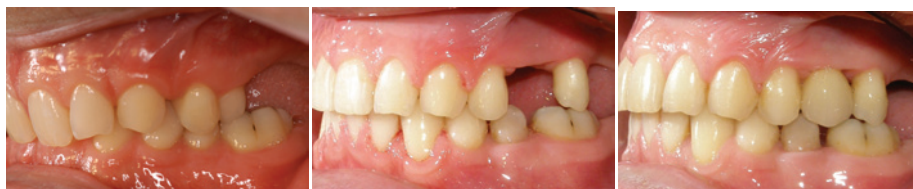

Figure 12. Subject 4: 30-year-old man. The second left premolar was distalized 6.4 mm. The final construction was an implant.

At the 1-year follow-up examination, the mean change in PPD relative to baseline was mainly reduced at the *pressure* side of the teeth. The most marked change was observed for the position of the GM, which showed a further mean apical displacement. However, the mean increase in gingival recession was predominantly related to the development of a pronounced recession in one patient (subject 2) and the variance was high mainly for the *buccal* side.

The mean gingival thickness at the buccal side of the teeth that were moved into the edentulous area showed a slight decrease at the time of retention and at 1-year follow-up. No change in the mean gingival thickness was observed at the *lingual* side, however.

Radiographic assessments

At the time of retention the distance between the marginal bone level and the cemento-enamel junction (CEJ) had increased on average more on the *pressure* side than on the *tension* side of the teeth that were moved into the edentulous area. At the final examination the mean change in the marginal bone level was of a similar magnitude on the two sides (Figure 13). At the time of retention,

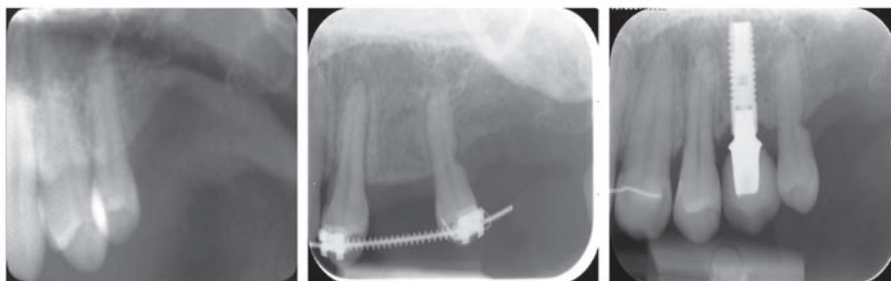


Figure 13. Periapical radiographs from baseline, retention and follow-up, subject 4. The distal lateral resorption seen at retention was more or less unchanged at follow-up.

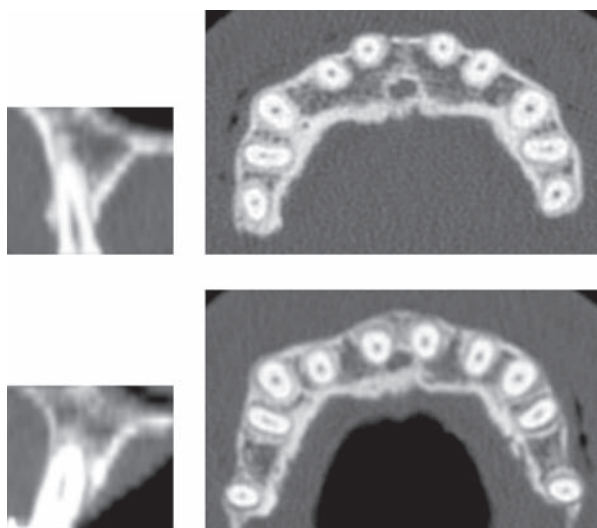


Figure 14. Axial and frontal (region 15) CT scans from baseline and at the start of retention, subject 4.

lateral resorptions were seen at all premolars on the *pressure* side, at the level of the alveolar crest, with a mean height of 3.0 mm and a mean depth of 0.7 mm (Figures 13). Apical root resorption, less than 2 mm, was observed in 4 of the 10 orthodontically moved teeth. At the 1-year follow-up the lateral resorption showed a reduction in 6 of 10 teeth, and the apical resorptions were unchanged (Figure 13).

Assessments on axial and frontal CT images showed that the tooth occupied on average approximately the same proportion (65 and 67 percent, respectively) of the width of the ridge before treatment and at the time of retention (Figure 14). This was in agreement with the observation of buccal bone dehiscence to the same extent before treatment and at the time of retention.

Study model assessments

The orthodontic movement of the premolars amounted to an average of 5.1 mm (range 3.5-6.8 mm).

Bucco-lingual assessments showed an initial mean difference between the *edentulous site* and the *tooth site* of 2 mm at a 2 mm-level from the crest

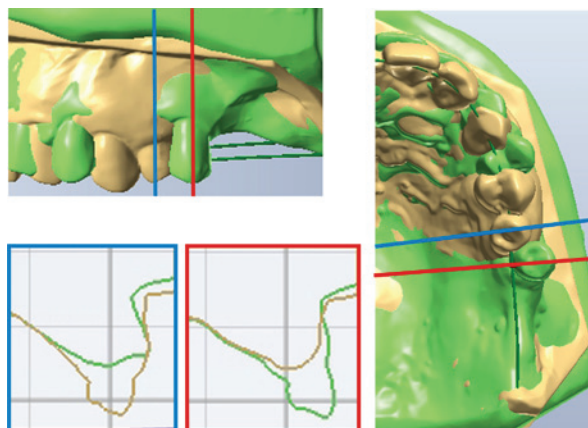


Figure 15. 3D images of study casts, subject 4, at baseline (yellow model) and at retention (green model) superimposed on each other. The blue line represents the cross section of the *tooth site* and the red line the *edentulous site*. The bucco-lingual width of the alveolar process was measured 2 and 5 mm apical to the crest level, perpendicular to the long axis of the tooth.

and 0.9 mm at a 5 mm-level from the crest, respectively (where the higher value represented the *tooth site*). After tooth movement, the mean increase was larger at the *edentulous site* than the mean reduction of the *tooth site* (Figure 15). However, at the time of the 1-year follow-up a minor reduction in the width was noted at both sites and at both levels .

Study IV

There was a statistically significant increase in overeruption of the molars, above all of the unopposed molars. The mean overeruption of the unopposed molars was 4.5 per cent, which corresponds to approximately 0.9 mm as compared to 0.4 mm for the opposed premolars (1.8 per cent). The risk for an overeruption of > 5 per cent (about 1 mm) revealed an odds ratio of 3.3 for unopposed molars, and the probability for overeruption of mandibular molars was lower than that of maxillary molars odds ratio 0.26.

The mean change in the inclination (tipping) of molars with a mesial edentulous space was 0.8 degrees (SD 5.6) and an increase of 5 degrees or more in mesial inclination (tipping) was observed in 17.9 per cent of these molars. There was no significantly higher risk for tipping of a molar with, as compared to without, a mesial edentulous space.

The multivariate, multilevel model revealed:

- a statistically significant greater overeruption for unopposed than opposed molars ($p < 0.001$) (Figure 16)
- that the degree of overeruption increased significantly with decreased initial mean alveolar bone level ($p < 0.05$) and increased mean longitudinal bone loss ($p < 0.01$) (Figures 16, 17)
- a positive correlation between overeruption and change in inclination (tipping); one unit of increase in overeruption was associated with 0.281 unit of increased tipping

The random part revealed that, in comparison to the null model, the final model reduced the variance for overeruption from 0.006 to 0.005, i.e. 18 per cent, while the variance for tipping was reduced by only 0.9 per cent. Hence, 82 per cent and > 99 per cent of the variance, respectively, remained unexplained.

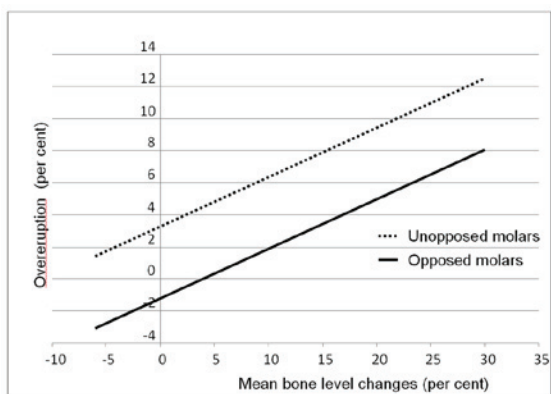


Figure 16. Final model (see text): there was a positive correlation between mean alveolar bone level changes and overeruption. Overeruption was observed regardless of whether the molar was unopposed or not.

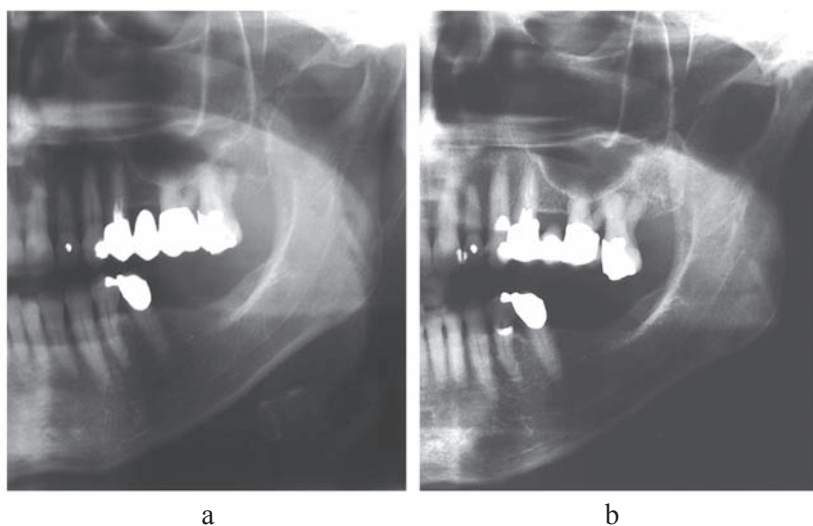


Figure 17. One of the cases of the most severe overeruption, this patient also showed a pronounced bone loss between 1968 (a) and 1981(b).

Main findings

- In the animal model, orthodontic bodily movement of teeth into, as well as away from, inflamed infrabony pockets may cause a progression of the periodontal disease.
- In the animal model, teeth orthodontically moved into an area of markedly reduced bone height maintain their supporting tissues.
- In humans, the orthodontic movement of a tooth into an edentulous area with a reduced dimension resulted in most individuals in only minor alterations in the periodontal tissues. The bucco-lingual width of the edentulous ridge increased in dimension following tooth movement into the area, and segments that became edentulous following orthodontic tooth movement showed a decreased bucco-lingual dimension. Lateral root resorption was an inevitable side effect, whereas apical root resorption was less common.
- Unopposed molars showed a statistically significant increased risk for overeruption compared to opposed teeth. Molars facing a mesial edentulous space showed a low risk for mesial tipping. There was a significant interaction between overeruption and tipping, i.e. in the presence of both conditions, an increase in overeruption was associated with tipping of the molar.
- The degree of overeruption of both unopposed and opposed molars increased significantly with decreased initial bone support and/or increased mean longitudinal bone loss.

Discussion

Methodological considerations

The experimental design used in *Study I* made it possible to establish an infrabony pocket with a subcrestal plaque-induced inflammatory lesion and to maintain this during the entire course of the study. In *Study II* the radiographic assessments revealed that bodily movement into the reduced edentulous area could be performed with no or only minimal vertical displacement of the teeth. The orthodontic appliance in *Studies I* and *II* was stable, and fulfilled the expectations of bodily movement. Periodic reproducible radiographs were taken by using a modification of the Eggen technique (Eggen 1969). In *Studies I* and *II* clinical measurements showed that the experimental teeth had been moved sagittally an average of 5 and 5.5 mm, respectively. This value agreed with the radiographic evaluation of the tooth movement in relation to the titanium markers and showed that the bodily movement had been carried out with no or only minimal displacement of the tooth position in the vertical plane or change in inclination.

In *Study III* the fixed pre-adjusted appliance with rectangular arches was individually designed sometimes in combination with lingual arches with extensions, including attached molars with tubes, to facilitate bodily movement into the edentulous area. When prosthetic restorations were performed before the 1-year follow-up registration, the position of the CEJ was transferred by using the crown height from the previous radiographs. The assessment of bone dehiscence was made on axial and frontal CT scans. However, when dehiscences and fenestrations are judged in CT- radiographs there may be an over or under-estimation due to the difficulty in identifying thin bone (Fuhrmann et al. 1995; Fuhrmann 1996; Nimigean et al. 2009). We used a 3D imaging technique of scanned study casts to measure the alterations in the dimension of the alveolar ridge. The 3D images representing two examination intervals were superimposed on stable anatomical structures (Cha et al. 2007;

Kamegawa et al. 2008; Jang et al. 2009). When almost all teeth are moved, it is important to find stable anatomical structures outside the tooth, e.g. the rugae in the maxilla and trigonum retromolare area in the mandible. The advantage of the 3D method is that it is possible to measure dimensional changes of the edentulous ridge as well as tooth movements.

Scanned digital images of panoramic radiographs were used in *Study IV*. The reference lines in the maxilla were constructed from the inferior border of the zygomatic process to the nasal spine separately for the right and left sides. The reason for using two separate reference lines and not a straight reference line in the maxilla, as in other studies (Packota et al. 1988; Xie et al. 1996; Xie et al. 1997), was to minimize the risk of distortion due to an improper patient position in the panoramic machine. To minimize the effect of variations in magnification between the radiographs, all linear variables were expressed as ratios (Packota et al. 1988; Xie et al. 1996; Stramotas et al. 2000). In addition control teeth were chosen close to the examined molar in the same quadrant which is in accordance with earlier studies (Frykholm et al. 1977; Xie et al. 1996; Catic et al. 1998), as the most reliable linear and angular measurements are those performed between neighboring structures (Frykholm et al. 1977; Tronje et al. 1981; Samawi and Burke 1984; Stramotas et al. 2000; Stramotas et al. 2002). However, an error of 5 degrees must be accepted for the angular measurements (Tronje et al. 1981).

Orthodontic tooth movement and infrabony pockets

All but one of the orthodontically moved teeth in *Study I* showed a further loss of attachment, while the control teeth had intact attachment levels. The additional loss of attachment was particularly evident when the tooth had been moved into the infrabony pocket. Previous studies have shown that, in areas with a plaque-induced suprabony lesions (gingivitis), orthodontic forces do not cause a further loss of attachment (Ericsson et al. 1978; Wennström et al. 1987). However, if a tooth is intruded or tipped, a plaque-induced suprabony lesion may shift into an infrabony lesion, with an enhanced rate of periodontal destruction as a result (Ericsson et al. 1977). The hypothesis that trauma caused

by orthodontic forces may potentiate the progression of a plaque-induced lesion positioned within an angular defect is also supported by previous experimental studies in dogs in which jiggling forces were studied (Lindhe and Svanberg 1974; Ericsson and Lindhe 1982).

Bodily movement into angular defects after elimination of the subgingival plaque was histologically studied in monkeys by Polson et al. (1984): no change in the level of connective tissue attachment occurred, but the angular defect was eliminated. Clinical case series/reports limited to clinical and/or radiographic evaluation also reported a reduced probing pocket depth and elimination of angular bone defects as an effect of orthodontic movements (Brown 1973; Ingber 1974; Wagenberg et al. 1980; Miyajima 1985; Nevins and Wise 1990; Corrente et al. 2003; Re et al. 2004; Ghezzi et al. 2008; Iino et al. 2008). On the other hand, Geraci et al. (1990) reported an experiment in monkey similar to the one by Polson et al. (1984) where after orthodontic tooth movement into an infrabony pocket, connective tissue attachment was gained. These diverging results could be explained by the different methods used to create the infrabony defects. In an animal study in foxhounds (Diedrich et al. 2003), attachment gain was also found when orthodontic treatment was combined with GTR and Emdogain.

Orthodontic tooth movement and edentulous areas

Sagittal aspects

In *Study III* the edentulous bone area was not only reduced in height but also in width, and the structure of the bone was different with more cortical bone than in *Study II*, where the bone defect was more recent and was artificially created.

None of the test or control teeth in *Study II* showed a loss of connective tissue attachment on the *pressure* side. However, a small reduction of the bone support was noted in *Study II* and *Study III*, which is in accordance with previous studies (Stepovich 1979; Hom and Turley 1984; Goldberg and Turley 1989; Diedrich et al. 1996). In *Study II* on the other hand, the bone level was more coronally situated than the initially, experimentally created level. When the supporting

bone on the *pressure* side in *Study II* was analyzed, it was obvious that the bone along the root surface was rather thin. It may thus be speculated that the bone remineralization is limited to the area of the bone that has a connection with the root through ligament fibers (the bundle bone), and a more extended retention period might have resulted in additional bone remineralization. The explanation for the different results may be that, in *Study II*, the orthodontic movement was performed inside the boundaries of the jaw while in *Study III*, the movement might to some extent have been outside the boundaries and, as in previous studies with tooth movement in the facial direction, where the root was brought out through the buccal bone plate, no remineralization took place (Steiner et al. 1981; Karring et al. 1982; Thilander et al. 1983; Wennström et al. 1987).

At the *tension* side, facing the newly formed edentulous area, the full height of the bone support was maintained in the orthodontically moved teeth in *Study II* whereas a small bone loss was noted in *Study III*, which is in accordance with Diedrich et al. (1996). No differences were found in pocket depth between test and control teeth in *Study II*, but a small reduction in pocket depth as well as width in gingival margin was noted in *Study III*.

Bucco-lingual aspects

The *bucco-lingual* aspects and dimensions were not investigated in *Study II*.

Bone resorption in edentulous areas after extractions is more pronounced *buccally* than *lingually* (Pietrokovski et al. 1976; Araujo and Lindhe 2005; Nevins et al. 2006; Reich et al. 2011), and the reduction of width is greater than the loss of height (Johnson 1969; Van der Weiden et al 2009). A sagittal tooth movement may thereby more easily result in a tooth position outside the buccal boundary of the jaw due to the narrow ridge with a reduction in dimension.

The increase in ridge dimension of the original edentulous area was about 25 per cent at the time of retention and with no changes 1 year later, which is comparable to other studies on orthodontic space closure and changes in bucco-lingual dimension (Stepovich 1979; Hom and Turley 1984;

Goldberg and Turley 1989). However, the observations might be a sign of an increase in the width of the ridge which was gained because of the width of the tooth and not by new bone formation.

The reduction of the new edentulous area was somewhat less (11 per cent at the time of retention and 15 percent 1 year after retention) than the physiologic bone resorption, of 30 per cent of the width, seen 3 months after and 50 per cent 1 year after extraction (Schropp et al. 2003). The loss of ridge dimension in a newly established edentulous area may also be related to the prevalence of bone dehiscences (Nevins et al. 2006) as the buccal bone coverage in these subjects is very thin. Dehiscences and fenestrations vary however in frequency and localization between different subject samples (Rupprecht et al. 2001). In the present study, the number of dehiscences was more or less unchanged during the study. This may perhaps have been an over or under-estimation according to Fuhrmann et al. (1995), who compared buccal defects on skulls with their CT images: not all bone defects could be seen on the CT images and not all defects seen on the CT images were found on the skulls.

The observed mean increase in soft tissue recession was mainly attributed to a marked recession developed in one patient who had a thin alveolar process. The risk for development of recession defects in conjunction with orthodontic tooth movement has been suggested to increase when the tooth is moved out of the alveolar bone housing (Wennström 1996). Furthermore a relationship between development of soft tissue recession and a thin gingival biotype, pre-treatment presence of recession as well as gingival inflammation has been shown (Melsen and Allais 2005; Yared et al. 2006).

Root resorption

Lateral resorptions were seen at the level of the alveolar crest in all teeth at the pressure side in *Study III* which is a higher prevalence than has previously been reported (Diedrich et al. 1996). Root resorptions were also seen in *Study II*, but not specifically at the level of the marginal crest. A possible explanation for this is that the bony defects in the experimental study were more recent, and

compact bone had not yet developed on the alveolar ridges as in the clinical study, where the ridge resorption was physiological. In *Study III* the youngest man with the longest duration of treatment experienced the greatest cervical resorption while the oldest woman with the shortest duration of treatment and approximately the same distance of tooth movement experienced the smallest cervical resorption. These results are in agreement with Baumrind et al. (1996) and Ren et al. (2008), who found that root resorption was positively correlated to treatment time and more common in men than women but was not correlated to age. Although root resorption is an undesirable side effect of orthodontic treatment, studies have shown a great potential for repair following termination of active tooth movement (Brudvik and Rygh 1995; Owman-Moll and Kuroil 1998; Fritz et al. 2005; Jimenez-Pellegrin and Arana-Chavez 2007, Cheng et al. 2010).

Physiological tooth movement into edentulous areas

Overeruption/tipping/drift

In *Study IV* unopposed molars showed a significantly increased risk for overeruption, whereas molars facing a mesial edentulous space, as a consequence of tooth extraction, experienced a low risk of tipping. Kiliaridis et al. (2000) and Shugars et al. (2000) also reported small changes where lost posterior teeth were not replaced. A dental stability/equilibrium (Proffit 1978) may already have become established before the start of the observation period, since a majority of the cases presented an edentulous space at the initial examination. There was a significant interaction between overeruption and tipping, which indicates that a change in occlusal loading might cause tipping of the tooth, in agreement with findings in study casts by Kiliaridis et al. (2000) and Christou and Kiliaridis (2007). The degree of overeruption also increased significantly with decreased initial bone support and increased mean longitudinal bone loss at the tooth, which may indicate that the development of periodontal disease prejudices tooth elongation. This is in concurrence with findings by Compagnon and Woda (1991), Christou and Kiliaridis (2007) and Fujita et al. (2010). However, overeruption changes of 2 mm or more were

seen in only about 21 per cent and there was no sign of overeruption in 22 per cent of the unopposed molars, these values are similar to findings by Kiliaridis et al. (2000) and indicate that in some individuals overeruption may cause an increased risk of occlusal interferences and changes in the dental equilibrium (Weinstein 1967; Proffit 1978; Ramfjord and Ash 1983; Craddock and Youngson 2004; Craddock 2008).

Opposed molars also showed a tendency toward overeruption that might be related to occlusal wear and continuous tooth eruption (Craddock et al. 2007). Studies in the literature report such a phenomenon in young animals (Fujita et al. 2009) and subjects below 50 years of age (Behrents 1985; Forsberg et al. 1991; Tallgren and Solow 1991; Thilander 2009) but to our knowledge, there is limited information available in the literature on continuous tooth eruption of posterior teeth in older individuals (≥ 50 years).

The mean reduction of the edentulous space mesial to the molar was larger in the maxilla than in the mandible and may be due to changes in the inclination of the molar and the premolar as well as migration of the teeth adjacent to the edentulous area (Kaplan 1985; Witter et al. 1987; Shugars et al. 2000; Craddock et al. 2007). There was no correlation between tipping, initial bone level or changes in mean bone level, which is in accordance with Lundgren et al. (1992) who did not find any significant differences between tipped and upright molars regarding initiation or aggravation of moderate periodontal breakdown.

Tipping changes in molars facing a mesial edentulous space was not common in this study. The incidence of mesial tipping ≥ 5 degrees was 18 per cent and only 1 of 112 molars had tipped more than 15 degrees. These findings agree in part with, Kiliaridis et al. (2000) and Craddock et al. (2007), who found no tipping in the majority of the observed molars, but these studies reported tipping over 15 degrees to be more frequent for both jaws and more severe in the mandible. However both the studies by Craddock et al. (2007) and Kiliaridis et al. (2000) had only one registration, and the inclusion criteria were restricted to unopposed molars.

Conclusion and future considerations

It has been suggested in the literature that angular bony defects can be eliminated by orthodontic means. Such treatment will however not improve the level of connective tissue attachment. To the contrary, the orthodontic treatment in combination with periodontal disease will increase the rate of periodontal tissue destruction.

The experimental study in dogs showed that a tooth with normal periodontal support could be moved into an edentulous area with artificially reduced bone height without loss of the supporting tissues. However, in the clinical situation when teeth were moved into edentulous ridges with reduced dimensions, minor alterations in the periodontal tissues were found and lateral root resorption was an inevitable adverse effect, which must be considered.

Conditions for implant placement might be achieved by moving an adjacent tooth into an edentulous area and placing the implant in the former position of the tooth, as an alternative to ridge augmentation by grafting.

Few subjects in the age group above 50 years may need restorative therapy for the loss of a posterior tooth in order to prevent a potential future occlusal interference. However, the clinician should be aware that compromised periodontal support might pose an increased risk for overeruption/tipping.

In the future, more studies on the effects of orthodontic treatment and tissue reactions in the adult population that use adequate comparison groups would be desirable. Further studies should also focus on finding factors that can identify individuals with a risk for severe overeruption and a potential need of restorative therapy to stabilize the occlusion.

References

- Ahlgvist, M., C. Bengtsson, et al. (1999). Dental status of women in a 24-year longitudinal and cross-sectional study. Results from a population study of women in Goteborg. *Acta Odontol Scand* 57(3): 162-167.
- Alstad, S. and B. U. Zachrisson (1979). Longitudinal study of periodontal condition associated with orthodontic treatment in adolescents. *Am J Orthod* 76(3): 277-286.
- Araujo, M. G. and J. Lindhe (2005). Dimensional ridge alterations following tooth extraction. An experimental study in the dog. *J Clin Periodontol* 32(2): 212-218.
- Artun, J. and K. S. Urbye (1988). The effect of orthodontic treatment on periodontal bone support in patients with advanced loss of marginal periodontium. *Am J Orthod Dentofacial Orthop* 93(2): 143-148.
- Atwood, D. A. (2001). Some clinical factors related to rate of resorption of residual ridges. 1962. *J Prosthet Dent* 86(2): 119-125.
- Bartold, P. M. and A. S. Narayanan (2006). Molecular and cell biology of healthy and diseased periodontal tissues. *Periodontol* 2000 40: 29-49.
- Batenhorst, K. F., G. M. Bowers, et al. (1974). Tissue changes resulting from facial tipping and extrusion of incisors in monkeys. *J Periodontol* 45(9): 660-668.
- Baumrind, S., E. L. Korn, et al. (1996). Apical root resorption in orthodontically treated adults. *Am J Orthod Dentofacial Orthop* 110(3): 311-320.
- Behrents, R. G., Ed. (1985). An atlas of growth in the aging craniofacial skeleton. Craniofacial growth series. Ann Arbor : The university of Michigan, Center for human growth and development.
- Bernard, J. P., J. P. Schatz, et al. (2004). Long-term vertical changes of the anterior maxillary teeth adjacent to single implants in young and mature adults. A retrospective study. *J Clin Periodontol* 31(11): 1024-1028.
- Bollen, A. M., J. Cunha-Cruz, et al. (2008). The effects of orthodontic therapy on periodontal health: a systematic review of controlled evidence. *J Am Dent Assoc* 139(4): 413-422.

- Bondemark, L. (1998). Interdental bone changes after orthodontic treatment: a 5-year longitudinal study. *Am J Orthod Dentofacial Orthop* 114(1): 25-31.
- Boyd, R. L., P. J. Leggott, et al. (1989). Periodontal implications of orthodontic treatment in adults with reduced or normal periodontal tissues versus those of adolescents. *Am J Orthod Dentofacial Orthop* 96(3): 191-198.
- Brown, I. S. (1973). The effect of orthodontic therapy on certain types of periodontal defects. I. Clinical findings. *J Periodontol* 44(12): 742-756.
- Brudvik, P. and P. Rygh (1994). Multi-nucleated cells remove the main hyalinized tissue and start resorption of adjacent root surfaces. *Eur J Orthod* 16(4): 265-273.
- Brudvik, P. and P. Rygh (1994). Root resorption beneath the main hyalinized zone. *Eur J Orthod* 16(4): 249-263.
- Brudvik, P. and P. Rygh (1995). The repair of orthodontic root resorption: an ultrastructural study. *Eur J Orthod* 17(3): p. 189-98.
- Cardaropoli, D., S. Re, et al. (2006). Bio-Oss collagen and orthodontic movement for the treatment of infrabony defects in the esthetic zone. *Int J Periodontics Restorative Dent* 26(6): 553-559.
- Catic, A., A. Celebic, et al. (1998). Evaluation of the precision of dimensional measurements of the mandible on panoramic radiographs. *Oral Surg Oral Med Oral Pathol Oral Radiol Endod* 86(2): 242-248.
- Cattaneo, P. M., M. Dalstra, et al. (2005). The finite element method: a tool to study orthodontic tooth movement. *J Dent Res* 84(5): 428-433.
- Cattaneo, P. M., M. Dalstra, et al. (2008). Moment-to-force ratio, center of rotation, and force level: a finite element study predicting their interdependency for simulated orthodontic loading regimens. *Am J Orthod Dentofacial Orthop* 133(5): 681-689.
- Cattaneo, P. M., M. Dalstra, et al. (2009). Strains in periodontal ligament and alveolar bone associated with orthodontic tooth movement analyzed by finite element. *Orthod Craniofac Res* 12(2): 120-128.
- Cha, B. K., J. Y. Lee, et al. (2007). Analysis of tooth movement in extraction cases using three-dimensional reverse engineering technology. *Eur J Orthod* 29(4): 325-331.

Cheng, et al. Repair of root resorption 4 and 8 weeks after application of continuous light and heavy forces on premolars for 4 weeks: A histology study. *Am J Orthod Dentofacial Orthop* 138(6): p. 727-34.

Christou, P. and S. Kiliaridis (2007). Three-dimensional changes in the position of unopposed molars in adults. *Eur J Orthod* 29(6): 543-549.

Cirelli, C. C., J. A. Cirelli, et al. (2003). Orthodontic movement of teeth with intraosseous defects: Histologic and histometric study in dogs. *Am J Orthod Dentofacial Orthop* 123(6): 666-673; discussion 673-665.

Compagnon, D. and A. Woda (1991). Supraeruption of the unopposed maxillary first molar. *J Prosthet Dent* 66(1): 29-34.

Corrente, G., R. Abundo, et al. (2003). Orthodontic movement into infrabony defects in patients with advanced periodontal disease: a clinical and radiological study. *J Periodontol* 74(8): 1104-1109.

Craddock, H. L. (2008). Occlusal changes following posterior tooth loss in adults. Part 3. A study of clinical parameters associated with the presence of occlusal interferences following posterior tooth loss. *J Prosthodont* 17(1): 25-30.

Craddock, H. L. and C. C. Youngson (2004). A study of the incidence of overeruption and occlusal interferences in unopposed posterior teeth. *Br Dent J* 196(6): 341-348; discussion 337.

Craddock, H. L., C. C. Youngson, et al. (2007). Occlusal changes following posterior tooth loss in adults. Part 1: a study of clinical parameters associated with the extent and type of supraeruption in unopposed posterior teeth. *J Prosthodont* 16(6): 485-494.

Craddock, H. L., C. C. Youngson, et al. (2007). Occlusal changes following posterior tooth loss in adults. Part 2. Clinical parameters associated with movement of teeth adjacent to the site of posterior tooth loss. *J Prosthodont* 16(6): 495-501.

Diedrich, P., U. Fritz, et al. (2003). Movement of periodontally affected teeth after guided tissue regeneration (GTR)--an experimental pilot study in animals. *J Orofac Orthop* 64(3): 214-227.

Diedrich, P. R., R. A. Fuhrmann, et al. (1996). Distal movement of premolars to provide posterior abutments for missing molars. *Am J Orthod Dentofacial Orthop* 109(4): 355-360.

Eggen, S. (1969). Standardiserad intraoral röntgenteknik. Sveriges Tandläkareförbunds Tidning (17): 867-872.

Eliasson, L. A., A. Hugoson, et al. (1982). The effects of orthodontic treatment on periodontal tissues in patients with reduced periodontal support. Eur J Orthod 4(1): 1-9.

Engelking, G. and B.U. Zachrisson (1982). Effects of incisor repositioning on monkey periodontium after expansion through the cortical plate. Am J Orthod, . 82(1): 23-32.

Ericsson, I. and J. Lindhe (1982). Effect of longstanding jiggling on experimental marginal periodontitis in the beagle dog. J Clin Periodontol 9(6): 497-503.

Ericsson, I. and J. Lindhe (1993). Probing depth at implants and teeth. An experimental study in the dog. J Clin Periodontol 20(9): 623-627.

Ericsson, I. and B. Thilander (1980). Orthodontic relapse in dentitions with reduced periodontal support: an experimental study in dogs. Eur J Orthod 2(1): 51-57.

Ericsson, I., B. Thilander, et al. (1978). Periodontal conditions after orthodontic tooth movements in the dog. Angle Orthod 48(3): 210-218.

Ericsson, I., B. Thilander, et al. (1977). The effect of orthodontic tilting movements on the periodontal tissues of infected and non-infected dentitions in dogs. J Clin Periodontol 4(4): 278-293.

Field, C., I. Ichim, et al. (2009). Mechanical responses to orthodontic loading: a 3-dimensional finite element multi-tooth model. Am J Orthod Dentofacial Orthop 135(2): 174-181.

Forsberg, C. M., S. Eliasson, et al. (1991). Face height and tooth eruption in adults--a 20-year follow-up investigation. Eur J Orthod 13(4): 249-254.

Fowler, C., S. Garrett, et al. (1982). Histologic probe position in treated and untreated human periodontal tissues. J Clin Periodontol 9(5): 373-385.

Fritz, U., I. Rudzki-Janson, et al. (2005). Light microscopic and SEM findings after orthodontic treatment--analysis of a human specimen. J Orofac Orthop 66(1): 39-53.

Frykholm, A., O. Malmgren, et al. (1977). Angular measurements in orthopantomography. Dentomaxillofac Radiol 6(2): 77-81.

- Fuhrmann, R. (1996). Three-dimensional interpretation of periodontal lesions and remodeling during orthodontic treatment. Part III. *J Orofac Orthop* 57(4): 224-237.
- Fuhrmann, R. A., H. Wehrbein, et al. (1995). Assessment of the dentate alveolar process with high resolution computed tomography. *Dentomaxillofac Radiol* 24(1): 50-54.
- Fujita, T., X. Montet, et al. (2009). Supraposition of unopposed molars in young and adult rats. *Arch Oral Biol* 54(1): 40-44.
- Fujita, T., X. Montet, et al. (2010). Overeruption of periodontally affected unopposed molars in adult rats. *J Periodontal Res* 45(2): 271-276.
- Geraci, T. F., M. Nevins, et al. (1990). Reattachment of the periodontium after tooth movement into an osseous defect in a monkey. 1. *Int J Periodontics Restorative Dent* 10(3): 184-197.
- Gesch, D., O. Bernhardt, et al. (2004). Association of malocclusion and functional occlusion with temporomandibular disorders (TMD) in adults: a systematic review of population-based studies. *Quintessence Int* 35(3): 211-221.
- Ghezzi, C., S. Masiero, et al. (2008). Orthodontic treatment of periodontally involved teeth after tissue regeneration. *Int J Periodontics Restorative Dent* 28(6): 559-567.
- Gkantidis, N., P. Christou, et al. (2010). The orthodontic-periodontic interrelationship in integrated treatment challenges: a systematic review. *J Oral Rehabil* 37(5): 377-390.
- Goldberg, D. and P. K. Turley (1989). Orthodontic space closure of the edentulous maxillary first molar area in adults. *Int J Adult Orthodon Orthognath Surg* 4(4): 255-266.
- Gragg, K. L., D. A. Shugars, et al. (2001). Movement of teeth adjacent to posterior bounded edentulous spaces. *J Dent Res* 80(11): 2021-2024.
- Grimes, D. A. and K. F. Schulz (2002). An overview of clinical research: the lay of the land. *Lancet* 359(9300): 57-61.
- Hamp, S. E., F. Lundström, et al. (1982). Periodontal conditions in adolescents subjected to multiband orthodontic treatment with controlled oral hygiene. *Eur J Orthod* 4(2): 77-86.

Heij, D. G., H. Opdebeeck, et al. (2006). Facial development, continuous tooth eruption, and mesial drift as compromising factors for implant placement. *Int J Oral Maxillofac Implants* 21(6): 867-878.

Hollender, L., A. Rönnerman, et al. (1980). Root resorption, marginal bone support and clinical crown length in orthodontically treated patients. *Eur J Orthod* 2(4): 197-205.

Hom, B. M. and P. K. Turley (1984). The effects of space closure of the mandibular first molar area in adults. *Am J Orthod* 85(6): 457-469.

Hugoson, A., G. Koch, et al. (2005). Oral health of individuals aged 3-80 years in Jonkoping, Sweden during 30 years (1973-2003). I. Review of findings on dental care habits and knowledge of oral health. *Swed Dent J* 29(4): 125-138.

Hugoson, A., B. Sjödin, et al. (2008). Trends over 30 years, 1973-2003, in the prevalence and severity of periodontal disease. *J Clin Periodontol* 35(5): 405-414.

Iino, S., K. Taira, et al. (2008). Isolated vertical infrabony defects treated by orthodontic tooth extrusion. *Angle Orthod* 78(4): 728-736.

Ingber, J. S. (1974). Forced eruption. I. A method of treating isolated one and two wall infrabony osseous defects--rationale and case report. *J Periodontol* 45(4): 199-206.

Ingber, J. S. (1976). Forced eruption: part II. A method of treating nonrestorable teeth--Periodontal and restorative considerations. *J Periodontol* 47(4): 203-216.

Iseri, H. and B. Solow (1996). Continued eruption of maxillary incisors and first molars in girls from 9 to 25 years, studied by the implant method. *Eur J Orthod* 18(3): 245-256.

Jang, I., M. Tanaka, et al. (2009). A novel method for the assessment of three-dimensional tooth movement during orthodontic treatment. *Angle Orthod* 79(3): 447-453.

Janson, G., R. Bombonatti, et al. (2003). Comparative radiographic evaluation of the alveolar bone crest after orthodontic treatment. *Am J Orthod Dentofacial Orthop* 124(2): 157-164.

Jemt, T., G. Ahlberg, et al. (2007). Tooth movements adjacent to single-implant restorations after more than 15 years of follow-up. *Int J Prosthodont* 20(6): 626-632.

Jimenez-Pellegrin, C. and V. E. Arana-Chavez (2007). Root resorption repair in mandibular first premolars after rotation. A transmission electron microscopy analysis combined with immunolabeling of osteopontin. *Am J Orthod Dentofacial Orthop* 132(2): 230-236.

Johnson, K. (1969). A study of the dimensional changes occurring in the maxilla following closed face immediate denture treatment. *Aust Dent J* 14(6): 370-376.

Kamegawa, M., M. Nakamura, et al. (2008). 3D morphological measurements of dental casts with occlusal relationship using microfocus X-ray CT. *Dent Mater J* 27(4): 549-554.

Kaplan, P. (1985). Drifting, tipping, supraeruption, and segmental alveolar bone growth. *J Prosthet Dent* 54(2): 280-283.

Karring, T., S. Nyman, et al. (1982). Bone regeneration in orthodontically produced alveolar bone dehiscences. *J Periodontal Res* 17(3): 309-315.

Kiliaridis, S., I. Lyka, et al. (2000). Vertical position, rotation, and tipping of molars without antagonists. *Int J Prosthodont* 13(6): 480-486.

Kvam, E. (1969). A study of the cell-free zone following experimental tooth movement in the rat. *Rep Congr Eur Orthod Soc*: 419-434.

Kvam, E. (1972). Cellular dynamics on the pressure side of the rat periodontium following experimental tooth movement. *Scand J Dent Res* 80(5): 369-383.

Larheim, T.A. and D.B. Svanaes (1986). Reproducibility of rotational panoramic radiography: mandibular linear dimensions and angles. *Am J Orthod Dentofacial Orthop* 90(1): 45-51.

Lindhe, J. and G. Svanberg (1974). Influence of trauma from occlusion on progression of experimental periodontitis in the beagle dog. *J Clin Periodontol* 1(1): 3-14.

Listgarten, M. A. (1980). Periodontal probing: what does it mean? *J Clin Periodontol* 7(3): 165-176.

Love, W. D. and R. L. Adams (1971). Tooth movement into edentulous areas. *J Prosthet Dent* 25(3): 271-278.

Lundgren, D., J. Kürol, et al. (1992). Periodontal conditions around tipped and upright molars in adults. An intra-individual retrospective study. *Eur J Orthod* 14(6): 449-455.

- Lundström, F., S. E. Hamp, et al. (1980). Systematic plaque control in children undergoing long-term orthodontic treatment. *Eur J Orthod* 2(1): 27-39.
- Martinez-Canut, P., A. Carrasquer, et al. (1997). A study on factors associated with pathologic tooth migration. *J Clin Periodontol* 24(7): 492-497.
- Meikle, M. C. (2006). The tissue, cellular, and molecular regulation of orthodontic tooth movement: 100 years after Carl Sandstedt. *Eur J Orthod* 28(3): 221-240.
- Melsen B (1991). Limitations in adult orthodontics. In: *Current controversies in orthodontics*. Melsen B, editor. Chicago: Quintessence:147-180.
- Melsen, B. and D. Allais (2005). Factors of importance for the development of dehiscences during labial movement of mandibular incisors: a retrospective study of adult orthodontic patients. *Am J Orthod Dentofacial Orthop* 127(5): 552-561; quiz 625.
- Miyajima, K. (1985). Root realignment in furcation-involved teeth. *J Clin Orthod* 19(7): 490-495.
- Modoni, D., M. Modoni, et al. (2009). Treatment of an isolated Vertical Infrabony Defect with Orthodontic extrusion. *Journal of Clinical Orthodontics XLIII(7)*: 453-458.
- Mohlin, B., S. Axelsson, et al. (2007). TMD in relation to malocclusion and orthodontic treatment. *Angle Orthod* 77(3): 542-548.
- Moss, J. P. and D. C. Picton (1972). The migration of teeth in adult monkeys. *Trans Eur Orthod Soc*: 443-451.
- Nemcovsky, C. E., L. Beny, et al. (2004). Bone apposition in surgical bony defects following orthodontic movement: a comparative histomorphometric study between root- and periodontal ligament-damaged and periodontally intact rat molars. *J Periodontol* 75(7): 1013-1019.
- Nemcovsky, C. E., M. Sasson, et al. (2007). Periodontal healing following orthodontic movement of rat molars with intact versus damaged periodontia towards a bony defect. *Eur J Orthod* 29(4): 338-344.
- Nevins, M., M. Camelo, et al. (2006). A study of the fate of the buccal wall of extraction sockets of teeth with prominent roots. *Int J Periodontics Restorative Dent* 26(1): 19-29.

- Nevins, M. and R. J. Wise (1990). Use of orthodontic therapy to alter infrabony pockets. 2. *Int J Periodontics Restorative Dent* 10(3): 198-207.
- Nimigean, V. R., V. Nimigean, et al. (2009). Alveolar bone dehiscences and fenestrations: an anatomical study and review. *Rom J Morphol Embryol* 50(3): 391-397.
- Nyman, S., T. Karring, et al. (1982). Bone regeneration in alveolar bone dehiscences produced by jiggling forces. *J Periodontal Res* 17(3): 316-322.
- Odenrick, L., E. L. Karlander, et al. (1991). Surface resorption following two forms of rapid maxillary expansion. *Eur J Orthod* 13(4): 264-270.
- Ogihara, S. and M. H. Marks (2006). Enhancing the regenerative potential of guided tissue regeneration to treat an intrabony defect and adjacent ridge deformity by orthodontic extrusive force. *J Periodontol* 77(12): 2093-2100.
- Ogihara, S. and H. L. Wang (2010). Periodontal regeneration with or without limited orthodontics for the treatment of 2- or 3-wall infrabony defects. *J Periodontol* 81(12): 1734-1742.
- Owin, K. and P. Diedrich (1990). [Changes in periodontal parameters during orthodontic treatment]. *Dtsch Zahnarztl Z* 45(2): 109-112.
- Owman-Moll, P., J. Kürol, et al. (1996). The effects of a four-fold increased orthodontic force magnitude on tooth movement and root resorptions. An intra-individual study in adolescents. *Eur J Orthod* 18(3): 287-294.
- Owman-Moll, P. and J. Kurol (1998). The early reparative process of orthodontically induced root resorption in adolescents--location and type of tissue. *Eur J Orthod*. 20(6): p. 727-32.
- Packota, G. V., J. N. Hoover, et al. (1988). A study of the height of intact alveolar bone on panoramic radiographs of adult patients. *J Prosthet Dent* 60(4): 504-509.
- Petridis, H. P., N. Tsiggos, et al. (2010). Three-dimensional positional changes of teeth adjacent to posterior edentulous spaces in relation to age at time of tooth loss and elapsed time. *Eur J Prosthodont Restor Dent* 18(2): 78-83.
- Petrokovski, J. and M. Massler (1967). Alveolar ridge resorption following tooth extraction. *J Prosthet Dent* 17(1): 21-27.
- Petrokovski, J., S. Sorin, et al. (1976). The residual ridge in partially edentulous patients. *J Prosthet Dent* 36(2): 150-158.

- Polson, A., J. Caton, et al. (1984). Periodontal response after tooth movement into intrabony defects. *J Periodontol* 55(4): 197-202.
- Polson, A. M. and B. E. Reed (1984). Long-term effect of orthodontic treatment on crestal alveolar bone levels. *J Periodontol* 55(1): 28-34.
- Polson, A. M. and H. A. Zander (1983). Effect of periodontal trauma upon intrabony pockets. *J Periodontol* 54(10): 586-591.
- Proffit, W. R. (1978). Equilibrium theory revisited: factors influencing position of the teeth. *Angle Orthod* 48(3): 175-186.
- Ramfjord, S. P. and M. M. Ash (1983). *Occlusion*. Philadelphia, WB Saunders 1983.
- Re, S., D. Cardaropoli, et al. (2004). Reduction of gingival recession following orthodontic intrusion in periodontally compromised patients. *Orthod Craniofac Res* 7(1): 35-39.
- Reich, K. M., C. D. Huber, et al. (2011). Atrophy of the residual alveolar ridge following tooth loss in an historical population. *Oral Dis* 17(1): 33-44.
- Ren, Y., J. C. Maltha, et al. (2003). "Optimum force magnitude for orthodontic tooth movement: a systematic literature review." *Angle Orthod* 73(1): 86-92.
- Ren, Y., J. C. Maltha, et al. (2008). "Age-related changes of periodontal ligament surface areas during force application." *Angle Orthod* 78(6): 1000-1005
- Ren, Y., J. C. Maltha, et al. (2008). Age-dependent external root resorption during tooth movement in rats. *Acta Odontol Scand* 66(2): 93-98.
- Rinchuse, D. J. and S. Kandasamy (2005). Evidence-based versus experience-based views on occlusion and TMD. *Am J Orthod Dentofacial Orthop* 127(2): 249-254.
- Rönnerman, A., B. Thilander, et al. (1980). Gingival tissue reactions to orthodontic closure of extraction sites. Histologic and histochemical studies. *Am J Orthod* 77(6): 620-625.
- Rotundo, R., T. Bassarelli, et al. (2011). Orthodontic treatment of periodontal defects. Part II: a systematic review on human and animal studies. *Progress in Orthodontics*(12): 45-52.

- Rupprecht, R. D., G. M. Horning, et al. (2001). Prevalence of dehiscences and fenestrations in modern American skulls. *J Periodontol* 72(6): 722-729.
- Rygh, P. (1973). Ultrastructural changes in pressure zones of human periodontium incident to orthodontic tooth movement. *Acta Odontol Scand.* 31(2): 109-22.
- Rygh, P. (1977). Orthodontic root resorption studied by electron microscopy. *Angle Orthod*, 1977. 47(1): 1-16.
- Rygh, P., K. Bowling, et al. (1986). Activation of the vascular system: a main mediator of periodontal fiber remodeling in orthodontic tooth movement. *Am J Orthod* 89(6): 453-468.
- Samawi, S. S. and P. H. Burke (1984). Angular distortion in the orthopantomogram. *Br J Orthod* 11(2): 100-107.
- SBU (2005). *Bettavvikelser och tandreglering i ett hälsoperspektiv. En systematisk litteraturöversikt.* Stockholm: Statens beredning för medicinsk utvärdering (SBU). SBU-rapport nr 176. ISBN 91-85413-06-2.
- Schroeder, H. (1986). *Handbook of microscopic anatomy: The Periodontium.* Berlin, Springer-Verlag Berlin Heidelberg New York Tokyo 1986.
- Schropp, L., A. Wenzel, et al. (2003). Bone healing and soft tissue contour changes following single-tooth extraction: a clinical and radiographic 12-month prospective study. *Int J Periodontics Restorative Dent* 23(4): 313-323.
- Shugars, D. A., J. D. Bader, et al. (2000). The consequences of not replacing a missing posterior tooth. *J Am Dent Assoc* 131(9): 1317-1323.
- Sjölien, T. and B. U. Zachrisson (1973). Periodontal bone support and tooth length in orthodontically treated and untreated persons. *Am J Orthod* 64(1): 28-37.
- Smith, R. (1996). The effects of extracting upper second permanent molars on lower second permanent molar position. *Br J Orthod* 23(2): 109-114.
- Snijders, T.A.B. and R.J. Bosker (1999). *Multilevel analysis: an introduction to basic and advanced multilevel modeling.* Thousand Oaks, California: London: SAGE.
- Steiner, G. G., J. K. Pearson, et al. (1981). Changes of the marginal periodontium as a result of labial tooth movement in monkeys. *J Periodontol* 52(6): 314-320.

Stepovich, M. L. (1979). A clinical study on closing edentulous spaces in the mandible. *Angle Orthod* 49(4): 227-233.

Stramotas, S., J. P. Geenty, et al. (2000). The reliability of crown-root ratio, linear and angular measurements on panoramic radiographs. *Clin Orthod Res* 3(4): 182-191.

Stramotas, S., J. P. Geenty, et al. (2002). Accuracy of linear and angular measurements on panoramic radiographs taken at various positions in vitro. *Eur J Orthod* 24(1): 43-52.

Tallgren, A. and B. Solow (1991). Age differences in adult dentoalveolar heights. *Eur J Orthod* 13(2): 149-156.

Thilander, B. (2009). Dentoalveolar development in subjects with normal occlusion. A longitudinal study between the ages of 5 and 31 years. *Eur J Orthod* 31(2): 109-120.

Thilander, B., S. Nyman, et al. (1983). Bone regeneration in alveolar bone dehiscences related to orthodontic tooth movements. *Eur J Orthod* 5(2): 105-114.

Thilander, B., J. Odman, et al. (2001). Orthodontic aspects of the use of oral implants in adolescents: a 10-year follow-up study. *Eur J Orthod* 23(6): 715-731.

Thilander, B., P. Rygh, et al. (2000). Tissue Reactions in Orthodontics. *Orthodontics Current Principles and Techniques*. T. M. V. Graber, Jr, R.L. St Louis, Missouri 63146, Mosby: 117-192.

Thilander, B. L. (1992). Complications of orthodontic treatment. *Curr Opin Dent* 2: 28-37.

Thompson, J. L., Jr. and G. S. Kendrick (1964). Changes in the vertical dimensions of the human male skull during the third and fourth decades of life. *Anat Rec* 150: 209-213.

Topoll, H. H., D. E. Lange, et al. (1990). [The effects of orthodontic treatment on periodontal findings in adults]. *Dtsch Zahnarztl Z* 45(2): 116-118.

Tronje, G., U. Welander, et al. (1981). Image distortion in rotational panoramic radiography. III. Inclined objects. *Acta Radiol Diagn (Stockh)* 22(5): 585-592.

Waerhaug, J. (1979). The infrabony pocket and its relationship to trauma from occlusion and subgingival plaque. *J Periodontol* 50(7): 355-365.

Wagenberg, B. D., R. N. Eskow, et al. (1980). Orthodontic procedures that improve the periodontal prognosis. *J Am Dent Assoc* 100(3): 370-373.

van der Weijden, F., F. Dell'Acqua, et al. (2009). Alveolar bone dimensional changes of post-extraction sockets in humans: a systematic review. *J Clin Periodontol* 36(12): 1048-1058.

van Venrooy, J. R. and R. A. Yukna (1985). Orthodontic extrusion of single-rooted teeth affected with advanced periodontal disease. *Am J Orthod* 87(1): 67-74.

Wang, M. Q., F. Xue, et al. (2009). Missing posterior teeth and risk of temporomandibular disorders. *J Dent Res* 88(10): 942-945.

Vardimon, A. D., T. M. Graber, et al. (1991). Determinants controlling iatrogenic external root resorption and repair during and after palatal expansion. *Angle Orthod* 61(2): 113-122; discussion 123-114.

Wehrbein, H., W. Bauer, et al. (1990). [The effect of the maxillary sinus floor on orthodontic tooth movement]. *Fortschr Kieferorthop* 51(6): 345-351.

Wehrbein, H., H. Riess, et al. (1990). [Bodily movement of teeth in atrophic jaw segments]. *Dtsch Zahnarzt Z* 45(3): 168-171.

Weinstein, S. (1967). Minimal forces in tooth movement. *Am J Orthod* 53(12): 881-903.

Weltman, B., et al. (2010). Root resorption associated with orthodontic tooth movement: a systematic review. *Am J Orthod Dentofacial Orthop*, 137(4): p. 462-76; discussion 12A.

Wennström, J. L. (1996). Mucogingival considerations in orthodontic treatment. *Semin Orthod* 2(1): 46-54.

Wennström, J. L., J. Lindhe, et al. (1987). Some periodontal tissue reactions to orthodontic tooth movement in monkeys. *J Clin Periodontol* 14(3): 121-129.

Wisth, J. (1975). Periodontal status of neighboring teeth after orthodontic closure of mandibular extraction sites. *Scand J Dent Res* 83(6): 307-313.

Witter, D. J., P. van Elteren, et al. (1987). Migration of teeth in shortened dental arches. *J Oral Rehabil* 14(4): 321-329.

von Böhl, M. and A. M. Kuijpers-Jagtman (2009). Hyalinization during orthodontic tooth movement: a systematic review on tissue reactions. *Eur J Orthod* 31(1): 30-36.

von Böhl, M., J. Maltha, et al. (2004). Changes in the periodontal ligament after experimental tooth movement using high and low continuous forces in beagle dogs. *Angle Orthod* 74(1): 16-25.

Xie, Q., K. Soikkonen, et al. (1996). Effect of head positioning in panoramic radiography on vertical measurements: an in vitro study. *Dentomaxillofac Radiol* 25(2): 61-66.

Xie, Q., J. Wolf, et al. (1997). Quantitative assessment of vertical heights of maxillary and mandibular bones in panoramic radiographs of elderly dentate and edentulous subjects. *Acta Odontol Scand* 55(3): 155-161.

Yared, K. F., E. G. Zenobio, et al. (2006). Periodontal status of mandibular central incisors after orthodontic proclination in adults. *Am J Orthod Dentofacial Orthop* 130(1): 6 e1-8.

Zachrisson, B. U. (1976). Cause and prevention of injuries to teeth and supporting structures during orthodontic treatment. *Am J Orthod* 69(3): 285-300.

Zachrisson, B. U. and L. Alnaes (1973). Periodontal condition in orthodontically treated and untreated individuals. I. Loss of attachment, gingival pocket depth and clinical crown height. *Angle Orthod* 43(4): 402-411.

Zachrisson, B. U. and L. Alnaes (1974). Periodontal condition in orthodontically treated and untreated individuals. II. Alveolar bone loss: radiographic findings. *Angle Orthod* 44(1): 48-55.

Zachrisson, B. U. and B. O. Brobakken (1978). Clinical comparison of direct versus indirect bonding with different bracket types and adhesives. *Am J Orthod* 74(1): 62-78.

Acknowledgements

My sincere gratitude goes to all those who have supported and encouraged me during my work with this thesis. In particular:

Professor Emeritus Birgit Thilander, my previous main supervisor, co-author, in Studies I and II and the former head of the Department of Orthodontics, who initiated the project and introduced me to research. She also supervised my Licenciate thesis and is still following my work with great interest.

Professor Jan Wennström, my present main scientific supervisor, co-author in Studies I-IV and the head of the Department of Periodontology for helpful and inspiring collaboration, constructive discussions in all the studies and who also encouraged me to continue with the last two studies.

Associate Professor Ken Hansen, my co-supervisor and co-author in Studies III and IV, for never failing enthusiasm and continuous help with introducing new computer software as well as for critical thoughts and stimulating discussions.

Professor Bengt Mohlin, head of the Department of Orthodontics, my co-supervisor for valuable support throughout the study.

Associate Professor Annika Ekestubbe, co-author in Study III, for sharing her knowledge in radiology and helping me with the analysis of the radiographs.

Dr. Christiano Tomasi, co-author in Study IV, for valuable help and support and introducing me into the advanced statistics, the RMM-model, with endless patience.

Professor Magnus Hakeberg, co-author in Study IV, for support and providing access to the radiographic material from the prospective population study of women in Gothenburg.

Associate Professor Margaretha Ahlqwist for support and providing access to the radiographic material from the prospective population study of women in Gothenburg.

Mrs. Laila Gustafsson and Pia Johansson for organizing patient recalls, excellent clinical assistance and for caring about the patients in Study III.

Mrs. Iréne Lindqvist for skilful technical assistance and superb collaboration in Studies I and II.

The staff of the Department and Clinic of Orthodontics and Department for Children's Dentistry for creating a pleasant work atmosphere with many stimulating discussions of all manner of topics.

Mrs. Inger Andersson for invaluable guidance in planning for my dissertation.

All the patients who participated in the clinical studies, for their time and great patience.

My family for their constant support and patience but who also continuously reminds me that life is going on and that there are a lot of other important things in the world apart from this thesis.

All my friends who have stimulated me with their different interests and through recurrent gatherings with e.g. cooking, dinners, book reading, golf and movies and a lot of gossip and lively discussions.

My cat Mysslan, purring and sleeping at my keyboard and helping with typing Ssssss and Zzzzzz.

This thesis was supported by grants from (in alphabetic order):

The Anna Ahrenberg Foundation

The Faculty of Odontology, University of Gothenburg

Stiftelsen Fru Mary von Sydows, född Wijk, donationsfond

The Gothenburg Dental Society

The Health and Medical Care Executive Board of the Region of Västra Götaland

Herbert och Karin Jacobssons stiftelse

Sigge Persson's and Alice Nyberg's Foundation

The Swedish Dental Society

Wilhelm & Martina Lundgren's Foundation