

**Molar Incisor Hypomineralization**  
**Morphological and chemical aspects, onset**  
**and possible etiological factors**

Tobias Fagrell

Department of Pediatric Dentistry  
Institute of Odontology,  
The Sahlgrenska Academy  
at the University of Gothenburg



UNIVERSITY OF GOTHENBURG



Gothenburg 2011

Molar Incisor Hypomineralization  
© Tobias Fagrell 2011  
Tobias.fagrell@vgregion.se

ISSN 0348-6672  
ISBN 978-91-628-8341-6

Swedish Dental Journal supplement 216  
Printed at Ineko AB, Göteborg, Sweden 2011

# CONTENTS

<b>Abstract</b>	<b>5</b>
<b>Preface</b>	<b>7</b>
<b>Abbreviations</b>	<b>9</b>
<b>1. Introduction</b>	<b>11</b>
1.1 Developmental defects in dental enamel (DDE)	12
1.2 Hypomineralized enamel in the permanent first molars	16
1.2.1 Epidemiology	17
1.2.2 Clinical appearance and symptoms	18
1.2.3 Histological, chemical and mechanical properties	19
1.2.4 Treatment	20
1.2.5 Etiology	22
<b>2. Aims</b>	<b>24</b>
<b>3. Material and methods</b>	<b>25</b>
3.1 Analytical instruments/methods	25
3.2 Un-decalcified specimens	29
3.3 Decalcified specimens	32
3.4 Ozone treated bacteria	33
3.5 The clinical study	35
<b>4. Results</b>	<b>39</b>
4.1 Un-decalcified specimens	39
4.2 Decalcified specimens and bacteria	48
4.3 Ozone treated bacteria	51
4.4 The clinical study	53

<b>5. Discussion</b>	<b>57</b>
5.1 Methodological considerations	57
5.2 Ethical considerations	60
5.3 Un-decalcified specimens	60
5.4 De-calcified specimens and bacteria	62
5.5 Ozone treated bacteria	63
5.6 Onset	63
5.7 The clinical study	65
<b>6. Conclusions</b>	<b>67</b>
<b>7. Clinical implications</b>	<b>69</b>
<b>Acknowledgement</b>	<b>71</b>
<b>References</b>	<b>73</b>
<b>Appendix</b>	<b>83</b>
<b>Studies I-V</b>	

# Molar Incisor Hypomineralization

## Morphological and chemical aspects, onset and possible etiological factors

Tobias Fagrell

Department of Pediatric Dentistry, Institute of Odontology, The Sahlgrenska Academy at the University of Gothenburg, Göteborg, Sweden

### ABSTRACT

**Overall aim:** The general objective of this thesis was to enhance the understanding of Molar Incisor Hypomineralization (MIH) in areas of the histological, chemical and mechanical properties of the hypomineralized enamel, objective and subjective clinical symptoms in relation to bacteria findings. Further, to estimate a time for onset of the disturbance and investigate possible etiological factors. **Material & Methods:** 22 teeth diagnosed with MIH were used in the histological and chemical studies. A number of analytical methods were used; Light microscopy, Polarized light microscopy, Scanning electron microscopy, X-ray microanalysis, Vickers hardness test and X-ray Micro Computed Tomography. Decalcified sections were stained with bacterial staining. An ozone device was tested for the ability to kill strains of oral bacteria. In collaboration with the prospective ABIS study, 17.000 individuals were examined and possible etiological causes of severe demarcated opacities were tested. **Results & Conclusions:** The hypomineralized enamel was mainly located in the buccal enamel of the teeth and had a high degree of porosity extending from enamel-dentin-junction with a distinct border to the normal cervical enamel. Teeth diagnosed MIH had lower hardness values in hypomineralized enamel and differences in the chemical composition. Bacteria were observed in the enamel and deep into the dentin. Ozone treatment for 20 seconds or more was effective to kill oral microorganisms. Significant relations were found between MIH in first molars and breast feeding more than 6 months, late introduction to gruel and infant formula (later than 6 months). The onset for the hypomineralized enamel was estimated to around 200 days from start of the enamel mineralization.

**Keywords:** Enamel, etiology, lactobacillus, light microscopy, molar incisor hypomineralization, oral streptococci, ozone, polarized light microscopy, scanning electron microscopy, X-ray microanalysis, X-ray micro-computed tomography.

Swedish Dental Journal Supplement 216

ISSN 0348-6672

ISBN 978-91-628-8341-6



## PREFACE

This thesis is based on the following studies, referred to in the text by their Roman numerals (I-V).

- I. Fagrell TG, Dietz W, Jälevik B, Norén JG. Chemical, mechanical and morphological properties of hypomineralized enamel of permanent first molars. *Acta Odontol Scand.* 2010;68:215-22.
- II. Fagrell TG, Lingström P, Olsson S, Steiniger F, Norén JG. Bacterial invasion of dentinal tubules beneath apparently intact but hypomineralized enamel in molar teeth with molar incisor hypomineralization. *Int J Paediatr Dent.* 2008;18:333-40.
- III. Fagrell TG, Dietz W, Lingström P, Steiniger F, Norén JG. Effect of ozone treatment on different cariogenic microorganisms in vitro. *Swed Dent J.* 2008;32:139-47.
- IV. Fagrell TG, Ludvigsson J, Ullbro C, Lundin SA, Koch G. Aetiology of severe demarcated enamel opacities - an evaluation based on prospective medical and social data from 17,000 children. *Swed Dent J.* 2011;35:57-67.
- V. Fagrell TG, Salmon P, Melin L, Norén JG. Onset of Molar Incisor Hypomineralization (MIH). Submitted for publication.

The papers are reprinted with kind permission from the copyright holders.





## ABBREVIATIONS

ABIS	All Babies In Southeast Sweden
B&B	Modified Brown and Brenn
BMP	Behavior management problems
DDE	Developmental defects in dental enamel
DPH	Diamond pyramid hardness
EDJ	Enamel-dentin-junction
FDI	World Dental Federation
HTX	Haematoxylin and eosin
HV	Vickers pyramid number, Hardness Value
LM	Light microscopy
MIH	Molar incisor hypomineralization
PDS	Public Dental Service
PEB	Post eruptive breakdown
POLMI	Polarized light microscopy
SDO	Severe demarcated opacity
SEM	Scanning electron microscopy
XMCT	X-ray micro-computed tomography
XRMA	X-ray microanalysis



# 1 INTRODUCTION

Dental development and mineralization in humans starts before birth and continues to adolescence when the permanent molars complete their mineralization. The first sign of tooth mineralization is seen in the primary lower incisors in the beginning of the second trimester of pregnancy and is finished around three months post partum. The first permanent molar is the first tooth in the permanent dentition to mineralize, a process that starts around birth and is completed at approximately three years of age (Reid & Dean 2006). Enamel and dentin are formed by secretory cells and the enamel forming cells, the ameloblasts, are highly specialized cells of ectodermal origin (Simmer 2010; Mahoney 2011). After mineralization neither enamel nor dentin is remodeled. Due to the high proportion of mineral, only minor changes are found post-mortem in the teeth, even for many hundred years after burial.

Dental enamel has a number of properties making it a unique tissue. It is the hardest tissue in the body and has a very high proportion of inorganic matter, mainly hydroxyapatite. The ameloblast has a limited reparative capacity; therefore disturbances occurring during the mineralization of enamel will remain as permanent marks. Defects in enamel quality or in other dental hard tissues are important implications for the understanding of evolution, function, origin and relation to etiological factors behind developmental disturbances but also how environmental factors may influence on the mineralization of the dental hard tissues. These unique properties of teeth have been widely used in research within biology, anthropology, archeology and several other areas (Fincham *et al.* 1999; Antoine *et al.* 2009; Mahoney 2011).

Clinically, disturbances in enamel mineralization may be seen as opaque areas with colors ranging from white to yellowish-brown, or as defects where no mineralization of enamel has occurred. However, even with the help of mineralization schemes the timing for a disturbance may not be possible. The extension of the tissue defect cannot be evaluated clinically, thus the start and length of a disturbance may not be assessed with any accuracy. Therefore, histological analyses are necessary in order to gain appropriate information.

The hard tissue formation of enamel and dentin is, as in many biological systems, characterized by a rhythmic appearance (Simmer 2010). The rate of mineralization is histologically seen as incremental lines in enamel and dentin. In the enamel the incremental lines are known as Retzius lines. Histological studies of dental hard tissues have provided information on the

timing of their mineralization. Therefore, enamel may serve as a kymograph for events occurring during its mineralization, which is especially true for histological sections of teeth.

The first-formed enamel is the enamel closest to the dentin horns, the cuspal enamel (Simmer 2010). The cuspal enamel does not display Retzius lines that meet the enamel surface. However, Retzius lines are seen in the later-formed enamel, extending to the tooth surface, forming the perikymata which creates a wavy appearance on the enamel surface (Dean 1987; Shellis 1998). The enamel prisms also show striations, short-period incremental lines, known as cross striations. The cross striations have a circadian repeat interval of 24-hours (Fitzgerald 1998) and can be used to determine the daily secretion rate (Smith 2006). By counting and measuring them, Retzius lines and cross striations can be used for estimating the crown mineralization time and for determining when a disturbance has occurred, as well as its duration (Boyde 1963, 1990).

The structure and chemical composition of enamel are so complex and difficult to study that several techniques and methods must be used to evaluate them in a correct context, taking into account the chemical and structural properties of enamel and dentin. From a technical point of view, enamel is by far the most difficult tissue to study, compared with dentin, cementum or bone. The low content of organic matter in enamel makes it in principle impossible to study but in un-decalcified sections. The preparation of un-decalcified sections with the brittle enamel may, however, be carried out with a diamond saw after embedding the tooth in an epoxy-resin. Sections with a thickness of 80-120  $\mu\text{m}$  can be prepared, but with a considerable loss of substances equal to the thickness of the saw blade ( $\approx 300 \mu\text{m}$ ). Therefore, it is not possible to achieve true serial sectioning. Further, the isolating properties of the dental hard tissues create certain problems when the tissues are analyzed in electron microscopes or with different types of ion or electron probes for analysis of chemical contents.

### *1.1 Developmental defects in dental enamel (DDE)*

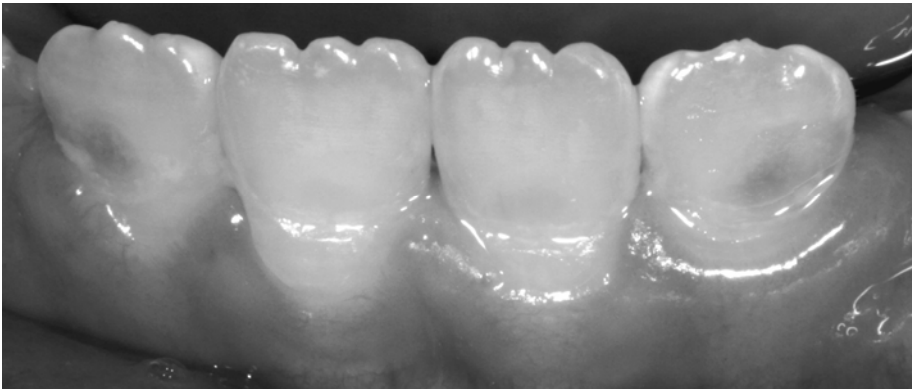In 1992, a working group of the FDI presented an epidemiological index of developmental defects of the dental enamel, the DDE index. A developmental defect was defined as a disturbance arising in hard tissue matrices and in their mineralization during odontogenesis (FDI Commission on Oral Health R&E 1992).

DDE is a common condition, in Caucasian populations in New Zealand (Suckling & Pearce 1984), Ireland (Clarkson 1987) and England (Brook & Smith 1998). The prevalence is reported as between 63 and 68% and may be as high as 95-99%, which has been found in a Hong Kong Chinese population (King & Brook 1984; King & Wei 1986).

There are basically two major developmental defects; *enamel hypoplasia* and *hypomineralized enamel* (FDI Commission on Oral Health R&E 1992).

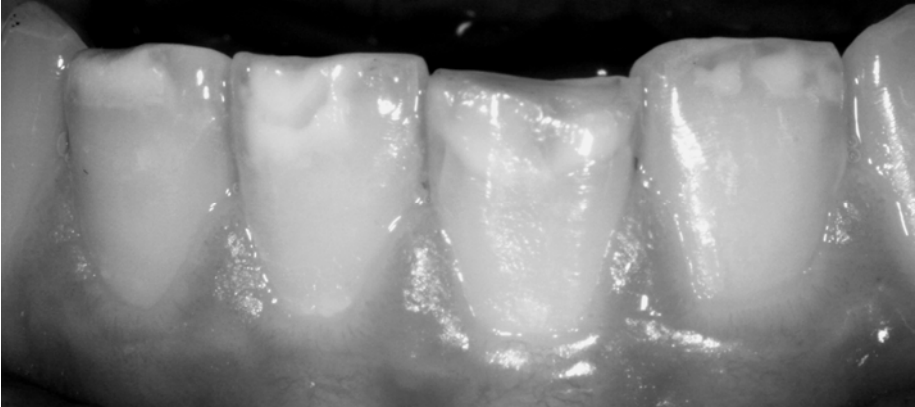*Enamel hypoplasia* is defined as a quantitative defect of enamel surface that is macroscopically detectable. The reduction of enamel thickness has smooth rounded borders and no fracture boundaries are seen. It may occur as pits or rows and the defect might be shallow or deep, local or generally distributed all over the enamel (Sabel *et al.* 2010) (Fig. 1).

*Hypomineralized enamel* is defined as a qualitative defect, identified visually. The color of the defect may be white, brown or yellow. The thickness of the enamel is normal at time of eruption. A posteruptive breakdown (PEB) may be seen. If PEB occurs, fractured edges are seen (Fig 2).

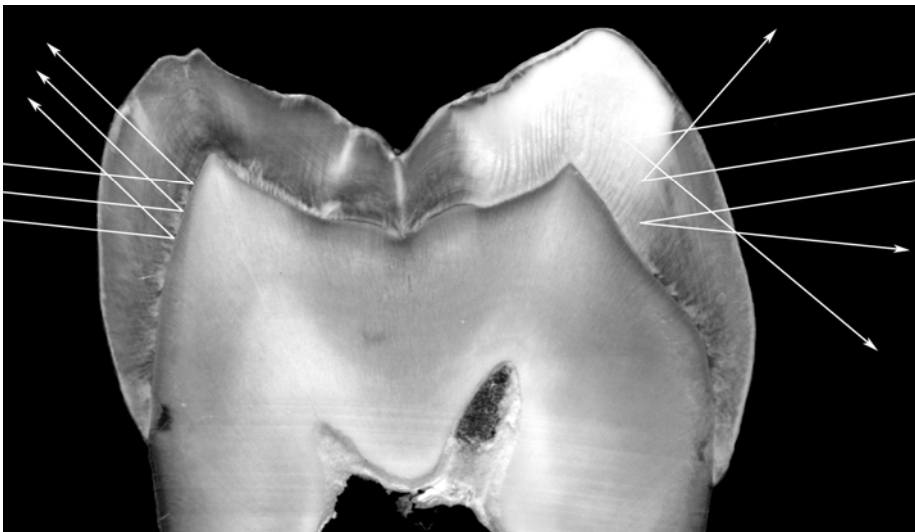


**Figure 1.** Buccal enamel hypoplasia on teeth 42-32. A reduction of the enamel thickness is seen and the cervical border of the defect is rounded and smooth without any fractured edges.

Enamel of a normal degree of mineralization in permanent teeth is translucent to visible light, which passes through the enamel and is reflected at the enamel dentin junction. Normal mineralized enamel has a refractive index of 1.62 (Fig. 3). If a developmental defect of the enamel or a caries lesion is present, the enamel is more porous and the refractive index will be lower *id est* =1.0.



**Figure 2.** Buccal hypomineralization on teeth 42-32 with a white to brown color. Posteruptive fractures are seen on the incisal edges on 41 and 31.



**Figure 3.** Schematic drawings of refractive index. Left: in normal enamel, the light passes through the enamel and is reflected at the enamel dentin junction. Normal enamel has a refractive index of 1.62. Right: the light is refracted in the porous enamel; the refractive index of the enamel is lower than in normal enamel.

The lower refractive index of the porous enamel will then clinically be seen as an opaque area with a color ranging from white, yellow to almost brown. The color is basically not an effect of discoloration but a change of the refractive index caused by the increased degree of porosity in the enamel. The color seen is to some extent dependent on the degree of hypomineralization but possibly also to the protein content in the enamel (Farah *et al.* 2010a; Da Costa-Silva *et al.* 2011).

The surface of hypomineralized enamel can be smooth or matt. If the hypomineralized area has distinct borders and a well mineralized intact surface with a glossy appearance, the clinical denomination is *opacity*. In more severe cases of hypomineralization the enamel surface may collapse and a loss of substance with fractured borders will appear. A matt enamel surface is characteristic for hypomineralized enamel in connection with dental fluorosis.

#### *Chronology of DDE*

In order to be able to assess the chronology of DDE, knowledge of the timing of the mineralization of teeth is important. A mineralization guide may to some extent help to determine when a disturbance has occurred, but it is important to understand and use the guide correctly since it only presents a 2-dimensional image. The most commonly used method is the scheme developed by Schour and Massler, in the early 1940's (Schour & Massler 1941). However, no more than a rough estimation can be achieved and only histological methods can reveal the onset and duration of a disturbance (Boyde 1963, 1990; Mahoney 2008, 2010, 2011).

#### *Etiology of DDE*

The etiology of a DDE may be of local or general origin (Table 1). Local defects affect a specific tooth or adjacent group of teeth. A general defect affects all teeth that are mineralized during the time period of the insult. The length of the insult will determine which and how many teeth will be affected.

**Table 1.** The most common causative factors of developmental defects in dental enamel (DDE) and their distribution in the dentition.

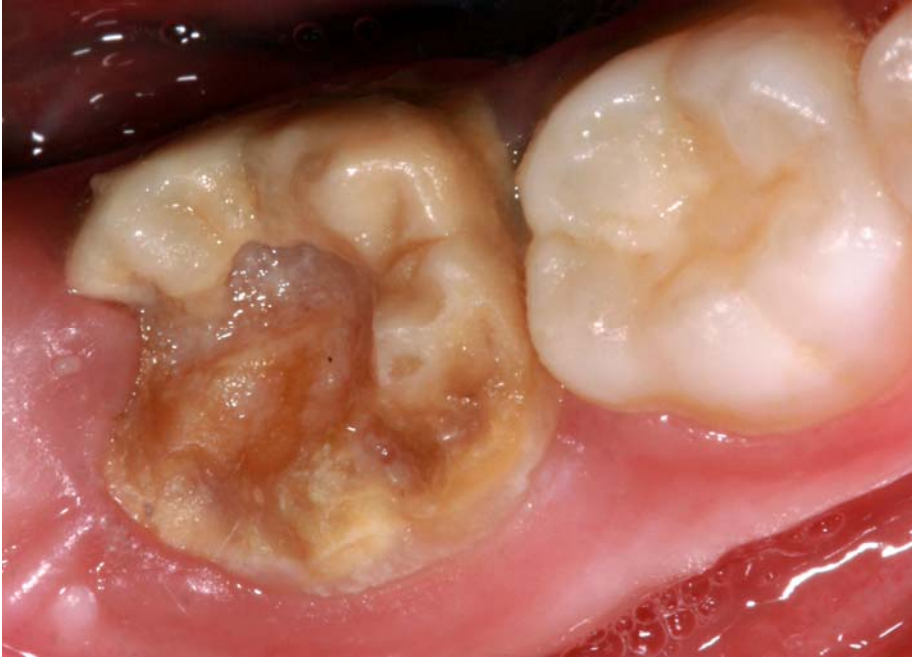<b>Causative factor</b>	<b>Distribution</b>	<b>Example</b>
<i>Mechanical</i>	Local	Trauma to a primary tooth may cause a sequel in the permanent successor.
<i>Radiation</i>	Local	Therapeutic radiation may disturb both development and mineralization
<i>Infection</i>	Local	As a sequel after an osteitis or trauma, the acid environment of a infection/ inflammation, may disturb mineralization
<i>Nutritional disease</i>	General	Disturbances of the nutrition and/or calcium metabolism, with changes in Ca- or pH levels in blood may bring about changes in the enamel mineralization.
<i>Systemic disease</i>	General	High fever and infections is examples of a variety of perinatal and childhood diseases who carry an increased risk for enamel defects.
<i>Toxic</i>	General	The most well-known toxic factors are fluoride and tetracycline.
<i>Genetic</i>	General	Amelogenesis imperfecta

### 1.2 *Hypomineralized enamel in the permanent first molars*

Since the early 1970's dentists have reported a developmental defect primarily located in the first molars and incisors in permanent dentition. Areas of demarcated hypomineralized enamel varying from opacity to more severe conditions with enamel surface breakdown (Fig. 4) were typical for the defect. This enamel disturbance was found predominately in first permanent molars and incisors. One of the first more extensive studies on the prevalence of demarcated opacities in first permanent molars and incisors was reported by Koch *et al.* in 1987 (Koch *et al.* 1987).

A number of different denominations have been used for the condition with hypomineralized permanent first molars (i.e. idiopathic hypomineralization, Morbus S, Cheese molars). The present definition and denomination was set in 2001 (Weerheijm *et al.* 2001).





**Figure 4.** Clinical image of a tooth diagnosed with MIH with post eruptive breakdown.

Molar Incisor Hypomineralization (MIH) is defined as a general and chronological hypomineralization of systemic origin of the permanent first molars and incisors. One or more of the molars may be affected, each with different degrees of severity. The permanent incisors may also be affected. Even though MIH is defined as a chronological and general disturbance the number of permanent first molars and the degree of hypomineralization varies extensively.

#### *1.2.1 Epidemiology*

MIH is recognized as a global dental problem and epidemiologic reports from all over the world are continuously published (Jälevik 2010). The prevalence varies considerably from a few percent in China (Cho *et al.* 2008) to almost 40% percent in Denmark and Brazil (Wogelius *et al.* 2008; Soviero *et al.* 2009).

Any number between 1 and 4 of the first permanent molars may be affected by MIH. The more teeth affected, the higher the probability for a more severe expression and about half of the children with MIH also showed clinical signs of MIH on the incisors (Jälevik *et al.* 2001c). Further, one third of the affected teeth (total 18.4% affected) had severe hypomineralization,

which is a ratio also found by Koch *et al.* where 4% percent were severely affected and the total prevalence was 15% (Koch *et al.* 1987).

### 1.2.2 *Clinical appearance and symptoms*

The clinical appearance of MIH is a demarcated opacity on the affected tooth with a white, beige to dark yellow color. The severity of MIH may vary considerably and one to all four of the permanent first molars may be affected in different individuals. A clinical classification of the severity of MIH into three categories (levels of severity) has been suggested: mild, moderate and severe (Leppäniemi *et al.* 2001).

MIH is connected to a number of subjective and objective problems for both the dental professions and for the patients. Some of the most prominent problems are loss of tooth substance, increased risk of plaque accumulation and dental caries, severe discomfort, hypersensitivity (shooting pain) and loss of fillings. Post-eruptive breakdown (PEB) most often occurs shortly after eruption, when the affected tooth is under occlusal load (Weerheijm 2003).

As many as 5% of the children in a Swedish population have a severe form of MIH and will experience extensive and difficult treatment (Jälevik *et al.* 2001c). It has been reported that children with MIH have ten times more dental treatment compared with a group of children with clinically healthy first molars (Jälevik & Klingberg 2002). These multiple treatment sessions may lead to an increased risk of developing behavior management problems as well as dental fear and anxiety (Jälevik & Klingberg 2002).

A recent study presented a correlation between the color of enamel and the severity of hypomineralization, where yellow and brown color of the hypomineralized enamel was at a higher risk for PEB and/or atypical restorations compared with white defects (Da Costa-Silva *et al.* 2011). Still, it is clinically difficult to estimate the degree of hypomineralization and the risk of loss of enamel.

One of the most common problems in teeth affected by MIH is the increased risk of dental caries (Jälevik & Klingberg 2002). It is a well established fact that bacteria will invade the dentinal tubules when a caries attack is present and bacteria and its toxins may cause a reversible or irreversible reaction in the pulp (Selwitz *et al.* 2007). Deep fissures and cracks in the enamel also constitute possible pathways for bacteria into the dentin. Since the young permanent teeth have wide dentinal tubules bacteria may penetrate deep into non-carious dentin.

A well known problem for patients with permanent first molars diagnosed with MIH is hypersensitivity (shooting pain), causing severe subjective problems during eating or brushing teeth. Even teeth with apparently intact enamel surface may show symptoms of pain. Dental treatment of the affected molars becomes difficult and in many cases the treatment must be performed under general anesthesia (Jälevik & Klingberg 2002). It is very plausible that the pulpal response may be attributed to bacteria penetration or bacteria toxins through the porous enamel found in teeth with MIH; however, the causative factor has still not been elucidated.

### 1.2.3 *Histological, chemical and mechanical properties*

The histological appearance of MIH has been presented in literature in a number of studies. The histological appearance of the enamel in teeth with MIH differs considerably from what is found in normal enamel. The hypomineralized enamel extends from the enamel-dentin junction at a cuspal horn, usually around the mesio-buccal cusp (Mahoney *et al.* 2004a). The hypomineralized enamel may cover any area from the coronal third part to almost all of the enamel towards the enamel-cementum junction. The cervical border to the normal enamel ends along a prism rather than along an incremental line which, however, has been suggested in literature (Farah *et al.* 2010a).

Enamel in teeth affected by MIH exhibits disorganized enamel prisms, a porous structure and loosely packed crystallites (Kodaka *et al.* 1991; 1992; Den Besten *et al.* 1989; Jälevik *et al.* 2001b; Fearne *et al.* 2004; Gao *et al.* 2004; Mahoney *et al.* 2004a, b; Angker *et al.* 2005; Braly *et al.* 2007; Xie *et al.* 2007, 2008). When the clinical and histological appearance of MIH is compared with normal enamel in a polarization microscope analyses, yellow/brown enamel opacities were shown to be more porous than lighter opacities (Da Costa-Silva *et al.* 2011).

The mechanical properties, hardness, mineral density and modulus of elasticity of the hypomineralized enamel in MIH teeth have lower values compared with normal enamel (Suckling *et al.* 1989; Mahoney *et al.* 2004a, b; Jälevik *et al.* 2005; Xie *et al.* 2007, 2008; Farah *et al.* 2010b). The lower values may explain why the enamel surface on a tooth with MIH often collapses and fractures under occlusal load.

Elemental analyses of MIH enamel have revealed some changes in the chemical composition and a reduction in the mineral composition (Jälevik *et al.* 2001b; Fearne *et al.* 2004; Mahoney *et al.* 2004b). Further, a correlation between hardness values, mineral density and the color of the

hypomineralized enamel has been shown, with yellow/brown opacities being softer than white (Suckling *et al.* 1989; Farah *et al.* 2010a).

#### 1.2.4 Treatment

Due to the special enamel composition and decreased mechanical properties in a tooth affected with MIH, different treatment options have been discussed (Daly & Waldron 2009; Lygidakis 2010). An individual long-term plan must be completed before the start of any treatment. A recent study has shown that children affected by MIH must undergo over four times more treatment during their adolescence than a control group without MIH and they also had significantly more behavior management problems (BMP) than the control group (Jälevik & Klingberg 2011).

In 2005 Mejare *et al.* presented the results of long-term treatment of MIH (Mejare *et al.* 2005). At the age of 18, more than 50 percent of the patients had unacceptable restorations in their first permanent molars. In order to minimize treatment failures and discomfort for the patients, it is important to have an early diagnosis and risk identification. Depending on the severity of the affected teeth and the symptoms, an individual treatment protocol containing strategies to minimize the hypersensitivity and make long lasting restorations of the affected teeth must be made. In the protocol, both the long term plan for the affected teeth as well as a plan for follow-up and maintenance must be documented in the dental files.

Treatment of MIH is dependent on severity and specific subjective symptoms. Restoring an affected molar can vary from adhesive intra coronal restorations (resin composite is the material of choice) to extra coronal restorations (e.g. preformed stainless steel crown) or extractions (Daly & Waldron 2009). Two Swedish studies have presented favorable results after extraction of first permanent molars diagnosed with severe MIH where spontaneous space closure after extraction was found in most of the cases (Mejare *et al.* 2005; Jälevik and Möller 2007).

Dentin hypersensitivity is a common complication of MIH, making oral hygiene and food intake more difficult for the affected individuals and it constitutes a severe problem. The finding of a subclinical pulpitis in teeth diagnosed with MIH has previously been presented (Rodd *et al.* 2007). Even non-invasive preventive clinical procedures such as fissure sealants may cause significant discomfort for these young children, increasing their anxiety and causing behavior management problems. When hypersensitivity is present, local anesthesia may be necessary for all treatment procedures.

Dental caries will, as MIH, lead to cavitations, discomfort, pain and eventual tooth loss. Dental caries is a bacterially mediated disease characterized by demineralization of the tooth surface (Selwitz *et al.* 2007). If the bacteria, such as streptococci and lactobacillus, which both are involved in the caries progression, are removed or killed, arrestment of the demineralization process could occur and in the presence of fluoride and other minerals, allow remineralization to occur (Holmes 2003).

Ozone treatment has been presented and discussed in literature as one of the “new” ways of treating dental caries bacteria, by killing the bacteria. Previous studies have shown that gaseous ozone may be used for antimicrobial treatment to arrest root- fissure- and smooth surface caries (Baysan *et al.* 2004, 2005, 2006; Nagayoshi *et al.* 2004; Stubinger *et al.* 2006). Furthermore, ozone treatment has been reported to be used for sterilizing cavities and root canals, as well as treatment of periodontal pockets, herpetic lesions and hypersensitive teeth (Baysan *et al.* 2006; Stubinger *et al.* 2006).

Since ozone is heavier than air, it falls back to earth, where it is known to naturally purify air and water. The powerful ability of ozone to inactivate microorganisms has led to its use for water disinfection, foodstuff sterilization and in the chemical industry (Kim *et al.* 1999; Filippi 2002). It is well documented that ozone kills bacteria, viruses and fungi upon contact with the various organisms (Kim *et al.* 1999). The bactericidal properties of ozone were used in medicine to treat infected wounds as early as the First World War. Medical ozone generators have since been developed and refined. Ozone applications in industry are, for example, water and air purification and in the food industry, processing and preservation. The antimicrobial effect of ozone results from oxidation of microbial cellular components (Bocci 1992).

The chemical denomination of an ozone molecule is O<sub>3</sub>. Ozone is a powerful oxidizing agent, far stronger than O<sub>2</sub>. It is unstable at high concentrations, decaying to ordinary oxygen. ( $2O_3 \rightarrow 3O_2$ ). In nature oxygen naturally turns into ozone when it reaches the upper atmosphere and is exposed to ultraviolet light from the sun and forms the protective ozone layer.

One of the major environmental advantages of ozone is its low cytotoxicity, which in clinical situations is caused by the rapid degradation of ozone just after contact with organic compounds (Bocci 1992).

### 1.2.5 Etiology

In order to understand the etiology of MIH, it is important to know the chronology of tooth mineralization. Research on the etiology of MIH has been focused on a medical or environmental insult occurring in the first three years of life.

The mineralization of enamel in a first permanent molar starts just before birth and is completed by the age of 1 year (Reid & Dean 2006). Therefore the critical period for the development of MIH is the first year of life.

No single etiological cause has been found responsible for the development of MIH but some possible sources have been suggested. Factors during the perinatal period that have been suggested to influence the prevalence of MIH are hypoxia (Lygidakis *et al.* 2008), hypocalcemia (Aine *et al.* 2000; Jälevik *et al.* 2001a) and preterm birth (Foote 2003; Brogårdh-Rot *et al.* 2011). Other authors investigated feeding patterns and environmental toxicants during the postnatal period (Alaluusua *et al.* 1996a; Alaluusua *et al.* 1996b). Prolonged breastfeeding has been proposed as being associated with MIH and also that exposure to dioxin via mothers' milk was a potential risk factor (Alaluusua *et al.* 1996a, 1996b). However, other studies could not fully confirm this (Jälevik *et al.* 2001a; Laisi *et al.* 2008; Kuscu *et al.* 2009). Different diseases in childhood, fever, and medication (e.g. antibiotics) have also been suggested to be causative factors behind MIH (Jälevik *et al.* 2001a; Beentjes *et al.* 2002; Whatling & Fearn 2008). To conclude the findings emerging from two extensive systematic reviews (Crombie *et al.* 2009; Alaluusua 2010) there is still insufficient evidence to verify the etiology of demarcated opacities in the enamel of the first permanent molars.

A probable reason for not finding the etiological cause of MIH may be that all studies so far have been retrospective and at present there are no prospective studies.

In the ABIS-study (All Babies In Southeast Sweden, starting in the late 1990's), which is a medical social prospective population study from birth of over 17,000 children, medical information has been collected. The purpose of the ABIS study was to prospectively investigate risk factors for immune mediated diseases in children, especially Type 1 diabetes (Ludvigsson *et al.* 2001). Numerous different, medical data, information from interviews, questionnaires and biological samples (blood from the umbilical cord, breast milk, hair samples, etc.) have been collected, from delivery until today. A detailed diary was kept during the first year of life documenting diseases,

medication, feeding, exposure to environmental toxicants etc. The study is still running and a follow-up at 12 years of age is ongoing. A total of about 4,000 variables for each child covering somatic growth; pre-, peri-, and neonatal status; childhood diseases; medications; vaccinations; socioeconomic factors; and nutrition etc., are stored into the ABIS databank at the Department of Pediatrics, Linköping University, Sweden.

## 2 AIM

### *Overall aim*

The general objective of this thesis was to enhance the understanding of MIH in areas of the histological, chemical and mechanical properties of the hypomineralized enamel, objective and subjective clinical symptoms in relation to bacteria findings. Further, to estimate a time for onset of the disturbance and investigate possible etiological factors.

### *Specific aims:*

- To measure the hardness values and analyze some elements in hypomineralized and normal enamel in teeth diagnosed with MIH.
- To investigate the penetration of bacteria through enamel and dentin in teeth diagnosed MIH.
- To, *in vitro*, investigate if gaseous ozone can kill different oral microorganisms.
- To investigate possible etiological causes to MIH in the ABIS population.
- To investigate the location and origin of hypomineralization in teeth diagnosed with MIH, and to estimate the possible onset of MIH.



### 3 MATERIAL AND METHODS

#### 3.1 Analytical instruments/methods

A number of different analytical instruments/methods have been used in this thesis. A short description is given below to introduce them to the reader.

##### *Cutting of un-decalcified dental hard tissues (I, V)*

The teeth were stored in 70% ethanol until further preparation, the ethanol also served as a fixation media. Since the enamel is so brittle the teeth have to be imbedded in a supporting media before cutting, normally an epoxy-resin. Sectioning is then carried out in a Leica SP1600 Saw Microtome (Leica Microsystems GmbH, Wetzlar, Germany) (Fig. 5). The saw microtome has a horizontally rotating saw blade with internal hole of 83 mm in diameter, a thickness of 280  $\mu\text{m}$  and with a cutting edge prepared with a diamond coating.



**Figure 5.** The Leica SP1600 saw microtome.

The cutting is performed with a constant rotation of the saw blade and by adjusting the advance of the specimen holder the cutting may be performed with minimal pressure to the specimen, thus minimizing damages.

Sections with a thickness of approximately 100-120  $\mu\text{m}$  may be prepared. However, for each section there is a loss of tooth substance equivalent to the thickness of the saw blade.

*Cutting of decalcified dental hard tissues (II)*

After demineralization of inorganic material in a tooth the remaining organic part of the tooth is embedded in paraffin as a supporting media. For the cutting a sliding microtome is used, producing serial sections with a thickness of 4-5  $\mu\text{m}$ , which may be subjected to different types of staining techniques.

*Stereo microscopy (I- III, V)*

The stereo microscope gives a large field of view, increased depth of focus and good resolution, which promotes easy replicate measurements, photography or inspection of large samples. The possibility to make an overview of a whole tooth or a section using illumination from above or from different angles increases information.

*Polarized light microscopy (V)*

Polarized light microscopy (POLMI) is a contrast enhancing light microscopic technique that improves image quality. It is based on two polarized light filters between which the specimen is placed. Light passing through the first filter (the polarizer) will only swing in one plane. The second filter (the analyzer) is placed after the specimen holder, at a 90 degree angle to the first; therefore, no light can pass through to the oculars. If a specimen with the capacity for double refraction (birefringence) is placed between the two filters an image with certain properties will then appear in the oculars.

Normal mineralized enamel has what is called negative birefringence and by using a  $\lambda$ -filter, the color of the enamel will become blue to turquoise. Enamel with a higher degree of porosities in the tissue (hypomineralized) will appear in colors from red, yellow to dark green, depending on the porosity of the tissue. If the enamel specimen is subjected to solutions with different refraction indexes (imbibition) and examined in polarized light, very detailed information concerning the pore volume distribution may be gained.

*Scanning electron microscopy (I-III, V)*

Scanning Electron microscopy (SEM) is a technique that allows examination of samples too small to be seen with a light microscope. Since the electrons have a shorter wavelength than visible light, the SEM can produce high resolution images of a sample surface (Fig. 6).

Images of a sample are produced by scanning it with a high-energy beam of electrons in a raster scan pattern. The electrons interact with the atoms that make up the sample, producing signals that contain information about the sample's surface topography and other properties. Since electrons cannot travel far in air the electron beam and the sample are kept in vacuum. The electron beam creates a surface charge on the sample. Since dental hard tissues have isolating properties the surface normally has to be coated with a thin layer (10-20 nm) of e.g. gold. The conducting layer leads off the surface charge that would otherwise prevent taking an image.



**Figure 6.** SEM instruments used in the thesis. *Left:* Philips SEM 515. *Right:* Gemini IMB LEO 1530 field emission SEM.

#### *X-ray microanalysis (I)*

X-ray microanalysis (XRMA) analysis may be performed in an SEM with a detector for X-rays and suitable software. In the XRMA technique the electron beam penetrates into the specimen (1-2  $\mu\text{m}$  depth) and characteristic X-rays (K- $\alpha$  radiation) are emitted from a pear shaped volume in the sample. Since the K- $\alpha$  radiation is characteristic for different elements the weight% for the measured elements can be calculated. As for SEM analysis the electron beam creates a surface charge, which is why the surface of the specimen has to be coated with a suitable layer of conductive material. The technique has limitations in the analysis of dental hard tissues; however, it is suitable for measurements of Ca and P. All specimens examined with the XRMA technique in this thesis were coated with a thin layer of carbon (10-15 nm) with vapor deposition.

#### *The Vickers hardness test (I)*

The basic principle in a Vickers hardness test, as with all common techniques for measuring hardness, is to observe the examined material's ability to resist plastic deformation from a standard source (Fig. 7). The unit of hardness

obtained by the test is known as the Vickers Pyramid Number (HV) or Diamond Pyramid Hardness (DPH). The hardness number is determined by the load over the surface area of the indentation and not the area normal to the force, and is therefore not a pressure value. The HV value is calculated after a measurement of the indentation from a square based pyramid with the equation  $HV=F/d^2$  (F=force applied on the diamond in Newtons, d=the average length of the diagonal left by the indenter).



**Figure 7.** The Leica Miniload 2 Microhardness Tester.

#### *X-ray Micro Computed Tomography (V)*

X-ray Micro computed tomography is an X-ray imaging technique in 3D. The principles are the same as for instruments used in hospital CT scans but on a small scale with massively increased resolution. The technique truly represents 3D microscopy, where very fine-scale internal structures of objects are imaged non-destructively, without sample preparation, staining or thin slicing. A single scan will image a tooth's complete internal 3D structure at high resolution.

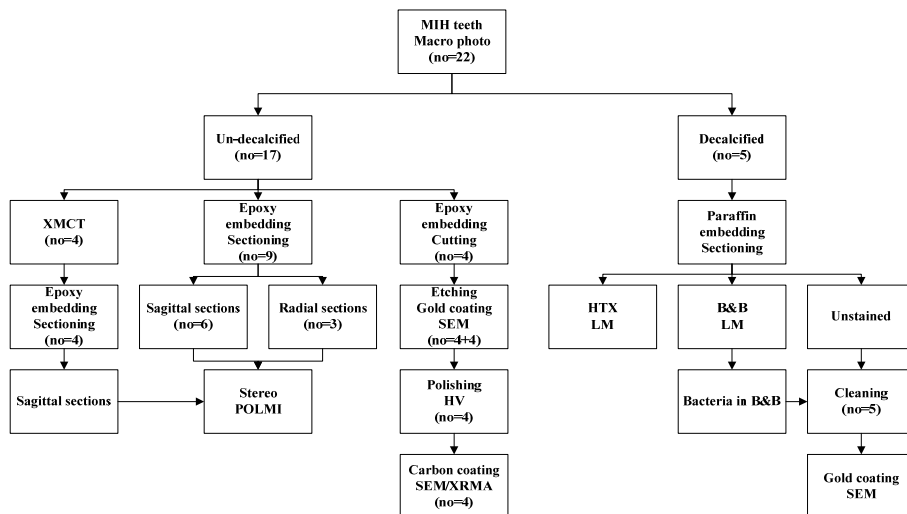
The basic principle for XMCT is that a micro-focus X-ray source illuminates the object and a planar X-ray detector collects magnified projection images. Based on hundreds of angular views acquired while the

object rotates, a computer synthesizes a stack of virtual cross section slices through the object. When the scan is finished and the images saved, it is possible to scroll through the cross sections, interpolating sections along different planes to inspect the internal structure. Selecting simple or complex volumes of interest, 3D morphometric parameters can be measured and realistic visual models can be created for virtual travel within the object.

### 3.2 Un-decalcified specimens (I, V)

#### Tooth material

A presentation of the number of collected first permanent molars, preparation and used methods are given in Figure 8 for both un-decalcified and decalcified specimens. With the exception of the five teeth used for decalcified sections all teeth were stored in 70% ethanol prior to any further treatment.



**Figure 8.** Schematic drawing of the study design of the dental hard tissue specimens. (XMCT=X-ray Micro CT; HTX=Haematoxylin & Eosin staining; B&B=modified Brown & Brenn staining; LM=Light Microscopy; POLMI=Polarized light microscopy; Stereo=Stereo microscopy; HV=Vickers hardness test; SEM=Scanning Electron Microscopy; XRMA=X-ray Micro Analysis; no=number.)

Macro photos of the teeth in different projections were taken either with a conventional digital camera or in a Leica stereo microscope (Leica M80 with 8:1 zoom, 0.75x-6x, Leica Microsystems GmbH Wetzlar, Germany) equipped with a Leica digital camera (Leica DFC420 C, Leica Microsystems GmbH Wetzlar, Germany). Before cutting, the teeth were oriented for a correct cutting direction and embedded in an epoxy-resin (Epofix®; Electron Microscopy Sciences, Fort Washington, PA).

#### *Cutting procedure*

The four teeth for XRMA analysis and hardness measurements were cut sagittally in a bucco lingual direction through the cuspal area in a Leica SP1600 Saw Microtome (Leica Microsystems GmbH, Wetzlar, Germany).

Sagittal bucco-lingual and radial serial sections were prepared from six and three teeth, respectively, in the Leica SP1600 Saw Microtome. After the first cut, in which excess epoxy was removed, an object glass was glued on the cut surface, with a light curing one-component adhesive (Technovit 7210 VLC, Heraeus Kulzer GmbH, Hanau, Germany). This technique prevents loss of enamel during the cutting procedure and allows optimal positioning of the sample on the glass.

After completed analysis, the four teeth in the XMCT analysis were embedded and serially sectioned as previously described.

#### *Light Microscopy (LM)*

From all sections digital photos were taken in a Leica M80 stereo microscope at low magnification (0.75x) and in incident light using a Leica digital camera (Leica DFC420 C, Leica Microsystems GmbH Wetzlar, Germany), equipped with Leica Application Suite LAS V3.7.0 (Leica Microsystems AG, Heerbrugg, Switzerland).

#### *Polarized light microscopy (POLMI)*

All sections were examined in an Olympus polarizing light microscope (Olympus, Tokyo, Japan). Digital images were produced using a Leica DFC420 C digital camera and the Leica Application Suite.

#### *Scanning Electron Microscope (SEM) analyses*

Prior to the SEM analysis the cut surfaces of the eight specimens were etched with 30 % phosphoric acid for 45 seconds, rinsed with de-ionized water and after drying coated with gold by means of vapor deposition. After examination with SEM (SEM 515, Philips, Eindhoven, The Netherlands) at 15 kV, four halves were left for hardness and XRMA measurements.

### *Hardness measurements*

The surface of the four tooth halves used in the hardness measurements was polished and the hardness measurements were performed according to Vickers. A digital micro hardness tester (Leitz Miniload 2; Wild Leitz, Wetzlar, Germany) was used for the analysis. The hardness tester was fitted with a Vickers diamond with a 1.961 N load, in order to make indentations. A total of 54 indentations were made in the hypomineralized enamel and 45 in the normal enamel, representing an area of 4 mm<sup>2</sup>. The hardness was measured as Vickers pyramid numbers (HV).

### *X-ray micro analyses (XRMA)*

After the hardness measurements the specimens were coated by vapor deposition with a thin layer of carbon. The elements C, O, P and Ca were measured in the test points of the hardness measurements by XRMA, using a Philips SEM 515, EDAX DX4, with an ECON detector. A small window for detecting the X-ray was used. A computerized calculation program (Point Electronic DISS 2; Point Electronic GmbH, Halle, Germany) was used to calculate the relative amount of the measured elements, expressed in weight% normalized to 100%. Additional SEM survey images were taken prior to and immediately after the elemental analysis.

### *X-ray Micro Computed Tomography (XMCT)*

The SkyScan 1172 (SkyScan N.V., Kontich, Belgium), XMCT system was used for scanning the teeth (Cha *et al.* 2009; Farah *et al.* 2010b; Sabetrsekh *et al.* 2010; Versiani *et al.* 2011). The parameters used were: camera pixel size 9.07 µm, source voltage 74 kV, source current 120 mA, image pixel size 15.80 µm, aluminum+copper filter, rotation step 0.360°, 360° rotation, frame averaging 8, geometrical correction, flat field correction, and median filtering on.

For the analysis, the CT Analyser software package (Version 1.11.6.0+, SkyScan N.V., Kontich, Belgium) was used. For each sample in the study, the enamel grey levels (0–255) were measured in two directions.

The gray level in normal and hypomineralized enamel was measured in CT Analyser in a series of XMCT scans from the cuspal parts to the cervical parts of the crown.

### *Statistical methods*

For statistical analysis the Mann–Whitney U-test of medians was used to analyze differences between normal and hypomineralized enamel concerning the measured XRMA values of the elements; C, O, P, Ca, the ratios Ca:P and

Ca:C and for the hardness values. The Mann–Whitney U-test of medians was chosen since the values did not have a normal distribution.

### 3.3 *Decalcified specimens (II)*

#### *Tooth samples and preparation*

Five permanent first molars, extracted due to MIH, were fixated immediately after extraction in 10% neutral buffered formalin for at least 48 hours. Macrophotos of the teeth were taken from different angles in order to relate any histological findings to the clinical appearance of the teeth.

The teeth were decalcified for 1 month using formic acid/sodium citrate (22.5%). The demineralization was controlled by radiography. After embedding in paraffin blocks, serial sagittal sections in bucco-lingual direction were made in a microtome, every section with a thickness of 4–5  $\mu\text{m}$ .

Every third section was stained with haematoxylin and eosin (HTX) and every adjacent section stained with a modified Brown and Brenn (B&B) technique for staining of bacteria. The third section was left unstained. The stained sections were mounted with cover glass and examined under a light microscope.

Sections adjacent to those where bacteria were found were selected for a SEM examination. Prior to the SEM analysis the specimens were cleaned from paraffin with Xylene. Five sections, stained with the modified B&B technique, were also used for the SEM analysis after removing the cover glasses with Xylene.

#### *SEM analyses*

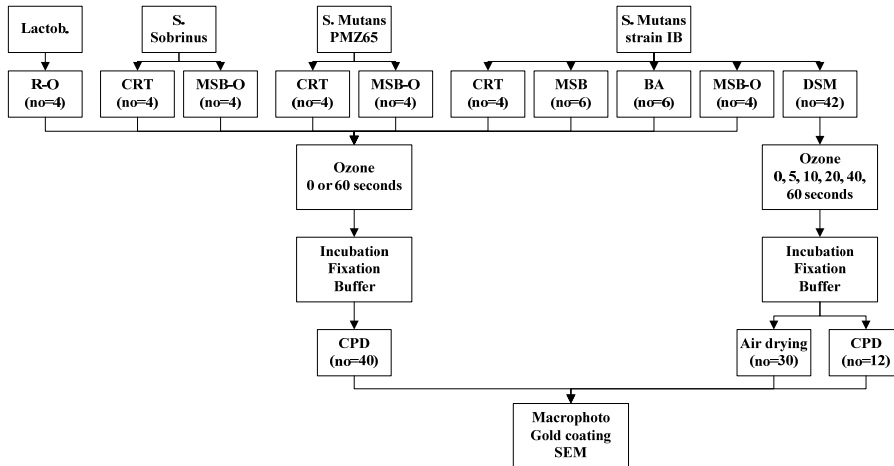
All specimens were coated with gold using vapor deposition, prior to the SEM examination. The SEM analyses were carried out in a field emission SEM (Gemini IMB, LEO 1530, Oberkochen, Germany) at 10 kV. Specimens examined with back scattered electrons were coated with a thin layer of carbon by vapor deposition.



### 3.4 Ozone treated bacteria (III)

#### Bacteria

The experimental design is shown in Figure 9. The effect of ozone was tested on four different specimens of oral bacteria (*S. Mutans* strain IB, *S. Mutans* OMZ65, *S. Sobrinus* B13 and *Lactobacilli* 90). A commercially available ozone-generating dental device, HealOzone™ 2130C (KaVo Dental, Biberach, Germany), was used for the ozone treatment.



**Figure 9.** Schematic drawing of the experimental design of the bacteria specimens. (D SM=Dentocult SM Strip Mutans; CRT=Vivacare line CRT; MSB-O=MSB-agar cultivated on object-glass; MSB=MSB-agar; BA=Blood-agar; R-O=Rogosa-agar cultivated on object glass; CPD=Critical Point Dry; SEM=scanning electron microscopy; no=number.)

HealOzone™ 2130C is a self-contained device that produces ozone at a fixed concentration of 2100 ppm through a connected hand piece. The ozone generator conforms to all European Union legislation covering medical devices [CE: 93/42/EWG (EEC)]. It has been shown that the HealOzone™ device is safe to use and does not create any detectable levels of ozone outside the treated area (Millar & Hodson 2006).

#### Preparation of microorganisms

The three strains of streptococci and the lactobacilli were cultivated on Blood agar plates and incubated in Candle Jar at 37 degrees for 24 hours. After cultivation the bacteria were re-suspended in a 0.05M phosphate buffer.

Test plates of agar with different optical density (0.1, 0.2 and 0.5) and different amounts of bacteria suspension (1, 3 and 5  $\mu$ l) were set up and arranged. The optical density (OD) was determined by a spectrophotometer at 550 nm. An OD of 0.2 and a bacteria suspension of 1  $\mu$ l were hence used.

#### *Ozone treatment*

All ozone treatment was performed by one of the authors (TF). To minimize the risk of traumatizing the bacteria suspended on the chair side test and the agars, a silicon cup with a diameter of 8 mm was used for the treatment. A new silicon cup was used for every specimen.

#### *Chair side strip tests*

*S. Mutans* strain IB was used for the analysis of chairside strip test (Dentocult SM Strip Mutans™, Orion Diagnostica Oy, Espoo, Finland). The bacteria were applied to separate strips and treated with ozone for 0, 5, 10, 20, 40 and 60 seconds, respectively. The ozone treatment was performed with a silicone cup with a diameter of 8 mm, in order to avoid any mechanical damage to the bacteria.

A total of 42 strips were treated with ozone and then cultivated in an incubator for 48 hours at 37° C. Twelve of the 42 strips were fixated in 4% glutaraldehyde for 1 minute and then stored in a 0.1 M sodium cacodylate buffer (pH 7.2) after which they were kept in a refrigerator (8° C) until they were stepwise dehydrated in ethanol (30, 50, 70, 90 and 100%) and critical point dried. The remaining thirty strips were air dried.

*S. Mutans* strain IB was also cultivated on eight CRT-agar plates (Vivacare line CRT™, Vivadent, Lichtenstein). The plates were left un-treated or treated with ozone for 60 seconds. The strips were fixated in 4% glutaraldehyde for 1 minute and then stored in a 0.1 M sodium cacodylate buffer (pH 7.2) and kept in a refrigerator (8° C) until further preparation. The strips were then stepwise dehydrated in ethanol (30, 50, 70, 90 and 100%) and critical point dried.

#### *Agar cultivation*

Bacteria suspensions (1  $\mu$ l) of the four different bacteria strains were each applied on separate blood agar plates. After application on the agar plates the bacteria were un-treated or treated with ozone for 60 seconds and then cultivated in an incubator for 48 hours at 37I C.

Suspensions of the three streptococci strains were applied on pieces of approximately 2 mm<sup>2</sup> MSB agar, fixed on object glasses. The same application model was used for the lactobacilli strain on Rogosa agar. After

incubation for 48 hours the agars were fixated by 4% glutaraldehyde for 1 minute, rinsed in phosphate buffer and then immediately placed in 0.1 M sodium cacodylate buffer (pH 7.2) and kept in a refrigerator (8° C) until stepwise dehydration in ethanol (30, 50, 70, 90 and 100%, respectively) and critical point dried.

#### *SEM analyses*

A total of 82 specimens (40 agar sand 42 Dentocult SM strips) were used for the SEM. The specimens were coated by a thin layer of gold (15-20nm) using vapor deposition. The SEM analyses were performed in a field emission scanning electron microscope (Gemini IMB™, LEO 1530, Germany) at 10 kV. All specimens were analyzed in four different magnifications (5,000x, 10,000x, 20,000x and 40,000x). Some specimens were analyzed with a higher magnification of 80,000x. In the analysis the quantity, structure and arrangement of bacteria were evaluated by two of the authors (TGF, JGN).

#### *Ethical considerations*

The teeth analyzed were all extracted due to severe MIH and were given by the patients of their own free will. After extraction the teeth were stored in unmarked plastic tubes without any possibility of identification.

### 3.5 *The clinical study (IV)*

All children participating in the study were part of the ABIS-study (Ludvigsson *et al.* 2001) and were born between October 1<sup>st</sup>, 1997 and October 1<sup>st</sup>, 1999 (22,000 patients). The study design is shown in Figure 10.

#### *MIH and SDO*

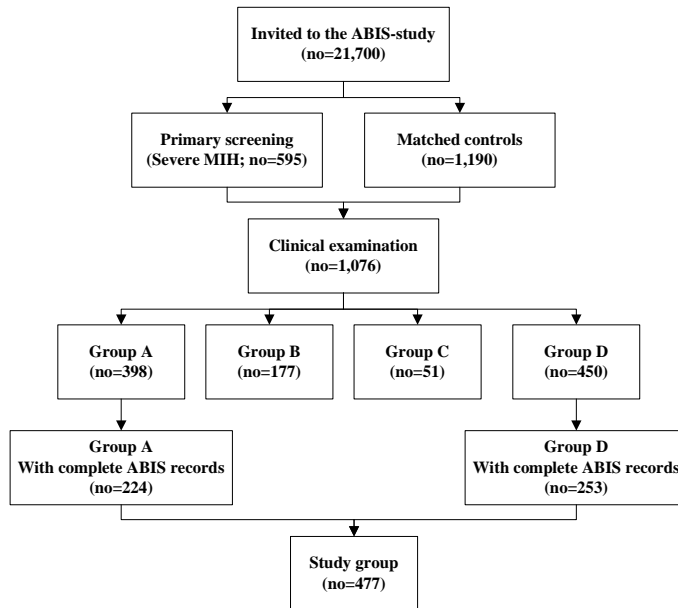
In the clinical study the term severe demarcated opacity, SDO, is used to denominate MIH. SDO is defined as severe MIH in first permanent molars with posteruptive breakdown. Further, MIH is used in the thesis synonymously to SDO.

#### *Patients and diagnostic criteria*

Information concerning the study was given to the five chief dental officers and the heads of the 89 Public Dental Service (PDS) clinics of the ABIS region (Blekinge, Jönköping, Kalmar, Kronoberg and Östergötland).

Over a two year period all children in the ABIS region were examined at their ordinary PDS clinic. In all 21,700 children were examined and checked for severe MIH using a special form for registering MIH in the first permanent molars (Appendix 1). A total of 595 forms were returned. The

PDS dentists had no knowledge if the child was participating in the ABIS study or not.



**Figure 10.** Schematic drawing of the clinical study. (Group A=Demarcated opacities with posteruptive enamel surface breakdown; Group B=Demarcated opacities without posteruptive breakdown; Group C=Other enamel disturbances, e.g. amelogenesis imperfecta, dentinogenesis imperfecta, enamel hypoplasia, dental fluorosis; Group D=No clinically detectable enamel disturbances; no=number)

Based on the 595 forms, a control group with two children matched by age and gender (1,190) was invited to participate in a clinical examination. Thus a total of 1,785 children became eligible for the study and 1,076 accepted to attend a clinical examination carried out by the research teams. The two groups were checked for complete ABIS data for the statistical analysis.

The clinical examination of the 1,076 children was performed at the children's regular dental clinic by two research teams, each consisting of two experienced specialists in pediatric dentistry (TF, GK, S-ÅL, CU). Every child was examined by both examiners in the respective team.

The following diagnostic criteria were used for grouping the examined patients:

- Group A** Demarcated opacities with posteruptive enamel surface breakdown – severe demarcated enamel opacities (SDO).
- Group B** Demarcated opacities without posteruptive breakdown.
- Group C** Other enamel disturbances, e.g. amelogenesis imperfecta, dentinogenesis imperfecta, enamel hypoplasia, dental fluorosis.
- Group D** No clinically detectable enamel disturbances.

Before the start of the clinical examinations, the members of the research teams were calibrated concerning diagnosing enamel disturbances. The calibration, which took place in a clinical setting, on 96 molars of children in the study, resulted in an inter-rater Kappa-value of 0.85.

#### *Selection of ABIS data and statistical analysis*

Information was extracted from the ABIS data base in order to compare Group A with Group D. The statistical analysis was generated using SAS/Stat software (version 9.2 of the SAS System for Windows, Copyright© 2002–2008/ SAS Institute Inc. Cary, NC, USA). Fischer's exact test was used to analyze differences in distribution of categorical variables between the groups, a p-value <0.05 was considered statistically significant. Variables with a p-value <0.2 were tested in the multivariate logistic regression model.

#### *Ethical considerations*

The children's parents received a letter with information about the study. The study was approved by the Ethics Committee of Linköping University, Linköping, Sweden (ref. no.: 96287) in accordance with the guidelines in the Declaration of Helsinki.




## 4 RESULTS

### 4.1 *Un-decalcified specimens (I, V)*

#### *SEM analyses*

At low magnification, normal enamel appeared white and bright, while hypomineralized areas appeared dark. In all specimens a porous zone of hypomineralized enamel was seen, extending from the cuspal part down to the cervical third of the enamel. The cervical third of the enamel appeared normal and the border between the hypomineralized and normal enamel was distinct (Fig. 11).

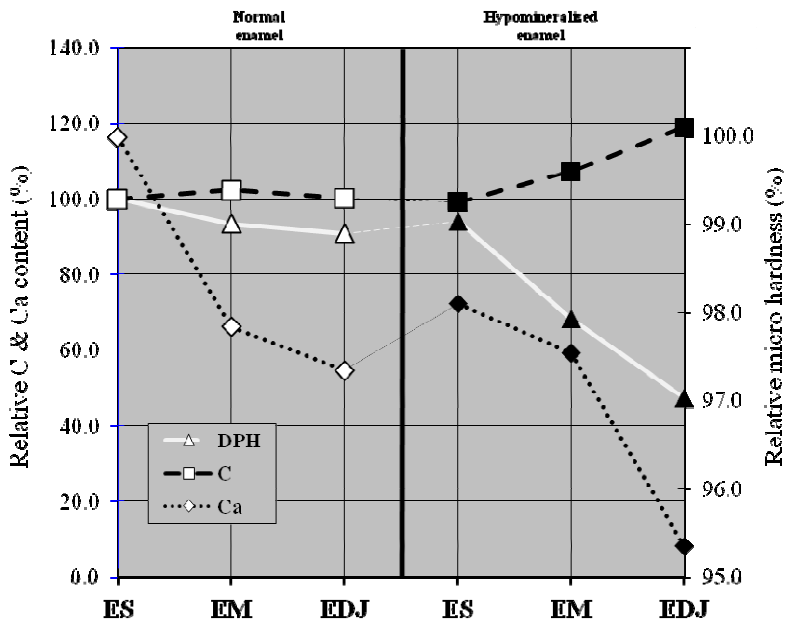


**Figure 11.** SEM image of a permanent first molar with normal and hypomineralized enamel. (NE= normal enamel; HM= hypomineralized enamel; D= dentin, C= caries, magnification x16.)

At higher magnifications, there was an apparent difference between the hypomineralized and the normal enamel. The prisms had a well-organized and distinct structure in normal enamel while the hypomineralized enamel had less organized prism structure and a larger inter-prismatic space.

Covering the enamel prisms, in the hypomineralized enamel, there appeared to be a structureless layer. Where a rupture in the structureless layer was found, enamel with irregular prism structure was seen. In specimens where the enamel was fractured, layers of structureless enamel and layers of irregular prisms with wide intra prismatic spaces were observed.

In the porous hypomineralized enamel both close to the surface and close to the enamel-dentin-junction (EDJ) bacteria were found on the prism sheets and between the prisms. Bacteria in different stages of dividing were also observed.



**Figure 12.** Graph showing the relative hardness and relative values for Ca and C in normal and hypomineralized enamel in three locations. (ES=enamel surface; EM=enamel middle; EDJ=enamel-dentin junction.)

#### *Hardness measurements*

The mean hardness values (HV) were 350.70 (range 284.00-411.00) in normal enamel, which was significantly higher compared with the mean value 244.30 (range 15.00-437.00) found in hypomineralized enamel (Fig.). The HV value of 437.00 was the highest recorded and was registered close to the enamel surface in the hypomineralized enamel.



The most marked differences for Ca were found at the EDJ with lower values in hypomineralized enamel. In contrast to what was seen in normal enamel the carbon values increased towards the EDJ in hypomineralized enamel.

The relative percentage values for HV were inverted to the carbon values in the hypomineralized enamel, with a steep slope towards the EDJ. The relative micro hardness values paralleled the relative carbon values in normal enamel; however, in hypomineralized enamel, the relative micro hardness values decreased from the enamel surface towards the EDJ, becoming almost parallel to the relative calcium values (Fig. 12).

### *XRMA*

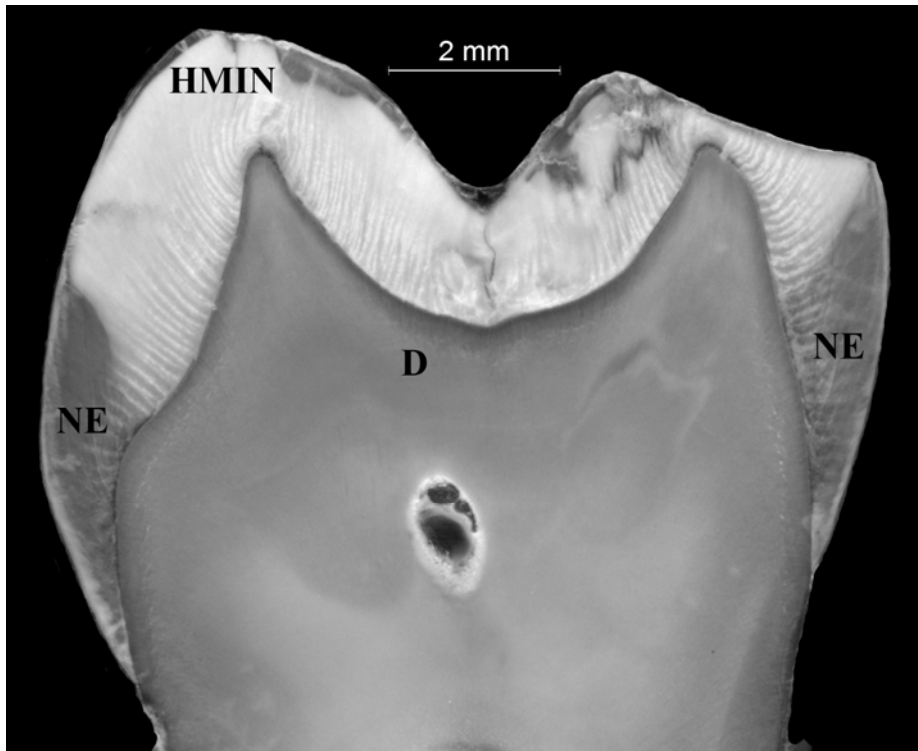
The median value for C was statistically significantly higher in hypomineralized enamel compared with normal enamel ( $p < 0.01$ ) while P and the Ca:C ratio had significantly lower median values in hypomineralized compared with normal enamel ( $p < 0.01$ ). The other elements in the XRMA analyses, the mean and median values of C, O, P and Ca as well as the C:P and Ca:C ratios, were calculated for the three measurements in each specimen. Since the measured XRMA values did not have a normal distribution the statistical analysis carried out for the median showed no statically significant differences.

In further analyses, the HV values and the values for Ca and C were normalized to respective values at the surface of normal enamel and the relative values for hardness. By calculating the percentages of Ca, C and hardness values they could be presented as relative percentages in relation to the values of the surface of normal enamel (Fig. 12). The relative values for Ca, C and HV were thereby 100% at the normal enamel surface.

The most marked differences for Ca were found at the EDJ with lower values in hypomineralized enamel. In contrast to what was seen in normal enamel the carbon values increased towards the EDJ in hypomineralized enamel. The relative percentage values for HV were inverted to the carbon values in the hypomineralized enamel, with a steep slope towards the EDJ.

### *LM analyses*

Normal and hypomineralized enamel differed clearly in the LM analyses. Hypomineralized enamel appeared more opaque than normal in incident light. The color of the hypomineralized enamel was white to beige. Normal mineralized enamel gave a translucent appearance. In ground sections of both normal and hypomineralized enamel, prisms, Hunter-Schreger band and Retzius lines were easy to locate (Fig. 13).



**Figure 13.** Light microscopic images of an un-demineralized sagittal section of a permanent first molar seen in incident light with hypomineralization extending over the occlusal area of the crown. (HMIN=hypomineralized enamel; NE=normal enamel; D=dentin.)

A correlation was seen between the degree of opaqueness and the degree of hypomineralization (degree of porosity) in the analyzed sections. This correlation implied that the more opaque the enamel appears, the more porous it is. A positive correlation was also found between the degree of opaqueness and the extension of hypomineralized enamel towards the enamel surface.

The location of hypomineralization was registered in sagittal and radial sections in all teeth. Hypomineralization was mainly found at the buccal cusps and started at the EDJ and increased towards the enamel surface due to its severity. In the case of more severe MIH, the hypomineralized area extended over to the occlusal and lingual/palatinal areas of the crown. Most of the examined teeth displayed enamel breakdown and caries lesions. The cervical extension reached from half to 2/3 of the coronal height.

Four of the examined teeth in the LM analyses were from the same patient. There was a great variation in hypomineralization between the four teeth, where one tooth was clearly more affected than the others, both in severity and extension.

In all sections, the transition between hypomineralized and normal enamel seemed to follow a prism and could not be related to the incremental lines.

The surface zone of the analyzed teeth most often consisted of a thin layer of normal enamel. However, in some sections of severe hypomineralization, the porous enamel extended all the way to the surface.


### *POLMI*

POLMI analyses were performed on all sections analyzed in LM. In the areas corresponding to the translucent areas (normal enamel) the enamel appeared bluish at the surface, when seen dry in air (positive birefringence). The remaining portion of the enamel appeared with a red color (positive birefringence).

After water imbibition the red color turned blue, indicating a pore volume less than 5%. As in the LM analyses, the Hunter-Schreger bands and the Retzius lines were readily seen. The surface enamel appeared normal. However, in some sections a thin hypomineralized band could be seen extending over parts of the enamel surface (Fig. 14).

The opaque areas had in the examinations, dry in air, a color ranging from dark brown to dark yellow, the darkest color was seen in the central part of the enamel. After water imbibition the brown-yellow color remained in the central part of the hypomineralization, indicating a pore volume of more than 5%. The central part of the hypomineralized enamel extended from the EDJ to the enamel surface. The borders of the central part of the hypomineralized enamel were distinct and followed a prism. The enamel surface had a yellow color that remained yellow after water imbibitions. Surrounding hypomineralized enamel changed color from brown to yellow or red, indicating a pore volume of around 5%.

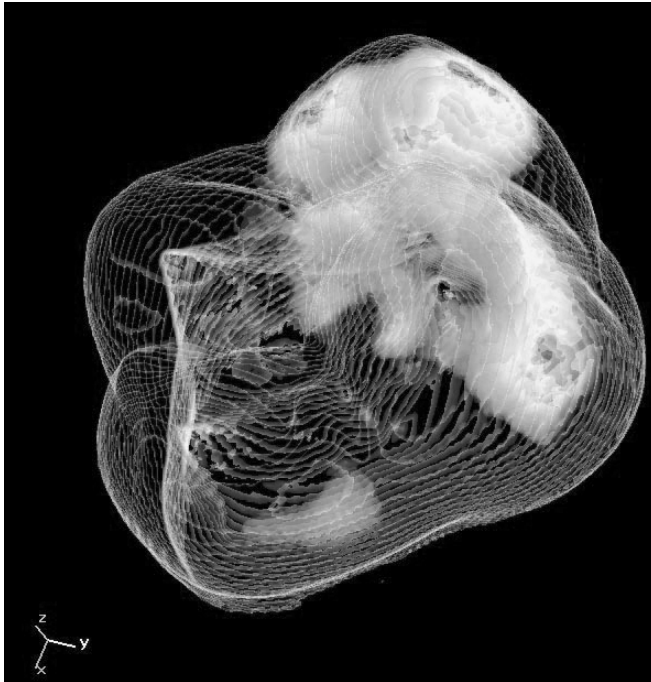The structure of the enamel in the opaque areas was less distinct compared with enamel in the translucent areas.



**Figure 14.** Un-demineralized sagittal section of a permanent first molar seen in polarized light after water imbibition. A hypomineralized lesion is seen as a darker area extending from the enamel-dentin junction towards the surface with a porous surface zone. To the left of the lesion the enamel has a normal degree of mineralization and a normal surface zone. (HMIN=hypomineralized enamel; NE=normal enamel; D=dentin; PES=porous enamel surface; NES=normal enamel surface.)

#### *X-ray Micro Computed Tomography (XMCT)*

The XMCT made it possible to show the extension of hypomineralization in three dimensions. The XMCT revealed hypomineralization as a coherent volume of tissue with a higher degree of radiolucency than normal enamel. The origin the hypomineralization was at the enamel-dentin-junction (Fig. 15).

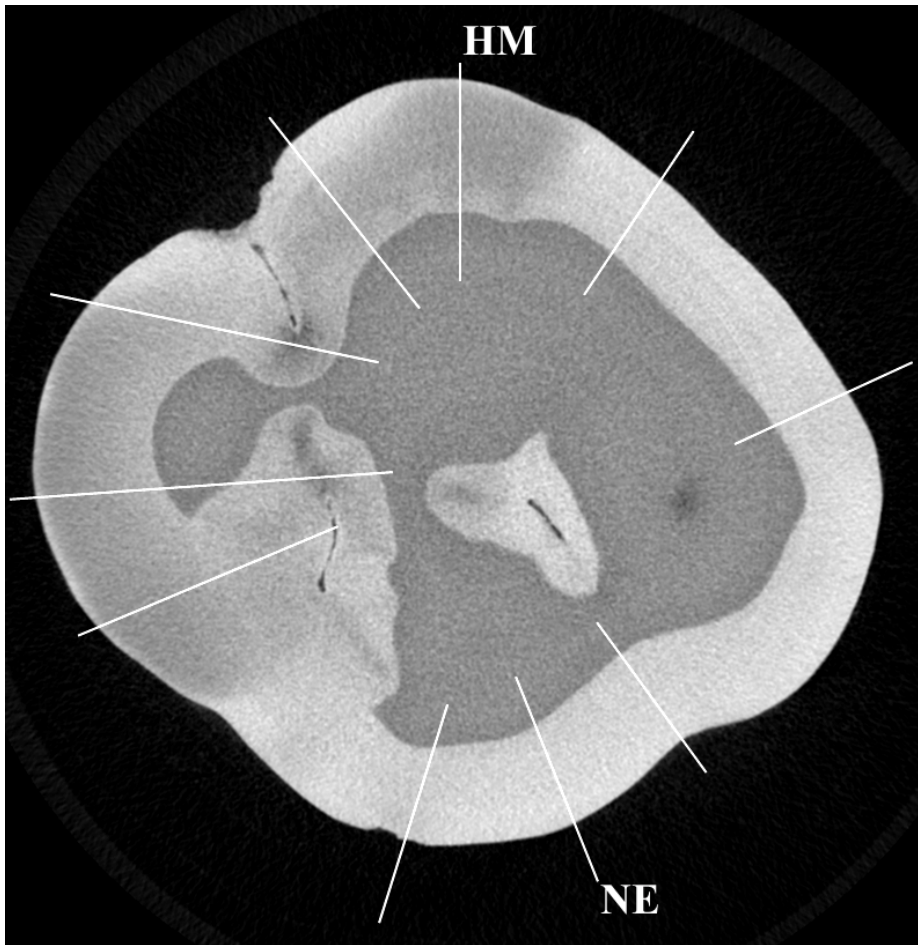


**Figure 15.** Example of a 3D X-ray micro-computed tomography image of an MIH tooth. The more compact areas represent hypomineralized enamel.

As in the LM analyses the hypomineralized enamel was mainly located in the buccal side of the tooth crown. The enamel around the mesio-buccal cusp being the most affected and followed by the disto-buccal cusp, a more limited hypomineralized area was seen in the disto-lingual cuspal area. In the analyzed tooth, the hypomineralized enamel did not extend into the outermost part of the cusp. The XMCT findings were confirmed in serial sections analyzed in LM (incident light) and POLMI.

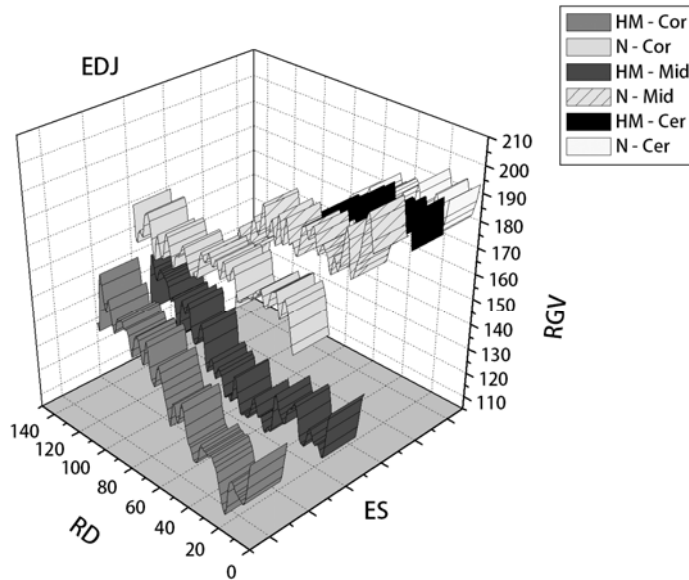
#### *Gray level measurement*

Measurements of the relative gray scale values were made in the radial XMCT images (27 images). The same locations were used in all images to measure the relative gray value intensities of the enamel in normal and hypomineralized enamel (Fig. 16).



**Figure 16.** X-ray micro-computed tomographic image of a MIH with lines indicating location for the gray level measurements in normal and hypomineralized enamel. (HM=hypomineralized enamel; NE=normal enamel.)

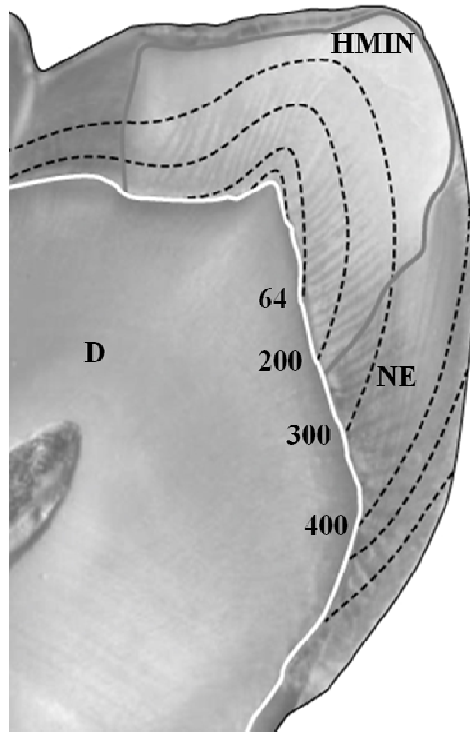
In the coronal and middle parts of the enamel the relative gray scale values were markedly higher in normal enamel compared with hypomineralized enamel. In the hypomineralized enamel the relative gray values decreased from the EDJ towards the enamel surface, while the values in normal enamel, irrespective of location, had a slight increase towards the enamel surface (Fig. 17). The cervical enamel in both locations represented relative gray values of normal enamel.



**Figure 17.** 3D ribbon plot of relative gray level measurements from the enamel surface towards the enamel-dentin-junction in X-ray micro-computed tomographic radial images of a tooth diagnosed with MIH. (HM-Cor=hypomineralized enamel coronal part; N-Cor=normal enamel coronal part; HM-Mid=hypomineralized enamel middle part; N-Mid=normal enamel middle part; HM-Cer=hypomineralized enamel cervical part; N-Cer=normal enamel cervical part; ES=enamel surface; EDJ=enamel-dentin-junction; RGV=relative gray value; RD=relative gray value.)

#### *Timing of hypomineralized enamel*

Incremental lines were easily discernable in both the radial and the sagittal ground sections. In the estimation of the appositional enamel growth over a certain time, only central sagittal sections of the crown were used. An estimation of the timing of the hypomineralized lesion was performed using a modified version of a histological-derived method described by Boyde (1963, 1990) and Mahoney (2008, 2010, and 2011). The most central mesial-sagittal sections in all teeth were used for the analyses. An image of the most central mesio-buccal was compared with a schematic drawing of the same area with incremental lines. The cervical extension of hypomineralization in six of the analyzed teeth (3 mandibular, 3 maxillary) was equal to a relative extension of 200 days and to a relative value of 300 in one (maxillary) first permanent molar. The hypomineralization started just below the dentin cusp in five of the analyzed teeth (2 mandibular, 3 maxillary). In the remaining two mandibular teeth the hypomineralization started at the top of the dentin cusp (Fig. 18).



**Figure 18.** Demineralized sections from permanent first molars diagnosed with MIH, stained with the modified Brown & Brenn technique. *Left:* Staining of bacteria in the cuspal parts of the dentin (magnification  $\times 40$ ). *Right:* Stained bacteria in carious dentin deep to the occlusal surface (magnification  $\times 40$ ).

#### 4.2 *De-calcified specimens and bacteria (II)*

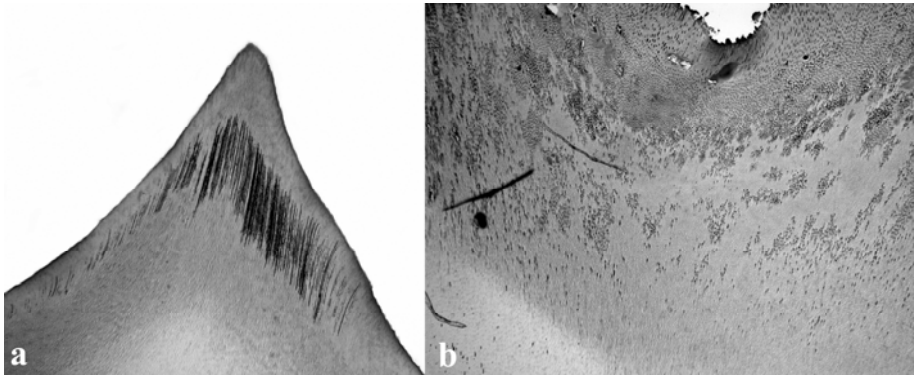
##### *Light microscopic examinations*

##### Brown and Brenn staining

In sections under the cuspal parts of the hypomineralized enamel, the dentinal tubules showed a bluish staining, indicating the presence of Gram-positive bacteria. Bacteria were also found in the proximal parts of the cuspal dentin. In one specimen, bacterial staining could be seen close to the pulp (Fig. 19).

In one of the specimens with an occlusal caries attack a massive staining in the dentin tubules was observed, as well as in the pulp (Fig. 19).

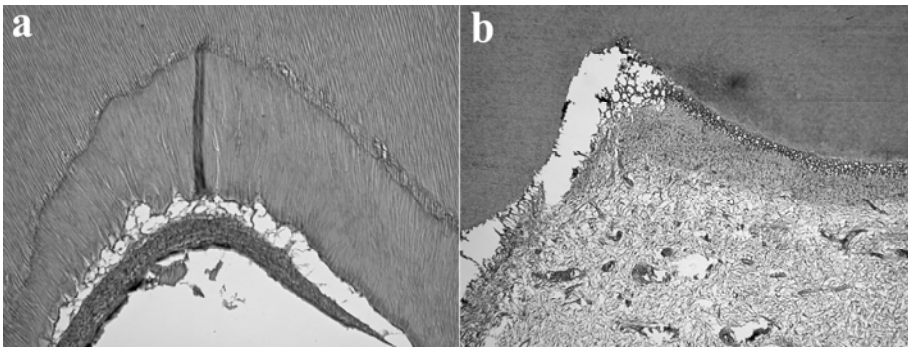




**Figure 19.** Demineralized sections from permanent first molars diagnosed with MIH, stained with the modified Brown & Brenn technique. a: Staining of bacteria in the cuspal parts of the dentin (magnification  $\times 40$ ). b: Stained bacteria in carious dentin deep to the occlusal surface (magnification  $\times 40$ ).

#### HTX-staining

In sections adjacent to a specimen with bacterial findings, zones of reparative dentin in the pulp were noted. An inflammatory reaction with inflammatory cells was found in one tooth. The pulp showed a normal appearance in sections adjacent to samples free of bacteria (Figs. 20).

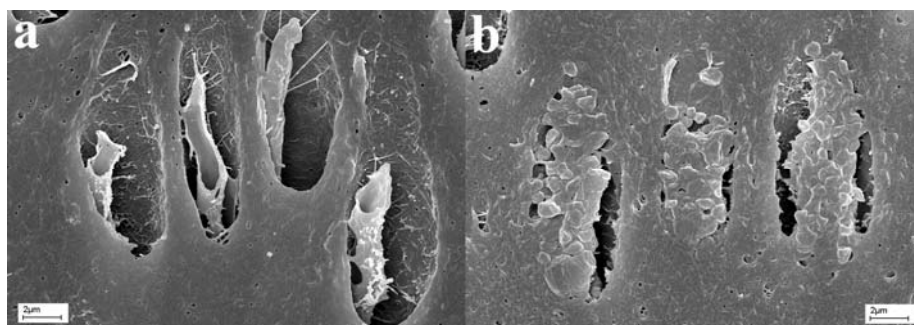


**Figure 20.** Demineralized sections from permanent first molars diagnosed molar incisor hypomineralization, stained with haematoxylin and eosin. a: A zone of reparative dentin in the pulp deep to cuspal dentin with bacterial staining (magnification  $\times 40$ ). b: Inflammatory reaction in the pulp deep to cuspal dentin with bacterial staining (magnification  $\times 40$ ).

### SEM examinations

Unstained sections next to those without bacteria staining and sections next to those with bacteria staining were selected for the SEM analysis. In sections without bacteria staining only empty tubules without odontoblast process or bacteria were seen. However, odontoblast processes were more often found closer to the pulp.

In the sections that were selected next to a section with bacteria staining the SEM analysis revealed that when odontoblast processes were found, their surface was covered with bacteria (Fig. 21).



**Figure 21.** Sections of demineralized dentin with dentinal tubules with odontoblast process examined in a scanning electron microscope. *a*: Odontoblast process without bacteria (magnification  $\times 5000$ ). *b*: Odontoblast processes covered with bacteria (magnification  $\times 5000$ ).

The odontoblast process was often damaged. Tubules with odontoblast processes covered with bacteria were predominant in some areas. The odontoblast processes appeared larger in areas with bacteria findings and measurements in SEM revealed a diameter twice as large compared with normal odontoblast process. Dentin tubules in connection to the caries attack were massively filled with bacteria.

When the sections were examined by backscattered electrons no contrast was seen between the odontoblast process and the bacteria, indicating that both structures had the same basic organic structure.

Sections next to those with stained bacteria were also examined by backscattered electrons, revealing no bacteria in areas with staining. The possibility of presence of bacteria in non-open tubules cannot be excluded.

The B&B-stained sections, which in the light microscope were examined with backscattered electrons, revealed no presence of bacteria in

areas with staining. The open tubules revealed no bacteria; however, the possibility of bacteria in non-open tubules may not be excluded. Nevertheless, bacteria were found deeper into the dentin as in the other samples.

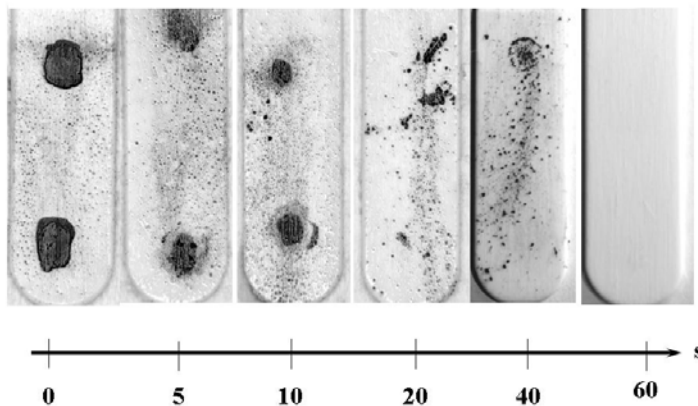
#### 4.3 Ozone treated bacteria (III)

##### *Optical Density (OD)*

Bacteria suspensions with different OD (0.1, 0.2 and 0.5) were incubated for 48 hours. No difference was found in the bacteria colonization between the different OD, which was in contrast to the ozone treated groups where there was a positive correlation between the OD and number of bacteria. Therefore, an OD of 0.2 was regarded as suitable for further studies.

##### *Evaluation of ozone treatment on bacteria on cultivation strips*

A macroscopical examination of the chair side cultivation strips was performed prior to the SEM analysis which showed a limited effect on the bacteria *S. Mutans* IB strain IB treated with ozone for 5-10 seconds. However, bacteria treated 20 seconds or more showed no bacterial growth, while the none-treated bacteria, used as controls, showed extensive growth (Fig. 22).



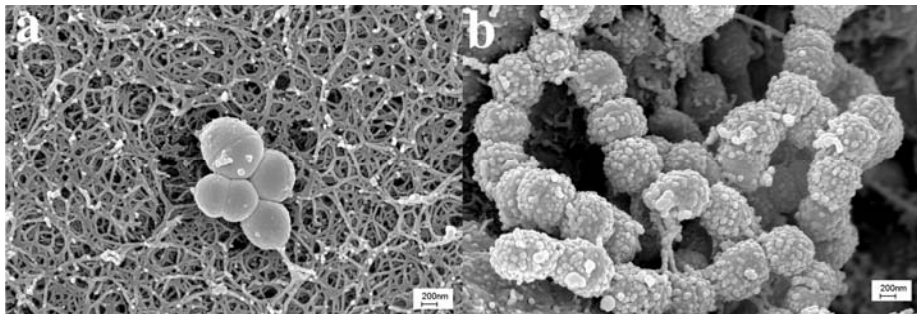
**Figure 22.** Growth of *S. Mutans* strain IB on Dentocult SM Strip Mutans after no ozone treatment and after ozone treatment for 5, 10, 20, 40 and 60 seconds, respectively. Microorganisms exposed for >20 seconds showed a minimal macroscopical growth while the non-treated samples showed extensive growth.

### *SEM analysis*

Bacteria were found in all samples. Non-ozone treated bacteria or bacteria treated only for 5 and 10 seconds showed bacteria colonies that had grown in height. Further, a large number of bacteria in stages of cell-division were seen. This was in contrast to bacteria treated with ozone for 20, 40 or 60 seconds, respectively. Only few bacteria arranged in a monolayer were found (Figs. 23).

Bacteria treated with critical dry-point technique before the SEM analysis appeared somewhat sharper and more distinct compared with those which were air-dried.

In the SEM analysis, the bacteria, cultivated on the three different agars (Blood-agar, Rogosa-agar and MSB-agar), showed a similar pattern, as on the strips. No growth was seen in the samples treated with ozone for 60 seconds. The same appearance was seen for the three different Streptococci; *S. Mutans* strain IB, *S. Mutans* OMZ65, *S. Sobrinus* B13 and for the *Lactobacilli* 90. Extensive growth was seen on the none-treated bacteria. The number of bacteria was high and formed multiple colonies. A larger polysaccharide production was also seen in the none-treated samples.



**Figure 23.** SEM images of *S. Mutans* strain IB (OD 0.2). *a*: No ozone treatment, rich growth and polysaccharide production is seen. *b*: Ozone treated for 60 seconds, no growth or polysaccharide production is seen (Magnification x20 000).

#### 4.4 *The clinical study (IV)*

Due to the large number of variables in the clinical study, these variables were grouped into five subgroups and each subgroup will thus be presented separately (Table 2). No statistically significant differences were found between the study and the control group for any of the variables in the first three subgroups.

##### *Socio-economic factors during birth–3 years*

Of the socioeconomic factors “the mother’s education level” ( $p < 0.01$ ) and “domestic moisture and mould” ( $p < 0.02$ ) differed statistically significantly between the study and the control group. These two variables were used in the multivariate regression model, in which, however, the statistically significant difference disappeared (Table 3).

##### *Nutrition during birth–3 years*

The variables concerning nutrition: “breastfeeding more than 6 months” ( $p < 0.03$ ), “late introduction of gruel (after 6 months)” ( $p < 0.02$ ), and “late introduction of infant formula (after 6 months)” ( $p < 0.01$ ), showed a statistically significant difference between the study and the control group (Table 3). A statistically significant difference was also found for “daily intake of vegetables (mother year 1)” ( $p < 0.03$ ) and “egg 2 times/w (mother year 1)” ( $p < 0.02$ ). However, the only variables that remained statistically significant after the multivariate logistic regression model were “breastfeeding more than 6 months”, “late introduction of gruel (after 6 months)”, and “late introduction of infant formula (after 6 months)”. In a combination of the three variables; the OR increased by over five times (OR 5.1; 95% CI 1.6–15.7) (Table 4).

**Table 2.** Subgroups and variables for the univariable analysis and for the multivariable model,  $p < 0.2$ .

**1.Pre-, peri- and neonatal problems in the child and/or the mother**

Family diseases i.e. thyroid disorders, B12 deficiency, adrenal deficiency, celiac disease, rheumatoid arthritis; family allergies i.e. cow's milk-, lactose-, food allergy or asthma; family situation; birth country mother, father.

**Medication during pregnancy**

Antibiotics, cortisone, blood pressure medication, psychopharmacology medication, painkillers, hormone therapy, chemotherapy, other medication, smoking during pregnancy, pregnancy diabetes/gestational diabetes.

**Delivery**

Delivery week, birth weight, type of delivery.

**Infectious diseases of mother during pregnancy**

**Neonatal complication of the child (birth-1 month)**

Infections, respiratory problems, jaundice, phototherapy, blood transfusion, Rh immunization, other blood group immunization.

**2.Common childhood illnesses during birth–3 years**

**Illnesses 1–12 months**

Upper respiratory infections, otitis media, lower respiratory infections, stomach flu, other infection, other disease.

**Infectious diseases 1–12 months**

Measles, rubella, mumps, chickenpox, pertussis, other infectious diseases, illnesses 1/12m, cold, stomach flu, infection which need antibiotics treatment, flu, cow's milk allergy, eczema, asthma/bronchitis.

**Illnesses 1–3 years**

Cold, tonsillitis, otitis media, pneumonia, meningitis, infection which need antibiotics treatment, stomach flu, flu, three-day fever, poor weight gain, psychiatric problems, other illnesses, asthma, poor appetite, diabetes, gluten intolerance, other allergy.

**Infectious diseases 1–3 years**

Measles, rubella, mumps, chickenpox, pertussis, other infectious diseases.

**3.Medication and vaccination during birth–3 years**

**Medication, 1–12 months**

Medication 1-12 month y/n, antibiotics, vitamin AD drops 1-12 month y/n, vitamin AD drops 1-2,5y y/n, Other vitamin and/or mineral supply 1-12m y/n, Other vitamin and/or mineral supply 1-3y y/n, Iron tablets 1-12m, Iron tablets 1-3y y/n.

**Medication 1–3 years**

Nose drops, painkillers–paracetamol, painkillers–ASA, antibiotics–PcV, antibiotics–others, bronchitis medication, cortisone, cough drops, other medication.

**Vaccinations**

BCG/Calmette, polio, tetanus, diphtheria, measles, mumps, rubella, hepatitis B, pertussis, hemophilus, other vaccination, followed the Swedish vaccination program the first 3y.

**4.Nutrition during birth–3 years**

Consumption water (private well /municipal water supply), cow's milk introduction, gluten intolerance, weekly intake of venison (mother birth, year 1), weekly intake of pork (mother birth, year 1), weekly intake of beef (mother birth, year 1), weekly intake of mushroom (mother birth, year 1), Baltic sea fish (mother birth, year 1), other fish (mother birth, year 1), Introduction of infant formula (1-5m v 6m-), Breastfeeding (1-5m v 6m-). Introduction of gruel (1-5m v 6m-), Daily intake of vegetables (mother year 1), Egg 2 times/w (mother year 1).

**5.Socio-economic factors during birth–3 years**

Gender, living area, education level (father), age (mother), age (father), siblings y/n, do mother/father work professionally, does mother consider herself healthy, domestic smoking mother/father, BMI (mother), BMI (father), born summer/winter, domestic smoking mother/father (yr 1), self estimation of health (yr 1), domestic high level of radon, Education level (mother) ( $\leq$  upper secondary school v  $\geq$  university), Domestic moisture and/or mold (y v n).

**Table 3** Result from the univariable logistic regression with SDO as the outcome variable.

Variables	n	OR	95% CI	p-value
<i>Introduction of infant formula</i>	309		1.2-2.9	0.01
1-5m	132	Reference		
≥6m	177	1.9		
<i>Breastfeeding</i>	373		1.1-3.2	0.03
1-5m	66	Reference		
≥6m	307	1.9		
<i>Introduction of gruel</i>	305		1.1-3.6	0.02
1-5m	64	Reference		
≥6m	241	2.0		
<i>Education level (mother)</i>	461		1.1-2.5	0.01
≤Upper secondary school	319	Reference		
≥University	142	1.6		
<i>Domestic moisture and/or mold</i>	303		1.1-6.0	0.02
No	276	Reference		
Yes	27	2.6		

**Table 4** The final logistic regression model with the grouping of three explanatory variables that combines long breast feeding and late introduction of gruel and infant formula compared to the control group and SDO as outcome.

Variables	n	OR	95% CI	p-value
<i>Introduction of gruel &gt; 6 mths</i>				
<i>Breastfeeding &gt; 6 mths</i>	173	5.1	1.6-15.7	0.02
<i>Introduction of infant formula &gt; 6mths</i>				



## 5 DISCUSSION

This thesis has focused on developmental disturbance in the enamel of permanent first molars, denominated as MIH and with special emphasis on areas of histological, chemical and mechanical properties, symptoms, onset and etiology.

The main findings were that the hypomineralized enamel was mainly located in the buccal enamel of the teeth and had a high degree of porosity extending from enamel-dentin-junction (EDJ) towards the enamel surface and with a distinct border to the normal cervical enamel. Teeth diagnosed with MIH have significantly lower hardness values (HV) in hypomineralized enamel as compared with normal enamel and also display differences in chemical composition. As an effect of the porous enamel, bacteria were observed in the enamel and deep into the dentin. Ozone-treatment for 20 seconds or more was effective in killing different oral microorganisms involved in the caries process. The onset of hypomineralized enamel was estimated at a period with relative values around 200 days from start of enamel mineralization. In the clinical study a statistically significant relation was found between MIH in first molars and breast feeding more than 6 months, late introduction to gruel and infant formula (later than 6 months).

### 5.1 *Methodological considerations*

#### *Tooth samples*

The tooth material in the thesis consisted of totally 22 permanent first molars with the diagnosis MIH. All diagnoses were set prior to extraction by the author (TF) and confirmed by the histological analysis. The number of teeth analyzed is in line with the number in other histological studies of MIH (Farah *et al.* 2010a, b; Fearné *et al.* 2009). In order to gain the most possible information from each tooth different analytical methods were applied on the same tooth and/or section when possible.

#### *Cutting of un-demineralized enamel*

The cutting of the un-demineralized enamel was made by low speed microtome with a diamond saw blade and under water cooling, which is an established method for the preparation of un-decalcified specimens. A limitation is the loss of substance during cutting depending on the thickness of the saw blade. However, careful cutting with minimum pressure and gluing an object glass on the cut surface minimized artifacts.

### *SEM*

SEM analysis is a frequently used method for morphological examinations of teeth or tooth sections thanks to its properties of making very high-resolution images of a sample surface, revealing details less than 1 nm in size (Schatten & Pawley 2007). For imaging in SEM the enamel has to be etched with for example phosphoric acid which, to some extent, introduces artifacts that must be taken into consideration in the analysis of the images. By coating the sample surface with gold the reflected signals are increased and build up of surface charging is avoided.

For the analysis of bacteria only minor differences were seen between air-dried bacteria specimens and those prepared according to the critical point drying method. Therefore, air drying was chosen, especially since it was only possible to analyze the demineralized specimens after air drying.

### *XRMA*

XRMA is not to be regarded as a surface analytical method since K- $\alpha$  radiation is emitted from a pear-shaped volume below the surface (depth 1-2  $\mu\text{m}$ ). As for imaging in SEM, a thin coating to avoid build up surface charging must be used. Depending on instruments and software used, in principle any type of conducting material may be used. For the analysis carried out in this thesis a carbon coating with a thickness of 10-15 nm was used. The software compensated for the carbon layer in the calculations of the measured elements.

### *Hardness tests*

Measurement of the micro hardness was performed by a Vicker's hardness tester, a micro indentation technique that has often been used for hardness measurements of enamel, and is a suitable hardness measurement method of dental hard tissues (Fearne et al. 2004, Cuy et al. 2007).

### *XMCT*

Micro computed tomography or "micro-CT" is X-ray imaging in 3D on a small scale with extremely increased resolution. A very fine scale internal structure of objects is imaged non-destructively. Without sample preparation, staining or sectioning a single scan can image a sample's complete internal 3D structure at high resolution. After an XMCT scan the sample may be sectioned and used for other more conventional histological or analytical methods. XMCT has become an important tool for dental hard tissue studies combining a non-destructive high resolution method with information on internal variations in the degree of mineralization and its extent within the tissue (Cha et al. 2009; Farah et al. 2010b; Sabetrasekh et al. 2010; Versiani et al. 2011).

*Modified Brown and Brenn staining for bacteria (B&B)*

This B&B staining method is a modification of Taylor's modification of the Brown-Brenn staining for bacteria. The modification reduces the staining time, but also eliminates the use of ether; a laboratory safety hazard. B&B has a history of being insensitive, particularly with regard to the observation of gram-negative bacteria (Pinheiro *et al.* 2003; Ricucci & Bergenholtz 2003). In order to minimize the insensitivity the tissue section should not be allowed to dry out at any point during the staining procedure. If the section is allowed to dry out, the staining will be inadequate.

*Optical density*

Optical density is an expression of the transmittance of an optical element. If the value of optical density is high, the transmittance of the solution is low. In an OD of 0.2 the bacteria were readily found and therefore chosen.

*Ozone*

A recent study has discussed the effectiveness of ozone in the oral environment, influenced by the oral bio film (Müller *et al.* 2007). It must be remembered that the ozone treatment in this study was carried out under laboratory conditions and the results may therefore not be directly transferred to the more complex clinical situation. This thesis has only shown the effect of ozone on single strains, which is why conclusions cannot be drawn concerning dental caries in a more complex situation with different bacteria present and different anatomical conditions of the tooth. Therefore, factors such as penetration depth of the ozone, different anatomical variations and the influence of the oral bio film must be subjected to future research.

*The clinical study*

The 17.055 individuals participating in the ABIS study were scattered over five Swedish counties. The ABIS population may be regarded as representative for the general Swedish population (SCB 1999).

The data in the ABIS study was collected prospectively; however, the clinical examination of children with MIH should be regarded as a retrospective study carried out within a prospective study. When the collaboration with the ABIS study started, it had already been ongoing for some years and there were no possibilities to influence the collection of data or any other parameters. Nevertheless, the amount of variables collected and the number of participants still made the ABIS study an excellent opportunity for an etiological study of MIH.

## 5.2 *Ethical considerations*

### *Tooth samples*

None of the collected teeth diagnosed with MIH were extracted but for strict odontological reasons, due to severe hypomineralized enamel. The patients and their parents were informed of the ongoing studies and the possibility of donating the extracted teeth to the project of their own free will. The donated teeth were stored in 70% ethanol without any possibility of identification. In a longer perspective the collected teeth may be of importance for understanding the reasons for subjective symptoms, relevant treatment and also possible etiological factors.

### *The clinical study*

In the clinical study a primary screening was performed during the patients' regular dental visits. All patients and their parents received written information about the clinical study and the collaboration with the ABIS study and that participation was voluntary. If any dental problems were found in the clinical inspection, the responsible dental personnel were informed. The clinical examination of patients with MIH and the controls were carried out in connection to the regular check-up as far as possible. No acts of intervention were carried out; however, the inconvenience for the parent and patient participating in any study must be recognized.

## 5.3 *Un-decalcified specimens*

Hypomineralized enamel in first permanent molars was mainly located in the buccal enamel of the teeth and had a high degree of porosity extending from enamel-dentin-junction (EDJ) towards the enamel surface. These findings have been demonstrated in previous studies (Jälevik *et al.* 2001b; Fearné *et al.* 2004; Farah *et al.* 2010b).

The distinct cervical border between hypomineralized and normal enamel in MIH following a prism coincides with previous findings (Jälevik *et al.* 2001b). This is contradictory to a previous study where the defects seemed to follow the incremental lines of enamel formation (Farah *et al.* 2010a).

In the LM analyses there were co-variations between the reflected opaqueness and the degree of hypomineralization (degree of porosity). The more opaque in incident light, the more porous it is. These findings were confirmed in POLMI analyses. The same results were found by Da Costa-Silva, who used the opaqueness and color of hypomineralization to determine the degree of hypomineralization and a similar result has been demonstrated

where the darkest and most opaque areas were the most hypomineralized (Farah *et al.* 2010a; Da Costa-Silva *et al.* 2011).

After acid etching of un-demineralized sections, a structureless layer became visible in SEM. This may be an effect of the higher organic component of the hypomineralized enamel, since the etching will expose the organic part of the prism sheets. When a rupture in the structureless layer was seen, the underlying prisms were exposed and probably unaffected by the acid etching. In higher magnifications, these prisms showed a porous structure and loosely packed crystallites, which is in line with findings in other studies (DenBesten *et al.* 1989; Angker *et al.* 1991; Kodaka *et al.* 1992; Jälevik *et al.* 2001; Fearné *et al.* 2004; Gao *et al.* 2004; Mahoney *et al.* 2004a, b; Braly *et al.* 2007; Cuy *et al.* 2007; Xie *et al.* 2007, 2008). The disorganized prisms, the wide prism sheets and the structureless organic layer seen after acid etching will very likely be negative for the success of filling therapy, with short function as well as an extended micro leakage, which are some of the clinical problems with teeth affected by MIH (Zivković *et al.* 2001; Mejàre *et al.* 2005).

In the SEM analyses, bacteria were found close to the surface as well as close to the EDJ, which may be explained by the porous enamel in the hypomineralized enamel. This finding is supported by a study of decalcified teeth diagnosed with MIH where bacteria had penetrated through hypomineralized enamel and into the dentin and to the pulp (Fagrell *et al.* 2008). The enamel surface of a tooth affected by MIH has earlier been described as being a thin normal outer layer (Jälevik *et al.* 2001b). In the teeth analyzed in this thesis a normal outer layer was seen interrupted by a porous surface zone in the central part of the hypomineralized enamel. This porous surface zone may therefore constitute a possible pathway for bacteria and other matter to penetrate through the enamel into the dentin, reaching the pulp. It is therefore reasonable to believe that the hypersensitivity in teeth affected by MIH is explained by bacteria penetration.

The XRMA analyses showed a higher relative carbon content in hypomineralized enamel in comparison with the normal enamel. Similar results have been presented in other studies (Jälevik *et al.* 2001b, Xie *et al.* 2008). A higher organic content in the hypomineralized enamel in the intra- as well as the inter-prismatic regions has also been shown (Xie *et al.* 2008).

The Ca:P ratio did not differ significantly between normal and hypomineralized enamel, which is in agreement with several other studies (Mahoney *et al.* 2004a, b, Suckling *et al.* 1989). This is in contrast to a previous study (Jälevik *et al.* 2001b). However, other studies have reported a

stable Ca:P ratio irrespective of differences in the degree of mineralization (Kodaka *et al.* 1991). The conflicting results in literature have been discussed, leaving the reasons open for further discussion as to what the Ca:P ratio actually represents (Mahoney *et al.* 2004b).

In the hypomineralized enamel a higher relative value for P was observed in the XRMA analyses which possibly may derive not only from the hydroxyapatite but also from the organic matter.

The results of the hardness measurements displayed lower values for hypomineralized enamel compared with normal enamel and are in line with results from other studies (Suckling *et al.* 1989; Angker *et al.* 1991; Mahoney *et al.* 2004a, b). The indentations in the enamel were not dependent on prism orientation or variations in the chemical composition (Braly *et al.* 2007; Kodaka *et al.* 1992). However, there was a relationship of micro hardness and the Ca:C ratio seen in both normal and hypomineralized enamel. The relative micro hardness values decreased from the enamel surface towards the EDJ, becoming almost parallel to relative calcium values, indicating that variations in the Ca:C ratio influence the hardness.

#### 5.4 *De-calcified specimens and bacteria*

Both in the sections with B&B staining and in the SEM analyses, bacteria were found in the dentinal tubules in the cuspal parts of teeth with MIH with apparently intact enamel. The bacteria penetration was found throughout dentin. In young permanent teeth, the dentinal tubules are wide, which is why any bacteria penetration will not be limited by tubular mineralization and obliteration as seen in older dentin (Carrigan *et al.* 1984).

In some specimens stained with HTX pulp reactions were found as the presence of reparative dentin and inflammatory cells in the pulp. If the teeth diagnosed with MIH had remained in the oral cavity, it is very likely that they would have developed clinically subjective problems such as hypersensitivity and chronic pulpitis.

In the SEM analyses of the specimens, the bacteria in the tubules were mainly attached to the odontoblast processes, which might explain why only a few bacteria were found in the coronal part of the specimens. It has been shown that invasion of streptococci in dentin is associated with an adhesion to un-mineralized collagen, which would explain the presence of bacteria in the odontoblast processes (Love 2002a, b).

The probability of finding an odontoblast process in the coronal part of the enamel is not very high, even if the literature is not clear cut (Sigal & Chernecky 1984; Thoms & Carella 1984; Frank & Steuer 1988; Ten Cate 1994; Grötz *et al.* 1998; Goracci *et al.* 1999). Studies on the extension of the odontoblast process in premolars suggest that the processes do not extend beyond the inner dentin of fully erupted human premolars (Yoshida *et al.* 2002).

### 5.5 *Ozone treated bacteria*

Ozone treatment for 20 seconds or more proved to effectively kill different oral microorganisms involved in the caries process, *in vitro*. Comparable results, of ozone treatment, were seen for all four strains used. Ozonated water has been used for treatment of Streptococcus Mutans and a treatment of 120 seconds resulted in complete destruction of the bacteria membrane (Nagayoshi *et al.* 2004). Permeability of the bacteria membrane is vital for cell function. When the membrane is damaged by oxidation its permeability increases and ozone molecules may readily enter the cells and with a dysfunctional membrane, the cell loses its vitality (Holmes 2003; Tortora *et al.* 2006). In the SEM analyses, no structural changes of the cell membrane were found, not even at a magnification of x80.000. Nevertheless, it can be concluded that vital cell functions had been disturbed since no bacterial growth or polysaccharide production was seen in bacteria treated with ozone for 20 seconds or more, which was in contrast to the none-treated bacteria that showed extensive growth. These findings indicate that the cell membrane was damaged by oxidation and the cell had lost its viability.

Ozone treatment of MIH teeth with hypersensitivity should be considered as a useful complement to decrease subjective symptoms. However, there is a need for structured and documented clinical studies.

### 5.6 *Onset*

Understanding the timing of crown formation is crucial in order to be able to estimate the time of a possible insult to the ameloblasts. Boyde used a histologically derived method to calculate the cuspal enamel formation rate of a lower first permanent molar at 334 days (Boyde 1963, 1990). However, the variations in enamel formation time have shown to be limited (Reid & Dean 2006).

In the analyzed sagittal and radial sections the mesio-buccal cusps of the molar teeth were affected most often and most severely. Considering the possibility of a limited and early period of time of life for an insult to the

ameloblasts this would be in agreement with the findings of several previous studies and that the initiation of the mineralization of the mesio-buccal cusp of the first permanent molars starts one to seven weeks before birth (Reid *et al.* 1998; Antoine 2001; Mahoney *et al.* 2010).

An early insult to the ameloblasts may influence the cell in at least three different ways, the first being that a disturbance may affect the ameloblast's possibility to produce a correct deposition of proteins. Enamel proteins play a crucial role in organizing and controlling the orientation of calcium phosphate crystals in the hydroxyapatite within the crystallites (Berkovitz *et al.* 2002). If the protein deposition is incorrect, later accurate maturation is impossible. An increase of 3-15 times more proteins in hypomineralized enamel has been found (Mangum *et al.* 2010). Most of the amelogenin was resorbed. However, other proteins such as e.g. albumin, which is a protein known to inhibit tooth mineralization, persisted (Robinson *et al.* 1992, 1994). The same result with an increased amount of albumin in hypomineralized enamel, is in line with results presented by Farah (Farah *et al.* 2010c). Secondly, ameloblasts in a transition stage (between secretory and maturation) during enamel mineralization, are the most vulnerable type of ameloblasts (Fearne *et al.* 2004). An insult to the ameloblasts at a specific time of the sensitive transition may affect the ameloblasts and cause a disturbed function. A third possibility is a problem in the maturation. If the mechanisms of water and protein resorption do not work, calcium and phosphate ions will not be able to enhance the prism development (Robinson *et al.* 1982, 1995).

Histologically the hypomineralized enamel in a tooth diagnosed with MIH extends from the enamel-dentin junction towards the enamel surface and with a distinct cervical border, suggesting an early insult to the ameloblasts from which they do not recover.



### 5.7 *The clinical study*

Possible etiological factors behind MIH have been presented in a number of studies suggesting; medical problems in prenatal, perinatal and postnatal periods, medication of the child during the first years of life and exposure to fluoride or environmental toxicants in early childhood (Jälevik *et al.* 2001a, c; Beentjes *et al.* 2002; Tapias-Ledesma *et al.* 2003; Whatling & Fearnle 2008; Alaluusua 2010; Brogårdh-Roth *et al.* 2011). However, the causative factor is still unclear. A number of reasons why it has not been possible to identify the etiological factors behind MIH have been suggested, such as unclear/inexact diagnostic criteria for classification of demarcated opacities, parents being unable to remember details with sufficient accuracy 8–10 years earlier, variations in quality and completeness of observations noted in children's medical records and that the study populations were small and consisted of atypical individuals (Crombie *et al.* 2009; Alaluusua 2010). Therefore, prospective studies on population level are needed.

The positive correlation of breast feeding for more than 6 months resulting in an increased risk for MIH found in this study is to some extent in line with previous findings of prolonged breast feeding and an increased risk for MIH (Alaluusua *et al.* 1996a, b). The latter study proposed dioxins being the causative factor which, however, has not been confirmed in other studies (Laisi *et al.* 2008; Kuscü *et al.* 2009). Animal experiments have shown that dioxin may cause retention of the enamel matrix and that the dioxin may cause a disturbed function early in the secretory phase (Gao *et al.* 2004). Nutritional factors as possible cause for enamel hypomineralization have been presented earlier (Alaluusua *et al.* 1996a, b; Velló *et al.* 2010).

The result of the correlation between late introduction of supplementary nutrition and the positive correlation to MIH has not been presented earlier, but does point to early onset of MIH. This possible risk for an early onset is further strengthened in a recent study (Brogårdh-Roth *et al.* 2011) of preterm birth children. This study found that preterm birth children had statistically significant higher prevalence of MIH compared to a control group. Both the study on preterm birth children and the present study suggest that disturbances in nutrition during the first 6 months of life might have an effect on the development of demarcated opacities.

There is still a need for prospective studies of the cause of MIH. A true prospective study should be based on the present knowledge on onset and timing of the hypomineralized enamel as well as possible etiological factors. The data collection should follow children during their first year of life with special emphasis on the first six months and cover the areas of nutrition,

medical problems in prenatal, perinatal and postnatal periods, medication of the child during the first year of life and exposure to fluoride or environmental toxicants. The clinical examination should take place shortly after the first molars have erupted.

## 6 CONCLUSIONS

The *general conclusion* of this thesis was that the knowledge of MIH has enhanced in the areas of histological, chemical and mechanical properties. A hypothesis of the clinical symptoms of MIH was confirmed. Further has this thesis demonstrated that a disturbance of the ameloblasts occurs during, approximately, the first 6 months of life. This disturbance is confirmed in histological, chemical as well as in etiological studies.

The *specific conclusions* of the thesis were:

- Teeth diagnosed with MIH have significantly lower hardness values (HV) in hypomineralized compared with normal enamel; further, an inverse relationship between micro-hardness and the Ca:C ratio.
- Bacteria were observed deep in the enamel and in the dentin diagnosed with MIH, even with apparently intact enamel surface. The bacteria may penetrate into the dentin pulp complex and create inflammatory reactions in the pulp.
- Gaseous ozone-treatment for 20 seconds or more is effective in killing different oral microorganisms involved in the caries process. Treatments less than 20 seconds had only a limited effect on the growth of microorganisms.
- A combination of breastfeeding more than 6 months, late introduction of gruel and/or infant formula (after 6 months) caused a fivefold higher risk for MIH compared with a control group.
- Hypomineralized enamel in first permanent molars was mainly located in the buccal enamel of the teeth and had a high degree of porosity extending from enamel-dentin-junction (EDJ) towards the enamel surface.

- The estimation of an onset and extension in time for the hypomineralized enamel ranges from the start of the enamel mineralization at the tip of the dentin cusp to a relative value of 200 days.

## 7 CLINICAL IMPLICATIONS

- The lower hardness value in hypomineralized enamel authenticates the post-eruptive breakdown of MIH teeth, which is one of several clinical objective symptoms of MIH.
- Penetration of oral bacteria contributes to the hypersensitivity of teeth diagnosed with MIH
- Teeth diagnosed with MIH, even with apparently intact surfaces, need special attention in order to avoid pulpal complications.
- An ozone treatment kills oral bacteria involved in the caries process in vitro. Therefore, ozone treatment of MIH teeth should be considered, especially with symptoms of hypersensitivity.
- In our study differences in nutrition during the first months of life might be responsible for hypomineralization of enamel. Introduction of gruel or infant formula at 4 months of age might decrease the risk of developing MIH.



## ACKNOWLEDGEMENT

I wish to express my sincere gratitude to all who have supported and encouraged me during my work on this thesis.

Special thanks are due to:

My supervisors: Professor Jörgen G. Norén and Professor Peter Lingström.

My co-authors: Odont Dr. Birgitta Jälevik, Dr. Wolfram Dietz, Stina Olsson, Frank Steiniger, Professor Göran Koch, Professor Johnny Ludvigsson, Odont Dr. Christer Ullbro, Odont. Dr. Sven-Åke Lundin, Odont. kand. Lisa Melin, Dr. Phil Salmon.

My friends and colleagues at the department of Pediatric Special Dental Service, Sahlgrenska University Hospital/Mölndal.

My family for their everlasting support.

The studies have been supported by grants from: The Gothenburg Dental Society, Gothenburg, Sweden, Public Dental Care, Region Västra Götaland, Sweden; Medical Research Council of Southeast Sweden (FORSS); Swedish Dental Society; Swedish Society of Pediatric Dentistry; Kavo Dental GmbH, Germany.





## REFERENCES

- Aine L, Backström MC, Mäki R, Kuusela AL, Koivisto AM, Ikonen RS, Mäki M. Enamel defects in primary and permanent teeth of children born prematurely. *J Oral Pathol Med* 2000;29:403-9. 2, 10
- Alaluusua S, Lukinmaa PL, Koskimies M, Pirinen S, Hölttä P, Kallio M, Holttinen T, Salnemenperä L. Developmental dental defects associated with long breast feeding. *Eur J Oral Sci.* 1996a;104:493-7.
- Alaluusua S, Lukinmaa P-L, Vartiainen T, Partanen M, Torppa J, Tuomisto J. Polychlorinated dibenzo-p-dioxins and dibenzofurans via mother's milk may cause developmental defects in the child's teeth. *Environ Toxicol Pharmacol* 1996b;1:193-7.
- Alaluusua S. Aetiology of Molar-Incisor Hypomineralisation: A systematic review. *Eur Arch Paediatr Dent.* 2010;11:53-8.
- Angker L, Swain MV, Kilpatrick N. Characterising the micro-mechanical behaviour of the carious dentine of primary teeth using nano-indentation. *J Biomech.* 2005;38:1535-42.
- Antoine D. Evaluating the periodicity of incremental structures in dental enamel as a means of studying growth in children from past populations. Ph.D. Dissertation, University of London 2001.
- Antoine D, Hillson S, Dean MC. The developmental clock of dental enamel: a test for the periodicity of prism cross-striations in modern humans and an evaluation of the most likely sources of error in histological studies of this kind. *J Anat.* 2009;214:45-55.
- Baysan A, Lynch E: Effect of ozone on the oral microbiota and clinical severity of primary root caries. *Am J Dent* 2004;17:56-60
- Baysan A, Lynch E. The use of ozone in dentistry and medicine. *Prim Dent Care* 2005;12:47-52.
- Baysan A, Lynch E. The use of ozone in dentistry and medicine. Part 2 Ozone and root caries. *Prim Dent Care* 2006;13:37-41.
- Beentjes VE, Weerheijm KL, Groen HJ. Factors involved in the aetiology of Molar-Incisor Hypomineralisation (MIH). *Eur J Paediatr Dent.* 2002;3:9-13.

- Berkovitz B, Holland GR, Moxham BJ. Oral Anatomy, Embryology and Histology. Third ed. Mosby International Ltd, Edinburgh 2002.
- Bocci V. Ozonization of blood for the therapy of viral diseases and immunodeficiencies. A hypothesis. *Med Hypotheses* 1992;39:30-4.
- Boyde A. Estimation of age at death from young human skeletal remains from incremental lines in dental enamel. Third International Meeting in Forensic Immunology, Medicine, Pathology and Toxicology, London, 1963;36-46.
- Boyde A. Developmental interpretations of dental microstructure; In: DeRousseau, J.C. (Ed.), *Primate Life History and Evolution*. Wiley-Liss, New York 1990.
- Braly A, Darnell LA, Mann AB, Teaford MF, Weihs TP. The effect of prism orientation on the indentation testing of human molar enamel. *Arch Oral Biol*. 2007;52:856-60.
- Brogårdh-Roth S, Matsson L, Klingberg G. Molar-Incisor Hypomineralization and oral hygiene in 10-to-12-year-old Swedish children born preterm *Eur J Oral Sci*. 2011;119:33-9.
- Brook AH, Smith JM. The aetiology of developmental defects of enamel: a prevalence study and a family study in East London, UK. *Connect Tissue Res* 1998 39:151-156.
- Carrigan PJ, Morse DR, Furst ML, Sinai IH. A scanning electron microscopic evaluation of human dentinal tubules according to age and location. *J Endod*. 1984;10:359-63.
- Cha JY, Lim JK, Song JW, Sato D, Kenmotsu M, Inoue T, Park YC. Influence of the length of the loading period after placement of orthodontic mini-implants on changes in bone histomorphology: microcomputed tomographic and histologic analysis. *Int J Oral Maxillofac Implants*. 2009;24:842-9.
- Cho SY, Ki Y, Chu V. Molar incisor hypomineralization in Hong Kong Chinese children. *Int J Paed Dent* 2008;18:348-352
- Clarkson J. An epidemiological study of enamel defects in fluoridated and non-fluoridated areas of Ireland. PhD Thesis. Cork, Ireland: University College, 1987.
- Crombie F, Manton D, Kilpatrick N. Aetiology of molar incisor hypomineralization: a critical review. *Int J Paediatr Dent*. 2009;19:73-83.

- Cuy JL, Mann AB, Livi KJ, Teaford MF, Weihs TP. Nanoindentation mapping of the mechanical properties of human molar tooth enamel. *Arch Oral Biol.* 2002;47:281-91.
- Da Costa-Silva CM, Ambrosano GM, Jeremias F, De Souza JF, Mialhe FL. Increase in severity of molar-incisor hypomineralization and its relationship with the colour of enamel opacity: a prospective cohort study. *Int J Paediatr Dent.* 2011;21:333-41.
- Daly D, Waldron JM Molar incisor hypomineralisation: clinical management of the young patient. *J Ir Dent Assoc.* 2009;55(2):83-6.
- Dean MC. Growth layers and incremental markings in hard tissues: a review of the literature and some preliminary observations about enamel structure in *Paranthropus boisei*. *J Hum Evol* 1987;16:157-172.
- DenBesten PK, Heffernan LM, Treadwell BW, Awbrey BJ. The presence and possible functions of the matrix metalloproteinase collagenase activator protein in developing enamel matrix. *Biochem J.* 1989;264:917-20.
- Elcock C, Lath DL, Luty JD, Gallagher MG, Abdellatif A, Bäckman B, Brook AH. The new Enamel Defects Index: testing and expansion. *Eur J Oral Sci.* 2006;114:35-8; discussion 39-41, 379
- Fagrell TG, Lingström P, Olsson S, Steiniger F, Norén JG. Bacterial invasion of dentinal tubules beneath apparently intact but hypomineralized enamel in molar teeth with molar incisor hypomineralization. *Int J Paediatr Dent.* 2008;18: 333-40.
- Farah R, Drummond B, Swain M, Williams S. Linking the clinical presentation of molar-incisor hypomineralisation to its mineral density. *Int J Paediatr Dent* 2010a; 20: 353-360.
- Farah RA, Swain MV, Drummond BK, Cook R, Atieh M. Mineral density of hypomineralised enamel. *J Dent.* 2010b;38:50-8.
- Farah RA, Monk BC, Swain MV, Drummond BK. Protein content of molar-incisor hypomineralisation enamel. *J Dent.* 2010c;38:591-6.
- FDI Commission on Oral Health Research & Epidemiology. A review of the developmental defects of enamel index (DDE Index). Commission on Oral Health, Research & Epidemiology. Report of an FDI Working Group. *Int Dent J.* 1992;42:411-26.
- Fearne J, Anderson P, Davis GR. 3D X-ray microscopic study of the extent of variations in enamel density in first permanent molars with

- idiopathic enamel hypomineralisation. *Br Dent J.* 2004;196:634-8; discussion 625.
- Filippi A. Water disinfection of dental units using ozone - microbiological results after 11 years and technical problems. *Ozone: Science & Engineering* 2002;24:479-83.
- Fincham AG, Moradian-Oldak J, Simmer JP. The structural biology of the developing dental enamel matrix. *J Struct Biol.* 1999;126:270-99.
- FitzGerald C. Do enamel microstructures have regular time dependency? Conclusions from the literature and a large-scale study. *J Hum Evol.* 1998;35:371-86.
- Foote KD, Marriott LD. Weaning of infants. *Arch Dis Child.* 2003;88:488-92.
- Frank RM, Steuer P. Transmission electron microscopy of the human odontoblast process in peripheral root dentine. *Arch Oral Biol.* 1988;33:91-8.
- Gao Y, Sahlberg C, Kiukkonen A, Alaluusua S, Pohjanvirta R, Tuomisto J, et al. Lactational exposure of Han/Wistar rats to 2,3,7,8-tetrachlorodibenzo-p-dioxin interferes with enamel maturation and retards dentin mineralization. *J Dent Res.* 2004;83:139-44.
- Goracci G, Mori G, Baldi M. Terminal end of the human odontoblast process: a study using SEM and confocal microscopy. *Clin Oral Investig.* 1999;3:126-32.
- Grötz KA, Duschner H, Reichert TE, de Aguiar EG, Gotz H, Wagner W. Histotomography of the odontoblast processes at the dentine-enamel junction of permanent healthy human teeth in the confocal laser scanning microscope. *Clin Oral Investig.* 1998;2:21-5.
- Holmes J. Clinical reversal of root caries using ozone, double-blind, randomised, controlled 18-month trial. *Gerodontology.* 2003;20:106-14.
- Jälevik B, Norén JG, Klingberg G, Barregard L. Etiologic factors influencing the prevalence of demarcated opacities in permanent first molars in a group of Swedish children. *Eur J Oral Sci.* 2001a;109:230-4.
- Jälevik B, Odelius H, Dietz W, Norén J. Secondary ion mass spectrometry and X-ray microanalysis of Hypomineralized enamel in human permanent first molars. *Arch Oral Biol.* 2001b;46:239-47.

- Jälevik B, Klingberg G, Barregård L, Norén JG. The prevalence of demarcated opacities in permanent first molars in a group of Swedish children. *Acta Odontol Scand.* 2001c;59:255-60
- Jälevik B & Klingberg G. Dental treatment, dental fear and behaviour management problems in children with severe enamel hypomineralization of their permanent first molars. *Int J Paediatr Dent.* 2002 Jan;12(1):24-32.
- Jälevik B, Dietz W, Norén JG. Scanning electron micrograph analysis of hypomineralized enamel in permanent first molars. *Int J Paediatr Dent* 2005;15:233-40.
- Jälevik B, Möller M. Evaluation of spontaneous space closure and development of permanent dentition after extraction of Hypomineralized permanent first molars. *Int J Paediatr Dent* 2007;17:328-335.
- Jälevik B. Prevalence and Diagnosis of Molar-Incisor- Hypomineralisation (MIH): A systematic review. *Eur Arch Paediatr Dent.* 2010;11:59-64.
- Jälevik B, Klingberg G. Treatment outcomes and dental anxiety in 18-year-olds with MIH, comparisons with healthy controls - a longitudinal study. *Int J Paediatr Dent.* 2011 [Epub ahead of print]
- Kim JG, Yousef AE, Dave S: Application of ozone for enhancing the microbiological safety and quality of foods: a review. *J Food Prot* 1999;62:1071-87.
- King NM, Brook AH. A prevalence study of enamel defects among young adults in Hong Kong. *N Z Dent J* 1984;80:47-49.
- King NM, Wei SH. Developmental defects of enamel: a study of 12 year olds in Hong Kong. *J Am Dent Assoc* 1986;112:835-839.
- Koch G, Hallonsten AL, Ludvigsson N, Hansson BO, Holst A, Ullbro C. Epidemiologic study of idiopathic enamel hypomineralization in permanent teeth of Swedish children. *Community Dent Oral Epidemiol.* 1987;15:279-85
- Kodaka T, Debari K, Kuroiwa M. Mineral content of the innermost enamel in erupted human teeth. *J Electron Microsc.* 1991;40:19-23.
- Kodaka T, Debari K, Yamada M, Kuroiwa M. Correlation between microhardness and mineral content in sound human enamel (short communication). *Caries Res.* 1992;26:139-41.

- Kuscu OO, Caglar E, Aslan S, Durmusoglu E, Karademir A, Sandalli N. The prevalence of molar incisor hypomineralization (MIH) in a group of children in a highly polluted urban region and a windfarm-green energy island. *Int J Paediatr Dent*. 2009;19:176-85.
- Laisi S, Kiviranta H, Lukinmaa PL, Vartiainen T, Alaluusua S. Molar-incisor-hypomineralisation and dioxins: new findings. *Eur Arch Paediatr Dent* 2008;9:224-7
- Leppäniemi A, Lukinmaa PL, Alaluusua A. Nonfluoride hypomineralizations in the permanent first molars and their impact on the treatment need. *Caries Res* 2001;35:36-40.
- Love RM. Bacterial adhesions - their role in tubule invasion and endodontic disease. *Aust Endod J*. 2002a;28:25-8.
- Love RM. The effect of tissue molecules on bacterial invasion of dentine. *Oral Microbiol Immunol*. 2002b;17:32-37.
- Ludvigsson J, Ludvigsson M, Sepa A. Screening for prediabetes in the general child population: maternal attitude to participation. *Pediatr Diabetes* 2001;2:170-4.
- Lygidakis NA, Dimou G, Marinou D. Molar-incisorhypomineralisation (MIH). A retrospective clinical study in Greek children. II. Possible medical aetiological factors. *Eur Arch Paediatr Dent* 2008;9:207-17.
- Lygidakis NA. Treatment modalities in children with teeth affected by molar-incisor enamel hypomineralisation (MIH): A systematic review. *Eur Arch Paediatr Dent*. 2010;11:65-74.
- Mahoney E, Ismail FS, Kilpatrick N, Swain M. Mechanical properties across hypomineralized/hypoplastic enamel of first permanent molar teeth. *Eur J Oral Sci*. 2004a;112:497-502.
- Mahoney EK, Rohanzadeh R, Ismail FS, Kilpatrick NM, Swain MV. Mechanical properties and microstructure of hypomineralised enamel of permanent teeth. *Biomaterials*. 2004b;25:5091-100.
- Mahoney P. Intraspecific variation in M1 enamel development in modern humans: implications for human evolution. *J Hum Evol*. 2008;55:131-47.
- Mahoney P. Two dimensional patterns of human enamel thickness on deciduous (dm1, dm2) and permanent first (M1) mandibular molars. *Arch Oral Biol*. 2010;55:115-26.

- Mangum JE, Crombie FA, Kilpatrick N, Manton DJ, Hubbard MJ. Surface integrity governs the proteome of hypomineralized enamel. *J Dent Res.* 2010;89:1160-5.
- Mejäre I, Bergman E, Grindefjord M. Hypomineralized molars and incisors of unknown origin: treatment outcome at age 18 years. *Int J Paediatr Dent.* 2005;15:20-8.
- Millar BJ, Hodson N. Assessment of the safety of two ozone delivery devices. *J Dent.* 2007;35:195-200.
- Müller P, Guggenheim B, Schmidlin PR. Efficacy of gasiform ozone and photodynamic therapy on a multispecies oral biofilm in vitro. *Eur J Oral Sci.* 2007;115:77-80.
- Nagayoshi M, Kitamura C, Fukuizumi T, Nishihara T, Terashita M. Antimicrobial effect of ozonated water on bacteria invading dentinal tubules. *J Endod* 2004;30:778-81.
- Pinheiro ET, Gomes BP, Ferraz CC, Sousa EL, Teixeira FB, Souza-Filho FJ. Microorganisms from canals of root-filled teeth with periapical lesions. *Int Endod J.* 2003;36:1-11.
- Reid DJ, Beynon AD, Ramirez Rozzi FV. Histological reconstruction of dental development in four individuals from a medieval site in Picardie, France. *J Hum Evol.* 1998;35:463-78.
- Reid DJ, Dean MC. Variation in modern human enamel formation times. *J Hum Evol.* 2006;50:329-46.
- Reid DJ, Ferrell RJ. The relationship between number of striae of Retzius and their periodicity in imbricational enamel formation. *J Hum Evol.* 2006;50:195-202.
- Ricucci D, Bergenholtz G. Bacterial status in root-filled teeth exposed to the oral environment by loss of restoration and fracture or caries: a histobacteriological study of treated cases. *Int Endod J.* 2003;36:787-802.
- Robinson C, Kirkham J, Briggs HD, Atkinson PJ. Enamel proteins: from secretion to maturation. *J Dent Res.* 1982;Spec No:1490-5.
- Robinson C, Kirkham J, Brookes SJ, Shore RC. The role of albumin in developing rodent dental enamel: a possible explanation for white spot hypoplasia. *J Dent Res.* 1992;71:1270-4.
- Robinson C, Brookes SJ, Kirkham J, Shore RC, Bonass WA. Uptake and metabolism of albumin by rodent incisor enamel in vivo and

- postmortem: implications for control of mineralization by albumin. *Calcif Tissue Int.* 1994;55:467-72.
- Robinson C, Kirkham J, Brookes SJ, Bonass WA, Shore RC. The chemistry of enamel development. *Int J Dev Biol.* 1995;39:145-52.
- Rodd HD, Boissonade FM, Day PF. Pulpal status of hypomineralized permanent molars. *Pediatr Dent* 2007;29:514-520.
- Sabel N, Klingberg G, Dietz W, Nietzsche S, Norén JG. Polarized light and scanning electron microscopic investigation of enamel hypoplasia in primary teeth. *Int J Paediatr Dent.* 2010;20:31-6.
- Sabetrasekh R, Tiainen H, Lyngstadaas SP, Reseland J, Haugen H. A novel ultra-porous titanium dioxide ceramic with excellent biocompatibility. *J Biomater Appl.* 2011;25:559-80
- SCB Befolkningsstatistik (Swedish population statistics). The Statistical Yearbook 1999, from <http://www.scb.se>.
- Schour I, Massler. The development of the human dentition. *J Am Dent Assoc* 1941;28:1153-1160.
- Schwartz GT, Dean C. Ontogeny of canine dimorphism in extant hominoids. *Am J Phys Anthropol.* 2001;115:269-83.
- Selwitz RH, Ismail AI, Pitts NB. Dental caries. *Lancet.* 2007;6:369(9555):51-9.
- Shellis RP. 1998. Utilization of periodic markings in enamel to obtain information on tooth growth. *J Hum Evol* 35:387-400.
- Sigal MJ, Chernecky R. Terminal end of the odontoblastic process. *J Endod.* 1988;14:543-5.
- Simmer JP, Papagerakis P, Smith CE, Fisher DC, Rountrey AN, Zheng L, Hu JC. Regulation of dental enamel shape and hardness. *J Dent Res.* 2010;89:1024-38.
- Soviero V, Haubek D, Trindade C, Matta T, Poulsen S. Prevalence and distribution of demarcated opacities and their squeals in permanent first molars and incisor in 7 to 13-year-old Brazilian children. *Acta Odontol Scand* 2009;66:170-175.
- Stubinger S, Sader R, Filippi A. The use of ozone in dentistry and maxillofacial surgery: a review. *Quintessence Int* 2006;37:353-9.



- Suckling GW, Pearce EI. Developmental defects of enamel in a group of New Zealand children. *Community Dent Oral Epidemiol* 1984;12:177-184.
- Suckling GW, Nelson DG, Patel MJ. Macroscopic and scanning electron microscopic appearance and hardness values of developmental defects in human permanent tooth enamel. *Adv Dent Res* 1989;3:219-33.
- Tapias-Ledesma MA, Jiménez R, Lamas F, González A, Carrasco P, Gil de Miguel A. Factors associated with first molar dental enamel defects: a multivariate epidemiological approach. *J Dent Child.* 2003;70:215-20.
- Ten Cate AR. Dentin-pulp complex. In: Ten Cate AR (ed.) *Oral Histology*. St Louis, MO: Mosby, 1994:169-217.
- Thoms HF, Carella P. Correlation of scanning and transmission electron microscopy of human dentinal tubules. *Arch Oral Biol.* 1984;29:641-6.
- Tortora GJ, Funke BR, Case CL. *Microbiology - An Introduction*, 9th edn. 2006, Redwood California, Benjamin/Cummings Pub. Co, 2006.
- Velló MA, Martínez-Costa C, Catalá M, Fons J, Brines J, Guijarro-Martínez R. Prenatal and neonatal risk factors for the development of enamel defects in low birth weight children. *Oral Dis.* 2010;16:257-62.
- Versiani MA, Pécora JD, Sousa-Neto MD. The anatomy of two-rooted mandibular canines determined using micro-computed tomography. *Int Endod J.* 2011;44:682-7.
- Weerheijm KL, Jälevik B, Alaluusua S. Molar incisor hypomineralization. *Caries Res* 2001;35:390-391.
- Weerheijm, K.L. Molar-incisor-hypomineralisation (MIH). *Eur J Paediatr Dent* 2003;4:115-120.
- Whatling R, Fearn JM. Molar incisor hypomineralization: a study of aetiological factors in a group of UK children *Int J Paediatr Dent.* 2008;18:155-62.
- Wogelius P, Haubek D, Poulsen S. Prevalence and distribution of demarcated opacities in permanent 1st molars and incisors in 6 to 8-year-old Danish children. *Acta Odontol Scand* 2008;66: 58-64
- Xie ZH, Mahoney EK, Kilpatrick NM, Swain MV, Hoffman M. On the structure-property relationship of sound and hypomineralized enamel. *Acta Biomater.* 2007;3:865-72.

- Xie Z, Kilpatrick NM, Swain MV, Munroe PR, Hoffman M. Transmission electron microscope characterisation of molar-incisor-hypomineralisation. *J Mater Sci Mater Med.* 2008;19:3187-92.
- Yoshida K, Yoshida N, Ejiri S, Iwaku M, Ozawa H. Odontoblast processes in human dentin revealed by fluorescence labeling and transmission electron microscopy. *Histochem Cell Biol.* 2002;118:205-12.
- Zivković S, Bojović S, Pavlica D. Bacterial penetration of restored cavities. *Oral Surg Oral Med Oral Pathol Oral Radiol Endod.* 2001;91:353-8.

# APPENDIX 1

Examination form

20051014

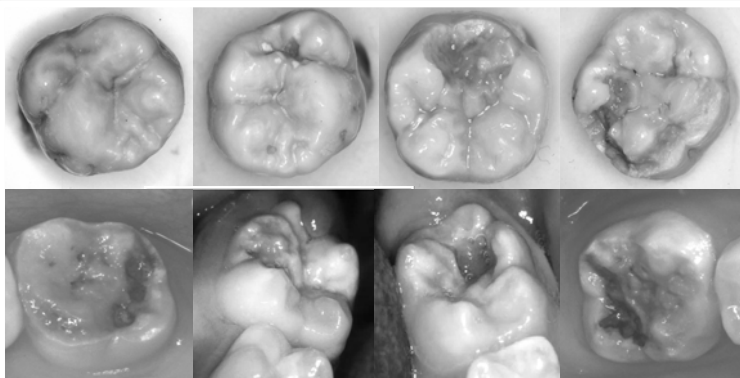
**This study is a examination of severe MIH (Molar Incisor Hypomineralisation). The aim of the study is to evaluate social and medical data collected in the prospective ABIS-study as possible etiological factors to MIH. All children born from 1 October 1997 – 1 October 1999 take part in the ABIS-study.**

The eight pictures below are examples of permanent first molars diagnosed with severe MIH.

Diagnose children with severe MIH similar to the pictures below and fill in one special form per patient. All special forms of diagnosed children should be sent to the principal investigator. Detected children will be asked to take part in a secondary screening performed by the principal investigators.

**Exampel of teeth diagnosed with severe MIH, which should be registered .**

Teeth may have light- to dark-brown opacities, post eruptive breakdown and/or atypical restorations and/or atypical dental caries.



Name \_\_\_\_\_  
 ID \_\_\_\_\_  
 Public dental office \_\_\_\_\_  
 Date \_\_\_\_\_

Please mark if the tooth have severe MIH or any other discrepancy which have a possible origin from a severe developmental defect.

16	26	36	46

*X- Severe MIH*  
*K- Atypical dental caries*  
*F- Atypical restorations*  
*S- Post eruptive breakdown*