

On the Treatment of Tibial Fractures using the Ilizarov Fixator

Telmo de Oliveira Ramos, MD

Department of Orthopaedics
Institute of Clinical Sciences
at Sahlgrenska Academy
University of Gothenburg
Gothenburg 2014



UNIVERSITY OF GOTHENBURG

Cover illustration: “Aus der Geschichte der Unfallchirurgie”. Mural painting by Johannes Grützke in the administration building of the Berufsgenossenschaftliche Unfallkrankenhaus, Hamburg, Germany[©]



1-Uwe Schümann, 2-Gerhard Künstcher, 3-Gerd Mehrtens, 4-H.C. Burri, 5 and 6- uninterested fellows, 7- **Gavril Ilizarov**, 8-Lutz Claes, 9-Erhard, 10- fellow, 11-Peter Neuhaus, 12- fellow, 13-Ortwin Runde, 14- Lothar Kinzl, 15- W. Grube, 16- Jörg Rehn, 17- Dieter Benseid, 18- Heinz Mecking, 19- Stephan Perren, 20-fellow, 21 and 22- fellows, 23- Carl Hansmann, 24- Bernhard von Langenbeck, 25- Otto von Bismark, 26, 27, 28, 29 and 30- fellows

On the Treatment of Tibial Fractures with the Ilizarov Fixator

©Telmo de Oliveira Ramos 2014

telmo.ramos@vgregion.se

ISBN 978-91-628-9068-1

Printed in Gothenburg, Sweden 2014

Ineko AB

To my beloved wife Ulrika

Abstract

The aim of this thesis was to analyse the results of the Ilizarov method in patients with different types of tibial fracture and compare them with conventional methods, in terms of primary union, complication rates, post-operative function, quality of life, and how the patients' gait was affected during rehabilitation. Fifty-eight patients with isolated diaphyseal fractures (Study I) were randomised to treatment with either the Ilizarov method (IL) or locked intramedullary nailing (IM). Thirty consecutive patients with isolated proximal metaphyseal fractures (Study II – 11 classified as Schatzker type I-IV and 19 as Schatzker type V-VI) and 39 consecutive patients with isolated distal metaphyseal fractures (Study III – 21 extra-articular and 18 intra-articular) were treated prospectively using the IL. The follow-ups included clinical investigations, roentgen assessments, self-appraisals (VAS Pain and VAS Satisfaction, NHP and EQ-5D). In Studies II and III, we also used specific questionnaires: the KOOS and FAOS respectively. In Study IV, 85 patients from the earlier studies were included in a gait analysis study, using the medilogic[®] insole pressure technique.

In Study I, in the IL and IM groups, nine and two patients respectively had open fractures. Twelve patients sustained major complications, four in the IL group and eight in the IM group ($p=0.107$). In the IL group, two patients developed pseudarthrosis and two malunion. In the IM group, two patients developed compartment syndrome, one had a deep infection, one hardware failure, one delayed union, one pseudarthrosis and two had a malunion. Superficial pin-site infections were observed in 16 patients in the IL group. The fractures were radiographically healed at an average of 12 weeks in both groups. At the one-year follow-up, there were differences in pain (VAS) and satisfaction (VAS) scores in favour of the IL treatment ($p=0.03$ and $p=0.02$ respectively). There were no differences between the groups with regard to range of motion (ROM) in the knee and ankle joints. Local tenderness and pain, mainly anterior knee pain, were registered in 19 patients in the IM group and one patient in the IL group at the one-year follow-up ($p<0.001$). In Study II, 25 of the 30 patients achieved a ROM in the knee exceeding 10-100°. The patients with Schatzker type I-IV fracture had a shorter operating time and hospital stay, as well as better knee flexion, and the self-appraisal indicated that they tolerated the treatment better than those with Schatzker type V-VI fracture. In Study III, one patient had a deep infection and developed a residual deformity. Another patient with residual deformity underwent re-operation. Even if the radiological results were "poor" in five patients, the overall self-appraisal showed satisfactory results in 36 of the 39 patients. In Study IV, there was an improvement in all the gait parameters as the fractures healed. There

were differences in recovery between the patients with Schatzker type I-IV and type V-VI fractures, corresponding to the severity of the fracture. In the diaphyseal fractures, there were no statistically significant differences between the IL and IM groups. Gait analysis demonstrated that step length and walking speed were more clearly correlated to increasing time after operation, compared with weight-bearing, i.e. load. To summarise, the Ilizarov method produced a good, satisfactory clinical outcome with a low complication rate and is at least as good as internal fixation. This technique should therefore be considered as a valid alternative and can be useful as the primary and definitive treatment of patients with all types of tibial fracture.

Keywords: tibial fracture, external fixation, intramedullary nail, randomised study, load, gait analysis, VAS, NHP, EQ-5D

ISBN: 978-91-628-9068-1

Sammanfattning på svenska

Syftet med denna avhandling var att analysera resultaten av Ilizarov metoden hos patienter med olika typer av tibiafraktur och jämföra med konventionella metoder, avseende primär läkning, komplikationsfrekvens, postoperativ funktion, livskvalitet och hur patienternas gång påverkades under rehabiliteringen. Femtioåtta patienter med isolerade diafysfrakter (Studie I) randomiserades till behandling med Ilizarov metoden (IL) eller märgspikning med tvärskruvar (IM). Trettio konsekutiva patienter med isolerade proximala metafysära frakturer (Studie II – 11 klassifierade som Schatzker I-IV och 19 som Schatzker V-VI frakturer) och 39 konsekutiva patienter med isolerade distala metaphysära frakturer (Studie III – 21 lednära och 18 ledengagerande) behandlades prospektivt med IL. Uppföljningen omfattade kliniska undersökningar, röntgenkontroller, självskattningar (VAS smärta och VAS tillfredsställelse, NHP, och EQ-5D). I Studierna II och III användes också ledspecifika frågeformulär; KOOS respektive FAOS. I Studie IV inkluderades 85 patienter från de tidigare studierna, och undersöktes med gånganalys med tryckkänsliga inläggssulor (medilogic®).

I Studie I hade nio patienter i IL gruppen och två i IM gruppen öppna frakturer. Tolv patienter hade allvarliga komplikationer, fyra i IL gruppen och åtta i IM gruppen ($p=0.107$). I IL gruppen, utvecklade två patienter pseudartros och två läkte med betydande felställningar. I IM gruppen, utvecklade två patienter kompartment syndrom, en fick en djup infektion, en hade spikbrott, en hade försenad benläkning, en hade pseudartros och två läkte med betydande felställningar. Ytliga pininfektioner förekom hos 16 patienter i IL gruppen. Frakturerna var röntgenlogiskt läkta efter i genomsnitt 12 veckor i båda grupperna. Vid ett-års uppföljningen förelåg skillnader i VAS smärta och VAS tillfredsställelse med fördel för IL gruppen ($p=0.03$ och $p=0.02$). Det fanns inga skillnader mellan grupperna avseende rörelseomfång i knä- och fotleder. Lokal ömhet och värk, huvudsakligen främre knäsmärta, registrerades hos 19 patienter i IM gruppen och en i IL gruppen vid ett-års uppföljningen ($p<0.001$). I Studie II hade 25 av 30 patienter ett rörelseomfång i knäleden, som var bättre än $10-100^\circ$. Patienterna med Schatzker I-IV fraktur hade kortare operationstid och sjukhusvistelse, liksom bättre knäböjning och självskattningen visade att de tolererade behandlingen bättre än de med Schatzker V-VI fraktur. I Studie III hade en patient en djup infektion och utvecklade en kvarvarande felställning. En annan patient med kvarvarande felställning genomgick en korrektionsoperation. Även om det röntgenlogiska resultatet var "dåligt" hos 5 patienter, visade självskattning tillfredställande resultat hos 36 av de 39 patienterna. I Studie IV noterades en förbättring av alla gångparametrar under läkningsstiden. Det fanns skillnader i återhämtning mellan den proximala

Schatzker I-IV och V-VI frakturerna, vilket motsvarade frakturernas svårighetsgrad. Avseende diafysära frakturer fanns det inga statistiskt signifikanta skillnader mellan IL och IM grupperna. Gånganalysen visade att steglängd och gånghastighet korrelerade bättre till tid efter operation jämfört med belastning. Sammanfattningsvis gav Ilizarov metoden ett tillfredställande kliniskt resultat med låg komplikationsfrekvens och visade minst lika bra resultat som efter inre fixation. Ilizarovtekniken bör därför övervägas som ett fullvärdigt alternativ och kan vara användbar både som primär och definitiv behandling av patienter med alla typer av tibiafrakturer.

LIST OF PAPERS

This thesis is based on the following studies, referred to in the text by their Roman numerals.

- I. Ramos T, Karlsson J, Eriksson BI, Nistor L. Ilizarov external fixation or locked intramedullary nailing for treatment in diaphyseal tibial fractures – a randomized prospective study of 58 consecutive patients. *Arch Orthop Trauma Surg.* 2014; 134 (6):793-802.
- II. Ramos T, Ekholm C, Eriksson BI, Karlsson J, Nistor L. The Ilizarov external fixator – a useful alternative for the treatment of proximal tibial fractures – a prospective observational study of 30 consecutive patients. *BMC Musculoskelet Disord.* 2013; 14 (1): 11.
- III. Ramos T, Karlsson, J, Eriksson BI, Nistor L. Treatment of distal tibial fractures with the Ilizarov external fixator –a prospective observational study in 39 consecutive patients. *BMC Musculoskelet Disord.* 2013; 14 (1): 30.
- IV. Ramos T, Hjältman K, Reetz T, Tranberg R, Nistor L. Gait analysis with insoles in different types of tibial fractures treated with Ilizarov external fixator. *Manuscript.*

CONTENTS

ABBREVIATIONS.....	14
PREFACE	16
1 INTRODUCTION.....	18
1.1 Epidemiology.....	18
2 THE TREATMENT OF TIBIAL FRACTURES.....	20
2.1 Conservative treatment.....	20
2.2 Surgical treatment.....	22
2.2.1 Plate osteosynthesis	22
2.2.2 Intramedullary nailing osteosynthesis	25
2.2.3 External fixation osteosynthesis	29
2.2.3.1 Types of frame configuration.....	32
2.2.3.2 Advantages of external fixation.....	33
2.2.3.3 Disadvantages and complications of external fixation	34
3 ILIZAROV METHOD.....	36
3.1 Ilizarov - short biography	37
3.2 Biomechanics of the Ilizarov apparatus.....	39
3.3 Technical developments of the Ilizarov technique	46
4 REVIEW OF THE LITERATURE.....	47
4.1 Systematic reviews of studies comparing the different surgical treatments.....	47
4.2 Preference of treatment has changed over time.....	51
4.3 Why do we need this thesis?.....	52
5 AIMS.....	53
6 PATIENTS.....	54
6.1 Inclusion/exclusion criteria.....	54
6.2 Flow charts	55
6.3 Demography and etiology	58
6.4 Ethics.....	59

7	METHODS.....	60
7.1	Examiners	60
7.2	Fracture classifications	60
7.3	Surgical technique	60
7.3.1	The Ilizarov fixator (IL).....	60
7.3.2	The intramedullary nail (IM)	62
7.4	Prophylaxis	62
7.5	Operation time	63
7.6	Hospital stay	63
7.7	Rehabilitation.....	63
7.8	Post-operative evaluation.....	63
7.8.1	Radiographic assessment	64
7.8.2	Assessment of fracture union.....	65
7.8.3	Pin infection assessment	65
7.8.4	Range of motion (ROM).....	66
7.8.5	Patient self-reported outcome and functional scores	66
7.8.5.1	Visual Analogue Scale (VAS)	66
7.8.5.2	Nottingham Health Profile (NHP)	67
7.8.5.3	Euroqol (EQ-5D).....	67
7.8.5.4	Knee injury and Osteoarthritis Outcome Score (KOOS) ...	67
7.8.5.5	Foot and Ankle injury and Osteoarthritis Outcome Score (FAOS).....	68
7.8.5.6	Anterior knee pain and pain at the fracture site	68
7.8.6	Major complications	68
7.8.6.1	Compartment syndrome.....	68
7.8.6.2	Deep infection.....	68
7.9	Re-operations.....	69
7.10	Gait analysis with pressure insoles	69
7.10.1	Gait parameters	71
8	STATISTICAL METHODS	72
9	RESULTS AND DISCUSSION	74

9.1	Treatment timing	74
9.1.1	Results	74
9.1.2	Discussion	75
9.2	Time to union	76
9.2.1	Results	76
9.2.2	Discussion	77
9.3	Articular function (ROM)	79
9.3.1	Results	79
9.3.2	Discussion	80
9.4	Gait	81
9.4.1	Results	81
9.4.2	Discussion	87
9.5	Malunion	91
9.5.1	Results	91
9.5.2	Discussion	91
9.6	Pin infections	93
9.6.1	Results	93
9.6.2	Discussion	94
10	MAJOR COMPLICATIONS	97
10.1	Deep infection	97
10.1.1	Results	97
10.1.2	Discussion	98
10.2	Compartment syndrome	98
10.2.1	Results	98
10.2.2	Discussion	99
11	SELF-APPRAISAL	101
11.1	Results	101
11.2	Discussion	103
12	RE-OPERATIONS	107
12.1	Results	107

12.2 Discussion.....	107
13 STRENGTHS AND LIMITATIONS	109
14 SUMMARY	110
15 GENERAL CONCLUSIONS	113
15.1 Clinical relevance	113
15.2 Future implications	114
ACKNOWLEDGEMENTS	118
REFERENCES.....	121
APPENDIX	155
PAPERS	I-IV

ABBREVIATIONS

AAOS	American Academy of Orthopaedic Surgeons
AO/ASIF	Arbeitsgemeinschaft für Osteosynthesefragen/Association for the Study of Internal Fixation
AOFAS	American Orthopaedic Foot and Ankle Society
AO/OTA	AO Foundation/Orthopaedic Trauma Association
ARDS	Adult Respiratory Distress Syndrome
ASAMI	Association for the Study and Application of the Method of Ilizarov
CI	Confidence Interval
CT	Computed Tomography Scan
CTN	Cannulated Tibial Nail
DCP	Dynamic Compression Plate
DSD	Double Step Duration
EQ5-D	European Quality-of-Life 5-Dimensions Questionnaire
EF	External Fixation
EFL	Effective Foot Length
FAOS	Foot and Ankle Outcome Score
HRQoL	Health-Related Quality of Life
IL	Ilizarov Fixator
IM	Locked Intramedullary Nailing

KOOS	Knee Injury and Osteoarthritis Outcome Score
L	Load
LCP	Locking Compression Plate
LC-DCP	Limited Contact Dynamic Compression Plate
LISS	Less Invasive Stabilising System
MA	Meta-Analysis
MCR	Multi-Centre Randomised Trial
MIPPO	Minimally Invasive Percutaneous Plate Osteosynthesis
MRI	Magnetic Resonance Imaging
NHP	Nottingham Health Profile
ORIF	Open Reduction and Internal Fixation
n.s.	Not significant
PC-Fix	Point Contact Fixator
RCT	Randomised Controlled Trial
ROM	Range of Motion
RDS	Relative Double Step
REV	Review
RS	Relative Speed
SF-12	Short Form Health Survey (12 items)
SF-36	Short Form Health Survey (36 items)

PREFACE

Old concept, new way...

During my first year (1990) as a resident at the Funchal Central Hospital in Madeira (Portugal), I saw for the first time the Ilizarov external fixator (IL), which was used to treat a patient with a tibial pseudarthrosis. In 1992, when I started to work at the Department of Orthopaedics at the Skaraborg Hospital in Skövde (Sweden) and, as in most Swedish hospitals, the IL was not used at all, not even as an alternative treatment option. This technique was mostly considered to be a bulky, technically difficult Siberian method of treatment with uncertain results and a high rate of complications, long hospital stays and unhappy patients. If used at all, the indications were very limited and the operations were therefore only performed by specially trained surgeons at specific centres and IL was mainly used in limb lengthening surgery. There was also a lack of studies in the western medical literature confirming the Kurgan experience, even though Professor Ilizarov had presented his results at several international conferences and published some articles in English. At our department, different external fixators were used in complicated, open fractures as a primary treatment. They were, however, rarely used as definitive treatment, because of the dislocation risk when loaded and the risk of pin/screw infections. Moreover, in the most recent editions of orthopaedic textbooks, the Ilizarov technique has been regarded as a treatment option/alternative mainly in very complicated fractures such as comminute, intra- and juxta-articular fractures, especially if combined with major soft-tissue injuries.

Because of the limited use in Sweden and the difficulty involved in obtaining sufficient experience to use the IL technique in a safe manner, I visited the Russian Ilizarov Scientific Centre for Restorative Traumatology and Orthopaedics in Kurgan, Siberia. I first spent two weeks there in 1999, followed by a further six weeks in 2000. This gave me the opportunity to study the theoretical background and also to participate in several operations where surgeons regularly used the technique for a large variety of indications according to the original instructions given by Professor Ilizarov. It was especially interesting to study the application of the IL technique in fractures normally treated with internal fixation at our department and to see how well the patients coped with the rehabilitation, as they were encouraged to walk with unrestricted weight-bearing immediately postoperatively, which is one of the cornerstones of this treatment. However, the practical conditions in Siberia were different, with most patients being hospitalised for the entire rehabilitation period, something that is not feasible for the health-care system

in Sweden. Based on what I learned in Kurgan, I started to use the IL in selected cases at our hospital.

In terms of the management of tibial fractures, there are well-established ORIF protocols. Even though the “gold standard” of treatment in diaphyseal fractures is IM, there are potential advantages to the IL technique and it appeared relevant to compare the two treatments in a randomised study. However, when it came to metaphyseal fractures of the tibia, the IL soon became the treatment of choice at our department, with fewer complications compared with ORIF, and for this reason we felt it was unethical to perform a randomised study comparing the IL and ORIF. Instead, we chose to follow these patients prospectively. I hope that the results of this work during the past eight years, as presented in this thesis, can be the basis of further discussions with the aim of better understanding and defining the extended use of the IL method.

1 INTRODUCTION

Studying the management of tibial fractures is important for several reasons. Firstly, there is a wide variation in complications with risks associated with both the type and the chosen method of treatment. Secondly, the patients are often active and an early return to daily activities is expected. Tibial fractures can therefore be one of the most challenging fractures to treat.

1.1 Epidemiology

In a United Nations report, Woolf and Pflieger claimed that long-bone fractures are among the most frequent non-fatal injuries sustained following trauma world-wide [1].

Tibial fractures have been reported to represent 17% to 19% of all patients with fractures [2, 3].

Table 1 shows the overall annual incidences of tibial fractures, their localisation and the age of the included patients. Possible reasons for the varying results in the presented studies might be that they are mainly retrospective and represent case series from single hospitals.

Table 1. Annual incidence/100,000 inhabitants calculated from data reported in different epidemiological studies.

Epidemiological studies of tibial fractures Author, (year of publication) and country	Annual fracture incidence/100,000	Included age (years)
Proximal metaphyseal		
Court-Brown & Caesar (2006), UK	13	>12
Diaphyseal		
Emami et al. (1996), Sweden	31	All ages
Ruiz et al. (2000), Northern Ireland	25	>18
Bengner et al. (2000), Sweden	50	All ages
Court-Brown & Caesar (2006), UK	21	>12
Weiss et al. (2008), Sweden	17	10->90
Distal metaphyseal		
Court-Brown & Caesar (2006), UK	7.9	>12

Bengner et al. found no increase in the incidence of tibial shaft fractures during a 30-year period in the city of Malmö in Sweden [4]. Emami et al. compared two time periods (1971-75 and 1986-90) in Uppsala County (Sweden) [5].

They found a higher incidence in men compared with women, but, during the second period, the incidence decreased in men aged 10-19 years because of a reduction in fractures sustained in road accidents. In terms of gender differences, Bengner et al. also found that men had a higher incidence in almost all age groups [4]. In a Swedish nation-wide study, Weiss et al. found an annual incidence rate of 17 per 100,000 person-years and the number of hospital admissions decreased by 12% during the period 1998-2004, mostly following a reduction in male incidence, i.e. confirming a decreasing incidence in Sweden [6].

The majority of diaphyseal tibial fractures are low-energy injuries with relatively minor degrees of soft-tissue injury. According to Court-Brown and McBirnie in the United Kingdom, 76.5% of tibial fractures were closed and 53.6% were Tscherne type C1 [7]. This indicates that severe fractures are relatively rare. The first report of the Swedish Fracture Registry (2011-2012) estimated that 12.6% of the diaphyseal tibial fractures were open [8].

In the United Kingdom in 2000, distal tibial fractures accounted for an incidence of 0.7% of all fractures [9]. Open tibial fractures constituted approximately 2.1% of all open fractures in long bones [10]. Distal intra-articular tibial fractures are relatively rare injuries. Bourne found that these fractures accounted for approximately 7-10% of all tibial fractures and fewer than 1% of all fractures of the lower limbs [11].

In the USA, tibial and fibular fractures annually accounted for 77,000 hospitalisations, 569,000 hospital stay days and 825,000 physician office visits [12]. Also in this country and in 2007, the Agency for Healthcare Research and Quality (AHRQ) reported online in its state inpatient database 151,966 hospital discharges for which tibial/fibular fracture diagnosis was a reason for a surgical procedure [13].

2 THE TREATMENT OF TIBIAL FRACTURES

Different treatment methods have different potential advantages and disadvantages in terms of ease of use, fracture stability, healing time, frequency and type of complications, and patient compliance.

2.1 Conservative treatment

The conservative or non-surgical treatment of fractures is a non-invasive method, based on the use of traction or external splinting producing a closed reduction to restore the alignment and subsequent fracture stabilisation by plaster or brace.

Well-healed fractures in mummies more than 4,000 years old show that, in ancient Egypt, physicians already understood this treatment rationale [14].

More than 2,400 years ago, Hippocrates of Kos described the treatment of limb fractures using a soft layer of bandages which were subsequently stiffened with a cerate [15, 16].

Arab authors reported in the 10th century that, when water was added to anhydrous calcium sulphate, a hard crystalline material was formed when it dried [17]. This procedure was later described as plaster-of-Paris after the city name where, by royal demand, the walls of all wooden houses had to be covered with plaster to provide fire protection in order to avoid a catastrophe similar to the Great Fire of London in 1666 [18]. The invention of plaster-of-Paris impregnated bandages to treat broken bones is attributed to Antonius Mathijsen [19] and Nicolay Pirogov [20]. The first functional plaster braces were introduced by Fedor Krause [21] and Pierre Delbet [22].

In proximal metaphyseal tibial fractures, Apley's method of skeletal traction and early flexion of the knee produced good functional results [23]. However, the technique was demanding, due to prolonged bed-rest followed by protected weight-bearing, which were the two main disadvantages related to this treatment. Cast-bracing treatment removed these disadvantages of Apley's treatment regimen by allowing early weight-bearing and early discharge from hospital [24]. Retrospectively, Anglen et al. found that non-surgical treatment in displaced comminuted proximal tibial fractures was inferior to surgical

treatment with regard to the duration of the hospital stay, the need for immobilisation and the functional results [25]. Jensen et al. (1990) studied the results of the treatment of tibial plateau fractures from two orthopaedic centres. At one hospital, severe fractures in 87 patients were treated non-surgically with traction and early movement, while, at the other, 73 patients were treated by ORIF according to the AO principles, even if the fractures were minimally displaced. As the non-surgical treatment was time consuming and involved a longer hospital stay, it was only recommended in patients where surgical treatment was undesirable for different reasons [26]. We have not found any report of the non-surgical treatment of proximal metaphyseal fractures in the English literature after 1990.

In a prospective survey comprising 674 tibial diaphyseal fractures that were treated non-surgically, Nicoll reported good intermediate-term results in the majority of patients [27]. Sarmiento described functional fracture bracing, inspired by the patellar-tendon-bearing prosthesis [28]. In a summary of his investigations over a 40-year period, he showed that functional bracing was an effective method in managing selected fractures of the tibial shaft [29, 30]. However, he stressed that several fracture types were not suitable for this type of treatment; they included open diaphyseal fractures with moderate or severe soft-tissue damage, closed axially unstable fractures (comminuted, oblique, or spiral), fractures with initially unacceptable shortening of more than 12 mm, which showed increasing angular deformity in the initial cast, fractures with an intact fibula showing an initial angular deformity of $> 5^\circ$ and segmental fractures with initially unacceptable shortening and those with uncorrectable angular deformity. These exclusion criteria limit the opportunity to treat tibial diaphyseal fractures with functional bracing. However, in a prospective series of 145 fractures, in which patients with associated injuries interfering with the normal ambulant treatment were excluded, the Sarmiento below-the-knee functional brace was applied to all patients but three [31]. On the other hand, the difficulty of performing this kind of treatment made Chapman argue “that the technique of applying an immediate weight-bearing cast is as demanding and requires as much motor skill as internal fixation does” [32].

In distal metaphyseal fractures, the disadvantages of non-surgical treatment are the risk of healing disturbances and displacement, as the plaster treatment is not stable enough when the soft-tissue swelling decreases and because of muscle hypotrophy during immobilisation. This calls for a complicated treatment protocol with numerous follow-ups to check and change the plaster. Even though non-surgical management might be a valid alternative to surgery [33, 34], it should probably be reserved for patients for whom an operation is not a choice for other medical reasons [35].

2.2 Surgical treatment

With primary or staged surgery, it is possible to avoid instability and malalignment and to correct articular incongruences. It is also often possible to achieve sufficient stability to allow immediate or early knee and ankle movement training and even weight-bearing. The disadvantages are mainly that surgery adds soft-tissue damage that can cause further healing disturbances/deep infections, while osteosynthesis material left in the body can cause discomfort for the patient and a second operation to extract it is then needed.

2.2.1 Plate osteosynthesis

Plate osteosynthesis is an invasive technique where a metal plate bridging the fracture site is fixed with screws. The plate accommodates compressive, bending and torsional loads, depending on the type of fracture. The plate is usually made of metal, but different composite materials have also been used. It has several holes for screw fixation. The holes can be threaded to allow for locking between the screws and the plate. The technique is more or less invasive. The advantage is that it is possible to achieve an anatomical reduction, restoring the length of the bone and eliminating axial and rotational malalignment. Plate osteosynthesis is often stable enough to enable the training of the adjacent joints. When it comes to proximal and distal metaphyseal fractures, the type of fracture and the size of the fragments will determine the method of osteosynthesis. Sometimes it is necessary to use two plates to increase stability, which further increases the risk of soft-tissue damage.

Back in 1886, Carl Hansmann used a plate which was fixed to the bone with percutaneously inserted screws that protruded through the skin [36]. In 1895, William Lane introduced a metal plate with screws for internal fixation [37]. The plates were, however, not strong enough and they also corroded rapidly. In 1906, Edward Martin published radiographs of fractures of the tibial shaft and metaphysis treated with plates and mono-cortical screws [38]. In 1909, Lewis Steinbach treated four patients with a fracture of the tibia with a silver plate, fixed to each of the fragments with two steel screws [39]. Albin Lambotte (1909) introduced a thin plate, round and tapered at both ends, with less corrosion but without sufficient strength [40].

The next important development in fracture plate design was initiated in 1948 by George Eggers [41]. The Eggers plate had two long slots that allowed the screw heads to slide and thus compensate for the resorption of bone at the fragment ends. However, this plate was structurally weak, which resulted in

instability of the fixation. The principle of inter-fragmental compression was described by Raoul Danis in 1949 [42].

The plate and screw osteosynthesis was re-introduced by the Swiss AO-group in 1958 [43] with the aim of obtaining a rigid, anatomical fixation in which the fragments were compressed against one another. A meticulous surgical technique and an excellent teaching programme further contributed to the success of this plating system. In 1965, Müller et al. presented the opportunity to achieve inter-fragmentary compression by tightening a tensioner that was temporarily anchored to the bone and the plate [44]. The use of the tensioner made it necessary to use a longer incision and it was eventually abandoned in favour of oval holes, the concept of the Dynamic Compression Plate (DCP) [45].

As there is a risk of re-fractures because of bone loss under the rigid plate (stress-shielding), it was recommended that the plate should not be removed for at least 15-18 months [44]. It was argued that this could be avoided with the development of the limited contact-dynamic compression plate (LC-DCP plate) by Perren [46]. The new design aimed to reduce plate interference with cortical perfusion and thus decrease cortical osteoporosis. This was estimated to reduce bone-plate contact by approximately 50% [47]. However, this was contradicted when Field et al. measured the bone-plate interface and found the same contact area for both DCPs and LC-DCPs fixed to cadaveric bone with the exception of the humerus [48]. Ahmad et al. studied the biomechanical stability of the LC-DCP plate *in vitro* and recommend that the plate should be fixed close to the bone (< 2 mm) to allow a mechanically stable environment at the fracture site [49]. This was addressed in the next development, i.e. the Locking Combination Plate (LCP), which permits a combination of locked and unlocked screws that can be fixated to only one cortex. The surgical technique using a minimally invasive procedure and locking screws further increased the opportunity to reduce the contact with bone. This meant that some of the previous disadvantages could be avoided [50].

Whether the cortical blood flow really is improved by these developments is still controversial. Jain et al. measured cortical blood flow with laser Doppler flowmetry of canine tibias fixed with a DCP or LC-DCP and they found no difference in cortical blood flow between the two groups, contradicting the theories behind the LC-DCP plate. They also reported on the biomechanical properties of the tibia and found no differences between the two groups. The authors concluded that “the LC-DCP is not advantageous in fracture healing or restoration of cortical bone perfusion to devascularized cortex” when compared with the older DCP plate [51]. Moreover, simple fractures can lead

to essential microcirculatory disturbances even in muscles at sites remote from the fracture site [52]. The dissection, which plate osteosynthesis requires, could add further soft-tissue damage and concomitant changes in blood circulation which might be more serious than the initial trauma.

Another technical development was the Less Invasive Stabilising System (LISS), in which the locking plate serves as a bridge over the fracture site. This is described as being similar to an external fixator, but the bridging part, the plate, is covered by the soft tissues. As the plate does not require direct contact with the bone, it can be introduced through small incisions with blind application close to the bone surface and fixated with self-tapping screws. With the development and popularisation of minimally invasive surgical implants for fracture fixation, it became increasingly important to use pre-contoured plates. However, Schmutz et al. showed that a global/anatomic fit only occurred for 19% of the bone models using anatomic plates for the distal medial tibia [53]. The LISS plate can be inserted using small incisions (MIPPO) and has the added advantage that direct exposure of the fracture lines is avoided, while the indirect reduction preserves the vascular perfusion, at least in theory [54]. Uthoff et al. claimed that only plates allowing dynamic fracture compression in the axial plane can lead to a revolution in fracture fixation [55]. Qiu et al. found that locking plates could be used as definitive external fixators with acceptable clinical results in tibial fractures with a compromised soft-tissue envelope [56].

Even though, the use of the LISS and the LCP has created new opportunities to treat metaphyseal and epiphyseal fractures [57], it has not been possible to demonstrate cost-effectiveness or cost-utility when compared with older plates [58, 59]. Nor have these more recent plate designs, like the PC-Fix in which the concept of inter-fragmentary compression and bicortical fixation was abandoned, improved the overall clinical outcome [55].

In proximal metaphyseal fractures, the minimally invasive technique should protect the soft-tissues, but Jöckel et al. found that the early functional results and complication rates were similar to those associated with earlier techniques reported in the literature [60].

In a meta-analysis of diaphyseal fractures, Bhandari et al. concluded that the reason for more complications with plate fixation compared with both external fixation and IM is the additional vascular damage to the bone and soft tissues [61].

In distal metaphyseal fractures, Zou et al. found no differences in healing time when MIPPO was compared with traditional ORIF in type A and B fractures. In type C fractures (extra-articular), there was a trend towards shorter healing times with MIPPO [62]. Bastias et al. compared DCP and LCP plates and found that both systems produced similar results in terms of time to union, infection rates and AOFAS score, but the LCP appeared to be superior with respect to alignment and the need for implant removal [63]. In another study of anatomical specimens, it was shown that MIPPO in the distal tibia could constitute a risk of damage to the neurovascular structures when the distal screws were placed through stab incisions [64]. However, Strauss et al. demonstrated that, in distal metaphyseal tibial fractures, locked plates produced better fixation stability when compared with the IM for axial loading, while they were less stiff in cantilever bending scenarios. Locked plates also appear to provide better fixation than intramedullary nails for fracture patterns in which the fibula cannot be stabilised [65].

2.2.2 Intramedullary nailing osteosynthesis

The IM is an invasive technique in which a rod/nail is used to bridge the fracture site. The nail is introduced at a distance from the fracture site. It is usually made of metal and can be hollow or solid, with stabilising screws on either or both sides of the fracture. The advantage is that it is possible to insert the nail without the open reduction of the fracture. When stabilising screws are used, it is often stable enough to allow the training of adjacent joints and also some weight-bearing.

This technique can be performed with or without reaming. Depending on the shape and type of fracture, direct stability can often be achieved. To secure length and rotational stability, one or more interlocking screws can be introduced proximally and distally through holes in the nail. The technique is minimally invasive, but the introduction of the nail in the medullary canal increases the intramedullary pressure and also the pressure in the surrounding soft tissues [66, 67]. This could theoretically be associated with an increased incidence of compartment syndrome [68, 69].

In 1887, Heinrich Bircher was the first to treat diaphyseal fractures of the femur and tibia with intramedullary ivory pegs [70]. In 1913, Georg Schöne in Germany made the first “closed” nailing (silver nail) of a diaphyseal fracture assisted by fluoroscopy [71]. In 1915, steel rods were used by Ernest Hej-Groves [72]. In 1937, the Rush brothers [73] in the USA and in 1940 Gerhard Künstcher [74] in Germany independently developed the intramedullary nailing technique.

Künstcher was the first to show that the stabilisation of the fixation could be improved by reaming the medullary canal [75]. The interlocking of the intramedullary nailing became popular after the work of Klemm [76] and also Grosse and Kempf [77] in the 1970s and 1980s. However, intramedullary reaming was considered to be the main reason for a higher risk of fat embolism syndrome and ARDS [78, 79]. The reaming and insertion of an IM has also been shown to reduce the endosteal and cortical blood flow by approximately 70% [80-82]. The use of unreamed nails should avoid these disadvantages and they could also be used when treating open fractures, thereby reducing the risk of infection with reaming [83]. Nevertheless, using unreamed nails has not been shown to improve the healing time [84, 85]. Reaming the medullary canal also appears to have some positive effects at the fracture site, such as increasing extra-osseous circulation, which is important for bone healing [86] and increased mechanical stability [87, 88]. In patients with closed tibial shaft fractures, it was reported in the SPRINT study that the re-operation and complication rates were lower after reamed IM compared with unreamed [89]. The reamed IM, when applied to closed and open Gustilo I diaphyseal fractures, produces good results and has also been recommended from an economic standpoint [90]. In a systematic review, Lam et al. found a consistent trend towards a reduced non-union rate in closed tibial shaft fractures with reamed IM compared with unreamed IM [91]. Xia et al. reported a meta-analysis studying the clinical outcomes of reamed vs unreamed IM in the treatment of 1,229 closed tibial fractures. They concluded that reamed IM may lead to a significantly lower risk of non-union, screw failure, implant exchange and dynamisation without increasing operative complications [92].

Titanium nails have also been used, but they have produced similar results to stainless steel nails [93].

IM can be challenging, especially when significant shortening and/or translation of the fracture is present. Several techniques have been described to facilitate the introduction of the nail in the diaphysis [94-96]. The nailing of fractures in the proximal third of the diaphysis is technically challenging [97, 98]. Rates of malalignment ranging between 58% and 84% have been reported after IM of proximal diaphyseal tibial fractures [99]. Choosing the right size of implant is also crucial for satisfactory outcomes, as pointed out by Galbraith et al. in a cadaveric study. They found that anatomical measurements, such as the distances between the knee joint line and the ankle joint and between the tibial tuberosity and the medial malleolus, were not accurate enough to predict the ideal tibial nail length. The only exact method to determine the ideal nail length was computed tomography. In the clinical setting, they recommended pre-operative measurements of the uninjured side [100]. Depending on the

fracture type, in most patients treated with IM, the stability is sufficient to enable a gradual increase in weight-bearing and, in several cases, full weight-bearing. However, IM of the tibial diaphysis is not without a risk of complications [94, 101-103].

The most important risk with IM is difficult-to-treat deep infections. The overall incidence of deep infections was more than 10% a few decades ago, but it has diminished during the last few years [104]. In a multicentre register study in low- and middle-income countries, the overall infection rate was 1.5% (95% CI: 1.4-1.6) in tibial fractures treated with IM. The association between follow-up and infection rates after IM was also studied. If only nails with a registered follow-up visit were included (n=10,684), the infection rate was 6.9% (95% CI: 6.4-7.4) for tibial fractures and the infection rate increased in studies with more adequate follow-up rates [105].

Other not uncommon complications after IM in diaphyseal fractures are shown in Table 2.

Table 2. Post-operative complications after acute IM in tibial diaphyseal fractures.

IM complications	%	Number of patients
Deep infection		
Klemm & Börner (1986)	2	401
Alho et al. (1990)	3	94
Court-Brown et al. (1990)	2	125
Angliss et al. (1996)	1	63
Blachut et al. (1997)	2	152
SPRINT study (2008)	1	1226
Young et al. (2011)	1	17382
Compartment syndrome		
Court-Brown et al. (1990)	3	123
McQueen et al. (2000)	6	810
Deep vein thrombosis		
Blachut et al. (1997)	1	154
Uhlen & Hammer (1998)	4	55
Larsen et al. (2004)	4	45
Pulmonary embolism		
Angliss et al. (1996)	1	63
Blachut et al. (1997)	1	154
Keating et al. (1997)	3	91
Dropped hallux deformity (without evidence of compartment syndrome)		
Robinson et al. (1999)	5	208
Peroneal nerve injury		
Klemm & Börner (1986)	1	401
Koval et al. (1991)	4	60
Anterior knee pain		
Court-Brown et al. (1997)	41	125
Toivanen et al (2002)	80	50
Material fatigue with breakage of the nail or locking screws/unreamed IM		
Cole & Latta (1992)	40	56
Iatrogenic fractures		
Strecker et al. (1996)	0-8	162
Malunion		
Alho et al. (1990)	21	94
Court-Brown et al. (1990)	2	123
Koval et al. (1991)	4	60
Freedman et al. (1995)	12	133
Blachut et al. (1997)	7	152
Boucher et al. (2002)	77	71
Non-union		
Alho et al. (1990)	3	94
Blachut et al. (1997)	15	152
Court-Brown (2004)	11	1106
Larsen et al. (2004)	7	45

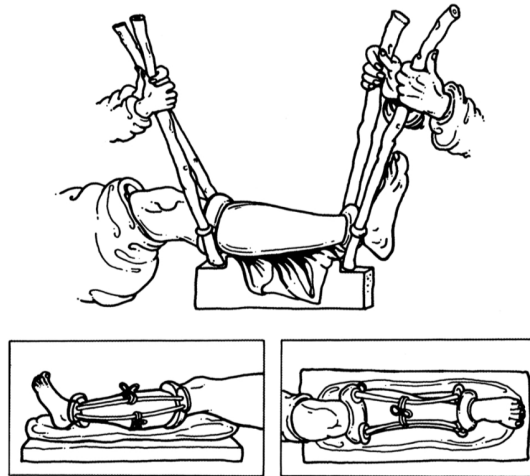
Despite these shortcomings, IM has become the preferred choice of treatment in tibial diaphyseal fractures and is regarded as the “gold standard” treatment at almost all hospital units [106]. There is also support for IM in randomised studies when compared with non-surgical treatment of diaphyseal fractures [107-109].

The introduction of interlocking tibial nails has extended the indications for nailing to include proximal and distal metaphyseal fractures of the tibia. However, the IM fixation of proximal tibial fractures is associated with a much higher rate of complications than the IM fixation of midshaft fractures [98]. The management of distal metaphyseal tibial fractures with IM has been more advantageous than the nailing of fractures of the proximal third of the tibia [110-114], but the control of alignment has been difficult [115]. In both extra-articular proximal and distal metaphyseal fractures, the widening of the metaphysis increases the risk of tilting in the metaphyseal fracture part, resulting in malunion and delayed healing [86]. In two studies of proximal and distal metaphyseal fractures treated with IM or plating, the complication rates were similar, regardless of treatment [33, 116]. In a recent study of distal metaphyseal extra-articular tibial fractures, Iqbal et al. showed that both nailing and plate techniques can provide adequate treatment in selected patients, albeit with a risk of significant complications [117].

2.2.3 External fixation osteosynthesis

External fixation is based on the principle that the fracture fragments are fixed with percutaneous screws, pins or wires, connected to a fracture bridging external frame. The surgical technique is minimally invasive.

The technique of using an external frame to control the bone fragments was described by Hippocrates. In his technique for tibial fractures, rings were placed below the knee and above the ankle. Hippocrates used levers to reduce the fracture and, after reduction, the rings were fixed to bridging sticks [118] (Figure 1). In 1843 Jean Malgaigne introduced a rudimentary external fixator with clamps with skin-penetrating tips to treat patellar fractures [119], which in 1861 was used in several patients by Elias S. Cooper [120].



©Einhorn-Presse Verlag

Figure 1. The principle of the external fixator for tibial fractures, with wooden splints, as applied by Hippocrates.

External fixation as we know it today is traditionally ascribed to Clayton Parkhill, who, in 1897 (USA), introduced a so-called bone clamp with percutaneous pins connected to a rigid external plate [121]. In Europe, Albin Lambotte (1907) presented a “bone suture device“, similar to Parkill’s bone clamp, at the beginning of the 20th century [122] (Figure 2).



Figure 2. A photograph taken on 24 April, 1902 shows Lambotte with his assistant/brothers applying his device to a femur in Styvenberg Hospital in Antwerp (Belgium).

He also used the term “external fixator” for the first time. Lambotte developed this system in order to make it suitable for almost all bones, including fresh diaphyseal fractures. One disadvantage of this external fixation was that the fracture reduction had to be performed meticulously, often using open surgery, before inserting the pins, as correction at a later stage was impossible. In 1934, Roger Anderson constructed a frame to reduce and compress fractures until a cast was applied. It worked with movable horseshoe-shaped clamps that encircled the leg posteriorly and was the first external fixator that made multiplanar adjustments possible [123]. Adjustable connecting metal bars, allowing reduction in three planes independently, were first described by the veterinary surgeon Otto Stader. He used it in long-bone fractures in dogs in 1937 [124].

In 1938, Raoul Hoffmann introduced a system with a universal ball joint pin holder that connected the rods and the fixed clamps, allowing better closed reduction and correction in three planes after the application [125]. He also developed self-tapping pins that could be inserted percutaneously.

In a retrospective study of 104 open fractures, Rosenthal et al. documented significant complications using external skeletal fixation and recommended against its use [126]. This study corroborated a previous report by the Committee on Fracture and Trauma Surgery of the AAOS, which led to reluctance to use external fixators during the following decades [127].

The AO/ASIF unilateral tubular monofixator was constructed to combine stability and versatility, making use of only four basic elements: tube, tube caps, Steinmann pins (or Schanz screws) and adjustable clamps. Jaskulka et al. found that the AO/ASIF fixator (as a one-plane, double-tube, unilateral frame) offered sufficient stability only in its non-dynamised form [128]. They recommended that this fixator should be restricted to cases where dynamisation was not desirable.

In 1995, a new generation of prototypes (Hoffmann II[®]) was presented internationally: they fulfilled some desirable requirements such as a pin holder with a spring-loaded, snap-fit mechanism, the opportunity for free pin placement, the reduction of the number of individual components and colouring of the fixator components for improved patient acceptance [129]. The Hoffmann II[®] external fixator system retained all the advantages of the original Hoffmann fixator, i.e. the modular system, the universal joints and the free placement of the pins in all three planes. This enabled exact fixation during assembly and reduction. Today, the connecting rods are made of aluminium or carbon fibre and are thus radiolucent. The introduction of the Hoffman II[®]

external fixator with its great versatility has made this external fixator the preferred method of emergency temporary treatment in the USA (Stryker, Mahwah, New Jersey) [130].

De Bastiani described a dynamic axial monolateral fixator (Orthofix[®]) with a telescopic single bar that allows dynamisation [131, 132]. The fixation bar has articulating ends with clamps and self-tapping screws are used. Since then, similar principles have been developed in other external fixators constructed to make application even easier, like the Hammerfix[®] [133], the Monticelli-Spinelli fixator[®] [134] or the Ex-Fi-Re[®] [135].

A simplified type of external fixator, using percutaneous half-pins fixed with a material that solidifies as plaster, such as methacrylate or epoxy, is still used in some countries [136].

2.2.3.1 Types of frame configuration

A comprehensive summary of different configurations of external fixators available at present is shown in Table 3.

Table 3. Configuration, definition and types of external fixation.

Configuration	Definition	Examples
Unilateral	One rod connecting two or more pins, clamps (sometimes with universal joints) attached to half-pins. All the elements are installed on one side.	AO Ex-Fi-Re Hammerfix Hoffmann Orthofix Wagner
Bilateral	Rods on both sides of the limb connected to transfixing pins, clamps attached to half-pins.	AO Hoffmann Roger-Anderson Vidal-Adrey
Quadrilateral	Four rods within the system, two on each side of the limb.	Kronner Vidal-Adrey
Biplanar	Rods connecting pins placed in two or more planes limited to sector α ($0 < \alpha < 180^\circ$), clamps attached to half-pins.	AO Hoffmann
Hybrid	Rods connected to transfixing pins and half-pins (alone or in combination) and a half-ring encircling the leg in the transverse plane to its long axis.	Ace-Fisher EBI DynaFix Howmedica antero-medial Monticelli-Spinelli Orthofix Sheffield Tenxor
Ring	Rods or struts connecting complete circular rings or hoops surrounding the limb attached to transfixing pins or wires.	Adams Ilizarov Kronner Matsukidis-Shevstov Seide TSF

2.2.3.2 Advantages of external fixation

External fixation is a versatile technique that can be used for almost all types of fracture and it is minimally invasive, thereby reducing the risk of devitalisation and contamination of the bone tissue. So, when compared with plate osteosynthesis and intramedullary nails, external fixation causes less damage to the soft-tissues, osseous blood supply and periosteum [137]. Because of this and the fact that external fixation is easy to apply provisionally, it is often used as the initial treatment of choice in high-energy closed or open fractures when the viability of the limb is threatened. With modern external fixators, it is also possible to improve the fracture reduction/alignment after the primary application. External fixation is also applicable in patients with unacceptably small medullary canals, e.g. children or patients with a complex peri-articular fracture.

There are further theoretical advantages to external fixation. Better stability can be achieved in comminute fractures by adding the fixation of several bone segments, where other methods would fail. It also offers the opportunity to change the relative position of the fracture fragments in order to correct deformities. The predominant stimulus for the proliferation of bone marrow stem cells is blood perfusion [138] and external fixation allows maximum perfusion at the fracture site [139, 140]. The negative effect of denervation on fracture healing as observed with plate osteosynthesis [141] might also be less pronounced.

External fixation has to be removed, but this can be done without regional or general anaesthesia in the majority of patients [142]. These devices might also have some financial advantages, because their re-use is safe and effective [143, 144].

2.2.3.3 Disadvantages and complications of external fixation

External fixators have a reputation for causing problems, but there are effective solutions for several of these problems [145]. To avoid complications when using external fixators, the surgeon must have a good knowledge of the cross-sectional anatomy, a three-dimensional approach to plan and modify the frame and use the correct technique when inserting the wires, screws and pins. Prophylactic cleaning of the entry sites of screws and pins is also important to avoid local infections [146, 147].

External fixation treatment is dependent on patient compliance. However, the removal of the fixator due to non-compliance is rare and should be avoided, as it might compromise the final result. To avoid serious problems during the treatment, it is helpful to show the patient the external fixator before surgery. The patient must be adequately prepared psychologically to accept alterations of the frame and repeated minor surgical procedures [148, 149].

When analysing complications, it is important to distinguish between minor and major complications. The former are simple and expected to occur during treatment and require simple measures. These minor complications are treated non-operatively or with simple alterations to the frame, without jeopardising the stability or the final result [150, 151]. Major complications are difficult to treat and could compromise the result.


Behrens made a summary (Table 4), identifying complications and disadvantages as clinical, mechanical, depending on product manufacture and multifactorial [152].

Table 4. Problems and complications of external fixation according to Behrens (1989).

Clinical	Incorrect pin placement causing neurovascular injuries and joint stiffness (tethering of tendons, ligaments, and capsular structures)
	Obstruction of wound or injury access by the fixator frame
Mechanical	Component failure caused by incorrect handling
	Mechanical frame properties inadequate for clinical needs
Product manufacture	Breakage, deformation, or malfunction of components
	Inadequate instrumentation and instruction
Multifactorial	Pin problems (drainage, loosening, infection)
	Delayed or inhibited bony consolidation
	Mismatch of clinical needs and frame properties
	Unrealistic expectations, lack of experience, and a lack of long-term planning

3 ILIZAROV METHOD

External devices with wires for the fixation and distraction of fractures were already in use before Ilizarov and some of them have been described by Klapp [153].



“Imagination is your limit”

Gavril Abrahmovich Ilizarov (1921-1992)

3.1 Ilizarov - short biography

Gavril Abrahamovich Ilizarov was born on 15 June 1921 in the town of Belovezh (Belarus). The start of his medical education at the Crimean Medical Institute in Sinferopol coincided with the beginning of the Second World War. In 1944, he was sent to Dolgovka in the Kurgan Region of Siberia to work as a general practitioner in a log cabin hospital with wood stove heating in very primitive conditions. In 1952, he patented his original fixator, which was an improved modular ring external fixation apparatus. In 1955, he became head of the Trauma and Orthopaedics Department at the Veterans' Hospital in Kurgan. There he was able to treat hundreds of soldiers with unhealed fractures mainly caused by gun shots. This experience made him understand that the delayed healing of limb fractures and their complications were due to the methods of treatment and fixation rather than the nature of the fractures. He systematically studied all possible applications of his external fixator in different fractures and pathologies.

Having achieved noticeable results in fracture treatment, Ilizarov gradually widened the indications for his fixator and, in 1952, the *Krasniy Kurgan* newspaper reported that he had performed a 12.3 cm lengthening of the tibia with the help of his apparatus without bone grafting. In parallel with his clinical work, Ilizarov also conducted scientific research at the Sverdlovsk Scientific Research Institute for Restorative Surgery, Traumatology and Orthopaedics in Yekaterinburg. He studied the influence of fixation forces on bone consolidation times. On the initiative of Ilizarov, a scientific laboratory was organized in Kurgan in 1966 and he was appointed its first director. In 1968, he presented and defended the scientific thesis *Compression osteosynthesis with the author's apparatus* which was evaluated and approved by the Specialised Council of the Perm Medical Institute.

In 1969, the Ilizarov Laboratory became affiliated with the Leningrad Scientific Research Institute for Traumatology and Orthopaedics. In 1970, the USSR Ministry of Health decided to organise the Russian Ilizarov Scientific Centre for Restorative Traumatology and Orthopaedics (RISC RTO) as an independent scientific institution. It was claimed to be the largest orthopaedic hospital in the world.

Despite its widespread use in the Soviet Union, Ilizarov's work was only published in the Russian language and, because of the political situation during the Cold War era, it was unknown to the western world for many years. In 1980, the technique was introduced in Western Europe thanks to the famous Italian alpinist and adventurer Carlo Mauri. Mauri had a tibial fracture with an

infected pseudarthrosis which had previously been treated unsuccessfully with eleven operations. After having been treated successfully by Ilizarov himself, he arranged an invitation from the Italian Orthopaedic Society for Ilizarov to visit Lecco, where he made his first presentation outside the countries behind the Iron Curtain. However, it was not until 1982, when Bianchi-Maiocchi and a group of Italian orthopaedic surgeons had visited Kurgan, that studies of the Ilizarov technique were started outside the Soviet Union, initially in Italy. A decision to start an Association for the Study and Application of the Method of Ilizarov (ASAMI) was made on this visit. During the following years, Ilizarov, also visited France, Mexico, Spain, Portugal, the USA and other countries, by invitation, and the ASAMI became an international network.

The ASAMI is still an active organisation, but another group, the ILLRS (International Limb Lengthening and Reconstruction Society), was started in 2012. They are aiming to broaden the discussion to include all types of external and internal fixation technique applied to limb lengthening and reconstruction. Some efforts are currently being made to unite both organisations, at least with common congresses.

Ilizarov paid a great deal of attention to training and instruction. As an active tutor, he also supervised 52 medical theses for candidate and doctor's scientific degrees.

Gavril Abrahmovich Ilizarov died in Kurgan (Siberia), on 24 July 1992.

Ilizarov's data biography was adapted from the web site of the Russian Ilizarov Scientific Centre for Restorative Traumatology and Orthopaedics in Kurgan, Russian Federation at:
http://www.ilizarov.ru/en/index.php?option=com_content&view=article&id=6&Itemid=

3.2 Biomechanics of the Ilizarov apparatus

Ilizarov stated that the application of his principles made it possible to treat all kinds of fracture, to repair extensive soft-tissue defects in one operative stage without grafts, to achieve bone thickening, to treat congenital or traumatic pseudarthrosis, to achieve limb lengthening, to correct bone and joint contractures or deformities, to perform percutaneous arthrodesis, to fill solitary bone cysts or other cavities, to treat septic non-unions and to stimulate vascular regeneration in occlusive vascular diseases without bypass grafting [154].

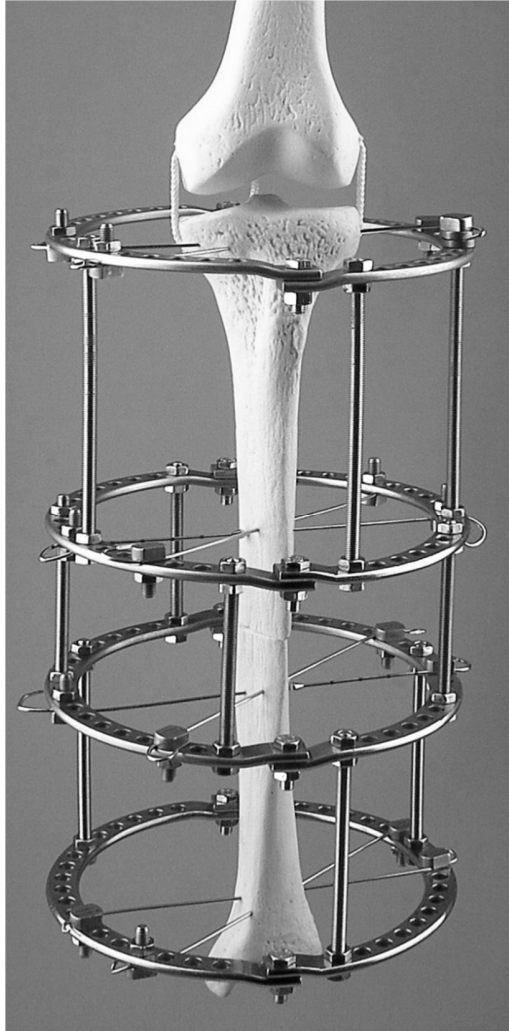
Ilizarov's treatment philosophy emphasises the importance of minimal surgical damage to anatomical structures and that bone loading is transmitted in such a way that bone healing is properly stimulated without permanent implants [155, 156].

In 1992, Ilizarov published his textbook in English on the principles and surgical technique of the IL [155]. This illustrated monograph is still the best available comprehensive description of the basic science, biomechanical principles and clinical strategies of the original method. In another work, published originally in Russia and later translated to English, Solomin included a comprehensive classification of external fixation devices and a description of the tools and the biomechanical basis of the Ilizarov apparatus [157]. In his book, Catagni et al. described the traditional application techniques compared with the newer development of the advanced hybrid system with minimal osteosynthesis and half-pins [158] and also published an atlas that shows the "safe corridors" to introduce the wires and/or half-pins in the extremities [159].

There are different strategies to accomplish the application of the IL in the tibia, and they have been described exhaustively by Hutson Jr. [160].

The behaviour of the IL, like other external fixators, is dependent on a large number of variables, which determine the overall biomechanical performance at the fracture site. Many of the studies have been conducted to determine the biomechanical characteristics of different frames. However, many are *in-vitro* studies and do not necessarily simulate a clinical fracture situation, because the interaction of the soft-tissues is not present [161]. The fact that these are also essential for stability was demonstrated in the studies by Sarmiento et al., who utilised the effects of the surrounding tissues to stabilise the fracture during weight-bearing [162].

Ilizarov suggested a configuration that allows adequate frame stability, using two rings for each bone segment assembled in line with one another [155] (Figure 3).



©T.Ramos

Figure 3. The standard IL with two tibial bone segments suspended by thin tensioned wires within an exoskeleton, consisting of four rings connected with four longitudinal rods.

According to Ilizarov, the success of his method depends on the specific mechanical behaviour of the device in which rigid systems, such as plates and traditional external fixators, have been replaced by the axially elastic system

of the IL [149]. The cyclic axial motion at the fracture site is a result of weight-bearing and is an important requirement for the formation of a callus.

According to Watson et al., the ideal characteristics of a ring fixator in order to optimise the healing process should be: (1) maximum off-axis rigidity to prevent rotational, torsional and shearing motion at the fracture site; (2) controllable and variable axial stiffness for the management of the degree of inter-fragmentary motion during all stages of the treatment; (3) minimum soft-tissue damage due to wires and pins and (4) the maintenance of strength and stability for long duration of treatment [161].

Biomechanically, axial compressive loading and micro-motion in the osteogenic zone will stimulate the bone bridging of the fracture gap [163-167]. Ilizarov stated that inadequate stability can lead to damage to local blood circulation and the formation of fibrocartilage that might delay or inhibit bone union [156]. This may lead to patient discomfort, which in turn can lead to a reduced functional level and altered vascularity, oedema, joint stiffness, osteoporosis, complex regional pain syndrome and wire infection [168]. Ilizarov also reported that a lack of axial loading in the presence of normal blood supply and adequate bone stability will cause resorption at the bone gap site [155]. This has also been observed in other studies [165, 169, 170]. When comparing unilateral fixators (Hoffmann, Wagner and Orthofix[®]) and the IL in an experimental evaluation performed with a testing machine, Juan et al. observed that there was insufficient rigidity in the external fixation devices during the early post-operative phase and concluded that “regardless of the external fixator callus development was the overriding element for the rigidity of the fixator-bone system”. They postulated that a highly rigid external fixator would avoid some micro-movements at early consolidation stages but would not prevent load transmission through the callus when the callus appears [171].

In order to understand how optimally to apply the Ilizarov system, a basic knowledge of the biomechanics of the applications is essential.

Gasser et al. compared the stiffness characteristics of the IL as opposed to conventional external fixators and found that the IL exhibited non-linear stiffness behaviour, particularly under axial load, which has a favourable effect on the induction and tolerance of bone formation [172].

There are several requirements that have to be met in order to achieve a stable, well-aligned frame. Firstly, it is important to attach at least two connected rings (a ring block) to each bone fragment. The stability of the ring block depends on the number of rings, the ring size, the distances between the rings, the span

of the rings across the bone, the number of connections between the rings and the number of points of fixation to the bone. The standard construction to stabilise a bone segment consists of two rings with two points of fixation (wires or half-pins) per ring and four connecting rods. Constructions with two wires and two half-pins connected to a single ring are less stable as compared to a double-ring block in almost all modes of loading [173].

The tension of the thin wires is essential for the stability of the IL construction. Hillard et al. studied the effects of plastic deformation in wires subjected to moderate loading conditions. They concluded that the high stresses generated adjacent to the points where the wires are fixed to the ring, due to the bending of the wire, exceeded the yield stress of the wires. This leads to a deformation that causes a successive reduction in tension per load cycle if the wires are not re-tensioned [174].

Compared with constructions using larger diameter fixation pins, the IL is relatively flexible in the axial direction of the long bones, perpendicular to the wires during loading [175, 176]. In order to promote axial micro-motion and to avoid the large inter-fragmental movements, the Ilizarov frame requires a “window” of adequate biomechanical settings for sufficient dynamic stable fixation: wire pre-tensions of 981-1,275 N (100-130 kg) and bolt-tightening torques in the 10-20 Nm range [155, 158, 177, 178]. The wires then act as small springs within the more rigid system of rings and the threaded connecting rods [175]. Bronson et al. found that, with a four-ring configuration, each extra-wire produced an improvement of approximately 10% for both axial and torsional stiffness and bending [179].

A reduction in ring size reduces the wire span and increases the overall frame stiffness. In biomechanical studies, the reduction-of the ring diameter by 2-4 cm has been shown to increase the axial stiffness by 30-70% [172, 179]. However, a limiting factor when trying to use smaller rings is that a distance to the skin of approximately 2-3 cm is necessary to allow for some post-operative swelling.

Gardner et al. tested the stability of tibial fractures treated with two different types of unilateral external fixator (Orthofix[®] and Howmedica Monotube[®]) in four patients. Since weight-bearing and displacements did not differ substantially, they were not able to show that one fixator provides a mechanical environment substantially different from another [180], which might have been due to the limited number of patients. In the fixators, which they tested, the assembly can become so rigid that it might cause healing disturbances due to stress-shielding. Undesirable plastic or slip failure of the unilateral frames may

also occur during routine weight-bearing on unstable fractures, which might affect long-term inter-fragmentary stability [181].

The more the IL is axially loaded, the more the wires and the frame tend to become stiffer (self-stiffening) [172, 182, 183]. This leads to increased rigidity in the system with higher loads and thereby more stability at the fracture site. It is possible that this effect makes the patient adjust the load passing through the fracture site. Bronson et al. concluded that the contribution of each parameter of fixation (ring diameter, wire angle, ring separation) to overall bone fragment stability is dependent on the mode and degree of loading [179].

The fixation achieved with unilateral fixators using half-pins differs from wire transfixation. The traditional IL allows more axial motion than the unilateral fixators [184]. The stability of a half-pin is much less in the cancellous metaphyseal bone compared with in the cortical diaphyseal bone. The pin of a unilateral fixator is also exposed to an undesirable cantilever effect, which can lead to loosening depending on the repetitive cyclical load during walking [185]. The interactions occurring at the interface between implant and bone might also be important when it comes to understanding the mechanical properties of the fixator. Board et al. analysed *in vitro* the pressure distribution at the wire-bone interface during loading and found that it was uniform 4.0 mm from the wire. In contrast, the half-pin model showed far higher pressures, which were present deeper in the bone specimen. A tensioned wire in the IL distributes stresses more evenly since the elastic modulus of the wire is closer to that of metaphyseal bone [186].

The method for the further optimisation of the beam load is to have rings on both sides of the fracture site. In an experimental study, the wires in the Ilizarov apparatus lost pre-tension during mechanical testing, but this did not appear to lead to increased cyclic axial micro-motions of the bone fragments [187]. Caja et al. concluded, when comparing the mechanical performance of three types of external fixator (unilateral, hybrid and Ilizarov), that some complications encountered during the treatment (e.g. pin-tract infections and loosening) can be related to the mechanical behaviour of the fixator [188]. The elastic deformation and slippage at the wire has been shown by Aronson and Harp to cause loss of wire tension during cycling loading. They found in tests that slotted bolts were the best to prevent this, as they have a larger wire/bolt contact area [178].

In vitro biomechanical analysis showed that the stability of the Ilizarov fixator depended on the function of bone position within the fixator rings as well as wire tension. The IL allowed significantly more axial motion at the fracture

site during axial compression than the other fixators (unilateral half-pins) [166]. In the same tests, the authors also noted that the use of an olive/“stopper” increased the shear resistance in the IL. Hasenboehler et al. studied the fatigue behaviour of the IL versus IM in a communitied tibial fracture model and found that both fixations were able to maintain the fracture stability of the tibial gap and to complete the full 252,000 loaded cycles during the entire study period of three months. A significantly higher stiffness to axial compression and torsion was demonstrated by the tibial interlocking nail model, while the IL provided a significantly increased range of axial micromotion. The fracture site with IM is often not compressed and might be held apart, as a result of which the majority of the weight-bearing force passes through the implant [189]. This is one reason for the high rate of locking screw failure [190].

When loaded, the IL resists almost any angulation and it has been demonstrated that, as in another ring fixator, there is a distribution of stresses through the fracture [182] Hybrid fixators in which, the metaphysis construction is fixated with tensioned wires and connected to the diaphysis with pins by connection bars, still have the problem of cantilever stresses. Unilateral, bilateral or hybrid frames do not provide sagittal or 360° rotational stability and do not have the rigidity of a circular wire frame. Moreover, the dampening of rotational forces is not possible with eccentrically placed fixators [191-193].

Circular fixation is more stable when compared with hybrid circular fixators. Ylmaz et al. noted that the hybrid fixator models had less axial and bending stiffness than standard IL models [194]. Voor et al. compared a unilateral frame with hybrid external fixation in proximal tibial fractures and found that approximately half the fracture site motion was related to frame deformation and half to deformation of the pins and wires [195]. So combining the configuration of the ring fixator with the unilateral fixator does not guarantee that the method will encompass the benefits of the two approaches, because they introduce unexpected angular, rotational and translational motion at the fracture site with higher loads [196, 197]. Gessmann et al. studied the influence of direct and indirect weight-loading on the tensioned wires using a weight-bearing platform applied to a composite tibial model with an osteotomy gap fixated with a standard four-ring IL. The wire strain was measured with two gauges positioned at the ring-wire interface of each wire. When using the weight-bearing platform, the mechanical stress on the tensioned wires was up to 400% higher on the proximal wires in the tibia and up to 250% higher on the distal wires under axial loading of the bone [198]. As bone healing progresses and the gap is filled with callus formation, the load which is taken up by the fixator decreases [199] (Figure 4).

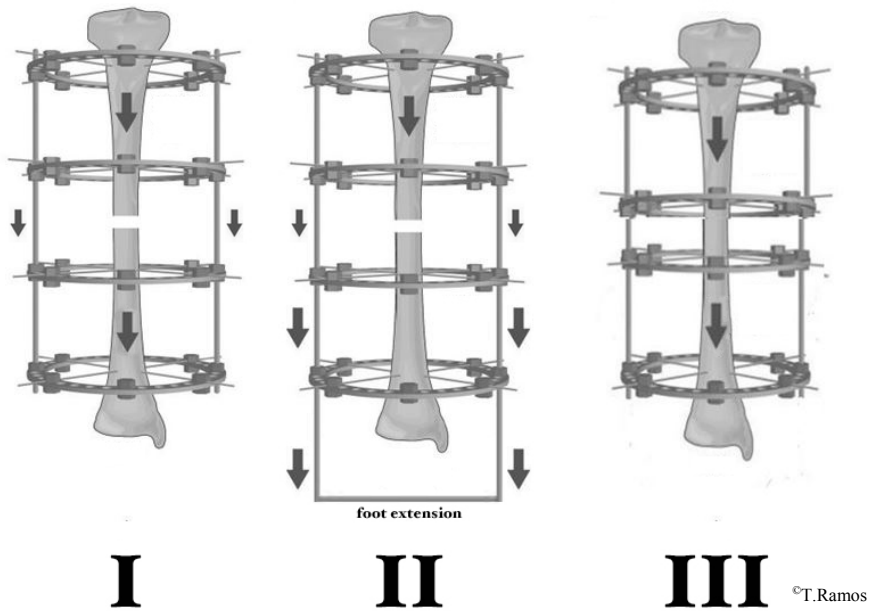


Figure 4. The load transmission in a tibial gap under direct load (I), indirect load with foot extension (II) and when the gap is filled (III) in a standard IL with two tibial bone segments (modified from Gessman et al. *J Orthop Surg Res* 2011; 6:61).

Aarnes et al. defined a load/share ratio to calculate the percentage of the weight-bearing load that was taken up by the fixator. As healing progressed, the amount of the load that the bone supported increased and the ratio decreased. When 10% of the load passed through the fixator, they considered that the frame could be removed [200].

3.3 Technical developments of the Ilizarov technique

During the last few decades, there has been a trend towards the construction and use of computer-dependent fixators (Taylor Spatial Frame[®] /TSF, Seide-Hexapod[®], Adam frame[®] and so on). These systems provide an opportunity to make corrections in six directions simultaneously and sequentially. They have “popularised” the use of ring fixators, but they require extensive training and are therefore mainly suitable in the treatment of complex deformities. A comprehensive review of the different hexapod systems and history has been presented by Paley [201].

The TSF is probably the most widespread hexapod system in clinical use since 1995. Binski et al. identified the TSF as a valuable tool in the acute care of tibial fractures [202] but Menakaya et al. reported that, in tibial fractures, the healing time with the TSF was no shorter compared with the IL [203]. Kristiansen et al. stated that there were no differences between using the TSF and the traditional IL in tibial lengthening [204]. Dammerer et al. evaluated the TSF compared with the IL and Orthofix[®] unilateral fixators in children where bony deformity corrections were performed and concluded that the advantages were not sufficient to justify the higher cost [205]. Elbatrawy et al. reported that the TSF is more cumbersome than the traditional IL and the financial cost is comparatively higher when it is used to treat deformity and trauma of the lower limb [206].

Seide et al. described a practical approach whereby a traditional IL can be converted to a hexapod system, by substituting the threaded rods with struts attached externally to the rings. Its telescopic rods are adjustable down to 0.1 mm [207].

The Adam frame[®] [208, 209] presented the idea of an octapod system in which the original four rod construction of the IL was combined with four stabiliser manipulator arms. The design has the advantages of the intuitive analogue Ilizarov design combined with the features of the hexapod design. It also offers a greater range of motion of the two rings relative to one another.

4 REVIEW OF THE LITERATURE

4.1 Systematic reviews of studies comparing the different surgical treatments

Tables 5-7 present an overview of the systematic reviews or meta-analyses comparing different surgical treatments and randomised, controlled studies. The reviews are presented in order of publication date and are divided up according to the localisation of the tibial fracture.

Table 5. Proximal metaphyseal fractures.

Studies	Fracture type	Intervention	Study type	Authors' conclusions
Canadian Orthopaedic Trauma Society 2006	Schatzker V-VI	Plate/circular EF	MCR	Because percutaneous reduction and application of a circular fixator results in a shorter hospital stay, a marginally faster return of function, and similar clinical outcomes and because the number and severity of complications is much higher with open reduction and internal fixation, we believe that circular external fixation is an attractive option for these difficult-to-treat fractures.
Mahadeva et al. 2008	Schatzker VI	Plate/hybrid EF	REV	Hybrid external fixation has theoretical advantages in terms of the soft tissues but the benefit over internal fixation is modest at best and has not demonstrated improved outcome.

Table 6. Diaphyseal fractures.

Studies	Fracture type	Intervention	Study type	Authors' conclusions
Hooper et al. 1991	Closed and G I	Plaster cast/IM	RCT	Closed intramedullary nailing is the most efficient treatment for displaced fractures of the tibial shaft.
Littenberg et al. 1998	Closed fractures	Plaster cast/Plate/IM	MA	Data from the published literature are inadequate for decision-making with regard to the treatment of closed fractures of the tibia.
Colles et al. 2000	Closed fractures	Plaster cast/Plate/IM	REV	All forms of treatment for tibial shaft fractures are associated with complications.
Karladani et al. 2000	Closed and G I	Plaster cast/IM	REV	We recommend intramedullary nailing for these fractures.
Bråten et al. 2005	Closed and G I-II	IM/EF (Ex-Fi-Re)	RCT	Unprotected weight-bearing was achieved earlier after IM nailing. Anterior knee pain was frequent after nailing.
Giannoudis et al. 2006	Open fractures	Plate/IM/EF	REV	All forms of treatment for tibial shaft fractures are associated with complications.
Soleimampour et al. 2008	Closed and G I-III	Ender/unreamed IM	RCT	The choice between the two methods of unreamed nailing is mainly controversial, depending on the priorities of the patient and surgeon.
Bhandari et al. 2008 (SPRINT)	Closed and open fractures	Reamed and unreamed IM	MCR	The present study demonstrates a possible benefit for reamed IM in patients with closed fractures. We found no difference between approaches in patients with open fractures. Delaying reoperation for nonunion for at least six months may substantially decrease the need for reoperation
Schemitsch et al. 2012	Closed and open fractures G1-III	IM	MCR	We identified several baseline fracture and surgical characteristics that may increase the risk of adverse events in patients with tibial shaft fractures. Surgeons should consider the predictors identified in our analysis to inform patients treated for tibial shaft fractures.
Li et al. 2014	Closed and open fractures G1-III	Plate/IM/EF	RCT	Minimally invasive plate osteosynthesis, locking IM stabilization and external fixation combined with limited open reduction and absorbable internal fixation techniques are all efficient methods for treating distal tibia fractures. With its wide indications, external fixation combined with limited open reduction and absorbable internal fixation leads to minimal soft tissue complication, good functional result and no local soft tissue irritation or implant removal.

Table 7. Distal metaphyseal fractures.

Studies	Fracture type	Intervention	Study type	Authors' conclusions
Im et al. 2005	Extra-articular	Plate/IM	RCT	IM are recommended for fractures associated with soft-tissue damage of Tscherne C2 or higher. In other cases, the authors think that either treatment modality can yield expected results.
Bedi et al. 2006	Extra-articular	Plate/EF/ IM	REV	Indications for IM have expanded to include distal metaphyseal tibia fractures. IM allows atraumatic closed stabilization while preserving vascularity of the fracture site and integrity of the soft-tissue envelope. Intra-medullary canal anatomy at this level prevents intimate contact between the nail and endosteum, however, and concerns have been raised regarding the biomechanical stability of fixation and risk of malunion. Plate fixation is effective stabilizing distal tibia fractures. Conventional techniques involve extensive dissection and periosteal stripping, which increase the risk of soft-tissue complications. Percutaneous plating techniques use indirect reduction methods and allow stabilization of distal tibia fractures while preserving vascularity of the soft-tissue envelope. External fixation is effective in the setting of contaminated wounds or extensive soft-tissue injury. Careful pre-operative planning with consideration for fracture pattern and soft-tissue condition helps guide implant selection and minimize post-operative complications.
Zelle et al. 2006	Extra-articular	Conservative/ Plate/IM/	REV	Open reduction and internal plate fixation results in extensive soft tissue dissection and may be associated with wound complications and infections. The optimal treatment of unstable distal tibia without articular involvement remains controversial.
Tarkin et al. 2007	Intra-articular	Plate/EF	REV	Emerging techniques such as staged operation, biological plating and vacuum-assisted closure methods may improve outcomes by limiting the infectious complications which have plagued operative management of type C pilon fractures. Nevertheless, despite the best care of these injuries, patient disability can be significant and it is important to counsel the patient about the severity of their injury and risks associated with surgery.

Papadokostakis et al. 2008	Intra-articular (70%)	EF	REV	There were no statistically significant differences between spanning and sparing fixation systems regarding the rates of infection, nonunion, and the time to union. Patients treated with spanning frames had significantly greater incidence of malunion compared with patients treated with sparing frames. Both IM and minimally invasive plating are appropriate management options for these fractures, but further studies are required.
Newman et al. 2011	Extra-articular	Conservative/ Plate/IM/EF	REV	High primary union rates were noted after surgical treatment of distal tibia shaft fractures with both nonlocked plates and reamed intramedullary nails.
Vallier et al. 2011	Extra-articular	Plate/IM	RCT	Rates of infection, nonunion, and secondary procedures were similar. Open fractures had higher rates of infection, nonunion, and malunion. IM was associated with more malalignment versus plating.
Richards et al. 2012	Intra-articular	Plate/EF	RCT	External fixation and ORIF can attain bony union with adequate articular reduction and similar infection rates. Patients treated with ORIF appeared to have improved union rates and early outcomes with ankle function and Short Form-36 Physical Function scores.
Li et al. 2013	Extra-articular	Plate/IM	REV	The results of this systematic review suggested that plate fixation, especially minimally invasive percutaneous plating osteosynthesis technique would be preferred for extra-articular distal tibia fractures because of its low complication rate. Nevertheless, IM should be taken priority for distal tibia fractures with serious soft tissue injuries.
Iqbal et al. 2013	Extra-articular	Plate/IM	REV	Both techniques can provide adequate treatments in appropriately selected patients. None of the studies had sufficient power to show clinically significant difference.
Xue et al. 2013	Extra-articular	Plate/IM	REV	With a satisfying alignment obtained, IMN may be preferential to plating for fixation of DTF with better function and lower risk of infection. However, IMN showed higher malunion rate for fixation of DTF. With the biases in our meta-analysis, it will ultimately require a rigorous and adequately powered randomised controlled trial (RCT) to prove.

4.2 Preference of treatment has changed over time

The treatment of tibial fractures has changed over time for different reasons, which are not always easy to understand.

Meling et al. studied a population in Norway during a period of four years. In this study, the most common primary treatments of metaphyseal fractures in the lower limb were plate and screws 72%, IM 8% and external fixation 5%. In primary treatment of diaphyseal fractures of the lower limb, the incidence was 60%, 22% and 4% for IM, plate and screws and external fixation respectively [210].

At a combined meeting (the Orthopaedic Trauma Association and the Osteosynthesis International-Gerhard Kuntscher Kreis), Khalily et al. asked the participating orthopaedic surgeons which method of treatment they preferred in a closed, non-displaced midshaft tibial fracture. Although most respondents favoured IM, a large proportion preferred cast treatment. The authors therefore concluded that there was no consensus with regard to the optimal treatment for closed midshaft tibial fractures, not even among trauma experts [211].

In an international survey, 577 surgeons (who were either members of the Orthopaedic Trauma Association, European clinics affiliated with AO International, Davos, Switzerland, or who were international members of the AAOS from Africa, Asia, or South America) were asked about their preferred treatment. Of the 444 (77%) who responded, the majority preferred IM as the treatment for low-energy fractures (95.5%) and also for high-energy fractures (96%) and fractures with associated compartment syndrome (80.4%) [212].

In Sweden, between 1998 and 2004, the surgical treatment of tibial shaft fractures (88% closed and 12% open) was dominated by IM (48%), followed by closed reduction and plaster cast (27%), external fixation (12%), plate and screws (8%) and other methods (5%) [6].

Today, plate osteosynthesis (ORIF) is the “gold standard” treatment in displaced proximal metaphyseal fractures (Schatzker type I-IV). However, there is no obvious evidence to support this paradigm. Circular external fixation is regarded as a valid alternative in displaced proximal metaphyseal fractures (Schatzker type V-VI). IM is the “gold standard” treatment in displaced diaphyseal fractures, even though there are clinically relevant

complications. Plate osteosynthesis (ORIF) and IM are regarded as the definitive treatment in displaced distal metaphyseal fractures. Taken together, external fixation is far from being the primary and definitive treatment in displaced tibial fractures.

4.3 Why do we need this thesis?

Even though displaced tibial fractures are routinely treated in most orthopaedic departments worldwide, the method of treatment, timing of the procedure and post-operative rehabilitation are still controversial. Despite modern techniques, there are still frequent and significant complications, such as infections, osteomyelitis and non-unions, which call for the improvement and diversification of the treatment. In many countries, the IL has been reserved for complex fractures with severe soft-tissue injuries. Expanding the indications in order to include less complicated fractures would increase the skills of the orthopaedic surgeons and would make it easier to handle more complicated fractures with IL or other ring fixators. This requires, however, that the use of the IL in simple fractures leads to results that are at least similar to those of “traditional” methods. Most of the reports on treatment with external fixators are based on different types of fixator (uniplanar, hybrids). However, all these fixators have different biomechanical characteristics and outcomes.

The measurement of clinical outcomes in this type of research is problematic, as there is no “gold standard” [213]. So far, the available functional outcome data are inconclusive and can therefore not be used to recommend any treatment over any other. The implementation of the IL as an alternative treatment calls for a critical evaluation, preferably using prospective randomised studies, single-centre cohort studies and registries. In the evaluation of the results of a specific treatment for tibial fractures, traditional clinical outcomes should be combined with patients’ self-assessment scores that actually indicate how good patient function is.

This thesis is needed in order to find a relevant place for the Ilizarov external fixation technique in the treatment options available for tibial fractures.

5 AIMS

The overall aim of this thesis was to analyse the results of the IL in the treatment of tibial fractures in order to obtain a better understanding of the opportunities of the method. The thesis is based on three papers dealing with the treatment of tibial fractures with different localisations and a fourth paper on gait patterns during the rehabilitation of these fractures. When designing and presenting the results of these studies, the aim was to define the indications and a place for this technique.

The specific aims were:

- to compare the outcomes of the IL and IM in terms of complications, function and patients' self-appraisal in a prospective randomised study of diaphyseal tibial fractures (Study I),
- to analyse the clinical results of the IL applied to proximal metaphyseal tibial fractures in a prospective study (Study II),
- to analyse the clinical results of the IL applied to distal metaphyseal tibial fractures in a prospective study (Study III),
- to analyse differences in gait pattern using a pressure insole system during the early healing phase of tibial fractures in the proximal and distal metaphysis, treated with the IL and in the diaphysis, treated with the IL or IM (Study IV).

6 PATIENTS

6.1 Inclusion/exclusion criteria

In all the studies, consecutive patients between 18 and 75 years of age with acute open or closed isolated dislocated tibial fractures were included.

The exclusion criteria were: orthopaedic disorders with impaired walking ability, dependent living status, severe cognitive dysfunction, or inability to understand or follow instructions in Swedish.

The algorithms of all the studies are shown in Figure 5.

In Study I, 58 individuals with a diaphyseal tibial fracture were randomly allocated to the IL or IM (Figure 6).

In Study II, 30 consecutive patients with a proximal tibial metaphyseal fractures were prospectively enrolled and treated with IL application if the tibial plateau had a displacement of more than 5 mm and/or instability when the knee was stressed in varus or valgus (Figure 7).

In Study III, 39 consecutive patients with a tibial distal metaphyseal fracture were prospectively enrolled and treated with IL application if there was an incongruence of the articular surface of more than 2 mm and/or if the angulation of the tibia or fibula exceeded 10° in any plane (Figure 8).

In Study IV, gait pattern and load were studied during the first three months post-operatively in 85 individuals recruited from Studies I-III. In order to evaluate the rehabilitation, only patients who had performed tests on at least two different occasions were included. Patients who had other confounding factors affecting gait, such as deep infections, pin-site infections with pain, compartment syndromes or foot fixation bridging the ankle joint, were also excluded (Figure 9).

In the patients from Study I, there were 28 patients in the IL group and 20 patients in the IM group who were able to participate in the early postoperative gait analysis and who had been instructed by the surgeons to perform unrestricted weight-bearing. Despite the fact that some of them were subsequently excluded from Study IV, because of the exclusion criteria in that study, they were compared separately regarding load in this thesis.

6.2 Flow charts

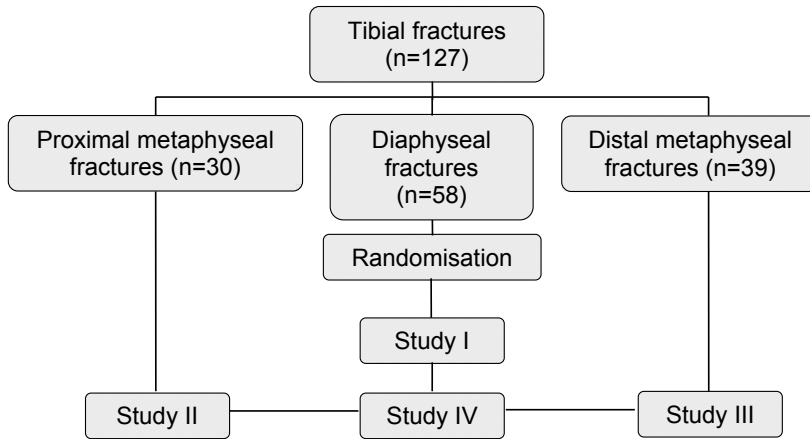


Figure 5. The algorithm of all studies.

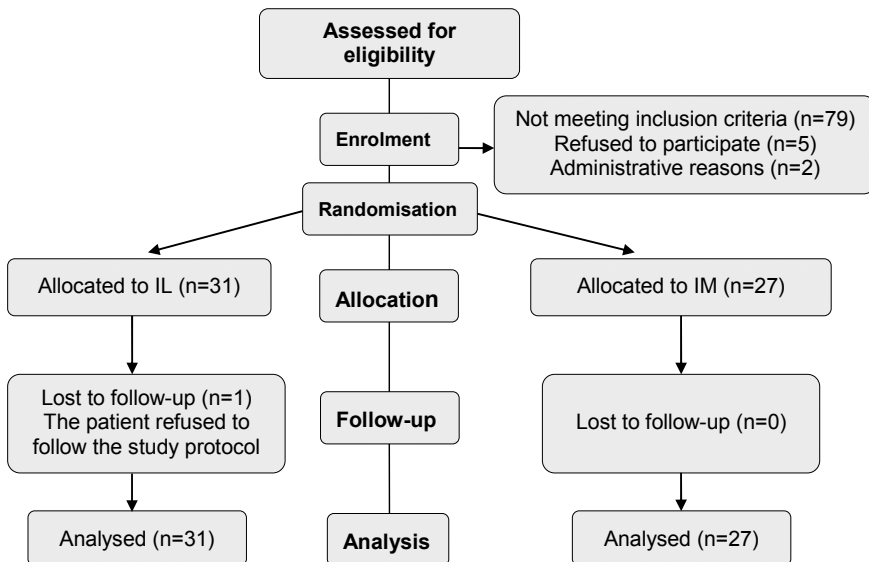


Figure 6. Study I flow chart.

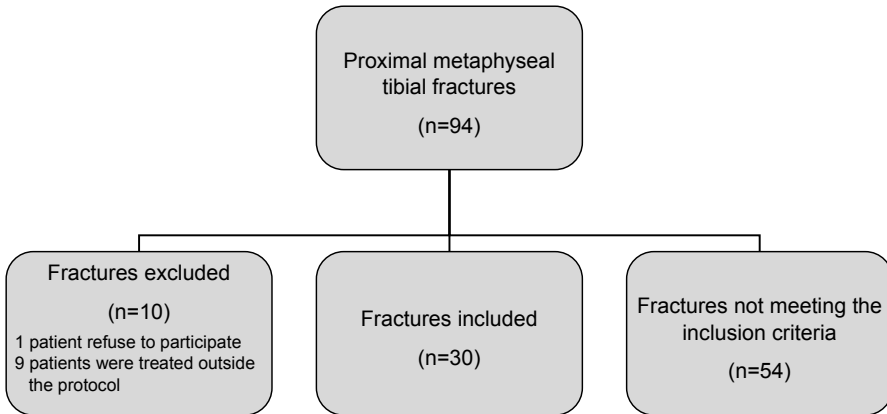


Figure 7. Study II flow chart.

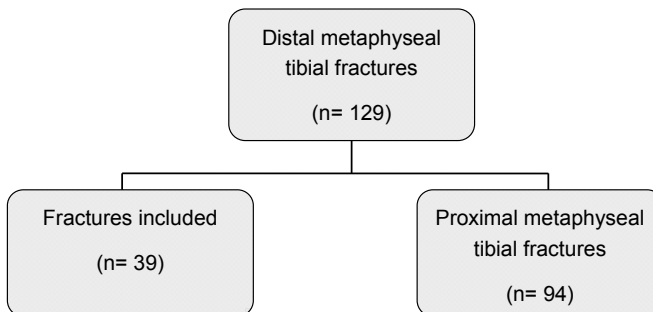


Figure 8 Study III flow chart.

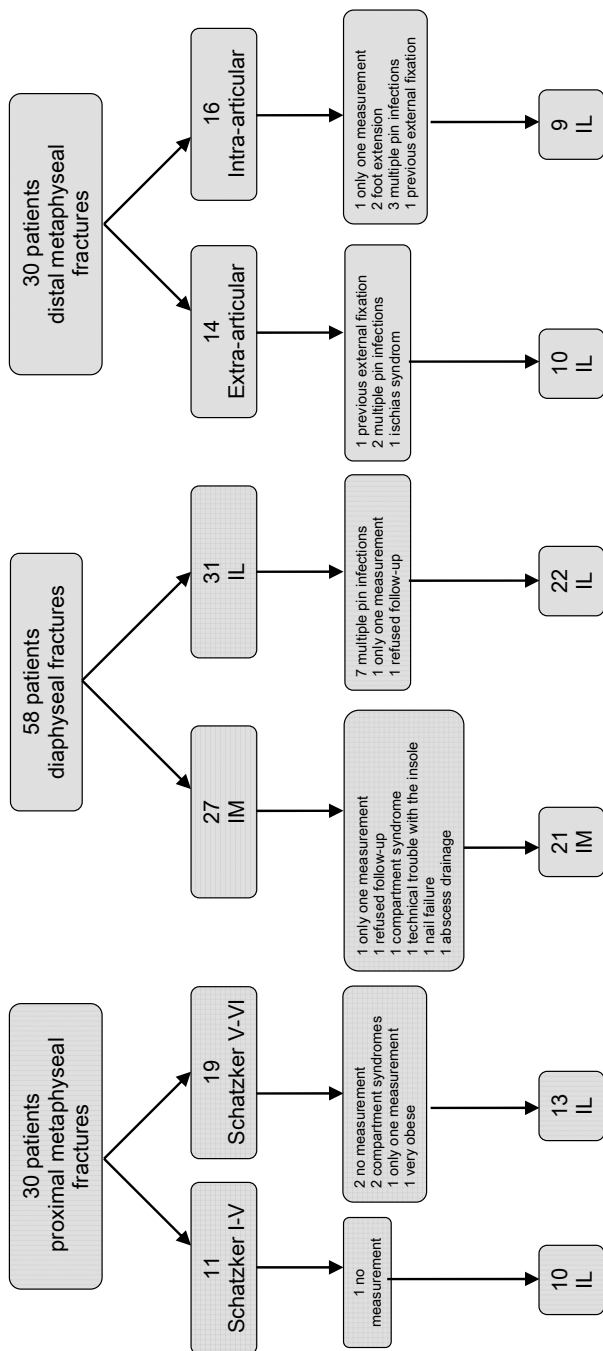


Figure 9. Study IV flow chart.

6.3 Demography and etiology

The demography of the patients included in this thesis and the etiology of their fractures are shown in Tables 8, 9, 10 and 11.

Table 8. Demographics for the patients included in the studies.

Demographics	Study I	Study II	Study III	Study IV
Patients included	n=58	n=30	n=39	n=85
Male/female	40/18	18/12	12/27	52/33
Age in years				
Median	41.5	51	50	46.5
Range	18-71	18-74	20-70	18-74
Smokers	8	4	9	

Table 9. Age stratification in Study I.

Age stratification in years	IL group n=31	IM group n=27
18-30	9	11
31-50	11	9
51-75	11	7

Table 10. The fracture types included in Studies I-III.

Fracture type	Study I n=58	Study II n=30	Study III n=39
Low-energy	42	16	29
High-energy	16	14	10
Closed	47	30	30
Gustilo I	6	0	6
Gustilo II	5	0	3
Gustilo III	0	0	0

Table 11. The etiology of the fractures included in the studies.

Accident type	Study I n=58	Study II n=30	Study III n=39
Motor-vehicle	11	10	5
Fall	24	13	25
Horse riding		4	1
Work	6	2	3
Sports	17		3
Assault		1	

6.4 Ethics

Study I was approved by the regional ethical review board at Sahlgrenska University Hospital in Gothenburg (ID: Ö 047-03).

Study II was approved by the regional ethical review board at Sahlgrenska University Hospital in Gothenburg (ID: 400-04).

Study III was approved by the regional ethical review board at Sahlgrenska University Hospital in Gothenburg (ID: 400-04).

Study IV was approved by the regional ethical review board at Sahlgrenska University Hospital in Gothenburg, Sweden (ID Ö 047-03 and 400-04).

Written and oral information was given according to the requirements of the Helsinki Declaration.

In all the studies, the patients gave their written consent to participate.

7 METHODS

7.1 Examiners

The clinical examinations were performed by the surgeons as part of the normal post-operative follow-ups, but the one-year follow-up was performed by two independent physiotherapists who had not been involved in the rehabilitation of the included patients. Two technicians supervised the gait analysis, but the data were analysed independently and primarily blinded by a technician without knowledge of treatment groups.

7.2 Fracture classifications

There are numerous classifications of fractures. We have chosen the most generally used systems. For the classification, the primary and immediate post-operative roentgen examinations were used. In the majority of the proximal metaphyseal fractures, this was complemented by CT.

All fractures were classified according to the AO/OTA system. In standard radiology, there are no precise landmarks that separate the metaphysis and the diaphysis. The proximal and distal metaphyseal areas were defined in the tibia by a square whose sides are the same length as the widest part of the epiphysis in question. The diaphyseal segment was defined according to Müller et al. as the part between the proximal and distal metaphysis [214].

For the proximal metaphyseal fractures (Study II), the Schatzker classification was also applied [215]. In the intra-articular distal metaphyseal fractures (pilon fractures), the extension of articular engagement was defined as suggested by Rüedi and Allgöwer [216]. Open fractures were classified according to the Gustilo classification [217, 218]. To describe the soft-tissue damage in closed fractures, we used the Tscherne classification [219].

7.3 Surgical technique

7.3.1 The Ilizarov fixator (IL)

The IL procedure in the proximal and diaphyseal fractures was carried out with the leg in a straight position, which provided a partial reduction in the axial direction. Biplane fluoroscopy was used during the reduction, pin insertion and assembly of the frame. The surgery was performed without a tourniquet. The

device (Smith & Nephew, Memphis, Tennessee, USA) was not assembled pre-operatively.

In the proximal metaphyseal fractures the depressed articular fracture fragments were first reduced under fluoroscopic supervision without arthrotomy. The joint surface was reconstructed if necessary, using closed pressure with percutaneously inserted elevators, reduction forceps and/or wires with olives. Subchondral defects were then packed with calcium sulphate bone pellets (Osteoset[®] or β -tri calcium phosphate ChronOs[®]). Depending on the type and size of the fragments, two to three olive wires were inserted parallel to the articular surface, with posts fixed on the proximal ring to achieve additional stability (drop-wire technique). The proximal ring was placed at the level of the fibular head. Depending on the complexity of the fracture, one to three additional rings were fixed with two to three wires in the tibia and they were connected with steel threaded rods. To eliminate the residual displacement of the bone fragments, some additional stabilising olive wires were inserted at different levels. All the wires were assembled and tensioned to at least 110 kg, as it is marked on the tensioner. In Schatzker type I-IV fractures, it was sufficient to apply the two proximal rings. In Schatzker type V-VI fractures, two rings in the distal femur were added to the construction with hinged rods bridging the knee.

In the diaphyseal fractures, the operation was performed with the patient in the supine position, using calcaneal traction. Four or five steel rings were used. The proximal ring was placed at the level of the fibular head and the most distal ring at the level of distal metaphysis with wires. Three crossing wires were fixed to each ring. To eliminate the residual displacement of the bone fragments, stabilising olive wires were inserted at different levels. If necessary, additional techniques such as drop-wires and/or the relocation of bone fragments using olive wires were used, together with arched bending of wires. All the wires were tensioned to at least 110 kg. Reduction was confirmed with the help of fluoroscopy and compression was performed as the final step.

The distal metaphyseal fractures were reduced with traction and manual external pressure. If this did not lead to acceptable anatomical reduction, the joint surfaces were reconstructed with percutaneously inserted elevators and/or a reduction forceps and/or wires with olives. If a distal fibula fracture was present, a wire was introduced from the tip of the distal fibula intra-medullary passing the fracture site. The proximal ring was placed at the level of the fibular head. The syndesmosis and malleolar fragments were stabilised with olive wires fixed to the ring on the lateral side or the medial side. All the wires were assembled and tensioned to a minimum of 110 kg. To achieve further stability

of the system and to allow for unrestricted weight-bearing, additional rings were used in the tibia. Steel-threaded rods were connected to the rings. If the fracture was very oblique, comminute or if the patient was heavy, a temporary foot frame was added to increase stability. This construction was made with one or two olive wires transfixing the metatarsum and two oblique wires through the calcaneus.

More details on the surgical technique are presented in the Appendix.

The skin was cleaned with hydrogen peroxide and Permafoam[®] dressings were applied.

All the operations were performed by or under the supervision of experienced trauma consultants, the patients received the same post-operative analgesia and compartment pressure monitoring was not performed.

7.3.2 The intramedullary nail (IM)

IM fixation (Study I) was performed with the patients in the supine position, using calcaneal traction. All the patients undergoing IM were operated on with 90° of knee flexion. Biplane fluoroscopy visualisation was used in all patients. The fractures were reduced partially with axial traction. The IMs (CTN Syntes[®]) were inserted using a longitudinal skin incision over the patellar tendon. The incision was extended proximally from the level of the tibial tubercle to the mid-portion of the patella. The patellar tendon was retracted laterally, to obtain access to the insertion site. The infra-patellar fat pad was retracted to expose the anterior surface of the proximal tibia. The IM was introduced after reaming the medullary canal according to the AO standard recommendations to 0.5-1 mm above the diameter of the nail. Proximal and distal 3.9 mm locking screws were used. The distal locking screws were placed using the free-hand technique. The tendon and subcutaneous tissues were adapted with Vicryl[®] sutures. The skin was sutured with Ethilon[®] and then cleaned with chlorhexidin. Dry dressings were then applied.

All the operations were performed by or under the supervision of experienced trauma consultants, the patients received the same post-operative analgesia and compartment pressure monitoring was not performed.

7.4 Prophylaxis

All the patients were given low-molecular-weight heparin (Fragmin[®], Pfizer, USA) pre-operatively and for approximately 10 days post-operatively as

prophylaxis against deep vein thrombosis. To diminish the risk of infection, they also received cloxacillin (2 grams i.v. Ekvacilin[®], Meda, Sweden) pre-operatively, which was repeated twice during the first 24 hours.

7.5 Operation time

The duration of surgery in minutes was measured from the insertion of the first wire to the last nut adjustment, including the pin-site dressing in the IL group. In the IM group, it was measured from the beginning of the wound incision to the last suture.

7.6 Hospital stay

The hospital stay is an indirect indicator of patient recovery and compliance. It can be used to measure the post-operative wellness related to early complications in orthopaedic surgery [220] and quality of care for the individual patient [221]. The hospital stay was calculated as the number of days after the operation until discharge from the ward.

7.7 Rehabilitation

Immediate full weight-bearing was encouraged in all the IL patients, independent of fracture type. In the diaphyseal fractures treated with IM, some patients were recommended restricted weight-bearing by the surgeon if the fixation was not considered stable enough.

Post-operatively, a common individually-based training programme was used. All the patients were informed about the mobilisation techniques by a physiotherapist and crutches were allowed at their convenience.

7.8 Post-operative evaluation

All the patients were followed up clinically after two, four, eight and 12 weeks and finally at one-year. Radiographs were taken at the same intervals. Additional clinical and radiographic assessments were made when necessary to evaluate fracture healing. Pain and patient satisfaction were registered using a visual analogue scale (VAS) at four and 12 weeks and at the one-year follow-up. The Swedish versions of the Nottingham Health Profile (NHP) [222, 223] and the EuroQol (EQ-5D) [224] were used for patient self-appraisal at the same time intervals. The KOOS [225] and FAOS [226] questionnaires were added to the follow-up between one and five years post-operatively in patients in

whom the observation period exceeded one year. Pain and satisfaction (VAS), NHP and EQ-5D questionnaires were then repeated at the same time.

The evaluation schedule used in the studies is summarised in Table 12.

Table 12. Time of evaluation of the studies.

Time of evaluation	Study I	Study II	Study III
Post-operative	Radiographs Gait analysis (Study IV)	Radiographs Gait analysis (Study IV)	Radiographs Gait analysis (Study IV)
1 month	ROM Radiographs VAS Pain VAS Satisfaction NHP EQ-5D Gait analysis (Study IV)	ROM Radiographs VAS Pain VAS Satisfaction NHP EQ-5D Gait analysis (Study IV)	ROM Radiographs VAS Pain VAS Satisfaction NHP EQ-5D Gait analysis (Study IV)
2 months	ROM Radiographs VAS Pain VAS Satisfaction NHP EQ-5D Gait analysis (Study IV)	ROM Radiographs VAS Pain VAS Satisfaction NHP EQ-5D Gait analysis (Study IV)	ROM Radiographs VAS Pain VAS Satisfaction NHP EQ-5D Gait analysis (Study IV)
3 months	ROM Radiographs VAS Pain VAS Satisfaction NHP EQ-5D Gait analysis (Study IV)	ROM Radiographs VAS Pain VAS Satisfaction NHP EQ-5D Gait analysis (Study IV)	ROM Radiographs VAS Pain VAS Satisfaction NHP EQ-5D Gait analysis (Study IV)
12 months	ROM Radiographs VAS Pain VAS Satisfaction NHP EQ-5D	ROM Radiographs VAS Pain VAS Satisfaction NHP EQ-5D KOOS	ROM Radiographs VAS Pain VAS Satisfaction NHP EQ-5D FAOS

7.8.1 Radiographic assessment

Standard radiographic examinations with anteroposterior and lateral views were used for the classification of the fractures. Computed tomography scanning was used to define the type of fracture in proximal metaphyseal fractures.

The post-operative radiographs were evaluated by one of the authors (TR) and separately by an independent surgeon/radiologist.

In the proximal metaphyseal fractures, we used Rasmussen's criteria to define residual displacement [227].

The definition of displacement in the diaphyseal fractures was based on the following fracture pattern: $> 5^\circ$ coronal angulation, $> 10^\circ$ sagittal angulation, > 1 cm shortening or translation over 50% of the tibial diaphysis.

In the distal metaphyseal fractures, the criteria formulated by Burwell and Charnley were used to define residual displacement [228].

7.8.2 Assessment of fracture union

The clinical criteria used for the assessment of union included the absence of pain in response to manual stress of the fracture and/or ability for full weight-bearing of the involved limb without pain or support. In the IL patients, the healing could also be assessed by registering pain and stability after the provisional removal of the connecting rods at the fracture level.

The fractures were regarded as radiologically healed when antero-posterior and lateral radiograms showed a bridging callus in three of four cortices.

Delayed union was diagnosed if consolidation was observed after 36 weeks post-operatively. Pseudarthrosis was diagnosed if further surgical procedure was necessary to promote healing.

7.8.3 Pin infection assessment

Pin-site infection was defined as discharge from the pin site with pain and/or tenderness in the soft tissues in accordance with the Checketts-Otterburn classification [229] (Table 13).

Table 13. The Checketts-Otterburn classification.

Grade	Characteristics	Treatment
Minor infection		
1	Slight redness and little discharge	Improved pin-site care
2	Redness of the skin, discharge, pain and tenderness in the soft tissue	Improved pin-site care and oral antibiotics
3	Grade 2 but not improved with oral antibiotics	Affected pin or pins placed at new site and external fixation can be continued
Major infection		
4	Severe soft-tissue infection involving several pins, sometimes with associated loosening of the pin	External fixation has to be abandoned
5	Grade 4 but also involvement of the bone visible on radiographs	External fixation has to be abandoned
6	The infection occurs after fixator removal. Pin tract heals initially but will subsequently break down and discharge intervals. Radiographs show new bone formation and sometimes sequestra	Curettage of the pin tract

7.8.4 Range of motion (ROM)

Range of motion (ROM) measurements of the knee and ankle joints were performed in the supine position using a hand-held goniometer graded in one-degree increments. The uninjured leg was always measured first.

7.8.5 Patient self-reported outcome and functional scores

The patients' self-reported outcomes and functional scores were all performed prior to the functional testing at one, three and 12 months post-operatively. The questionnaire was administered in the waiting room. The last week was taken into consideration when answering the questionnaire.

7.8.5.1 Visual Analogue Scale (VAS)

Global quality of life was measured using a type of single-item visual analogue scale (VAS). There is a 10 cm line with "no pain" at one end and "worst imaginable pain" at the other end or, alternatively, in a different form "very satisfied with treatment" and "very dissatisfied". The patient was asked to rate the current level of his/her experience related to pain and satisfaction. The end-

point descriptors were not changed. The visual analogue scale that was used was not numbered and there were no verbal ratings along the line.

7.8.5.2 Nottingham Health Profile (NHP)

The Nottingham Health Profile (NHP) consists of two independent sections. Section I comprises 38 yes/no items in six dimensions: pain, physical mobility, emotional reactions, energy, social isolation and sleep. This section is scored using weighted values which give a range of possible scores from zero (no problems at all) to 100 (presence of all problems within each dimension). Section II contains seven general yes/no questions on daily living problems. The results from Section II were not used in the final analysis.

7.8.5.3 Euroqol (EQ-5D)

General health-related quality of life (HRQoL) was measured by the Euroqol (EQ-5D). This questionnaire consists of four components, the health part (EQ-5D), visual analogue scale (EQ-VAS), the valuation part and background data. The first part of EQ-5D, used in the studies (I-III) is a standardized, non-disease-specific instrument that measures the quality of life in five dimensions: mobility, self-care, usual activities, pain/discomfort and anxiety/depression. Each dimension is divided into three degrees of severity: no problems, some problems and major problems. The EQ-5D measures quality of life with a value between -0.594 and 1, based on a weighting of the answers to the five questions. A value of 1 indicates the best possible health status.

7.8.5.4 Knee injury and Osteoarthritis Outcome Score (KOOS)

This is a knee-specific instrument, a self-explanatory questionnaire which is used as a validated instrument for short- and long-term follow-ups to assess the patients' opinion of their knee function and associated problems. The KOOS is intended to be used for knee injuries which can result in post-traumatic osteoarthritis, i.e. anterior cruciate ligament injury, meniscus injury, chondral injury and so on, has been used in patients between 13 and 79 years of age [225, 230, 231]. The KOOS questionnaire consists of five subscales; pain (P), other symptoms (S), function in daily living (ADL), function in sport and recreation (Sport/Rec) and knee-related quality of life (QoL). Patients answer nine questions to evaluate P, seven questions to evaluate S, 17 questions on ADL, five questions on Sport/Rec and four questions on QoL. All the questions are graded from zero to four points. A normalised score between 0 and 100 (with 0 indicating no symptoms and 100 extreme symptoms) is calculated for each subscale. This functional score has been validated in Swedish [232].

7.8.5.5 Foot and Ankle injury and Osteoarthritis Outcome Score (FAOS)

This is a foot- and ankle-specific instrument, a self-explanatory questionnaire which is used as a validated instrument for short- and long-term follow-ups to assess the patients' opinion of their foot and ankle function and associated problems. The FAOS content is based on the Knee injury and Osteoarthritis Outcome Score (KOOS) and was originally intended for use in patients with a variety of foot- and ankle-related problems. It has been used in patients between 20 and 60 years of age [225, 226].

The FAOS questionnaire consists of five subscales; pain (P), other symptoms (S), function in daily living (ADL), function in sport and recreation (Sport/Rec) and knee-related quality of life (QoL). Patients answer nine questions to evaluate P, seven questions to evaluate S, 17 questions on ADL, five questions on Sport/Rec and four questions on QoL. All the questions are graded from zero to four points. A normalised score between 0 and 100 (with 0 indicating no symptoms and 100 extreme symptoms) is calculated for each subscale. This functional score is validated in Swedish [226].

For more details on KOOS and FAOS, please go to web address: <http://www.koos.nu>

7.8.5.6 Anterior knee pain and pain at the fracture site

The patients were classified as having anterior knee pain or fracture site pain if the pain was present during stair climbing, sitting or any other daily activity at the one-year follow-up.

7.8.6 Major complications

Major complications were defined as those requiring unplanned surgery due to compartment syndrome and deep infection.

7.8.6.1 Compartment syndrome

Compartment pressure monitoring was not used. Clinical symptoms and signs were used for diagnosis and the decision to perform a fasciotomy.

7.8.6.2 Deep infection

Deep infection was defined as purulent drainage presenting after definitive wound healing or osteomyelitis and was diagnosed by the treating surgeon based on clinical examination and subsequent cultures. The diagnosis of osteomyelitis was based on radiological examination.

7.9 Re-operations

Re-operation was defined as any surgical intervention in the operating room where regional or general anaesthesia was needed after the primary procedure in order to treat compartment syndromes, to achieve fracture union, to eradicate infection, to achieve soft-tissue coverage, to stabilise the hardware after breakage of the primary implant or to remove all or parts of the IL or IM. The re-operations were subdivided into major and minor revisions. Major revisions included fasciotomy, the removal or exchange of the IM, bone grafting and soft-tissue coverage. Revisions were classified as minor for the replacement or removal of all or parts of the IL or the removal of the locking screw from the IM (dynamisation).

7.10 Gait analysis with pressure insoles

For data acquisition a telemetric insole system (medilogic® T&T medilogic Medizintechnik GmbH, Schoenefeld, Germany) was used. This system allows wireless registration of the pressure load beneath the patient's foot during standing and/or walking. One measurement sole is placed in each of the patient's shoes (Figure 10).

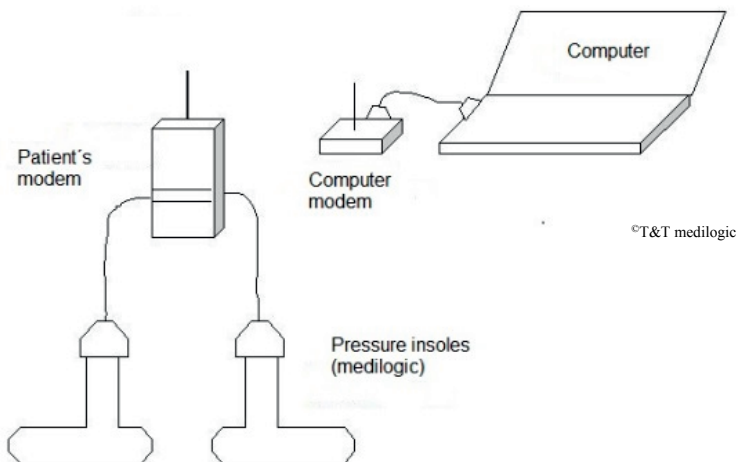


Figure 10. Schematic principles of the medilogic pressure insole system.

The pressure load is continuously measured and transmitted to a laptop computer, where it is registered and displaced on the screen (Figure 11).

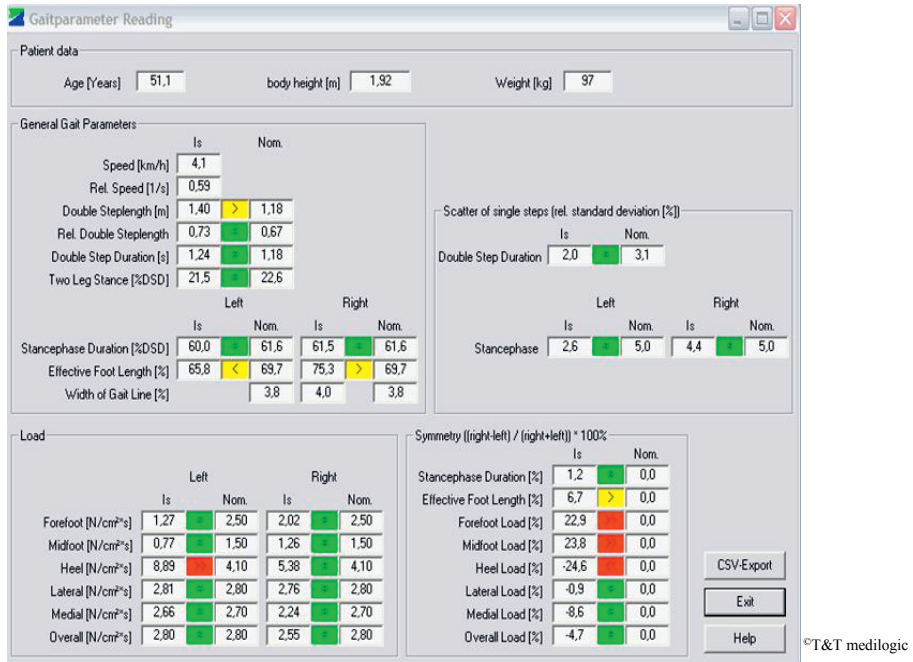

Figure 11. The “gait parameter” window of the medilogic insole pressure system in which a large number of the parameters are based on the load distribution under the patient’s foot. The upper part of window contains the basic patient data: age, height and weight. The lower part shows gait parameters calculated from the values recorded with the insoles. The coloured display shows the relative position of every parameter compared to a comparison group. The colour green indicates a close match with comparative values, yellow indicates a small deviation and red a strong deviation. For further details see the medilogic manual at the web site: http://www.medilogic.com/uploads/media/medilogic_Handbuch_01.pdf

The patients were asked to walk in the way they normally walked and felt comfortable with during their rehabilitation with or without crutches. The tests were performed before discharge from hospital, usually within a week post-operatively, and repeated one, two and three months after the time of surgery. Before measurements took place, all the patients were allowed to perform a test run in the same levelled area, which was a 40 m long and 3 m wide closed hospital corridor. Two tests were performed in a 12 m marked area in which 10 m of the gait cycles were registered. With regard to tests performed immediately post-operatively, not all patients managed to walk the whole distance and, in those cases, only 5 m were used for the registration of gait cycles. Two technicians supervised all the tests, without any clinical staff being

present. The same system was used throughout the tests. The manufacturer performed an annual calibration of the insole system to ensure its accuracy and precision. Consistency tests, of the system, using healthy individuals with known body weight, were performed before and after calibration of the system. The system criterion for detecting steps was attuned to the very asymmetrical walking style in the early phase of recovery and was kept at that level for all tests. As a default, a fall below 6% of the overall load was normally used to indicate that the foot is in the swing phase. This threshold was lowered to 1% in the present study.

At each time interval, we used the registration for further analysis with the “best quality” (meaning a regular gait pattern without stumbling, rest period or hesitation, i.e. data showing a low scatter in variation). This almost always turned out to be the second trial.

7.10.1 Gait parameters

Using the medilogic[®] insole system, several gait parameters can be calculated, as well as parameters “relative to the body height of the patient” (parameter/body height); speed (km/h), relative speed (1/s) – RS, double step length (m), relative double step length – RDS, double step duration (s) – DSD, two-leg stance (% of DSD). The stance phase duration is calculated for each foot as a percentage of DSD. Effective foot length – EFL is the percentage of the insole loaded during the rolling-over motion. The overall load – L (Ns/cm²) in terms of load over the entire time of the step is calculated from the pressure-time areas (integrals) beneath the graphs of the average step.

Overall load (L), RS, RDS and EFL were studied. For comparisons between sides, a symmetry index was calculated by taking the load on the injured side as the percentage of the sum of the total load – (load injured side)/(load injured side + load uninjured) x 100. With this calculation, a value of 50% indicates that both legs are loaded equally and a value of 0% means that the injured leg is not loaded at all, which would be defined as maximum asymmetry. Speed and double step length are dependent on the height of the patient, which was taken into account when the gait parameters of “relative speed” and “relative double step length” were calculated. These values can and have also been calculated in the few patients in whom the load on the injured side was low and irregular, or below the threshold of the system. An “effective foot length” index was calculated from the average gait line and is given as a symmetry (injured side – uninjured side)/(injured side + uninjured side) x 100.

8 STATISTICAL METHODS

In Study I, the randomisation procedure was performed with numbered, opaque and sealed envelopes prepared by a biostatistician.

As age is a major prognostic factor in fracture healing, a skewed age distribution could affect the interpretation of the results. The patients were therefore stratified into three age groups prior to the randomisation: 18-30, 31-50 and 51-75 years. The age intervals were based on the historical age distribution at our department.

A sample size calculation was primarily based on the frequency of deep infections and compartment syndromes. The frequencies of these complications together were retrospectively approximately 20% at our department (unpublished data) in IM-treated fractures, which was higher than the data reported in the literature published before the start of our study. With 30 patients in each group, 80% power is achieved in order statistically to detect a difference if there are no such complications in the patients treated with the Ilizarov method. This power calculation was accepted by the ethical review board at the Sahlgrenska Academy, Gothenburg University.

The statistical analyses of the results in Study I were performed using chi-square or Fisher's exact test when comparing categorical variables between the groups. Descriptive statistics were calculated for the variables of ordinal and continuous data type. The Mann-Whitney test was used to compare differences between the two groups with respect to part 1 of the NHP, the total NHP score and VAS scores. To explore correlations between VAS Pain, NHP and EQ-5D, Spearman's correlation analysis was used.

In Study II, descriptive statistical values as median and 95% confidence intervals (CI) or range are given. Further statistical comparisons between the groups were not meaningful, as the number of patients is small and they would only reflect differences that could be anticipated.

In Study III, descriptive statistics as median and range were calculated. As the number of patients in the subgroups was small and as several of the variables were of ordinal data type, we decided to use non-parametric tests for statistical

analysis. For comparisons within the group, we used Wilcoxon's test, while the Mann-Whitney U-test was used between the groups.

In Study IV, descriptive statistics as median with quartiles were presented for data for different subgroups of patients. Some of the variables we wanted to explore had a skewed distribution diverging from normal distribution and we therefore decided to use non-parametric statistical tests. For comparisons of two independent samples, the Mann-Whitney U-test was used and correlations were calculated using Spearman's correlation test. Correlation coefficients were interpreted as poor ($r < 0.3$), moderate ($0.3 > r < 0.6$), good ($0.6 > r < 0.8$) and very good ($r > 0.8$).

The statistical significance level in all studies was set at $p < 0.05$. All the statistical tests were two-sided.

The statistical software used for all statistical analyses, was the SPSS package version 19 for Windows in Studies I-III and version 20 in Study IV.

9 RESULTS AND DISCUSSION

9.1 Treatment timing

9.1.1 Results

Table 14. Surgery and hospital stay are in days and operation time in minutes. For all the parameters, median and range have been calculated.

	Study I IL	Study I IM	Study II SI-IV	Study II SV-VI	Study III Extra- articular	Study III Intra- articular
Surgery delay in days (range)	2 (0-9)	2 (0-6)	3 (1-11)	2 (1-9)	2 (0-24)	1 (0-5)
Operation time in minutes (range)	137 (65-195)	153 (85-250)	130 (100-165)	223 (164-240)	152 (50-224)	165 (72-314)
Hospital stay in days (range)	5 (2-13)	6 (1-16)	4 (3-9)	9 (3-13)	5 (3-10)	5 (2-7)

Study I: The median delay between injury and surgery was two days in both treatment groups. The median operation time was 137 minutes (65-195) in the IL group compared with 153 minutes (85-250) in the IM group ($p=0.094$). There were no significant differences between the groups when it came to the hospital stay.

Study II: The median operation time was shorter for the Schatzker type I-IV fractures, with 130 minutes (100-165), than for the Schatzker type V-VI fractures, with 223 minutes (164-240). The Schatzker I-IV fracture group had a shorter hospital stay, four days (3-9), than the Schatzker V-VI fracture group, nine days (3-13).

Study III: The median delay between injury and surgery was two days. There were no differences in median operation time in terms of extra-articular fractures, with 152 minutes (50-224), compared with the intra-articular fractures, with 165 minutes (72-314).

9.1.2 Discussion

Operating time

Study I: There was no statistically significant difference in operation time between the IL group and the IM group. Pre-assembling the external frame could shorten the operation time with IL treatment. However, as this type of surgery is minimally invasive, this is less important. With regard to IM, however, as Malik et al. have pointed out, the length of the operation may affect the outcome [233].

Study II: The median operation time for the Schatzker type V-VI fracture group was close to three hours. If open plating had been used instead with the same surgery time, there would have been an increased risk of wound contamination [234]. In the present study, it was not necessary to use a staged protocol in any fracture, as has sometimes been recommended, especially for high-energy injuries [235-238]. Lee et al. operated on 36 tibial fractures, AO type B and C fractures, using the less invasive stabilisation system (LISS) with a mean operation time of 150 minutes [239]. Moreover, Jöckel et al. prospectively reported on a mixed series of 45 type B and 38 type C fractures operated on using locking plate fixation (MIPPO) and had a mean operation time of 116 minutes [60]. Proximal metaphyseal tibia fractures treated with hybrid external fixation (Tenxor[®], Stryker-Howmedica) had a shorter operating time, with 100 minutes (range 65-120) in AO type A fractures and 140 minutes (range 75-225) in type C fractures [240]. These results are comparable with Study II in terms of the Schatzker type I-IV fractures. With regard to the Schatzker type V-VI fractures, there were longer operation times related to the more complex assembly of the external frame. In spite of this, they are consistent with the results of a multicentre, randomised clinical trial where Schatzker type V-VI fractures were treated with a circular fixator or ORIF. The mean total operation time in that study was 170 minutes for the fixator group and 183 minutes for the group managed with internal fixation ($p=0.229$) [241].

Study III: It was possible to operate on almost all patients without delay, regardless of the status of soft tissues, the size of the distal fragment and the intra-articular fracture lines (if present). The operation time with the IL in this series was higher compared with those in the literature [242, 243]. However, since one important advantage of the IL technique is that it is an essentially closed method, a longer operating time does not increase wound contamination.

Pre-assembling the frame could reduce the time in the operating room for the patient, but it instead requires the same time to prepare the construction before the operation. As mentioned above, the IL is essentially a closed technique and, as result, a reduction in operating time of this kind would not affect the risk of contaminating the fracture site.

Hospital stay

The median duration of hospital stay was four to six days in all the studies, independent of fracture type, except for Schatzker type V-VI fractures. There is generally, no correlation between the length of hospital stay and patient satisfaction [244].

9.2 Time to union

9.2.1 Results

Study I: Two of 31 patients (6%) in the IL group and one of 27 (4%) in the IM group developed pseudarthrosis. They were all treated successfully using the Ilizarov technique. In the remaining patients, the median time to healing in the IL group calculated from the day of the injury to the removal of the frame was 15 weeks (12-24). The radiological healing period was 12 weeks (4-88) in the IL group and 12 weeks (6-110) in the IM group (n.s.). Radiological delayed healing was observed in four patients in the IL group (75 and 77 weeks and two patients at 88 weeks) and two patients in the IM group, who healed at 92 and 110 weeks. However, none of these patients required a surgical intervention to promote healing and they were therefore not classified as having a pseudarthrosis.

Study II: There were no differences between the fracture types in terms of the time to clinical fracture healing. The fixator could be removed without anaesthesia, in Schatzker type I-IV fractures after 11 weeks (6-16) and in type V-VI fractures at 12 weeks (10-15).

Study III: All the fractures were judged as being clinically and radiologically healed when the fixator was removed at a median of 16 weeks (range 11-30). However, in one patient with a C1 fracture, a progressive loss of reduction was observed after the fixator had been removed. This patient was diagnosed as having a deep Staph. aureus infection and was subsequently treated with a second IL. This fracture then healed after another 23 weeks of fixation combined with 12 weeks of antibiotic therapy (clindamycin).

9.2.2 Discussion

In many cases, deciding when a fracture can be regarded as “healed” is difficult [213, 245, 246]. The distinction between delayed union and non-union is also arbitrary [247]. The radiological loss of a visible fracture line, and callus size, has been shown to correlate poorly with tibial shaft fracture stability [248]. Nor is the radiological appearance of fracture healing and fracture stiffness well correlated [249, 250].

Conventional radiographs can not be used alone to define union in internally fixed fractures with sufficient accuracy to enable their use as end-points of fracture healing. In a systematic review of long-bone fracture healing assessments, Corrales et al. reported a lack of consensus with regard to the definition of fracture healing. In this report, the majority of studies (62%) used a combination of clinical and radiographic criteria [251]. The surgeons’ ability to judge fracture union using sequential radiographs following internal fixation is estimated to be correct in approximately 70% of cases [252].

Even if, there are alternatives to conventional radiographs in assessing fracture union (absorptiometry, photodensitometry, scintigraphy, ultrasonography, CT), these methods have still not been proven valid, reliable, economical or practical enough to use as standard techniques when evaluating fracture healing [245, 253]. It is not yet possible to use biological markers accurately to predict normal consolidation in long bones [254, 255].

In the present studies, we combined the radiographic results with a clinical evaluation in the assessment of fracture healing. This is similar to the most frequently used criteria in the literature [251].

Smoking habits constitute a considerable risk factor when it comes to fracture healing and the time to union or non-union and secondary surgery in diaphyseal tibial fractures is consistently more frequent in smokers [256-261]. In this thesis, only 21 of 127 patients were smokers (16.5%) and smoking could not therefore be analysed as a possible confounding factor regarding time to healing or other complications.

Study I: There was a difference between the radiological healing time and the time when the fracture was considered to be clinically healed in the IL group. A corresponding difference was not possible to observe in the IM group, mainly due to the fact that the nail was left *in-situ*, which affected any clinical evaluation. Accordingly, it is not feasible to apply identical clinical healing criteria to the two treatment groups in the present study. This is reflected by the difference in the IL group between the time of clinical and radiographic

fracture healing. In the IL group, the fracture was considered to be radiographically healed before it was considered safe to remove the fixator.

In tibial shaft fractures, the radiological callus formation is difficult to judge at an early stage because of the inaccuracy of the radiological definition of non-union and malunion among orthopaedic surgeons and radiologists [248, 251, 252, 262]. Blinding to the radiological outcome would be ideal, but, for obvious reasons, this is not possible in this type of study with two distinctly different surgical procedures [263]. Moreover, the inter-observer agreement is low with regard to the radiographic assessment of fracture healing following the IM treatment of tibial shaft fractures [264].

Using the above-mentioned fracture healing criteria in Study I, there were no re-fractures or increased deformities after removal of the IL frame. Despite the fact that all the IL-treated patients were allowed to start loading directly post-operatively, this did not affect the radiological healing time, which was almost identical in both treatment groups and similar to that reported [265-267].

Non-unions increase the total burden of distal tibial shaft fractures and lead to additional health-care interventions [268, 269]. Brinker et al. evaluated 243 tibial shaft non-unions and concluded that tibial shaft fracture non-union is a devastating medical condition that negatively affects both physical and mental health and quality of life. The impact of tibial shaft fracture non-union on physical health (measured with SF-12 and the AAOS Lower Limb Core Scale) was comparable to the reported impact of end-stage hip arthrosis and worse than that of congestive heart failure. Although there was no matched cohort of patients with healed tibial diaphyseal fractures for comparison, they found that, on average, patients with non-union reported physical health poorer than that of 90% of the normal population and mental health poorer than that of 75% [270]. Historically, tibial fractures have constituted the bulk of non-unions and/or delayed unions of lower extremity fractures [271]. However, Zlowodzki et al. showed that the SF-36 and social function scores had improved significantly from the pre-treatment values to the values one-year after the successful treatment of tibial non-union [272].

The prevalence of long-bone non-unions in the diaphysis has been reported to be higher after tibial fractures compared with humeral and femoral fractures [273]. In twenty studies that comprised 5,517 mainly closed shaft tibial fractures caused by low-energy trauma, the prevalence of non-union was 2.5% and the combined prevalence of delayed union and non-union was 4.4% [274]. This is comparable to the results in Study I.

Fong et al. identified an association between the degree of cortical continuity and the development of a non-union in tibial shaft fractures treated with internal fixation [275]. Unreamed IM has been shown to be inferior to reamed IM in terms of re-operations and complications in patients with closed tibial diaphyseal fractures [89, 276]. In the treatment of non-union or delayed union in patients primarily treated with reamed IM, nailing is currently recommended. However, these procedures might lead to an infection rate as high as 11-12% [277-280].

Study II: The vast majority of tibial plateau fractures heal uneventfully, and there are almost no case series of intra-articular tibial plateau non-unions [281, 282].

Study III: Ristiniemi et al. used hybrid ring fixators in different types of intra-articular fracture, with or without osteoinduction. In the group without osteoinduction, the healing period was 21 weeks, which compares favourably with the 15 weeks for similar fractures in the present study [283].

Bacon et al. showed that intra-articular distal tibial fractures of an AO type C that were operated on using ORIF had a longer healing time when compared with fractures treated with the IL (39 to 25 weeks respectively) [284]. However, they did not find a statistically significant difference between the treatments in terms of non-union, malunion or infection.

9.3 Articular function (ROM)

9.3.1 Results

Study I: There were no differences in terms of knee or ankle joint ROM in the two groups at one year. In both groups, all the patients were able to bend their knees on the injured side more than 110°, in the IL group: median 140° (range 120-150) and in the IM group: median 140° (110-154). The ankle dorsiflexion on the injured side in the IL group was 10° (2-30), while it was 18° in the IM group (0-40). The plantar flexion on the injured side in the IL group was 35° (10-35), while it was 40° (20-68) in the IM group. Compared with the uninjured side, there was a reduction of more than 15° in passive ankle dorsiflexion in two patients in each treatment group and more than 15° in passive plantar flexion in six patients in the IL group and seven in the IM group.

Study II: Two patients with stiff knees with AO type C3 fractures were mobilised under epidural anaesthesia post-operatively at five and seven months

respectively. At the one-year follow-up, two patients had 90° knee flexion and other three patients had flexion of less than 90° with also extension deficits of more than 10°. Four of the five patients with reduced knee flexion had Schatzker type V or VI fractures. Taken as a whole, the patients with Schatzker type I-IV fractures had better knee flexion (140°, 86-156) than those with Schatzker type V-VI fractures (120°, 83-148). Ankle motion was not affected.

Study III: The median ankle dorsiflexion on the injured side was 21° (10-29) in the extra-articular group and 17° (5-26) in the intra-articular group. Compared with the uninjured side, three patients had reduced dorsiflexion of more than 10° (14, 15, and 16°). The plantar ankle flexion was reduced by more than 10° in seven patients in the type A fracture group (15°, range 12-23) and in nine patients in the type C group (22°, range 18- 33).

9.3.2 Discussion

Study I: When using the Ilizarov technique, some tethering of muscles and tendons is inevitable and this would theoretically affect the ROM in the knee and ankle joints. A study of adolescents has, however, shown good or excellent articular function after IL in diaphyseal fractures [285]. We have not found any previous study that addresses this issue in adults with tibial shaft fractures. In the present study, the ROM was similarly affected in both groups.

Study II: Knee stiffness is a common problem after tibial plateau fracture surgery [286]. Gaston et al. reported a series of sixty-three patients with mainly Schatzker type I-IV fractures in which 51 fractures were treated by internal fixation. At one year, 20% of the patients had knee stiffness, defined as flexion of less than 100° and an extension deficit of more than or equal to 5° [287]. Dendrinos et al. achieved good clinical results in 24 patients who had sustained high-energy tibial plateau fractures treated with the IL, in which 13 had full knee extension and 13 had flexion of more than 130° [288]. In 24 patients with the same fractures types treated with hybrid external fixators combined with limited internal fixation, Mikulak et al. reported that one patient had a 10° knee flexion contracture [289]. The results in the present study are similar to those in the above-mentioned studies. Even the complex fractures in the present study, requiring a hinged extension to the femur, had a satisfactory ROM, as only four of 15 patients with Schatzker type V-VI fractures had knee flexion of 90° or less. It was shown in a multicentre randomised trial of Schatzker type V-VI fractures treated with a circular fixator or ORIF that there was a substantial residual limb-specific deficit even at the two-year follow-up. In that study, the group managed with external fixation displayed a trend towards a

superior ROM of the knee compared with the group treated with ORIF, but the differences were not statistically significant [241].

Study III: In a retrospective study comprising 101 patients with fractures of AO type A, B or C treated with non-surgical, internal or unilateral external fixation, ankle stiffness was shown to be related to the fracture severity in distal tibial fractures with or without articular engagement. They reported a follow-up of 19 months with an average ROM of 10° (range -15 – 30) of ankle dorsiflexion and 28° (0-60) of ankle plantar flexion [290]. The results for ROM observed in Study III were similar.

9.4 Gait

9.4.1 Results

For the proximal Schatzker type I-IV fractures, the load (L) was higher than the load for the Schatzker type V-VI fractures at one, two and three months, but the difference was not statistically significant ($p=0.061$, $p=0.54$, $p=0.34$).

Forty-eight patients from Study I (28 in the IL group and 20 in the IM group) could be tested at an early stage post-operatively regarding load. There were four patients in the IL group and seven patients in the IM group in whom the load was below the threshold of the system or low and irregular. The load in these patients was set as 0% of the load on the uninjured side. The median value for the IL group was then 22% and for the IM group 9.4% ($p=0.046$). According to the inclusion criteria established in Study IV, not all patients were able to follow the protocol (Figure 9). Forty-three patients (22 in the IL group and 21 in the IM group) were followed up during the rehabilitation. Of these, the IL group loaded more immediately post-operatively than the IM group, but, at one, two and three months, the IM group loaded more. However, these differences were not statistically significant ($p=0.167$, $p=0.32$, $p=0.190$ and $p=0.158$) (Figure 12) (Table 15).

The difference in relative speed (RS) between type Schatzker I-IV and V-VI fractures at three months was statistically significant ($p=0.041$). At the early post-operative stage, the absolute RS values were low for both groups of proximal fractures. In the diaphyseal fractures, there was a consistent difference in absolute values at all time intervals between the two treatment groups in favour of the IM group ($p=0.067$, $p=0.063$, $p=0.080$ and $p=0.072$ respectively). The RS values for the distal fractures indicated a slow recovery (Figure 13) (Table 16).

With regard to the initial relative double-step length (RDS), all patients had short steps post-operatively. The proximal Schatzker type V-VI group also had the slowest rehabilitation in relation to this parameter. Compared with the proximal Schatzker type I-IV group, the difference at three months was statistically significant ($p=0.041$). The IL-treated group had a shorter RDS compared with the IM-treated group at one, two and three months ($p=0.063$, $p=0.080$, $p=0.072$). This parameter indicated a low recovery rate in the patients with distal fractures (Figure 14) (Table 17).

The symmetry of EFL of the proximal Schatzker type I-IV and the diaphyseal fractures (IL and IM) essentially followed the same pattern, initially with an affected roll-over of the foot, which was almost symmetrical after just one month. The proximal Schatzker type V-VI group displayed a different pattern, with seemingly more roll-over initially post-operatively and, when the femoral extension was removed at one month, the roll-over was instead reduced. The distal fracture group had less roll-over than the other fracture types at all time intervals (Figure 15) (Table 18).

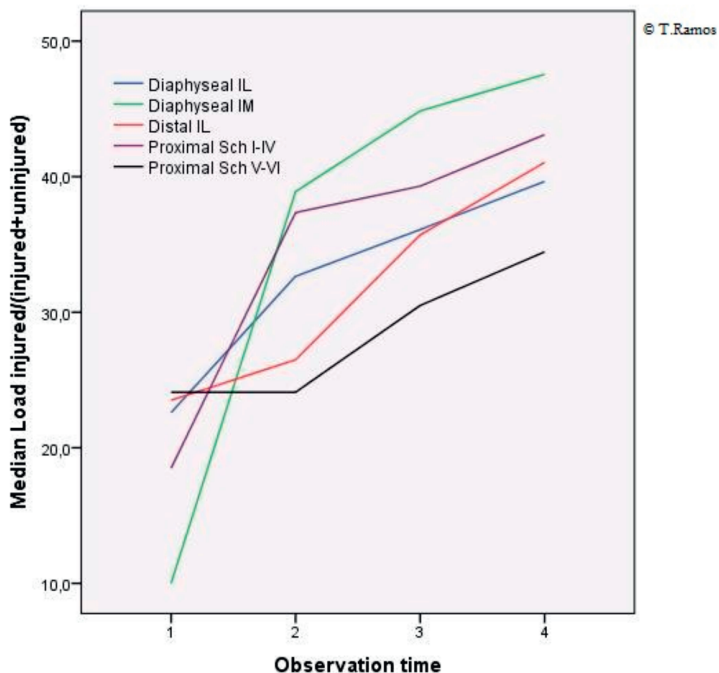


Figure 12. Median values for load $[\text{injured}/(\text{injured}+\text{uninjured})\times 100]$; 1 = post-operatively, 2 = 1 month, 3 = 2 months, 4 = 3 months, Sch = Schatzker

Table 15. Load (L) in %, median and percentiles 25-75. IL = Ilizarov, IM = Intramedullary nailing, Sch = Schatzker.

Fracture type	Post-operative	1 month	2 months	3 months
Diaphyseal IL	22.6 13.8-35.4	32.6 16.6-40.3	36.1 26.5-44.9	39.6 31.6-45.5
Diaphyseal IM	10.0 3.8-28.5	38.9 21.2-46.8	44.9 34.0-51.1	47.5 34.2-50.4
Distal IL	23.5 11.8-32.5	26.5 9.3-31.9	35.7 26.3-40.1	41 34.3-44.0
Proximal IL Sch I-IV	18.5 8.2-33.0	37.3 26.0-46.3	39.3 24.1-46.3	43.1 33.9-46.1
Proximal IL Sch V-VI	24.1 11.3-39.7	24.1 12.6-31.6	30.5 24.3-40.7	34.4 25.9-55.1

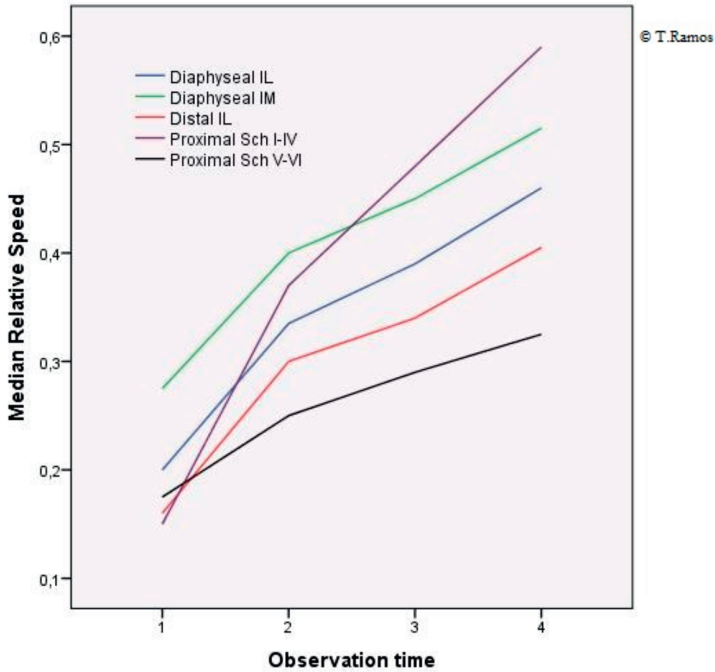


Figure 13. Median values for relative speed (RS 1/s) at different observation times. 1 = post-operatively, 2 = 1 month, 3 = 2 months, 4 = 3 months, Sch = Schatzker

Table 16. Relative speed (RS) in 1/s, median and percentiles 25-75.

IL = Ilizarov external fixator, IM = Intramedullary nailing, Sch = Schatzker.

Fracture type	Post-operative	1 month	2 months	3 months
Diaphyseal IL	0.20 0.10-0.22	0.33 0.24-0.44	0.39 0.33-0.47	0.46 0.36-0.50
Diaphyseal IM	0.27 0.15-0.37	0.40 0.32-0.50	0.45 0.39-0.53	0.51 0.42-0.60
Distal IL	0.16 0.12-0.21	0.30 0.25-0.37	0.34 0.27-0.40	0.40 0.33-0.53
Proximal IL Sch I-IV	0.15 0.10-0.28	0.37 0.23-0.53	0.48 0.31-0.56	0.59 0.32-0.71
Proximal IL Sch V-VI	0.17 0.11-0.21	0.25 0.17-0.33	0.29 0.23-0.36	0.32 0.23-0.41

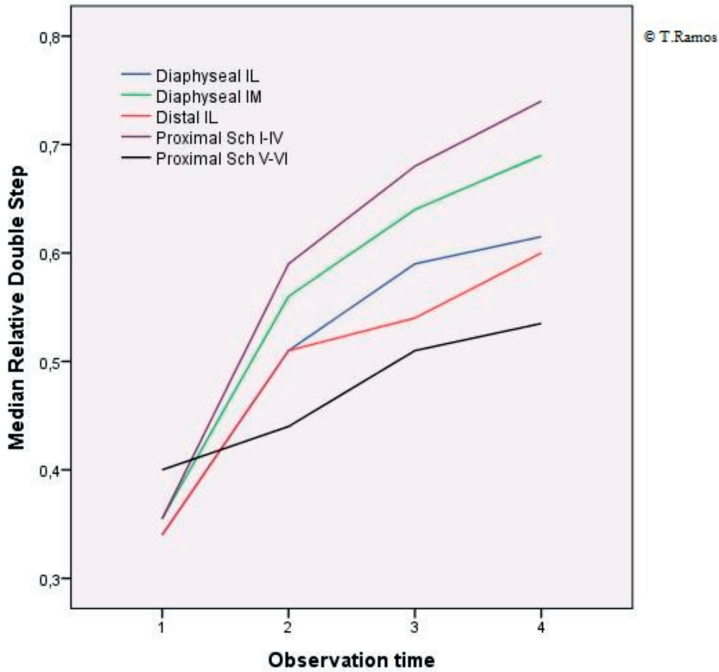


Figure 14. Median values for relative double step at different observation times. 1 = post-operatively, 2 = 1 month, 3 = 2 months, 4 = 3 months, Sch = Schatzker

Table 17. Relative double step (RDS), median and percentiles 25-75.

IL = Iliarov external fixator, IM = Intramedullary nailing, Sch = Schatzker.

Fracture type	Post-operative	1 month	2 months	3 months
Diaphyseal IL	0.34 0.26-0.41	0.51 0.45-0.60	0.59 0.5-0.67	0.61 0.55-0.70
Diaphyseal IM	0.35 0.18-0.49	0.56 0.47-0.72	0.64 0.56-0.73	0.69 0.61-0.76
Distal IL	0.34 0.27-0.41	0.51 0.41-0.55	0.54 0.48-0.57	0.6 0.50-0.68
Proximal IL Sch I-IV	0.35 0.29-0.48	0.59 0.44-0.70	0.68 0.51-0.72	0.74 0.54-0.80
Proximal IL Sch V-VI	0.40 0.30-0.45	0.44 0.30-0.51	0.51 0.43-0.58	0.53 0.46-0.60

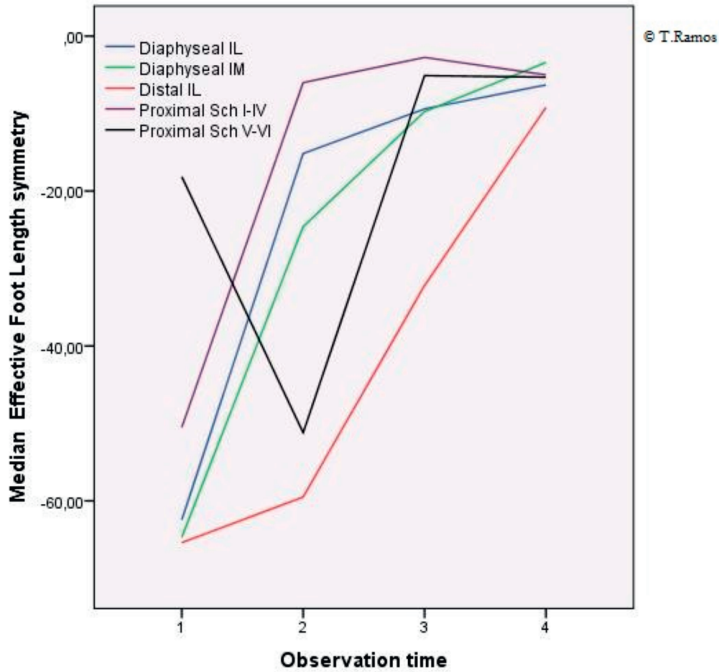


Figure 15. Median values for effective foot length (% of DSD) at different observation times. 1 = post-operatively, 2 = 1 month, 3 = 2 months, 4 = 3 months, Sch = Schatzker.

Table 18. Effective foot length (EFL) symmetry, median and percentiles 25-75. IL = Ilizarov external fixator, IM = Intramedullary nailing, Sch = Schatzker.

Fracture type	Post-operative	1 month	2 months	3 months
Diaphyseal IL	-62.4 -84.9 - -38.7	-15.1 -42.3 - -7.3	-9.4 -35.3 - -2.6	-6.3 -13.5 - -3.0
Diaphyseal IM	-64.7 -94.0 - -13.1	-24.6 -73.4 - -2.4	-9.8 -42.5 - -2.0	-3.4 -9.0 - -0.6
Distal IL	-65.4 -85.6 - -49.0	-59.5 -82.9 - -33.9	-32.2 -66.1 - -4.5	-9.2 -17.0 - -2.7
Proximal IL Sch I-IV	-50.5 -95.3 - -5.9	-6.0 -22.5 - -1.7	-2.8 -17.9 - -0.1	-5.0 -7.0 - -1.7
Proximal IL Sch V-VI	-18.1 -66.0 - -5.6	-51.2 -91.0 - -10.0	-5.1 -12.5 - -3.8	-5.3 -9.2 - -1.0

The correlations between the time post-operatively and the gait parameters (RS, RDS and L) are shown in Table 19. They are statistically significant for all parameters ($p < 0.01$) except L in Schatzker type V-VI fractures ($p = 0.050$). RS and RDS correlate more strongly than L with post-operative days and also with one another, varying between $r = 0.812$ for the diaphyseal IM patients and $r = 0.979$ for the Schatzker type I-IV fractures (Table 20).

Table 19. Correlation (Spearman's correlation coefficient - r) between days post-operatively and relative speed (RS), relative double step (RDS) and load (L) respectively. IL = Ilizarov, IM = Intramedullary nailing, Sch=Schatzker.

Fracture type	RS	RDS	L
Diaphyseal IL	0.639	0.659	0.378
Diaphyseal IM	0.485	0.581	0.436
Distal IL	0.720	0.703	0.394
Proximal IL Sch I-IV	0.615	0.594	0.560
Proximal IL Sch V-VI	0.522	0.505	0.291

All p -values < 0.01 except for L vs days for proximal Schatzker V-VI ($p = 0.05$)

Table 20. Correlation (Spearman's correlation coefficient - r) between relative speed (RS) and relative double step (RDS). IL = Ilizarov, IM = Intramedullary nailing, Sch=Schatzker.

Fracture type	RS/RSD
Diaphyseal IL	0.891
Diaphyseal IM	0.812
Distal IL	0.945
Proximal IL Sch I-IV	0.979
Proximal IL Sch V-VI	0.917

All p -values < 0.01

9.4.2 Discussion

The most important advantages of using pressure insoles are that they can be used outside a gait laboratory setting and the number of steps that can be registered is not limited. Furthermore, this type of system also allows measurements to be made with patients using an ordinary walking shoe, which is another advantage, as it is more representative of the way patients walk compared with bare-foot walking. There are no cables restricting movement. It is also possible to perform comprehensive studies on large patient

populations. To summarise, the pressure insoles offer simple and practical spatio-temporal gait parameters and loading patterns.

The reduction of pain and improved functional performance are expected to be seen over time and should be considered in relation to the progress of fracture healing. The improvement in gait parameters over time is a consequence of all these factors.

Weight-bearing *per se* has been shown to increase over time and correlates with the progress of the healing process [291, 292] and it could therefore be used as an indirect measurement of fracture healing [293]. There are studies in humans in which walking speed and step length have been used to evaluate early rehabilitation and indirectly fracture healing [294, 295].

In a study of 27 individuals, with tibial diaphyseal fractures treated with unilateral external fixation, the patients were instructed to bear weight as tolerated. The initial axial motion across the fracture site was small at 5 weeks post-operatively (mean 0.28 mm), peaked at 11 weeks (mean 0.43 mm) and then decreased as fracture healing progressed [296].

Kershaw et al. reported good results with immediate weight-bearing in 45 patients with tibial diaphyseal fractures treated with the unilateral external Dynabrace[®] fixator [292]. Joslin et al. studied 12 patients with diaphyseal tibial fractures treated with the Orthofix[®] fixator, who were allowed to bear weight as tolerated. Ten of 12 patients progressively increased the weight-bearing and reached 90% of the uninjured side at the time of the removal of the external fixator (mean 15.9 weeks) [293].

In the SPRINT trial, a large, multicentre randomised study, Schemitsch et al. analysed several prognostic factors for predicting outcomes after unreamed and reamed IM of diaphyseal tibial fractures. Post-operative full weight-bearing was a significant predictor of beneficial outcome compared with partial weight-bearing and non-weight-bearing after surgery. On the basis of their findings, weight-bearing should not necessarily be limited following IM of the tibia. However, if all patients were to bear full weight following surgery, the rate of auto-dynamisations (breaking of locking screws that result in fracture collapse) would probably increase. Auto-dynamisation may be associated with negative outcomes, such as retained broken screws, temporary pain and potential problems with revision surgery [297]. Unfortunately, the clinical relevance of a potentially improved union rate compared with an increase in the risk of screw breakage is still unknown.

In tibial shaft fractures fixed with IM, loads simulating partial weight-bearing after a fracture caused considerable interfragmentary movements of up to 10 mm in a study of cadaveric bones [298]. Hasenboehler et al. compared the biomechanical properties of IM and IL in a model of comminuted tibial shaft fractures when loaded axially and in torsion. They found that the IL provided a significantly higher range of axial micro-motion [189]. In spite of this immediate weight-bearing in diaphyseal tibial fractures, the fact remains that approximately 90% of the surgeons restricted weight-bearing in the immediate post-operative period according to the SPRINT study [297].

Most surgeons restrict weight-bearing after distal metaphyseal fractures for eight to twelve weeks. Bacon et al. retrospectively compared 28 patients with AO type C fractures who underwent surgery using a locking plate followed by non-weight-bearing until healing and 14 patients treated with the IL who were allowed immediate unrestricted weight-bearing. They found no statistical significant differences, although the plate group had a longer time to heal and the rates of non-union, malunion and soft-tissue infection were lower compared to the IL group [284]. Zarek et al. treated eight patients using the IL after tibial plafond fractures and allowed immediate weight-bearing. They showed bony union in all patients [299]. Fractures of the tibial pilon lead to restricted function of the lower limb and produce changes in gait patterns [300]. In the present study, distal fractures recover slowly and this might be due to the fact that it is difficult to achieve stability without a foot extension. The recovery pattern is otherwise similar to that in the other fracture types. The unrestricted weight-bearing appeared not be a negative factor for the final outcome.

Patient compliance with the surgeons' restrictions on weight-bearing is poor [301-303] and this was also noted in the present study. Even though the IL-treated patients were allowed unrestricted weight-bearing, the results show that, regardless of fracture type, they unloaded the injured extremity immediately post-operatively. Moreover, walking speed and step length were also affected during this period.

In all fracture types, the gait parameters showed improving results over time, as could be expected.

Except for the immediate post-operative period, the patients with diaphyseal tibial fractures in the present study treated with IM loaded more and walked faster, with a longer step length, compared with the IL patients. This difference, which is only a trend statistically, could probably be explained to some extent by the bulk of the external fixation being a partial obstacle when walking.

The EFL (the roll-over of the foot) has also been studied. The patients with diaphyseal fractures and the less complex proximal fractures (Schatzker type I-IV) regained an almost symmetrical roll-over within one month post-operatively. The Schatzker type V-VI fractures initially appeared to have more roll-over than the other fractures. If this is true, it could be explained by the femoral extension, which, even if hinged, restricts the knee flexion, forcing increased roll-over. Moreover, the distal fractures, engaging the ankle, have restricted motion for a longer time and the recovery of the normal roll-over is therefore slower.

The proximal tibial Schatzker type V-VI fractures that are more complex could be expected to experience slower normalisation of gait patterns compared with the Schatzker type I-IV fractures. Load, walking speed and step length increased more rapidly in the less complex fractures. Although the difference was not statistically significant for all parameters at all time intervals, the tendency was evident.

Another important issue is how the different gait parameters correlate to one another and whether any of these parameters has a higher correlation with the time parameter. The correlations between gait parameters and time were statistical significant, but it appears that walking speed and step length correlate better than load with rehabilitation time. Walking speed and step length also correlate highly with one another. The results indicate that fracture healing is reflected not only by how much the patients load but also to an even higher degree by walking speed and step length. If this could be confirmed in other studies, it could indicate a simplified way to study rehabilitation by just measuring walking speed and step length. Dingwell et al. compared step length and walking speed during over-the-ground and treadmill walking [304]. They found that treadmill walking was associated with significant reductions in locomotor variability, which could mask differences in gait variables that would present if patients had the opportunity to walk at a self-selected speed. The area used for the gait tests in the present study was large enough not to restrict the patient's ability to walk.

To summarise, the results of the present study show that a comprehensive study of gait parameters with an easy-to-use insole system can be a valuable adjunct in the evaluation of fracture treatment.

9.5 Malunion

9.5.1 Results

Study I: In the IL group, there were two malunions, both with 6° of valgus, and, in the IM group, there was one patient with 10° of valgus and one patient with an external rotation of 40°. Only the patient treated with IM who had 10° valgus deformity required corrective surgery.

Study II: The radiological results at the one-year follow-up were good in 27 patients, according to the criteria formulated by Rasmussen [227]. Six patients (20%) had instability and/or significant radiological deformity of 10 mm articular depression and/or condylar widening of more than 10 mm and/or valgus deformity of more than 10°. However, no patient complained of functional instability of the knee. No correctional osteotomies were performed, but two patients underwent total knee arthroplasties 2 and 4.5 years after the study was completed.

Study III: According to the radiological findings using the modified Burwell and Charnley classification, 13 patients were rated as good, 21 as fair and five had poor results in the total study cohort at the one-year follow-up. One patient with a poor result had a residual deformity of 12° valgus and developed post-traumatic sympathetic dystrophy. The deformity was treated with ankle arthrodesis 1.5 years after the index injury.

9.5.2 Discussion

Study I: Freedman et al. reported that 12% of their patients developed malalignment in 133 tibial fractures fixed with IMs [305]. In Study I, there were only a few malunions. An external fixator allows correction of the malalignment, but it was not necessary to use this opportunity in this series. Malalignment of the lower limb does not lead to any functional deficit of osteoarthritis of clinical significance, even with an angulation of up to 15°, according to evidence from the literature [306-308].

Study II: Several researchers have discussed the degree of dislocation that can be accepted with remaining good knee function. The post-operative articular congruity and normal axis of the lower leg after plate fixation in lateral tibial fractures appear to play a role in the prevention of post-traumatic osteoarthritis, but they do not appear to predict clinical outcome at the medium-term follow-up [309]. The long-term results reported by Rasmussen [310] and Lansinger et al. [311] showed that a residual depression of up to 10 mm could be accepted, provided the knee was stable. In a five-year follow-up of 109 fractures, Lucht

and Pilgaard reported that the functional outcome with a depression of <10 mm was acceptable [312]. Mattiassich et al. examined the development of osteoarthritis and post-traumatic bone loss after internal fixation for tibial plateau fractures in a short-term follow-up (median three years after the injury) and a long-term follow-up (median 23 years after the injury). They concluded that half the patients with minimal or no osteoarthritis at the first follow-up showed no deterioration of radiological osteoarthritis at the second follow-up [313]. However, the study population with a long-term follow-up is small and does not adequately represent all types of tibial plateau fracture.

In terms of articular depression, the recommended “acceptable” dislocation varies between 2 and 10 mm [314]. Marsh et al. pointed out that the scientific basis for the different recommendations is generally weak [315]. Giannoudis et al. found that, in tibial plateau fractures, articular incongruities appear to be well tolerated [316]. In addition to the articular depression, Rasmussen also found that instability and residual joint malalignment with varus and valgus angulations over 10° affected the outcome adversely [317]. The residual displacements observed in the present series are within these limits in all but three patients and, of the three patients with asymptomatic knee laxity, none had a valgus plateau tilt exceeding 5°.

Study III: The amount of residual deformity that can be accepted is still controversial [228]. It is difficult to correlate the post-operative radiological findings to the clinical result and to use this as a prognostic factor. In a study of 118 displaced ankle fractures, Joy et al. reported that precise measurements on the post-reduction radiograms correlated with the final clinical result, but other variables, such as the degree of talar displacement prior to reduction, the type of fracture and the presence of a deltoid ligament rupture, also significantly affected the final clinical outcome [318].

In a 10-year follow-up, Etter & Ganz examined how the fracture pattern and the degree of reduction correlated to post-operative osteoarthritis in 41 patients with plafond fractures treated with internal fixation. Anatomical reduction correlated with a better prognosis in terms of a lower risk of post-traumatic osteoarthritis, but it did not guarantee a good clinical outcome. Nor did severe radiological osteoarthritis present at the 10-year follow-up correlate with poor subjective or objective function [319]. DeCoster et al. came to the same conclusions when assessing the quality of the articular reduction of displaced intra-articular distal tibial fractures in 25 patients treated with articulated external fixation and limited internal fixation [320].

A future long-term follow-up of the patients in Study III might produce different results in terms of radiological findings and functional outcome. Marsh et al., who reported on a group of patients with a similar distribution of fractures according to the AO classification, did not, however, find any association between fracture type and clinical outcome at the five- to 12-year follow-up. The majority of their patients had some limitation with regard to recreational activities and the degree of osteoarthritis was grade two or more in 26 patients. In spite of this, a minimum of five years after the injury, few patients required secondary reconstructive procedures, because the pain and functional deficit tended to decrease over a long time period [321].

Even if the follow-up in the present study is too short to detect post-traumatic osteoarthritis, the radiological and clinical results are acceptable when compared with these earlier reports.

9.6 Pin infections

9.6.1 Results

Table 21. Pin infection incidence analysis in all patients treated with the IL. The pin-site infections were classified according to Checketts-Otterburn.

	Study I	Study II	Study III	Total
Number of patients	31	30	39	100
Number of rings	134	113	157	286
Number of patients with pin-site infections (in some >1)	16 (51%)	16 (53%)	34 (87%)	66 (66%)
Pin-sites	804	642	1.102	2.548
Pin-site infections	35 (4.3)%	27 (4%)	44 (4%)	106 (4%)
Minor infections (Grades I-III)	35	25	42	102
Major infections (Grades IV-VI)	0	2	2	4

Study I: Thirty-five minor pin-site infections were observed: 23 Checketts-Otterburn II in nine patients who were treated with short-term antibiotics and 12 Checketts-Otterburn III in seven patients, all treated with the removal of the offending wire.

Study II: Twenty-five minor pin-site infections Checketts-Otterburn II were observed in 16 patients who were all treated with short-term antibiotics. Two had grade IV infections that healed after soft-tissue debridement.

Study III: Forty-two minor pin-site infections were observed: 24 Checketts-Otterburn type II in 19 patients who were treated with short-term antibiotics

and 18 Checketts-Otterburn type III in 15 patients all treated with the removal of the offending wire. One patient with an A2 fracture had a grade IV pin-tract infection that was successfully treated with soft-tissue curettage. After the fixator had been removed, in one patient with a C1 fracture, a deep Staph. aureus infection was diagnosed in an area with a previous pin scar. The lesion was treated with curettage; however, there was a progressive loss of reduction. This was treated successfully with stabilisation and progressive correction with a new Ilizarov external fixator application for a period of 23 weeks combined with per-oral antibiotic therapy (clindamycin) for 12 weeks.

9.6.2 Discussion

The definition of pin-site infections is controversial, as there are many different definitions. Pin-site infections are one of the most common complications of the IL [322] and their incidence has been reported to range from 10% to 100% [323-325].

The detail when it comes to clarifying the difference between a wound that is irritated and a wound that is infected is not completely clear [326]. There is no standardised validated grading system to assess pin sites infections [327]. The Checketts-Otterburn classification appears to be a useful tool in clinical decision-making [328]. External fixation wires and pins are colonised with bacteria, usually *Staphylococcus aureus* and *Staphylococcus epidermidis* [329, 330].

Local pain is a cardinal symptom in defining pin infection, but it is associated with the individual profile, pre-operative information and cultural background, which might be factors of importance. Dellinger et al. defined a wound infection as superficial when it is located entirely above the fascia with erythema and tenderness that requires antibiotic therapy and opening of the wound. A deep infection was defined as infected tissue underneath the muscular fascia [331].

It is probably more appropriate to discuss the superficial infections in the IL in relation to pin sites instead of per individual. The rationale for this is that we are actually talking about the number of superficial infections related to the number of wounds. From this perspective, the risk of infection is low, especially considering how few of them result in more serious infections.

The rate of pin-site infection in the present study was 4% of all pin sites, of which approximately 90% were minor infections, Checketts-Otterburn I-III. These findings are similar to those in other studies where the pin-site rates have been calculated as varying between 4% and 18% [146, 327, 332, 333]. In the

present studies, the vast majority of the pin infections were minor infections when using the Checketts-Otterburn classification. This is also in accordance with the previous reports.

In a study examining 214 pin sites during the pin removal, Mahan et al. reported that 75% of the pin tips had positive bacteria cultures [334]. We have not routinely used bacteria cultures to establish the diagnosis. Firstly, it would be impractical to perform cultures from several pin sites and secondly, if deemed necessary, short-term antibiotic treatment was started as soon as possible. For diagnosis, we therefore relied on local tenderness and purulent discharge to define infection.

Pin-tract infection was defined as any persistent drainage from a pin site requiring intervention or positive bacterial cultures. Alemdaroglu et al. analysed the contribution of the various risk factors to the delay in healing in tibial shaft fractures treated by circular external fixator in 32 tibial shaft fractures. They found that infection and not using supplementary fixation techniques were the main factors that delayed healing [335]. Poor reduction is also related to the occurrence of pin-tract infections. Parameswaran et al. found that the incidence of pin-tract infections was lower for ring fixators (3.9%) than for a hybrid external fixator (20%) and unilateral fixator (13%) [336]. The rate of pin-tract infection can probably be reduced using antibiotic dressings. In a randomised trial, Lee et al. showed that the use of gauze impregnated with polyhexamethylene biguanide reduced the risk of pin-tract infections compared with plain gauze in external fixation [337].

Pin-site complications are related to motion at the pin-skin interface, the amount of soft tissue between the skin and bone, surgical technique and the diameter of the pin that is used [338]. The diameter of the tensioned IL pin is approximately one-third compared with that of conventional half-pins, reducing the soft-tissue and bone damage [179]. Saw et al. reported that the rate of infection was higher on half-pin-sites than wire sites ($p = 0.002$) [327]. The risk of pin-site infection is also lower if measures are taken to avoid thermal injury and the formation of a local haematoma during surgery and if the after-care includes the use of alcoholic antiseptic and occlusive pressure dressings [339].

In the present study, chlorhexidine was used for pin-site care. Chlorhexidine is an inexpensive anti-septic coating with a low risk of bacterial resistance [340]. It has been shown that nihilistic care is also possible [333, 341]. Different anti-septic strategies, such as the use of titanium-copper alloys, nanosilver coatings, nitric oxide coatings, chitosan coatings, iodine, hydroxyapatite, chlorhexidine

and antibiotic coatings, have been studied and it is unclear which method is the most appropriate [342]. It might be possible to reduce the incidence of pin infections in the future with a better site strategy which includes correct external fixator biomechanics, surgical technique and a standardised post-operative pin-site care protocol [328]. Recently, the Royal College of Nursing in the UK published a guidance consensus on pin-site care [343].

In the present studies, the preferred treatment for all superficial infections was fluocloxacillin (beta-lactamase) when antibiotics were required. It is clear that antibiotic resistance appears to be inevitable, but different solutions have been proposed by experts. In a systematic review, Tacconnelli et al. concluded that there is a clear association between exposure to antibiotics and MRSA. The risk ratio for a single class of antibiotics was the lowest with beta-lactamase when compared with quinolones, glycopeptides and cephalosporin antibiotics [344]. A “niche” antibiotic, such as the beta-lactamases in the treatment of pin infections, avoiding the use of broad-spectrum antibiotics, represents a form of control of antibiotic resistance [345].

The only way to avoid or slow down the speed of excess resistance formation is the prudent use of antibiotics and/or the development of alternative strategies to control pathogens [346]. The risk of developing MRSA due to a deep infection treated with long-term antibiotics is expected to be increased compared with short-term beta-lactamase treatment of superficial infections. These aspects are also important to consider when there is a choice between the external and internal fixation of fractures.

10 MAJOR COMPLICATIONS

The majority of tibial fractures are simple and major complications are often unexpected. Even if the classification of fractures is important when discussing the choice of treatment, they often fail when it comes to predicting complications. This is especially true when evaluating soft-tissue injuries. Despite the wide use of the Gustilo classification for open fractures, its reliability has been challenged [347, 348]. The Tschernke classification has been suggested as being more predictive of the prognosis than other classifications of tibial shaft fractures [349].

Complications after the use of the IL have been discussed by several authors, such as Paley [338], and the ASAMI group [350, 351]. However, most of the complication classifications that have been recommended are related to when the IL method is used in reconstruction and corrections of deformities and these classifications do not appear to be relevant in the discussion or comparison with the results of the present studies.

In acute trauma surgery, the Ilizarov application appeared to have fewer complications than other reconstructive procedures. This was confirmed in a retrospective analysis of prospectively collected data relating to 304 patients from Ireland and the United Kingdom, in which Adair et al. showed that there were significant differences between complication rates when Ilizarov frames were applied for acute trauma, late presentation of trauma and elective surgery. They also reported that this difference did not appear to relate to time spent in the frame but instead to the different clinical settings [352]

Deep infection and compartment syndrome are the most devastating complications related to the surgical treatment of tibial fractures.

10.1 Deep infection

10.1.1 Results

No case of osteomyelitis was observed in the series of patients treated with IL. In Study I, there was one patient in the IM group with a deep infection (abscess near the fracture site) but without radiological signs of osteomyelitis.

10.1.2 Discussion

Osteomyelitis due to local spread from a continuously contaminated source of infection is a serious complication of either open fractures or in relation to orthopaedic implants [353]. In closed tibial and femoral fractures, bacteria strains have been detected in the fracture gap callus during surgery. They most probably colonised the tissues even before the surgical intervention took place [354]. The presence of an implant in the body is known to increase the susceptibility to infection [355], even though different methods to reduce bacterial adhesions are known [356]. In a retrospective study of closed diaphyseal fractures treated with IM and complicated with infection, Petrisor et al. found that, in approximately 56% of the cases, there was no obvious cause [357].

In the IM group, the efficacy of all anti-staphylococcal agents is seriously reduced in established implant-related deep-seated infections. Frequently, in addition to wide-spectrum antibiotics, surgical implant removal might be required [353].

The incidence of chronic osteomyelitis, after unilateral external fixation using half-pins, has been reported to be between 0% and 4% [358]. Pin-tract infections do not usually progress to osteomyelitis, but, if it occurs, it leads to a major problem, especially for future surgery [359]. The placement of definitive plate fixation overlapping previous external fixator pin sites significantly increases the risk of deep infection in the two-stage treatment of bicondylar tibial plateau and pilon fractures [360]. There are several reports of an increased rate of infection when IM was performed after more than two weeks of external fixation [359, 361]. In the case of a pin-tract infection, there is a high risk (up to 71%) of deep infection if the external fixation device is changed to an IM, compared with a low incidence (5.9%) when performing this exchange in the absence of a pin-tract infection [359]. In the present study, conversion to internal fixation was not a problem, as all patients treated with the IL were able to pursue the treatment until the fractures had healed.

10.2 Compartment syndrome

10.2.1 Results

Study I: In the IM group, two patients developed compartment syndrome and underwent fasciotomy within 24 hours after the index operation. One of them developed a permanent drop foot and disturbed peroneus nerve sensory function.

Study II: Two patients with Schatzker type VI fractures developed compartment syndrome (Schatzker VI/AO C3 and VI/C2). In the first patient, the compartment syndrome was masked by an over-consumption of opiates and the patient did not undergo fasciotomy until one day after the initial operation. He had muscle necrosis of the lateral compartment of the leg and permanent peroneal nerve palsy. The other patient underwent fasciotomy immediately after the application of the fixator. He developed a fistula in the fasciotomy wound, which required excision but healed without sequelae.

Study III: No patients developed compartment syndrome.

10.2.2 Discussion

Clinical signs and surgeon experience are still of key importance for the diagnosis [362-364]. The decision to perform an acute fasciotomy is not easy, regardless of the criteria used, as this intervention increases the risk of impaired fracture healing and longer time to union [365, 366]. Fasciotomy might also lead to functional disabilities, poorer quality of life and long-term wound sequelae [367-369]. The exact threshold parameters of compartment pressure that define compartment syndrome and the efficacy of the clinical examination continue to be an area of research. In closed diaphyseal fractures treated with plaster casts, the routine monitoring of pressure measurements up to 72 hours after trauma resulted in borderline benefits [370]. As a result, compartment pressure monitoring has not become a “gold standard” [363, 371].

Study I: Thirty-six per cent of all compartment syndromes occur after tibial diaphyseal fractures [372]. The acute compartment syndrome prevalence in the IM group was comparable to earlier reports with a prevalence of up to 10% [363, 373, 374].

Traction using the fracture table and reamed IM may increase the risk of compartment syndrome [67, 375, 376]. Both interventions in Study I were performed using a traction table. One advantage of the IL is that the traction created by the frame can be reduced if a compartment syndrome is suspected during and after surgery.

Study II: In a retrospective study, Park et al. found a low rate (1.6%) of compartment syndromes requiring fasciotomy in patients with proximal tibial fractures [377]. However, in more complex fractures, the risk of compartment syndrome is considerably higher. For Schatzker type VI fractures, Stark et al. found a difference in the risk of developing compartment syndrome depending on whether or not the medial plateau was dislocated, 53% and 18% respectively, with an overall risk of 27% [378]. The incidence of compartment

syndrome in the more severe fractures (Schatzker types V and VI) in the present series was 10.5% (2/19 patients). The compartment syndromes were interpreted as a direct result of the fracture and the soft-tissue injury and not of the surgical procedure. Even though the Ilizarov technique is “gentle” to the soft tissues, minimising the risk of developing compartment syndrome, the IL frame does not exclude fasciotomy when necessary. In the present study, one patient with a proximal metaphyseal fracture who developed compartment syndrome might possibly have been treated at an earlier stage if compartment pressure monitoring had been used routinely.

Study III: No compartment syndrome was observed. Distal metaphyseal fractures associated with acute compartment syndrome are rare occurrences in adults, despite the relatively high-energy mechanisms that cause many pilon fractures [377, 379].

11 SELF-APPRAISAL

11.1 Results

A summary of the results of the self-appraisal scores is given in Table 22.

Study I: At the one-year follow-up, there were differences in terms of pain (VAS) and satisfaction (VAS) scores in favour of the IL treatment. Pain or local tenderness localization at the one-year follow-up was registered. There were 19 patients who experienced anterior knee pain in the IM group and one in the IL group ($p=0.001$). Five patients in each treatment group had pain at the fracture site.

Study II: The differences between the pain (VAS), NHP and EQ-5D values at one year were not significant. The NHP total scores and EQ-5D values show that the overall function was severely affected at four weeks. However, there were no differences between the subgroups. The knee function as expressed in self-appraisal scores improved more rapidly in patients with Schatzker type I-IV fractures than in those with the more severe Schatzker type V-VI fractures. Good knee function was registered at the one-year follow-up and there were no differences between the groups.

Study III: The pain values (VAS) reached acceptable levels at four weeks, but they did not improve further between four and 12 weeks post-operatively. Patient satisfaction (VAS) was generally high in both groups at all follow-up assessments. The NHP total score showed a relatively moderate effect at four and twelve weeks and was almost normal at one year. The EQ-5D values showed a similar pattern. After one year, there were no clinically important differences between the A and C groups in terms of pain (VAS), patient satisfaction (VAS), NHP total score, EQ5D or FAOS. Intra-articular fractures showed a tendency to result in lower FAOS subscores.

Table 22. The patients' pain (VAS), satisfaction (VAS), the NHP total score and EQ-5D at different time intervals. Median values (95% CI) are given. p-values of <0.05 are highlighted in bold.

Parameter	Study I (II)	Study I (IM)	p-value	Study II (SI-IV)	Study II (SV-VI)	Study III Extra-articular	Study III Intra-articular
Number of patients	30 ¹	27		11	19	14	16
Pain (VAS)							
4 weeks	18 (0-78)	28 (0-78)	n.s.	20 (0-50)	28 (24-27)	27 (7-63)	28 (8-58)
12 weeks	14 (0-78)	18 (0-48)	n.s.	7 (0-45)	25 (9-29)	29 (3-56)	26 (0-78)
1 year	5 (0-69)	18 (0-58)	0.03	9 (0-21)	16 (1-23)	7 (0-54)	14 (0-76)
At KOOS				5 (0-47)	18 (0-69)		
At FAOS						7 (0-67)	8 (0-49)
Patient satisfaction (VAS)							
4 weeks	27 (0-42)	27 (0-67)	n.s.	9 (3-28)	28 (7-42)	14 (1-29)	9 (7-47)
12 weeks	10 (0-48)	27 (0-99)	n.s.	8 (5-48)	14 (6-30)	24 (0-52)	14 (3-35)
1 year	9 (0-69)	27 (0-99)	0.02	13 (0-22)	13 (6-23)	8 (0-61)	20 (0-53)
At KOOS				13 (0-49)	27 (0-100)		
At FAOS						7 (0-67)	8 (0-49)
NHP total score							
4 weeks	17.5 (5.6-65.2)	19.0 (0-59.5)	n.s.	5.3 (3.5-36.8)	37.3 (15.7-46.8)	20.2 (4.9-83.3)	12.4 (0-48.6)
12 weeks	17.9 (1.4-41.8)	12.2 (0-42.0)	n.s.	1.8 (0-17.4)	20.2 (11.2-34.5)	16.8 (0-69.8)	15.4 (0-48.7)
1 year	1.6 (0-62.2)	5.2 (0-52)	n.s.	1.8 (0-11.4)	7.4 (1.8-19.3)	1.8 (0-76.3)	2.7 (0-39.8)
At KOOS				16.8 (2.1-42.5)	17.8 (2.1-56.3)		
At FAOS						1.8 (0-65)	4.1 (0-54)
EQ-5D							
4 weeks	0.59 (-0.003-0.85)	0.62 (0.10-0.88)	n.s.	0.66 (0.29-0.81)	0.59 (0.29-0.62)	0.62 (-0.07-0.88)	0.52 (0.15-0.73)
12 weeks	0.69 (0.088-1.0)	0.69 (0.18-0.85)	n.s.	0.76 (0.62-1.0)	0.62 (0.29-0.69)	0.69 (0.19-1.0)	0.62 (0.02-0.73)
1 year	0.93 (-0.077-1.0)	0.79 (0.16-1.0)	n.s.	0.89 (0.69-1.0)	0.80 (0.69-0.85)	1.0 (0.29-1.0)	0.80 (0.20-1.0)
At KOOS				1.0 (0.69-1.0)	0.74 (0.08-1.0)		
At FAOS						0.93 (0.66-1.0)	0.80 (0.36-1.0)

¹ One patient refused to comply with the study protocol. Comparisons between the groups are made using the Mann-Whitney U- test n.s. = not statistically significant

11.2 Discussion

In recent years there has been increasing interest in the patients' opinion of functional outcomes. However, there is no consensus about which score to use. This is a major limitation and makes conclusions difficult to draw and, as different scores are used, it is almost impossible to compare studies.

The patients' satisfaction may influence treatment outcomes [380]. Moreover, the effectiveness of a treatment from a patient's perspective can be estimated using patient-related outcomes [381]. Measuring health-related quality of life (HRQoL) at population level is also becoming increasingly important for priority setting in health-care policy [382]. In studies of the IL, most authors have primarily adopted a biomechanical, physiological and medical perspective. Using qualitative research studies might also provide additional information to explain the patients' experiences. In a qualitative study of fracture patients treated with the IL, Modin et al. described the limitations in daily living during the early post-operative weeks according to patient experience. They found that some of these limitations were explained by the suboptimal information given to patients prior to discharge, concerning the value of weight-bearing [383]. Baschera et al. assessed the impact on patient quality of life using the SF-12 health survey and questions about various aspects of the quality of life of patients treated with the IL after severe tibial fractures compromised by extensive soft-tissue damage. They found that the majority of the patients were satisfied and 91% would choose the same method of treatment again under similar circumstances [384].

The self-appraisal tests performed in these studies have previously been used in different clinical situations. A VAS has been used to measure specific aspects of the quality of life, such as pain [385, 386] and global quality of life [387, 388]. This instrument has been recommended as a global quality of life measurement in a clinical trial [389]. The Nottingham Health Profile (NHP) was developed for use in epidemiological studies of health and disease [223]. The Swedish version [390] has proved to be valid and reliable, for example, in patients with degenerative arthritis of the hip joint [222] and in patients suffering from severe ventricular arrhythmias [391]. A previous evaluation of NHP and SF-36 scores in a prospective trial, designed to study the effect of Ilizarov reconstruction of post-traumatic lower-limb deformities on general health status, showed improvements equal to or better than the improvements reported for other orthopaedic procedures, including total joint arthroplasty [392].

Study I: There was a good correlation between the scores. There was a trend indicating that the patients in the IL group generally scored better than the patients in the IM group and the difference in the VAS scores was statistically significant for pain and satisfaction at one year. However, the wide score range confirms that long-term physical disability remains a problem for many patients following tibial shaft fracture.

Foster et al. reported that the IL was a reliable method to treat complex segmental diaphyseal fractures resulting in good SF-12 scores [393]. Giotakis et al. reported that, in segmental tibial fractures, treatment with circular external fixation resulted in satisfactory functional scores for the knee and ankle and general health status in the SF-36 questionnaire, including the Mental Component Score [394]. However, these studies were performed on multiple injuries and the results are not comparable to those in Study I.

Dogra et al. reported that 31% of patients with isolated tibial shaft fractures treated with IM, followed-up during a mean of 57 months post-operatively, had unsatisfactory late results, with significant disability and poor quality of life, according to the patient-oriented outcomes (Iowa Knee and Ankle Scores, VAS pain and SF-36). Knee pain was the most important factor. [395]. The majority of patients in Study I treated with IM had anterior knee pain, which is also the most common long-term problem in the treatment of tibial fractures using this method [103, 396-399]. The etiology of the anterior knee pain is still uncertain, but it is probably due to a combination of several factors [396, 400]. Just the presence of the tibial nail causing a bending strain exerted by the proximal part on the bone could in itself be an explanation for anterior knee pain [401].

The incidence of anterior knee pain has been reported in more than 50% of patients [398]. Keating et al. found that 77% of patients developed knee pain after a tendon-splitting incision, whereas only 50% developed pain after a parapatellar approach [399]. However, Toivanen et al. reported no significant difference in pain between the approaches in a prospective randomised, controlled study [397]. Using a paratendinous approach for the nail insertion after tibial fractures does not appear to reduce the prevalence of chronic anterior knee pain or functional impairment compared with the trans-patellar tendon approach [402, 403]. Rothberg et al. recently reported on a new “semi-extended”, extra-articular, para-patellar approach. They did not observe any increase in anterior knee pain measured by the Lysholm Knee Score compared with an uninjured control group one year post-operatively [404]. Ryan et al. used this approach to proximal and distal third tibial fractures, but contrary to the results of Rothberg et al. the incidence of post-operative knee pain at the

follow-up (two years) was the same as with the para-patellar approach [405]. Darabos et al. claimed that precise nail tip positioning prevents the anterior knee pain after IM [406]. Even if the pain eventually subsides or disappears, it is still present in approximately 30% of patients during a long time period (three to eight years) independently of the para-patellar or trans-patellar approach [407].

In a prospective study of 64 consecutive patients with tibial diaphyseal fractures (in which 67% of the patients were treated with IM, 17% with a plate and 16% using a cast), Skoog et al. showed that 12 months after the injury, half the patients operated on with IM had knee pain and nearly half the patients still experienced functional limitations related to the fracture, which was also reflected in the quality-of-life parameters [408]. Even approximately eight years after IM of tibial shaft fractures, the majority of the patients experienced anterior knee pain, limitations in activity and restrictions in QoL compared with a reference population [409]. Ferguson et al. also concluded in a study comprising 60 patients (80% of them treated with IM, 10% with a cast and 9% with external fixation) that long-term physical disability remained a problem in many patients following tibial shaft fractures [410]. Lefaivre et al. reported on 56 patients with isolated tibial fractures treated with IM and a follow-up of 14 years that 73% of patients had at least moderate knee pain with any activity. They therefore concluded that this should be taken into consideration when providing prognostic information to patients [101].

It is not unusual that the osteosynthesis needs to be removed under full anaesthesia. Patients' reported reasons for hardware removal (IM) in diaphyseal fractures included pain (46%), infection (3%) and patient request or no indication (44%) [411, 412]. However, the results of nail removal to alleviate pain are poor. Karladani et al. found that approximately 44% of the patients still experienced dysesthesia related to the infra-patellar nerve due to the local injury to the soft tissues during the introduction of the nail [411]. Other reasons for dysesthesia were related to injuries to the superficial peroneal nerve in 8% and the saphenous nerve in 1%. Sala et al. found no resolution of anterior knee pain after IM removal and MRI showed patellar tendinitis [413].

Study II: Some residual pain was still present at the one-year follow-up, which most probably reflects the severe nature of these fractures more than treatment failure.

Despite successful treatment and improvement in their outcomes, the KOOS subscores showed the lowest values for Sport/Rec and QoL, which is probably due to the fact that patients from previous studies using this score are

commonly younger and more active than the patients enrolled in the present study. In two recently published studies, the KOOS has been used in the follow-up after IM of tibial shaft fractures and osteosynthesis of patellar fractures showing results similar to those in the present study [409, 414]. Apart from this, patients with type I-IV fractures had results similar to those of patients after ACL reconstruction [230] and even the patients with fractures type V-VI had acceptable results.

Study III: The groups were compared with results from the literature demonstrating that distal tibial metaphyseal fractures have a negative effect on ankle function and general health in a short to intermediate perspective, but symptoms tend to decrease gradually during a long time period after healing [321, 415, 416]. Despite successful treatment and improvement in their outcomes, the FAOS subscores showed the lowest values for Sport/Rec and QoL, especially for the C fractures. They did not differ significantly, when compared with patient-reported outcomes after surgery on ankle ligaments, trimalleolar or distal fibular fractures [315, 415, 417]. All the patients in the present study returned to work, while sporting activities were severely restricted, without significant differences between subgroups or fracture types.

To summarise, the patients' self-appraisals used in the present series (Pain-VAS, Satisfaction-VAS, NHP, EQ-5D, KOOS and FAOS) showed that the IL was well tolerated and the overall restoration of function was good in all studies.

12 RE-OPERATIONS

12.1 Results

Table 23. The reasons for re-operations where general or regional anaesthesia had to be used.

	Study I IL	Study I IM	Study II	Study III
Compartment syndrome	0	2	2	0
Deep infection	0	1	2	2
Broken hardware	0	1	0	0
Pseudarthrosis	2	1	0	0
Nail removal	0	6	0	0
Screw removal/ replacement of wires	4	8	0	0
Knee arthroscopy	0	0	1	0
Total knee arthroplasty	0	0	2	0
Ankle arthrodesis	0	0	0	1

12.2 Discussion

Study I: Hardware problems related to IM are more complicated than those related to the IL. When it comes to IM fixations, this includes the breakage of interlocking screws or more rarely the nail itself. Broken hardware, especially screws, is more common when small-diameter nails are used, with a reported prevalence as high as 40% [418]. Small-diameter nails are associated with an increased risk of delayed union and have less mechanical strength, both of which may lead to an increased rate of material failure. To reduce the risk of hardware failure, a large-diameter nail should be used with two distal screws (as in Study I) rather than one. Kneifel et al. reported that the rate of screw failure was 59% when a single distal screw was used compared with 5% when two screws were used [419].

Fong et al. also identified the degree of cortical continuity as a risk factor for re-operation [275]. Bhandari et al. defined re-operation as any surgical procedure after the initial surgery that was aimed specifically at achieving bony union of the fracture and found a total number of re-operations of 22.4% in 192 patients with tibial diaphyseal fractures [420]. With the same definition of re-operation, Harris et al. found that the overall reoperation rate was 35.8% in 151 consecutive patients with tibial shaft fractures [421]. In Study I, the rate was 19% in the IL group (the ambulatory extraction of wires was excluded) and

70% in the IM group. The high re-operation rate observed in the IM group is mainly due to anterior knee pain, with the removal of screws or nails. If these re-operations are excluded, the rate is the same as for the IL group, 19%.

Study II: A re-operation rate of 22% in Study II, including 19 Schatzker type V-VI fractures, is not regarded as high compared with results previously published in the literature [237, 239, 241, 422-430]. In a large cohort of 8,426 patients operated on because of Schatzker type V-VI fractures, the rate of subsequent total knee arthroplasty was compared with the rate in the general population. It was found that, ten years after tibial plateau fracture surgery, 7.3% of the patients had received a total knee arthroplasty. This corresponded to a 5.3-fold increase in the likelihood of receiving a total knee arthroplasty, compared with a matched group from the general population. In spite of the low rate of conversion to knee arthroplasty, the presence of implants might add some technical obstacles to routine arthroplasty surgery [431]. This is avoided when the IL is used.

Study III: A re-operation rate of 7.7% in Study III, with eighteen intra-articular fractures, is low, compared with results previously published in the literature [111, 112, 432-437].

13 STRENGTHS AND LIMITATIONS

The strength of Studies I-III is that it was possible to analyse consecutive series of patients and that the results could be related to their own perception of the treatment and outcome, which has rarely been the case in previous evaluations of fracture treatment. Only one patient in all the studies did not comply with the follow-up plan.

In Study I, all the patients were treated in accordance with the randomisation protocol. In both treatment groups, the patients were operated on by several surgeons, with similar levels of expertise.

There are several limitations that apply to the present studies. In Study I, the cohort might have been too small to detect differences in terms of major complications. The impossibility of blinding surgeons also introduces a risk of bias. In Studies II and III, there were no control groups and the follow-up is too short to detect late post-traumatic degenerative osteoarthritis. In Study IV, a fairly high drop-out rate was observed, which could contribute to some selection bias.

Ideally, the follow-up time should be longer, because the prolonged deficits after tibial fractures are well known [408]. The follow-up of 12 months is adequate for an initial assessment of procedural efficacy, but it does not take the development of long-term degenerative osteoarthritis into account.

14 SUMMARY

Study I: The most important finding in this study was that the IL treatment of tibial diaphyseal fractures produced results at least as good as the “gold standard”, IM.

In a *post-hoc* analysis, we combined malunion and pseudarthrosis as a composite variable called “major complications”. A power analysis based on this assumption would have required 90 patients in each group, an almost impossible study design. There is also the question of whether this difference is so clinically important that it should justify a change in treatment from the “gold standard”. For minor complications, such as anterior knee pain in the IM group and pin infections in the IL group, with the frequencies observed, 10 patients in each group would have been sufficient, assuming that these are one-sided estimations.

Study II: The most important finding in this study was that, in both Schatzker type I-IV and Schatzker type V-VI fractures, the IL fixation allowed early weight-bearing without jeopardising the fracture stability and healing and with results comparable to reports in the literature.

Study III: The most important finding in this study was the satisfactory outcome of the Ilizarov method, independent of fracture pattern. Using an identical protocol for both intra- and extra-articular fractures, it was possible to operate on all patients without delay, regardless of the status of soft tissues, the size of the distal fragment and the intra-articular fracture engagement, without using a staged protocol. This was also emphasised by the absence of clinically important differences between the outcomes for intra- and extra-articular fractures.

Study IV: The most important finding in this study was that a gait analysis with an easy-to-use pressure insole system could provide valuable information on the rehabilitation and healing of fractures in the tibia. The operational simplicity and high capacity of insole technology suggest that the method is suitable for use in clinical settings and not only restricted to a gait laboratory. There appear to be different “rehabilitation patterns” that reflect the different fracture types. The study also showed that, even though the IL patients were allowed immediate, unrestricted weight-bearing, they did not do this.

The demography and etiology of the results in the studies included in this thesis were similar to the studies in the literature discussed in Studies I-III. We chose

to stratify to ensure that age would not be a confounding factor and this was therefore not discussed further.

The IL technique should not affect the range of motion, which is obvious in Study I. The reduced range of motion in the knee and ankle joints noted in some patients in Studies II and III is mainly attributed to the fracture type.

One general objection against using the IL technique is the view that patient compliance is not satisfactory. Despite the importance of the patients' experience when evaluating a treatment, this has rarely been done. The self-appraisal scores used in the studies on which this thesis is based showed that treatment with the IL, including the "clumsy" frame, was well tolerated.

As a result of differences in bone morphology, due to the patient's age, gender and ethnic origin [438], it is not possible to use a uniformly designed implant in every individual patient. However, in this context, the IL represents a versatile alternative.

In several textbooks hybrid fixators with proximal rings are recommended in comminuted proximal metaphyseal fractures (Schatzker type V and VI). In Study II, it was possible to show that both Schatzker type I-IV and Schatzker type V-VI fractures could be treated with results similar to those with ORIF. It was also possible for the IL patients to start immediate weight-bearing without jeopardising the fracture stability or the healing, which is not normally recommended when using hybrid fixators.

Because of the high risk of soft-tissue injuries in distal metaphyseal fractures, especially if comminuted and intra-articular, a staged protocol is recommended. The results in study III clearly indicate that this is not necessary if treatment with the IL is chosen.

Even though the IL is burdened with a high frequency of superficial pin infections, the problem is limited, apparently without a negative impact in terms of the patients' self-appraisal and clinical outcome.

The indications for the removal of implants are not clear and this surgical procedure is not free from complications, such as sensorial nerve injury, neurovascular injury, re-fractures or the recurrence of the deformity. Persistent pain after radiographic evidence of fracture union commonly leads to implant removal, even though this does not guarantee complete pain relief [439]. In cases of non-union, malunion, infection, peri-implant failure and pre-arthroplasty surgery, the removal of earlier implants is often necessary as a part

of revision with new implants. The operating surgeon therefore needs a profound knowledge not only of the techniques for implant fixation but also of removing stripped or broken hardware. Equipment with the correct instruments to expedite this demanding procedure and skilful experience are needed [440]. Contrary to this, the removal of the IL is a part of the procedure and is easy to perform.

Economically, the removal of osteosynthesis implants is one of the most common elective orthopaedic procedures in the industrial countries [441]. In the USA, 5% of all orthopaedic procedures involve hardware removal [442]. The workload caused by routine removals of internal fracture implants was analysed during a seven-year period in a large Finnish university orthopaedic and trauma unit (where no removal policy existed). The removals accounted for 29% of all elective operations and for 15% of all operations at the department. The corresponding nationwide figure was 6.3% of all orthopaedic operations in Finland [443]. Sanderson et al. reported that the complication rate related to the removal of tibial implants was 23% [444].

Today, the term “Ilizarov method” refers to something more than circular external fixation with wires. It instead represents a whole concept of fracture treatment [445]. Even if this method is associated with some different technical difficulties when compared with other techniques, it is wise to recall what Alho et al. pointed out during the introduction of the IM [446]. This might also apply to the IL.

“The operative treatment of tibial fractures is demanding, but, as in other fields of modern orthopaedics, technical difficulties should not deter the surgeon from using a method which gives superior results. The operative technique must be meticulously performed by adequately trained surgeons, and the cases must be carefully selected for each type of treatment.”

15 GENERAL CONCLUSIONS

The results of this thesis indicate that the IL, compared with IM, provides at least as good and in some respects a better clinical outcome in the treatment of tibial fractures. The major complications and re-operation rates were significantly lower for the IL and the outcome in terms of function and HRQoL were favourable.

The IL has the advantage that, independently of fracture pattern, it is possible to operate on all patients without delay. In the metaphyseal fractures, this can be done without staged protocols. We were thus, able to avoid disturbing the healing process with soft-tissue interventions that might delay rehabilitation, thereby guaranteeing faster rehabilitation.

Even if the gait analysis indicated that patient compliance with weight-bearing was reduced, it is possible to start immediate unrestricted weight-bearing using the IL independent of the grade of the fracture, without any risk of jeopardising the stability of the construction, clinical or functional results.

The surgical time did not differ from other conventional techniques.

15.1 Clinical relevance

External fixators in general have often been viewed as temporary devices mostly suitable in emergency situations, like mass disaster and war, which should be removed as soon as possible when other treatment forms are available. There are, however, several external fixators that are effective when used as definitive methods of tibial fracture care. When choosing an external fixator, the IL is rarely the first choice in the emergency situation, as the application is considered cumbersome by many colleagues. However, a stripped-down version of the IL can be used in the acute setting to provide temporary stability and it can then subsequently be incorporated in a definitive frame construction. Delaying definitive mechanical stabilisation even appears to have a positive biological benefit on callus formation and fracture healing [447].

The use of the IL for the routine treatment of fractures enables surgeons to obtain enough technical skill to treat more demanding fractures or other

pathologies with this method, when this technique is preferable. The clinical relevance of this thesis is that IL treatment can be used as routine in tibial fractures and the clinical outcome is similar to that for internal osteosynthesis.

In overall terms, the most important finding in this thesis might be that it was possible to treat different types of tibial fracture with the IL with a low risk and similar results compared with more invasive methods. The fact that the majority of the fractures healed indicates that sufficient stability in the fixation was achieved without permanent implants.

With pressure insoles, like the medilogic[®] insole system, used in the present study, it was possible to monitor the fracture healing and detect different “rehabilitation patterns”. The results indicate that this type of gait analysis might be a useful adjunct when monitoring the rehabilitation process after tibial fractures.

15.2 Future implications

Limb reconstruction procedures with the IL might become a vital part of trauma and orthopaedic treatment and care in the future. The results of the studies in this thesis are satisfactory and they can therefore be used as a starting point for further studies of fracture treatment in other localisations according to the Ilizarov technique. Another reason for including the IL in daily fracture care is its versatility and it should therefore not only be reserved to a few specialised centres. The high frequency of complex fractures of the proximal and distal metaphyseal tibia at relatively small hospitals emphasises the fact that a basic knowledge of these applications is important for orthopaedic surgeons responsible for the treatment of trauma.

The treatment of dislocated tibial fractures might benefit from an individualised approach in which the selection of the surgical method should be planned based on the patient’s age, functional demands and risk profile. At the same time, the results of recent studies are interpreted differently around the world in certain institutions and health-care systems, thereby resulting in obvious obstacles.

As introducing a “new” technique always means that the surgeon has to both change his mindset and acquire new skills, there is always some obstruction in the current health-care system. An uncertain “fear of the unknown” has definitely influenced the introduction of the IL in Sweden, as well as in the rest of the western world. As there is also interest in the application of the IL method not only in fracture care but also in other reconstructive surgery, it is

desirable to organise the treatment within a multidisciplinary team including nurses, physiotherapists and occupational therapists. This approach has showed profound benefits in terms of effective rehabilitation [448, 449].

One common complaint about the IL is the difficulty involved in applying the frame. This argument must be placed in the general context of surgical procedures. With appropriate education, like any other technique, the IL is fully applicable for a novice user.

To summarise, I believe that the classical IL should be employed more in the daily practice of fracture care. Obviously, there are still a number of issues to resolve. In my opinion, the following questions need to be answered regarding the treatment of tibial fractures in patients with the IL.

- As the scarcity of health-care resources has become an unavoidable reality, it is necessary not only to study the clinical outcomes of the IL, but also to conduct an economic analysis of the management strategies. What is the economic burden when the IL is the chosen method in terms of the costs of the emergency treatment until healing?
- In the acute setting, should the IL full frame be applied immediately, or is it better and more efficient to apply a scaled-down fixator during the acute phase, which could then be converted to a full frame in more advantageous conditions?
- Should the fixator be used alone or should it be combined with internal fixation?
- Should the fixator always be used until the bone is healed, or are there circumstances in which it would be better to replace it with a cast or internal fixation?
- Which is the best equipment to treat tibial fractures in daily practice, the traditional IL or the hexapod fixator?
- How should the optimal teaching of the IL technique be organised?
- Should the technique only be used by specialised teams or should it be a part of the basic knowledge for trauma orthopaedic surgeons?

- Which other fracture types could be expected to be suitable for the IL and which of those are frequent enough to make it practically possible to study them in randomised or observational studies?
- Which are the optimal clinical, radiological and functional tests and/or scores when studying fracture healing and rehabilitation?

Based on decades of continuous development of tibial implants and techniques used in fracture management, which we currently have at our disposal, future innovation will probably not involve new implant designs, but a biological device or drug that enhances the healing potential of fractures would be the paramount and, in the long-term, most important aspect of treatment. In this context, the future might belong to minimally invasive therapies allowing alignment of the fracture fragments and provisional fracture fixation enhancing the healing process.

ACKNOWLEDGEMENTS

I would like to thank everyone who has helped me to complete this work and particularly:

HELENA BRISBY, Professor, MD, PhD, Head of the Orthopaedic Department at Sahlgrenska University Hospital in Gothenburg, Sweden, for her encouragement.

LARS NISTOR, MD, PhD, my main supervisor, mentor, tutor and co-author, who was always available during all these years and who gave me this opportunity with his never-ending enthusiasm and philanthropy, and for sharing his excellent scientific knowledge.

JÓN KARLSSON, Professor, MD, PhD, my co-supervisor and co-author. During most of the time I was working on this thesis, he was Head of the Orthopaedic Department at the Sahlgrenska Academy in Gothenburg, Sweden. From the beginning, he recognised the potential and encouraged me to start this work and over the years he has been an invaluable support and guide.

BENGT I. ERIKSSON, Professor, MD, PhD, my co-supervisor and co-author and valuable adviser with many suggestions. Over the years, he has become a dear friend and also a devoted supporter of the Ilizarov technique.

CARL EKHOLM, Associate Professor, MD, PhD, co-author in Study II, who contributed to a broader discussion about the rationale of using the IL in proximal metaphyseal fractures.

ROY TRANBERG, Certified Prosthetist and Orthotist, co-author in Study IV, who patiently contributed his knowledge with precious details about gait complexity.

TOM REETZ, chartered engineer for medical technology, co-author in Study IV, who helped us with his know-how of the insole systems and in understanding the harmony of walking.

KATARINA HJÄLTMAN, Certified Prosthetist and Orthotist, for her accurate work during all the gait analysis tests and also as a co-author in Study IV.

ANNA-LENA EMANUELSSON LOFT, research secretary at the Research Fund at Skaraborg Hospital, for her kind assistance during the thesis lay-out.

ANNA-LENA WETTERTEG, physiotherapist at Skaraborg Hospital, who help to assess the patients included in the studies at the one-year follow-up.

CAROLINE HATTEVIG, physiotherapist at Skaraborg Hospital, in Skövde, Sweden, who patiently assessed the patients included in the studies at the one-year follow-up.

CATRIN OLOFSSON, professional communicator at Skaraborg Hospital in Skövde, Sweden, who supervised the design of the thesis.

MALGORZATA SOJA, MD, for her expert help with the roentgenologic assessment.

PATRIK LEIDEFORS, Certified Prosthetist and Orthotist, for his accurate work during all the gait analysis tests.

PETER JOHANSSON, photographer at Skaraborg Hospital in Skövde, Sweden for doing some nice photos include in this work.

SALMIR NÁSIC, biostatistician at the Research Fund at Skaraborg Hospital, Sweden, for his inestimably kind professional help with statistical analyses of the data in all the studies.

ULRIKA PARKER, nurse at Skaraborg Hospital in Skövde, Sweden, who collected and checked the post-operative analgesia pumps of all the patients included in the studies.

MARINA MODIN, RN and Master of Science, who has analysed the Ilizarov method applied to some patients from Studies II and III in the light of the qualitative approach.

AGNETHA LINDÉN, chief-secretary at the Orthopaedic Department, Skaraborg Hospital, in Skövde, Sweden, who administered all the financial documents relating to the studies.

EWA AVERLAND, secretary at the Orthopaedic Department, Skaraborg Hospital, in Skövde, Sweden, who diligently guaranteed that the patients included in the studies were scheduled according to the study protocol.

JEANETTE KLIGER, for patiently making excellent English language revisions.

LINDA JOHANSSON, administrator, at the Sahlgrenska Academy, for outstanding administrative guidance.

NUNO CRAVEIRO LOPES, friend and president of the ILLRS, who played a decisive part in the development of my technical skills.

MY COLLEAGUES at the Department of Orthopaedics, Skaraborg Hospital in Skövde, Sweden.

ALL THE OPERATING STAFF at Skaraborg Hospital in Skövde, Sweden, for their professionalism and support from the very beginning.

ALL THE STAFF at the outpatient clinic and patient wards at the Department of Orthopaedics at Skaraborg Hospital in Skövde, for their good work in patient care.

THE GRAN CANARIA RESEARCH GROUP, for good company and inspiration which made this journey a delightful adventure under the sun of research.

THE RUSSIAN ILIZAROV SCIENTIFIC CENTRE FOR RESTORATIVE TRAUMATOLOGY AND ORTHOPAEDICS in Kurgan, Russian Federation, for the exhaustive and warm fellowship which was very animated in every sense!

THE ASAMI, for its amazing experience and source of inspiration demonstrated during all these years at the congresses I attended.

Financial support was obtained from:

**THE RESEARCH FUND AT SKARABORG HOSPITAL
THE SKARABORG RESEARCH AND DEVELOPMENT COUNCIL
THE SKARABORG INSTITUTE OF RESEARCH AND DEVELOPMENT**

ROBERT WIGGINTON, Smith & Nephew Company, in Dallas, USA. In 1999 and 2000, he kindly helped me with logistical support when I visited Kurgan.

Eternal thanks to my family my wife, **Ulrika**, my sons, **Marco, Filipe** and **Hugo**.

REFERENCES

1. Woolf AD, Pfleger B: **Burden of major musculoskeletal conditions.** *Bulletin of the World Health Organization* 2003, **81**(9):646-656.
2. Kaye JA, Jick H: **Epidemiology of lower limb fractures in general practice in the United Kingdom.** *Journal of the International Society for Child and Adolescent Injury Prevention* 2004, **10**(6):368-374.
3. Zhang Y (ed.): **Clinical Epidemiology of Orthopedic Trauma.** Stuttgart, Germany: Georg Thieme Verlag KG; 2012.
4. Bengner U, Ekblom T, Johnell O, Nilsson BE: **Incidence of femoral and tibial shaft fractures. Epidemiology 1950-1983 in Malmö, Sweden.** *Acta Orthopaedica Scandinavica* 1990, **61**(3):251-254.
5. Emami A, Mjoberg B, Ragnarsson B, Larsson S: **Changing epidemiology of tibial shaft fractures. 513 cases compared between 1971-1975 and 1986-1990.** *Acta Orthopaedica Scandinavica* 1996, **67**(6):557-561.
6. Weiss RJ, Montgomery SM, Ehlin A, Al Dabbagh Z, Stark A, Jansson KA: **Decreasing incidence of tibial shaft fractures between 1998 and 2004: information based on 10,627 Swedish inpatients.** *Acta Orthopaedica* 2008, **79**(4):526-533.
7. Court-Brown CM, McBirnie J: **The epidemiology of tibial fractures.** *The Journal of Bone and Joint Surgery British volume* 1995, **77**(3):417-421.
8. Frakturregistret S: **Årsrapport för 2011 och 2012.**edn Gothenburg 2013: Möller M, Ekholm C, Sandelin A, Akrami L. ISSN 2001-2276. URL: www.frakturregistret.se.
9. Court-Brown CM, Caesar B: **Epidemiology of adult fractures: A review.** *Injury* 2006, **37**(8):691-697.
10. Court-Brown CM, Rimmer S, Prakash U, McQueen MM: **The epidemiology of open long bone fractures.** *Injury* 1998, **29**(7):529-534.
11. Bourne RB: **Pylon fractures of the distal tibia.** *Clinical Orthopaedics and Related Research* 1989(240):42-46.
12. Praemer A, Furner S, Rice DP: **Musculoskeletal conditions in the United States**, 1st edition edn. Park Ridge, Illinois: American Academy of Orthopaedic Surgeons (Park Ridge, Ill.); 1992.
13. (AHRQ) HCUP: **Introduction to the HCUP state inpatient databases (SID). Online Manual.** In.: US Agency for Healthcare Research and Quality (AHRQ).
14. Smith GE: **The Most Ancient Splints.** *British Medical Journal* 1908, **1**(2465):732-736 732.
15. Peltier LF: **Fractures: A History and Iconography of Their Treatment**, II edition, San Francisco: Norman Publishing; 1999.

16. Monro JK: **The history of plaster-of-Paris.** *The British Journal of Surgery* 1936, **23**:257-266.
17. LeVay D: **History of Orthopedics.** New York: Parthenon Publishing Group; 1990.
18. Carter CB, Norton MG: **Ceramic Materials.Science and Engineering,** II edition, New York: Springer Verlag; 2013.
19. Mathijssen A: **Der Gyps-Verband und seine Anwendung bei Knochenbrüchen.** Crefeld: Gustav Kühler; 1857.
20. Pigorov N: **Grundzuge der allgemeinen Kriegschirurgie.** Leipzig: Verlag Vogel; 1864.
21. Krause F: **Beitrage zur Behandlung der Knochenbruche der unteren Gliedmassen im Umhergehen.** *Deutsche Medizinische Wochenschrift* 1891, **13**:457.
22. Delbet P: **Method de traitement des fractures.** *Annales de la Clinique Chirurgicale* 1916:5.
23. Apley AG: **Fractures of the lateral tibial condyle treated by skeletal traction and early mobilisation; a review of sixty cases with special reference to the long-term results.** *The Journal of Bone and Joint Surgery British volume* 1956, **38-B(3)**:699-708.
24. Scotland T, Wardlaw D: **The use of cast-bracing as treatment for fractures of the tibial plateau.** *The Journal of Bone and Joint Surgery British volume* 1981, **63B(4)**:575-578.
25. Anglen JO, Healy WL: **Tibial plateau fractures.** *Orthopedics* 1988, **11(11)**:1527-1534.
26. Jensen DB, Rude C, Duus B, Bjerg-Nielsen A: **Tibial plateau fractures. A comparison of conservative and surgical treatment.** *The Journal of Bone and Joint Surgery British volume* 1990, **72(1)**:49-52.
27. Nicoll EA: **Fractures of the Tibial Shaft. a Survey of 705 Cases.** *The Journal of Bone and Joint Surgery British volume* 1964, **46**:373-387.
28. Sarmiento A: **A functional below-the-knee cast for tibial fractures.** *The Journal of Bone and Joint Surgery American volume* 1967, **49(5)**:855-875.
29. Sarmiento A: **A functional below-the-knee brace for tibial fractures: a report on its use in one hundred and thirty-five cases. 1970.** *The Journal of Bone and Joint Surgery American volume* 2007, **89 Suppl 2 Pt.2**:157-169.
30. Sarmiento A, Gersten LM, Sobol PA, Shankwiler JA, Vangsness CT: **Tibial shaft fractures treated with functional braces. Experience with 780 fractures.** *The Journal of Bone and Joint Surgery British volume* 1989, **71(4)**:602-609.
31. Austin RT: **The Sarmiento tibial plaster: a prospective study of 145 fractures.** *Injury* 1981, **13(1)**:10-22.

32. Chapman MW: **The use of external fixators in the management of tibial shaft fractures.** In: *Chapman's Orthopaedic Surgery. Volume I*, edn. Edited by Chapman MW. Philadelphia: Lippincot Williams & Wilkins; 2001: 755-810.
33. Zelle BA, Bhandari M, Espiritu M, Koval KJ, Zlowodzki M: **Treatment of distal tibia fractures without articular involvement: a systematic review of 1125 fractures.** *Journal of Orthopaedic Trauma* 2006, **20**(1):76-79.
34. Othman M, Strzelczyk P: **Results of conservative treatment of "pilon" fractures.** *Ortopedia, Traumatologia, Rehabilitacja* 2003, **5**(6):787-794.
35. Sarmiento A, Latta LL: **450 closed fractures of the distal third of the tibia treated with a functional brace.** *Clinical Orthopaedics and Related Research* 2004,(428):261-271.
36. Hansmann C: **Eine neue Methode der Fixierung der Fragmente bei komplizierten Frakturen.** *Verhandlungen der Deutschen Gesellschaft für Chirurgie* 1886, **15**:134.
37. Lane WA: **Some remarks on the treatment of fractures.** *British Medical Journal* 1895, **1**:861-863.
38. Martin E: **The open treatment of fractures.** *Surgery, Gynecology& Obstetrics* 1906, **3**:258-271.
39. Steinbach LW: **On the use of fixation plates in the treatment of fractures of the leg.** *Annals of Surgery* 1900, **31**:436-442.
40. Lambotte A: **Technique et indication des prothèses dans le traitement des fractures.** *Presse Médicale* 1909, **17**:231.
41. Eggers GW: **Internal contact splint.** *The Journal of Bone and Joint Surgery American volume* 1948, **30A**(1):40-52.
42. Danis R: **Théorie et pratique de l'osteosynthèse.** Paris: Masson; 1949.
43. Müller ME, Allgöwer M, Schneider R, Willenegger H: **Manual der Osteosynthesen AO-Technik.** Berlin: Springer Verlag; 1977.
44. Müller ME, Allgöwer M, Willenegger H: **Compression fixation with plates.** In: *Technique of Internal Fixation of Fractures.* edn. Springer Verlag Berlin; 1965: 47-51.
45. Perren SM, Russenberger M, Steinemann S, Muller ME, Allgöwer M: **A dynamic compression plate.** *Acta Orthopaedica Scandinavica Supplementum* 1969, **125**:31-41.
46. Perren SM: **The concept of biological plating using the limited contact-dynamic compression plate (LC-DCP). Scientific background, design and application.** *Injury* 1991, **22 Suppl 1**:1-41.
47. Gautier E, Perren SM: **Die limited contact dynamic compression plate (LC-DCP): Biomechanische Forschung als Grundlage des neuen Plattendesigns.** *Der Orthopäde* 1992, **21**:11-23.
48. Field JR, Hearn TC, Caldwell CB: **Bone plate fixation: an evaluation of interface contact area and force of the dynamic compression**

- plate (DCP) and the limited contact-dynamic compression plate (LC-DCP) applied to cadaveric bone. *Journal of Orthopaedic Trauma* 1997, **11**(5):368-373.**
49. Ahmad M, Nanda R, Bajwa AS, Candal-Couto J, Green S, Hui AC: **Biomechanical testing of the locking compression plate: when does the distance between bone and implant significantly reduce construct stability?** *Injury* 2007, **38**(3):358-364.
50. Farouk O, Krettek C, Miclau T, Schandelmaier P, Guy P, Tschernke H: **Minimally invasive plate osteosynthesis: does percutaneous plating disrupt femoral blood supply less than the traditional technique?** *Journal of Orthopaedic Trauma* 1999, **13**(6):401-406.
51. Jain R, Podworny N, Hupel TM, Weinberg J, Schemitsch EH: **Influence of plate design on cortical bone perfusion and fracture healing in canine segmental tibial fractures.** *Journal of Orthopaedic Trauma* 1999, **13**(3):178-186.
52. Zhang L, Bail H, Mittlmeier T, Haas NP, Schaser KD: **Immediate microcirculatory derangements in skeletal muscle and periosteum after closed tibial fracture.** *The Journal of Trauma* 2003, **54**(5):979-985.
53. Schmutz B, Wullschlegel ME, Kim H, Noser H, Schutz MA: **Fit assessment of anatomic plates for the distal medial tibia.** *Journal of Orthopaedic Trauma* 2008, **22**(4):258-263.
54. Perren SM: **Evolution of the internal fixation of long bone fractures. The scientific basis of biological internal fixation: choosing a new balance between stability and biology.** *The Journal of Bone and Joint Surgery British volume* 2002, **84**(8):1093-1110.
55. Uthoff HK, Poitras P, Backman DS: **Internal plate fixation of fractures: short history and recent developments.** *Journal of Orthopaedic Science* 2006, **11**(2):118-126.
56. Qiu XS, Yuan H, Zheng X, Wang JF, Xiong J, Chen YX: **Locking plate as a definitive external fixator for treating tibial fractures with compromised soft tissue envelop.** *Archives of Orthopaedic and Trauma Surgery* 2014, **134**(3):383-388.
57. Schutz M, Sudkamp NP: **Revolution in plate osteosynthesis: new internal fixator systems.** *Journal of Orthopaedic Science* 2003, **8**(2):252-258.
58. Anglen J, Kyle RF, Marsh JL, Virkus WW, Watters WC, 3rd, Keith MW, Turkelson CM, Wies JL, Boyer KM: **Locking plates for extremity fractures.** *The Journal of the American Academy of Orthopaedic Surgeons* 2009, **17**(7):465-472.
59. Ronga M, Shanmugam C, Longo UG, Oliva F, Maffulli N: **Minimally invasive osteosynthesis of distal tibial fractures using locking plates.** *The Orthopedic Clinics of North America* 2009, **40**(4):499-504, ix.

60. Jockel JA, Erhardt J, Vincenti M, Reissig J, Hoffmann R, Husain B, Tager G, Partenheimer A, Lill H, Gebhard F *et al*: **Minimally invasive and open surgical treatment of proximal tibia fractures using a polyaxial locking plate system: a prospective multi-centre study.** *International Orthopaedics* 2013, **37**(4):701-708.
61. Bhandari M, Guyatt GH, Swiontkowski MF, Schemitsch EH: **Treatment of open fractures of the shaft of the tibia.** *The Journal of Bone and Joint Surgery British volume* 2001, **83**(1):62-68.
62. Zou J, Zhang W, Zhang CQ: **Comparison of minimally invasive percutaneous plate osteosynthesis with open reduction and internal fixation for treatment of extra-articular distal tibia fractures.** *Injury* 2013, **44**(8):1102-1106.
63. Bastias C, Henriquez H, M. P, Rammelt S, Cuchacovich N, Lagos L, Carcuro G: **Are locking plates better than non-locking plates for treating distal tibial fractures?** *Foot and Ankle Surgery* 2014.
64. Deangelis JP, Deangelis NA, Anderson R: **Anatomy of the superficial peroneal nerve in relation to fixation of tibia fractures with the less invasive stabilization system.** *Journal of Orthopaedic Trauma* 2004, **18**(8):536-539.
65. Strauss EJ, Alfonso D, Kummer FJ, Egol KA, Tejwani NC: **The effect of concurrent fibular fracture on the fixation of distal tibia fractures: a laboratory comparison of intramedullary nails with locked plates.** *Journal of Orthopaedic Trauma* 2007, **21**(3):172-177.
66. Torrero I, Aroles F: **Effect of intramedullary nails in tibial shaft fractures as a factor raised intra-compartmental pressures. A clinical study.** *The Journal of Bone and Joint Surgery British volume* 2011, **93-B**(Supp II):105-106.
67. Tischenko GJ, Goodman SB: **Compartment syndrome after intramedullary nailing of the tibia.** *The Journal of Bone and Joint Surgery American volume* 1990, **72**(1):41-44.
68. Nassif JM, Gorczyca JT, Cole JK, Pugh KJ, Pienkowski D: **Effect of acute reamed versus unreamed intramedullary nailing on compartment pressure when treating closed tibial shaft fractures: a randomized prospective study.** *Journal of Orthopaedic Trauma* 2000, **14**(8):554-558.
69. McQueen MM, Christie J, Court-Brown CM: **Compartment pressures after intramedullary nailing of the tibia.** *The Journal of Bone and Joint Surgery British volume* 1990, **72**(3):395-397.
70. Bircher H: **Eine neue Methode unmittelbar Retention bei Frakturen der Rohrenknochen.** *Archiv für Klinische Chirurgie* 1887, **34**:410-422.
71. Schöne G: **Zur Behandlung von Vorderarmfrakturen mit Bolzung.** *Münchener Medizinische Wochenschrift* 1913, **60**:2327-2328.

72. Hej-Groves E: **On the application of the principle of extension to comminuted fractures of long bones, with special reference to gunshot injuries.** *British Journal of Surgery* 1915, 2:429.
73. Rush LV, Rush HL: **A reconstructive operation for comminuted fractures of the upper third of ulna.** *American Journal of Surgery* 1937, 38:332.
74. Küntscher G: **Die Marknagelung von Knochenbrüchen.** *Klinische Wochenschrift* 1940, 19:6.
75. Küntscher G: **Die Stabile Osteosynthese.** *Deutsche Zeitschrift für Chirurgie* 1951:1951.
76. Klemm K: **Begründete Indikationen für den Verriegelungsnagel.** *Hefte Unfallheilk* 1977, 129:84.
77. Kempf I, Grosse A, Beck G: **Closed locked intramedullary nailing. Its application to comminuted fractures of the femur.** *The Journal of Bone and Joint Surgery American volume* 1985, 67(5):709-720.
78. Pape HC, Remmers D, Regel G, Tscherne H: **[Pulmonary complications following intramedullary stabilization of long bones. Effect of surgical procedure, time and injury pattern].** *Der Orthopäde* 1995, 24(2):164-172.
79. Wenda K, Runkel M, Degreif J, Ritter G: **Pathogenesis and clinical relevance of bone marrow embolism in medullary nailing--demonstrated by intraoperative echocardiography.** *Injury* 1993, 24 Suppl 3:S73-81.
80. Baumgart F, Kohler G, Ochsner PE: **The physics of heat generation during reaming of the medullary cavity.** *Injury* 1998, 29 Suppl 2:B11-25.
81. Ochsner PE, Baumgart F, Kohler G: **Heat-induced segmental necrosis after reaming of one humeral and two tibial fractures with a narrow medullary canal.** *Injury* 1998, 29 Suppl 2:B1-10.
82. Klein MP, Rahn BA, Frigg R, Kessler S, Perren SM: **Reaming versus non-reaming in medullary nailing: interference with cortical circulation of the canine tibia.** *Archives of Orthopaedic and Trauma Surgery* 1990, 109(6):314-316.
83. Melcher GA, Metzendorf A, Schlegel U, Ziegler WJ, Perren SM, Printzen G: **Influence of reaming versus nonreaming in intramedullary nailing on local infection rate: experimental investigation in rabbits.** *The Journal of Trauma* 1995, 39(6):1123-1128.
84. Schemitsch EH, Kowalski MJ, Swiontkowski MF, Harrington RM: **Comparison of the effect of reamed and unreamed locked intramedullary nailing on blood flow in the callus and strength of union following fracture of the sheep tibia.** *Journal of Orthopaedic Research* 1995, 13(3):382-389.

85. Reikeras O, Skjeldal S, Groggaard B: **Mechanical effects of intramedullary reaming in pinned osteotomies in rats.** *Journal of Orthopaedic Trauma* 1989, **3**(1):53-56.
86. Bong MR, Kummer FJ, Koval KJ, Egol KA: **Intramedullary nailing of the lower extremity: biomechanics and biology.** *The Journal of the American Academy of Orthopaedic Surgeons* 2007, **15**(2):97-106.
87. Gomez-Benito MJ, Fornells P, Garcia-Aznar JM, Seral B, Seral-Innigo F, Doblare M: **Computational comparison of reamed versus unreamed intramedullary tibial nails.** *Journal of Orthopaedic Research* 2007, **25**(2):191-200.
88. Fairbank AC, Thomas D, Cunningham B, Curtis M, Jinnah RH: **Stability of reamed and unreamed intramedullary tibial nails: a biomechanical study.** *Injury* 1995, **26**(7):483-485.
89. Bhandari M, Guyatt G, Tornetta P, 3rd, Schemitsch EH, Swiontkowski M, Sanders D, Walter SD: **Randomized trial of reamed and unreamed intramedullary nailing of tibial shaft fractures.** *The Journal of Bone and Joint Surgery American volume* 2008, **90**(12):2567-2578.
90. Busse JW, Bhandari M, Sprague S, Johnson-Masotti AP, Gafni A: **An economic analysis of management strategies for closed and open grade I tibial shaft fractures.** *Acta Orthopaedica* 2005, **76**(5):705-712.
91. Lam SW, Teraa M, Leenen LP, van der Heijden GJ: **Systematic review shows lowered risk of nonunion after reamed nailing in patients with closed tibial shaft fractures.** *Injury* 2010, **41**(7):671-675.
92. Xia L, Zhou J, Zhang Y, Mei G, Jin D: **A Meta-analysis of Reamed Versus Unreamed Intramedullary Nailing for the Treatment of Closed Tibial Fractures.** *Orthopedics* 2014, **37**(4):e332-338.
93. Young H, Topliss C: **Complications associated with the use of a titanium tibial nail.** *Injury* 2007, **38**(2):223-226.
94. Cannada LK, Anglen JO, Archdeacon MT, Herscovici D, Jr., Ostrum RF: **Avoiding complications in the care of fractures of the tibia.** *The Journal of Bone and Joint Surgery American volume* 2008, **90**(8):1760-1768.
95. Krause PC, Whatley AN, Mautner JF: **A technique for nailing severely shortened and displaced tibia fractures.** *Journal of Orthopaedic Trauma* 2008, **22**(2):138-141.
96. Kim KC, Lee JK, Hwang DS, Yang JY, Kim YM: **Tibial unreamed intramedullary nailing using schanz screws in displaced diaphyseal segmental fractures.** *Orthopedics* 2007, **30**(11):906-908.
97. Safran O, Liebergall M, Segal D, Mosheiff R: **Proximal tibial fractures—should we nail them?** *American Journal of Orthopedics* 2001, **30**(9):681-684.

98. Lang GJ, Cohen BE, Bosse MJ, Kellam JF: **Proximal third tibial shaft fractures. Should they be nailed?** *Clinical Orthopaedics and Related Research* 1995(315):64-74.
99. Nork SE, Barei DP, Schildhauer TA, Agel J, Holt SK, Schrick JL, Sangeorzan BJ: **Intramedullary nailing of proximal quarter tibial fractures.** *Journal of Orthopaedic Trauma* 2006, **20**(8):523-528.
100. Galbraith JG, O'Leary DP, Dailey HL, Kennedy TE, Mitra A, Harty JA: **Preoperative estimation of tibial nail length--because size does matter.** *Injury* 2012, **43**(11):1962-1968.
101. Lefavre KA, Guy P, Chan H, Blachut PA: **Long-term follow-up of tibial shaft fractures treated with intramedullary nailing.** *Journal of Orthopaedic Trauma* 2008, **22**(8):525-529.
102. Strecker W, Suger G, Kinzl L: **[Local complications of intramedullary nailing].** *Der Orthopäde* 1996, **25**(3):274-291.
103. Koval KJ, Clapper MF, Brumback RJ, Ellison PS, Jr., Poka A, Bathon GH, Burgess AR: **Complications of reamed intramedullary nailing of the tibia.** *Journal of Orthopaedic Trauma* 1991, **5**(2):184-189.
104. Väistö O: **Intramedullary nailing of tibial shaft fractures - with special attention given to anterior knee pain.** Tampere, Finland: University of Tampere, Finland; 2011.
105. Young S, Lie SA, Hallan G, Zirkle LG, Engesaeter LB, Havelin LI: **Risk factors for infection after 46,113 intramedullary nail operations in low- and middle-income countries.** *World Journal of Surgery* 2013, **37**(2):349-355.
106. Bhandari M, Guyatt GH, Swiontkowski MF, Tornetta P, 3rd, Hanson B, Weaver B, Sprague S, Schemitsch EH: **Surgeons' preferences for the operative treatment of fractures of the tibial shaft. An international survey.** *The Journal of Bone and Joint Surgery American volume* 2001, **83-A**(11):1746-1752.
107. Karladani AH, Granhed H, Edshage B, Jerre R, Styf J: **Displaced tibial shaft fractures: a prospective randomized study of closed intramedullary nailing versus cast treatment in 53 patients.** *Acta Orthopaedica Scandinavica* 2000, **71**(2):160-167.
108. Toivanen JA, Hirvonen M, Auvinen O, Honkonen SE, Jarvinen TL, Koivisto AM, Jarvinen MJ: **Cast treatment and intramedullary locking nailing for simple and spiral wedge tibial shaft fractures--a cost benefit analysis.** *Annales Chirurgiae et Gynaecologiae* 2000, **89**(2):138-142.
109. Hooper GJ, Keddell RG, Penny ID: **Conservative management or closed nailing for tibial shaft fractures. A randomised prospective trial.** *The Journal of Bone and Joint Surgery British volume* 1991, **73**(1):83-85.
110. Dogra AS, Ruiz AL, Thompson NS, Nolan PC: **Dia-metaphyseal distal tibial fractures--treatment with a shortened intramedullary nail: a review of 15 cases.** *Injury* 2000, **31**(10):799-804.

111. Tyllianakis M, Megas P, Giannikas D, Lambiris E: **Interlocking intramedullary nailing in distal tibial fractures.** *Orthopedics* 2000, **23**(8):805-808.
112. Mosheiff R, Safran O, Segal D, Liebergall M: **The unreamed tibial nail in the treatment of distal metaphyseal fractures.** *Injury* 1999, **30**(2):83-90.
113. Konrath G, Moed BR, Watson JT, Kaneshiro S, Karges DE, Cramer KE: **Intramedullary nailing of unstable diaphyseal fractures of the tibia with distal intraarticular involvement.** *Journal of Orthopaedic Trauma* 1997, **11**(3):200-205.
114. Robinson CM, McLauchlan G, Christie J, McQueen MM, Court-Brown CM: **Tibial fractures with bone loss treated by primary reamed intramedullary nailing.** *The Journal of Bone and Joint Surgery British volume* 1995, **77**(6):906-913.
115. Janssen KW, Biert J, van Kampen A: **Treatment of distal tibial fractures: plate versus nail: a retrospective outcome analysis of matched pairs of patients.** *International Orthopaedics* 2007, **31**(5):709-714.
116. Lindvall E, Sanders R, Dipasquale T, Herscovici D, Haidukewych G, Sagi C: **Intramedullary nailing versus percutaneous locked plating of extra-articular proximal tibial fractures: comparison of 56 cases.** *Journal of Orthopaedic Trauma* 2009, **23**(7):485-492.
117. Iqbal HJ, Pidikiti P: **Treatment of distal tibia metaphyseal fractures; plating versus intramedullary nailing: a systematic review of recent evidence.** *Foot and Ankle Surgery* 2013, **19**(3):143-147.
118. Adams F: **Works of Hippocrates.** Baltimore: Williams & Wilkins; 1939.
119. Malgaigne J: **Treatise on fractures.** Philadelphia: Lippincott; 1859.
120. Cooper S: **Treatment of fractured patella by Malgaigne's Hooks.** *San Francisco Médicale Preses* 1861, **2**(5):13:16.
121. Parkhill C: **A new apparatus for the fixation of bones after a resection and in fractures with a tendency to displacement.** *Transactions of the American Surgical Association* 1897, **15**:251.
122. Lambotte A: **L'intervention opératoire dans les fractures récentes et anciennes envisagée particulièrement au point de vue de l'ostéosynthèse avec la description de plusieurs techniques nouvelles.** Brussels: Lamertin; 1907.
123. Anderson R: **An automatic method of treatment for fracture of the tibia and the fibula.** *Surgery, Gynecology & Obstetrics* 1934, **58**:639.
124. Stader O: **A preliminary announcement of a new method of treating fractures.** *North American Veterinary* 1937, **18**(37).
125. Hoffman R: **Rotules a'os por la reduction dirigée non sanglante, de fractures (osteotaxis).** *Helvetica Medica Acta* 1938, **844**.

126. Rosenthal RE, MacPhail JA, Oritz JE: **Non-union in open tibial fractures.** *The Journal of Bone and Joint Surgery American volume* 1977, **59(2)**:244-248.
127. Johnston R, Stovall S: **External fixation of fractures.** *Journal of Bone Joint Surgery* 1950, **32-A**:466.
128. Jaskulka RA, Egkher E, Wielke B: **Comparison of the mechanical performance of three types of unilateral, dynamizable external fixators. An experimental study.** *Archives of Orthopaedic and Trauma Surgery* 1994, **113(5)**:271-275.
129. Asche G, Roth W, Schroeder L: **Hystory/Introduction.** In: *The External Fixator Standard indications, operating instructions and examples of frame configurations.* edn. Edn E-P. Reinbeck, Germany: Einhorn-Pressse Verlag; 2002: 223.
130. Schwechter EM, Swan KG: **Raoul Hoffmann and his external fixator.** *The Journal of Bone and Joint Surgery American volume* 2007, **89(3)**:672-678.
131. De Bastiani G, Aldegheri R, Renzi Brivio L: **Dynamic axial fixation. A rational alternative for the external fixation of fractures.** *International Orthopaedics* 1986, **10(2)**:95-99.
132. De Bastiani G, Aldegheri R, Renzi Brivio L: **The treatment of fractures with a dynamic axial fixator.** *The Journal of Bone and Joint Surgery British volume* 1984, **66(4)**:538-545.
133. Hammer RR, Rooser B, Lidman D, Smeds S: **Simplified external fixation for primary management of severe musculoskeletal injuries under war and peace time conditions.** *Journal of Orthopaedic Trauma* 1996, **10(8)**:545-554.
134. Monticelli G, Spinelli R: **Leg lengthening by closed metaphyseal corticotomy.** *Italian Journal of Orthopaedics and Traumatology* 1983, **9(2)**:139-150.
135. Helland P, Boe A, Molster AO, Solheim E, Hordvik M: **Open tibial fractures treated with the Ex-fi-re external fixation system.** *Clinical Orthopaedics and Related Research* 1996,(326):209-220.
136. Anderson L, W. H: **Fractures of the tibia and fibula treaed with casts and transfixing pins.** *Southern Medical Journal* 1966, **59**:1026.
137. Claes L, Heitemeyer U, Krischak G, Braun H, Hierholzer G: **Fixation technique influences osteogenesis of comminuted fractures.** *Clinical Orthopaedics and Related Research* 1999, (365):221-229.
138. Jagodzinski M, Krettek C: **Effect of mechanical stability on fracture healing--an update.** *Injury* 2007, **38 Suppl 1**:S3-10.
139. Smith SR, Bronk JT, Kelly PJ: **Regional fracture site blood flow following compression plate intramedullary rod and external fixation.** In: *Bone Circulation and Bone Necrosis.* edn. Arlet J, Mazieres B. Springer-Verlag Berlin Heidelberg 1990, 179-184.
140. Lewallen DG, Chao EY, Kasman RA, Kelly PJ: **Comparison of the effects of compression plates and external fixators on early bone-**

- healing. *The Journal of Bone and Joint Surgery American volume* 1984, **66**(7):1084-1091.
141. Apel PJ, Crane D, Northam CN, Callahan M, Smith TL, Teasdall RD: **Effect of selective sensory denervation on fracture-healing: an experimental study of rats.** *The Journal of Bone and Joint Surgery American volume* 2009, **91**(12):2886-2895.
142. Ryder S, Gorczyca JT: **Routine removal of external fixators without anesthesia.** *Journal of Orthopaedic Trauma* 2007, **21**(8):571-573.
143. Sung JK, Levin R, Siegel J, Einhorn TA, Creevy WR, Tornetta P, 3rd: **Reuse of external fixation components: a randomized trial.** *Journal of Orthopaedic Trauma* 2008, **22**(2):126-130; discussion 130-121.
144. Dirschl DR, Smith IJ: **Reuse of external skeletal fixator components: effects on costs and complications.** *The Journal of Trauma* 1998, **44**(5):855-858.
145. Green SA: **Complications of external skeletal fixation.** *Clinical Orthopaedics and Related Research* 1983(180):109-116.
146. Dahl AW, Toksvig-Larsen S: **Pin site care in external fixation sodium chloride or chlorhexidine solution as a cleansing agent.** *Archives of Orthopaedic and Trauma Surgery* 2004, **124**:555-558.
147. Grant AD, Atar D, Lehman WB: **Pin care using the Ilizarov apparatus: recommended treatment plan in Kurgan, Russia.** *Bulletin* 1992, **52**(1):18-20.
148. Slomka R: **Complications of ring fixators in the foot and ankle.** *Clinical Orthopaedics and Related Research* 2001,(391):115-122.
149. Schwartzman V, Choi SH, Schwartzman R: **Tibial nonunions. Treatment tactics with the Ilizarov method.** *The Orthopedic Clinics of North America* 1990, **21**(4):639-653.
150. Hawkins BJ, Langerman RJ, Anger DM, Calhoun JH: **The Ilizarov technique in ankle fusion.** *Clinical Orthopaedics and Related Research* 1994, (303):217-225.
151. Grant AD, Atar D, Lehman WB: **The Ilizarov technique in correction of complex foot deformities.** *Clinical Orthopaedics and Related Research* 1992,(280):94-103.
152. Behrens F: **General theory and principles of external fixation.** *Clinical Orthopaedics and Related Research* 1989,(241):15-23.
153. Klapp F: **Precursors of the Ilizarov technique.** *Injury* 1993, **24 Suppl 2**:S25-28.
154. Ilizarov GA: **The tension-stress effect on the genesis and growth of tissues. Part I. The influence of stability of fixation and soft-tissue preservation.** *Clinical Orthopaedics and Related Research* 1989, (238):249-281.
155. Ilizarov GA (ed.): **Transosseous osteosynthesis**, I edition. Berlin, Heidelberg, New York: Springer Verlag; 1992.

156. Ilizarov GA: **Clinical application of the tension-stress effect for limb lengthening.** *Clinical Orthopaedics and Related Research* 1990, (250):8-26.
157. Solomin L (ed.): **The basic principles of external fixation using the Ilizarov device.** Milan, Berlin, Heidelberg, New York: Springer Verlag; 2008.
158. Catagni MA, Malzev V, Kirienko A: **Advances in Ilizarov Apparatus Assembly: fractures treatment, pseudarthroses, lengthening, deformity correction.** Milan Medicalplast SRL; 1994.
159. Catagni M: **Atlas for the insertion of transosseous wires and half-pins.** Milan: Medicalplastic srl; 2002.
160. Hutson JJ, Jr.: **Applications of Ilizarov fixators to fractures of tibia: a practical guide.** *Techniques in Orthopaedics* 2002, 17(1):1-111.
161. Watson MA, Mathias KJ, Maffulli N: **External ring fixators: an overview.** *Proceedings of the Institution of Mechanical Engineers Part H, Journal of engineering in medicine* 2000, 214(5):459-470.
162. Sarmiento A, Schaeffer JF, Beckerman L, Latta LL, Enis JE: **Fracture healing in rat femora as affected by functional weight-bearing.** *The Journal of Bone and Joint Surgery American volume* 1977, 59(3):369-375.
163. Claes L, Augat P, Schorlemmer S, Konrads C, Ignatius A, Ehrnthaller C: **Temporary distraction and compression of a diaphyseal osteotomy accelerates bone healing.** *Journal of Orthopaedic Research* 2008, 26(6):772-777.
164. Aronson J, Harp JH: **Mechanical forces as predictors of healing during tibial lengthening by distraction osteogenesis.** *Clinical Orthopaedics and Related Research* 1994, (301):73-79.
165. Kenwright J, Richardson JB, Cunningham JL, White SH, Goodship AE, Adams MA, Magnussen PA, Newman JH: **Axial movement and tibial fractures. A controlled randomised trial of treatment.** *The Journal of Bone and Joint Surgery British volume* 1991, 73(4):654-659.
166. Fleming B, Paley D, Kristiansen T, Pope M: **A biomechanical analysis of the Ilizarov external fixator.** *Clinical Orthopaedics and Related Research* 1989,(241):95-105.
167. Goodship AE, Kenwright J: **The influence of induced micromovement upon the healing of experimental tibial fractures.** *The Journal of Bone and Joint Surgery British volume* 1985, 67(4):650-655.
168. Goldstein RY, Jordan CJ, McLaurin TM, Grant A: **The evolution of the Ilizarov technique: part 2: the principles of distraction osteosynthesis.** *Bulletin of the Hospital for Joint Disease* 2013, 71(1):96-103.
169. Klein P, Schell H, Streitparth F, Heller M, Kassi JP, Kandziora F, Bragulla H, Haas NP, Duda GN: **The initial phase of fracture**

- healing is specifically sensitive to mechanical conditions. *Journal of Orthopaedic Research* 2003, **21**(4):662-669.
170. Sarmiento A, McKellop HA, Llinas A, Park SH, Lu B, Stetson W, Rao R: **Effect of loading and fracture motions on diaphyseal tibial fractures.** *Journal of Orthopaedic Research* 1996, **14**(1):80-84.
171. Juan JA, Prat J, Vera P, Hoyos JV, Sanchez-Lacuesta J, Peris JL, Dejoz R, Alepuz R: **Biomechanical consequences of callus development in Hoffmann, Wagner, Orthofix and Ilizarov external fixators.** *Journal of Biomechanics* 1992, **25**(9):995-1006.
172. Gasser B, Boman B, Wyder D, Schneider E: **Stiffness characteristics of the circular Ilizarov device as opposed to conventional external fixators.** *Journal of Biomechanical Engineering* 1990, **112**(1):15-21.
173. Sarpel Y, Gulsen M, Togrul E, Capa M, Herdem M: **Comparison of mechanical performance among different frame configurations of the Ilizarov external fixator: experimental study.** *The Journal of Trauma* 2005, **58**(3):546-552.
174. Hillard PJ, Harrison AJ, Atkins RM: **The yielding of tensioned fine wires in the Ilizarov frame.** *Proceedings of the Institution of Mechanical Engineers Part H, Journal of Engineering in Medicine* 1998, **212**(1):37-47.
175. Aronson J, Johnson E, Harp JH: **Local bone transportation for treatment of intercalary defects by the Ilizarov technique. Biomechanical and clinical considerations.** *Clinical Orthopaedics and Related Research* 1989,(243):71-79.
176. Aronson J, Harrison B, Boyd CM, Cannon DJ, Lubansky HJ: **Mechanical induction of osteogenesis: the importance of pin rigidity.** *Journal of Pediatric Orthopedics* 1988, **8**(4):396-401.
177. Mullins MM, Davidson AW, Goodier D, Barry M: **The biomechanics of wire fixation in the Ilizarov system.** *Injury* 2003, **34**(2):155-157.
178. Aronson J, Harp JH, Jr.: **Mechanical considerations in using tensioned wires in a transosseous external fixation system.** *Clinical Orthopaedics and Related Research* 1992, (280):23-29.
179. Bronson DG, Samchukov ML, Birch JG, Browne RH, Ashman RB: **Stability of external circular fixation: a multi-variable biomechanical analysis.** *Clinical Biomechanics* 1998, **13**(6):441-448.
180. Gardner TN, Evans M, Hardy J, Kenwright J: **Is the stability of a tibial fracture influenced by the type of unilateral external fixator?** *Clinical Biomechanics* 1998, **13**(8):603-607.
181. Gardner TN, Evans M, Kenwright J: **A biomechanical study on five unilateral external fracture fixation devices.** *Clinical Biomechanics* 1997, **12**(2):87-96.
182. Lewis DD, Bronson DG, Samchukov ML, Welch RD, Stallings JT: **Biomechanics of circular external skeletal fixation.** *Veterinary Surgery : VS* 1998, **27**(5):454-464.

183. Podolsky A, Chao EY: **Mechanical performance of Ilizarov circular external fixators in comparison with other external fixators.** *Clinical Orthopaedics and Related Research* 1993, (293):61-70.
184. Paley D, Fleming B, Catagni M, Kristiansen T, Pope M: **Mechanical evaluation of external fixators used in limb lengthening.** *Clinical Orthopaedics and Related Research* 1990, (250):50-57.
185. Aro HT, Markel MD, Chao EY: **Cortical bone reactions at the interface of external fixation half-pins under different loading conditions.** *The Journal of Trauma* 1993, **35**(5):776-785.
186. Board TN, Yang L, Saleh M: **Why fine-wire fixators work: an analysis of pressure distribution at the wire-bone interface.** *Journal of Biomechanics* 2007, **40**(1):20-25.
187. Aquarius R, Van Kampen A, Verdonschot N: **Rapid pre-tension loss in the Ilizarov external fixator: an in vitro study.** *Acta orthopaedica* 2007, **78**(5):654-660.
188. Caja V, Kim W, Larsson S, E YC: **Comparison of the mechanical performance of three types of external fixators: linear, circular and hybrid.** *Clinical Biomechanics* 1995, **10**(8):401-406.
189. Hasenboehler E, Smith WR, Laudicina L, Philips GC, Stahel PF, Morgan SJ: **Fatigue behavior of Ilizarov frame versus tibial interlocking nail in a comminuted tibial fracture model: a biomechanical study.** *Journal of Orthopaedic Surgery* 2006, **1**:16.
190. Boenisch UW, de Boer PG, Journeaux SF: **Unreamed intramedullary tibial nailing--fatigue of locking bolts.** *Injury* 1996, **27**(4):265-270.
191. Zarutsky E, Rush SM, Schuberth JM: **The use of circular wire external fixation in the treatment of salvage ankle arthrodesis.** *The Journal of Foot and Ankle Surgery* 2005, **44**(1):22-31.
192. Kummer FJ: **Biomechanics of the Ilizarov external fixator.** *Clinical Orthopaedics and Related Research* 1992(280):11-14.
193. Hoffmann R, McKellop HA, Sarmiento A, Lu B, Ebramzadeh E: **[Three-dimensional measurement of fracture gap motion. Biomechanical study of experimental tibial fractures with anterior clasp fixator and ring fixator].** *Der Unfallchirurg* 1991, **94**(8):395-400.
194. Yilmaz E, Belhan O, Karakurt L, Arslan N, Serin E: **Mechanical performance of hybrid Ilizarov external fixator in comparison with Ilizarov circular external fixator.** *Clinical Biomechanics* 2003, **18**(6):518-522.
195. Voor M, Antoci V, Kam B, Roberts C: **Hybrid external fixation of proximal tibia fractures: biomechanical analysis of four commercial systems.** *Orthopedics* 2007, **30**(12):1033-1038.
196. Pugh KJ, Wolinsky PR, Dawson JM, Stahlman GC: **The biomechanics of hybrid external fixation.** *Journal of Orthopaedic Trauma* 1999, **13**(1):20-26.

197. Khalily C, Voor MJ, Seligson D: **Fracture site motion with Ilizarov and "hybrid" external fixation.** *Journal of Orthopaedic Trauma* 1998, **12**(1):21-26.
198. Gessmann J, Jettkant B, Schildhauer TA, Seybold D: **Mechanical stress on tensioned wires at direct and indirect loading: a biomechanical study on the Ilizarov external fixator.** *Injury* 2011, **42**(10):1107-1111.
199. Paley D: **Biomechanics of the Ilizarov external fixator.** In: *Operative principles of Ilizarov: fracture treatment, nonunion, osteomyelitis, lengthening, deformity correction.* edn. Edn J. B-MAA. Baltimore: Williams & Wilkins; 1991: 33-41.
200. Aarnes GT, Steen H, Ludvigsen P, Waanders NA, Huiskes R, Goldstein SA: **In vivo assessment of regenerate axial stiffness in distraction osteogenesis.** *Journal of Orthopaedic Research* 2005, **23**(2):494-498.
201. Paley D: **History and Science Behind the Six-Axis Correction External Fixation Devices in Orthopaedic Surgery.** *Operative Techniques in Orthopaedics* 2011, **21**(2):125-128.
202. Binski J: **Taylor Spatial Frame in Acute Fracture Care.** *Techniques in Orthopaedics* 2002, **17**(2):173-184.
203. Menakaya C, Hadland Y, Barron E, Sharma H: **Fracture healing in tibial fractures: Ilizarov versus Taylor Spatial Frame.** *The Bone & Joint Journal* 2013, **95-B**(Supp 7):18.
204. Kristiansen LP, Steen H, Reikeras O: **No difference in tibial lengthening index by use of Taylor spatial frame or Ilizarov external fixator.** *Acta Orthopaedica* 2006, **77**(5):772-777.
205. Dammerer D, Kirschbichler K, Donnan L, Kaufmann G, Krismer M, Biedermann R: **Clinical value of the Taylor Spatial Frame: a comparison with the Ilizarov and Orthofix fixators.** *Journal of Children's Orthopaedics* 2011, **5**(5):343-349.
206. Elbatrawy Y, Fayed M: **Deformity correction with an external fixator: ease of use and accuracy?** *Orthopedics* 2009, **32**(2):82.
207. Seide K, Wolter D: **[Universal 3-dimensional correction and reposition with the ring fixator using the hexapod configuration].** *Der Unfallchirurg* 1996, **99**(6):422-424.
208. Gulsen M, Oto M, Ozcan C, Ozturk H, Demilrap B, Basbozkurt M: **Adam frame: technique of computer aided ring fixator with navigatiopn software.** In: *II world congress on external fixation and bone reconstruction societies, XI brazilian congress of ASAMI.* São Salvador, Brazil; 2012.
209. Gulsen M, Demilrap B, Ayas M, Ozturk H, Marangoz, Oto M: **New approach to the external fixators: quadrilateral octopod adam frame.** In: *ASAMI 2012: 2012; Thalossoiniki;* 2012.
210. Meling T, Harboe K, Soreide K: **Incidence of traumatic long-bone fractures requiring in-hospital management: a prospective age-**

- and gender-specific analysis of 4890 fractures.** *Injury* 2009, **40**(11):1212-1219.
211. Khalily C, Behnke S, Seligson D: **Treatment of closed tibia shaft fractures: a survey from the 1997 Orthopaedic Trauma Association and Osteosynthesis International--Gerhard Kuntscher Kreis meeting.** *Journal of Orthopaedic Trauma* 2000, **14**(8):577-581.
212. Bhandari M, Guyatt GH, Tornetta P, 3rd, Swiontkowski MF, Hanson B, Sprague S, Syed A, Schemitsch EH: **Current practice in the intramedullary nailing of tibial shaft fractures: an international survey.** *The Journal of Trauma* 2002, **53**(4):725-732.
213. Kooistra BW, Sprague S, Bhandari M, Schemitsch EH: **Outcomes assessment in fracture healing trials: a primer.** *Journal of Orthopaedic Trauma* 2010, **24 Suppl 1**:S71-75.
214. Müller M (ed.): **The comprehensive classification of fractures of long bones.** New York: Springer Verlag; 1990.
215. Schatzker J, McBroom R, Bruce D: **The tibial plateau fracture. The Toronto experience 1968--1975.** *Clinical Orthopaedics and Related Research* 1979, (138):94-104.
216. Ruedi TP, Allgower M: **The operative treatment of intra-articular fractures of the lower end of the tibia.** *Clinical Orthopaedics and Related Research* 1979, (138):105-110.
217. Gustilo RB, Mendoza RM, Williams DN: **Problems in the management of type III (severe) open fractures: a new classification of type III open fractures.** *The Journal of Trauma* 1984, **24**(8):742-746.
218. Gustilo RB, Anderson JT: **Prevention of infection in the treatment of one thousand and twenty-five open fractures of long bones: retrospective and prospective analyses.** *The Journal of Bone and Joint Surgery American volume* 1976, **58**(4):453-458.
219. Tscherne H, Oestern HJ: **Pathophysiology and classification of soft tissue injuries associated with fractures.** In: *Fractures with soft tissue injuries.* Tscherne H. GL. Berlin: Springer Verlag; 1984: 1-9.
220. Maher AB, Salmond SW, Pellino TA: **Orthopaedic Nursing**, III edn. London: Saunders Company; 2002.
221. Thomas JW, Guire KE, Horvat GG: **Is patient length of stay related to quality of care?** *Hospital & Health Services Administration* 1997, **42**(4):489-507.
222. Wiklund I, Romanus B, Hunt SM: **Self-assessed disability in patients with arthrosis of the hip joint. Reliability of the Swedish version of the Nottingham Health Profile.** *International Disability Studies* 1988, **10**(4):159-163.
223. Hunt SM, McEwen J: **The development of a subjective health indicator.** *Sociology of Health & Illness* 1980, **2**(3):231-246.

224. Brooks R: **EuroQol: the current state of play.** *Health Policy* 1996, **37**(1):53-72.
225. Roos EM, Roos HP, Lohmander LS, Ekdahl C, Beynnon BD: **Knee Injury and Osteoarthritis Outcome Score (KOOS)--development of a self-administered outcome measure.** *The Journal of Orthopaedic and Sports Physical Therapy* 1998, **28**(2):88-96.
226. Roos EM, Brandsson S, Karlsson J: **Validation of the foot and ankle outcome score for ankle ligament reconstruction.** *Foot & Ankle International / American Orthopaedic Foot and Ankle Society [and] Swiss Foot and Ankle Society* 2001, **22**(10):788-794.
227. Rasmussen PS: **Tibial condylar fractures. Impairment of knee joint stability as an indication for surgical treatment.** *The Journal of Bone and Joint Surgery American volume* 1973, **55**(7):1331-1350.
228. Burwell HN, Charnley AD: **The treatment of displaced fractures at the ankle by rigid internal fixation and early joint movement.** *The Journal of Bone and Joint Surgery British volume* 1965, **47**(4):634-660.
229. Checketts R, Otterburn M, Mac Eachern A: **Pin track infection; definition, incidence and prevention.** *International Journal Orthopaedic Trauma* 2003, **3**(3):16-18.
230. Roos EM: **Outcome after anterior cruciate ligament reconstruction--a comparison of patients' and surgeons' assessments.** *Scandinavian Journal of Medicine & Science in Sports* 2001, **11**(5):287-291.
231. Roos EM, Ostenberg A, Roos H, Ekdahl C, Lohmander LS: **Long-term outcome of meniscectomy: symptoms, function, and performance tests in patients with or without radiographic osteoarthritis compared to matched controls.** *Osteoarthritis and Cartilage / OARS, Osteoarthritis Research Society* 2001, **9**(4):316-324.
232. Roos EM, Roos HP, Ekdahl C, Lohmander LS: **Knee injury and Osteoarthritis Outcome Score (KOOS)--validation of a Swedish version.** *Scandinavian Journal of Medicine & Science in Sports* 1998, **8**(6):439-448.
233. Malik MH, Harwood P, Diggle P, Khan SA: **Factors affecting rates of infection and nonunion in intramedullary nailing.** *The Journal of Bone and Joint Surgery British volume* 2004, **86**(4):556-560.
234. Colman M, Wright A, Gruen G, Siska P, Pape HC, Tarkin I: **Prolonged operative time increases infection rate in tibial plateau fractures.** *Injury* 2012.
235. Ma CH, Yu SW, Tu YK, Yen CY, Yeh JJ, Wu CH: **Staged external and internal locked plating for open distal tibial fractures.** *Acta Orthopaedica* 2010, **81**(3):382-386.

236. Dirschl DR, Del Gaizo D: **Staged management of tibial plateau fractures.** *American Journal of Orthopedics* 2007, **36**(4 Suppl):12-17.
237. Egol KA, Tejwani NC, Capla EL, Wolinsky PL, Koval KJ: **Staged management of high-energy proximal tibia fractures (OTA types 41): the results of a prospective, standardized protocol.** *Journal of Orthopaedic Trauma* 2005, **19**(7):448-455; discussion 456.
238. Tejwani NC, Achan P: **Staged management of high-energy proximal tibia fractures.** *Bulletin* 2004, **62**(1-2):62-66.
239. Lee JA, Papadakis SA, Moon C, Zalavras CG: **Tibial plateau fractures treated with the less invasive stabilisation system.** *International Orthopaedics* 2007, **31**(3):415-418.
240. Savolainen VT, Pajarinen J, Hirvensalo E, Lindahl J: **Hybrid external fixation in treatment of proximal tibial fractures: a good outcome in AO/ASIF type-C fractures.** *Archives of Orthopaedic and Trauma Surgery* 2010, **130**(7):897-901.
241. **Open reduction and internal fixation compared with circular fixator application for bicondylar tibial plateau fractures. Results of a multicenter, prospective, randomized clinical trial.** *The Journal of Bone and Joint Surgery American volume* 2006, **88**(12):2613-2623.
242. Guo JJ, Tang N, Yang HL, Tang TS: **A prospective, randomised trial comparing closed intramedullary nailing with percutaneous plating in the treatment of distal metaphyseal fractures of the tibia.** *The Journal of Bone and Joint Surgery British volume* 2010, **92**(7):984-988.
243. Im GI, Tae SK: **Distal metaphyseal fractures of tibia: a prospective randomized trial of closed reduction and intramedullary nail versus open reduction and plate and screws fixation.** *The Journal of Trauma* 2005, **59**(5):1219-1223; discussion 1223.
244. Borghans I, Kleefstra SM, Kool RB, Westert GP: **Is the length of stay in hospital correlated with patient satisfaction?** *International Journal for Quality in Health Care / ISQua* 2012, **24**(5):443-451.
245. Dijkman BG, Sprague S, Schemitsch EH, Bhandari M: **When is a fracture healed? Radiographic and clinical criteria revisited.** *Journal of Orthopaedic Trauma* 2010, **24** Suppl 1:S76-80.
246. Kooistra BW, Dijkman BG, Busse JW, Sprague S, Schemitsch EH, Bhandari M: **The radiographic union scale in tibial fractures: reliability and validity.** *Journal of Orthopaedic Trauma* 2010, **24** Suppl 1:S81-86.
247. Frolke JP, Patka P: **Definition and classification of fracture non-unions.** *Injury* 2007, **38** Suppl 2:S19-22.
248. Hammer RR, Hammerby S, Lindholm B: **Accuracy of radiologic assessment of tibial shaft fracture union in humans.** *Clinical Orthopaedics and Related Research* 1985, (199):233-238.

249. McClelland D, Thomas PB, Bancroft G, Moorcraft CI: **Fracture healing assessment comparing stiffness measurements using radiographs.** *Clinical Orthopaedics and Related Research* 2007, **457**:214-219.
250. Claes L, Grass R, Schmickal T, Kisse B, Eggers C, Gerngross H, Mutschler W, Arand M, Wintermeyer T, Wentzensen A: **Monitoring and healing analysis of 100 tibial shaft fractures.** *Langenbeck's Archives of Surgery / Deutsche Gesellschaft für Chirurgie* 2002, **387**(3-4):146-152.
251. Corrales LA, Morshed S, Bhandari M, Miclau T, 3rd: **Variability in the assessment of fracture-healing in orthopaedic trauma studies.** *The Journal of Bone and Joint Surgery American volume* 2008, **90**(9):1862-1868.
252. Davis BJ, Roberts PJ, Moorcroft CI, Brown MF, Thomas PB, Wade RH: **Reliability of radiographs in defining union of internally fixed fractures.** *Injury* 2004, **35**(6):557-561.
253. Babatunde OM, Fragomen AT, Rozbruch SR: **Noninvasive quantitative assessment of bone healing after distraction osteogenesis.** *The Musculoskeletal Journal of Hospital for Special Surgery* 2010, **6**(1):71-78.
254. Pountos I, Georgouli T, Pneumáticos S, Giannoudis PV: **Fracture non-union: Can biomarkers predict outcome?** *Injury* 2013, **44**(12):1725-1732.
255. Zimmermann G, Müller U, Wentzensen A: **The value of laboratory and imaging studies in the evaluation of long-bone non-unions.** *Injury* 2007, **38 Suppl 2**:S33-37.
256. Castillo RC, Bosse MJ, MacKenzie EJ, Patterson BM: **Impact of smoking on fracture healing and risk of complications in limb-threatening open tibia fractures.** *Journal of Orthopaedic Trauma* 2005, **19**(3):151-157.
257. Harvey EJ, Agel J, Selznick HS, Chapman JR, Henley MB: **Deleterious effect of smoking on healing of open tibia-shaft fractures.** *American Journal of Orthopedics* 2002, **31**(9):518-521.
258. Adams CI, Keating JF, Court-Brown CM: **Cigarette smoking and open tibial fractures.** *Injury* 2001, **32**(1):61-65.
259. Schmitz MA, Finnegan M, Natarajan R, Champine J: **Effect of smoking on tibial shaft fracture healing.** *Clinical Orthopaedics and Related Research* 1999, (365):184-200.
260. Kyro A, Usenius JP, Aarnio M, Kunnamo I, Avikainen V: **Are smokers a risk group for delayed healing of tibial shaft fractures?** *Annales Chirurgiae et Gynaecologiae* 1993, **82**(4):254-262.
261. Scolaro JA, Schenker ML, Yannascoli S, Baldwin K, Mehta S, Ahn J: **Cigarette smoking increases complications following fracture: a systematic review.** *The Journal of Bone and Joint Surgery American volume* 2014, **96**(8):674-681.

262. Bhandari M, Guyatt GH, Swiontkowski MF, Tornetta P, 3rd, Sprague S, Schemitsch EH: **A lack of consensus in the assessment of fracture healing among orthopaedic surgeons.** *Journal of Orthopaedic Trauma* 2002, **16**(8):562-566.
263. Boutron I, Tubach F, Giraudeau B, Ravaud P: **Blinding was judged more difficult to achieve and maintain in nonpharmacologic than pharmacologic trials.** *Journal of Clinical Epidemiology* 2004, **57**(6):543-550.
264. Whelan DB, Bhandari M, McKee MD, Guyatt GH, Kreder HJ, Stephen D, Schemitsch EH: **Interobserver and intraobserver variation in the assessment of the healing of tibial fractures after intramedullary fixation.** *The Journal of Bone and Joint Surgery British volume* 2002, **84**(1):15-18.
265. Sarmiento A, Burkhalter WE, Latta LL: **Functional bracing in the treatment of delayed union and nonunion of the tibia.** *International Orthopaedics* 2003, **27**(1):26-29.
266. Karladani AH, Granhed H, Karrholm J, Styf J: **The influence of fracture etiology and type on fracture healing: a review of 104 consecutive tibial shaft fractures.** *Archives of Orthopaedic and Trauma Surgery* 2001, **121**(6):325-328.
267. Coles CP, Gross M: **Closed tibial shaft fractures: management and treatment complications. A review of the prospective literature.** *Canadian Journal of Surgery/Journal Canadien de Chirurgie* 2000, **43**(4):256-262.
268. Antonova E, Le TK, Burge R, Mershon J: **Tibia shaft fractures: costly burden of nonunions.** *BMC Musculoskeletal Disorders* 2013, **14**:42.
269. Heckman JD, Sarasohn-Kahn J: **The economics of treating tibia fractures. The cost of delayed unions.** *Bulletin* 1997, **56**(1):63-72.
270. Brinker MR, Hanus BD, Sen M, O'Connor DP: **The devastating effects of tibial nonunion on health-related quality of life.** *The Journal of Bone and Joint Surgery American volume* 2013, **95**(24):2170-2176.
271. Connolly JF, Guse R, Tiedeman J, Dehne R: **Autologous marrow injection as a substitute for operative grafting of tibial nonunions.** *Clinical Orthopaedics and Related Research* 1991(266):259-270.
272. Zlowodzki M, Obremskey WT, Thomison JB, Kregor PJ: **Functional outcome after treatment of lower-extremity nonunions.** *The Journal of Trauma* 2005, **58**(2):312-317.
273. Tzioupis C, Giannoudis PV: **Prevalence of long-bone non-unions.** *Injury* 2007, **38 Suppl 2**:S3-9.
274. Phieffer LS, Goulet JA: **Delayed unions of the tibia.** *The Journal of Bone and Joint Surgery American volume* 2006, **88**(1):206-216.
275. Fong K, Truong V, Foote CJ, Petrisor B, Williams D, Ristevski B, Sprague S, Bhandari M: **Predictors of nonunion and reoperation in**

- patients with fractures of the tibia: an observational study. *BMC Musculoskeletal Disorders* 2013, **14**:103.
276. Larsen LB, Madsen JE, Hoiness PR, Ovre S: **Should insertion of intramedullary nails for tibial fractures be with or without reaming? A prospective, randomized study with 3.8 years' follow-up.** *Journal of Orthopaedic Trauma* 2004, **18**(3):144-149.
277. Court-Brown CM, McQueen MM: **High success rate with exchange nailing to treat tibial shaft aseptic nonunion.** *Journal of Orthopaedic Trauma* 1999, **13**(4):274.
278. Levin PE: **Exchange reamed intramedullary nailing for delayed union and nonunion of the tibia.** *Clinical Orthopaedics and Related Research* 1996(332):304-305.
279. Court-Brown CM, Keating JF, Christie J, McQueen MM: **Exchange intramedullary nailing. Its use in aseptic tibial nonunion.** *The Journal of Bone and Joint Surgery British volume* 1995, **77**(3):407-411.
280. Templeman D, Thomas M, Varecka T, Kyle R: **Exchange reamed intramedullary nailing for delayed union and nonunion of the tibia.** *Clinical Orthopaedics and Related Research* 1995, (315):169-175.
281. Toro-Arbelaez JB, Gardner MJ, Shindle MK, Cabas JM, Lorich DG, Helfet DL: **Open reduction and internal fixation of intraarticular tibial plateau nonunions.** *Injury* 2007, **38**(3):378-383.
282. Schatzker J, Schulak DJ: **Pseudarthrosis of a tibial plateau fracture: report of a case.** *Clinical Orthopaedics and Related Research* 1979, (145):146-149.
283. Ristiniemi J, Flinkkila T, Hyvonen P, Lakovaara M, Pakarinen H, Biancari F, Jalovaara P: **Two-ring hybrid external fixation of distal tibial fractures: a review of 47 cases.** *The Journal of Trauma* 2007, **62**(1):174-183.
284. Bacon S, Smith WR, Morgan SJ, Hasenboehler E, Philips G, Williams A, Ziran BH, Stahel PF: **A retrospective analysis of comminuted intra-articular fractures of the tibial plafond: Open reduction and internal fixation versus external Ilizarov fixation.** *Injury* 2008, **39**(2):196-202.
285. Sahtarker H, Gillson SC, Stolero J, Kaushansky A, Volpin G: **Ilizarov external fixator as an alternative treatment for tibial shaft fractures in adolescents.** *Journal Bone Joint Surgery Br* 2002, **84-B**(Supp III):305.
286. Papagelopoulos PJ, Partsinevelos AA, Themistocleous GS, Mavrogenis AF, Korres DS, Soucacos PN: **Complications after tibia plateau fracture surgery.** *Injury* 2006, **37**(6):475-484.
287. Gaston P, Will EM, Keating JF: **Recovery of knee function following fracture of the tibial plateau.** *The Journal of Bone and Joint Surgery British volume* 2005, **87**(9):1233-1236.

288. Dendrinios GK, Kontos S, Katsenis D, Dalas A: **Treatment of high-energy tibial plateau fractures by the Ilizarov circular fixator.** *The Journal of Bone and Joint Surgery British volume* 1996, **78(5)**:710-717.
289. Mikulak SA, Gold SM, Zinar DM: **Small wire external fixation of high energy tibial plateau fractures.** *Clinical Orthopaedics and Related Research* 1998, (356):230-238.
290. Joveniaux P, Ohl X, Harisboure A, Berrichi A, Labatut L, Simon P, Mainard D, Vix N, Dehoux E: **Distal tibia fractures: management and complications of 101 cases.** *International Orthopaedics* 2010, **34(4)**:583-588.
291. Aranzulla PJ, Muckle DS, Cunningham JL: **A portable monitoring system for measuring weight-bearing during tibial fracture healing.** *Medical Engineering & Physics* 1998, **20(7)**:543-548.
292. Kershaw CJ, Cunningham JL, Kenwright J: **Tibial external fixation, weight bearing, and fracture movement.** *Clinical Orthopaedics and Related Research* 1993, (293):28-36.
293. Joslin CC, Eastaugh-Waring SJ, Hardy JR, Cunningham JL: **Weight bearing after tibial fracture as a guide to healing.** *Clinical Biomechanics* 2008, **23(3)**:329-333.
294. Macri F, Marques LF, Backer RC, Santos MJ, Belangero WD: **Validation of a standardised gait score to predict the healing of tibial fractures.** *The Journal of Bone and Joint Surgery British volume* 2012, **94(4)**:544-548.
295. Archer KR, Castillo RC, Mackenzie EJ, Bosse MJ: **Gait symmetry and walking speed analysis following lower-extremity trauma.** *Physical Therapy* 2006, **86(12)**:1630-1640.
296. Cunningham JL, Evans M, Kenwright J: **Measurement of fracture movement in patients treated with unilateral external skeletal fixation.** *Journal of Biomedical Engineering* 1989, **11(2)**:118-122.
297. Schemitsch EH, Bhandari M, Guyatt G, Sanders DW, Swiontkowski M, Tornetta P, Walter SD, Zdero R, Goslings JC, Teague D *et al*: **Prognostic factors for predicting outcomes after intramedullary nailing of the tibia.** *The Journal of Bone and Joint Surgery American volume* 2012, **94(19)**:1786-1793.
298. Augat P, Penzkofer R, Nolte A, Maier M, Panzer S, v Oldenburg G, Poeschl K, Simon U, Buhren V: **Interfragmentary movement in diaphyseal tibia fractures fixed with locked intramedullary nails.** *Journal of Orthopaedic Trauma* 2008, **22(1)**:30-36.
299. Zarek S, Othman M, Macias J: **The Ilizarov method in the treatment of pilon fractures.** *Ortopedia, Traumatologia, Rehabilitacja* 2002, **4(4)**:427-433.
300. Jansen H, Fenwick A, Doht S, Frey S, Meffert R: **Clinical outcome and changes in gait pattern after pilon fractures.** *International Orthopaedics* 2013, **37(1)**:51-58.

301. Hustedt JW, Blizzard DJ, Baumgaertner MR, Leslie MP, Grauer JN: **Is it possible to train patients to limit weight bearing on a lower extremity?** *Orthopedics* 2012, **35**(1):e31-37.
302. Hurkmans HL, Bussmann JB, Selles RW, Benda E, Stam HJ, Verhaar JA: **The difference between actual and prescribed weight bearing of total hip patients with a trochanteric osteotomy: long-term vertical force measurements inside and outside the hospital.** *Archives of Physical Medicine and Rehabilitation* 2007, **88**(2):200-206.
303. Warren CG, Lehmann JF: **Training procedures and biofeedback methods to achieve controlled partial weight bearing: an assessment.** *Archives of Physical Medicine and Rehabilitation* 1975, **56**(10):449-455.
304. Dingwell JB, Cusamo JP, Cavanagh PR, Sternad D: **Local dynamic stability versus kinematic variability of continuous overground and treadmill walking.** *Journal of Biomechanical Engineering* 2001, **123**:27-32.
305. Freedman EL, Johnson EE: **Radiographic analysis of tibial fracture malalignment following intramedullary nailing.** *Clinical Orthopaedics and Related Research* 1995, (315):25-33.
306. Milner SA, Davis TR, Muir KR, Greenwood DC, Doherty M: **Long-term outcome after tibial shaft fracture: is malunion important?** *The Journal of Bone and Joint Surgery American volume* 2002, **84-A**(6):971-980.
307. Kristensen KD, Kiaer T, Blicher J: **No arthrosis of the ankle 20 years after malaligned tibial-shaft fracture.** *Acta Orthopaedica Scandinavica* 1989, **60**(2):208-209.
308. Kettelkamp DB, Hillberry BM, Murrish DE, Heck DA: **Degenerative arthritis of the knee secondary to fracture malunion.** *Clinical Orthopaedics and Related Research* 1988, (234):159-169.
309. Parkkinen M, Madanat R, Mustonen A, Koskinen SK, Paavola M, Lindahl J: **Factors predicting the development of early osteoarthritis following lateral tibial plateau fractures Mid-term clinical and radiographic outcomes of 73 operatively treated patients.** *Scandinavian Journal of Surgery* 2014, **0**:1-7.
310. Rasmussen P: **A functional approach to evaluation and treatment of tibial condylar fractures.** Gothenburg: Gothenburg University; 1971.
311. Lansinger O, Bergman B, Korner L, Andersson GB: **Tibial condylar fractures. A twenty-year follow-up.** *The Journal of Bone and Joint Surgery American volume* 1986, **68**(1):13-19.
312. Lucht U, Pilgaard S: **Fractures of the tibial condyles.** *Acta Orthopaedica Scandinavica* 1971, **42**(4):366-376.
313. Mattiassich G, Foltin E, Scheurecker G, Schneiderbauer A, Kropfl A, Fischmeister M: **Radiographic and clinical results after surgically**

- treated tibial plateau fractures at three and twenty two years postsurgery. *International Orthopaedics* 2014, **38**(3):587-594.
314. Ali AM, El-Shafie M, Willett KM: **Failure of fixation of tibial plateau fractures.** *Journal of Orthopaedic Trauma* 2002, **16**(5):323-329.
315. Marsh JL, Buckwalter J, Gelberman R, Dirschl D, Olson S, Brown T, Llinias A: **Articular fractures: does an anatomic reduction really change the result?** *The Journal of Bone and Joint Surgery American volume* 2002, **84-A**(7):1259-1271.
316. Giannoudis PV, Tzioupi C, Papathanassopoulos A, Obakponovwe O, Roberts C: **Articular step-off and risk of post-traumatic osteoarthritis. Evidence today.** *Injury* 2010.
317. Rasmussen PS: **Tibial condylar fractures as a cause of degenerative arthritis.** *Acta Orthopaedica Scandinavica* 1972, **43**(6):566-575.
318. Joy G, Patzakis MJ, Harvey JP, Jr.: **Precise evaluation of the reduction of severe ankle fractures.** *The Journal of Bone and Joint Surgery American volume* 1974, **56**(5):979-993.
319. Etter C, Ganz R: **Long-term results of tibial plafond fractures treated with open reduction and internal fixation.** *Archives of Orthopaedic and Trauma Surgery* 1991, **110**(6):277-283.
320. DeCoster TA, Willis MC, Marsh JL, Williams TM, Nepola JV, Dirschl DR, Hurwitz SR: **Rank order analysis of tibial plafond fractures: does injury or reduction predict outcome?** *Foot & Ankle international / American Orthopaedic Foot and Ankle Society [and] Swiss Foot and Ankle Society* 1999, **20**(1):44-49.
321. Marsh JL, Weigel DP, Dirschl DR: **Tibial plafond fractures. How do these ankles function over time?** *The Journal of Bone and Joint Surgery American volume* 2003, **85-A**(2):287-295.
322. Britten S, Ghos A, Duffield B, Giannoudis PV: **Ilizarov fixator pin site care: the role of crusts in the prevention of infection.** *Injury* 2013, **44**(10):1275-1278.
323. Hosny G, Fadel M: **Ilizarov external fixator for open fractures of the tibial shaft.** *International Orthopaedics* 2003, **27**(5):303-306.
324. Marsh DR, Shah S, Elliott J, Kurdy N: **The Ilizarov method in nonunion, malunion and infection of fractures.** *The Journal of Bone and Joint Surgery British volume* 1997, **79**(2):273-279.
325. Shtarker H, David R, Stolerio J, Grimberg B, Soudry M: **Treatment of open tibial fractures with primary suture and Ilizarov fixation.** *Clinical Orthopaedics and Related Research* 1997, (335):268-274.
326. Santy-Tomlinson J, Vincent M, Glossop N, Jomeen J, Pearcey P: **Calm, irritated or infected? The experience of the inflammatory states and symptoms of pin site infection and irritation during external fixation: a grounded theory study.** *Journal of Clinical Nursing* 2011, **20**(21-22):3163-3173.

327. Saw A, Chua YP, Hossain G, Sengupta S: **Rates of pin site infection during distraction osteogenesis based on monthly observations: a pilot study.** *Journal of Orthopaedic Surgery* 2012, **20**(2):181-184.
328. Ferreira N, Marais LC: **Prevention and management of external fixator pin track sepsis.** *Strategies in Trauma and Limb Reconstruction* 2012, **7**(2):67-72.
329. Antoci V, Ono CM, Antoci V, Jr., Raney EM: **Pin-tract infection during limb lengthening using external fixation.** *American Journal of Orthopedics* 2008, **37**(9):E150-154.
330. Collinge CA, Goll G, Seligson D, Easley KJ: **Pin tract infections: silver vs uncoated pins.** *Orthopedics* 1994, **17**(5):445-448.
331. Dellinger EP, Miller SD, Wertz MJ, Grypma M, Droppert B, Anderson PA: **Risk of infection after open fracture of the arm or leg.** *Archives of Surgery* 1988, **123**(11):1320-1327.
332. Chan CK, Saw A, Kwan MK, Karina R: **Diluted povidone-iodine versus saline for dressing metal-skin interfaces in external fixation.** *Journal of Orthopaedic Surgery* 2009, **17**(1):19-22.
333. Gordon JE, Kelly-Hahn J, Carpenter CJ, Schoenecker PL: **Pin site care during external fixation in children: results of a nihilistic approach.** *Journal of Pediatric Orthopedics* 2000, **20**(2):163-165.
334. Mahan J, Seligson D, Henry SL, Hynes P, Dobbins J: **Factors in pin tract infections.** *Orthopedics* 1991, **14**(3):305-308.
335. Alemdaroglu KB, Tiftikci U, Iltar S, Aydogan NH, Kara T, Atlihan D, Atesalp AS: **Factors affecting the fracture healing in treatment of tibial shaft fractures with circular external fixator.** *Injury* 2009, **40**(11):1151-1156.
336. Parameswaran AD, Roberts CS, Seligson D, Voor M: **Pin tract infection with contemporary external fixation: how much of a problem?** *Journal of Orthopaedic Trauma* 2003, **17**(7):503-507.
337. Lee CK, Chua YP, Saw A: **Antimicrobial gauze as a dressing reduces pin site infection: a randomized controlled trial.** *Clinical Orthopaedics and Related Research* 2012, **470**(2):610-615.
338. Paley D: **Problems, obstacles, and complications of limb lengthening by the Ilizarov technique.** *Clinical Orthopaedics and Related Research* 1990, (250):81-104.
339. Davies R, Holt N, Nayagam S: **The care of pin sites with external fixation.** *The Journal of Bone and Joint Surgery British volume* 2005, **87**(5):716-719.
340. Zhao L, Chu PK, Zhang Y, Wu Z: **Antibacterial coatings on titanium implants.** *Journal of Biomedical Materials Research Part B, Applied Biomaterials* 2009, **91**(1):470-480.
341. Camathias C, Valderrabano V, Oberli H: **Routine pin tract care in external fixation is unnecessary: a randomised, prospective, blinded controlled study.** *Injury* 2012, **43**(11):1969-1973.

342. Jennison T, McNally M, Pandit H: **Prevention of infection in external fixator pin sites.** *Acta Biomaterialia* 2014, **10**(2):595-603.
343. Timms A, Vicent M, Santy-Tomlinson J, Hertz K: **Guidance on pin site care. Report and recommendations from the 2010 Consensus. Project on Pin Site Care.** In: *Smith & Nephew*. Edn Nursing RCo. London: Royal College of Nursing; 2011.
344. Tacconelli E, De Angelis G, Cataldo MA, Pozzi E, Cauda R: **Does antibiotic exposure increase the risk of methicillin-resistant Staphylococcus aureus (MRSA) isolation? A systematic review and meta-analysis.** *The Journal of Antimicrobial Chemotherapy* 2008, **61**(1):26-38.
345. Davies J, Davies D: **Origins and evolution of antibiotic resistance.** *Microbiology and Molecular Biology Reviews* 2010, **74**(3):417-433.
346. Berger-Bachi B, McCallum N: **State of the knowledge of bacterial resistance.** *Injury* 2006, **37 Suppl 2**:S20-25.
347. Brumback RJ, Jones AL: **Interobserver agreement in the classification of open fractures of the tibia. The results of a survey of two hundred and forty-five orthopaedic surgeons.** *The Journal of Bone and Joint Surgery American volume* 1994, **76**(8):1162-1166.
348. Horn BD, Rettig ME: **Interobserver reliability in the Gustilo and Anderson classification of open fractures.** *Journal of Orthopaedic Trauma* 1993, **7**(4):357-360.
349. Gaston P, Will E, Elton RA, McQueen MM, Court-Brown CM: **Fractures of the tibia. Can their outcome be predicted?** *The Journal of Bone and Joint Surgery British volume* 1999, **81**(1):71-76.
350. Kristiansen LP: **Reconstructive surgery of the human tibia by use of external ring fixator and the Ilizarov method.** *Acta Orthopaedica Supplementum* 2009, **80**(331):1-43.
351. Bianchi Maiocchi A, Aronson J: **Operative Principles of Ilizarov. Fracture treatment-Nonunion-Osteomyelitis-Lengthening Deformity Correction.** Baltimore: Williams & Wilkins; 1991.
352. Adair A, Narayan B, Andrews C, Laverick M, Marsh D: **The complication rate in Ilizarov surgery.** *The Journal of Bone and Joint Surgery British volume* 2003, **85-B SUPP 2**:139.
353. Vaudaux P, Lew DP: **Tolerance of staphylococci to bactericidal antibiotics.** *Injury* 2006, **37 Suppl 2**:S15-19.
354. Szczesny G, Interewicz B, Swoboda-Kopec E, Olszewski WL, Gorecki A, Wasilewski P: **Bacteriology of callus of closed fractures of tibia and femur.** *The Journal of Trauma* 2008, **65**(4):837-842.
355. Petty W, Spanier S, Shuster JJ, Silverthorne C: **The influence of skeletal implants on incidence of infection. Experiments in a canine model.** *The Journal of Bone and Joint Surgery American volume* 1985, **67**(8):1236-1244.
356. Harris LG, Richards RG: **Staphylococci and implant surfaces: a review.** *Injury* 2006, **37 Suppl 2**:S3-14.

357. Petrisor B, Anderson S, Court-Brown CM: **Infection after reamed intramedullary nailing of the tibia: a case series review.** *Journal of Orthopaedic Trauma* 2005, **19**(7):437-441.
358. Green SA, Ripley MJ: **Chronic osteomyelitis in pin tracks.** *The Journal of Bone and Joint Surgery American volume* 1984, **66**(7):1092-1098.
359. Maurer DJ, Merkow RL, Gustilo RB: **Infection after intramedullary nailing of severe open tibial fractures initially treated with external fixation.** *The Journal of Bone and Joint Surgery American volume* 1989, **71**(6):835-838.
360. Shah CM, Babb P, McAndrew CM, Brimmo O, Badarudeen S, Tornetta P, 3rd, Ricci WM, Gardner MJ: **Definitive plates overlapping provisional external fixator pin sites: is the infection risk increased?** *Journal of Orthopaedic Trauma* 2014.
361. McGraw JM, Lim EV: **Treatment of open tibial-shaft fractures. External fixation and secondary intramedullary nailing.** *The Journal of Bone and Joint Surgery American volume* 1988, **70**(6):900-911.
362. Al-Dadah OQ, Darrach C, Cooper A, Donell ST, Patel AD: **Continuous compartment pressure monitoring vs. clinical monitoring in tibial diaphyseal fractures.** *Injury* 2008, **39**(10):1204-1209.
363. Shadgan B, Menon M, O'Brien PJ, Reid WD: **Diagnostic techniques in acute compartment syndrome of the leg.** *Journal of Orthopaedic Trauma* 2008, **22**(8):581-587.
364. DeLee JC, Stiehl JB: **Open tibia fracture with compartment syndrome.** *Clinical Orthopaedics and Related Research* 1981, (160):175-184.
365. Reverte MM, Dimitriou R, Kanakaris NK, Giannoudis PV: **What is the effect of compartment syndrome and fasciotomies on fracture healing in tibial fractures?** *Injury* 2011, **42**(12):1402-1407.
366. Turen CH, Burgess AR, Vanco B: **Skeletal stabilization for tibial fractures associated with acute compartment syndrome.** *Clinical Orthopaedics and Related Research* 1995, (315):163-168.
367. Giannoudis PV, Nicolopoulos C, Dinopoulos H, Ng A, Adedapo S, Kind P: **The impact of lower leg compartment syndrome on health related quality of life.** *Injury* 2002, **33**(2):117-121.
368. Fitzgerald AM, Gaston P, Wilson Y, Quaba A, McQueen MM: **Long-term sequelae of fasciotomy wounds.** *British Journal of Plastic Surgery* 2000, **53**(8):690-693.
369. Vandervelpen G, Goris L, Broos PL, Rommens PM: **[Functional sequelae in tibial shaft fractures with compartment syndrome following primary treatment with urgent fasciotomy].** *Acta Chirurgica Belgica* 1992, **92**(5):234-240.

370. Triffitt PD, Konig D, Harper WM, Barnes MR, Allen MJ, Gregg PJ: **Compartment pressures after closed tibial shaft fracture. Their relation to functional outcome.** *The Journal of Bone and Joint Surgery British volume* 1992, **74(2)**:195-198.
371. Prayson MJ, Chen JL, Hampers D, Vogt M, Fenwick J, Meredick R: **Baseline compartment pressure measurements in isolated lower extremity fractures without clinical compartment syndrome.** *The Journal of Trauma* 2006, **60(5)**:1037-1040.
372. Court-Brown CM, Koval KJ: **The epidemiology of fractures.** In: *Rockwood and Green's Fractures in Adults.* edn. Edited by Buchholz H, Court-Brown eds. Philadelphia: Lippincott Williams & Wilkins; 2006: 96-143.
373. Gershuni DH, Mubarak SJ, Yaru NC, Lee YF: **Fracture of the tibia complicated by acute compartment syndrome.** *Clinical Orthopaedics and Related Research* 1987, (217):221-227.
374. Black SS, Brumback RJ, Poka A, Burgess AR, Ebraheim NA: **Compartment syndrome in open tibial fractures.** *The Journal of Bone and Joint Surgery American volume* 1986, **68(9)**:1348-1353.
375. Moed BR, Strom DE: **Compartment syndrome after closed intramedullary nailing of the tibia: a canine model and report of two cases.** *Journal of Orthopaedic Trauma* 1991, **5(1)**:71-77.
376. Shakespeare DT, Henderson NJ: **Compartmental pressure changes during calcaneal traction in tibial fractures.** *The Journal of Bone and Joint Surgery British volume* 1982, **64(4)**:498-499.
377. Park S, Ahn J, Gee AO, Kuntz AF, Esterhai JL: **Compartment syndrome in tibial fractures.** *Journal of Orthopaedic Trauma* 2009, **23(7)**:514-518.
378. Stark E, Stucken C, Trainer G, Tornetta P, 3rd: **Compartment syndrome in Schatzker type VI plateau fractures and medial condylar fracture-dislocations treated with temporary external fixation.** *Journal of Orthopaedic Trauma* 2009, **23(7)**:502-506.
379. Patillo D, Della Rocca GJ, Murtha YM, Crist BD: **Pilon fracture complicated by compartment syndrome: a case report.** *Journal of Orthopaedic Trauma* 2010, **24(6)**:54-57.
380. Hudak PL, Wright JG: **The characteristics of patient satisfaction measures.** *Spine* 2000, **25(24)**:3167-3177.
381. Jackowski D, Guyatt G: **A guide to health measurement.** *Clinical Orthopaedics and Related Research* 2003(413):80-89.
382. Burstrom K, Johannesson M, Diderichsen F: **Swedish population health-related quality of life results using the EQ-5D.** *Health Policy* 2001, **10(7)**:621-635.
383. Modin M, Ramos T, Stomberg MW: **Postoperative impact of daily life after primary treatment of proximal/distal tibiafracture with Ilizarov external fixation.** *Journal of Clinical Nursing* 2009, **18(24)**:3498-3506.

384. Baschera D, Walter C, Wren M, Zellweger R: **Behandlung schwerster Tibiafrakturen mit gefährdetem Weichteilmantel und/oder Kontamination Lebensqualität nach Einsatz des Ilizarov-Fixateur externe.** *Der Unfallchirurg* 2013.
385. Schwenk W, Mall JW, Neudecker J, Muller JM: **One visual analogue pain score is sufficient after laparoscopic cholecystectomy.** *The British Journal of Surgery* 2002, **89**(1):114-115.
386. Kemler MA, Barendse GA, van Kleef M, de Vet HC, Rijks CP, Furnee CA, van den Wildenberg FA: **Spinal cord stimulation in patients with chronic reflex sympathetic dystrophy.** *The New England Journal of Medicine* 2000, **343**(9):618-624.
387. Bessette L, Sangha O, Kuntz KM, Keller RB, Lew RA, Fossel AH, Katz JN: **Comparative responsiveness of generic versus disease-specific and weighted versus unweighted health status measures in carpal tunnel syndrome.** *Medical Care* 1998, **36**(4):491-502.
388. Sloan JA, Loprinzi CL, Kuross SA, Miser AW, O'Fallon JR, Mahoney MR, Heid IM, Bretscher ME, Vaught NL: **Randomized comparison of four tools measuring overall quality of life in patients with advanced cancer.** *Journal of Clinical Oncology* : 1998, **16**(11):3662-3673.
389. de Boer AG, van Lanschot JJ, Stalmeier PF, van Sandick JW, Hulscher JB, de Haes JC, Sprangers MA: **Is a single-item visual analogue scale as valid, reliable and responsive as multi-item scales in measuring quality of life?** *Quality of Life Research* 2004, **13**(2):311-320.
390. Wiklund I, Dimenas E: **[The Swedish version of the Nottingham Health Profile. A questionnaire for the measurement of health-related quality of life].** *Lakartidningen* 1990, **87**(18):1575-1576.
391. Carlsson E, Olsson SB, Hertervig E: **The role of the nurse in enhancing quality of life in patients with an implantable cardioverter-defibrillator: the Swedish experience.** *Progress in Cardiovascular Nursing* 2002, **17**(1):18-25.
392. McKee MD, Yoo D, Schemitsch EH: **Health status after Ilizarov reconstruction of post-traumatic lower-limb deformity.** *The Journal of Bone and Joint Surgery British volume* 1998, **80**(2):360-364.
393. Foster PA, Barton SB, Jones SC, Morrison RJ, Britten S: **The treatment of complex tibial shaft fractures by the Ilizarov method.** *The Journal of Bone and Joint Surgery British volume* 2012, **94**(12):1678-1683.
394. Giotakis N, Panchani SK, Narayan B, Larkin JJ, Al Maskari S, Nayagam S: **Segmental fractures of the tibia treated by circular external fixation.** *The Journal of Bone and Joint Surgery British volume* 2010, **92**(5):687-692.
395. Dogra AS, Ruiz AL, Marsh DR: **Late outcome of isolated tibial fractures treated by intramedullary nailing: the correlation**

- between disease-specific and generic outcome measures. *Journal of Orthopaedic Trauma* 2002, **16**(4):245-249.
396. Katsoulis E, Court-Brown C, Giannoudis PV: **Incidence and aetiology of anterior knee pain after intramedullary nailing of the femur and tibia.** *The Journal of Bone and Joint Surgery British volume* 2006, **88**(5):576-580.
397. Toivanen JA, Vaisto O, Kannus P, Latvala K, Honkonen SE, Jarvinen MJ: **Anterior knee pain after intramedullary nailing of fractures of the tibial shaft. A prospective, randomized study comparing two different nail-insertion techniques.** *The Journal of Bone and Joint Surgery American volume* 2002, **84-A**(4):580-585.
398. Court-Brown CM, Gustilo T, Shaw AD: **Knee pain after intramedullary tibial nailing: its incidence, etiology, and outcome.** *Journal of Orthopaedic Trauma* 1997, **11**(2):103-105.
399. Keating JF, Orfaly R, O'Brien PJ: **Knee pain after tibial nailing.** *Journal of Orthopaedic Trauma* 1997, **11**(1):10-13.
400. Weil YA, Gardner MJ, Boraiah S, Helfet DL, Lorich DG: **Anterior knee pain following the lateral parapatellar approach for tibial nailing.** *Archives of Orthopaedic and Trauma Surgery* 2009, **129**(6):773-777.
401. Hernigou P, Cohen D: **Proximal entry for intramedullary nailing of the tibia. The risk of unrecognised articular damage.** *The Journal of Bone and Joint Surgery British volume* 2000, **82**(1):33-41.
402. Duan X, Al-Qwbani M, Zeng Y, Zhang W, Xiang Z: **Intramedullary nailing for tibial shaft fractures in adults.** *Cochrane Database of Systematic Reviews* 2012, **1**:CD008241.
403. Vaisto O, Toivanen J, Kannus P, Jarvinen M: **Anterior knee pain after intramedullary nailing of fractures of the tibial shaft: an eight-year follow-up of a prospective, randomized study comparing two different nail-insertion techniques.** *The Journal of Trauma* 2008, **64**(6):1511-1516.
404. Rothberg DL, Daubs GM, Horwitz DS, Kubiak EN: **One-year postoperative knee pain in patients with semi-extended tibial nailing versus control group.** *Orthopedics* 2013, **36**(5):e548-553.
405. Ryan SP, Steen B, Tornetta P, 3rd: **Semi-extended nailing of metaphyseal tibia fractures: alignment and incidence of postoperative knee pain.** *Journal of Orthopaedic Trauma* 2014, **28**(5):263-269.
406. Darabos N, Banic T, Lubina Z, Darabos A, Bilic V, Sabalic S: **Precise nail tip positioning after tibial intramedullary nailing prevents anterior knee pain.** *International Orthopaedics* 2013, **37**(8):1527-1531.
407. Vaisto O, Toivanen J, Kannus P, Jarvinen M: **Anterior knee pain and thigh muscle strength after intramedullary nailing of a tibial shaft**

- fracture: an 8-year follow-up of 28 consecutive cases.** *Journal of Orthopaedic Trauma* 2007, **21**(3):165-171.
408. Skoog A, Soderqvist A, Tornkvist H, Ponzer S: **One-year outcome after tibial shaft fractures: results of a prospective fracture registry.** *Journal of Orthopaedic Trauma* 2001, **15**(3):210-215.
409. Larsen P, Lund H, Laessoe U, Graven-Nielsen T, Petruskevicius J, Rasmussen S: **Anterior knee pain and limitations in activity and participation after intramedullary nailing of tibial shaft fracture.** In: *DOS Kongressen.* vol. 2012. Copenhagen, Denmark: Dansk Ortopædisk Selskab; 2012: 126.
410. Ferguson M, Brand C, Lowe A, Gabbe B, Dowrick A, Hart M, Richardson M: **Outcomes of isolated tibial shaft fractures treated at level 1 trauma centres.** *Injury* 2007.
411. Karladani AH, Ericsson PA, Granhed H, Karlsson L, Nyberg P: **Tibial intramedullary nails -- should they be removed? A retrospective study of 71 patients.** *Acta Orthopaedica* 2007, **78**(5):668-671.
412. Boerger TO, Patel G, Murphy JP: **Is routine removal of intramedullary nails justified.** *Injury* 1999, **30**(2):79-81.
413. Sala F, Binda M, Loviseti G: **Anterior gonalgic syndrome after intramedullary nailing: ultrasound and radiologic study.** *La Chirurgia degli Organi di Movimento* 1998, **83**(3):271-275.
414. Hayashi A: **Poor outcomes for surgically treated patella fractures.** *AAOS Now* 2010, **4**(1).
415. Berkes MB, Little MT, Lazaro LE, Sculco PK, Cymerman RM, Daigl M, Helfet DL, Lorich DG: **Malleolar fractures and their ligamentous injury equivalents have similar outcomes in supination-external rotation type IV fractures of the ankle treated by anatomical internal fixation.** *The Journal of Bone and Joint Surgery British volume* 2012, **94**(11):1567-1572.
416. Vallier HA, Cureton BA, Patterson BM: **Factors influencing functional outcomes after distal tibia shaft fractures.** *Journal of Orthopaedic Trauma* 2012, **26**(3):178-183.
417. Bedi A, Le TT, Karunakar MA: **Surgical treatment of nonarticular distal tibia fractures.** *The Journal of the American Academy of Orthopaedic Surgeons* 2006, **14**(7):406-416.
418. Cole JD, Latta L: **Fatigue failure of interlocking tibial nail implants.** *Journal of Orthopaedic Trauma* 1992(6):507-508.
419. Kneifel T, Buckley R: **A comparison of one versus two distal locking screws in tibial fractures treated with unreamed tibial nails: a prospective randomized clinical trial.** *Injury* 1996, **27**(4):271-273.
420. Bhandari M, Tornetta P, 3rd, Sprague S, Najibi S, Petrisor B, Griffith L, Guyatt GH: **Predictors of reoperation following operative management of fractures of the tibial shaft.** *Journal of Orthopaedic Trauma* 2003, **17**(5):353-361.

421. Harris I, Lyons M: **Reoperation rate in diaphyseal tibia fractures.** *Australian and New Zealand Journal of Surgery* 2005, **75**(12):1041-1044.
422. Yu B, Han K, Ma H, Zhang C, Su J, Zhao J, Li J, Bai Y, Tang H: **Treatment of tibial plateau fractures with high strength injectable calcium sulphate.** *International Orthopaedics* 2009, **33**(4):1127-1133.
423. Phisitkul P, McKinley TO, Nepola JV, Marsh JL: **Complications of locking plate fixation in complex proximal tibia injuries.** *Journal of Orthopaedic Trauma* 2007, **21**(2):83-91.
424. Boldin C, Fankhauser F, Hofer HP, Szyszkowitz R: **Three-year results of proximal tibia fractures treated with the LISS.** *Clinical Orthopaedics and Related Research* 2006, **445**:222-229.
425. Oh CW, Oh JK, Kyung HS, Jeon IH, Park BC, Min WK, Kim PT: **Double plating of unstable proximal tibial fractures using minimally invasive percutaneous osteosynthesis technique.** *Acta Orthopaedica* 2006, **77**(3):524-530.
426. Cole PA, Zlowodzki M, Kregor PJ: **Treatment of proximal tibia fractures using the less invasive stabilization system: surgical experience and early clinical results in 77 fractures.** *Journal of Orthopaedic Trauma* 2004, **18**(8):528-535.
427. Ricci WM, Rudzki JR, Borrelli J, Jr.: **Treatment of complex proximal tibia fractures with the less invasive skeletal stabilization system.** *Journal of Orthopaedic Trauma* 2004, **18**(8):521-527.
428. Zecher SB, Danziger MB, Segal D, Foster T, Whitelaw GP, Covall DJ: **Treatment of high-energy proximal tibial fractures using the Monticelli-Spinelli external fixator: a preliminary report.** *American Journal of Orthopedics* 1996, **25**(1):49-54.
429. Marsh JL, Smith ST, Do TT: **External fixation and limited internal fixation for complex fractures of the tibial plateau.** *The Journal of Bone and Joint Surgery American volume* 1995, **77**(5):661-673.
430. Yang EC, Weiner L, Strauss E, Sedlin E, Kelley M, Raphael J: **Metaphyseal dissociation fractures of the proximal tibia. An analysis of treatment and complications.** *American Journal of Orthopedics* 1995, **24**(9):695-704.
431. Wasserstein D, Henry P, Paterson JM, Kreder HJ, Jenkinson R: **Risk of total knee arthroplasty after operatively treated tibial plateau fracture: a matched-population-based cohort study.** *The Journal of Bone and Joint Surgery American volume* 2014, **96**(2):144-150.
432. Fan CY, Chiang CC, Chuang TY, Chiu FY, Chen TH: **Interlocking nails for displaced metaphyseal fractures of the distal tibia.** *Injury* 2005, **36**(5):669-674.
433. Nork SE, Schwartz AK, Agel J, Holt SK, Schrick JL, Winkquist RA: **Intramedullary nailing of distal metaphyseal tibial fractures.** *The*

- Journal of Bone and Joint Surgery American volume* 2005, **87**(6):1213-1221.
434. Maffulli N, Toms AD, McMurtie A, Oliva F: **Percutaneous plating of distal tibial fractures.** *International Orthopaedics* 2004, **28**(3):159-162.
435. Borg T, Larsson S, Lindsjo U: **Percutaneous plating of distal tibial fractures. Preliminary results in 21 patients.** *Injury* 2004, **35**(6):608-614.
436. Oh CW, Kyung HS, Park IH, Kim PT, Ihn JC: **Distal tibia metaphyseal fractures treated by percutaneous plate osteosynthesis.** *Clinical Orthopaedics and Related Research* 2003(408):286-291.
437. Khoury A, Liebergall M, London E, Mosheiff R: **Percutaneous plating of distal tibial fractures.** *Foot & Ankle International / American Orthopaedic Foot and Ankle Society [and] Swiss Foot and Ankle Society* 2002, **23**(9):818-824.
438. Wagner M (ed.): **The Human Bone Manual.** San Diego: Elsevier Academic Press; 2005.
439. Busam ML, Esther RJ, Obremsky WT: **Hardware removal: indications and expectations.** *The Journal of the American Academy of Orthopaedic Surgeons* 2006, **14**(2):113-120.
440. Stafford P, Norris BL, Nowotarski PJ: **Hardware removal: tips & techniques in revision fracture surgery.** *Techniques in Orthopaedics* 2003, **17**(4):522-530.
441. Hanson B, van der Werken C, Stengel D: **Surgeons' beliefs and perceptions about removal of orthopaedic implants.** *BMC Musculoskeletal Disorders* 2008, **9**:73.
442. Rutkow IM: **Orthopaedic operations in the United States, 1979 through 1983.** *The Journal of Bone and Joint Surgery American volume* 1986, **68**(5):716-719.
443. Bostman O, Pihlajamaki H: **Routine implant removal after fracture surgery: a potentially reducible consumer of hospital resources in trauma units.** *The Journal of Trauma* 1996, **41**(5):846-849.
444. Sanderson PL, Ryan W, Turner PG: **Complications of metalwork removal.** *Injury* 1992, **23**(1):29-30.
445. Gubin AV, Borzunov DY, Malkova TA: **The Ilizarov paradigm: thirty years with the Ilizarov method, current concerns and future research.** *International Orthopaedics* 2013, **37**(8):1533-1539.
446. Alho A, Ekeland A, Stromsoe K, Folleras G, Thoresen BO: **Locked intramedullary nailing for displaced tibial shaft fractures.** *The Journal of Bone and Joint Surgery British volume* 1990, **72**(5):805-809.
447. Miclau T, Lu C, Thompson Z, Choi P, Puttlitz C, Marcucio R, Helms JA: **Effects of delayed stabilization on fracture healing.** *Journal of Orthopaedic Research* 2007, **25**(12):1552-1558.

448. Narayan B, Marsh D: **The Ilizarov method in the treatment of fresh fractures.** *Current Orthopaedics* 2003, **17**(447-457).
449. Beals TC: **Applications of ring fixators in complex foot and ankle trauma.** *The Orthopedic Clinics of North America* 2001, **32**(1):205-214.

APPENDIX

Components of the Ilizarov external fixator

The components of the classical Ilizarov apparatus have been standardised since 1952. There are 32 different parts that can be used to assemble modular constructions with hundreds of possible configurations.

Wires

The function of the wires is to suspend the bone segments within the frame, allowing a controlled range of inter-fragmentary movement. Two different diameter sizes are available: 1.5 mm and 1.8 mm. The larger diameter wire is recommended for tibial applications in adults.

The wires are introduced percutaneously without protection sleeves according to known “safe corridors”, avoiding major vessels, nerves and the tethering of tendons and muscles in each tibial anatomical segment. The wire is guided by holding it with one hand in chlorhexidine-soaked gauze. The tip of the wire should be in contact with the bone surface before the drilling begins. In long bones like the tibia, the wires are usually inserted perpendicularly to the long axis. It is important to use low-speed drilling to avoid local thermal necrosis. If the bone is very hard, it is necessary to use intermittent drilling. The wires should be drilled through both cortices and then tapped with a small mallet through the soft tissues. Unintentional wire contact with a motor nerve can be detected by noting muscular fasciculation. In this case, the wire is withdrawn and replaced. It is very rare that this causes any sequelae.

To increase the mechanical resistance of the wires, they have to be tensioned. This tensioning can be achieved by using a slotted bolt or preferably with a wire tensioner graded in kg. The final tensioning depends on the weight of the patient and should normally be 100-130 kg. Too little tension permits the undesirable bending of the wire during the loading cycles. On the other hand, too much tension might lead to plastic deformation and wire breakage. Excessive loss of tension can lead to instability, which increases the risk of pin-tract infections and pain. In this situation, re-tensioning is necessary. If the wire tip protruding out of the ring is too short for the use of the tensioner, it is still possible to re-tension the wire by turning the slotted bolt, but this can cause a displacement of several mm along the axis of the wire. Ilizarov himself

outlined the importance of fixating the ring to the wire instead of the wire to the ring, as bending the wire also leads to loosening and deformities.

At least two tensioned wires must be used for each full- or part-ring. The closer to 90° the crossing angles of the wires are, the more stable to axial load the construction becomes. On the other hand, experiments have demonstrated that a 30° crossing angle provides better resistance to medial bending forces. It has been shown in some studies that the way the wires are attached is one of the most important variables affecting the overall frame bending stiffness, together with the axial distance between the rings.

There are also wires with a 4 mm bead (“stopper” or “olive”) welded around its mid-portion. A bone fragment with an olive wire can be translocated in a controlled manner, compressing fragments by pulling the wire. When the position of the bone/bone fragments is satisfactory, the nut on the olive side should be fixed first, after which the wire is tensioned as usual. The olive wire fixation contributes to stability and reduces undesirable effects of translational forces, especially when the wire-crossing angle is small.

“Reference wires” are the initial single wires placed in the proximal and distal fracture fragments and they are used to position the rings of the fixator. They are without olives to permit the translation (sliding) of the frame relative to the bone.

Rings

The main components are half-rings that can be assembled with screws and nuts to form a complete ring. The half-rings are made of 8 mm thick steel or of composite material 10 mm thick and have a diameter of between 100 and 220 mm. Lighter and radiolucent composite rings can also be used.

Wire/ring connectors (Bolts, Buckles, and Nuts)

Cannulated and slotted bolts and also slotted washers and buckles are used to secure the wires to the rings.

Longitudinal elements (Rods)

Several types of longitudinal support are used to connect the rings: simple threaded rods, telescopic rods and articulating distraction assemblies.

In the lower extremity, four threaded rods normally provide adequate stability between the rings, but, with wider rings (diameter over 160 mm), an extra rod is recommended.

For special cases of reconstruction, telescopic rods, with a click-mechanism that gives more accurate compression-distraction measurements, can be added.

Articulating distraction assemblies or hinges are needed in severe intra-articular fractures to permit controlled movement of the joint while the intra-articular fracture heals.

More complex articulating distraction assemblies (hexapod) might allow further correction in a few selected cases, without changing the parts of the original construction.

Supports - Posts and Plates

Posts 20-50 mm long can be fixed to the rings and the wires attached to them (drop-wires) can be used to further stabilise a fixator. A drop-wire will increase the stiffness but only half as much as adding another ring. Drop-wires can also be fixed to different types of plate connected to the rings. It is important that the posts are of suitable length so that the wire is not bent when tensioned.

Wrenches

Two 10 mm wrenches are needed to assemble the construction.

Details of the surgical techniques

This is a comprehensive description based on the author's own experience. For further details on the surgical technique I recommend the richly illustrated description by James Hutson Jr: Applications of Ilizarov Fixators to Fractures of the Tibia: a Practical Guide. Techniques in Orthopaedics 2002; 17 (1): 1-111.

General aspects of controlling the repositioning of bone fragments

The sideways translation of a bone fragment within a frame is one of the most important manoeuvres for fracture reduction. Several different strategies can be used to accomplish the repositioning: contra-lateral olive wires, bending wires and missing-a-bone wires, for example (Figure 1).

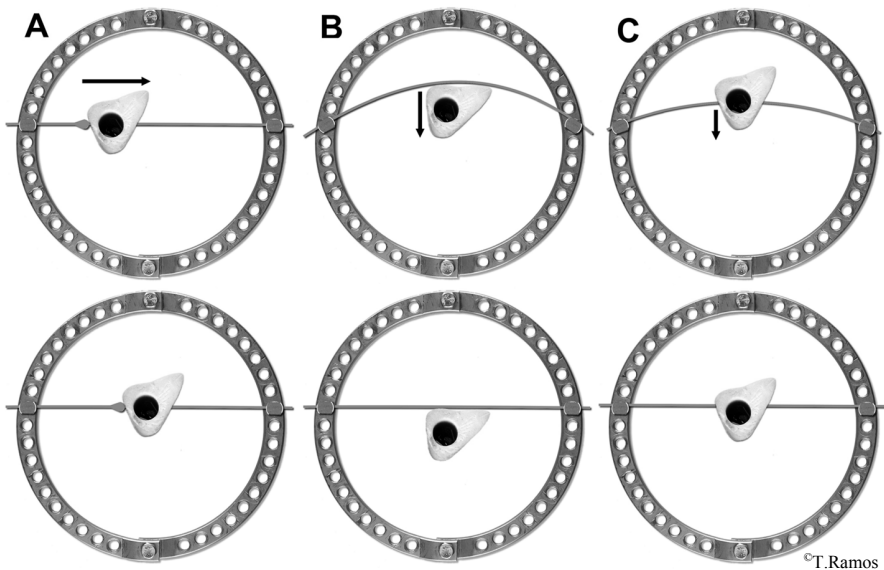


Figure 1. Strategies to accomplish the repositioning of bone fragments with wires: contralateral olive wire (A), missing-a-bone wire (B) and bending wire (C).

The sideways translation of bone fragments, rotation and angulation can also be achieved by frame movement in a hexapod system, when complex repositioning manoeuvres in several planes are necessary, usually in a multi-directional deformity but rarely in fracture treatment.

Proximal metaphyseal fractures

The configuration used is depicted in Figure 2. After percutaneous reconstruction of the articular surface, three olive wires (a, b, c) are introduced parallel and 3-4 mm under the articular surface. They will subsequently be fixed as drop-wires (see below). A fourth wire (d) without an olive is drilled at the level of the fibular head under fluoroscopic control (reference wire) and tensioned to a ring (A) in which two rods are fixed anteriorly (1) and posteriorly (3).

These rods are connected to another ring (B) with a reference wire (e) placed at the level of the proximal diaphysis in Schatzker I-IV fractures.

In the more complex fractures (Schatzker V-VI) the reference wire (f) is instead inserted a few cm above the ankle and fixed to a ring (C). This ring is connected to ring B with two rods (5 and 7).

One olive wire (g) in the distal ring (C) is used to reduce the translational forces of the apparatus. Additional wires are then introduced. The frame is also stiffened by adding two rods at each level (2, 4, 6 and 8). Finally, the

repositioning olive wires (a, b, c) are secured to posts. This is done in several steps. First, only slight tension is applied to achieve inter-fragmentary compression using the olive pressing against the bone fragment. Then, on the olive side, the wires are secured with bolts and the definitive tension is applied. When tensioning the wires, it is important to avoid tilting the posts.

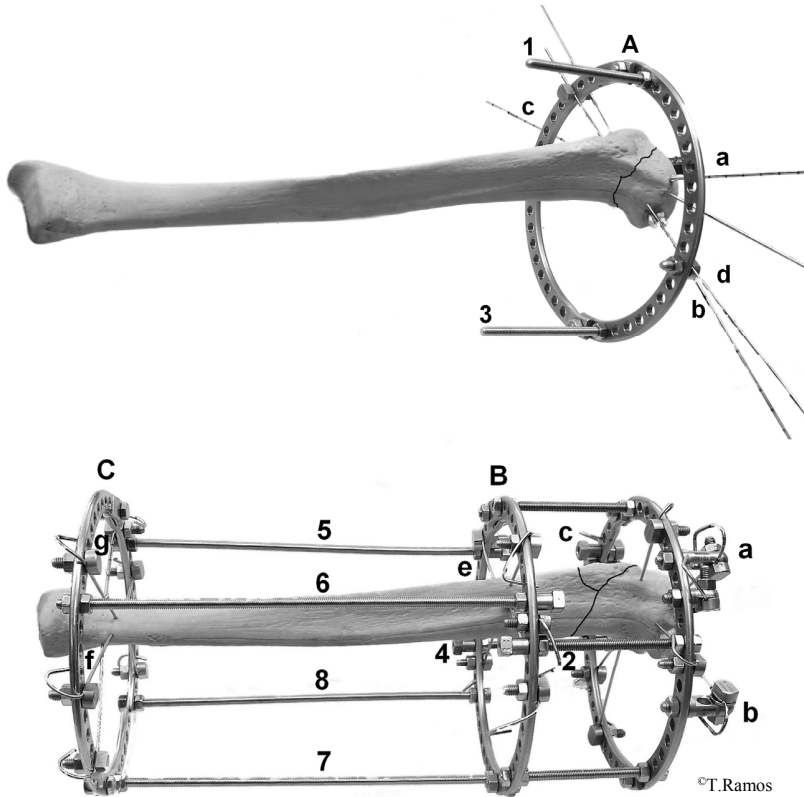


Figure 2. Configuration of the Ilizarov frame in a proximal metaphyseal tibial fracture. The wires are indicated with small letters, the rings with capital letters and the rods with numbers.

In Schatzker I-IV fractures, the two proximal rings (A and B) are sufficient. In Schatzker V-VI fractures, a femoral extension with hinges is added to the leg construction. The femoral extension is constructed by fixating reference wires in two rings, the proximal one in the distal femur and the distal one five cm above the patella. The frame is then completed first with two rods, then with additional wires and finally with two additional rods. It is important that the hinges are aligned as closely as possible to the “centre of rotation” of the knee. They also have to be parallel to the extremity and the frames.

Diaphyseal fractures

The configuration used is depicted in Figure 3. A reference wire (a) is introduced at the level of the fibular head under fluoroscopic control and tensioned in a ring (A). Two rods, one anterior (1) and one posterior (3), are connected with another ring (B) and placed proximally to the fracture site. Two more rods (5 and 7) are connected to the ring (C) placed distally to the fracture site. Two more rods (9 and 11) are connected to the most distal ring (D), a few cm above the ankle. A second reference wire (b) is secured to the distal ring (D). The levels of the rings are checked with fluoroscopy to ensure that they do not overshadow the fracture.

One olive wire (c) in the proximal ring (A) and another (d) in the distal ring (D) in opposite directions are used to reduce the translational forces of the apparatus. Two additional wires are introduced and tensioned in each ring (A and D). The frame is also stiffened by adding a rod at each level between the rings (2, 6 and 10). Further reduction of the fracture is accomplished with the techniques described above (Figure 1). In the example in Figure 3, olive wires (e and f) are used.

Additional wires are inserted and fixed to rings B and C. The wires do not need to be set at the level of each ring; if necessary, drop-wires can be secured using posts or rods. The last rods are then tightened (4, 8 and 12) and complete the assembly. Finally, axial compression of the fracture is performed under fluoroscopy.




Figure 3. Configuration of the Ilizarov frame in a diaphyseal tibial fracture. The wires are indicated with small letters, the rings with capital letters and the rods with numbers.

Distal metaphyseal fractures

The configuration used is depicted in Figure 4. After percutaneous reconstruction of the articular surface, one wire is introduced intramedullarily at the tip of the fibula, if there is a fracture in the distal fibula (not depicted), under fluoroscopic control. A reference wire (a) is introduced at the level of the fibular head under fluoroscopic control and tensioned to a ring (A). Two rods, one anterior (1) and another posterior (3), are connected to another ring (B). Two more rods (5 and 7) are connected to the ring (C) placed above the fracture site. Two more rods (9 and 11), are connected to the lowest ring (D), a few cm above the ankle. The distal reference wire (b) is placed temporarily through the calcaneus parallel to the distal ring and secured with a posterior half-ring and three (13, 14, 15) rods to use for axial traction.

One olive wire (c) and a wire without an olive are secured and tensioned to ring A. The frame is then stiffened by adding rods at each level between the rings (2, 8 and 10). In this way, the distortion forces, which tend to tilt the construction, are counteracted. The axial traction in the fracture is performed manually and by turning the nuts on the rods to increase the distance between the half-ring (E) and the distal ring (D). A control with fluoroscopy will ensure that the levels of the rings are adequate and the fracture is visualised.

If dislocated, the medial malleolus can be reduced and fixed with an oblique olive wire (d) fixed to one of the more proximal rings (B or C). At this stage, final interfragmentary reduction is achieved by adding olive wires (e, f), if needed, using the drop-wire technique. These drop-wires are fixated with posts. First, only slight tension is applied to achieve inter-fragmentary compression using the olive pressing against the bone fragment. On the olive side, the wires are then secured with bolts and the definitive tension is applied. When tensioning the wires, it is important to avoid tilting the posts. Additional wires in ring B and ring C are then introduced. The frame is also stiffened by adding two rods at each level (4, 6 and 12). The hindfoot extension can be removed immediately, but it can also be left during the first post-operative weeks. In highly comminuted fractures, a foot extension without hinges is added to the leg construction. This frame is constructed by extending the half-ring hindfoot fixation with two long connection plates parallel to the forefoot and connected to a half-ring with another half-ring connecting the plates with ring D. The foot is transfixated with two olive wires to the calcaneus and one olive wire trans-metatarsally. If the hinges are used, it is important that they are aligned as closely as possible to the “centre of rotation” localised at the level of the tarsal sinus.

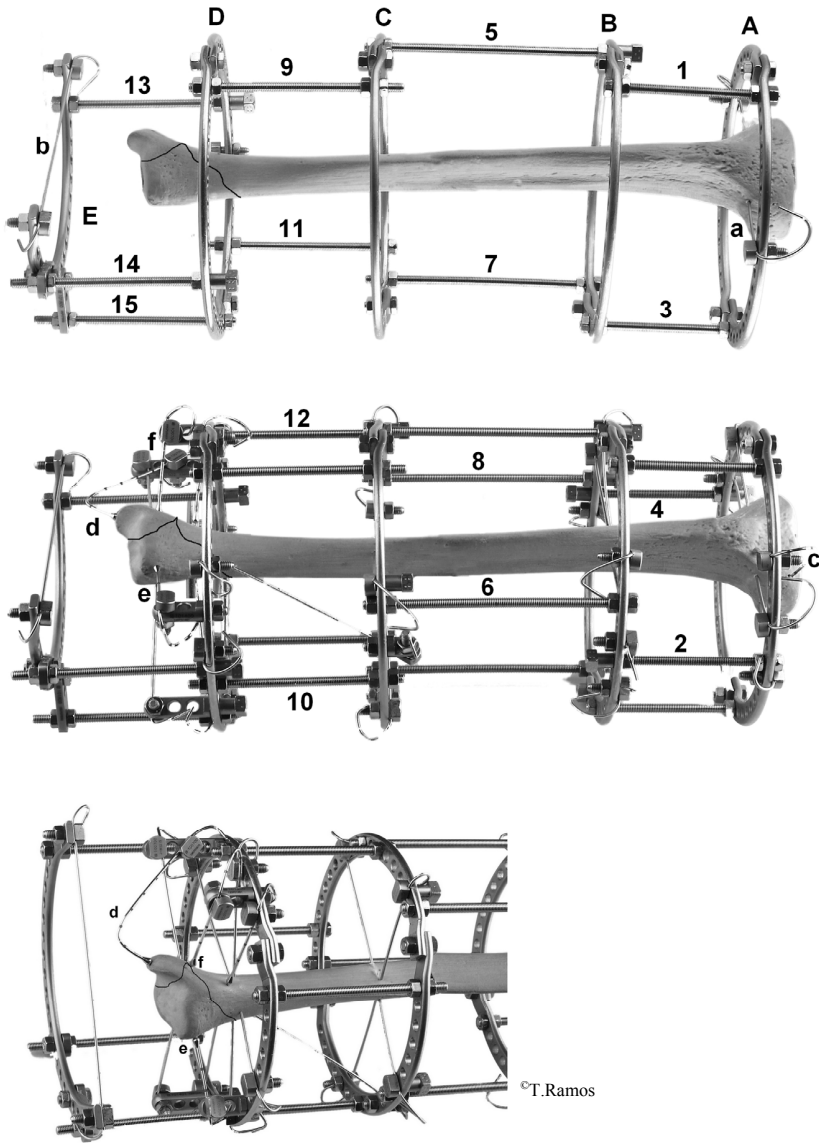


Figure 4. Configuration of the Ilizarov frame in a distal tibial fracture. The wires are indicated with small letters, the rings with capital letters and the rods with numbers.

The pin-site dressing protocol

The pin-site dressing protocol is based on the routine used at the Russian Ilizarov Scientific Centre for Restorative Traumatology and Orthopaedics in Kurgan.

Dry dressings (Permafoam[®]) are used for the pin sites at the completion of the operation, with pressure to reduce haematoma, during the first 24 hours. The pin sites are then cleaned every day for three days and dressings with 0.5% chlorhexidine solution are applied.

Afterwards, dressing changes and crust removal are only performed in the presence of exudates. Otherwise, pin cleaning and dressing changes are repeated every seven to ten days using the same technique.

Prolonged skin contact with a strong antiseptic solution might produce hypersensitivity reactions. These can be treated successfully with a cream of 0.1% betamethasone and 2% fusidic acid.

卷之三