

On Factors Influencing the Clinical Outcome in Orthognathic Surgery

Fredrik Widar

Department of Oral and Maxillofacial Surgery
Institute of Odontology at Sahlgrenska Academy
University of Gothenburg
Gothenburg, Sweden

Department of Oral and Maxillofacial Surgery &
Otolaryngology at NU Hospital Group
Trollhättan, Sweden

2015



UNIVERSITY OF GOTHENBURG



On Factors Influencing the Clinical Outcome in Orthognathic Surgery.

© 2015 Fredrik Widar

Email: fredrik.widar@vgregion.se

<http://hdl.handle.net/2077/38462>

ISBN: 978-91-628-9386-6 (tryckt)

ISBN: 978-91-628-9387-3 (e-publicering)

Coverdesign by: pixlar.se

Printed by Ineko AB, Gothenburg, Sweden.

To Hanna
Alfred, Lilly and Axel.

“En ängel utan ansikte omfamnade mig och viskade genom hela kroppen: Skäms inte för att du är människa, var stolt. Inne i dig öppnar sig valv bakom valv oändligt. Du blir aldrig färdig, och det är som det ska”. Tomas Tranströmer

ABSTRACT

Background. Orthognathic surgery means surgical correction of dentofacial and congenital deformities, which includes unsatisfactory facial aesthetics, malpositioned teeth, jaw malformations and masticatory dysfunction. Correction of these conditions requires a multidisciplinary approach with a combination of orthodontics and surgery. Successful outcome of orthognathic treatment requires pre-, intra- and postoperative considerations with a multimodal approach in order to minimize morbidity and enhance recovery after surgery. Developments within the orthognathic field should focus on multimodal approaches with combined effects of modern anaesthetic protocols, minimal invasive surgery and pharmacological modification of inflammatory responses. However, surgical morbidity after orthognathic surgery is still associated with undesirable sequelae such as damage to teeth, facial oedema, pain, neurosensory disturbances, prolonged recovery time and removal of titanium plates.

Intraoperative anchorage of the occlusion is a major keystone in the implementation of the orthognathic planning during surgery. Bone anchor screws are therefore occasionally required in transalveolar positions as reinforced rigid emergency anchor for proper intermaxillary fixation in cases when orthodontic appliances loosen or when preoperative orthodontic treatment isn't indicated. Furthermore, steroids are recommended to reduce swelling, pain, nausea and vomiting (PONV) and may promote nerve healing after surgery. The multimodal effects of steroids need further investigation, thus the optimal dosages and the timing of administration is of great interest. Moreover, removal of inserted titanium fixation plates after surgery occur due to plate related complications. The reason for plate removal needs further investigation. Finally, different general anaesthetic protocols influence haemodynamics and subsequently postoperative pain, recovery and hospitalization. Evaluation of these protocols is needed to understand the recovery process and to promote mobilization of the patient after surgery.

Objectives. The aim of the first study was to evaluate two types of surgical approaches for insertion of bone anchor screws for intermaxillary fixation, regarding frequency of iatrogenic dental root injuries. The second trial investigated the efficacy of single versus repeated betamethasone doses on facial oedema, pain and neurosensory disturbances after bilateral sagittal split osteotomy (BSSO). The main objective of the third study was to investigate the incidence and reasons for removal of titanium fixation plates following orthognathic surgery, identify risk factors predisposing removal and to explore if the patients discomfort was reduced after removal. The primary objective of the fourth study was to evaluate haemodynamics and recovery parameters in relation to two general anaesthetic protocols; remifentanyl-propofol based total intravenous anaesthesia (TIVA) versus fentanyl-sevoflurane based balanced inhalation anaesthesia (BA) in orthognathic surgery. The second objective was to evaluate long duration local anaesthesia on recovery parameters and hospitalization.

Material & Methods. Study I: Two surgical methods for insertion of bone anchor screws for intermaxillary fixation were compared retrospectively (n=123). Study II: Two study groups and a control group were compared with a randomized controlled trial (RCT) in order to evaluate the effect of steroids. This was performed with repeated doses (4+8+4 mg betamethasone, n=14), a single dose (16 mg betamethasone, n=11) and controls (n=12). Study III: Medical records were retrospectively reviewed (n=404) and an additional questionnaire was used to evaluate fixation plate related complications. Totally 323 (80%) patients responded the questionnaire and were subsequently included in the study. Study IV: Anaesthetic curves and medical records were retrospectively reviewed for the comparison of two anaesthetic protocols (n=269). Ninety-four patients were audited due to strict inclusion criteria.

Results. The first study revealed that the twist drill was hazardous in transalveolar positions since it could cause iatrogenic dental root injuries ($p<0.001$). The second study showed that steroids inhibited progression of facial oedema the first day after surgery ($p=0.017$). However, steroids did not reduce neurosensory disturbances over time. Reduced bleeding was associated with improved pain recovery over time ($p=0.043$). Patients requiring higher dosages of analgesics due to pain had significantly delayed recovery regarding neurosensory disturbances ($p<0.001$). The third study revealed that smoking, osteotomies performed in the mandible and additional number of

inserted fixation plates resulted in more plate removal. A majority of the patients were relieved from plate related complications after plate removal. In the fourth study no significant differences between the two anaesthetic protocols were found regarding: blood loss, operating time, recovery time, postoperative nausea and vomiting (PONV) and hospitalization. Remifentanil-propofol based TIVA facilitated haemodynamic stability. Long duration local anaesthetics (ropivacaine 7.5 mg/ml) administered at the end of surgery appears to improve mobilization of the patient and reduce hospitalization.

Conclusions. Morbidity was reduced when the twist drill was avoided prior the insertion of bone anchor screws in transalveolar positions. Steroids reduced facial oedema. The need for fixation plate removal was reduced when the numbers of inserted plates were minimized and smoking arrest was emphasized. Recovery from pain was enhanced when blood loss was minimized.

Key words. Intermaxillary fixation, iatrogenic root damage, osteotomy, sagittal split ramus, steroid, hypoesthesia, inferior alveolar nerve, risk factors, smoking, mandible, orthognathic surgery, anaesthesia, haemodynamic, remifentanil, ropivacaine, recovery.

Correspondence: Fredrik Widar, Department of Oral and Maxillofacial Surgery

Institute of Odontology, Sahlgrenska Academy, University of Gothenburg.

Box 450, SE-405 30, Gothenburg, Sweden. Email: fredrik.widar@vgregion.se

ISBN: 978-91-628-9386-6 (tryckt)

ISBN: 978-91-628-9387-3 (e-publicering)

CONTENTS

PREFACE

DEFINITIONS

ABBREVIATIONS

INTRODUCTION

Orthognathic surgery	1
Background	1
Maxillary osteotomies.....	1
Mandibular osteotomies.....	2
Genioplasty.....	2
Review of the literature.....	2
The future of orthognathic surgery	6
Intermaxillary fixation	7
Background	7
Anatomical positioning of the bone anchor screw	8
Surgical technique of the bone anchor screw (pre-drilled)	11
Surgical technique of the bone anchor screw (drill-free)	11
Bone anchor screws in orthognathic surgery.....	12
Osteosynthesis	13
Trigeminal nerve anatomy	14
Nerve morphology.....	14
Trigeminal nerve.....	15
Surgical anatomy & morbidity	17

Surgical considerations of the maxilla.....	17
Surgical considerations of the mandible	18
Nerve injury	20
Review of the literature.....	20
Causes of nerve injury.....	20
Compression.....	20
Laceration.....	21
Penetrating.....	21
Stretch	21
Ischemia.....	21
Classification of nerve injury	21
Neuropraxia.....	21
Axonotmesis.....	22
Neurotmesis.....	22
Nerve regeneration.....	22
Inflammation	23
Steroid characteristics	24
Corticosteroids.....	24
Anti-inflammatory and immunosuppressive effects.....	25
Administration.....	25
Glucocorticoids and pain	26
Glucocorticoids and facial oedema.....	27
Glucocorticoids and postoperative nausea and vomiting (PONV)	28
Glucocorticoids and neurosensory disturbances.....	29
Glucocorticoids and non-steroidal anti-inflammatory drugs (NSAIDs).....	29
Glucocorticoids and considerations	30

Analgesics	30
Non-opioid analgesics.....	30
NSAIDs.....	30
Paracetamol.....	32
Summary of none-opioid analgesics.....	32
Intraoperative local anaesthesia	32
Postoperative local anaesthesia.....	32
Recovery	33

AIMS	35
-------------------	----

MATERIAL & METHODS

Design	36
Patient selection	37
Prelude	37
Inclusion criteria.....	37
Exclusion criteria.....	38
Data collection	38
Quantitative data collection	38
Qualitative data collection	38
Questionnaire (paper III).....	38
Radiographic examinations	40
Hypothesis	40
Paper I.....	40
Paper II	40
Paper III.....	42
Paper IV	42

Basic study protocol and procedures.....	42
Paper I.....	42
Paper II.....	42
Paper III.....	43
Paper IV.....	44
Data collection proforma.....	45
Preoperative protocol.....	47
Clinical studies.....	47
Prophylactic antibiotics.....	47
Steroids.....	47
Local anaesthesia.....	47
Intraoperative protocol.....	47
Paper I.....	47
Paper II.....	48
Paper III.....	49
Paper IV.....	50
Postoperative protocol.....	50
Local anaesthesia.....	50
Analgesics.....	51
Prophylactic antibiotics.....	51
Follow-up.....	51
Statistical methods & analysis.....	51
Methods of statistic analysis.....	51
Statistical analysis (paper I).....	52
Statistical analysis (paper II).....	52
Statistical analysis (paper III).....	52
Statistical analysis (paper IV).....	53

Ethical considerations.....	53
------------------------------------	-----------

RESULTS

Study groups.....	54
Subjects	54
Mean age and range	54
Osteotomies (paper II-IV)	54
Osteotomies and genioplasty (paper II-IV).....	54
Paper I	54
Dental root injury	54
Surgical technique	54
Paper II.....	55
Facial oedema.....	55
Pain	55
Neurosensory disturbances	55
Steroids	55
Paper III	55
Fixation plate removal.....	55
Survival of plates.....	55
Plate related complications	56
Reasons for plate removal.....	56
Smoking.....	56
Osteotomy in the mandible (BSSO).....	56
Additional fixation plates	56
Operating time	57
Paper IV.....	58

Blood loss 58
Heart rate 58
Mean arterial pressure (MAP)..... 58
Recovery time at postoperative anaesthetic care unit (PACU)..... 58
Postoperative analgesics..... 58
Hospitalization..... 58

DISCUSSION

Methodological considerations59
Comments on material, methods and results59

CONCLUSIONS.....75

ACKNOWLEDGEMENTS76

REFERENCES.....79

PAPERS (I-IV).....95

PREFACE

This thesis is based on the following papers, which will be referred to in the text by their Roman numerals I-IV. They are reprinted with permission from the copyright owners.

- I. Widar F, Kashani H, Kanagaraja S, Dahlin C, Rasmusson L. A retrospective evaluation of iatrogenic dental root damage with predrilled vs drill-free bone anchor screws for intermaxillary fixation. *Dent Traumatol* 2012 Apr;28(2):127-31.
- II. Widar F, Kashani H, Alsén B, Dahlin C, Rasmusson L. The effects of steroids in preventing facial oedema, pain and neurosensory disturbances after bilateral sagittal split osteotomy: a randomized controlled trial. *Int J Oral Maxillofac Surg* 2015 Feb;44(2):252-8.
- III. Widar F, Afshari M, Rasmusson L, Dahlin C, Kashani H. Incidence and risk factors predisposing plate removal following orthognathic surgery. *Journal Craniomaxillofac Surg* 2014, SUBMITTED.
- IV. Widar F, Sköldstam J, Creutz J, Kashani H, Dahlin C. Effects of total intravenous anaesthesia versus balanced inhalation anaesthesia on haemodynamics and recovery in orthognathic surgery. *Journal Craniomaxillofac Surg* 2015, SUBMITTED.

DEFINITIONS

Allodynia	Pain due to stimulus that normally provokes pain
Autacoids	Any one of the substances produced locally by one group of cells that exert effects on other types of cells in the same region
Analgesia	Absence of pain in response to stimulation that would normally be painful
Anaesthesia	Absence of any sensation in response to stimulation that would normally be painful or not painful
Axon	The nerve fibre connecting the nerve cell body with the periphery, or distribution area of the nerve
Bimaxillary	Pertaining to both the upper and lower jaw
Corticosteroid	Any of the steroid hormones produced by the adrenal cortex or their synthetic equivalents
Genioplasty	An operation performed to reshape the chin
Hypoesthesia	Reduced sense of touch or sensation, or partial loss of sensitivity to sensory stimuli

Inferior alveolar nerve	Part of the mandibular nerve that runs in a canal through the mandible
Mandible	The lower jaw
Mandibular nerve	The lower branch of the trigeminal nerve
Neuron	A nerve cell including cell body, dendrite and axon
Neurosensory disturbances	A general expression for disturbed sensitivity
Occlusion	The relation in which the upper and lower teeth come together
Orthognathic surgery	Surgical procedures designed to establish proper jaw relationships and normal facial aesthetics
Osteosynthesis	A method of attaching bone fragments to each other. Examples of devices mentioned in the thesis are steel wire, screws, and combinations of screws and plates
Osteotomy	Surgical operation whereby a bone is cut to shorten, lengthen or change its alignment. The procedure is performed with saws, piezo-devices, burs, chisels and osteotomes
Sagittal split osteotomy	Osteotomy in the mandible along the nerve canal in order to shorten, lengthen, rotate or change its alignment. Also referred to as bilateral sagittal split osteotomy (BSSO)

Sensitivity

A physical sensation of modalities such as touch and temperature

Steroid

Steroid medicines are man-made but are similar to their natural hormones.

Trigeminal nerve

The nerve responsible for the sensitivity of the face

ABBREVIATIONS

AO	“Arbeitsgemeinschaft für Osteosynthesfragen”
BA	Balanced inhalation anaesthesia
BIS	Bispectral index
BSSO	Bilateral sagittal split osteotomy
ECG	Electrocardiography
IAN	Inferior alveolar nerve
IMF	Intermaxillary Fixation
IMFS	Intermaxillary Fixation Screws
MMF	Maxillo Mandibular Fixation (same as above)
OBA screws	Orthodontic Bone Anchor screws
PONV	Postoperative nausea and vomiting
RCT	Randomized clinical trial
SARME	Surgical assisted rapid maxillary expansion
TIVA	Total intravenous anaesthesia
TOF	Transmittor of four stimulators
TMJ	Temporomandibular joint (disorders
VAS	Visual analogue scale

INTRODUCTION

Orthognathic surgery

Background

Orthognathic surgery is a dynamic field including both art and science. The term orthognathic arise from the greek words orthos meaning straight and gnathos meaning jaw. Orthognathic surgery refers to surgical procedures of the facial skeleton used to restore the proper anatomical and functional relationship in patients with dentofacial skeletal deformities. These discrepancies of the facial skeleton, with either excess or deficiency of the jawbone, can be corrected between the upper- and the lower jaw, between the upper jaw and the base of the skull or in combination with adjustments of the chin (Reyneke, 2010).

Severe dentofacial deformities can be accompanied with malpositioned teeth, jaw malformations, masticatory dysfunction and aesthetic divergences. These patients may have functional and occasionally psychological problems due to their situation. The indications for treatment are therefore complex with functional, morphological and psychological aspects to be considered (Krekmanov, 1989). Oth-

er more specific indications for treatment are asymmetrical conditions due to congenital growth disturbances, tumour resections, sleep apnoea, tempo-ro-mandibular joint disorders (TMJ), orthodontic problems or malformations of the jaw due to post-traumatic malocclusion (Riley et al., 1993; Sailer et al., 1999; Becking et al., 2007). Treatment objectives include restoration of jaw function, optimal facial aesthetics and long-term stability (Bell et al., 1986).

Maxillary osteotomies

Maxillary osteotomies can be divided into three classes; Le Fort I, II and III (Le Fort, 1901). The most frequently used osteotomy in orthognathic surgery is the Le Fort I osteotomy. Additionally, it is possible to perform segmental maxillary osteotomies such as single tooth-, anterior segmental, posterior segmental, and horseshoe osteotomy or surgical assisted rapid maxillary expansion (SARME). The down-fracture technique with complete mobilization of the maxilla allows the maxilla to be positioned in all three planes of space. This makes it possible to correct asymmetries of the maxilla in relation to the base of the skull. Further indications for treatment may be maxillary antero-posterior ex-

cess or deficiency, and/or vertical maxillary excess/impaction. Conventional Le Fort I osteotomy without segmentation, is considered safe for corrections of deformities related to the maxilla (Panula et al., 2001). But many centres also regard segmentation as a safe method without complications (I. Silva et al., 2013).

Mandibular osteotomies

Bilateral sagittal split osteotomy (BSSO) is currently the most common method used to correct mandibular prognathism, retrognathism or asymmetry of the mandible. BSSO allows for setback or lengthening and correction of asymmetry in one operation. The technique is possible to combine with distraction osteogenesis. There have been various techniques, all designed with the intent of minimizing morbidity and maximizing adequate bone healing and stability (Dal Pont, 1961; Hunsuck, 1968). BSSO has been proven to be safe over time with predictable and stable results and few serious complications. The method is beneficial for the patient and provides a high degree of satisfaction, often because of both improved facial aesthetics and improved masticatory function (Blomqvist et al., 1998; Panula et al., 2001). Neurosensory disturbanc-

es of the inferior alveolar nerve remain as the main drawback of the operation (Westermarck et al., 1998c; Nesari et al., 2005).

Genioplasty

Genioplasty is used to address a variety of facial concerns from a balancing procedure in conjunction with orthognathic surgery in the support of soft tissue contours for patients undergoing elective facial surgery (Rieck, 2013).

Review of the literature

The first surgeon describing a segmented osteotomy of the mandible was Hullihen (1849). Blair (1907) later described a horizontal ramus osteotomy for mandibular advancement or setback. The technique, which was performed transcutaneously with a Giggly saw, was oppressed with instability and frequent facial nerve disturbances. Therefore, the development of the intraoral split technique of the mandible was initiated (Schuchardt, 1942). The sagittal split ramus technique was introduced worldwide by Trauner and Obwegeser, and modified by Dal Pont, through an "oblique retromolar osteotomy". Hence, the bony interface increased by advancing the lateral and vertical cut towards the second molar

region (Trauner and Obwegeser, 1957; Dal Pont, 1961). A further modification of the sagittal split osteotomy was suggested so that the method could be used for cases of prognathism, retrognathism and open-bite cases (Hunsuck, 1968). All three techniques described by Obwegeser, Dal Pont and Hunsuck, required tunnelling of the lingual pterygo-mandibular space with only minimal muscular and periosteal stripping. Obwegeser et al., (1957) revolutionized oral and maxillofacial surgery when introducing the BSSO as a standardized safe procedure today used worldwide. Bell & Schendel (1977) opened the discussion regarding biological issues such as muscles and temporo-mandibular joint function involved with the procedure. Stripping of the muscular attachments was suggested in order to inhibit muscular strain and furthermore the need for complete osteotomy of the inferior mandibular cortex was emphasized to avoid bad splits (Bell and Schendel, 1977; B. N. Epker, 1977). These findings were recently confirmed by (Beukes et al., 2013).

Following the foundation of the "Arbeitsgemeinschaft für Osteosynthesfragen" (AO) at Biel, Switzerland (1958), the next revolution started affecting the BSSO technique. Spiessl

(1976) introduced rigid internal fixation in the form of inter-fragmentary bone screws (lag screws). It was shown that bone screws added to the stability of the fragments and decreased healing time because of fragment compression osteosynthesis. The use of thin bone saws over thicker burs was favoured in order to save the bone and minimizing the gap between the split osteotomies. Furthermore, he modified the osteotomy technique by removing the lingual aspect of the cortical bone plate covering the oblique line in order to create a good overview of the cancellous and cortical bone structures of the retromolar lingual mandible.

Nevertheless, neurosensory disturbances remained as a significant problem. New techniques with the computed tomography (CT) scan technology gained new knowledge regarding the position of the nerve. It was suggested that the location of the anterior buccal osteotomy should be located in the region of the first molar for the safety of the inferior alveolar nerve. The reason was that the neurovascular bundle is most often located in contact with the buccal cortex in the region posterior of the second molar (Rajchel et al., 1986). Early mobilization of the jaws in contrast to rigid postoperative

intermaxillary fixation (IMF) was introduced with the intention to mobilize the temporo-mandibular joint (Wolford et al., 1987). The existing split techniques resulted in a high lingual split, often making it impossible to place the inferior third bone screw. A new concept of the inferior border split was therefore introduced, with improved saw technique of the lower cortical boarder, thus leading to a lower lingual split, which less frequently resulted in nerves found in the proximal segment (Wolford and Davis, 1990).

Rigid internal fixation has been state-of-the-art since the 80s. The advantages were obvious: no rigid postoperative IMF was necessary, increased comfort for the patient, mobilization of the temporo-mandibular joint and stabilization of bony fragments without the use of wire osteosynthesis. Sagittal split osteotomies can be fixed in three ways: using bicortical lag screws, bicortical position screws or miniplates with monocortical screws. Three bicortical screws are usually used, engaging the buccal cortex of the proximal fragment and the lingual cortex of the medial fragment. Position screws have threads that engage both cortices, which results in less compression of the fragments, in comparison with the lag

screw. The small osteosynthesis plates with monocortical screws for trauma and orthognathic purposes were introduced in the early 70's, presenting the term "functional stability" in contrast to rigid compression osteosynthesis as defined by AO (Michelet et al., 1971).

Westermarck presented a thesis (1999), on inferior alveolar nerve function after sagittal split osteotomy. He found neurosensory disturbances in the lower lip and chin in 40 % of the operated sides. Half of these disturbances were mild and half were considered more pronounced. Nerve damage was suggested to be a result of dissection and compression. Al-Bishri et al., (2004) presented results on factors affecting neurosensory disturbances after mandibular osteotomies. He showed that perioperative steroids might decrease neurosensory disturbances and experimental studies confirmed these findings, also showing that steroids may facilitate nerve healing.

Development of surgical techniques has moved further with modern equipment. The ultrasonic bone cutting surgery, also called piezosurgery, is a medical device that allows efficient cutting of mineralized hard tissues with minimal trauma to soft tissues. Critical structures such as ves-

sels and nerves can be managed with a minimum of trauma. This is particularly important in occasions of a “bad split”. Thus, the split procedure can safely be carried on with minimal risk for nerve damage (Olate et al., 2014). Hence, the split can be performed without sharp instruments and therefore many clinicians are in favour of the piezo-technique (Bockmann et al., 2014).

Evaluation methods for neurosensory disturbances, described in the literature, vary from strictly objective to strictly subjective. There is a wide variation in the reported incidence of inferior alveolar nerve injury due to lack of standardized assessment procedures and reporting (Agbaje et al., 2014). Furthermore, neurosensory disturbance sequelae consolidate the need to proceed with validated evaluations regarding changes in quality of life (QoL) using either generic oral quality of life or oral-related quality of life investigations or condition specific approaches such as the Orthognathic Quality of Life Questionnaire (OQLQ) (Choi et al., 2010).

The vertical ramus osteotomy technique was initially described as an extraoral procedure by Limberg (1925) and Caldwell and Letterman (1954). Disadvantages with the tech-

nique were visible postoperative retro-mandibular scars of the skin, condylar sag, necrosis of parts in the proximal segment and the need for postoperative IMF. The intraoral approach eliminated the disadvantages of the retromandibular scars (Moose, 1964). The remaining disadvantages for vertical ramus osteotomy is suitable only for mandibular setback and the need for postoperative IMF. Main advantages for the vertical osteotomy technique, in comparison with BSSO, is an alternative therapy to rotate the mandible and the low incidence of neurosensory disturbances, which ranges approximately from 0 - 35% (Al-Bishri, Dahlberg, et al., 2004; Hoenig, 2007).

The maxillary Le Fort osteotomies originate from classifications of facial fractures described by the French physician Rene Le Fort (Le Fort, 1900, 1901). The technique of the Le Fort I osteotomy, was first described by Cheever (1864) for the resection of a rhino-pharyngeal tumour (Halvorson and Mulliken, 2008). Development of the Le Fort I osteotomy for orthognathic purposes was developed in order to perform a partial osteotomy in which the segments were moved into the planned position with elastics (Wassmund, 1927). The technique

with a mobilized Le Fort I osteotomy allowed for open bite corrections (Axhausen, 1934). A segmented maxillary osteotomy with palatal elevation combined with mid-palatal osteotomy was developed and performed (Converse and Shapiro, 1952). The importance of close collaboration between the surgeon and the orthodontist was stressed (Converse and Horowitz, 1969). Development of the Le Fort I technique was enhanced, with the down-fracture technique, for complete maxillary mobilization (Hogeman and Wilmar, 1967; Stoker and Epker, 1974; B.N Epker and Wolford, 1975; Bell et al., 1988).

Dentofacial deformities were treated before (1965), mainly with mandibular osteotomies even though the skeletal problems were present in the maxillary bones. The outcome was therefore in many cases poor and not aesthetically satisfactory. The introduction of “two jaw surgery” also called bimaxillary osteotomies, with simultaneously mobilization of the maxilla and mandible, solved these issues (Obwegeser, 1970).

The genioplasty with an extraoral submental approach, performed as a sliding osseous genioplasty, was first described on cadavers (Hofer, 1942). The technique was thereafter

fully developed on patients (Trauner and Obwegeser, 1957). Postoperative concerns such as “witch’s chin” and “deep submental fold” were addressed during the 1970s, which resulted in modifications of the technique (Gonzalez-Ulloa, 1972; Loeb, 1978; Field, 1981).

The future of orthognathic surgery

Successful outcome of the orthognathic treatment require preoperative, intraoperative and postoperative considerations with a multimodal approach in order to achieve the ultimate goal of a pain and risk free operation. Future developments within the orthognathic field should focus on multimodal approaches with combined effects of regional anaesthetic techniques, minimal invasive surgery and pharmacological modification of inflammatory responses. Provided that orthognathic surgery is considered as a safe and predictable therapy, surgical morbidity is still associated with undesirable sequelae such as damage to teeth, facial oedema, pain, neurosensory disturbances, prolonged recovery and removal of titanium plates due to infection or discomfort (Bockmann et al., 2014).

Intermaxillary fixation

Background

Surgical correction of jaw deformities includes improvement of occlusion and masticatory function. Application of IMF during surgery is the best way to place the osteotomized segments in proper positions (B. N. Epker and Fish, 1986). Intraoperative predictable anchorage of the occlusion is therefore a major keystone in the implementation of orthognathic planning during surgery. IMF during orthognathic surgery is most commonly performed with reinforced orthodontic appliances due to the heavy muscular strain when repositioning the jaws.

Nevertheless, progress in development of new techniques for IMF started within the field of maxillofacial fracture surgery, and the literature contains several studies evaluating different techniques used in promotion to control the occlusion. IMF techniques have evolved exponentially from awkward, painful and time-consuming procedures with wiring and arch bar fixation, to the current rapid and efficient techniques, with the intermaxillary fixation screw (IMFS) technique (Ingole et al., 2014). The previous techniques used in both fracture treat-

ment and occasionally in orthognathic surgery (in cases without orthodontic appliances) such as; interdental wiring, Erlich's arch bar and Gilmer's wiring were inexpensive and simple, but have various inherent drawbacks. Most of these techniques require wires to be tightened around the teeth, which can cause ischemic necrosis of the marginal gingiva, trauma to the adjacent mucosa and therefore subsequently discomfort for the patient. The constant traction applied on the engaged teeth can also make the teeth extrude (Shephard et al., 1982). Additionally, these techniques cannot be used in patients with partially edentulous dentition or extensive crown and bridgework. However, long term deleterious effects on teeth and periodontal tissues due to interdental wiring were shown to be uncommon (Thor and Andersson, 2001).

In 1989, Arthur and Berardo introduced a simplified technique for IMF using cortical bone screws. These bone anchor screws offered several advantages over traditional IMF with archbars: speed of application, the possibility to insert under local anaesthesia, increased comfort for the patient, minimal hardware, less complicated oral hygiene, decreased trauma to the periodontium and could

be removed relatively painless. A pilot drill was used, in this pre-drilled technique, through the stretched mucosa and into the bone where the screw was inserted. Wires or elastics could be used between the bone screws for temporary intraoperative or postoperative IMF. The most important benefit with the IMFS has been shown to be the significant savings in time and costs, especially when comparing with arch-bars due to the prolonged time for general anaesthesia. IMFS can be placed and removed in less than 15 minutes, whereas arch bar placement can take 45 - 100 minutes for placement and removal (Vartanian and Alvi, 2000). Since the introduction of IMFS, the technique has been received with enthusiasm but also criticism, mainly due to anatomical positioning near critical structures and subsequently with morbidity such as iatrogenic dental root damage (Karlis and Glickman, 1997; D. C. Jones, 1999; Holmes and Hutchison, 2000; Farr and Whear, 2002).

Anatomical positioning of the bone anchor screw

Different approaches regarding positioning of the screws have been described in the literature. Initially, manufacturers recommended placement

of self-tapping bone anchor screws in location above the root apices in the maxilla and near the piriform rim area or the zygomatic buttress region. The placements of the screws in the mandible were initially recommended below the root apices and between the mental foramina (Figure 1) (Gordon et al., 1995). However, these positions are only suitable intraoperatively and not always possible to achieve in severe cases of malocclusion and/or great inclination of the teeth. This due to the long distance between the bone anchor screws, which occasionally interferes with the vector of the wires applied to the screws. Further limitations are overgrowth of mucosa, especially when the screws are positioned in the non-keratinized lining mucosa, which can cause severe inflammation adjacent to the screws, and subsequently with great discomfort for the patient.

Further development of the IMFS technique resulted in positioning of the bone anchor screws in the dentoalveolar bone and adjacent to the dental roots. Fabbroni et al., (2004) were the first describing this technique as transalveolar approach. The benefit of positioning the bone anchor screws in these transalveolar and horizontal positions

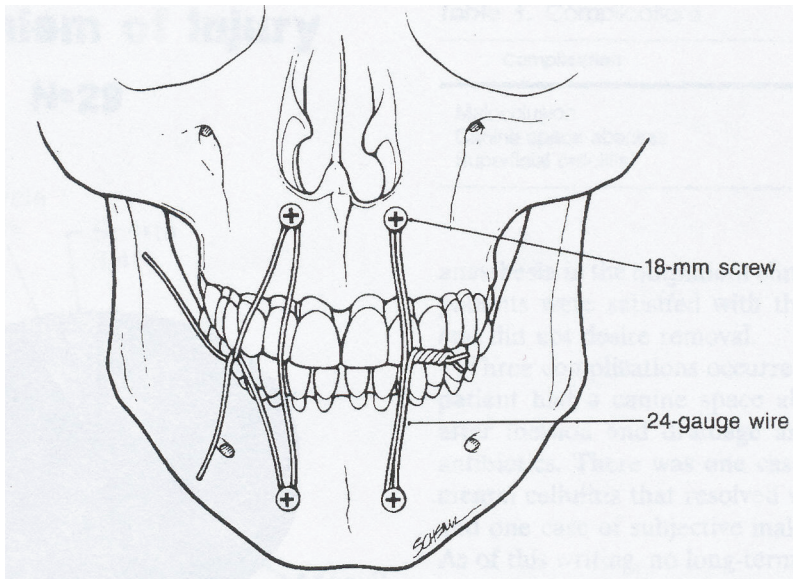


Figure 1. Cortical bone screws placed above the teeth roots (Gordon et al., 1994).

was obvious in regard to the possibility of using the screws during several stages during the surgical treatment; preoperative, intraoperative and finally leaving the screws in place postoperatively in cases of guided elastics in order to correct the occlusion. The transalveolar approach shortens the distance between the bone anchor screws, which makes it easier to place the wires in stable positions. Furthermore, it is possible to find multiple options for screw placements between all the teeth in the dentition (Figure 2 & 3). In order to minimize inflammatory reactions and overgrowth of mucosa, the screws

should be inserted in the keratinized attached mucosa between the teeth and in transalveolar positions. However, the IMFS are not without disadvantages and common sense bases on solid anatomical knowledge must be undertaken before insertion of the screw. Injudicious placement of these screws may cause damage to the adjacent dental roots, dental apices, perforation of the maxillary sinus and damage to the mental nerve. The insertion of screws may be hazardous in dental crowded situations with limitations of space. Anatomical considerations are therefore continuously essential although new screw

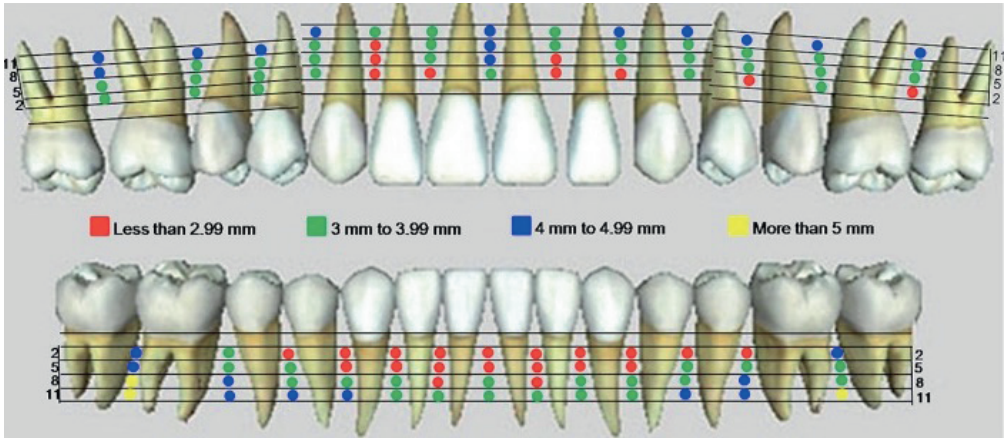


Figure 2. 3D anatomical mapping for safe and danger zones based on the mesiodistal distance in the maxilla and mandible (Courtesy of Dr. Purmal 2013).

techniques are introduced. 3D mapping for optimal positions versus danger zones for placement and insertion of bone anchor screws have been evaluat-

ed in respect to the mesiodistal (Figure 2), and buccopalatal versus buccolingual distance of the dentoalveolar bone (Figure 3) (Purmal et al., 2013).

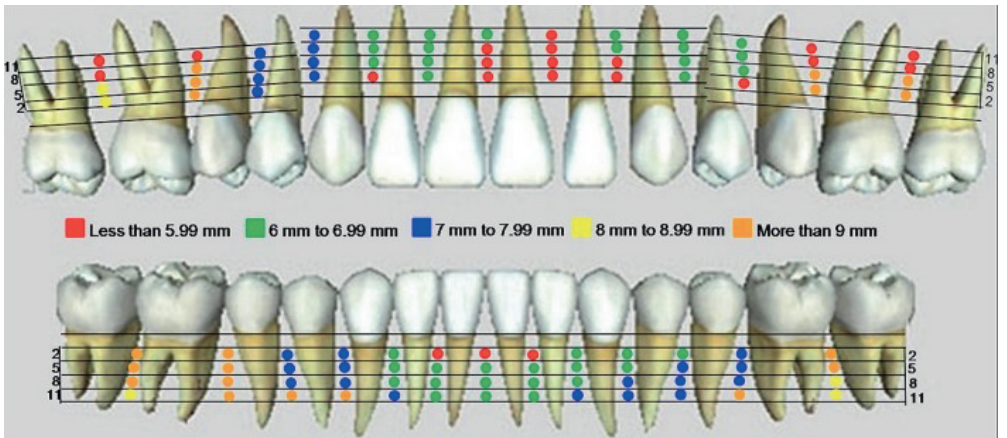


Figure 3. 3D anatomical mapping for safe and danger zones based on the buccopalatal distance in the maxilla, and the buccolingual distance in the mandible (Courtesy of Dr. Purmal 2013).

Surgical technique of the bone anchor screw (pre-drilled)

The first generation of IMFS were simply modified mono-cortical self-tapping screws because they required a drilled-hole for placement. However, there were concerns about suboptimal placement and consequently root damage that could occur during insertion. Coburn et al., (2002) recommends careful procedure during drilling of the bur hole with slow speed and copious irrigation with sterile saline. Complications such as fracture of screws on insertion, iatrogenic dental root damage, and bone loss due to bony sequestrs were described. Fabbroni et al., (2004) evaluated a pre-drilled technique and described the injuries as minor or major contacts to the dental roots, although concluding permanent dental iatrogenic dental damage as low. Roccia et al., (2005) described a technique with pre-drilled holes at the junction of the attached and mobile mucosa. Iatrogenic injury to dental roots was the most important issue of the procedure although they purposed that the risk could be minimized by an experienced surgeon.

Surgical technique of the bone anchor screw (drill-free)

The second generation of IMFS, presented for the use within the field of oral and maxillofacial surgery, improved technical and tactile feedback during insertion and therefore limiting the possibility of root damage. Additionally, because power equipment is not needed, the system can be used outside the operation room. These screws are described as drill-free, self-drilling and self-tapping bone anchor screws (Roccia et al., 2009). Coletti et al., (2007) showed that the technique is safe, time sparing, although not without limitations or potential consequences, which the surgeon must be aware of in order to provide safe and effective treatment. Complications such as screw loosening with potential risk for ingestion, aspiration and dental root fracture were mentioned. Roccia et al., (2009) reported that there was no risk of dental lesions due to the bone anchor screws. Minor complications such as loosening of screw and coverage of oral mucosa were mentioned. Son et al., (2014) evaluated the primary stability of self-drilling and self-tapping orthodontic mini screws. Mini screws that endured orthodontic forces (7.5 Ncm) six months or more were considered successful. However, mini screws with dental root contact had greater

mobility, which emphasises the importance of positioning the screws in solid bone. Additionally, bicortical bone anchorage with IMFS reduced bone stress, and added superior stability compared with mono-cortical screws (Brettin et al., 2008). Asscherickx et al., (2005) evaluated bone anchor screws in an animal-experimental study. Histological examination showed almost complete repair of periodontal structures within 12 weeks following removal of screws. Dao et al., (2009) evaluated the IMFS in an animal model, confirming these findings with the conclusion that when titanium IMFS penetrate root cementum or dentin, pulpal necrosis and/or inflammation were not observed at 12 week after surgery.

Bone anchor screws in orthognathic surgery

Orthognathic surgery treatment conventionally relies on the use of full arch fixed orthodontic appliances. However, these orthodontic appliances must resist the muscular strain due to movements of the segments during the surgical procedure. Occasion-

ally these appliances may partly loosen during surgery and may subsequently result in inadequate occlusion. Temporary bone anchor screws in transalveolar, horizontal and bicortical positions may in these circumstances serve as a temporary reinforced rigid emergency bone anchor for proper IMF. Ueki et al., (2007) showed that the use of IMFS was helpful for orthognathic surgery as rigid bone anchor for IMF in cases when setback amount or counter-clockwise rotation is large due to a significant extrusive load to the anterior teeth (Figure 4).

However, the introduction of orthodontic bone anchor screws and further development of the screw design has introduced the mini-im-

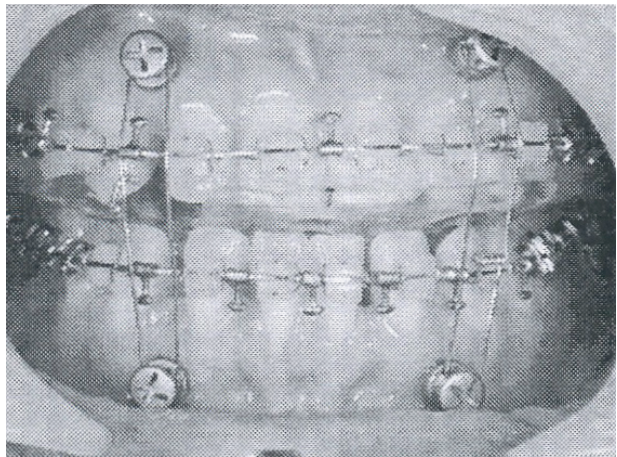


Figure 4. Method of IMFS anchorage during orthognathic surgery (Ueki et al., 2007).

plants that have altered surgical options in terms of providing an alternative to IMFS. Different shapes and sizes are provided such as cylindrical or conical, miniplate implants and disc implants. These bone anchor screws can be osseointegrated or non-osseointegrated. The application can be for orthodontic purposes and/or prosthodontics purposes (Papadopoulos and Tarawneh, 2007). These new techniques may be useful in new treatment modalities in the correction of dentofacial disorders without surgery or new therapy modalities such as “surgery first” before the orthodontic treatment starts (Im et al., 2014).

Osteosynthesis

The osteosynthesis technique with fixation plates was introduced for open reduction and internal fixation of fractures and osteotomies in the facial skeleton. The basic of the technique was that the function of the masticatory apparatus was determined by the state of the occlusion, and that the new technique reached the specific requirements, which were guided by remodelling of the face and safekeeping of functions (Michelet et al., 1973). The new and small fixation plates made the

intraoral route possible and further allowing simultaneous reduction of osseous fragments with small incisions in contrast to previous early bulky plates. Additional advantages with the internal fixation systems involving plates and screws, was the avoidance of post-operative IMF that may be hazards to the airway, and a more rapid turn after surgery to normal function including mobilization and jaw opening (Brown et al., 1989; Spiessl, 1989). These first plates introduced were made of vitallium or stainless steel and removal of the plates once they had ceased to function was advocated as part of the treatment. The Strasbourg Osteosynthesis Research Group (SORG) founded in 1988 as a team of independent, dedicated surgeons working for the scientific and technical advancements in oral and cranio-maxillofacial surgery, made the following recommendations at a symposium in Volendam, Netherlands in 1991: “A plate which is intended to assist the healing of the bone becomes a non-functional implant once the role is completed. It may then be regarded as a foreign body. While there is no clear evidence to date that a plate causes actual harm, our knowledge still remains incomplete. It is therefore not possible to state with certainty that an otherwise

symptomless plate, left in situ, is harmless. The removal of a non-functioning plate is desirable provided that the procedure does not cause undue risk to the patient”.

Titanium is currently the material of choice for internal fixation systems within the field of orthognathic surgery. The excellence and biocompatibility of titanium and its relation to the bone, was stated through the innovation of osseointegration with dental implants, and was scientifically evaluated by Professor Per-Ingvar Brånemark et al., (1969). Titanium is considered to be non-carcinogenic, resistant to corrosion, non-toxic and without allergic associations (Haug, 1996). Langford et al., (2002) evaluated tissue changes adjacent to titanium fixation plates in patients. All of the soft tissues showed fibrosis. Pigmented debris was present in 70% of the specimens and identified as titanium. The debris was predominantly extra-cellular and was not associated with any inflammatory response or giant cell reaction. Eppley et al., (1993) stated that titanium does not contraindicate the use of magnetic resonance imaging (MRI), produces no high density scatter in computer tomography (CT), offers no interface with complex three dimensional CT reconstructions

and is compatible with radiography.

In most maxillofacial units it is a routine policy not to remove titanium plates and screws following bony union, in contrast to the previously mentioned stainless steel plates (Brown et al., 1989). However, removal of inserted titanium fixation plates are indicated in cases of plate related complications or if requested by the patients because of subjective discomfort. The incidence of plate removal within the field of orthognathic surgery varies between 10.0 % and 27,5% (Alpha et al., 2006; Theodossy et al., 2006; Haraji et al., 2009; Kuhlefeldt et al., 2010; Falter et al., 2011). Previous studies have showed that smoking is a risk factor and predictor for titanium fixation plate removal. The role of infection appears to be another major reason for plate removal in several studies (Falter et al., 2011). Theodossy et al., (2006) showed that the operating time was a significant risk factor for plate removal.

Trigeminal nerve anatomy

Nerve morphology

A nerve consists of a cordlike structure that contains many axons, also called nerve fibers. Within each nerve, a layer of connective tissue called en-

doneurium surrounds each axon. The axons are bundled together in groups called fascicles, and each fascicle is wrapped in a layer of connective tissue called perineurium. The entire nerve is wrapped in a layer of connective tissue called epineurium. Vascular networks are contained within the epineurium to supply the capillaries of the endoneurium. Greater nerve trunks are suspended in a layer of connective tissue called mesoneurium. The layers of connective tissue define the nerve, and protect it from mechanical stress. Myelinating nerves include Schwann cells that support the neuron and coat each axon. In non-myelinating nerves, one Schwann cell supports the neuron, through several axons. Schwann cells are involved in many important aspects of the peripheral nerve biology through conduction of nervous impulses along axons, nerve development and regeneration (Gartner and Hiatt, 2001).

The axon is the extension of a neuron and is characterized by morphology, conduction velocity and function. A-alpha fibres are the largest myelinated fibres and functionally they encode for transmission of muscle spindle and tendon organ afferents and skeletal muscle efferents. A-beta fibres are the next largest myelinated axons

with the function of transmitting signals for sensation of touch. A-delta fibres are the smallest myelinated fibres with the function to transmit stimuli encoded for temperature and pain. C-fibres are the smallest axons and without myelination. These fibres transmit stimuli encoded for slow or referred pain, temperature and efferent sympathetic fibres (Gartner and Hiatt, 2001).

Trigeminal nerve

The trigeminal nerve (nervus trigeminus V) is the largest and the most complex of the twelve cranial nerves. The nerve has three divisions; the ophthalmic V1, maxillary V2 and mandibular V3s. The large sensory root and the smaller motor root leave the brainstem at the midlateral surface of pons. The sensory root terminates in the largest of the cranial nuclei, which extends from the pons all the way down into the second level of the spinal cord. The sensory root joins the trigeminal or semilunar ganglion (Gasserian ganglion) at the base of the skull. The motor root originates from cells located in the masticatory motor nucleus of the trigeminal nerve located in midpons of the brainstem. The motor root passes through the trigeminal ganglion and combines with the corresponding sensory root to

become the mandibular nerve. It is distributed to the muscles of mastication. The three sensory branches of the trigeminal nerve proceeds from the ganglia to form the three branches of the trigeminal nerve (Heinz, 1984).

The ophthalmic V1 branch (sensory) runs in the wall of the cavernous sinus and exits the skull through the superior orbital fissure. Before entering the superior orbital fissure, the nerve is divided into the smaller frontal (supratrochlear and supraorbital branches), lacrimal (parasympathetic supply), the nasociliary branches (ciliary, infratrochlear and ethmoid branches) and the ciliary ganglion (parasympathetic supply - sensory root support of the eyeball). The parasympathetic ciliary ganglion controls m. sphincter papillae and m. ciliaris (Heinz, 1984).

The maxillary V2 branch (sensory) runs in the wall of the cavernous sinus. One branch remains in the cranium (middle meningeal). Three branches are divided after exit through foramen rotundum. The first branch divides in the pterygopalatine fossa (zygomatic branches, pterygopalatine ganglion, posterior & superior & alveolar nerves). The second branch constitutes and divides from the infraorbital nerve

(anterior & middle & posterior superior alveolar and internal nasal branches). The third branch divides on the face (inferior palpebral, external nasal, superior labial and infra orbital plexus). The parasympathetic pterygopalatine ganglion receives fibers from the greater petrosal nerve (n. facialis VII) and innervates the lacrimal gland, palate and nasal mucosa that regulate heat or cools the air in the nose (Heinz, 1984).

Mandibular V3 branch (mixed) constitutes of a large and a small sensory root which units into a nerve trunk after exit from foramen ovale. Three branches are divided after exit from the skull. The first branch enters the skull through foramen spinosum following the middle meningeal artery and innervates the dura mater. The second anterior branch innervates the muscles of mastication: masseteric, deep temporal, medial pterygoid, tensor veli palatine and lateral pterygoid, with the exception of the buccal nerve, which is a sensory branch. The third posterior branch follows the medial surface of the ascending ramus and divides into two branches: auriculo-temporal (sensory), lingual (sensory) and inferior alveolar (mixed). The inferior alveolar branch divides in two and innervates the teeth & gum (sensory)

and the anterior part of the mylohyoid and digastricus muscles (motor). The parasympathetic otic ganglion divides from the pterygopalatine fossa and innervates the parotid gland. The parasympathetic submandibular ganglion innervates the external carotid plexus, the sublingual gland, the submandibular glands and the oral salivary glands (Heinz, 1984).

The sensory portions of the trigeminal nerve supplies touch, pain and temperature to the face. The innervation includes: the cornea and conjunctiva of the eye, mucosa of the sinuses, nasal and oral cavities, the dura of the anterior, middle and part of the posterior cranial fossae. The mandibular part conveys proprioceptive impulses from the temporo-mandibular joint (Heinz, 1984).

The motor division of the trigeminal nerve produces elevation, depression, protrusion, retraction, and side-to-side movements of the mandible (Heinz, 1984).

Surgical anatomy & morbidity

Surgical considerations of the maxilla

The maxilla is the second largest bone of the face. It contributes to the for-

mation of the face, nose, mouth, orbit, infraorbital and pterygopalatine fossa. The maxilla consists of a body and on each side with four processes: frontal, zygomatic, alveolar and palatine. Four surfaces encloses and defines the anatomy: anterior or facial, posterior or infratemporal, medial or nasal, superior or orbital) and encloses the maxillary sinus.

The principles of the Le Fort I technique are based on surgical and anatomic techniques that aim to maintain the soft tissue pedicle and thereby the blood supply of the bone tissue. The surgical approach includes limitation of the incision up to the first molars bilaterally and not detaching the gingival mucosa. By cutting the superior alveolar and the nasopalatine arteries through the osteotomies of the lateral parts of the maxilla and the nasal septum, the blood supply to the bone then comes from the descending palatine artery and from the microvasculature of the palate and the gingiva. Nevertheless, reservation of descending palatine arteries does not seem to be determinant to vascular blood flow to the osteotomized maxilla. The exceptions are unfavourable factors such as segmented surgery in combination with ligation of the artery and major

movements such as superior positioning and transverse expansion. Major intraoperative or postoperative bleeding associated with Le Fort I osteotomies can be venous and/or arterial. Maxillary haemorrhage generally involves the maxillary artery and its terminal branches. Arterial haemorrhage tends to be more persistent and can be recurrent, which makes it more difficult to manage. Other complications mentioned in the literature are trigeminal nerve injury, oronasal fistula and dental injuries (Lanigan et al., 1990; Tung et al., 1995; Kahnberg, 2007).

Surgical considerations of the mandible

The mandible is the largest bone of the face with a horseshoe shaped body, which is curved horizontally. Two rami ascend vertically and posteriorly with two processes, one condylar and the other is the coronoid process. The upper border of the body bears sockets for the teeth and the lower border makes the base of the mandible. The angle connects the rami and the body. The neurovascular bundle enters the mandibular foramen and runs within the mandibular body until it exits at the mental foramen (Heinz, 1984).

The sagittal split pro-

cedure includes bone cuts of the bone cortex on the medial and lateral sides with a reciprocating saw, a Lindemann bur or recently with the piezosurgical device. The split is performed with osteotomes and a bone spreader. Care must be taken in order to perform an accurate split and simultaneously identify the position of the neurovascular bundle in order to handle it with care. The nerve can be visible or embedded in the cancellous bone. Manipulation of visible nerves should be avoided. Thus the split most commonly is performed bilaterally, the position of the nerve can differ between the two sides. Embedded nerves in the cancellous bone may function directly or recover quickly within weeks postoperatively. A visible nerve most commonly loses sensitivity the first months, thus most commonly recover thereafter within six months and up to one year (Kuhlefeld et al., 2014).

Anatomical variations in the course of the inferior alveolar neurovascular bundle are described in several studies with great variability (Daw et al., 1999). Classification of the nerve in the vertical aspect is described by McManners (2000): I. The nerve has a course near the apices of the teeth, II. The main trunk is low down in the

body, III. The main trunk is low down in the body of the mandible with several smaller trunks to the molar teeth. Rajchel et al., (1986) reported specifically on the mediolateral position of the nerve canal thus suggesting that their study material favoured the extension of the sagittal osteotomy cut into the area of the first molar for the following reason: I. The buccal cortical plate is thicker, II. The total mandibular body width is thicker, III. The distance between the inner aspect of the buccal cortical plate and the mandibular canal is consistently greater in that location.

The frequencies of neurosensory disturbances after BSSO in patients with class III cases depend not only on the position of the mandibular canal, but also on the length of the mandibular angle. A lateral course of the mandibular canal and long mandibular angle appear to result in a high risk of injury to the inferior alveolar nerve (Yamauchi et al., 2012).

The primary sensory innervation to the chin area is from the paired mental nerves that exist the body of the mandible near the apices of the premolar teeth and through foramen mentalis. In cases of genioplasty the osteotomy must stay at minimum 4.5 mm below the mental foramen to

avoid nerve injury. Reported incidences of nerve injuries are reported to be as high as 12%. The primary muscle involved with the genioplasty is the mentalis muscle, which provides the primary vertical support to the lip. It is important to maintain a broad pedicle to the chin for sufficient blood supply of the osteotomized segment. Improper repositioning of the mentalis muscle can result in delayed healing and occasionally deformities of the chin. The primary motor component to the muscles associated with the anterior aspect of the chin is from the buccal and marginal mandibular branches of the facial nerve VII. These muscles include the depressor labii inferior, depressor anguli oris, mentalis and orbicularis oris muscles. The lingual muscle pedicle of the genioplasty will include the geniohyoid, mylohyoid and anterior digastric muscles, which obtain their innervation from the hypoglossal nerve XII (geniohyoid) and inferior alveolar nerves (Westermarck et al., 1998a; Hwang et al., 2005).

Soft tissue complications are most commonly related to improper mentalis muscle reattachment. Loss of tooth vitality, defective ossification and lip incompetence are rare complications commented in the literature (Kim et al., 2002).

Nerve injury

Review of the literature

One of the major drawbacks with the orthognathic procedure BSSO is a varying degree of postoperative neurosensory disturbances of the lower lip and chin due to direct or indirect intraoperative injury to the inferior alveolar nerve. Reported incidence of nerve injuries varies from 5 - 85%, which likely reflects non-standardized methods of neurosensory testing and the duration from operation to evaluation (August et al., 1998). Neural impairment is thought to be influenced by multiple causal factors such as: fixation methods (Fujioka et al., 1998; Stoelting and Borstlap, 2003), the patient's age (Blomqvist et al., 1998; Al-Bishri, Rosenquist, et al., 2004), magnitude of mandibular movement (Ylikontiola, Kinnunen, & Oikarinen, 2000), postoperative swelling and the "bad split" (D. L. Jones et al., 1990) Fujioka et al., (1998) reported that monocortical osteosynthesis caused less damage to the inferior alveolar nerve compared to position screws. Some surgeons have suggested that compressive forces can occur when fixing the two mandibular segments together with compression (Nesari et al., 2005). Soft tissue dissection on the me-

dial aspect of the mandibular ramus due to protection of the nerve and/or surgical trauma to the neurovascular bundle (Westermarck et al., 1998c), setback or advancement (Ylikontiola, Kinnunen, & Oikarinen, 2000) and various types of osteosynthesis techniques have been discussed as the cause to nerve trauma. These nerve traumas, which potentially might disturb the nerve function, have been described as compression, lacerations and/or stretching of the inferior alveolar nerve.

Causes of nerve injury

Compression

External pressure from adjacent structures may cause nerve compression and therefore nerve injury. These injuries might result from crush injuries, pressure from fractures, haematoma, blunt injury and as in the compartment syndrome where swelling of tissues in a closed muscular compartment results in compression of the nerve or its blood supply. It has been suggested that dissection techniques on the medial aspect of the mandibular ramus aiming to protect the nerve might disturb the nerve function (Bouwman et al., 1995; Westermarck, 1999; Robinson, 2004; Campbell, 2008).

Laceration

A blunt or penetrating injury causes irregular patterns of nerve damage mainly due to injuries with slight cuts due to sharp bone fragments or osteotomes (Campbell, 2008).

Penetrating

These injuries result in partial or complete rifts of the nerve due to sharp objects such as an injection needle (Robinson, 2004).

Stretch

These injuries are defined as a “sudden stretch” of the nerve during dislocation of fragments due to violent traction. The stretch trauma can occur during the BSSO and between medial and proximal segments during mobilization (Takeuchi et al., 1994; Robinson, 2004).

Ischemia

All nerve traumas include more or less severe ischemia due to injury of the vascular networks. Compression trauma follows with ischemia and results in more severe nerve injuries (Campbell, 2008).

Classification of nerve injury

Classification of nerve injury was de-

scribed by Seddon (1943) and by Sunderland (1951). Seddon proposed a three-tiered model for nerve injury; neuropraxia, axonotmesis and neurotmesis. Sunderland suggested further subcategories. Classification of peripheral nerve mechanical injuries is important to assist in prognosis and determination of treatment strategy.

Neuropraxia

(mild - recovery)

Neuropraxias are a type of peripheral nerve injury that are known as the mildest form of nerve injury. They are classified as a transient conduction of sensory or motor function without nerve degeneration. The axon's continuity is remained and the autonomic function is preserved. Inferior alveolar nerve injuries following BSSO are predominantly neuropraxias. The injuries might occur during the split procedure as a result of nerve trunk manipulation, nerve traction and/or nerve compression:

- Trauma of sufficient magnitude may injure the vascular networks within the epineurium, resulting in local ischemia (Type I)
- And/or intrafascicular oedema (Type II) thus with conduction

block. Healing of the nerve occurs generally within 1–2 days, or occasionally within a week, following the resolution of the intrafascicular oedema

- Pressure trauma of the nerve may also result in segmental demyelisation (Type III) or mechanical disruption of the myelin sheaths. In these cases healing is prolonged and recovery is complete within 1–2 months.

The prognosis is good (Seddon, 1942; Sunderland, 1951; Hall, 2005).

Axonotmesis

(severe – regeneration – recovery)

Axonotmesis is a more severe stage of injury, with disruption of the myelin sheath and the axon. The epineurium and perineurium remains intact and the continuity of the nerve is intact. Traction and compression are usual mechanisms of this type of injury and may cause severe ischemia, intrafascicular oedema, or demyelisation. Complete recovery occurs within 2–4, but improvement leading to complete recovery may take as long as 12 months. The psycho-physiological response to axonotmesis is an initial anaesthesia followed with paraesthesia as recovery

begins. The prognosis is fair and recovery requires months (Seddon, 1942; Sunderland, 1951; Hall, 2005).

Neurotmesis

(degeneration – neuroma)

Neurotmesis is the most severe stage of nerve injury, with disruption of the myelin sheath, the axon and the endoneurium. The aetiology of the nerve injury may be traction, injection injury, chemical injury or a complete disruption of the nerve trunk. The prognosis for recovery is poor. The psycho-physical response to these injuries is immediate anaesthesia. This may be followed by paraesthesia or possibly neuropathic responses such as allodynia, hyperpathia, hyperalgesia or chronic pain. This type of nerve injury has high possibility of development of central neuro-
ma (Seddon, 1942; Sunderland, 1951; Hall, 2005).

Nerve regeneration

Nerve regeneration has long been studied within the field of neuroscience, due to traumatic nerve injuries resulting in temporary or permanent sequelae. Axonal damages in the Central Nervous System (CNS) are believed unable to fully regenerate. The Peripheral Nervous System (PNS) have however oth-

er abilities to regenerate axons due to the supportive functions of Schwann cell, which can promote a favourable environment for growth (Ferguson and Son, 2011). The regeneration process begins with demyelination of the axons after detection of the injury: I. The Schwann cells revert back to an undifferentiated state, II. The previous Schwann cell becomes precursor to aid the axonal regeneration, III. Macrophages are recruited to aid Schwann cells in demyelisation, IV. After removal of myelin and axonal debris (Wallerian degeneration), the axon can regenerate, V. Schwann cells then redifferentiate to fully complete the process (Viader et al., 2011).

The two first cranial nerves, opticus and olfactorius, originate from neurons that are considered embryological extensions of the brain. Glia cells such as oligodendrocytes, which are surrounding these cranial nerves, do not appear to produce the neurotrophic factors necessary to support neural regeneration. In reality, the first and second cranial nerves are part of the central nervous system. The remaining ten cranial nerves, including the trigeminal nerve, are surrounded by supportive structures that contain Schwann cells, which have the ability of

neural regeneration. Thus, trigeminal nerve injuries should have the capacity to regenerate (Gartner and Hiatt, 2001).

Inflammation

Inflammation is a normal reflective response of the body designed to protect and promote healing of injuries. The inflammation consists primarily of vascular events, but also cellular functions that cooperate with the immune system. Regardless the nature of the injury the response and sequence of events are remarkably similar. The events can be divided in terms of vascular and cellular phases although they occur simultaneously.

Vascular changes account for clinical signs of inflammation: redness (rubor), heat (calor), pain (dolor) and swelling (tumor). Vasodilatation and increased vessel wall permeability are the most consistent vascular responses. Vasodilatation accommodates an increase in blood flow and hyperaemia, producing redness and heat. Increase in permeability of the vascular endothelium allows exudation of plasma, resulting in swelling and pain. Local chemical mediators bring about these vascular changes through auto-

coids. These substances are either released by damaged cells or synthesized within the injured tissue including: histamine, bradykinin, prostaglandins and a variety of complex agents. Autooids also sensitize sensory nerve endings and enhance nociception and pain transmission. The cellular phase of the inflammation occurs when leukocytes adhere to the endothelial wall and emigrate into the damaged tissues. The leukocytes perform phagocytosis and perform other processes conventionally attributed to the immune system. The cells are summoned by a variety of chemical substances through a process called chemotaxis. Some of these chemotactic agents are identical autooids that mediate the vascular changes described above. Others are specific agents such as cytokines.

Although the inflammatory process is a normal protective process, its intensity and duration may become inappropriate and destructive. Anti-inflammatory drugs interrupt the synthesis and/or release mediators that initiate vascular changes and thereby suppress the cardinal signs of inflammation. Non-steroidal anti-inflammatory drugs (NSAIDs) are solely anti-inflammatory whereas glucocorticoids are both anti-inflammatory and

immunosuppressant (Becker, 2013).

Steroid characteristics

Corticosteroids

The adrenal cortex is divided into three cellular zones, each synthesizing a specific class of steroidal hormones (corticosteroids). Their synthesis starts with cholesterol and culminates in the production of mineralocorticoids, glucocorticoids and androgens. Aldosterone is the principal endogenous mineralocorticoid and functions in the conservation of sodium and water. Its' synthesis and release is controlled by the angiotensin pathway and has no additional metabolic or anti-inflammatory influences (electrolytes balance regulating) (Becker, 2013). Cortisol (hydrocortisone) is the principal endogenous glucocorticosteroid and provides physiological functions including gluconeogenesis (carbohydrate and metabolism regulating). Glucocorticoids are produced in the adrenal cortex under hypothalamic control and functions within the hypothalamic-pituitary-adrenal axis. The body produces a continuous background level of cortisol that peaks before waking and after every meal. Although approximately 5–30 mg cortisol is released each day, the cycle

is altered when the hypothalamic-pituitary region is excited by stress, trauma or hypoglycaemia (Chung et al., 2011). These stressful situations can increase endogenous cortisol up to 300 mg per day (Gersema and Baker, 1992). Surgery and anaesthesia combines the psychological, physical and metabolic stress, which stimulates the release of endogenous cortisol (Becker, 2010).

Anti-inflammatory and immunosuppressive effects

Glucocorticoids are among the most important drugs used in clinical practice because of their powerful anti-inflammatory and immunosuppressive effects (Salerno and Hermann, 2006). Anti-inflammatory and most of the metabolic actions starts with glucocorticoids binding to specific receptors within the cytoplasm of targeted cells. The receptor-steroid complex then migrates into the nucleus where it binds to DNA and alters genetic synthesis of proteins. Any numbers of cellular functions are thereby modified, including the production of enzymes that regulate myriad metabolic processes and those that regulate synthesis of inflammatory autacoids and immune-related cytokines. This mechanism is time consuming and accounts for a delayed onset of effect (6-8

hours) when glucocorticoids are administered clinically (Rhen and Cidlowski, 2005; Becker, 2013). Glucocorticoids also produce additional non-genomic actions on the brain where excess may lead to euphoria and psychosis, whereas deficiency results in lethargy, apathy and depression. The sum of these actions result in suppression of vascular changes that is responsible for cardinal signs of inflammation. Glucocorticoids also inhibit certain aspects of leucocyte function, which accounts largely for their immunosuppressive effect. They inhibit phagocytosis among macrophages and reduce the number and activity of specific subsets of T-lymphocytes (Becker, 2013).

Administration

The use of steroids in orthognathic surgery is only for a brief period and predominantly in a population of young and healthy individuals, and therefore carries little risk for those complications described with chronic use. A single dose of steroids, even a large one, is without harmful effects, and a short regime of therapy (up to one week), in the absence of contraindications, is unlikely to be harmful (Schimmer and Funder, 2011). Endogenous hydrocortisone is the standard in which the pharmaco-

logical properties of various exogenous synthetic corticosteroids are compared. Many synthetic agents that are more potent, have longer duration of action, have greater anti-inflammatory activity and generate fewer unwanted mineralocorticoid side effects than hydrocortisone have developed (Salerno and Hermann, 2006). In order to suppress inflammation corticosteroids must be administered in doses exceeding the normal physiological amounts of endogenous cortisol released (Gersema and Baker, 1992). Corticosteroids are divided into short-, intermediate- and long-acting groups. Dexamethasone and betamethasone shows the highest anti-inflammatory activity, have no mineralocorticoid activity and with a biologic half-life of 36-54 hours, the longest available. Virtually all routes of administration can be used for corticosteroids. Corticosteroids administered through the oral route are rapidly and almost totally absorbed. The water-soluble ester forms of the drug can be delivered intravenously or intramuscularly to achieve high concentrations systemically (Salerno and Hermann, 2006).

Glucocorticoids and pain

Surgery causes mechanical tissue damage and pain is a direct response to the tissue damage. This is called nociceptive pain and decreases as the tissue damage resolves. The surgical incision causes mechanical distortion of sensitive nerve terminals and activates receptors that generate the first pain transmission to higher centres to trigger pain response. Acute postoperative pain can be considered a complex relationship among three components: affective nociceptive stimulation, interpretation and modulation of these signals to higher centres (involving memory and previous experiences), and an affective component (involving fear, anxiety, and depression). Therefore, the degree of postoperative pain experienced by the patient can vary greatly (Salerno and Hermann, 2006).

Inadequate postoperative pain relief can delay recovery, increase the duration of hospital stay, increase health costs and reduce patient satisfaction (Shang and Gan, 2003). Studies have revealed that 30-77 % of the patients experiences moderate to severe pain following surgery, and that this pain had been poorly controlled in many cases despite the various analgesics available (Oates et al., 1994;

Warfield and Kahn, 1995; Mattila et al., 2005). The surgical incision and osteotomy leads to inflammatory responses with the release of bradykinins and prostaglandins. They reduce the pain threshold of local pain receptors and induce the release of neuropeptides, which further stimulate inflammation. Glucocorticoids dampens local inflammation and thereby reduce pain and may have a neuromodulatory effect reducing peripheral and central sensitisation (Salerno and Hermann, 2006). Fleischli and Adams (1999) reviewed the literature on the use of postoperative steroids to reduce pain and inflammation, and concluded that evidence support the administration following a variety of surgical procedures. Holte and Kehlet (2002) found that a single dose of glucocorticoid inhibits the synthesis and the release of proinflammatory and anti-inflammatory mediators. Dan and Thygesen (2010) reviewed the literature regarding the effect of steroids on oedema and analgesia in oral surgery, as well as the risk of developing side effects. They concluded that oedema and pain were significantly decreased with no higher risk for infection and with a minimal risk of other side effects.

Glucocorticoids and facial oedema

The measurement of postoperative facial oedema, followed over time is not easily performed. Different approaches have been considered in the literature in order to evaluate the effect of glucocorticoids on facial oedema and only a small number of studies are found. The main indication for steroid use intraoperatively in orthognathic surgery is postoperative facial oedema, which in severe cases can compromise the airway, patient recovery and the surgical outcome (Chegini and Dhariwal, 2012). Munro et al., (1986) compared a preoperative dose of 0.5 mg/kg/day followed by a two-day postoperative dose of 0.25 mg/kg/day with placebo in the BSSO technique. Photographs were taken 24 hours postoperatively and compared by three independent observers. The results seemed better for the patients receiving steroids but the difference was not statistically significant. Schaberg et al., (1984) compared the effect of methylprednisolone in a cohort study with patients who underwent Le Fort I osteotomy or transoral vertical osteotomy. Facial oedema was evaluated with computed tomograms, which were performed preoperatively, and at 24 and 72 hours postoperatively. It was concluded that methylprednisolone is effective for

the control and management of postoperative facial oedema. Weber et al., 1994 evaluated the effect of different dosages of intravenous dexamethasone on postoperative facial oedema in a randomized, prospective and double blind study. Twenty-three patients requiring BSSO were divided into three groups and were given either placebo, preoperative dexamethasone 16 mg, or preoperatively dexamethasone 16 mg and with three postoperative 8 mg doses intravenously every following six hours. In both dexamethasone groups there was a significant reduction in facial oedema day one, as assessed by computer scanning of clinical photographs, but there were no statistical differences between the groups. Chegini et al., (2012) evaluated in a review the evidence for the use of steroids in orthognathic surgery regarding postoperative swelling, pain and postoperative nausea and vomiting (PONV). It was stated that evidence supports the use preoperatively but the timing of their postoperative use remains contentious. Three-dimensional (3D) stereophotogrammetry is a new technique that is reliable, accurate and non-invasive for measuring changes in soft tissue volume over time. The technique makes it possible to evaluate oedema and soft tissue changes in both

maxilla and mandible (van der Vlis et al., 2014).

Glucocorticoids and postoperative nausea and vomiting (PONV)

PONV has a high prevalence among patients undergoing orthognathic surgery and with a negative impact on patient satisfaction and comfort. It also increases recovery time and the duration of hospital stay. Repeated surveys have shown that patients fear PONV more than pain in the postoperative period while physicians commonly think that pain is the patients greatest concern. Bimaxillary osteotomy is the strongest predictor for PONV and may be attributed to the long operating time. Maxillary osteotomy entails a higher risk for PONV than mandibular osteotomy, which is probably related to greater blood loss (Kovac, 2005; A. C. Silva et al., 2006). In a cross-sectional analytic survey of 553 patients who had mandibular and maxillary osteotomies, or both, the incidence of PONV was 40% (Kovac, 2005). Dexamethasone and the risk for nausea and vomiting and postoperative bleeding after tonsillectomy in children were evaluated. Dexamethasone decreased the risk for PONV dependently on the dosage, but was also associated with an increased risk of

postoperative bleeding. The trial was therefore stopped early for safety reasons (Czarnetzki et al., 2008).

Glucocorticoids and neurosensory disturbances

Studies evaluating the effects of steroids on neurosensory disturbances in orthognathic surgery are sparse. Al Bishri et al., (2004) assessed neurosensory disturbances retrospectively after BSSO in relation to age, gender, satisfaction and the effect of steroids. Two cohorts with steroid regimes were utilized from the medical journals; 4 mg betamethasone 4 times or 8 mg 3 times per day during the first 24 hours. Interestingly, it was stated that steroid regimes might be beneficial in reducing neurosensory disturbances after BSSO. Al-Bishri et al., (2005) proceeded with an experimental study and concluded that betamethasone accelerates functional recovery after crush injury to rat sciatic nerve. Furthermore, a second experimental study was performed in order to explain previous findings in analysing the pattern of macrophage recruitment and expression of nerve growth factor p75. It was found that moderate perioperative doses with betamethasone reflected the recruitment of macrophages although only to a small extent in the

expression of p75 (Al-Bishri et al., 2008). Local application of dexamethasone on the exposed alveolar nerve did not make any difference and is therefore not recommended (Pourdanesh et al., 2014). Seo et al., (2004) evaluated the appropriate timing for giving steroids and found that steroid treatment for sensory impairment given after orthognathic surgery has the potential to accelerate recovery starting about one week postoperatively.

Glucocorticoids and non-steroid anti-inflammatory drugs (NSAIDs)

NSAIDs are effective anti-inflammatory agents, and should be considered as first-line agents for managing musculoskeletal pain. However, there are several indications for which glucocorticoids either are preferable or may be considered when NSAIDs prove ineffective. These situations of treatment could be inflammatory intraoral lesions that benefits of added immunosuppression of glucocorticoids or in prophylaxis of PONV (Becker, 2013). Clinical trials have confirmed the advantage of the preoperative administration of both NSAIDs and glucocorticoids together, in comparison with either agent alone regarding postoperative trismus, pain and swelling (Sisk and Bonnington,

1985; Troullos et al., 1990; Buyukkurt et al., 2006).

Glucocorticoids and considerations

The glucocorticoids are widely used in the management of primary inflammatory disorders, especially those attributed to immunologic mechanisms such as, autoimmune disease, asthma, and rheumatoid arthritis. The anti-inflammatory efficacy of glucocorticoids exceeds the NSAIDs but their potential for side effect is also greater. Long-term use is associated with a sobering list of adverse side effects, but a few days, or even a week, of steroid therapy is generally free from significant side effects. Short-term use (5-7 days) of glucocorticoids is unlikely to induce any significant side effect. Although glucose levels and blood pressure may elevate slightly during the treatment, short-term administration is rarely of consequence for the patient. Nevertheless, several conditions should be regarded as relative contraindications even in short-term use. These include poorly controlled diabetes, immune-compromise, active peptic ulcer, osteoporosis, and herpetic or fungal infections. High dosages should probably be avoided in patients suffering psychoses or other

affective disorders (Fardet et al., 2012; Becker, 2013).

Analgesics

Non-opioid analgesics

The non-opioid analgesics include paracetamol - acetaminophen (APAP) or NSAIDs. The analgesic efficacies of these agents are often underestimated, which is unfortunate because they generally are equivalent or superior to opioids for the managing of musculoskeletal pain. These agents produce lower incidence of side effects, including the potential for abuse. Orthognathic surgery is included in the musculoskeletal category, and for decades studies have repeatedly found that NSIADs are generally superior to opioids at conventional doses (Fricke et al., 1992; Van Dyke et al., 2004).

NSAIDs

NSAIDs are known for their analgesic, antipyretic and anti-inflammatory efficacy. These therapeutic effects and their most notable side effects can be explained almost entirely by their ability to inhibit cyclooxygenase (COX), which is required for synthesis of prostaglandins (Becker, 2010).

The most important ad-

verse effects of NSAIDs include gastrointestinal ulceration, renal dysfunction, inhibition of platelet function and induction of asthma. Contraindications to use NSAIDs should be respected because of their harmful effects and the incidence and severity are greater in the elderly (Salerno and Hermann, 2006).

The most frequent side effects of NSAIDs are related to gastrointestinal toxicity. Prostaglandins stimulate the production of a mucous lining that protect the stomach and small intestine. The erosive and ulcerative side effects common to NSAIDs are related to the inhibition of prostaglandins. This action occurs not only locally when orally administered drugs lie in contact with the gastric mucosa, but also when the drug follows absorption and systemic distribution to the gastrointestinal mucosa. Parenteral administration does not prevent a risk for gastro intestinal erosions and ulcerations (Kimmey, 2004). Prostaglandins play an essential role in renal perfusion and diminished levels of these are believed to account for cases of nephrotoxicity after long-term NSAIDs use. In healthy patients, nephrotoxicity due to NSAIDs, require high doses over extended periods such as years. However, a patient with com-

promised renal function relies more heavily on prostaglandins for adequate function, and acute renal failure can occur within 24 hours of NSAID administration (De Broe and Elseviers, 1998).

It is the ability of NSAIDs to inhibit cyclooxygenases in platelets that reduces the synthesis of thromboxane A₂, which normally contributes to platelet aggregation. This accounts for the so-called anti-platelet effect of these agents and is a consideration following surgical procedures. However, aspirin is the drug of choice in comparison with NSAIDs that has proven effective in preventing thrombotic events such as acute coronary syndromes or stroke. This is so because the antiplatelet action of aspirin is irreversible, lasting the life span of the platelet (10–14 days). Non-aspirin NSAID binds weakly and reversibly to platelet cyclooxygenases, which result in loss of their mild antiplatelet influence after drug elimination (Goldenberg et al., 2005). Nevertheless, non-aspirin NSAIDs are generally withheld in major thoracic, abdominal, orthopaedic procedures or orthognathic surgery even though the effect on intraoperative bleeding is considered minor. Patients receiving mono-therapy with low-dose aspirin are not of great concern but should be

considered before the administration of NSAIDs. Additionally, NSAIDs should be avoided in patients who suffer from bleeding disorders, in those taking anticoagulants such as warfarin, and antiplatelet drugs such as clopidogrel. The issue with NSAIDs is not so much about their antiplatelet action, but the NSAID-induced injury of the gastrointestinal mucosa that may bleed far more profusely in this patient population (Becker, 2010).

Paracetamol

In comparison with NSAID the mechanism of action of paracetamol is less clear but is believed to involve an inhibition of prostaglandin synthesis within the CNS. It has little influence on peripheral prostaglandin synthesis, especially within inflamed tissues, which likely explains the lack of anti-inflammatory efficacy and sharing none of the peripheral side effects attributed to NSAIDs. However, it is an ideal analgesic for patients who present no contraindications to NSAIDs (Becker, 2010).

Summary of non-opioids analgesics

Postoperative pain management after orthognathic surgery includes an inflammatory component. For this reason, NSAIDs are the most rational

first-line agents and often superior to conventional dosages of opioids. None-opioids may reach a ceiling to their analgesic response, but optimal doses should be established before it is assumed that NSAID has failed. Furthermore, the combination of an NSAID with paracetamol provides greater analgesic efficacy than does either agent alone. This may obviate the need for opioids (Hyllested et al., 2002; Becker, 2010).

Intraoperative local anaesthesia

Local anaesthesia with mandibular block given intraoperatively reduces opioid consumption but does not alternate the opioid side effects in the postoperative phase (Van Lancker et al., 2003). Inferior mandibular block with ropivacaine given at the start of surgery increases the patient's comfort by decreasing PONV and improving postsurgical analgesia (Chatellier et al., 2012). Mandibular nerve block with ropivacaine can improve intraoperative inferior alveolar nerve visualization during BSSO through decrease of intraoperative bone bleeding (Espitalier et al., 2011).

Postoperative local anaesthesia

To my knowledge there are no scien-

tific evaluations available regarding infiltration with short or long duration anaesthesia given after surgery within the field of orthognathic surgery. However, the effect of postoperative wound infusion with local anaesthesia is evaluated within other surgical specialities. Preperitoneal continuous wound infusion of ropivacaine is an effective and safe addition to multimodal analgesia regime for colorectal surgery (Fustran Guerrero et al., 2015). Continuous episcapsular wound infusion with ropivacaine 0.3% after minimal invasive hip replacement is effective and reduces morphine consumption and improve the quality of postoperative analgesia (Aguirre et al., 2012).

Recovery

Multimodal, multidisciplinary fast-track surgery, also known as accelerated post-operative rehabilitation or enhanced recovery after surgery (ERAS) pathways has been shown to reduce perioperative morbidity and enhance functional recovery after surgery and thus shorten hospitalization (Joshi et al., 2014). In this context, there is a need for enhanced procedure-specific pain management that aims to overcome the limitations of conventional guidelines

and provide recommendations formulated in a way that facilitates clinical decision-making across all stages of the perioperative period. It is emphasized in the literature that the use of multimodal analgesia and preventive analgesia reduces central sensitization (Joshi et al., 2014). Inadequate treated pain may have long-term consequences with regard to the development of chronic pain (Kehlet et al., 2006). In order to understand postoperative morbidity it is therefore necessary to understand the pathophysiological role of the various components of the surgical stress response and to determine if modifications of such responses may improve the surgical outcome (Kehlet, 1997). Also in order to develop postoperative health care and identify the patients with recovery problems, it is of great importance to ask, why is the postoperative patient in the hospital today? (Kehlet et al., 2006). Future improvements are expected by integration of minimal invasive surgery, pharmacological stress-reduction and effective multimodal, non-opioid analgesia (Kehlet et al., 2006). Today, there is a lack of studies regarding the principals on multimodal fast-track orthognathic surgery. Nevertheless, further advancement and development in surgical techniques,

short acting reliable anaesthetic drugs, pre- and postoperative care, multimodal approaches and multidisciplinary collaboration, will most likely improve the outcome and progress in recovery after surgery.

AIMS

Paper I

The main objective was to evaluate two types of bone anchor screws for intermaxillary fixation, regarding frequency of iatrogenic dental root damage.

Paper II

The main objective was to determine the efficacy of single versus repeated beta-methasone doses on facial oedema, pain and neurosensory recovery after bilateral sagittal split osteotomy (BSSO).

Paper III

The main objective was to investigate the incidence and reasons for removal of titanium fixation plates following orthognathic surgery. The second objective was to identify risk factors predisposing plate removal.

Paper IV

The main objective was to evaluate haemodynamics and recovery parameters in relation to two general anaesthetic protocols used for orthognathic surgery. The second objective was to evaluate long duration local anaesthesia on recovery parameters.

MATERIAL & METHODS

Design

The studies included in this thesis were conducted in order to study multiple perspectives on factors influencing clinical outcome in orthognathic surgery. The research design, combining quantitative and qualitative methods, is descriptive and randomized, including comparative, correlational and regres-

sional analysis. The direction of the inquiry is still forwarded in time, from a possible risk factor to an outcome. This study describes merely an investigator's experience with a group of patients and attempt to identify features associated with a good or bad outcome (Table 1) (Trapp and Dawson-Saunders, 1994).

The second study was designed as a randomized controlled trial (RCT) (Paper II). The RCT provides

Table 1. Study designs

Study	Design	Type	Method	Outcome
I	Descriptive	Clinical study	Longitudinal	Retrospective
II	Randomized	Clinical trial	Controlled	Prospective
III	Descriptive	Clinical study	Longitudinal	Retrospective
IV	Descriptive	Clinical study	Longitudinal	Retrospective

sional analysis

In the descriptive studies (Papers I, III and IV), two groups of patients were observed. In the randomized trial (Paper II), three groups of patients were divided in two study groups and one control group. Characteristics about the patients were recorded for analyse.

The first study is called a longitudinal (historical) method due to the fact that a previously used technique was evaluated (Paper I). One of the surgical techniques was used before

the strongest evidence for concluding causation and it provides the best insurance that the result is due to the intervention (Table 1) (Trapp and Dawson-Saunders, 1994).

The third and fourth studies were designed as longitudinal and retrospective studies (Paper III and IV). The studies begin with the absence or presence of an outcome and then look backward in time to try to detect possible causes for risk factors. These

studies involve an extended period of time defined by the point when the study begins and at the point when the study ends (Table 1) (Trapp and Dawson-Saunders, 1994).

Patient selection

The studies in this thesis involved patients who had been referred during 2000-2013. The departments involved were Department of Oral and Maxillofacial Surgery and Otolaryngology, NU Hospital Group, Trollhättan Sweden and Department of Oral and Maxillofacial Surgery, Sahlgrenska Academy, University of Gothenburg. Single and/or double centre studies were performed. All patients were registered in the region (Table 2).

Prelude

The first study contained a separate group of patients (Paper I). The second, third and fourth studies overlap each other and include partly the same patients (Paper II, III & IV).

Inclusion criteria

The first study included patients needing intermaxillary fixation, with the use of bone anchor screws (Paper I). The second study included patients treated with BSSO, healthy and without regular medications, although contraceptives were allowed, during the study period (Paper II). The third study included all patients that were treated with BSSO, Le Fort I osteotomies and/or genioplasty during the study period (Paper III). The fourth study included patients with

Table 2. Demographic details and characteristics

Study	No	Included	Male/female	Clinic	Period
I	123	123	97/26	NU Hospital Group & Sahlgrenska	2000-2008
II	37	37	7/30	NU Hospital Group	2006-2011
III	404	323	135/188	NU Hospital Group & Sahlgrenska	2003-2011
IV	269	94	39/55	NU Hospital Group	2003-2013

the American Society of Anaesthesiologists (ASA) physical status I - II, and patients that had undergone BSSO, Le Fort I, or bimaxillary procedures during the study period (Paper IV).

Exclusion criteria

The first study excluded patients with other means of IMF, such as archbars and ligatures (Paper I). The second study excluded patients requiring additional genioplasty and maxillary osteotomies, as well as patients with contradictions for steroids (Paper II). The third study excluded 81 patients demanding bioabsorbable fixation plates and other mandibular osteotomies than BSSO (typically oblique-vertical osteotomies) (Paper III). The fourth study excluded as many as 175 patients in order to strictly evaluate the two general anaesthetic protocols. These exclusions were: segmentations, genioplasty osteotomies, β -adrenergic antagonists, atropine, ephedrine/phenylephrine, BMI ≥ 35 kg, coagulopathy, age < 18 years, ASA \geq III, bone augmentation, missing charts, combinations of remifentanyl-sevoflurane based anaesthesia (n=2), tooth extraction and implant installation (Paper IV).

Data collection

Quantitative data collection

Quantitative data was collected from medical charts, anaesthetic charts, drug charts, recovery observations charts and radiographs (Paper I-IV). Facial oedema was measured objectively as the distance between the inferior borders of the patient's two earlobes and below the chin in millimetres (Table 3) (Paper II).

Qualitative data collection

Pain was subjectively estimated by the patient using the visual analogue scale (VAS) ranging from 0 -10, with zero indicating no pain and ten indicating maximum pain (Paper II & IV). Sensitivity was self-estimated by the patients in the lower lip, right and left side, using the VAS, ranging from 0 - 10, with zero indicating no sensitivity and ten indicating maximum sensitivity (Table 3) (Paper II).

Questionnaire (paper III)

The National Board of Health and Welfare in Sweden publishes statistics in the area of health and medicine care (including causes of death) and social services. Statistical databases for research purposes include in-patient care

Table 3. The methods used in the clinical studies

Study	Sample	Ethical approval	Data collection	Methods of analysis
I	Consecutive	Not needed	Quantitative - Medical records - X-rays	Statistical analysis - descriptive - comparative
II	Consecutive	Approved Dnr. 287-08	Quantitative - Medical records - <i>Facial oedema</i> Qualitative - <i>Pain (VAS)</i> - <i>Sensory (VAS)</i>	Statistical analysis - descriptive - comparative - regression - correlations
III	Consecutive	Approved Dnr. 805-13	Quantitative - Medical records - Questionnaires	Statistical analysis - descriptive - survival analysis
IV	Consecutive	Approved Dnr. 391-14	Quantitative - Medical records - Anaesthetic charts - Drug charts - Recovery observation charts Qualitative - <i>Pain (VAS)</i>	Statistical analysis - descriptive - comparative - regression - correlations

operations. It was revealed that observations regarding reporting statistic information about operations to The National Board of Health and Welfare varied enormously in different parts of Sweden regarding orthognathic surgery, which resulted in incomplete data. Therefore, in order to perform an accurate survival analysis a questionnaire was sent to all patients for fol-

low-up. Patients not responding were contacted for a structured telephone interviews based on the questionnaire. The questionnaire's sent to the patients contained the following questions:

- Have you undergone orthognathic surgery (yes or no)?
- Have you removed titanium fixation plates (yes or no)?

- What reason predisposed titanium plate removal (the patients answer)?
- In what city/hospital did you remove the plates (the patients answer)?
- Were you relieved from symptoms after plate removal (yes or no)?
- Were you a smoker at the time of orthognathic surgery (yes or no)?
- Did you use Swedish snuff at the time of orthognathic surgery (yes or no)?

In total 323 (80%) patients out of 404 patients responded to the questionnaire. The posted questionnaire was answered in written by 178 patients and complemented with 145 patients who accepted a structured telephone interview based on the questionnaire.

Radiographic examinations

Frontal and lateral (profile) radiographs were obtained after surgery and before discharge from the hospital (Paper I-IV) (Figure 5). Two months and one year after surgery new radiographs lateral (profile), and orthopantomogram were obtained (Figure 6) (Paper II-IV). Intraoral radiograph images were obtained in cases of dental root injuries (Figure 7 and 8) (Paper I).

Hypothesis

Paper I

The null hypothesis was that there are no differences between predrilled versus drill-free bone anchor screws regarding iatrogenic dental root damage.

Paper II

The null hypothesis was that postoperative facial oedema was not associated with neurosensory disturbances and that there are no differences between

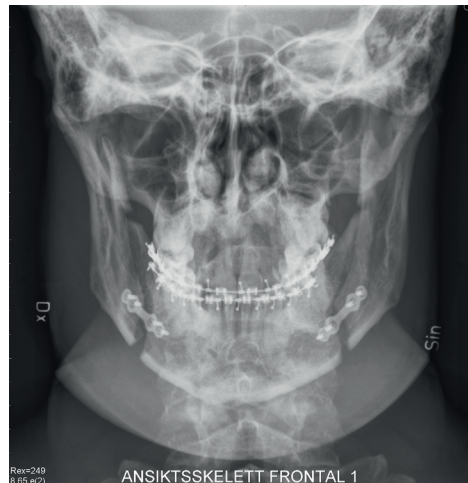

Figure 5. Frontal radiograph obtained the day after surgery and before discharge from the hospital.

repeated or single betamethasone regimens in the protection of the alveolar nerve from surgical trauma, postopera-

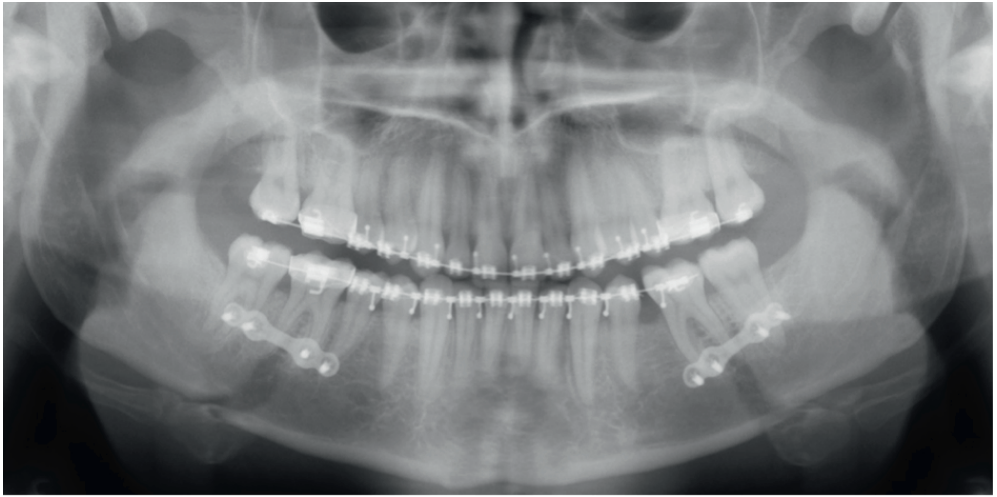


Figure 6. Orthopantomogram with single fixation plates inserted on each side.

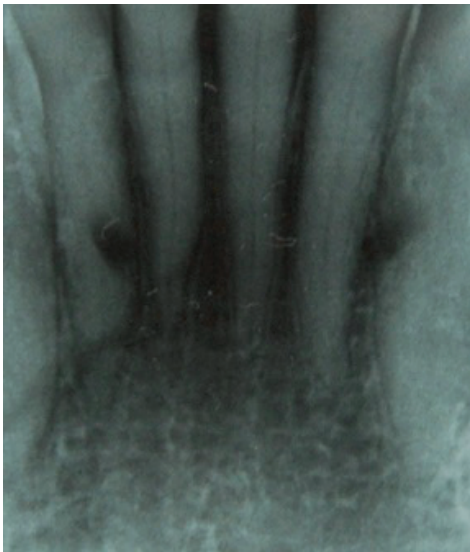

Figure 7. Intraoral radiograph images showing iatrogenic root damage as an outcome of the twist drill used between dental roots of lateral incisors in the mandible.

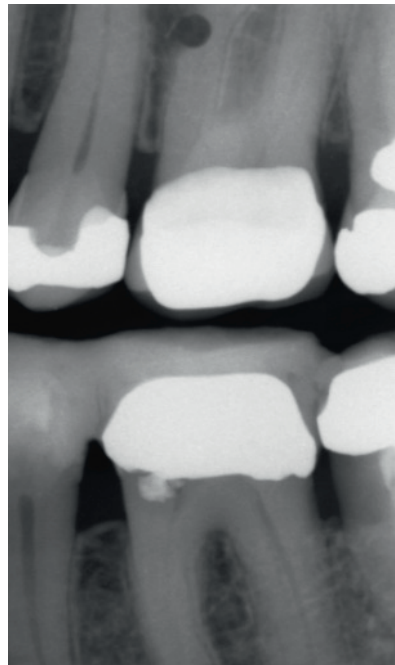


Figure 8. Intraoral radiograph images showing iatrogenic dental root damage as a result of the twist drill.

tive oedema and to promote nerve recovery.

Paper III

The null hypothesis was that smoking makes no difference in the survival of osteosynthesis fixation plates and that the number of inserted fixation plates does not increase the need for removal of plates.

Paper IV

The null hypothesis was that there are no differences between remifentanyl-propofol based total intravenous anaesthesia (TIVA) versus fentanyl-sevoflurane based balanced inhalation anaesthesia (BA) in orthognathic surgery, regarding haemodynamics and recovery parameters. The second hypothesis was that local anaesthesia given after surgery makes no difference regarding recovery parameters.

Basic study protocol and procedures

Paper I

A protocol was rendered to consecutively collect retrospective data from medical records and radiographs during the designed study period (Table 3). A technique with two different bone

anchor screws were evaluated regarding iatrogenic dental root damage. The bone screws were used as bone anchor positions for IMF and were completed with steel ligatures during operation. The first technique evaluated bone anchor screws requiring predrilling of holes with a twist drill in transalveolar positions before the bone anchor screw could be inserted. The second technique evaluated bone anchor screws inserted with a drill-free, self-cutting and self-tapping function, in transalveolar positions. One single examiner performed all the radiographic analysis.

Paper II

A prospective, randomized, double blind protocol was used to assign consecutive patients to one of the three experimental groups (Table 3). Support staff drew designations from sealed envelopes. The following groups and betamethasone regimes were used: 1. control (n=12), 2. repeated dose of 4 mg betamethasone administered orally the first day prior to surgery, 8 mg betamethasone administered intravenously (IV) at induction and 4 mg betamethasone administered orally the first day postoperatively (n=14), 3. single dose 16 mg betamethasone administered IV at induction (n=11). Facial oedema,

pain, and sensitivity were recorded with a protocol, preoperatively (baseline), and at 1 day, 7 days, 2 months, and at 6 months postoperatively. All measurements were obtained bedside or at scheduled return visits to the clinic. All participating clinicians performed calibrated measurements. Furthermore, possible influences such as gender, age, total operating time, amount of bleeding, postoperative hospitalization, and advancement versus setback were recorded.

Paper III

A protocol was rendered to consecutively collect retrospective data from registers and medical records during the designed study period (Table 3). All patients were admitted to the ward one night after the single jaw procedure and minimum two nights after the bimaxillary procedure. Information regarding mandibular advancement or setback was not possible to retrieve. Statistical analysis regarding the different manufactures of osteosynthesis plates was not performed. The osteotomies reviewed were divided into the following six groups: maxillary; mandibular; bimaxillary; bimaxillary and chin; mandibular and chin; maxillary and chin. The numbers of plates inserted were di-

vided into four groups: titanium plates total; titanium plates maxilla; titanium plates mandibular; titanium plates chin. The number of plates removed and their localization were evaluated. Furthermore, possible influences such as age, gender, tobacco habits, number and position of plates, bone augmentation, intermaxillary fixation, medications, operating time, craniofacial syndrome and health & medications were recorded and analysed.

The decision for post surgical removal of fixation plates was based on the patient's complaint about discomfort and supported by the clinical appearance. Surgical removal of plates in the mandible was performed only on the side with plate related complications or discomfort. In the maxilla, the plates were most often totally removed on both sides under general anaesthesia.

The calculation of incidence, risk factors and reasons for plate removal (such as infection) was based on data from medical records and validated with the patient's answers from the questionnaire. Moreover, the classification of infection was double-checked and confirmed with diagnosis in the patient's journal and administered antibiotic treatment. Ad-

ditional causes for plate removal such as tenderness/pain, exposed plates, detached plates, aesthetic considerations and other reasons were not possible to retrieve from medical records due to incomplete information. Therefore, these findings were based only on the answers from the questionnaire revealing the patients subjective apprehension about the indication for plate removal.

Paper IV

A protocol was rendered to consecutively collect retrospective data from medical records during the designed study period (Table 3). The study was audited in order to evaluate and suggest improvements regarding the anaesthetic protocols, with focus on haemodynamics and recovery parameters. Additionally, possible effects of long duration local anaesthesia (ropivacaine 0.75 mg/ml) administered after surgery regarding pain relief, recovery parameters including early mobilization and hospitalization were evaluated. Data preparation was compiled with a proforma.

Data collection proforma

Demographics

Date of surgery	
ID number	
Age	
Male / female	
ASA	I or II or III (American Society of Anaesthesiologists)
BMI	Mass (kg) / height (m) ²
Smoking	yes / no
Medication	yes / no
Surgery	Mandibular osteotomy (BSSO) Maxillary osteotomy (Le Fort I) Bimaxillary osteotomy
Exclusion criteria I	Segmentations Genioplasty
Exclusion criteria II	1. β -adrenergic antagonists preoperatively 2. Atropine and/or glycopyrrrolate intraoperatively 3. Ephedrine and/or phenylephrine intraoperatively 4. Body Mass Index (BMI) \geq 35 5. Age < 18 years 6. ASA \geq III 7. Bone augmentation 8. Missing charts 9. Tooth extraction and /or implant installation

Preoperative

Premedication		
"	paracetamol 1500 mg	1/0
"	triazolam (Halcion®)	1/0
"	NSAID	1/0
"	meclizine (Postafen®)	1/0
"	morphine or oxycodone	1/0

Intraoperative

Operating time	minutes	
Anaesthetic time	minutes	
Bleeding	millilitre	
Anaesthesia	remifentanyl + propofol fentanyl + sevoflurane	
Anaesthesia depth	TIVA (1) propofol	mg x kg ⁻¹ x h ⁻¹
	remifentanyl	mg x kg ⁻¹ x h ⁻¹
	Inhalation (2,3)	MAC, mean value
<i>Medication IV (according to standard protocol)</i>		
Antibiotics	benzylpenicillin 3 g x 3 IV clindamycin 600 mg x 3 IV (in case of allergy)	
Cortisone (Betamethasone®)	8 mg 8-16 mg 16 mg	Le Fort I BSSO bimaxillary
Tranexamic acid (Cyklokapron®)	1 g	bimaxillary
<i>Before surgery (local anaesthesia)</i>		
Lidocaine 2% epinephrine (1:200,000)	7 ml 14 ml	single jaw bimaxillary
<i>Medications (anaesthetist decision)</i>		
Ondansetron (Zofran®), droperidol (Dridol®)	1/0	

Materials and Methods

Clonidine (Catapressan®)	0	
	I	(preoperative)
	II	(intraoperative)
Rokuroniumbromid/atrakurium	1/0	
<i>Intraoperative measurements</i>		
Blood pressure (measured every 10 th minute) (mmHg)	systolic	diastolic
MAP (mean arterial pressure, mmHg)	diastole + (systole - diastole)/3	
Heart rate (during surgery)	rate/min	
<i>After surgery</i>		
Ropivacain 7,5 mg/ml (local anaesthesia)	5 ml single jaw	
	10 ml bimaxillary	
Ketorolac (Toradol®), parecoxib (Dynastat®)	1/0	
Ketobemidon or morphine	1/0	
<i>Postoperative</i>		
Post-anaesthesia care unit (PACU)		
Recovery (minutes)		
Pain - visual analogue scale (VAS)	0 - 10	
Nausea	1/0	
Vomiting	rate	
Adverse effects	1/0 + specification	
<i>Analgesics</i>		
Paracetamol (Perfalgan®)	mg	
Ketorolac (Toradol®)	mg	
Morphine	mg	
Ketobemidon (Ketogan®)	mg	
Oxycodone (OxyNorm®)	mg	
<i>Discharge from PACU (criteria)</i>	Visual analogue scale (VAS) 4	
	Stabile circulation and respiratory	
	Full bladder function	
	Arrest of bleeding	
	No or minimal nausea	
	Normal body temperature	
<i>Ward</i>		
Duration at the ward	Days	
	Nights	
Discharge from ward	Mobilized	
	Able to swallow medication	
<i>Analgesics</i>		
Paracetamol	mg	
Diklofenak (Diklofenac®)	mg	
Kodein & paracetamol (Citodon®)	mg	
Ketobemidon (Ketogan®)	mg	
Oxycodone (OxyNorm®)	mg	

Preoperative protocol

Clinical studies (Paper I-IV)

Patients were preoperatively assessed with radiographs (Paper I-IV). Cephalometric analysis and diagnostic imaging were performed using Facad Software (Ilexis AB, Linköping, Sweden). Functional and aesthetic demands were discussed with the patients (Paper II, III & IV).

All third mandibular molars had been preoperatively removed and with a minimum of six months healing prior to operation with BSSO (Paper II, III & IV). All patients had been submitted for routine preoperative evaluation by the anaesthetist. Preoperative medications were prescribed in order to prevent pain and PONV postoperatively and could vary between the patients during the study periods depending on changes in standard protocol at the Department of Anaesthesiology. All patients fasted from midnight and received prescribed medications one hour before induction. Collection of data regarding preoperative medications was performed only in the fourth study (Paper IV).

Prophylactic antibiotics

Antibiotics were administered accord-

ing to department routines: penicillin G (3g x 3) IV or clindamycin (600 mg x 3) IV at induction and postoperatively during hospitalization.

Steroids

Steroid regimes were administered at induction. Betamethasone 16 mg IV was administered in bimaxillary osteotomies and betamethasone 8 mg IV were administered in maxillary or mandibular osteotomies at induction as standard protocol (Paper I-IV). The standard protocol was temporary changed during performance of the second study (Paper II).

Local anaesthesia

All patients received infiltration with local anaesthesia, lidocaine 2% epinephrine (1:200,000), in order to minimize hemodynamic stress, consumption of anaesthetic drugs, blood loss and to facilitate intraoperative surgical visualization. Single jaws received 7 ml and double jaws received 14 ml lidocaine 2% epinephrine (1:200,000) (Paper I-IV).

Intraoperative protocol

Paper I

The pre-drilled technique: A twist drill

was required in transalveolar position between dental roots prior to insertion of bone anchor screws (Stryker Leibinger screws 2.0 x 12–16 mm, Freiburg, Germany) or (Walter Lorenz IMF screws 2.0 x 5–7 mm, Jacksonville, Florida, USA) (Figure 9).

The drill-free technique: No twist drill was used. The screws were inserted directly through the mucosa in transalveolar positions between dental roots due to the self-cutting and self-tapping function of the screws (Synthes Inc., IMF screws 2.0 x 8–12 mm, Monument, Colorado, USA) or (Biomet Microfixation IMF screw 2.0 x 5–7 mm, Warsaw, Indiana, USA) or (Stryker Leibinger Maxillo Mandibular Fixation (MMF) screws 2.0 x 8–12 mm), Freiburg, Germany) (Figure 10).

Temporary IMF was achieved using steel wires or elastic bands. The bone anchor screws were removed directly after surgery or retained postoperatively in order to correct small discrepancies of the occlusion with guided elastics.

Paper II

The BSSO's were operated with Hunsuck's (1968) and Epker's modification (1977) of the Obwegeser-Dal Pont method (1961-1964). The osteotomy

was performed with burrs, osteotomies and spreaders. No attempt was made to dissect the inferior alveolar nerve (IAN). The position of the nerve was recorded, whether it was visible or hidden (embedded) in the cancellous bone (Figure 11). Internal fixation was utilized with one straight mini-plate (four holes and four screws) (Matrix-ORTHOGNATHIC Plating System, DePuy Synthes, Zuchwil, Switzerland or 2.0 mm mini-system, KLS Martin, Tuttlingen, Germany) on each side of the mandible. Mono-cortical approach was chosen to minimize compression effects on the inferior alveolar nerve during fixation of the proximal and caudal bone segments. Intraoperative complications such as "bad split" were noted. The "bad split" was defined as an unfavourable outcome of the split, which gave no possibility to proceed with the BSSO as planned. The first three authors performed all the surgery. Postoperative elastics were in a majority of the cases introduced one week postoperatively at return visit. In cases of heavy muscular strain these elastics were introduced directly after hospitalization, although the guided elastics were most often introduced one week after surgery at decline of facials oedema. The elastics were individually positioned bimaxil-

lary on the orthodontic appliances for approximately two months after surgery to correct occlusion and inhibit muscular strain. Liquid diet was recommended the first week and soft diets were strongly advised up to six weeks postoperatively.

Paper III

The BSSO's had been performed with Hunsuck's (1968) and Epker's modification (1977) of the Obwegeser-Dal Pont method (1961-1964). Le Fort I osteotomies had been performed with the method described by Hogeman et al., (1967) and Bell et al., (1988). Genioplasty osteotomies had been performed according to Trauner et al., (1957).

One or two straight fixation plates on each side of the mandible were inserted (thickness 1.0 mm). Two L-shaped fixation plates were inserted lateral to the nose aperture (thickness 0.8 or 1.0 mm) and followed by two L-shaped fixation plates at the zygo-maxillary buttress (thickness 0.5 or 0.6 mm). Manufacturers: DePuy Synthes® MatrixORTHOGNATHIC, Zuchwil, Switzerland or KLS Martin Group®, Tuttlingen, Germany

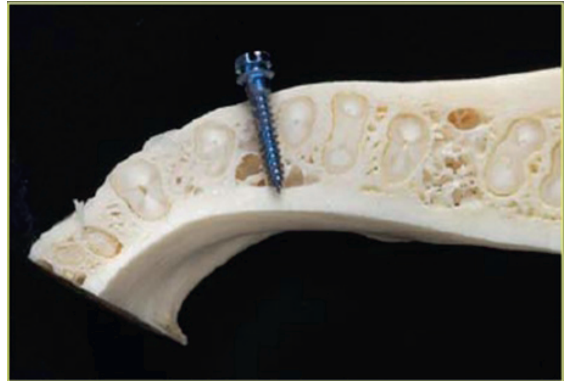

Figure 9. Transalveolar position of bone anchor screws.

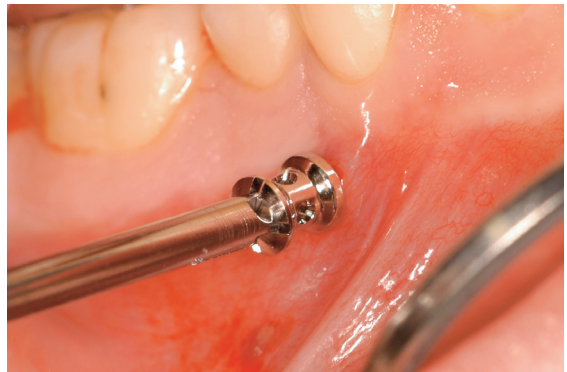

Figure 10. Drill-free, self-cutting and self-tapping bone anchor screw inserted in transalveolar position.

or Walter Lorenz Surgical® or Biomet Fixation®, Jacksonville, Florida, U.S.A. No specific attempt was made in positioning the fixation plates near the inferior border of the mandible. The plates were rather inserted by random in the best position from the surgeon's point of view.

Before closing the

wound the osteotomies were thoroughly rinsed with saline solution 0,9%. Suturing was performed with polyglactin (Polysorb® 4-0) and with the intention to catch the periosteum and mucosa in two layers in both maxilla and mandible. The genioplasty was sutured in two layers including the muscular portion. No suction drainage was used in any case. Guided elastics on surgical hooks were used postoperatively to guide the patient into correct occlusion in the range of one or approximately two months postoperatively depending on muscular strain. Liquid diet was recommended the first week and soft diets were strongly advised up to six weeks postoperatively.

Paper IV

The BSSO's had been performed with Hunsuck's (1968) and Epker's modification (1977) of the Obwegeser-Dal Pont method (1961-1964). Le Fort I osteotomies had been performed with the method described by Hogeman et al., (1967) and Bell et al., (1988).

The anaesthetic protocols were remifentanyl-propofol based TIVA or fentanyl-sevoflurane based BA.

Postoperative protocol

Local anaesthesia

Infiltration with long duration local

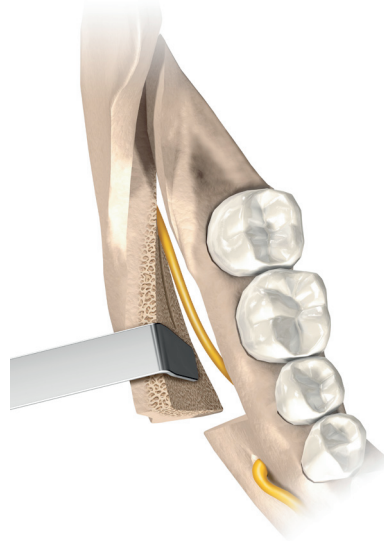


Figure 11. The position of the nerve was recorded, whether it was visible or hidden (embedded) in the cancellous bone.

anaesthesia (ropivacaine 7.5 mg/ml) was introduced in all patients as standard protocol from August 2010 at the end of surgery and before extubation. Single jaws received 5 ml and double jaws received 10 ml. The duration for ropivacaine is approximately 2-6 hours, depending on vascularisation (Paper III-IV).

Analgesics

All patients were offered diclofenac 50 mg x 3 and paracetamol 1000 mg x 4 depending on the patient's individual demands postoperatively. If pain relief was insufficient, opioids were individually administered (Paper I-IV).

Prophylactic antibiotics

Penicillin V (1g x 3) or clindamycin (300 mg x 2) were administered orally for the first postoperative week (Paper I-IV).

Follow-up

In cases of detected dental root trauma the patients were recalled for follow-up with orthopantomogram or intraoral radiograph images (Paper I). Postoperative follow-up period was mandatory for orthognathic patients the first week, at one month, at two months, at twelve months and eighteen months after surgery. In cases of heavy muscular strain affecting occlusal stability, consultations were more frequently required the first eight weeks (Paper II-IV). Supplemented clinical or radiographic examinations varied between the two clinics due to different follow-up protocols (Paper II-IV).

Statistical methods and analysis**Methods of statistical analysis**

Non-parametric statistical methods were used since the sample sizes were relatively small (Paper I, II, IV). If the variables tested were normally distributed the non-parametric tests are equally as good as the parametric. When the variables tested were not normally distributed the non-parametric test was used. The data was presented as frequencies and/or percentages (Paper I-IV), median (Paper I), range (Paper I-IV) or percentiles (Paper III, IV). Two-sided P-values were used. All tests were two-sided and $P < 0.05$ was considered statistically significant. The variables were analysed using a univariate test (Paper I-IV). For the second and the fourth study a multivariate test was added (Table 4) (Paper II & IV).

Fisher exact test was used to test between-group differences (Paper I). Linear regression coefficients were calculated for each individual to represent the change of the variable over time (Paper II). Fisher's permutation test was used to test between-group differences between all variables (Paper II, IV). Pitman's test was used to test correlations (Paper II

and IV). Mantel's test was used to test the between-group differences when adjusted for baseline variables (Paper II). A Poisson regression model was used to study relationship between risk and conditions at baseline (Paper III). A spline regression model was used with knots at the 10th, 50th and 90th percentiles in order to study associations (Table 4) (Paper III-IV) (Harrell, 2001)

Statistical analysis (Paper I)

Injuries related to the patient were managed as categorical data and analysed with crosstabs and Fisher's exact test. Injuries related to the teeth were analysed with basic descriptive statistics.

Statistical analysis (Paper II)

Postoperative VAS values in relation to the present position of the nerve at surgery, left side versus right side, were merged for a mean value. This merging was also performed in cases in which the nerves on both sides were hidden or visible during surgery. Pairwise comparisons of the VAS scale values showed that there were no significant differences between the hidden and visible nerves. Therefore, the data were not separated in the statistical analysis. For each patient and each variable in the re-

sults (facial oedema, pain and sensitivity), a linear regression coefficient was calculated to describe the trend over time from the first day after surgery until six months postoperatively.

Statistical analysis (Paper III)

A Poisson regression model was used to study the relationship between the risk for plate removal and conditions at baseline. In contrast to the logistic regression, the Poisson regression utilizes the length of each individual's follow-up period and the hazard function is assumed to be $\exp(\beta_0 + \beta_1 \cdot \text{current variable of interest})$. The observation period of each patient was divided in intervals of one month. Statistical calculations were based on the first date of plate removal in cases when patients removed plates twice. The variables were analysed using a univariate model. A spline regression model was fitted using knots at the 10th, 50th and 90th percentiles, as recommended by Harrell 2001, in order to study the association between total operating time and the risk for plate removal. The splines were second-order functions between the breakpoints and linear functions at the tails resulting in a smooth curve (Breslow and Day, 1987).

Statistical analysis (Paper IV)

In order to study the associations between the year of operation, blood loss and operating time a spline regression model was fitted using knots at the 10th, 50th and 90th percentiles year of

conducted in accordance with the World Medical Association Declaration of Helsinki (MRF-rapport, 2000). The Regional Ethical Review board in Gothenburg obtained approval: Dnr. 287-08 (Paper II), Dnr. 805-13 (Paper III) and Dnr. 391-14 (Paper IV).

Table 4. Statistical methods

Study	Data	Analysis	Test	Evaluations
I	Categorical	Non-parametric	Fisher's exact test	Between group differences
II	Categorical Numerical	Non-parametric	Fisher's permutation test Pitman's test Mantel's test	Between-group differences Correlations Between-group differences adjusted for other variables
III	Categorical Numerical	Parametric	Poisson regression model Spline regression model	Survival analysis Survival analysis
IV	Categorical Numerical	Non-parametric	Fisher's permutation test Pitman's test Spline regression model	Between-group differences Correlations Correlations

operation to, as recommended by (Harrell, 2001). The splines were second-order functions between the breakpoints and linear functions at the tails resulting in a smooth curve.

Ethical considerations

The first study was a register study and therefore not proved ethically due to the retrospective design (Paper I). All the other studies in this thesis were

RESULTS

Study groups

Subjects

- The study groups were comparable regarding the number of patients, age and gender

Mean age and range

- Mean age 38.5 years (range 16–84) (Paper I)
- Mean age 23.6 years (range 17–62) (Paper II)
- Mean age 22.9 years (range 15–66) (Paper III)
- Mean age 23.2 years (range 18–62) (Paper IV)

Osteotomies (Paper II-IV)

- Maxillary (n=103)
- Mandibular (n=150)
- Bimaxillary (n=155)

Osteotomies and genioplasty (Paper II-IV)

- Bimaxillary and genioplasty (n=21)
- Mandibular and genioplasty (n=12)
- Maxillary and genioplasty (n=13)

Paper I

Dental root injury (Paper I)

All iatrogenic dental injuries were associated with the predrilled bone anchor screw technique. Twenty-nine patients (45.3%) ($p < 0.001$) and 59 teeth were injured at time of surgery. These findings were based on information from postoperative radiographs that were obtained after surgery and before discharge from the hospital. Ten patients (15,6%) and 16 teeth were considered permanently damaged one year after surgery. These findings were based on follow-up radiographs, which were performed on the twenty-nine patients with dental root injuries. To sum up, forty-three teeth recovered spontaneously, thirteen teeth were treated with endodontics and one tooth was extracted. No visible injuries to dental roots were noticed on radiographs in the drill-free group.

Surgical technique (Paper I)

The twist drill, pre-drilled technique, used in transalveolar positions caused all iatrogenic dental root damages.

Paper II

Facial oedema

The level of facial oedema was significantly less in the steroid groups compared to the control group the first day after surgery ($p=0.017$). No differences were found between the study groups regarding facial oedema 7 days, 2 months and 6 months postoperatively.

Pain

Significantly more postoperative pain was associated with increased intraoperative bleeding ($p=0.043$) in all study groups. No differences between the study groups regarding postoperative pain were found during the follow-up period.

Neurosensory disturbances

A visualized nerve in the cancellous bone during the BSSO procedure resulted in impaired sensitivity the first day after surgery ($p=0.018$), with minimal differences 7 days after surgery and with no differences 2 months and 6 months after surgery. Increased age hindered full recovery of neurosensory disturbances at 6 months postoperatively ($p=0.046$). Higher postoperative requirements of diclofenac and paracetamol were associated with significant

delayed recovery of neurosensory disturbances in the lower lip ($p<0.001$).

Steroids

The two study groups with betamethasone reduced facial oedema equally the first day after surgery ($p=0.017$). Betamethasone could not shield the nerve and could therefore not reduce self-experienced neurosensory disturbances over time.

Paper III

Fixation plate removal

- The incidence of plate removal was 15% ($n=50$)
- The incidence of plate removal due to infection was 10% ($n=33$).

Survival of plates

- Fifteen percent of all responding subjects had plates removed: 17 patients (34%) had their plates removed within the first six months and 31 (62%) had their plates removed within the first year
- Ten percent of all responding subjects had plates removed due to infection: 15 patients (45%) had their fixation plates removed within the first six months and 24 patients (73%) had their fixation plates removed within the first year.

Plate related complications

- Fifteen percent of all included patients had plates removed due to plate related complications and 92% of these patients were relieved from discomfort after removal.

Reasons for plate removal (n=50)

- Tenderness/pain (66%)
- Exposed plate (8%)
- Detached plate (6%)
- Aesthetics (6%)
- Other reasons (12%)

Smoking

- Smoking increased the risk for plate removal: Hazard Ratio (HR 2.74) (p=0.024)
- Smoking and infection increased the risk for plate removal with (HR 3.44) (0.0024).

Osteotomy in the mandible (BSSO)

- Osteotomy in the mandible increased the risk for plate removal: (HR 2.40) (p=0.025)
- Osteotomy in the mandible increased the risk for removal with (HR 3.31) (p=0.025) in combination with infection.

Additional fixation plates

- For each additional plate added the

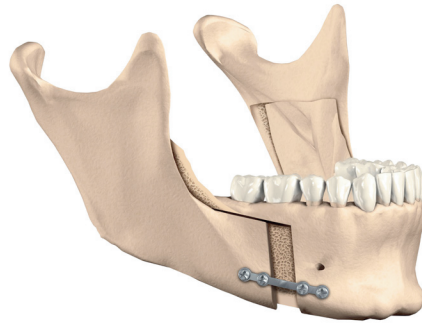


Figure 12. One single osteosynthesis plate inserted near the mandibular border implicate that the distance to the mucosal incision line is extended.

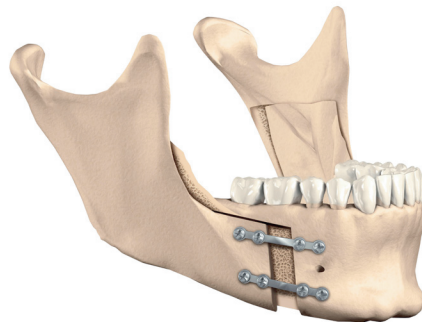


Figure 13. One additional osteosynthesis plate on each side of the mandible implicates that the distance to the mucosal incision line is reduced.

risk for removal increased with 34% (p=0.0038) (Figure 12 & 13)

- For each additional plate added the risk for removal increased with 37% (p=0.0096) in combination with infec-

tion.

Operating time

- The mean operation time was 190 minutes (range 57–460) and was not shown to be a risk factor for fixation plate removal.
- A spline regression model reveals a trend towards higher risk for plate re-

plate removal per 100-person and year was HR 3.3 (95% CI: 1.9-5.5), at the 50th percentile of total operating time (161 minutes) the risk of plate removal per 100-person and year was HR 2.6 (95% CI: 1.7-4.0) and at the 90th percentile (331 minutes) the risk of plate removal per 100-person and year was HR 4.3 (95% CL: 2.5-7.3) (Figure 6, Paper III).

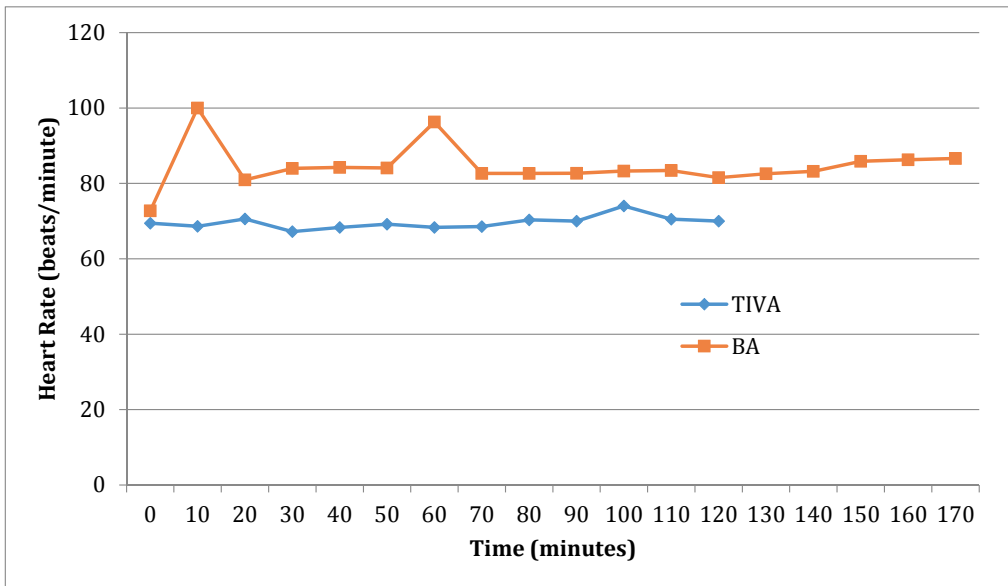


Figure 14. Heart rate measured every 10th minute during surgical procedures. Mean value of heart rate for TIVA (n=18) and BA (n=76).

moval in relation to operating time with approximately <100 minutes or >200 minutes. At the 10th percentile of total operating time (93 minutes) the risk for

Paper IV

Blood loss

- Increased intraoperative bleeding resulted in delayed recovery from pain during the postoperative period (p=0.043)
- No differences were found between the two general anaesthetic protocols regarding blood loss
- Higher age resulted in decreased blood loss (p<0.001).

Heart rate

- TIVA facilitated haemodynamic stability through superior pain/stress control during the surgical procedure in comparison to the BA group (Figure 14)
- Higher heart rates (mean & max) increased blood loss and operating time.

Mean arterial pressure (MAP)

- Higher MAP (max) increased hospitalization (p=0.043).

Recovery time at the post anaesthetic care unit (PACU)

- Prolonged operating time increased recovery time (minutes) (p=0.0029)
- Prolonged anaesthetic time increased recovery time (minutes) (p=0.0020).

Postoperative analgesics

No significant differences regarding the

two general anaesthetic protocols were found regarding consumption of analgesics such as paracetamol, NSAID's or opioids.

Hospitalization

- Prolonged operating time increased hospitalization (days) (p<0.001)
- Prolonged anaesthetic time increased hospitalization (days) (p<0.001).

DISCUSSION

Methodological considerations

The aim of this thesis was to evaluate short- and longterm factors that could influence the clinical outcome of orthognathic surgery. Furthermore, the thesis was designed to study multiple perspectives such as morbidity, surgical technique, survival of fixation plates, risk factors, haemodynamics and recovery parameters. This was performed with the use of both quantitative- and qualitative data, and with two different methodological approaches; controlled and longitudinal. The longitudinal method was appropriate for studying a cause of a condition, a risk factor for examining conditions that develop over long time and investigating a preliminary hypothesis. The controlled trial is the basic method against which other methods are judged, because it provides the greatest justification for concluding causality and is related to the least number of problems or biases. This method was preferable when the objective was to establish the efficacy of a treatment or a procedure (Trapp and Dawson-Saunders, 1994).

The single centre ap-

proach was beneficial for the randomized controlled trial (Paper II) and the longitudinal study (Paper IV) because that evaluation of intraoperative drugs requires the surgical procedure and anaesthetic protocols to be as constant as possible during the study period (Table 1). Additionally, these studies were further strengthened due to frequent use of standard protocol during the study period and the limited number of surgeons involved. The dual centre approach was beneficial for the longitudinal studies, because similar surgical techniques were used in the region, thus maximizing the size of the patient material (Table 1) (Paper I, III).

The main shortcomings in the longitudinal studies were the limited possibilities of controlling potential confounding factors and bias. These limitations consisted of extended study periods, subsequently adjustments in surgical technique and variations in quality of the data assembled from medical records over time. Strict inclusion criteria resulted in higher reliability although with a potential risk of reducing the study group.

Comments on material, methods and results

The first study was designed as a dual centre study in order to assemble as many patients as possible from the same region (Paper I). The study period was chosen to include sufficient and equal number of patients with the pre-drilled and the drill-free bone anchor screw technique, in order to utilize comparable groups. It was known that the pre-drilled technique, with use of the twist drill in transalveolar positions, possibly was hazardous to dental roots, although not the magnitude. The drill-free technique was the most frequent technique in use when the study design was planned. Both techniques had been used in both orthognathic and maxillofacial trauma patients for intermaxillary fixation, although more frequently in use on trauma cases. It was therefore decided to include a population with trauma patients for the study. In the historical context, advancements within the field of orthognathic surgery have from different aspects evolved through basic principles on traumatology, such as intermaxillary fixation or with miniplates for osteosynthesis. It was therefore assumed that the outcome from a population with trauma patients could be applicable even on orthognathic patients. Additionally, the dual centre approach was appropri-

ate due to the similar techniques for bone anchor screws used in the region during the study period. The retrospective design, with the ability to expose a risk factor, was the most ethical and reasonable approach to the data on the existing knowledge regarding the possibility to expose a hazardous surgical technique. The study period was not extended to include more patients because of difficulties to retrieve radiographs before the year of 2000.

Nevertheless, the use of bone anchor screws in orthognathic patients are occasionally required in transalveolar position as a horizontal reinforced rigid emergency anchor for proper intermaxillary fixation if occasionally the orthodontic appliances loosen during surgery. Stable intermaxillary fixation is essential and a keystone in order to implement the orthognathic planning to the jaws and dentition. Additionally, the bone anchor screws may be used for intermaxillary fixation in patients who are planned for surgery due to jaw malformation, although with a correct occlusion, and therefore not requiring preoperative orthodontic treatment with orthodontic appliances.

The radiographs taken before discharge from the hospital were: profile, frontal, orthopanthomo-

gram or computer tomography (CT) scans in all patients. These radiographs were not standardized between the two centres involved in the study and could therefore vary in performance. The calculations regarding “number of injured patients at the end of surgery” were therefore considered solid. However, the main shortcoming in this study was the calculation of “number of injured patients after >1 year” because it was not possible to retrieve complete information regarding recall visits due to incomplete medical records. The quality of the study would have been strengthened if additionally a questionnaire had been sent to all patients or if all patients had been offered additional follow-up clinically and radiographically. This approach would have confirmed existing iatrogenic injuries and evaluated progression or healing of these injuries. However, it was ethically not risk free to recall patients regarding a previously used hazardous surgical technique and therefore not done. Implications and results regarding the incidence of permanent injuries with extracted teeth, endodontic treatment, and healing situations one year after surgery are therefore weak and should be interpreted with caution.

The results of the first

study showed that the use of the drill-free, self-drilling and self-tapping screws was safe due to the absence of visible radiographically iatrogenic dental root injuries. These findings are confirmed in previous clinical studies (Coletti et al., 2007; Roccia et al., 2009) and in experimental studies (Asscherickx et al., 2005; Dao et al., 2009). Nevertheless, the technique is not without limitations or potential consequences. Preoperative radiographs are recommended for anatomical orientation and in order to provide safe treatment. Anatomical structures such as the neurovascular bundle must be respected. The risk of screw loosening with risk for ingestion or aspiration should be considered (Son et al., 2014). The use of the smaller orthodontic bone anchor screws is regarded safe in the hands of a professional, simplifies the intermaxillary procedure, saves time and subsequently costs.

The use of the twist drill in transalveolar positions (predrilled technique) has been evaluated in several studies (Coburn et al., 2002; Fabbroni et al., 2004; Roccia et al., 2005). Fabbroni et al., (2004) investigated the incidence of iatrogenic dental root injuries caused by the twist drill on dental roots as minor (15.9%) or major contacts (11,2%),

and concluded that the clinically significant damage to the dental roots appears to be low. However, this conclusion is not acceptable due to the safe and viable alternatives such as drill-free bone anchor screws, archbars and ligatures. Iatrogenic dental root injuries are unacceptable, and it is therefore suitable to proclaim that the pre-drilled bone anchor technique with a twist drill is highly hazardous for iatrogenic dental root injuries, and the technique should therefore not be used in transalveolar positions. Furthermore, clinical recommendations regarding insertion of the drill-free bone anchor screw are preferred to be in the attached mucosa near the junction to the mobile mucosa in order to minimize the risk of mucosal wounds. Additionally, the orthodontic titanium bone anchor screws with smaller thread diameters, approximately 1.5 mm, thread lengths of 6-8 mm, and a flattened head are sufficient in most cases. Bicortical positions are recommended for stability during extended use in time (Paper I, Figure 7) (Brettin et al., 2008). These smaller screws are well tolerated by the patients and are therefore possible to use with guided elastics for weeks post-operatively. The bigger screws with a thread diameter of 2.0 mm, and thread

lengths of 8-12 mm, have greater heads and can cause massive mucosal wounds if they are left for traction use postoperatively, and are therefore only suitable for use intraoperatively. These longer thread lengths are also often too long in transalveolar positions causing unnecessary trauma (Paper I, Figure 6).

The second study was designed as a clinical randomized controlled trial (RCT) in order to evaluate the efficacy of two steroid regimes on postoperative facial oedema, pain and neurosensory disturbances (Paper II). The single centre design secured homogenous surgical technique in performance of the BSSO with a uniform team of surgeons. The patients were consecutively recruited and received information regarding the objectives of the study. It was emphasized that participation was based on free will. All participating patients signed informed consent. The inspiration and aim was to confirm the results earlier presented by Weber et al., (1992) and Al-Bishri et al., (2004). Weber et al., (1994) designed a randomized, prospective, double blind study (n=23) to determine the efficacy of dexamethasone in reducing facial oedema after BSSO's and concluded that betamethasone significantly reduced

facial oedema the first day after surgery. Al-Bishri et al., (2004) performed a retrospective study (n=43) and concluded that steroid regimes might be beneficial in reducing neurosensory disturbances after BSSO, although suggesting further investigations. The size of the study groups in this present study was decided to be the same as in the study presented by Weber et al., (1994) (n=23) or if possible extended. Patients were consecutively recruited to the study and the assembled data was analysed (n=37) (Paper II). Based on the differences between the two treatment arms and the control group, it was statistically estimated that a future study would require a three to four times larger study group to achieve statistical power of 80%, if the differences were found true. However, it was difficult to recruit sufficient number of patients in this limited surgical population and the enlisting of patients was drawn-out over time. It was therefore decided to terminate the recruitment of patients in March 2011 (n=37).

General anaesthesia was during the first part of the study period (2008-2009) predominantly performed with BA. The standard protocol for general anaesthesia was changed during the last part of the study peri-

od (2010-2011) in favour for TIVA for a majority of the patients. The change of the general anaesthetic protocol was performed due to changes in standard protocols at the local hospital and therefore not able to control. Although, it was assumed that the two general anaesthetic protocols did not influence the outcome of the study design, which partly was confirmed by the results in the fourth study, since we did not find any significant differences between the protocols (Paper IV). Nevertheless, it was a drawback that the anaesthetic protocols were not maintained homogenous during the study period. Postoperative infiltration of the wound with long duration local anaesthesia (ropivacaine 7.5 mg/ml) administered at the end of surgery was not performed in this study group.

Weber et al., (1994) utilized measurements of facial oedema with CT scans and standardized photographs. In this present study it was decided that it was not ethical to measure facial oedema with CT scans due to the high exposure of radiation. Furthermore, standardized photographs were not considered accurate alone. It was therefore decided to use a new simple, although not validated method. Facial oedema was objectively measured as

the distance between the earlobes and below the chin. All participating clinicians were instructed and informed regarding the measurements before onset of the study. The inter- and intra-operator reliability had been even more strengthened if structured measurement exercises had been utilized and evaluated before start of the study. This was unfortunately not done. The simple measurement method presented in this study may furthermore be criticized due to limited possibilities to differentiate between facial oedema and haematoma. Nevertheless, it was believed that postoperative bleeding mainly was drained through intraoral incisions due to the incompact suturing of the mobile mucosa. Extraoral drainage was not used in any cases because these incisions give visible scars and are furthermore believed to increase the risk for postoperative infections. Therefore, the reliability of the measurements regarding facial oedema would have been even more strengthened if they statistically had been compared and validated in relation to the newly developed Gothenburg Trismus Questionnaire (GTQ) (Johnson et al., 2012). For future measurements there is a new superior and recently validated technique, the three-dimensional stereophotogram-

metry, that is a reliable, accurate and non-invasive tool for measuring soft tissue changes over time (van der Vlis et al., 2014).

Neurosensory disturbances can be measured subjectively and/or objectively. They can be quantified objectively with measures of 2-point discrimination or as pressure-pain thresholds or as perceived self-ratings regarding sensation changes in specific facial regions. Chen et al., (1999) compared these three methods of assessing neurosensory loss following orthognathic surgery. It was found that subjective self-rating reports of neurosensory changes were consistent with tests of 2-point discrimination but the objective test of pressure-pain thresholds was least sensitive to neurosensory changes. Other tests described in the literature are thermal discrimination and sensibility testing of mandibular molars, although not used in this present study (Ylikontiola, Kinnunen, Laukkanen, et al., 2000). Pratt et al., (1996) confirmed that objective neurosensory testing validated the patients subjectively reported sensory status. Nevertheless, it is also reported that subjective self-reports have higher scores of neurosensory deficit compared with objective sensory testing

(Leira and Gilhuus-Moe, 1991), but the reverse relationship has been found as well (Fridrich et al., 1995). In order to limit the amount of testing on the patients (facial oedema, pain and neurosensory disturbances) over time, it was decided appropriate to measure neurosensory disturbances only subjectively in this thesis.

The visual analogue scale (VAS) is a one-dimensional numeric self-rating scale for assessment of pain. It is widely used in acute and postoperative pain assessments. The scale has good validity and reliability due to its clinical relevance (Huskisson, 1974; Breivik et al., 2008). This was the only method used in assessing postoperative self-estimated pain in the present study.

Steroids reduced facial oedema significantly the first day after surgery. This finding confirms the result presented by Weber et al., (1994), although different strategies for administration and dosages were presented in the two studies. Weber et al., (1994) administered each patient one preoperative infusion and three postoperative infusions every six hours. Controls received placebos for all infusions. The first group received 16 mg dexamethasone (intravenous) preoperatively and

three placebo doses. The second received 16 mg dexamethasone (intravenous) and three 8 mg dexamethasone doses. The dosages administered varied between 16-40 mg dexamethasone (biologic half-life 36-54 hours). In the present study (Paper II) the first group received a single betamethasone dose (16 mg intravenously at induction), the second group received repeated betamethasone dosages (4 mg orally one day before surgery, 8 mg intravenously at induction, and 4 mg orally one day after surgery) and the controls received no placebo and no steroids. The dosages administered were totally 16 mg betamethasone (biologic half-life 36-54 hours). Lack in differences between the steroid regimes and administration strategies, regarding the effect on facial oedema the first day after surgery in both studies, might support the single dose due to its convenience. Furthermore, these results may recommend 16 mg betamethasone in all orthognathic cases to promote reduction of facial oedema the first day after surgery. However, lower dosages might be sufficient in reducing facial oedema but this was not possible to show with the present study design. New treatment modalities regarding facial oedema have recently evolved. Shetty et al., (2013) have eval-

uated systemic enzyme therapy, which shows significantly decrease of post-operative facial oedema. However, this new therapy was not evaluated in relation to multimodal outcomes such as pain and recovery.

Al-Bishri et al., (2004) rendered that steroid regimes might be beneficial in reducing neurosensory disturbances after BSSO's. The regimes demonstrated were administered as a standard doses of 4 mg four times or 8 mg three times per day during the first 24 hours and starting immediately before surgery. The dosages administered varied between 12-24 mg betamethasone (biologic half-life 36-54 hours). Conversely, these findings were not possible to confirm with the study design. It was therefore concluded that betamethasone couldn't reduce neurosensory disturbances over time with the administration strategies and dosages presented in this study (Paper II). However, the timing for administration and optimal dosages of steroids remains unclear. Seo et al., (2004) presented an alternative approach with starting time for steroid treatment: 1 week, 3 weeks or 6 weeks after surgery, and with a control group that did not receive steroid treatment. Prednisolone treatment was administered orally to all patients:

30 mg for 7 days, 15 mg for 4 days and 5 mg for 3 days. It was concluded that steroid treatment for sensory impairment after BSSO's has the potential to accelerate recovery of the nerve and it appears desirable to start treatment later than one week postoperatively. These findings may support extended steroid treatment after BSSO's although these findings were not supported in this present study due to limitations in study design. Additionally, it is previously shown that prolonged neurosensory deficit is strongly related to the intraoperative magnitude of mandibular movement (Leira and Gilhuus-Moe, 1991; Ylikontiola, Kinnunen, & Oikarinen, 2000). However, these findings were not confirmed in the present study, likewise not in the thesis presented by Al-Bishri (2004). Furthermore, this present study demonstrated that higher postoperative requirements for diclofenac and paracetamol were significantly associated with delayed recovery of neurosensory disturbances in the lower lip during the six months study period. This finding may correlate with more advanced mechanical nerve injuries caused during the surgical procedure of the split osteotomy. Sutherlands (1951) classification of nerve injuries shows that demyelinating nerve

lesions heal completely, normally within 2-4 months, along with remyelination. This whilst axonal injuries recover incompletely, slowly over months and years, and also with higher risk of developing postoperative sequelae such as postoperative pain and paraesthesia. The nerve injuries presented in this study were not possible to classify or measure with the present study protocol. However, the trigeminal somatosensory evoked potential (TSEP) and sensory nerve action potential (SNAP) recording are two techniques utilized in order to classify nerve injuries. The TSEP technique uses electroencephalography (EEG) electrodes on the scalp in order to register responses to nerve stimulation. Nevertheless, this method is not fully reliable in order to monitor peripheral sensory nerve function during surgery due to the so-called amplification factor, which may obscure axonal lesions by compensation at the more proximal levels (Nakagawa et al., 2001). The SNAP technique is the most reliable and sensitive method but also the most invasive measurement method for intraoperative evaluation of nerve lesions. The inferior alveolar nerve is stimulated at the mental foramen with two monopolar needle electrodes fixed to the dental splint, and

the SNAP of the inferior alveolar nerve is recorded with a silver-wire electrode inserted near the foramen ovale at each side of the patient (Jaaskelainen et al., 2000; Jaaskelainen et al., 2004).

No differences regarding pain were found between the two steroids regimes and the control group the first day after surgery. This result was unexpected because several clinical trials have confirmed the advantage in combining NSAID's and glucocorticoids over either agent alone in the control of postoperative pain (Troullos et al., 1990; Buyukkurt et al., 2006). Compensation with postoperative opioids may explain the lack of these differences. Consequently, it would have been beneficial for the quality of the study to measure postoperative opioid consumption, but this has unfortunately not been done. Additionally, Dan et al., (2010) showed in a systematic review that administration of corticosteroids decrease facial oedema and pain significantly with no higher risk for infection and with a minimum risk of other side effects.

Increased intraoperative blood loss resulted in a significantly delay in recovery from pain during the postoperative period. These findings are unique, and to my knowledge

not found elsewhere in the literature. However, no differences were found between the study groups and control group regarding blood loss. This result might therefore indicate that higher doses of steroids do not increase blood loss in orthognathic patients. However, another study evaluating postoperative bleeding in children after tonsillectomy, that received dexamethasone (0.05 mg/kg; 0.15 mg/kg; 0.5 mg/kg) showed an increased risk for postoperative bleeding complications and the trial was stopped for safety reasons (Czarnetzki et al., 2008). Nevertheless, no severe bleeding complications occurred in this present study.

The third study was designed as a longitudinal dual centre study in order to assemble as many patients as possible in two study groups from the same region (paper III). The study was strengthened due to the high prevalence of patients responding on the questionnaire. Additionally, all combinations of osteotomies were included in the study. To my knowledge this is the first study found in the literature evaluating plate related complications regarding genioplasty osteotomies. The power analysis supported statistical strength of 80% with 405 included patients, although this was not fully

achieved due to the dropouts (20%) in the chosen study period. Data was extracted from medical records and complemented with a questionnaire. This was utilized for several reasons. The first reason was to control the study population. We had to be absolutely certain that patients had not moved and/or removed plates in other counties of Sweden or other worldwide countries. This made it possible to calculate on survival analysis of the fixation plates. The second reason was to secure the information in the medical journals regarding tobacco use, even though this information was incomplete.

All patients were in written informed about their free will in participating and answering the questionnaire. Patients not responding on the questionnaire were contacted for a structured telephone interview. The patients were once again informed about their free will in participating. The questions were discussed and together with the patient interpreted as dichotomous answers. All patients operated with orthognathic surgery were at three planned appointments preoperatively informed about the negative consequences of smoking. The patients were recommended to quit smoking or take a break one month before and

one month after surgery. However, the tobacco habits registered in the medical journals quantified only as dichotomous answers. Many journals were also incomplete regarding tobacco habits but this drawback was complemented by the questionnaire. Additionally, many patients could not answer on the degree on tobacco consumption in past times and perhaps due to psychological suppression. Therefore, we could not differentiate the different consumption levels of tobacco habits and transform these results as risk factors.

Bacterial sampling or blood infection parameters were not performed in any case when treating demarcated chronic or acute infections related to the inserted plates. The classification of infection in this present study was therefore based on the patient's opinion of the cause for plate removal and this information was confirmed by data from the medical journals regarding diagnosis of infection and administration of antibiotics. Also the wound appearance was not described properly in the medical journals, which was a drawback. These facts were together shortcomings although higher quality of answers would require a prospective approach and perhaps another alternative study design

to distinguish between foreign body reaction with inflammation and perhaps subsequently infection. The reliability in the answer regarding the reason for plate removal due to infection was therefore weakened. Nevertheless, we believe that the results are strengthened in the best way possible with this present retrospective study design and that the conclusions therefore are valid.

It is hypothesized that early infections with removal of plates within the first year after surgery relates to the distance between the fixation plate and the mucosal incision line and subsequently exposing the plate or plates for the intraoral microbiological environment during the healing period. It is shown that fixation plates placed near the mandibular lower border have reduced risk for removal Alpha et al., (2006). The reason is not clear although it could furthermore be hypothesized that the vascularization is superior near the mandibular border in comparison to the position close to the mucosal incision line. These findings might be in line with the present results that additional number of inserted plates resulted in more plate removal, thus related to shorter distance between the fixation plate and the mucosal incision line because lack

of space. However, deeper analysis regarding the relations or the differences regarding inflammation, foreign body and subsequently infections are needed to fully understand the reasons for plate removal. The study would have been strengthened even more if we could have distinguished between the distance of the inserted fixation plates and the mucosal incision line. This was not done in the present study.

Removal of plates in the mandible with local anesthesia is a simple procedure with low morbidity. Additionally, this present study shows that a majority of the patients with removed plates due to any plate related complications or inconveniences were relieved from discomfort after plate removal. Thus, the decision to remove plates inserted in the mandible was therefore simple to decide and with limited costs for the patient and the clinic. However, removal of plates in the maxilla requires in many cases general anaesthesia and the indication has to be strong due to higher morbidity and with higher expenses. Nevertheless, postoperative removal of fixation plates is an unnecessary cost for the patient and the clinic, and it is therefore of great importance to minimize this procedure. This present study shows

that the incidence of plate removal can be minimized through elimination of smoking. However, it was not possible to recommend any time span for a temporary break in smoking before and after surgery with this study design.

The fourth study was designed as a single centre study in order to compare two general anaesthetic protocols and to evaluate the outcome of these protocols on haemodynamics and recovery parameters in orthognathic patients (Paper IV). The single centre design was believed beneficial in securing data from as homogenous protocols as possible, thus these protocols can vary between different hospitals and sometimes within the hospital. Patient selections regarding inclusion and exclusion criteria were thoroughly discussed in the research group, which included a statistician. The main objective was to establish comparable study groups with sufficient amount of patients for statistical strength. It was therefore decided to perform a longitudinal 10-year study. Segmental osteotomies and genioplasty osteotomies were excluded because these patient groups were believed not homogenous due to great variations in blood loss and operating time. Preoperative β -adrenergic an-

tagonists were excluded due to their heavy impact on intraoperative haemodynamics. Patients that who received intraoperative atropine, glycopyrrolate, ephedrine or phenylephrine were excluded due to occasions of bradycardia and/or severe hypotension. This because the intention with the study design was to strictly evaluate the two general anaesthetic protocols separately in relation to haemodynamics. The NU Hospital Group classified children as <18 years. All children were excluded due to different standard protocols regarding postoperative care and opioid treatment at the PACU in contrast to the adult population. Patients with BMI ≥ 35 were excluded due to the risk of uneven distributions of the anaesthetic drugs and subsequently lack of standard protocol regarding dosages of anaesthetic drugs. Patients demanding bone augmentation, tooth extraction or implant placements were excluded because we wanted to maintain strict comparable groups in regard to operating time.

The main shortcoming with this study was that data was collected retrospectively and with limited possibilities of controlling potential confounding factors and bias. Nevertheless, it was believed that the use of

standard protocols and application of strict exclusion criteria have strengthened the study. On the other hand this selection resulted in decimated and subsequently uneven study groups. However, a dual centre study evaluation had been difficult and most certainly impossible to perform, due to different standard protocols in anaesthesia and surgery techniques at different clinics in the region. Less strict exclusion criteria regarding segmental osteotomies would have increased the number of subjects. Nevertheless, this had raised the question regarding bias and reliability of the study due to more intraoperative bleeding in vertical osteotomies and subsequently extended operation time. Given these limitations the results should be interpreted with caution.

Significant differences at baseline regarding date of surgery and diastole were found. Furthermore, the two general anaesthetic protocols were not evenly distributed during the study period between 2003 and 2013. The fentanyl-sevoflurane based BA protocol was more common in the first part of the study period, whilst the remifentanyl-propofol based TIVA protocol was more common in the later part of the study period. Diastole at baseline was lower in the BA group and probably

due to the premedication with triazolam that was more frequently used in the BA group (Paper IV, Table 2). Additionally, significant differences were found regarding preoperative administration of morphine/oxycodone and meclizine. However, it is not believed that these differences due to premedication further influenced on variables regarding baseline haemodynamics. No significant differences regarding blood loss, operating time, recovery time, PONV or hospitalization were found between the general two anaesthetic protocols. To my knowledge this is the first study comparing intraoperative blood loss between the remifentanyl-propofol based TIVA protocol and the fentanyl-sevoflurane based BA protocol. Eberhart et al., (2003) rated surgical conditions in visibility significantly better in the remifentanyl group and hypothesized that lower cardiac output may be responsible for the result. However, the present study design could not clarify the role of cardiac output related to blood loss and it was therefore not possible to confirm these finding.

It might be reasonable to assume that faster elimination properties of the ultra-short acting opioid remifentanyl in comparison with longer-acting opioids may reduce the opi-

oid-related side effects such as PONV due to the faster elimination of the opioid. However, Komatsu et al., (2007) and Chegini et al., (2012) showed that there were no differences in the incidence of PONV between the general two anaesthetic protocols, which also was supported in this present study. Komatsu et al., (2007) showed in a review that the recovery profile was enhanced and with less respiratory depression when using remifentanyl. Nooh et al., (2013) found that the use of remifentanyl-propofol based anaesthesia TIVA facilitated early emergency from anaesthesia, time to awakening was shortened, tracheal extubation was performed sooner, and they concluded that these findings are exceptional useful in orthognathic surgery because remifentanyl may enhance the possibility to extubate with the airway reflex intact. This is important because bleeding from the maxilla can be extensive and occasionally continue after surgery. Nevertheless, it was not possible with this retrospective study design to demonstrate significantly differences regarding the quality of recovery (Nooh et al., 2013; Lee et al., 2014) shorter recovery times or hospitalization as presented in several other studies when comparing these two general anaesthetic protocols (Twersky et al.,

2001; Komatsu et al., 2007).

It was graphically exposed that the starting point of more painful procedures were revealed in the BA group due to episodes of increased heart rates in contrast to the TIVA group (Figure 14). The heart rates were measured every 10th minute and graphically shown as a mean value. The haemodynamic effects of preoperative infiltration with lidocaine 2% epinephrine (1:200,000) intubation and extubation were in this present study not graphically exposed because these procedures were performed before the measurements were started and finished. Additionally, one single study in the literature has previously graphically shown that haemodynamic measurements starting at baseline reveals that remifentanyl is effective in the control of the pain and stress response related to both tracheal intubation and extubation (Wilhelm et al., 2000). Nooh et al., (2013) chose to measure haemodynamics as heart rate and MAP. Wilhelm et al., (2000) chose to quantify haemodynamics as heart rate and systolic blood pressure. This present study evaluated haemodynamics with heart rate, systole (mean & max), diastole (mean & max) and MAP (mean and max) in relation to blood loss. To sum up, this present study

revealed that remifentanyl-propofol based TIVA promotes superior haemodynamic stability in comparison to the fentanyl-sevoflurane based BA protocol. These findings add to the accumulation of evidence towards the positive effect of remifentanyl in preventing responses of noxious stimuli during surgery. Twersky et al., (2001) confirmed the superior effect of remifentanyl on haemodynamic control due to lower heart rate in comparison to fentanyl in a large cohort study with 2438 patients. Komatsu et al., (2007) found that the administration of remifentanyl was associated with signs of deep-operative analgesia and anaesthesia such as lower blood pressure and heart rates, as well as lesser hypertension and tachycardia in response to surgical stimuli. Nooh et al., (2013) concluded that remifentanyl promotes haemodynamic stability and blunts stress response to noxious stimuli in comparison to fentanyl in a smaller prospective study with 17 patients.

There was a significant and continuously improvement regarding reduced blood loss, operating time and hospitalization during the 10 year study period regardless anaesthetics technique (Paper IV, Figure 4 & 5). However, it was not possible to point out any specific reasons for these improve-

ments over time. Therefore, it is reasonable to believe that this outcome may be caused by continuously refinement of the surgical technique, improved surgical skills with reduced operating time and subsequently with decreased blood loss. These results were followed by a non-significant trend through reduced hospitalization in favour for the remifentanil-propofol based TIVA protocol with approximately 0.5 days.

Several studies have associated remifentanil with a higher need for postoperative analgesics (Guignard et al., 2000; Komatsu et al., 2007). Patients receiving remifentanil required additional postoperative analgesics about 40% more frequently than patients receiving other types of longer-acting opioids (Komatsu et al., 2007). This need for additional analgesics after remifentanil-propofol based TIVA may be explained by the effect of the ultra-short opioid. It is therefore necessary to effectively address this need for pain relief with appropriate postoperative treatment without hindering postoperative mobilization. However, longer-acting opioids have potential adverse effects such as prolonged mobilization and recovery. At the time for introduction of remifentanil-propofol based TIVA at the an-

aesthetic unit, involved in this present study (Paper IV), the PACU experienced difficulties in controlling postoperative pain although increased dosages of longer-acting opioids were administered. Therefore, local infiltration of the surgical wound with ropivacaine 7.5 mg/ml was introduced at the end of surgery in order to relieve pain, to minimize postoperative longer-acting opioid consumption and to facilitate mobilisation of the patient. Subsequently, it was shown that long duration local anaesthetics administered at the end of surgery significantly reduced hospitalization when analysed separately. However, this significance was lost when the time factor was added and data was analysed multivariate, probably due to the late introduction of ropivacaine during the study period (August 2010). It was therefore concluded that ropivacaine appears to improve mobilisation of the patient and reduce hospitalization.

CONCLUSIONS

- There is a potential risk for iatrogenic injury and permanent damage to dental roots during intermaxillary fixation when using a twist drill for bone anchor screws. Drill-free, self-tapping, bone anchor screw do not cause root injuries
- Facial oedema was reduced the first day after surgery when betamethasone was administrated regardless dose. However, betamethasone did not reduce neurosensory disturbances. Less intraoperatively blood loss was associated with enhanced pain recovery over time. Patients who required higher dosages of postoperative analgesics due to pain had delayed recovery of the neurosensory disturbances
- The incidence of plate removal was 15%. Smoking, osteotomies performed in the mandible, and additional number of inserted plates, resulted in more frequent plate removal. A majority of the patients were relieved from plate related complications and discomfort after plate removal
- No significant differences were found between the two general anaesthetic protocols regarding blood loss, operating time, recovery time, postoperative nausea and vomiting (PONV) and hospitalization. Remifentanil-propofol based total intravenous anaesthesia (TIVA) facilitates better haemodynamic stability than fentanyl-sevoflurane based balanced anaesthesia (BA). Long duration local anaesthetics given at the end of surgery appears to improve mobilization of the patient and reduce hospitalization.

ACKNOWLEDGEMENTS

This thesis was carried out in co-operation with the Department of Oral and Maxillofacial Surgery, Institute of Odontology, Sahlgrenska Academy, Gothenburg University and the Department of Oral And Maxillofacial Surgery and Otolaryngology, NU Hospital Group, Trollhättan. I would like to express my sincere appreciation and gratitude to all who have supported me and made this thesis possible, in particular:

My supervisors

Lars Rasmusson, professor and main supervisor, sharing deep experiences of research, encouragement and guidance throughout the thesis, always being available, accepting me as a doctoral student and for all help in the planning of the dissertation. It has been a great pleasure

Christer Dahlin, professor and co-supervisor, who during the last four years daily has supported me in questions, patiently encouraged my progress in research, sharing comprehensive scientific experience and guidance in applications for financial support. Giving me the opportunity to join the fellowship at the Department of Biomaterials. It has been a great privilege to spend my time of writing here

Hossein Kashani, associate professor and co-supervisor, for introducing me to the world of research, always with enthusiasm and great inspiration during the research progress, for daily guidance during the first four years, for sharing broad clinical knowledge in orthognathic surgical skills and advise in clinical reviews. I will always be grateful

My co-authors

Bengt Alsén, former head for the Department of Oral and Maxillofacial Surgery and Otolaryngology at NU Hospital Group in Trollhättan, for encouragement and sup-

port in applications for funding, providing me leave for research, help with reviews (Paper I–IV), excellent teaching and for sharing great experience especially in my orthognathic surgical training

Sanjiv Kanagaraaja, for friendship and sharing data and clinical review of (Paper I)

Jan Creutz, anaesthetist at NU Hospital Group in Trollhättan, for professional support, co-operation during the planning process, generously teaching me basic knowledge regarding general anaesthetics and for clinical review (Paper IV)

Josephine Sköldstam, dentist at the department, for extensive work in gathering and organizing data as well as having great fun together at work (Paper IV)

Mariam Afshari, dentist at the department, for extensive work in gathering and organizing data (Paper III)

My valuable supporters

Thord Ekström, specialist in otolaryngology, Head for the Department of Oral and Maxillofacial Surgery and Otolaryngology, at NU Hospital Group in Trollhättan, for support with applications for funding and providing me leave

Peter Thomsen, professor and Head of the Department of Biomaterials in Gothenburg, for generously giving me opportunity to use the resources available at the department during the writing of my thesis as well as scientific advise

Pentti Tengvall, professor at the Department of Biomaterials in Gothenburg, for valuable scientific discussions, advise in research and fellowship during coffee breaks

Júri Kartus, professor and Head of the R&D council at NU Hospital Group in Trollhättan, for generous research funding during all the years

Mogens Bove, associate professor, specialist in otolaryngology, at NU Hospital Group

Acknowledgements

in Trollhättan, for valuable scientific discussions and always presenting a good atmosphere regarding research at the local hospital

Ninni Sernert, PhD and **Leyla Roshani**, PhD, at the Department for R&D at NU Hospital Group, Trollhättan, for kind support and assistance in practical research issues

Helena Johansson, PhD in statistics, for professional statistical support and also teaching and leading me in deeper understanding of statistics

Kate Christensen, registrar at my department, for encouragement, friendship and never ending support

Marita Widar, PhD, for valuable discussions

All my dear colleagues, nurses and secretaries at the Department of Oral & Maxillofacial Surgery and Otolaryngology, NU Hospital Group in Trollhättan for friendship, encouragement and support over the years and giving me the opportunity to complete this work. Also all staff at the Department of Biomaterials & BIOMATCELL VINN Excellence Centre, Sahlgrenska Academy, University of Gothenburg for practical support and fellowship.

For financial support I want to thank:

- The R&D council of Fyrbodal, NU Hospital Group
- The Institute of Odontology, University of Gothenburg.

Finally, the most important, I want to express my warmest thanks and love to my wife Hanna who has carried an enormous working load in taking care of our home and our sweet children Alfred, Lilly and Axel. Hanna has also emotionally and faithfully supported and encouraged me during this long-time research process. I also wish to thank Ingrid and Christer, my parents-in-law, in emotional and practical help supporting Hanna and taking care of our children. Furthermore, I want to thank my parents Marita and Weine for emotional loving support and encouragement.

REFERENCES

- Agbaje JO, Salem AS, Lambrechts I, Jacobs R, Politis C: Systematic review of the incidence of inferior alveolar nerve injury in bilateral sagittal split osteotomy and the assessment of neurosensory disturbances. *Int J Oral Maxillofac Surg*, 2014. doi: 10.1016/j.ijom.2014.11.010
- Aguirre J, Baulig B, Dora C, Ekatodramis G, Votta-Velis G, Ruland P, Borgeat A: Continuous epicapsular ropivacaine 0.3% infusion after minimally invasive hip arthroplasty: a prospective, randomized, double-blinded, placebo-controlled study comparing continuous wound infusion with morphine patient-controlled analgesia. *Anesth Analg* 114: 456-461, 2012. doi: 10.1213/ANE.0b013e318239dc64
- Al-Bishri A. (2004). *Factors Affecting Neurosensory Disturbances after Mandibular Osteotomies*. (Clinical and Experimental Studies), University of Malmö, Malmö.
- Al-Bishri A, Dahlberg G, Barghash Z, Rosenquist J, Sunzel B: Incidence of neurosensory disturbance after sagittal split osteotomy alone or combined with genioplasty. *Br J Oral Maxillofac Surg* 42: 105-111, 2004. doi: 10.1016/j.bjoms.2003.12.002
- Al-Bishri A, Dahlin L, Sunzel B, Rosenquist J: Systemic betamethasone accelerates functional recovery after a crush injury to rat sciatic nerve. *J Oral Maxillofac Surg* 63: 973-977, 2005.
- Al-Bishri A, Forsgren S, Al-Thobaiti Y, Sunzel B, Rosenquist J: Effect of betamethasone on the degree of macrophage recruitment and nerve growth factor receptor p75 immunoreaction during recovery of the sciatic nerve after injury: an experimental study in rats. *Br J Oral Maxillofac Surg* 46: 455-459, 2008. doi: 10.1016/j.bjoms.2008.01.020
- Al-Bishri A, Rosenquist J, Sunzel B: On neurosensory disturbance after sagittal split osteotomy. *J Oral Maxillofac Surg* 62: 1472-1476, 2004.
- Alpha C, O’Ryan F, Silva A, Poor D: The incidence of postoperative wound healing problems following sagittal ramus osteotomies stabilized with miniplates and monocortical screws. *J Oral Maxillofac Surg* 64: 659-668, 2006. doi: 10.1016/j.joms.2005.12.013
- Arthur G, Berardo N: A simplified technique of maxillomandibular fixation. *J Oral Maxillofac Surg* 47: 1234, 1989. doi: 0278-2391(89)90024-4 [pii]

- Asscherickx K, Vannet BV, Wehrbein H, Sabzevar MM: Root repair after injury from mini-screw. *Clin Oral Implants Res* 16: 575-578, 2005. doi: CLR1146 [pii]10.1111/j.1600-0501.2005.01146.x
- August M, Marchena J, Donady J, Kaban L: Neurosensory deficit and functional impairment after sagittal ramus osteotomy: a long-term follow-up study. *J Oral Maxillofac Surg* 56: 1231-1235; discussion 1236, 1998.
- Axhausen G: Zur Behandlung veralteter disloziert geheilter Oberkieferbrache. *Dtsch Zahn-Mund-Kieferheilk* 6: 582, 1934.
- Becker DE: Pain management: Part 1: Managing acute and postoperative dental pain. *Anesth Prog* 57: 67-78; quiz 79-80, 2010. doi: 10.2344/0003-3006-57.2.67
- Becker DE: Basic and clinical pharmacology of glucocorticosteroids. *Anesth Prog* 60: 25-31; quiz 32, 2013. doi: 10.2344/0003-3006-60.1.25
- Becking AG, Zijdeveld SA, Tuinzing DB: The surgical management of post-traumatic malocclusion. *Clin Plast Surg* 34: e37-43, 2007. doi: 10.1016/j.cps.2007.04.007
- Bell WH, Jacobs JD, Quejada JG: Simultaneous repositioning of the maxilla, mandible, and chin. Treatment planning and analysis of soft tissues. *Am J Orthod* 89: 28-50, 1986.
- Bell WH, Mannai C, Luhr HG: Art and science of the Le Fort I down fracture. *Int J Adult Orthodon Orthognath Surg* 3: 23-52, 1988.
- Bell WH, Schendel SA: Biologic basis for modification of the sagittal ramus split operation. *J Oral Surg* 35: 362-369, 1977.
- Beukes J, Reyneke JP, Becker PJ: Medial pterygoid muscle and stylomandibular ligament: the effects on postoperative stability. *Int J Oral Maxillofac Surg* 42: 43-48, 2013. doi: 10.1016/j.ijom.2012.05.010
- Blair V: Operations on the jaw-bone and face. *Surg Gynecol Obstet* 4: 67-68, 1907.
- Blomqvist JE, Alberius P, Isaksson S: Sensibility following sagittal split osteotomy in the mandible: a prospective clinical study. *Plast Reconstr Surg* 102: 325-333, 1998.
- Bockmann R, Meyns J, Dik E, Kessler P: The modifications of the sagittal ramus split osteotomy: a literature review. *Plast Reconstr Surg Glob Open* 2: e271, 2014. doi: 10.1097/gox.0000000000000127

- Bouwman JP, Husak A, Putnam GD, Becking AG, Tuinzing DB: Screw fixation following bilateral sagittal ramus osteotomy for mandibular advancement--complications in 700 consecutive cases. *Br J Oral Maxillofac Surg* 33: 231-234, 1995.
- Branemark PI, Adell R, Breine U, Hansson BO, Lindstrom J, Ohlsson A: Intra-osseous anchorage of dental prostheses. I. Experimental studies. *Scand J Plast Reconstr Surg* 3: 81-100, 1969.
- Breivik H, Borchgrevink PC, Allen SM, Rosseland LA, Romundstad L, Hals EK, Kvarstein G, Stubhaug A: Assessment of pain. *Br J Anaesth* 101: 17-24, 2008. doi: 10.1093/bja/aen103
- Breslow N, Day N: Statistical methods in Cancer Research. IARC Sci Publ Volume II: 131-135, 1987.
- Brettin BT, Grosland NM, Qian F, Southard KA, Stuntz TD, Morgan TA, Marshall SD, Southard TE: Bicortical vs monocortical orthodontic skeletal anchorage. *Am J Orthod Dentofacial Orthop* 134: 625-635, 2008. doi: 10.1016/j.ajodo.2007.01.031
- Brown JS, Trotter M, Cliffe J, Ward-Booth RP, Williams ED: The fate of miniplates in facial trauma and orthognathic surgery: a retrospective study. *Br J Oral Maxillofac Surg* 27: 306-315, 1989.
- Buyukkurt MC, Gungormus M, Kaya O: The effect of a single dose prednisolone with and without diclofenac on pain, trismus, and swelling after removal of mandibular third molars. *J Oral Maxillofac Surg* 64: 1761-1766, 2006. doi: 10.1016/j.joms.2005.11.107
- Caldwell JB, Letterman GS: Vertical osteotomy in the mandibular ramus for correction of prognathism. *J Oral Surg (Chic)* 12: 185-202, 1954.
- Campbell WW: Evaluation and management of peripheral nerve injury. *Clin Neurophysiol* 119: 1951-1965, 2008. doi: 10.1016/j.clinph.2008.03.018
- Chatellier A, Dugue AE, Caufourier C, Maksud B, Compere JF, Benateau H: [Inferior alveolar nerve block with ropivacaine: effect on nausea and vomiting after mandibular osteotomy]. *Rev Stomatol Chir Maxillofac* 113: 417-422, 2012. doi: 10.1016/j.stomax.2012.10.003
- Chegini S, Dhariwal DK: Review of evidence for the use of steroids in orthognathic surgery. *Br J Oral Maxillofac Surg* 50: 97-101, 2012. doi: 10.1016/j.bjoms.2010.11.019

- Choi WS, Lee S, McGrath C, Samman N: Change in quality of life after combined orthodontic-surgical treatment of dentofacial deformities. *Oral Surg Oral Med Oral Pathol Oral Radiol Endod* 109: 46-51, 2010. doi: 10.1016/j.tripleo.2009.08.019
- Chung S, Son GH, Kim K: Adrenal peripheral oscillator in generating the circadian glucocorticoid rhythm. *Ann N Y Acad Sci* 1220: 71-81, 2011. doi: 10.1111/j.1749-6632.2010.05923.x
- Coburn DG, Kennedy DW, Hodder SC: Complications with intermaxillary fixation screws in the management of fractured mandibles. *Br J Oral Maxillofac Surg* 40: 241-243, 2002. doi: 10.1054/bjom.2001.0771S0266435601907715 [pii]
- Coletti DP, Salama A, Caccamese JF, Jr: Application of intermaxillary fixation screws in maxillofacial trauma. *J Oral Maxillofac Surg* 65: 1746-1750, 2007. doi: S0278-2391(07)00591-5 [pii]10.1016/j.joms.2007.04.022
- Converse JM, Horowitz SL: The surgical-orthodontic approach to the treatment of dentofacial deformities. *Am J Orthod* 55: 217-243, 1969.
- Converse JM, Shapiro HH: Treatment of developmental malformations of the jaws. *Plast Reconstr Surg* (1946) 10: 473-510, 1952.
- Czarnetzki C, Elia N, Lysakowski C, Dumont L, Landis BN, Giger R, Dulguerov P, Desmeules J, Tramer MR: Dexamethasone and risk of nausea and vomiting and postoperative bleeding after tonsillectomy in children: a randomized trial. *JAMA* 300: 2621-2630, 2008. doi: 10.1001/jama.2008.794
- Dal Pont G: Retromolar osteotomy for the correction of prognathism. *J Oral Surg Anesth Hosp Dent Serv* 19: 42-47, 1961.
- Dan AE, Thygesen TH, Pinholt EM: Corticosteroid administration in oral and orthognathic surgery: a systematic review of the literature and meta-analysis. *J Oral Maxillofac Surg* 68: 2207-2220, 2010. doi: 10.1016/j.joms.2010.04.019
- Dao V, Renjen R, Prasad HS, Rohrer MD, Maganzini AL, Kraut RA: Cementum, pulp, periodontal ligament, and bone response after direct injury with orthodontic anchorage screws: a histomorphologic study in an animal model. *J Oral Maxillofac Surg* 67: 2440-2445, 2009. doi: 10.1016/j.joms.2009.04.138
- Daw JL, Jr, de la Paz MG, Han H, Aitken ME, Patel PK: The mandibular foramen: an anatomic study and its relevance to the sagittal ramus osteotomy. *J Craniofac Surg* 10: 475-479, 1999.

- De Broe ME, Elseviers MM: Analgesic nephropathy. *N Engl J Med* 338: 446-452, 1998. doi: 10.1056/nejm199802123380707
- Eberhart LH, Folz BJ, Wulf H, Geldner G: Intravenous anesthesia provides optimal surgical conditions during microscopic and endoscopic sinus surgery. *Laryngoscope* 113: 1369-1373, 2003. doi: 10.1097/00005537-200308000-00019
- Epker BN: Modifications in the sagittal osteotomy of the mandible. *J Oral Surg* 35: 157-159, 1977.
- Epker BN, Fish LC. (1986). *Dentofacial Deformities*. In S. Louis (Ed.), (pp. 343-395). Toronto: Princeton: CV Mosby Company.
- Epker BN, Wolford: Middle-third facial osteotomies: their use in the correction of acquired and developmental dentofacial and craniofacial deformities. *J Oral Surg* 33: 491-514, 1975.
- Eppley BL, Sparks C, Herman E, Edwards M, McCarty M, Sadove AM: Effects of skeletal fixation on craniofacial imaging. *J Craniofac Surg* 4: 67-73, 1993.
- Espitalier F, Remerand F, Dubost AF, Laffon M, Fusciardi J, Goga D: Mandibular nerve block can improve intraoperative inferior alveolar nerve visualization during sagittal split mandibular osteotomy. *J Craniomaxillofac Surg* 39: 164-168, 2011. doi: 10.1016/j.jcms.2010.04.015
- Fabbroni G, Aabed S, Mizen K, Starr DG: Transalveolar screws and the incidence of dental damage: a prospective study. *Int J Oral Maxillofac Surg* 33: 442-446, 2004. doi: 10.1016/j.ijom.2003.10.014S0901-5027(03)00307-2 [pii]
- Falter B, Schepers S, Vrielinck L, Lambrichts I, Politis C: Plate removal following orthognathic surgery. *Oral Surg Oral Med Oral Pathol Oral Radiol Endod* 112: 737-743, 2011. doi: 10.1016/j.tripleo.2011.01.011
- Fardet L, Petersen I, Nazareth I: Suicidal behavior and severe neuropsychiatric disorders following glucocorticoid therapy in primary care. *Am J Psychiatry* 169: 491-497, 2012.
- Farr DR, Whear NM: Intermaxillary fixation screws and tooth damage. *Br J Oral Maxillofac Surg* 40: 84-85, 2002. doi: 10.1054/bjom.2001.0625bjom.2001.0625 [pii]
- Ferguson TA, Son YJ: Extrinsic and intrinsic determinants of nerve regeneration. *J Tissue Eng* 2: 2041731411418392, 2011. doi: 10.1177/2041731411418392

- Field LM: Correction by a flap of suprahyoid fat of a “witch’s chin” caused by a submental retracting scar. *J Dermatol Surg Oncol* 7: 719-721, 1981.
- Fleischli JW, Adams WR: Use of postoperative steroids to reduce pain and inflammation. *J Foot Ankle Surg* 38: 232-237, 1999.
- Fricke JR, Jr, Angelocci D, Fox K, McHugh D, Bynum L, Yee JP: Comparison of the efficacy and safety of ketorolac and meperidine in the relief of dental pain. *J Clin Pharmacol* 32: 376-384, 1992.
- Fridrich KL, Holton TJ, Pansegrau KJ, Buckley MJ: Neurosensory recovery following the mandibular bilateral sagittal split osteotomy. *J Oral Maxillofac Surg* 53: 1300-1306; discussion 1306-1307, 1995.
- Fujioka M, Hirano A, Fujii T: Comparative study of inferior alveolar disturbance restoration after sagittal split osteotomy by means of bicortical versus monocortical osteosynthesis. *Plast Reconstr Surg* 102: 37-41, 1998.
- Fustran Guerrero N, Dalmau Llitjos A, Ferreres Albert E, Camprubi Sociats I, Sanzol Berruezo R, Redondo Diaz S, Kreisler E, Biondo S, Sabate Pes A: Postoperative analgesia with continuous wound infusion of local aneesthesia vs saline: a double-blind randomised, controlled trial in colorectal surgery. *Colorectal Dis*, 2015. doi: 10.1111/codi.12893
- Gartner L, Hiatt J. (2001). *Color textbook of histology*. Pennsylvania: Saunders WB.
- Gersema L, Baker K: Use of corticosteroids in oral surgery. *J Oral Maxillofac Surg* 50: 270-277, 1992.
- Goldenberg NA, Jacobson L, Manco-Johnson MJ: Brief communication: duration of platelet dysfunction after a 7-day course of Ibuprofen. *Ann Intern Med* 142: 506-509, 2005.
- Gonzalez-Ulloa M: Ptosis of the chin. The witches’ chin. *Plast Reconstr Surg* 50: 54-57, 1972.
- Gordon KF, Reed JM, Anand VK: Results of intraoral cortical bone screw fixation technique for mandibular fractures. *Otolaryngol Head Neck Surg* 113: 248-252, 1995. doi: S0194-5998(95)70113-3 [pii]
- Guignard B, Bossard AE, Coste C, Sessler DI, Lebrault C, Alfonsi P, Fletcher D, Chauvin M: Acute opioid tolerance: intraoperative remifentanil increases postoperative pain and morphine requirement. *Anesthesiology* 93: 409-417, 2000.
- Hall S. (2005). *“Mechanisms of Repair after Traumatic injury”*. Philadelphia: Elsevier Saunders.

- Halvorson EG, Mulliken JB: Cheever's double operation: the first Le Fort I osteotomy. *Plast Reconstr Surg* 121: 1375-1381, 2008. doi: 10.1097/01.prs.0000304442.15532.40
- Haraji A, Motamedi MH, Moharamnejad N: Causes and incidence of miniplate removal following Le Fort I osteotomy. *Eplasty* 9: e45, 2009.
- Harrell FJ. (2001). *General aspects of fitting regression models; regression modeling strategies*. New York: Springer Science + Business Media Inc.
- Haug RH: Retention of asymptomatic bone plates used for orthognathic surgery and facial fractures. *J Oral Maxillofac Surg* 54: 611-617, 1996.
- Heinz F. (1984). *Anatomisk bildordbok "Anatomisches Bildwörterbuch der internationalen Internationalen Nomenklatur"* (Second edition ed.). Falköping: Almqvist & Wiksell Förlag AB.
- Hoenig JF: Sliding osteotomy genioplasty for facial aesthetic balance: 10 years of experience. *Aesthetic Plast Surg* 31: 384-391, 2007. doi: 10.1007/s00266-006-0177-6
- Hofer O: Operation del prognathie und microgenie. *Deutch Zahn-Mund-Kleferhlpk* 9, 1942.
- Hogeman KE, Wilmar K: [Surgical mobilization of the maxilla for correction of malocclusion]. *Fortschr Kiefer Gesichtschir* 12: 275-278, 1967.
- Holmes S, Hutchison I: Caution in use of bicortical intermaxillary fixation screws. *Br J Oral Maxillofac Surg* 38: 574, 2000. doi: 10.1054/bjom.2000.0514S0266-4356(00)90514-X [pii]
- Holte K, Kehlet H: Perioperative single-dose glucocorticoid administration: pathophysiologic effects and clinical implications. *J Am Coll Surg* 195: 694-712, 2002.
- Hullihen S: Case of elongation of the underjaw and distorsion of the face and neck, caused by burn, successfully treated. *Am J Dent Sci* 9: 157-161, 1849.
- Hunsuck EE: A modified intraoral sagittal splitting technic for correction of mandibular prognathism. *J Oral Surg* 26: 250-253, 1968.
- Huskisson EC: Measurement of pain. *Lancet* 2: 1127-1131, 1974.
- Hwang K, Lee WJ, Song YB, Chung IH: Vulnerability of the inferior alveolar nerve and mental nerve during genioplasty: an anatomic study. *J Craniofac Surg* 16: 10-14; discussion 14, 2005.

- Hyllested M, Jones S, Pedersen JL, Kehlet H: Comparative effect of paracetamol, NSAIDs or their combination in postoperative pain management: a qualitative review. *Br J Anaesth* 88: 199-214, 2002.
- Im J, Kang SH, Lee JY, Kim MK, Kim JH: Surgery-first approach using a three-dimensional virtual setup and surgical simulation for skeletal Class III correction. *Korean J Orthod* 44: 330-341, 2014. doi: 10.4041/kjod.2014.44.6.330
- Ingole PD, Garg A, Sheno SR, Badjate SJ, Budhraja N: Comparison of intermaxillary fixation screw versus eyelet interdental wiring for intermaxillary fixation in minimally displaced mandibular fracture: a randomized clinical study. *J Oral Maxillofac Surg* 72: 958.e951-957, 2014. doi: 10.1016/j.joms.2014.01.005
- Jaaskelainen SK, Teerijoki-Oksa T, Forssell K, Vahatalo K, Peltola JK, Forssell H: Intraoperative monitoring of the inferior alveolar nerve during mandibular sagittal-split osteotomy. *Muscle Nerve* 23: 368-375, 2000.
- Jaaskelainen SK, Teerijoki-Oksa T, Virtanen A, Tenovu O, Forssell H: Sensory regeneration following intraoperatively verified trigeminal nerve injury. *Neurology* 62: 1951-1957, 2004.
- Johnson J, Carlsson S, Johansson M, Pauli N, Ryden A, Fagerberg-Mohlin B, Finizia C: Development and validation of the Gothenburg Trismus Questionnaire (GTQ). *Oral Oncol* 48: 730-736, 2012. doi: 10.1016/j.oraloncology.2012.02.013
- Jones DC: The intermaxillary screw: a dedicated bicortical bone screw for temporary intermaxillary fixation. *Br J Oral Maxillofac Surg* 37: 115-116, 1999. doi: S0266-4356(98)90086-9 [pii]10.1054/bjom.1998.0086
- Jones DL, Wolford LM, Hartog JM: Comparison of methods to assess neurosensory alterations following orthognathic surgery. *Int J Adult Orthodon Orthognath Surg* 5: 35-42, 1990.
- Joshi GP, Schug SA, Kehlet H: Procedure-specific pain management and outcome strategies. *Best Pract Res Clin Anaesthesiol* 28: 191-201, 2014. doi: 10.1016/j.bpa.2014.03.005
- Kahnberg K: Transverse expansion of the maxilla using a multisegmentation technique. *Scand J Plast Reconstr Surg Hand Surg* 41: 103-108, 2007. doi: 778246747 [pii]10.1080/02844310601159923
- Karlis V, Glickman R: An alternative to arch-bar maxillomandibular fixation. *Plast Reconstr Surg* 99: 1758-1759, 1997.

- Kehlet H: Multimodal approach to control postoperative pathophysiology and rehabilitation. *Br J Anaesth* 78: 606-617, 1997.
- Kehlet H, Jensen TS, Woolf CJ: Persistent postsurgical pain: risk factors and prevention. *Lancet* 367: 1618-1625, 2006. doi: 10.1016/s0140-6736(06)68700-x
- Kim SG, Lee JG, Lee YC, Cho BO: Unusual complication after genioplasty. *Plast Reconstr Surg* 109: 2612-2613, 2002.
- Kimmey MB: Cardioprotective effects and gastrointestinal risks of aspirin: maintaining the delicate balance. *Am J Med* 117 Suppl 5A: 72s-78s, 2004.
- Komatsu R, Turan AM, Orhan-Sungur M, McGuire J, Radke OC, Apfel CC: Remifentanyl for general anaesthesia: a systematic review. *Anaesthesia* 62: 1266-1280, 2007. doi: 10.1111/j.1365-2044.2007.05221.x
- Kovac AL: The prophylactic treatment of postoperative nausea and vomiting in oral and maxillofacial surgery. *J Oral Maxillofac Surg* 63: 1531-1535, 2005. doi: 10.1016/j.joms.2005.06.004
- Krekmanov L. (1989). *Orthognathic surgery without the use of postoperative intermaxillary fixation*. (PhD Clinical and cephalometric), University of Gothenburg.
- Kuhlefelt M, Laine P, Suominen AL, Lindqvist C, Thoren H: Nerve manipulation during bilateral sagittal split osteotomy increases neurosensory disturbance and decreases patient satisfaction. *J Oral Maxillofac Surg* 72: 2052.e2051-2055, 2014. doi: 10.1016/j.joms.2014.06.444
- Kuhlefelt M, Laine P, Suominen-Taipale L, Ingman T, Lindqvist C, Thoren H: Risk factors contributing to symptomatic miniplate removal: a retrospective study of 153 bilateral sagittal split osteotomy patients. *Int J Oral Maxillofac Surg* 39: 430-435, 2010. doi: 10.1016/j.ijom.2010.01.016
- Langford RJ, Frame JW: Tissue changes adjacent to titanium plates in patients. *J Craniomaxillofac Surg* 30: 103-107, 2002b. doi: 10.1054/jcms.2002.0286
- Lanigan D, Hey J, West R: Aseptic necrosis following maxillary osteotomies: report of 36 cases. *J Oral Maxillofac Surg* 48: 142-156, 1990. doi: S0278239190000581 [pii]
- Le Fort R: Fractures de la machoire supérieure. *Cong intenant De mèd C-r, Sect. de chir Gèr*: 275-278, 1900.
- Le Fort R: Etude experimentale sur les fractures de la machoire superieure. *Rec Chir* 23: 479-507, 1901.

- Lee WK, Kim MS, Kang SW, Kim S, Lee JR: Type of anaesthesia and patient quality of recovery: a randomized trial comparing propofol-remifentanyl total i.v. anaesthesia with desflurane anaesthesia. *Br J Anaesth*, 2014. doi: 10.1093/bja/aeu405
- Leira JI, Gilhuus-Moe OT: Sensory impairment following sagittal split osteotomy for correction of mandibular retrognathism. *Int J Adult Orthodon Orthognath Surg* 6: 161-167, 1991.
- Limberg A: Treatment of open bite by means of plastic oblique osteotomy of the ascending rami of the mandible. *Dent. Cosmos* 67: 1191-1197, 1925.
- Loeb R: Surgical elimination of the retracted submental fold during double chin correction. *Aesthetic Plast Surg* 2: 31-40, 1978. doi: 10.1007/bf01577937
- Mattila K, Toivonen J, Janhunen L, Rosenberg PH, Hynynen M: Postdischarge symptoms after ambulatory surgery: first-week incidence, intensity, and risk factors. *Anesth Analg* 101: 1643-1650, 2005. doi: 10.1213/01.ane.0000184189.79572.28
- McManners R. (2000). *Mandibular body osteotomy*. Philadelphia: WB Saunders Co.
- Michelet FX, Benoit JP, Festal F, Despujols P, Bruchet P, Arvor A: [Fixation without blocking of sagittal osteotomies of the rami by means of endo-buccal screwed plates in the treatment of antero-posterior abnormalities]. *Rev Stomatol Chir Maxillofac* 72: 531-537, 1971.
- Michelet FX, Deymes J, Dessus B: Osteosynthesis with miniaturized screwed plates in maxillo-facial surgery. *J Maxillofac Surg* 1: 79-84, 1973.
- Moose SM: SURGICAL CORRECTION OF MANDIBULAR PROGNATHISM BY INTRA-ORAL SUBCONDYLAR OSTEOTOMY. *J Oral Surg Anesth Hosp Dent Serv* 22: 197-202, 1964.
- MRF-rapport. (2000). *Riktlinjer för etisk värdering av medicinsk humanforskning. Forskningsetisk policy och organisation i Sverige. (In Swedish)*. Stockholm.
- Munro IR, Boyd JB, Wainwright DJ: Effect of steroids in maxillofacial surgery. *Ann Plast Surg* 17: 440-444, 1986.
- Nakagawa K, Ueki K, Takatsuka S, Takazakura D, Yamamoto E: Somatosensory-evoked potential to evaluate the trigeminal nerve after sagittal split osteotomy. *Oral Surg Oral Med Oral Pathol Oral Radiol Endod* 91: 146-152, 2001. doi: 10.1067/moe.2001.112331
- Nesari S, Kahnberg KE, Rasmusson L: Neurosensory function of the inferior alveo-

- lar nerve after bilateral sagittal ramus osteotomy: a retrospective study of 68 patients. *Int J Oral Maxillofac Surg* 34: 495-498, 2005. doi: 10.1016/j.ijom.2004.10.021
- Nooh N, Abdelhalim AA, Abdullah WA, Sheta SA: Effect of remifentanyl on the hemodynamic responses and recovery profile of patients undergoing single jaw orthognathic surgery. *Int J Oral Maxillofac Surg* 42: 988-993, 2013. doi: 10.1016/j.ijom.2013.02.001
- Oates JD, Snowdon SL, Jayson DW: Failure of pain relief after surgery. Attitudes of ward staff and patients to postoperative analgesia. *Anaesthesia* 49: 755-758, 1994.
- Obwegeser H: [The one time forward movement of the maxilla and backward movement of the mandible for the correction of extreme prognathism]. *SSO Schweiz Monatsschr Zahnheilkd* 80: 547-556, 1970.
- Olate S, Pozzer L, Unibazo A, Huentequero-Molina C, Martinez F, de Moraes M: LeFort I segmented osteotomy experience with piezosurgery in orthognathic surgery. *Int J Clin Exp Med* 7: 2092-2095, 2014.
- Panula K, Finne K, Oikarinen K: Incidence of complications and problems related to orthognathic surgery: a review of 655 patients. *J Oral Maxillofac Surg* 59: 1128-1136; discussion 1137, 2001.
- Papadopoulos MA, Tarawneh F: The use of miniscrew implants for temporary skeletal anchorage in orthodontics: a comprehensive review. *Oral Surg Oral Med Oral Pathol Oral Radiol Endod* 103: e6-15, 2007. doi: 10.1016/j.tripleo.2006.11.022
- Pourdanesh F, Khayampour A, Jamilian A: Therapeutic effects of local application of dexamethasone during bilateral sagittal split ramus osteotomy surgery. *J Oral Maxillofac Surg* 72: 1391-1394, 2014. doi: 10.1016/j.joms.2013.12.025
- Pratt CA, Tippet H, Barnard JD, Birnie DJ: Labial sensory function following sagittal split osteotomy. *Br J Oral Maxillofac Surg* 34: 75-81, 1996.
- Purmal K, Alam MK, Pohchi A, Abdul Razak NH: 3D mapping of safe and danger zones in the maxilla and mandible for the placement of intermaxillary fixation screws. *PLoS One* 8: e84202, 2013. doi: 10.1371/journal.pone.0084202
- Rajchel J, Ellis E, 3rd, Fonseca RJ: The anatomical location of the mandibular canal: its relationship to the sagittal ramus osteotomy. *Int J Adult Orthodon Orthognath Surg* 1: 37-47, 1986.

- Reyneke JP. (2010). *Essentials of orthognathic surgery* (B. G. a. L. Huffman Ed.). Canada: Quintessence Publishing Co, Inc.
- Rhen T, Cidlowski JA: Antiinflammatory action of glucocorticoids--new mechanisms for old drugs. *N Engl J Med* 353: 1711-1723, 2005. doi: 10.1056/NEJMr-a050541
- Rieck KL. (2013). *Taking on the chin - The art of genioplasty* (Vol. 21).
- Riley RW, Powell NB, Guilleminault C: Obstructive sleep apnea syndrome: a surgical protocol for dynamic upper airway reconstruction. *J Oral Maxillofac Surg* 51: 742-747; discussion 748-749, 1993.
- Robinson LR: traumatic injury to peripheral nerves. *Suppl Clin Neurophysiol* 57: 173-186, 2004.
- Roccia F, Rossi P, Gallesio C, Boffano P: Self-tapping and self-drilling screws for intermaxillary fixation in management of mandibular fractures. *J Craniofac Surg* 20: 68-70, 2009. doi: 10.1097/SCS.0b013e318190df2f00001665-200901000-00018 [pii]
- Roccia F, Tavolaccini A, Dell'Acqua A, Fasolis M: An audit of mandibular fractures treated by intermaxillary fixation using intraoral cortical bone screws. *J Craniomaxillofac Surg* 33: 251-254, 2005. doi: S1010-5182(05)00063-6 [pii]10.1016/j.jcms.2005.02.005
- Sailer HF, Haers PE, Gratz KW: The Le Fort I osteotomy as a surgical approach for removal of tumours of the midface. *J Craniomaxillofac Surg* 27: 1-6, 1999.
- Salerno A, Hermann R: Efficacy and safety of steroid use for postoperative pain relief. Update and review of the medical literature. *J Bone Joint Surg Am* 88: 1361-1372, 2006. doi: 10.2106/jbjs.d.03018
- Schaberg SJ, Stuller CB, Edwards SM: Effect of methylprednisolone on swelling after orthognathic surgery. *J Oral Maxillofac Surg* 42: 356-361, 1984.
- Schimmer B, Funder J. (2011). *ACTH, adrenal steroids and pharmacology of the adrenal cortex* (Vol. 12th edition). New York: NY: McGraw-Hill Companies Inc.
- Schuchardt K: Ein Beitrag zur chirurgischen Kieferorthopädie unter Berücksichtigung ihrer für die Behandlung angeborener und erworbener Kieferdeformitäten bei Soldaten. *Dtsch Zahn Mund Kieferheilk.* 9: 73-89, 1942.
- Seddon HJ: A Classification of Nerve Injuries. *Br Med J* 2: 237-239, 1942.
- Seo K, Tanaka Y, Terumitsu M, Someya G: Efficacy of steroid treatment for sensory

- impairment after orthognathic surgery. *J Oral Maxillofac Surg* 62: 1193-1197, 2004.
- Shang AB, Gan TJ: Optimising postoperative pain management in the ambulatory patient. *Drugs* 63: 855-867, 2003.
- Shephard BC, Townsend GC, Goss AN: The oral effects of prolonged intermaxillary fixation by interdental eyelet wiring. *Int J Oral Surg* 11: 292-298, 1982.
- Silva AC, O’Ryan F, Poor DB: Postoperative nausea and vomiting (PONV) after orthognathic surgery: a retrospective study and literature review. *J Oral Maxillofac Surg* 64: 1385-1397, 2006. doi: 10.1016/j.joms.2006.05.024
- Silva I, Suska F, Cardemil C, Rasmusson L: Stability after maxillary segmentation for correction of anterior open bite: a cohort study of 33 cases. *J Craniomaxillofac Surg* 41: e154-158, 2013. doi: 10.1016/j.jcms.2012.12.003
- Sisk AL, Bonnington GJ: Evaluation of methylprednisolone and flurbiprofen for inhibition of the postoperative inflammatory response. *Oral Surg Oral Med Oral Pathol* 60: 137-145, 1985.
- Son S, Motoyoshi M, Uchida Y, Shimizu N: Comparative study of the primary stability of self-drilling and self-tapping orthodontic miniscrews. *Am J Orthod Dentofacial Orthop* 145: 480-485, 2014. doi: 10.1016/j.ajodo.2013.12.020
- Spiessl B. (1976). *New concepts in maxillofacial bone surgery*. (S.-V. B. a. H. G. C. K Ed. 1976 ed.).
- Spiessl B: [Perspectives of maxillary surgery in Switzerland]. *Helv Chir Acta* 55: 953-958, 1989.
- Stoelinga PJ, Borstlap WA: The fixation of sagittal split osteotomies with miniplates: the versatility of a technique. *J Oral Maxillofac Surg* 61: 1471-1476, 2003.
- Stoker NG, Epker BN: The posterior maxillary osteotomy: a retrospective study of treatment results. *Int J Oral Surg* 3: 153-157, 1974.
- Sunderland S: A classification of peripheral nerve injuries producing loss of function. *Brain* 74: 491-516, 1951.
- Takeuchi T, Furusawa K, Hirose I: Mechanism of transient mental nerve paraesthesia in sagittal split mandibular ramus osteotomy. *Br J Oral Maxillofac Surg* 32: 105-108, 1994.
- Theodossy T, Jackson O, Petrie A, Lloyd T: Risk factors contributing to symptomatic plate removal following sagittal split osteotomy. *Int J Oral Maxillofac Surg*

35: 598-601, 2006. doi: 10.1016/j.ijom.2006.02.001

- Thor A, Andersson L: Interdental wiring in jaw fractures: effects on teeth and surrounding tissues after a one-year follow-up. *Br J Oral Maxillofac Surg* 39: 398-401, 2001. doi: 10.1054/bjom.2001.0670
- Trapp RG, Dawson-Saunders B. (1994). *Basic & Clinical Biostatistics* (J. Dolan Ed. Second edition ed.). Connecticut: Appleton & Lange.
- Trauner R, Obwegeser H: The surgical correction of mandibular prognathism and retrognathia with consideration of genioplasty. II. Operating methods for microgenia and distocclusion. *Oral Surg Oral Med Oral Pathol* 10: 899-909, 1957.
- Troullos ES, Hargreaves KM, Butler DP, Dionne RA: Comparison of nonsteroidal anti-inflammatory drugs, ibuprofen and flurbiprofen, with methylprednisolone and placebo for acute pain, swelling, and trismus. *J Oral Maxillofac Surg* 48: 945-952, 1990.
- Tung TC, Chen YR, Bendor-Samuel R: Surgical complications of the Le Fort I osteotomy--a retrospective review of 146 cases. *Changgeng Yi Xue Za Zhi* 18: 102-107, 1995.
- Twersky RS, Jamerson B, Warner DS, Fleisher LA, Hogue S: Hemodynamics and emergence profile of remifentanyl versus fentanyl prospectively compared in a large population of surgical patients. *J Clin Anesth* 13: 407-416, 2001.
- Ueki K, Marukawa K, Shimada M, Nakagawa K, Yamamoto E: The use of an intermaxillary fixation screw for mandibular setback surgery. *J Oral Maxillofac Surg* 65: 1562-1568, 2007. doi: S0278-2391(06)02063-5 [pii]10.1016/j.joms.2006.10.071
- van der Vlis M, Dentino KM, Vervloet B, Padwa BL: Postoperative swelling after orthognathic surgery: a prospective volumetric analysis. *J Oral Maxillofac Surg* 72: 2241-2247, 2014. doi: 10.1016/j.joms.2014.04.026
- Van Dyke T, Litkowski LJ, Kiersch TA, Zarringhalam NM, Zheng H, Newman K: Combination oxycodone 5 mg/ibuprofen 400 mg for the treatment of postoperative pain: a double-blind, placebo- and active-controlled parallel-group study. *Clin Ther* 26: 2003-2014, 2004. doi: 10.1016/j.clinthera.2004.12.002
- Van Lancker P, Abeloos JV, De Clercq CA, Mommaerts MY: The effect of mandibular nerve block on opioid consumption, nausea and vomiting in bilateral mandibular osteotomies. *Acta Anaesthesiol Belg* 54: 223-226, 2003.

- Vartanian AJ, Alvi A: Bone-screw mandible fixation: an intraoperative alternative to arch bars. *Otolaryngol Head Neck Surg* 123: 718-721, 2000. doi: S0194-5998(00)76964-6 [pii]10.1067/mhn.2000.111286
- Viader A, Chang LW, Fahrner T, Nagarajan R, Milbrandt J: MicroRNAs modulate Schwann cell response to nerve injury by reinforcing transcriptional silencing of dedifferentiation-related genes. *J Neurosci* 31: 17358-17369, 2011. doi: 10.1523/jneurosci.3931-11.2011
- Warfield CA, Kahn CH: Acute pain management. Programs in U.S. hospitals and experiences and attitudes among U.S. adults. *Anesthesiology* 83: 1090-1094, 1995.
- Wassmund M: *Frakturen und Luxationen des Gesichtsschgdels*, Meusser, Leipzig, Germany, 1927.
- Weber CR, Griffin JM: Evaluation of dexamethasone for reducing postoperative edema and inflammatory response after orthognathic surgery. *J Oral Maxillofac Surg* 52: 35-39, 1994. doi: 0278-2391(94)90010-8 [pii]
- Westermarck A. (1999). *On inferior Alveolar Nerve Function After Sagittal Split Osteotomy of the Mandible*. (Clinical), University of Stockholm, Stockholm.
- Westermarck A, Bystedt H, von Konow L: Inferior alveolar nerve function after mandibular osteotomies. *Br J Oral Maxillofac Surg* 36: 425-428, 1998a.
- Westermarck A, Bystedt H, von Konow L: Inferior alveolar nerve function after sagittal split osteotomy of the mandible: correlation with degree of intraoperative nerve encounter and other variables in 496 operations. *Br J Oral Maxillofac Surg* 36: 429-433, 1998c.
- Wilhelm W, Grundmann U, Van Aken H, Haus EM, Larsen R: A multicenter comparison of isoflurane and propofol as adjuncts to remifentanil-based anesthesia. *J Clin Anesth* 12: 129-135, 2000.
- Wolford LM, Bennett MA, Rafferty CG: Modification of the mandibular ramus sagittal split osteotomy. *Oral Surg Oral Med Oral Pathol* 64: 146-155, 1987.
- Wolford LM, Davis WM: The mandibular inferior border split: a modification in the sagittal split osteotomy. *J Oral Maxillofac Surg* 48: 92-94, 1990. doi: 0278-2391(90)90190-D [pii]
- Yamauchi K, Takahashi T, Kaneuji T, Nogami S, Yamamoto N, Miyamoto I, Yamashita Y: Risk factors for neurosensory disturbance after bilateral sagittal split osteotomy based on position of mandibular canal and morphology of man-

dibular angle. *J Oral Maxillofac Surg* 70: 401-406, 2012. doi: 10.1016/j.joms.2011.01.040

Ylikontiola L, Kinnunen J, Laukkanen P, Oikarinen K: Prediction of recovery from neurosensory deficit after bilateral sagittal split osteotomy. *Oral Surg Oral Med Oral Pathol Oral Radiol Endod* 90: 275-281, 2000. doi: 10.1067/moe.2000.108920

Ylikontiola L, Kinnunen J, Oikarinen K: Factors affecting neurosensory disturbance after mandibular bilateral sagittal split osteotomy. *J Oral Maxillofac Surg* 58: 1234-1239; discussion 1239-1240, 2000. doi: 10.1053/joms.2000.16621