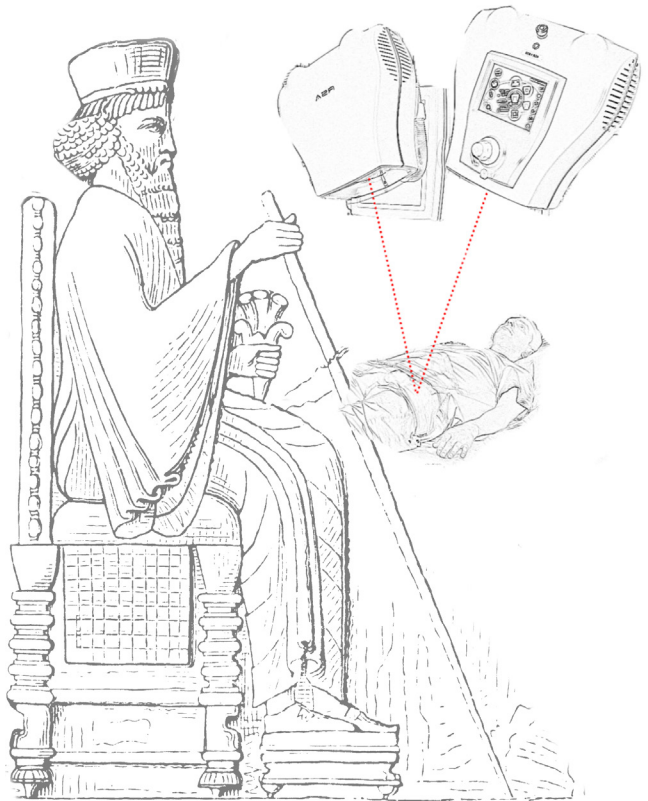


Acetabular Revisions

Risk Factors &
Prediction of Re-revision



Maziar Mohaddes

Institute of Clinical Sciences
at Sahlgrenska Academy
University of Gothenburg

Acetabular Revisions

Risk Factors & Prediction of Re-revision

Maziar Mohaddes

Departments of Orthopaedics, Institute of Clinical Science
at Sahlgrenska Academy, University of Gothenburg



UNIVERSITY OF GOTHENBURG

Gothenburg, Sweden 2015

Cover illustrations: by Maziar Mohaddes, courtesy of Educational Technology Clearinghouse, Florida Center for Instructional Technology, College of Education, University of South Florida

Acetabular Revisions

© Maziar Mohaddes 2015

The published articles are reproduced with permission from the respective journals.

maziar.mohaddes@gmail.com, maziar.mohaddes_ardebili@vgregion.se

Department of Orthopaedics

Institute of Clinical Sciences

Sahlgrenska Academy

University of Gothenburg

SE-413 45 Gothenburg

Sweden

Printed in Gothenburg by Ineko AB

ISBN 978-91-628-9529-7

“The practice of medicine is not the work which the physician carries out, but is that branch of medical knowledge which, when acquired, enables one to form an opinion upon which to base the proper plan of treatment.”

Avicenna
980 – 1037

Avicenna was a Persian polymath and jurist. He became known as the “Prince of Physicians” in the western world. One of his most famous books, Liber Canonis Medicine (The Canon of Medicine) was a standard medical encyclopaedia at many universities and remained in use as late as 1650



Courtesy of Historical Collections & Services,
Claude Moore Health Sciences Library,
University of Virginia

Contents

ABSTRACT	ii
SAMMANFATTNING PÅ SVENSKA	iv
SUMMARY IN PERSIAN	vi
LIST OF PAPERS	viii
ABBREVIATIONS	x
BRIEF DEFINITIONS	xi
1 INTRODUCTION	1
1.1 Total hip arthroplasty	2
1.2 Revision hip arthroplasty	3
1.2.1 Acetabular revision surgery	3
1.2.2 Bone defect classifications.....	4
1.2.3 The inter-observer and intra-observer validity of acetabular bone defect classifications	5
1.2.4 Treatment of bone defects.....	6
1.2.5 Trabecular metal cups	6
1.3 The Swedish Hip Arthroplasty Register	7
1.4 Radiostereometry	8
1.4.1 RSA investigation	8
1.4.2 The accuracy and precision of RSA measurements.....	10
1.4.3 RSA in evaluating new surgical techniques and implant designs	11
2 AIMS	13
3 PATIENTS AND METHODS	15
3.1 Paper I.....	15
3.2 Paper II.....	16
3.3 Paper III	16
3.4 Paper IV	17
3.5 Paper V.....	18

4	STATISTICAL METHODS	21
4.1	Descriptive statistics	21
4.2	Statistical interference.....	21
4.3	Regression models	21
4.4	Software	21
5	RESULTS	23
5.1	Paper I.....	23
5.2	Paper II.....	23
5.3	Paper III	25
5.4	Paper IV	27
5.5	Paper V.....	27
6	LIMITATIONS	29
6.1	Observational studies using data from the Swedish Hip Arthroplasty Register	29
6.2	Clinical studies.....	30
7	DISCUSSION	31
7.1	Acetabular revisions and the Swedish Hip Arthroplasty Register	32
7.2	Liner revisions and the Swedish Hip Arthroplasty Register.....	34
7.3	RSA in predicting risk of loosening.....	35
7.4	RSA and method of fixation in acetabular revision	36
7.5	Patient- reported outcomes and psychosocial determinants in revision surgery.....	37
8	CONCLUSIONS	39
9	FUTURE PERSPECTIVE	41
	ACKNOWLEDGMENTS	43
	REFERENCES	45



UNIVERSITY OF GOTHENBURG

Acetabular Revisions

Risk Factors & Prediction of Re-revision

Maziar Mohaddes

Department of Orthopaedics, Institute of Clinical Sciences at
Sahlgrenska Academy, University of Gothenburg
Gothenburg, Sweden

ABSTRACT

Hip replacement is a successful intervention when treating patients with hip osteoarthritis. Approximately 10% of all patients undergoing primary hip replacement surgery require further surgical interventions (revisions) during their lifetime. Acetabular component (cup) failure is the most common reason for a revision. Cemented fixation in acetabular revision surgery was a common method until the mid-1980s. Low survival rates reported for cemented revision cups and encouraging results. There are, however, no studies comparing the results of revision surgery based on the method of fixation for the acetabular component. In 2006, a highly porous trabecular metal (TM) tantalum cup was introduced in the Swedish market and, in 2013, this cup was the most commonly used acetabular revision component in Sweden.

The primary aim of this thesis was to compare cemented and uncemented fixation in acetabular revisions using radiostereometric analysis (RSA). Further,

a comparative analysis of the TM cup and other cup designs frequently used in acetabular revisions was performed.

Data from the SHAR, on 18,593 first-time revisions, were used in the first study to analyse differences relating to the risk of re-revision between cemented and uncemented cups. The overall risk of acetabular component failure did not differ between the two modes of fixation. In this analysis, cemented revision cups were re-revised more often due to aseptic loosening but less often due to dislocation.

In Paper II, TM cups were compared with the other two cups most frequently used in first-time revisions recorded in the SHAR. The short-term re-revision rate of the TM design did not differ from that of the other two designs.

The third paper addressed the influence of proximal migration on the risk of aseptic loosening. An analysis of 312 acetabular

revisions followed with RSA for two to 20 years showed that proximal migration measured with RSA can be used a predictor of aseptic loosening of the acetabular component.

In the fourth paper, 45 patients (47 hips) undergoing surgery with cemented or uncemented fixation were followed prospectively for 17 years. Radiostereometry was used to monitor the migration and rotation of acetabular components. Cups installed using cemented fixation showed a higher rate of early migration.

In a randomised prospective study (Paper V), the RSA migration pattern of the TM cup was compared with that of a cemented cup in hips with large bone defects. The TM design showed less proximal migration compared with the cemented design, indicating a lower risk of aseptic loosening when the TM cup is used in hips with large bone defects.

To summarise, there was no difference in the overall risk of re-revision based on the method of fixation, according to data from the SHAR. Proximal migration measured with RSA is a predictor of late aseptic loosening in acetabular revisions. The TM cup shows promising short-term results in the SHAR. The low early proximal migration of the TM design suggests that it has the potential to reduce the risk of late aseptic loosening in revision surgery, but this remains to be demonstrated in clinical studies with longer follow-up.

Keywords: Acetabular revision, Radiostereometry, Trabecular metal, Register studies

ISBN: 978-91-628-9529-7

SAMMANFATTNING PÅ SVENSKA

I Sverige utförs årligen cirka 16000 primära höftprotesoperationer och cirka 1100 omoperationer med partiellt eller totalt protesbyte alternativt borttagande av proteskomponenter. Risken för att patienterna ska bli omopererade under sin livstid varierar beroende på när första operationen görs. Risken för omoperation ökar med sjunkande ålder vid primäroperation. Hos patienter yngre än 50 år är cirka 30 % omopererade efter 15 år, medan motsvarande andel endast är 5-10% för patienter äldre än 75 år. Risken för omoperationer ökar efter varje ny operation i höftleden.

En höftprotes består av två delar, en del som ersätter ledpannan och kallas för cup samt en del som ersätter höftledens lårbensdel och kallas för stam. Fixation av protesdelar både vid primäroperation och omoperation kan ske med eller utan bencement. I

Skandinavien och ett fåtal andra länder är användandet av den cementerade tekniken utbrett då det finns djupt rotade kunskaper och färdigheter vid användning av denna teknik. Den cementerade tekniken betraktas dock som mer krävande, och anses öka risken för lossning. I Sverige och i än större omfattning utanför Sverige har man därför i ökande omfattning börjat använda ocementerade implantat vid utbytesoperationer. Det finns internationella rapporter om lovande resultat vid användning av ocementerade teknik åtminstone efter medellånga uppföljningstider (mindre än 10 år). En relativ ny tillkommen protestyp gjord av eller täckt med porös tantalum har i studier visat bättre resultat än de traditionella ocementerade protesmodellerna. Förespråkarna för denna tantalumprotes hävdar att protesens egenskaper främjar beninväxt och minskar risken för omoperation. Det finns idag inga studier med tillräcklig lång uppföljningstid

som stödjer detta påstående.

Syftet med denna avhandling är att studera patienter som genomgår omoperation för att kunna avgöra vilken cupfixationsmetod som innebär bäst prognos för dessa patienter. I litteraturen rapporteras vanligen serier med cirka 100 opererade patienter vilket ofta inte är tillräckligt för att besvara våra frågeställningar. För att kunna få tillräckligt stort patientunderlag har vi i två av delarbeten valt att använda data från Svenska Höftprotesregistret (SHAR).

I första delarbete inkluderades samtliga patienter som var opererade med bytesoperation av leddskålen under åren 1979-2010. Denna analys visade inte några skillnader i den totala risken för omoperation baserad på fixationsmetod. I det andra delarbetet jämfördes tantalumcupar och två andra cupdesign som använts mest frekvent

under 2006-2012. Studien visade att TM cupen hade goda resultat de första åren efter operation men att vidare studier behövdes för att utröna huruvida dessa cupdesign på sikt kan förbättra resultat hos patienter som genomgår omoperation.

I de övriga tre delarbeten har en röntgenundersökningsmetod kallad radiostereometri (RSA) använts för att studera protesdesign och fixationsmetoder som används vid bytesoperationer. RSA är en metod som med stor noggrannhet kan mäta protesers rörelse (migration och rotation) i förhållande till benet. Dessa studier visad att tidig migration av cupen, uppmätt med RSA, ökade risken för senare lossning av cupen. Den nyintroducerade Tantalum designen uppvisade mindre rörelser jämfört med de cementerade cuparna vid bytesoperationer där stora bendefekter förelåg.

جراحی مجدد کاسه ران را در سال های ۱۹۷۹ تا ۲۰۱۰ انجام داده اند هیچگونه اختلافی در احتمال کلی جراحی مجدد بر اساس روش اتصال کاسه پروتز ملاحظه نشد.

در مقاله دوم کاسه های تانتالم در SHAR را مورد تحلیل قرار دادیم و نتیجه گرفتیم که این ایمپلنت دارای نتایج خوبی در سال های اول بعد از جراحی خواهد بود اما به منظور تعیین اینکه آیا این کاسه ها می توانند در نهایت نتایج جراحی بر روی بیماران را بهبود بخشند به بررسی بیشتری نیاز داریم.

برای سه دستخط دیگر نیز از روش اشعه ایکس با عنوان رادیواسترومتری (RSA) استفاده کردیم و طراحی های مختلف پروتز و روش های اتصال مورد استفاده در جراحی های مجدد کاسه ران را مورد بررسی قرار دادیم. RSA نوعی روش رادیوگرافیکی بادقت بالا است که امکان سنجش دقیق حرکات پروتز نسبت به استخوان را به وجود می آورد. بر اساس این مطالعات می توانیم نتیجه گیری کنیم که حرکت اولیه کاسه ران که با RSA اندازه گیری می شود منجر به شل شدن کاسه خواهد شد. همچنین نشان دادیم که در مواردی که در جراحی مجدد نقایص استخوانی بزرگی وجود داشته باشد، کاسه تانتالم جابجایی کمتری نشان می دهد.

خلاصه به زبان فارسی

سوی استفاده از ایمپلنت های غیرسیمانی در جراحی های اولیه و مجدد مفصل ران مشاهده می شود. گزارش هایی از سراسر جهان با نتایج امیدوار کننده در دسترس است که از روش غیرسیمانی حداقل در دوره های پیگیری نسبتاً بلند مدت (کمتر از ۱۰ سال) استفاده می شود.

ایمپلنتی نسبتاً جدید که دارای تانتالم است، نتایج بهتری در مقایسه با پروتزهای سنتی غیرسیمانی نشان داده است. طرفداران ایمپلنت ساخته شده از تانتالم این بحث را مطرح می نمایند که ویژگی های این پروتز رشد استخوان را بهبود بخشیده و بقای آن را تضمین می کند. اما هیچگونه مطالعه بلند مدت مؤید این ادعا انجام نشده است.

هدف این پایان نامه مطالعه بر روی بیمارانی است که متحمل جراحی مجدد شده اند تا مشخص شود کدام روش اتصال در جراحی مجدد ران باید مورد استفاده قرار گیرد. بسیاری از مقالات قبلی در این حوزه تقریباً بر روی تحقیقاتی متشکل از ۱۰۰ بیمار متمرکز شده اند که غالباً برای پاسخ به این پرسش کفایت نمی کند. به منظور برخورداری از نمونه کافی از بیماران، طی دو مقاله از داده های رجیستری آرتروپلاستی تعویض مفصل سوئد (SHAR) استفاده کردیم. بررسی تمامی بیمارانی که

سالیانه در سوئد تقریباً ۱۶۰۰۰ عمل اولیه تعویض مفصل ران و ۱۱۰۰ عمل مجدد یا تعویض پروتز انجام می گیرد. احتمال نیاز بیماران به عمل مجدد طی مدت زندگی بستگی به زمانی دارد که عمل اول انجام شده است. احتمال عمل مجدد با کاهش سن انجام عمل اولیه تقلیل می یابد. در بیماران دارای سن زیر ۵۰ سال احتمال عمل مجدد بعد از ۱۵ سال در حدود ۳۰ درصد خواهد بود در حالیکه این احتمال در بیماران سن بالای ۷۵ سال بین ۵ تا ۱۰ درصد خواهد بود. احتمال عمل مجدد بعد از هر جراحی جدید افزایش پیدا می کند.

پروتز ران از دو بخش تشکیل شده است؛ یک بخش که جایگزین کاسه مفصل ران شده و کاسه نامیده می شود و بخشی که جایگزین قسمت ران شده و ساقه نامیده می شود. ثبوت مولفه های پروتز به بدن با سیمان استخوانی (اتصال سیمانی) صورت گرفته یا پروتز با گوه به استخوان متصل می شود که امکان رشد استخوان در پروتز را فراهم می آورد.

در کشورهای اسکاندیناوی و بعضی از کشورهای دیگر، استفاده از روش سیمانی معمول است. دانش و مهارت فراوانی در استفاده از این فناوری مورد نیاز میباشد. در بسیاری از نقاط دیگر در خارج از سوئد، گرایشی به

LIST OF PAPERS

This thesis is based on the following studies, referred to by their Roman numerals.

- I. Maziar Mohaddes, Göran Garellick, and Johan Kärrholm. “Method of fixation does not influence the overall risk of rerevision in first-time cup revisions.” *Clinical Orthopaedics and Related Research*® 471, no. 12 (2013): 3922-3931.
- II. Maziar Mohaddes, Ola Rolfson, and Johan Kärrholm. “Short-term survival of the trabecular metal cup is similar to that of standard cups used in acetabular revision surgery: Analysis of 2,460 first-time cup revisions in the Swedish Hip Arthroplasty Register.” *Acta Orthopaedica* 86, no. 1 (2015): 26-31.
- III. Tina Klerken, Maziar Mohaddes, Szilard Nemes, and Johan Kärrholm. “High early migration of the revised acetabular component is a predictor of late cup loosening: 312 cup revisions followed with radiostereometric analysis for 2-20 years.” *Hip International* (2015).
- IV. Maziar Mohaddes, Peter Herberts, Henrik Malchau, Per-Erik Johanson, and Johan Kärrholm. “High Proximal Migration in Cemented Acetabular Revisions Operated with Bone Impaction Grafting; 47 Revision Cups Followed with RSA for 17 years”. Submitted
- V. Maziar Mohaddes, Bitra Shareghi, and Johan Kärrholm“. Bone Impaction Grafting with a Trabecular Metal Revision Cup Show Promising Early Results”. Submitted

ABBREVIATIONS

CI Confidence interval

GP Gustilo & Pasternak bone defect classification system

PMMA Polymethyl methacrylate

PROM Patient reported outcome measure

RR Relative risk

RSA Radiostereometric analysis

SD Standard deviation

SHAR Swedish Hip Arthroplasty Register

THA Total hip arthroplasty

TM Trabecular metal

BRIEF DEFINITIONS

Bone graft	Chips of bone, produced from allografts using a bone mill or a rongeur
Cox-regression	Statistical method used to analyse the time-dependent effects of different variables on a specified event
Inter-observer validity	Reliability in assessment of the same radiograph by two different observers
Intra-observer validity	Reliability in two consecutive assessments of the one radiograph by the same observer
Liner revision	Exchange of the liner in an uncemented cup
Proximal migration	Cranial migration of the acetabular component
Radiostereometry	or <i>radiostereometric analysis (RSA)</i> , or <i>Roentgen Stereophotogrammetric Analysis</i> , a low-dose radiographic investigation enabling measurement of implant motion with high resolution.
Re-operation	Any surgical intervention on the current hip following a total joint replacement
Re-revision	<i>Revision</i> of a previously revised joint
Revision	A <i>re-operation</i> involving the extraction or exchange of parts or the entire implant (e.g. cup and stem)
Survival	Estimated percentage of patients not requiring a new surgical intervention

1 INTRODUCTION

The number of patients with hip osteoarthritis requiring total hip arthroplasty (THA) has increased during the last three decades. This increase is projected to continue during the next two decades. According to several authors (Kurtz et al. 2007, Nemes et al. 2014), there will be an increasing need for THA during the next two decades. About 5-10% of all patients undergoing a THA will require a new surgical intervention (re-operation) during their lifetime (Garellick et al. 2013). Kurtz et al. (2007) have predicted that the number of re-operations after a total hip arthroplasty will increase two fold. In Sweden and Norway, the frequency of re-operations has been fairly constant during the last few years. The exchange of one or several parts of the implant (revision) is the most common reason for a re-operation. According to available data in the Swedish Hip Arthroplasty Register, the majority of revisions performed in the 1980s and 1990s were due to failure of the femoral component or both the acetabular and femoral components due to the loosening of the implant. During the last two decades, the proportion of acetabular revisions has increased and, in 2011, some 50% of all revisions were performed due to aseptic cup loosening. The early migration of the prosthesis measured with radiostereometric analysis (roentgen stereophotogrammetric analysis, radiostereometry, RSA) has been found to be a predictor of loosening in

primary THA (Pijls et al. 2012). Cup failure is often associated with minor or major bone erosion in the acetabulum, endangering the fixation of the new acetabular component.

In 1998, a new acetabular design, made from highly porous tantalum, was introduced (Mulier et al. 2006). According to laboratory and animal tests (Bobyne et al. 1999, 1999), these designs have superior biomechanical properties and are expected to improve early implant fixation and reduce the risk of late aseptic loosening. Several variations of implants, supplied with high-friction materials made of titanium with increased porosity, have subsequently been introduced both for primary cup fixation and for acetabular revisions.

The risk of failure is higher in revision surgery compared with primary THA. There are no published randomised trials comparing cemented and uncemented fixation in acetabular revision surgery. The role of RSA in predicting the aseptic loosening of the revision cup has not yet been studied. Clinical studies of the above-mentioned all-porous tantalum acetabular shells reveal a low re-revision rate due to loosening in the short to medium term (Kim et al. 2008, Lakstein et al. 2009, Siegmeth et al. 2009, Sporer & Paprosky 2006, Sternheim et al. 2012, Unger et al. 2005).

In this thesis, the importance of the method of fixation, the influence of early migration of the cup and the risk of re-revision with special emphasis on aseptic loosening have been studied. In addition, the migration pattern and risk of early re-revision of a trabecular metal cup were investigated. The results of these investigations are presented in the following five papers:

Two observational studies using data from the Swedish Hip Arthroplasty Register (SHAR) regarding acetabular revisions reported to this registry in 1979-2012 and three clinical studies in which early micro-motion of the revision acetabular component was measured with radiostereometry. In one of the papers, the influence of early migration on the risk of aseptic loosening was analysed. In a randomised clinical trial, with a 17-year follow-up (Paper IV), the method of fixation in acetabular revision surgery was studied. In Paper V, the early migration pattern of a TM cup was compared with that of a cemented cup used in revisions with bone impaction grafting.

1.1 Total hip arthroplasty

In 1891, the German professor, Thomas Gluck, was the first to produce a total hip prosthesis consisting of an ivory ball and socket fixed to the bone with nickel-plated screws (Gomez & Morcuende 2005). During the early 1900s, several other attempts were made to produce hip prostheses containing rubber, glass, stainless steel and

cobalt chrome. All these attempts were unsuccessful, due in part to inferior materials, design rationales and problems related to infection. Sir John Charnley is regarded as the father of modern hip arthroplasty. On 22 November 1962, he inserted the first modern hip prosthesis consisting of a metal stem with a 22-millimetre head and a high molecular weight polyethylene cup. The fixation of the implant was achieved by using polymethyl methacrylate (PMMA) bone cement. Bone cement consists of two primary components: a powder (pre-polymerised PMMA) and a liquid (methyl methacrylate monomer). To avoid premature polymerisation, hydroquinone is added to the liquid as an inhibitor. A starter, di-benzoyl peroxide, is added to the powder and an initiator, N, N-dimethyl-p- toluidine, is added to the liquid to boost polymerisation at room temperature. Finally, a radiopaque contrast agent (zirconium dioxide or barium sulphate) and chlorophyll or other colouring agents may be added. Most of the bone cements used in Scandinavia are supplemented with antibiotics. The polymerisation process starts when the two components are mixed. This transforms the PMMA from a liquid to the solid state during the release of heat. The penetration of the bone cement into trabecular bone causes an interlock, which stabilises the cement mantle to the bone. Inspired by the success of the low-friction arthroplasty by Charnley, many different cemented designs were introduced and the number of patients undergoing THA surgery increased steadily.

1.2 Revision hip arthroplasty

The increasing number of THAs performed during the 1970s led to an increasing number of failures. These failures were mainly due to dislocation (Beckenbaugh & Ilstrup 1978, Lindberg et al. 1982) and infection (Carlsson 1981). Some progress has been made in improving the design of implants and the surgical techniques used in THA since Charnley's invention in 1962. Despite these continuous improvements, about 10% of all patients undergoing a THA will still suffer from implant failure, necessitating a new surgical intervention with the exchange of the prosthesis (revision).

In the early 1960s, failures after THA were most commonly treated by the removal of the implant (Parrish & Jones 1964). The successful introduction of Charnley's low-friction arthroplasty in primary THA encouraged the use of this prosthesis in revision cases (Dupont & Charnley 1972, Eftekhar et al. 1973). According to these reports, the short-term results were promising, but nonetheless both Dupont and Charnley (1972) and Eftekhar et al. (1973) focused on technical difficulties associated with the revision of a THA. Today, revisions are frequently regarded as complex surgical interventions. In addition and partly due to the differences in each case undergoing surgery, revisions are more complex to evaluate from a clinical perspective compared with primary THR. Several

factors, such as an indication of revision being performed, the degree of bone defects and the vitality of the host bone, may vary in each case. In some instances, these factors are difficult to measure or classify properly. Indications may vary between operating units, the patient may have passed repeated revision and the overall categorisation of procedures will become complex. Finally, the influence of co-morbidity may be more significant than in THA when this type of surgery is performed.

1.2.1 Acetabular revision surgery

More than 50 years ago, Charnley (1963) reported on osteolytic lesions around cemented sockets made of Teflon. He stated that these lesions were caused partly by motion between the implant and the bone and partly by a chemical reaction induced by abraded particles. Willert and Semlitsch (1977) examined tissue samples taken from the capsule of patients undergoing THA. They found granulation tissue containing foreign particles, macrophages and giant cells. They concluded that this reaction might be loosening of the implants due to the deterioration of the bone around the implant. Loosening of the acetabular component is often preceded by bone resorption, leading to periprosthetic bone defects. These bone defects endanger the fixation of the new implants and need to be addressed during revision surgery. In order

adequately to address the bone defects in acetabular revision, careful pre-operative planning is required. The main aim of this planning is to assist the surgeon in choosing the correct implant and method of fixation by systematically estimating the extent of periprosthetic bone defects on the pre-operative radiographs. Several bone defect classifications have been described in order to facilitate this pre-operative planning.

1.2.2 Bone defect classifications

Gustilo-Pasternak

Gustilo and Pasternak (1988) presented a comprehensive classification system in 1988. The bone defects were divided into four different categories (Table 1). In 1990, to facilitate comparisons between different centres performing revision surgery, the Swedish Orthopaedic Association suggested that the classification formulated by Gustilo & Pasternak (GP) should be used at all Swedish centres performing revisions. As a result, the GP classification was the most

frequently used acetabular bone defect classification system in Sweden for a period of about 10 years. The bone defect classification was later revised by Raut et al. (1995). In Sweden, the GP classification system has gradually been replaced by other bone defect classification systems.

D'Antonio

The D'Antonio classification (D'Antonio 1992), also referred to as the AAOS classification, consists of five main types, i.e. segmental deficiencies, cavitory deficiencies, combined deficiencies, pelvic discontinuity and arthrodesis. Types I and II are further divided into five subtypes depending on the anatomic locations of the bone loss in the acetabulum; peripheral, superior, anterior, posterior or central.

Gross

The classification proposed by Gross et al. (1993) divides bone defects into three groups. Type one is a contained bone defect with intact acetabular walls and columns. Type two is described as bone defects resulting in damage of less than 50% of the

Table 1. The acetabular bone defect classification described by Gustilo & Pasternak in 1998

Type	Description
1	Lucent line around the cup, minimal acetabular bone loss or thinning
2	Severe acetabular enlargement. Marked thinning of acetabulum
3	Anterior, superior and/or central bone loss causing instability of the implant
4	Acetabular collapse with fracture or sever bone loss

acetabulum, while type three is characterised by major bone loss affecting more than 50% of the acetabulum.

Paprosky

According to the classification system suggested by Paprosky et al. (1994), acetabular bone defects are divided into three main types based on whether the acetabular hemisphere (rim) is intact, distorted or missing. Type 2 bone defects in which the rim is distorted are further divided into three subtypes based on the migration pattern of the cup. In Type III bone defects, the acetabular rim is missing. The severity of the rim defect and the amount of cup migration determine whether the bone defect is classified as 3A or 3B..

Saleh

The classification system described by Saleh et al. (2001) consists of five types (I-V). In Type I, the bone loss is not notable and Type V represents pelvic discontinuity. Cavitory enlargement of the acetabulum with contained loss of bone stock identifies Type II bone defects. Segmental loss of bone

stock less or more than 50% respectively characterises Type III and IV defects. Pelvic discontinuity represents Type V.

1.2.3 The inter-observer and intra-observer validity of acetabular bone defect classifications

The validity of the bone defect classification systems used in acetabular revision surgery has been evaluated by two different authors (Campbell et al. 2001, Gozzard et al. 2003). The inter- and intra-observer agreement were calculated using Cohen's kappa values (Cohen 1960, Svanholm et al. 1989). Analysing the Gross, Paprosky and D'Antonio classification systems. Campbell et al. (2001) report moderate (Svanholm et al. 1989) intra-observer validity when the classification is performed by the inventor of the classification system. However, if the classification was made by clinicians, there was only poor agreement in both the inter-observer and intra-observer evaluations (Table 2). Assessing the Paprosky and D'Antonio classification systems, Gozzard et al. (2003) report similar values for the

Table 2. Kappa-values for inter-observer and intra-observer validity in the three classification systems evaluated by Campbell et al. (2001).

Observers	Intra-observer validity			Inter-observer validity		
	D'Antonio	Paprosky	Gross	D'Antonio	Paprosky	Gross
Originators	0.57	0.75	0.59	–	–	–
Experts	0.37	0.46	0.47	0.16	0.27	0.28
Residents	0.37	0.37	0.47	0.37	0.31	0.44

intra- and inter-observer validity of these classifications. Both studies underline the limitations that exist in current classification systems. Campbell et al. suggest that the existing classification systems should be regarded as general guidelines distinguishing between a simple and a complex acetabular revision.

1.2.4 Treatment of bone defects

Several different methods are described in the literature when bone defects are treated in acetabular revision surgery. These methods can be divided into two main categories; bypassing the bone deficiency or restoring the bone stock with biological material. Treating the bone defects using biological materials is an attractive method. It facilitates the fixation of the new prosthesis, offers biomechanical advantages and, if needed, simplifies future revisions. Two main methods with biological materials have been used in acetabular revision surgery; structural allografts and bone impaction grafting.

Structural allografts

Structural allografts were initially used in THA. Harris (1969) suggested the insertion of a femoral-head allograft to compensate for acetabular deficiencies in patients with congenital hip disease. In this paper, with a mean follow-up of two years, there were promising results. However, subsequent reports from the same group were discouraging (Shinar & Harris 1997).

Bone impaction grafting

Bone impaction grafting was first described by Slooff et al. (1984). They suggested the use of cortico-cancellous grafts to address bone defects in both THA and revisions. A few years later, the same group (Schreurs et al. 1998) reported survival of 90%, with a mean follow-up of 11.8 years, using impacted morsellised cancellous bone grafts in 60 acetabular revisions.

1.2.5 Trabecular metal cups

In a study by Bobyn et al. (1999), a canine model was used to analyse a transcortical all-porous tantalum implant. They showed that 13% of the implant was filled by new bone two weeks post-operatively. The extent of filling increased gradually during the follow-up and was 80% by 52 weeks. Together with findings that tantalum has excellent biocompatibility, high frictional characteristics and low modulus of elasticity, this caused (Levine et al. 2006) to encourage surgeons to use the TM design in acetabular revisions. Several authors have reported excellent results using a TM cup in cases with large bone defects (Davies et al. 2011, Lakstein et al. 2009, Richards et al. 2008). During the last decade, several other cup designs with trabecular titanium, Tritanium (Stryker, Mahwah, NJ), Regenerex (Biomet, Warsaw, IN), Stiktite (Smith and Nephew, Memphis, TN) and Delta TT (Lima Corporate spa, Udine, Italy), have been introduced and are being used in hip arthroplasty.

1.3 The Swedish Hip Arthroplasty Register

The Swedish Hip Arthroplasty Register was established in 1979. Since the start, more than 370,000 primary operations and 48,193 re-operations have been recorded in this register (Garellick et al. 2013). The SHAR aims to record data for every primary operation and re-operation performed in Sweden. Demographic data, date of operation, type of prosthesis, reason for revision (if relevant) and type of revision procedure performed are examples of the data collected. Data on each patient are linked to a unique personal identification number. This number is given to each individual in Sweden at the time of birth and to all immigrants after entry into Sweden. Some of the questions raised in revision surgery require a large number of patients to be included. These studies are difficult to perform in a timely manner. Analysing data from a national joint register with high coverage and high completeness (Söderman et al. 2001) offers excellent opportunities to address the aforementioned questions.

The SHAR was initiated as a national research project in 1976. At that time, the main purpose was to identify and analyse re-operations performed in Sweden in 1976-1977. When analysing data from the SHAR, Lennart Ahnfelt (1986) concluded in his thesis that re-operations were far more common than expected. He also demonstrated that about one third of all re-operations necessitated further surgical interventions. In 1979, an agreement

was made by the Swedish Orthopaedic Association to start a national hip register. All re-operations were reported to this register, with complete details on the demographic and surgical data for every single re-operation.

In the SHAR, re-operation is defined as any surgical intervention performed after a THA or a previous revision. The exchange or removal of the implant or any of its parts is described as a revision. All data relating to re-operations in the SHAR have been linked to the identification number described earlier. Until 1991, primary total hip arthroplasties were reported to the SHAR as aggregated data per operating unit. In 1992, a decision was made to gather individual data on primary THA and, in 1999, the data were supplemented with article numbers from each manufacturer and they were recoded into unique numbers corresponding to the different parts of each prosthesis.

Ring (1974) reported on 1,000 hips undergoing THR. He stated that femoral loosening was the most common reason for revision. According to the available data in the Swedish Hip Arthroplasty Register (SHAR), the majority of revisions in Sweden during the 1980s and 1990s were performed due to failure of the femoral component or both the acetabular and femoral components (Figure 1). The proportion of revisions performed due to cup loosening has increased during the last two decades. In 2012, more than 75% of all revisions were performed due to acetabular loosening with or without concomitant stem loosening.

1.4 Radiostereometry

In 1972, Göran Selvik presented a method in which the three-dimensional position of a distinct point was determined using simultaneous exposure with two roentgen tubes (Selvik 1989). The method was called roentgen stereophotogrammetric analysis and was subsequently renamed radiostereometric analysis (RSA) by Selvik. The method has been continuously updated (Bragdon et al. 2002, Börlin et al. 2006, Börlin et al. 2002, Nyström et al. 1994, Selvik 1983) and is now widely used in orthopaedics (Valstar et al. 2005).

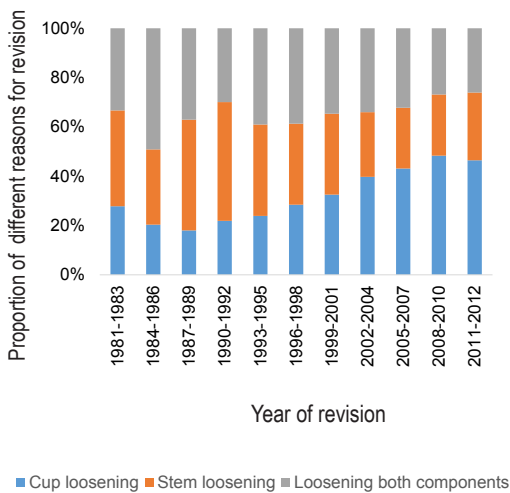


Figure 1. Reasons for revision, reported to the SHAR during years 1981-2012. According to data from the SHAR the proportion of cup loosening necessitating revision has been increasing during the last 2 decades.

The term “radiostereometry”, introduced as a synonym about 30 years ago, has been used more frequently in the literature in recent years. Radiostereometry (RSA) is an accurate, precise method used for the three-dimensional assessment of the movement between implant and host bone.

1.4.1 RSA investigation

RSA investigation comprises four steps; the insertion of the tantalum markers, radiographic examination, measurement on radiographs and computation of motions.

Insertion of tantalum markers

Eight to 10 hemispherical tantalum markers with a diameter of 0.8 and 1.0 mm respectively are inserted into the host bone and the implant. A hand-operated piston is used to insert the markers. In order to obtain optimal accuracy, the markers should be as scattered as possible within each segment (e.g. the acetabulum or the proximal femur). This method is defined as marker-based RSA and requires tantalum markers to be attached both to the bone and to the implant. However, attaching markers increases the cost of manufacturing implants, is technically demanding and may endanger the stability of inserted implants (Valstar et al. 2001). Furthermore, some implants could mask the inserted markers, making marker-based analysis difficult or impossible (Valstar et al. 2001). Several authors have reported the use of a model-based technique based on geometric configurations of parts or entire implants using three-dimensional

scanned or CAD models of the prosthesis (Kärrholm 1989, Snorrason & Kärrholm 1990, Valstar 1996, 2001, 1997, Önsten et al. 1995). The main advantage of using the model-based technique is to obviate the need for markers to be inserted into the implants and to enable the researcher to perform RSA measurements in cases where the implant makers are not present or are difficult to visualise.

Radiographic examination

The subject is placed inside or in front of a calibration cage consisting of Margard®, a polymer resistant to humidity, temperature changes and abrasions. The cages are equipped with tantalum markers (Figure 2). Initially, the markers closest to the roentgen film, so-called fiducial markers, were used to identify the laboratory co-ordinate system. A different set of markers called control points, placed in the wall closest to the roentgen tubes, were used to identify the position of the tubes. In later, updated versions of the software, all markers in the cage can be used for both purposes.

Measurement on radiographs

Images of the markers are numbered according to a standardised template. Until the mid-1990s, the measurements on the radiographs were made using a measuring table equipped with a camera. Different types of computer software were used to calculate the three-dimensional position of each marker and analyse the motion between subsequent examinations corresponding to the motions of a marker (point motion) or set of markers (segment motion). With

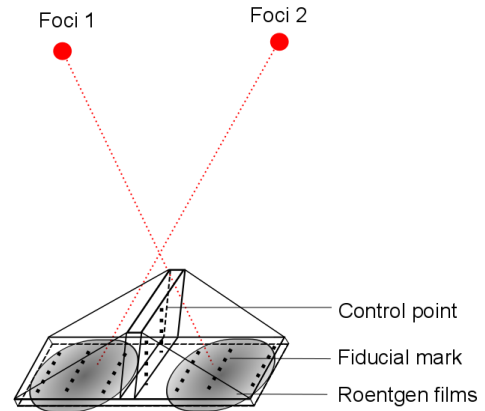


Figure 2. Schematic drawing of a calibration cage and roentgen tubes (foci 1 and 2). Control points placed close to the roentgen tubes identify the position of the tubes. Fiducial marks, placed in the floor of the calibration cage close to roentgen films were used to identify the laboratory coordinate system. In the later updates all markers can be used for both purposes.

the evolution of computer hardware and software technology, measuring the marker positions and analysing the motion between the tantalum markers have been simplified.

Computation of motions

The migration of the implant relative to the host bone can be measured using both segment motion and point motion. Segment-motion analysis requires at least three identifiable markers with a good scatter in the implant and host bone respectively. If fewer than three markers are identifiable in the implant, point-motion or model-based measurement is applied. In model-based RSA, an asymmetrical implant is necessary

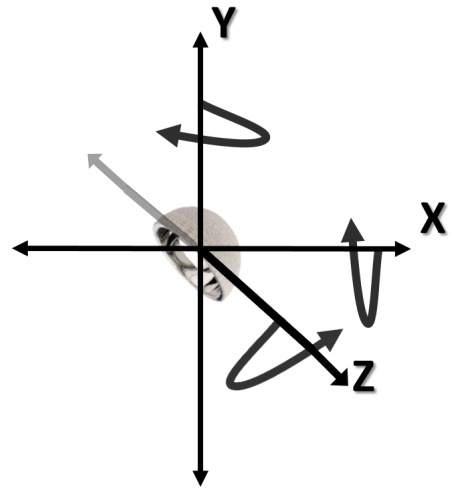
to record rotations in all three directions. The measurement of the rotation is only possible using segment motion. Movements of a segment are measured at the gravitational centre of the markers included. In this thesis, the movements between the two segments are analysed in relation to a body-fixed coordinate system defined by its three axes. The cup translation and rotations around the three axes are translated into anatomical alternations of the cup, as described in Figure 3.

1.4.2 The accuracy and precision of RSA measurements

The accuracy and precision of the RSA measurements depend on several factors. The most important factors are marker scatter, marker stability and number of markers available for analysis.

Accuracy is determined by a comparison between RSA measurements and true motion determined with a method that has no error. In reality, no such method exists; instead, comparison is performed with a method that has a higher resolution than RSA. In practice, phantom models are used, where an implant is, for example, attached to a device allowing for small implant motions with very high accuracy (Bojan et al. 2015, Bragdon et al. 2002, Önsten et al. 1995). Precision corresponding to the repeatability of the measurements is evaluated by comparing double examinations. The difference between

Axis	Translation	
	(+)	(-)
X	Medial	Lateral
Y	Proximal	Distal
Z	Anterior	Posterior



Axis	Rotation	
	(+)	(-)
X	Anterior tilt	Posterior tilt
Y	Retroversion	Anteversion
Z	↑ inclination	↓ inclination

Figure 3. Description of the three different axis in RSA measurements

repeated RSA examinations, presumed to mirror a fixed position of the implant, is calculated. Ideally, the radiographic equipment should be repositioned between

the examinations and the patient should also leave the examination table and then be placed in a similar position a second time. The computed change in implant position between these two examinations is supposed to represent precision. This error is usually expected to have a mean value of zero, provided that a sufficient number of double examinations are available (no systematic difference between examination one and two). The magnitude of the error is expressed as the minimum detection limit in the individual case with a certainty of 95 or 99 per cent based on a normal distribution. The standard deviation from a supposed mean value of zero is computed and multiplied by a constant available for two-sided tests in a t-table, based on the number of observations available.

The precision of RSA measurements has been reported by several authors (Bragdon et al. 2002, Mjoberg et al. 1986, Selvik 1989, Valstar et al. 2005). In most studies of total hip prostheses, the precision of translation measured with RSA varies between 0.05 and 0.50 mm. The corresponding value for rotation is between 0.15° and 1.15°, depending on the direction analysed and the overall quality of the data obtained (Kärrholm 1989).

1.4.3 RSA in evaluating new surgical techniques and implant designs

Due to low failure rates after a THA, clinical studies analysing new implants and

surgical techniques require a large number of patients. Further failures due to loosening and wear do not normally occur until the second decade after a THA. Operating on a large number of patients with an implant that might render inferior results, not recognised by the patient or the surgeon during the first decade, might give rise to challenging ethical considerations. A method which, after a short observation period and based on a limited number of observations, can be used to predict future revisions will therefore be of value to both surgeons and patients.

The high accuracy and precision of RSA offer a means for comparing different implants and surgical techniques by including a small number of patients (Kärrholm et al. 1994). According to a meta-analysis published in 2012 (Pijls et al.), the early proximal migration (translation along the y axis) of the acetabular component is a predictor of late aseptic loosening in primary THA. In this meta-analysis, two different systematic reviews were performed. In the first review, all the studies of primary THA with long-term data were identified. In the second review, RSA studies of THA with a minimum follow-up of one year were included. After combining these two reviews, the authors found that the risk of aseptic cup loosening at 10 years increased by 10% for every millimetre of proximal migration at two years. They concluded that proximal cup migration, measured during the first two years, should be used in the phased, evidence-based introduction of new implants.

The RSA migration pattern of the implants used in revision surgery has been reported by several authors (Nivbrant & Kärrholm 1997, Ornstein et al. 1999, Saari et al. 2014). As described, earlier revisions are more challenging to evaluate. Inferior acetabular bone quality and the use of bone grafts might influence early proximal migration. The influence of early proximal migration in predicting late aseptic loosening after revision surgery has not been studied in the past. The presence of any correlation between early implant migration and the risk of late aseptic loosening in revisions would be important to establish. If present, measurements of proximal migration with RSA could be used in the evaluation of new designs and surgical techniques that are being introduced in revision hip arthroplasty.

2 AIMS

- I. Does the method of fixation influence the risk of re-revision in acetabular revisions?
- II. Is the outcome for liner revision similar to that for revisions of the entire cup?
- III. Are there any differences in the risk of early re-revision between the trabecular metal cup and the most frequently used cemented and uncemented revision cups in Sweden?
- IV. Is early proximal migration, measured with radiostereometry, a predictor of late aseptic loosening in acetabular revision surgery?
- V. Does the method of fixation influence the proximal migration of acetabular components when bone impaction grafting is used?
- VI. Is there a difference in the amount of early migration between a cemented and a trabecular metal revision cup when bone impaction grafting is used?

3 PATIENTS AND METHODS

Observational studies using data from the Swedish Hip Arthroplasty Register

3.1 Paper I

All first-time cup revisions reported to the SHAR in 1979 and 2010 ($n=19,342$) were identified. Cases with missing data ($n=297$), two-stage revisions ($n=391$) and revisions in which a hip resurfacing or a tumour prosthesis had been inserted ($n=61$) were excluded. The remaining 18,593 cases were analysed regarding the method of fixation used at revision. Re-revision, defined as the exchange or removal of the cup, was used as the end-point. The mean follow-up was 7.6 years and the mean time from index revision to re-revision was 6.4 years. A Cox regression model adjusted for age, gender, primary diagnosis, method of fixation at primary THA and components revised was applied to identify differences between cemented and uncemented revision cups. Re-revision for any reason and re-revision secondary to aseptic loosening, infection and dislocation were used as end-points. In this study, liner revisions were compared with those revisions in which the uncemented primary cup was revised with a new uncemented cup.

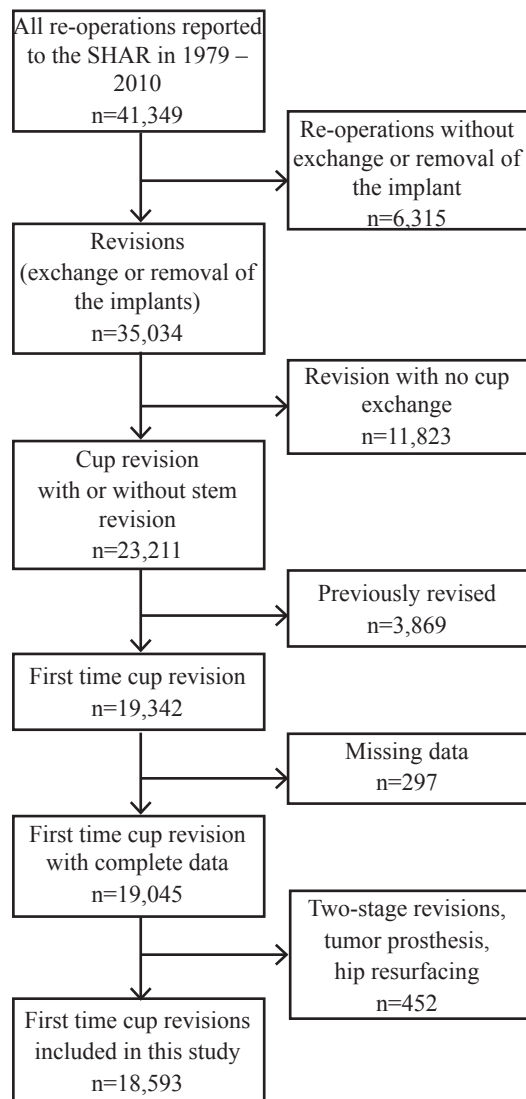


Figure 4. Paper I flowchart

3.2 Paper II

All first-time acetabular revisions performed with the most frequently used TM design (Trabecular Metal™, n=805), the most commonly used uncemented cup (Trilogy®, n=870) or the most frequently used cemented cup design (Lubinus®, n=785) performed in 2006-2012 were analysed. Re-operation, defined as any surgical intervention (n=215), and re-revision (exchange or removal of the cup, n=132) were used as end-points (Table 3). The mean age at the time of the index revision was 72 years. The most common primary diagnosis was primary osteoarthritis (76%). The first-time revision was performed after a mean of 13 years following the primary hip replacement. The mean follow-up time, with re-operation as the end-point, was 3.2 years and the corresponding figure for re-revision was 3.3 years. Cox regression analysis adjusted for gender, age, primary diagnosis, method of fixation in primary surgery, use of bone grafting and concomitant stem revision was applied.

Clinical studies

3.3 Paper III

All acetabular revisions included in prospective RSA studies at Sahlgrenska University Hospital were identified (n=384). Patients operated multiple times (n=49) were excluded. Three hundred and twelve patients were eligible for further analysis (Figure 5). There were 187 females and 125 males. Their mean age was 64 years. The pre-operative bone defect was classified according to Gustilo & Pasternak (1988). RSA was performed one to 11 days post-operatively, after three and six months and one and two years post-operatively. Further radiographic and radiostereometric follow-ups were scheduled at three, five, seven, 10, 13, 17 and 20 years post-operatively. The last available radiograph in each case was evaluated according to a modified DeLee and Charnley classification (DeLee & Charnley 1976, Hultmark et al. (2003).

Table 3. Surgical interventions performed after first time revision divided into re-operation and re-revision

Second surgical intervention	Re-operation	Re-revisions
Cup (or liner) and stem exchange	26	34
Cup (or liner) exchange	80	89
Cup and/or stem extraction	6	9
Stem exchange	35	—
Debridement	30	—
Osteosynthesis	14	—
Others	24	—

Radiographic loosening was defined as complete radiolucency in either AP or lateral projections. A Cox regression model

adjusted for age, gender, primary diagnosis, previous revisions, bone defects, method of fixation and amount of bone graft was applied to assess the influence of proximal migration on the risk of aseptic loosening of the acetabular component.

The Akaike information criterion (Akaike 1987) and Akaike weights (Wagenmakers & Farrell 2004) were used to identify the best predictor among the proximal migration values measured during the first two years.

3.4 Paper IV

Forty-five patients (47 hips) with less than 50% host bone-implant contact undergoing acetabular revision surgery were included in this study. Patients were randomised before surgery to an uncemented or a cemented cup and were followed for a minimum of 17 years. The baseline demographics are presented in Table 4. Bone impaction grafting was used in all cases. One patient in each of the two groups required a bulk allograft. All uncemented cups required additional fixation with three to five screws. In four cemented revisions, a mesh was placed medially before the bone graft was impacted. Partial weight-bearing was prescribed for three month. Radiographic and RSA follow-up was performed at three and six months and one, two, three, five, seven, 10, 13, 17 and 20 years. A clinical follow-up was scheduled from one year post-operatively and at the same aforementioned interval. No patients were lost to follow-up. Re-revision due to aseptic loosening or radiographic loosening of the acetabular component at the last follow-up was used as the end-point. Two patients, neither re-revised, were

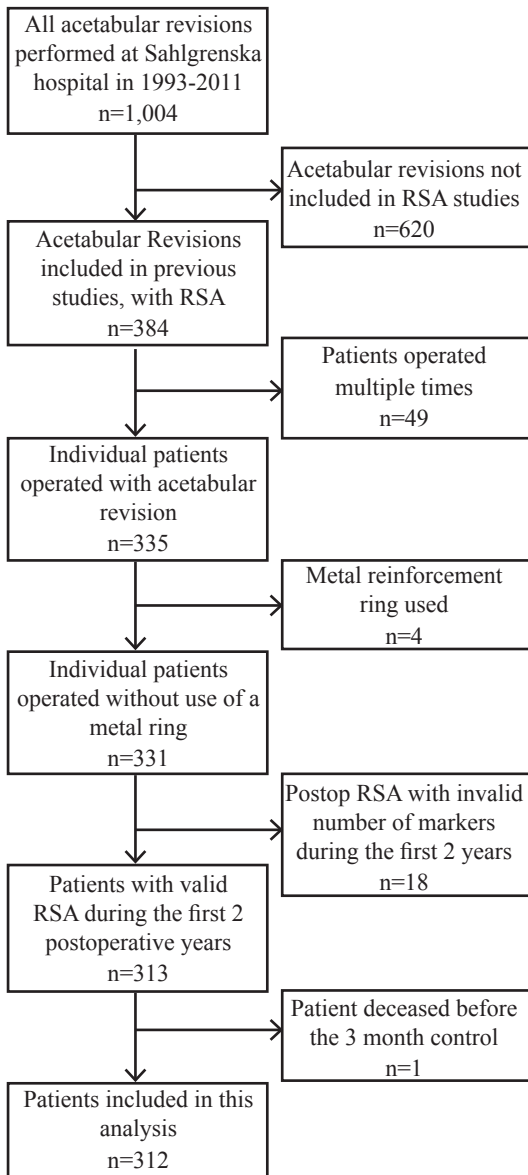


Figure 5. Paper III flowchart

unable to attend the last scheduled follow-up due to a deteriorating medical condition not associated with the revision surgery.

These patients were contacted and they did not report any disability associated with the revised hip.

Table 4. Base line demographic data, Paper IV

Demographic and surgical data	Uncemented (n=20)	Cemented (n=27)	p
Men/Women	9/11	9/18	0.14
Age	61 (33-77)	56 (38-79)	0.43
Osteoarthritis			
primary/secondary	11/9	17/10	0.59
Weight (Kg)	74 (48-100)	70 (58-72)	0.82
Incision			
Lateral/Posterolateral	13/7	24/3	0.06
Number of previous open surgery	1(1-5)	1(1-6)	0.51
Number of previous cup revision	0(0-2)	0(0-3)	0.06
Type of revision (cup/total, n)	10/10	15/12	0.71
Bone defect (n in I/II/III/IV) ¹			
Before acetabular preparation	1/6/12/1	0/9/10/8	0.23
After acetabular preparation	0/6/13/1	0/7/11/9	0.13
Allograft volume (mL)	100 (30-200)	110 (60-300)	0.33

Numbers are given as median (range). P-values are for non-parametric statistics comparing cemented and uncemented cups (TM). Bone defects were classified according to Gustilo Pasternak (GP)

3.5 Paper V

Patients aged 30-79 years, scheduled for acetabular revision surgery at Sahlgrenska University Hospital, Mölndal, undergoing surgery between June 2006 and December 2011, were asked to participate. Pre-operatively, bone defects were classified as small or large. Patients with large peri-acetabular bone defects, where the cup was expected to rest on less than 50% vital bone,

were included. Patients were randomised to a cemented all-poly cup (n=19) or an uncemented trabecular metal cup (n=23). Patients were followed for two years. The follow-up schedule is shown in Table 5. Detailed baseline demographic data are presented in Table 6. Re-revision, defined as the exchange of the cup, liner exchange or removal of the prosthesis, was used as the end-point of the study.

Table 5. Follow-up scheme

Follow-up	Pre-op	Post-op	3 month	6 month	1 year	2 years
Radiology (pelvis AP + lateral)	+	+			+	+
Harris Hip Score	+				+	+
EQ-5D [†] , Pain VAS	+					+
Complications		+	+	+	+	+
Radiostereometry		+	+	+	+	+

[†]Standardised instrument for use as a measure of health outcome, developed by EuroQoI Group Association.

Table 6. Base-line demographic data

Demographic and Surgical data	Cemented (n=19)	Uncemented (n=23)	p
Age	69 (40 - 77)	68 (42 - 79)	0.84
Weight	80 (52 - 107)	74 (45 - 103)	0.29
Gender - female	8	14	0.23
Primary osteoarthritis	14	9	0.16
Previously cup revised	3	11	0.89
Bone defect			0.35
GPI	4	6	—
GP II	6	10	—
GP III	9	7	—
Incision			0.57
Anterolateral	17	18	—
Posterolateral	2	5	—
Concomitant stem revision	14	17	0.99
Allograft volume (ml)	120 (35 - 200)	60 (0 - 200)	<0.01

Numbers are given as median (range). P-values are for non-parametric statistics comparing cemented and uncemented cups (TM). Bone defects were classified according to Gustilo Pasternak (GP)

4 STATISTICAL METHODS

4.1 Descriptive statistics

Data on continuous variables are presented with mean and range (minimum-maximum). Variables with asymmetric distributions are presented with median and range. Survival of the components after revision surgery was calculated using a Kaplan-Meier estimator. Values are presented as the mean cumulative survival ratio in per cent with a 95% confidence interval (CI) or standard deviations (SD).

4.2 Statistical interference

Inferential statistics were used to compare different groups in this study. Non-parametric testing with the Kruskal-Wallis H test was applied to compare unrelated groups. Wilcoxon's signed-rank test was used to find differences in the related samples, such as alterations in measurement values over time in the same group. A log-rank test, reported with p-values, was

applied to calculate differences in mean cumulative survival ratios.

4.3 Regression models

Cox regression analysis was used to adjust for dissimilarities in baseline demographics and differences in time to follow-up. The proportional hazard was controlled using Schoenfeld residuals. Variables with more than two nominal values have been categorised. The data are presented as relative risks (RR) and 95% CI.

4.4 Software

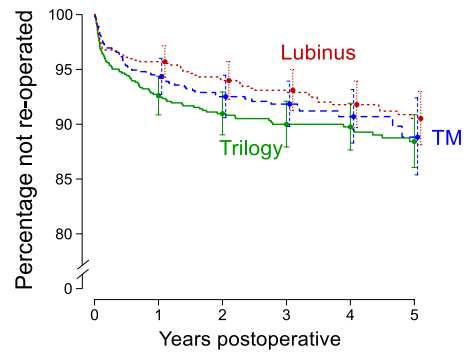
SPSS 20.0 subsequently upgraded to 22.0 (IBM Corporation, Armonk, NY), was used for data collection and most of the analyses. Graphs were created and parts of the analysis were performed using R-software (R Development Core Team, Vienna, Austria).

5 RESULTS

Observational studies using data from the Swedish Hip Arthroplasty Register

5.1 Paper I

During the follow-up, re-revision was performed in 2,250 cases. The main reason for re-revision was aseptic loosening (n=1,446). The mean cumulative survival of the cemented revision cups at 10 years (84%) was higher ($p < 0.001$) than when uncemented fixation was used (81%). This difference was even greater at 20 years (cemented: 73%, uncemented: 60%, $p < 0.001$). When adjusting for co-variables, the risk of re-revision did not differ based on the method of fixation used during first-time revision (RR: 0.94, CI: 0.85-1.03). Cemented revision cups were re-revised more often due to aseptic loosening (RR: 1.14, CI: 1.00-1.29). Re-revision due to dislocation was less common if cemented fixation was used (RR: 0.51, CI: 0.4-0.66). Liner revision increased the risk of a second revision (RR: 1.70, CI: 1.34-2.14). This risk was even higher when dislocation was used as the end-point (RR: 2.94, CI: 1.70-5.00).



Number at risk	0	1	2	3	4	5
Lubinus (---)	785	655	563	466	360	250
TM (---)	805	625	473	327	156	70
Trilogy (—)	870	721	622	483	378	260

Figure 6. Cumulative survival of different cup designs using re-operation due to any reason as end-point.

5.2 Paper II

In this analysis, 215 cases (8.8%) had been re-operated. The main reasons for re-operation were dislocation (n=62) and infection (n=51). There were no differences ($p = 0.31$) in the survival rate at five years when comparing the TM cup (89%) with the cemented Lubinus (91%) and the uncemented Trilogy design (88%) (Figure 6). When adjusting for differences in demographic and surgical data in a Cox regression model, the risk of re-operation on the TM cup did not differ when compared with the other two designs ($p \geq 0.78$) (Table 7). Re-revision (exchange or removal of the

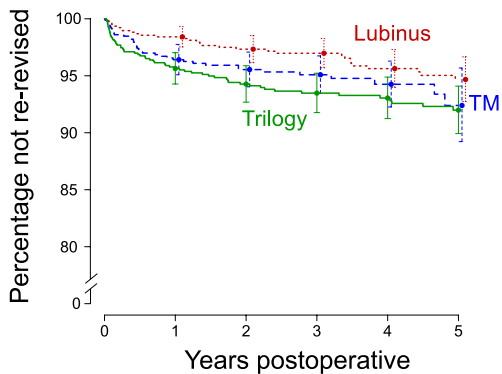
implant) was performed in 132 hips (5.4%), mainly due to dislocation (n=48) and infection (n=35). The five-year cumulative survival did not differ significantly for the three aforementioned cup designs (p=0.05) (Figure 7). The Trilogy cup was more frequently re-revised than the Lubinus

design (p=0.01). After adjusting for covariates in the Cox regression analysis, the risk of re-revision was lower (p=0.04) for the Lubinus cup compared with when the Trilogy design had been used (Table 7). The risk of re-revision increased if the stem had not been revised.

Table 7. Cox-regression analysis, re-operation or re-revision used as end-point

Risk factor	Re-operation			Re-revision		
	RR	95% CI	p	RR	95% CI	p
Gender						
Male	1.1	0.83 – 1.4	0.6	1.1	0.76 – 1.5	0.7
Female ^a	1	–	–	1	–	–
Age (years)						
< 70	1.1	0.79 – 1.5	0.6	1.3	0.84 – 1.9	0.3
70-79 ^a	1	–	–	1	–	–
> 79	0.87	0.59 – 1.3	0.5	1.1	0.64 – 1.7	0.8
Diagnosis						
Secondary OA ^b	1.2	0.88 – 1.7	0.3	1.4	0.96 – 2.1	0.08
Primary OA ^a	1	–	–	1	–	–
Primary cup						
Uncemented	0.98	0.68 – 1.4	0.9	1.1	0.73 – 1.8	0.6
Cemented ^a	1	–	–	1	–	–
Bone grafting						
Yes	0.91	0.68 – 1.2	0.5	0.9	0.64 – 1.3	0.7
No ^a	1	–	–	1	–	–
Components revised						
Cup	1.1	0.85 – 1.5	0.4	1.8	1.23 – 2.6	0.002
Cup + Stem ^{a,d}	1	–	–	1	–	–
Cup^c						
TM ^d	0.85	0.61 – 1.2	0.3	0.8	0.54 – 1.2	0.3
Lubinus	0.78	0.57 – 1.1	0.1	0.6	0.41 – 0.97	0.04
Trilogy ^a	1	–	–	1	–	–

RR = relative risk; CI = confidence interval; ^aReference; ^bInflammatory hip disease (35%), sequel after childhood disease (26%), fracture (17%), avascular necrosis (13%) and others (9%); ^cCup used during the first time revision; ^dTrabecular metal.



Number at risk

Lubinus (.....)	785	672	580	481	371	259
TM (---)	805	638	490	337	162	73
Trilogy (—)	870	746	647	504	396	272

Figure 7. Cumulative survival of different cup designs using exchange or removal of the cup as end-point.

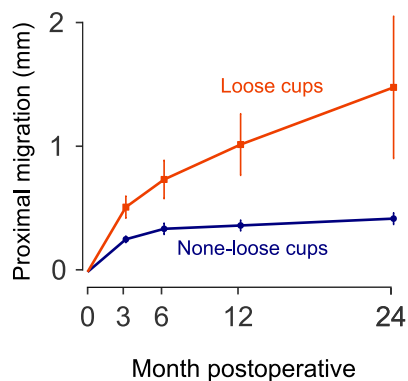


Figure 8. Cups judged as loose at the last follow-up or becoming re-revised due to aseptic loosening showed a higher proximal migration during the first two years.

Clinical studies

5.3 Paper III

By the end of the study, 46 hips had been re-revised. Aseptic loosening of the acetabular component necessitated re-revision in 26 cases at a mean of eight (SD: 3.7) years after the initial revision. Seven cases (not re-revised) were regarded as loose at the last radiographic evaluation. In all, aseptic loosening of the acetabular component occurred in 33 cases. These cups showed significantly higher early proximal migration (Figure 8).

High early proximal migration during the first two post-operative years increased the risk of subsequent aseptic loosening. Proximal migration measured two years post-operatively was the best predictor of subsequent loosening. (Table 8).

The risk of loosening increased almost six fold (RR: 5.6, CI: 2.0- 15.4) if the proximal migration at two years exceeded 1.0 mm (Table 9).

Table 8. Adjusted relative risk of loosening with proximal migration measured at different time points

Postoperative proximal migration measured with RSA	RR	95% CI	p	AIC	BIC	wAIC
3 months	2.93	1.64 — 5.25	< 0.01	294	325	< 0.01
6 months	1.72	1.14 — 2.57	< 0.01	295	326	< 0.01
1 year	2.51	1.78 — 3.53	< 0.01	280	310	< 0.01
2 years	1.57	1.34 — 1.84	< 0.01	262	292	1.00

Adjusted relative risks for proximal migration with numeric and nominal variables non-categorized. Low AIC and BIC values and high wAIC indicate the better model. RR = relative risk; CI = confidence interval; AIC = Akaike Information Criteria; BIC = Bayesian Information Criteria; wAIC= Akaike weights.

Table 9. Cox regression analysis, aseptic loosening of the acetabular component used as end point

Risk factor	RR	95% CI	p
Gender			
Male ^a	1	—	—
Female	0.52	0.23 — 1.2	0.12
Age			
≥ 65 years ^a	1	—	—
< 65 years	1.03	1.01 — 1.0	< 0.01
Bone defect			
GP 1,2 ^{a,b}	1	—	—
GP 3,4	1.08	0.49 — 2.4	0.85
Diagnosis			
Primary OA ^a	1	—	—
Secondary OA ^c	0.68	0.31 — 1.5	0.34
Revision cup			
Uncemented ^a	1	—	—
Cemented	1.21	0.51 — 2.9	0.67
Previously revised			
No ^a	1	—	—
Yes	0.33	0.10 — 1.1	0.08
Bone graft			
< 50 ml ^a	1	—	—
≥ 50 ml	0.99	0.93 — 1.0	0.71
Proximal migration at 2 years			
< 0.2 mm ^a	1	—	—
0.2-1 mm	1.04	0.38 — 2.8	0.94
> 1 mm	5.58	2.02 — 15.4	< 0.01

RR = relative risk; CI = confidence interval; ^a Reference; ^b Bone defects according to Gustilo Pasternak; ^c sequel after childhood disease (36%), Inflammatory hip disease (30%), fracture (21%), avascular necrosis (12%).

5.4 Paper IV

At the last follow-up, 14 hips had been re-revised due to aseptic loosening. Three hips (not re-revised) were assessed as loose at three to 13 years, two patients had died before re-revision and one hip was asymptomatic. The last patient had restricted mobility due to transfemoral amputation on the contralateral leg and declined further participation in the study after the 13-year follow-up. One additional patient with a deteriorating medical condition was unable to attend past 13 years.

Three cup or liner revisions were performed in hips (all uncemented) with femoral loosening, acetabular osteolysis and liner wear respectively not permitting further RSA measurements. In the total study population, and up to two years, the proximal migration was lower in the uncemented group. The proximal migration of the cemented cases tended to increase during the follow up. At 17 years, the mean proximal migration in the cemented group reached 2.18 mm (SD 1.42). The corresponding value in the uncemented group was 0.01 mm (SD 0.21). In the whole study group, the Harris hip and pain scores increased from a median of 47 and 20 before the index revision to 83 and 44 respectively, at the one-year follow-up ($p < 0.001$). There was no difference between the cemented and the TM cups regarding improvements in the clinical outcomes ($p \geq 0.12$) at one year.

5.5 Paper V

At the two-year follow-up, two patients had died. One patient declined participation past

six months due to a deteriorating medical condition not related to the revision. During the first two years, one cemented cup was re-revised due to dislocation at 17 months. In the entire study group, the EQ general health VAS was unchanged at two years ($p=0.2$). Harris hip scores increased from a median of 54 before the revision to 85 and 90 at the one-year and two-year follow-up respectively ($p < 0.001$). The EQ-5D index increased from a median of 0.69 pre-operatively to 0.74 at two years ($p=0.005$). The improvement in the EQ-5D index was higher in patients undergoing surgery with the TM cup ($p=0.03$). None of the other clinical parameters collected pre-operatively and at two years differed significantly between the cemented and the TM group ($p > 0.08$). The cemented cups had a higher proximal migration at three months compared with the TM cup. This difference increased during the first two years (Figure 9).

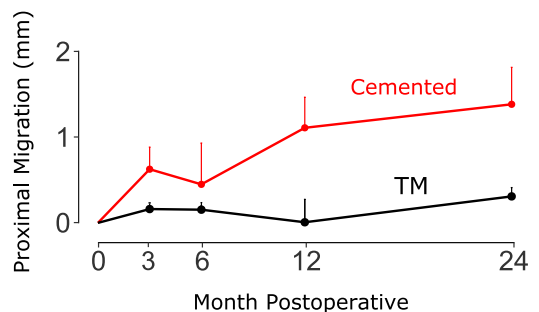


Figure 9. Proximal migration measured with radiostereometry during the first two years.

6 LIMITATIONS

6.1 Observational studies using data from the Swedish Hip Arthroplasty Register

Swedish surgeons have preferred cemented fixation in both THA and revision surgery. However, the relative share of uncemented fixation has increased in primary cases and revisions during the last two decades (Garellick et al. 2013, Mohaddes et al. 2013). In Paper I, more than half the uncemented revisions were performed at nine hospitals and about 50% of the cemented revisions were performed at 15 hospitals nationwide. These data suggest that surgeons familiar with revision surgery performed the majority of the revisions, especially those cases in which an uncemented cup had been used. In Paper I, all first-time revisions reported to the SHAR in 1979-2010 were included. Some of the designs included in this analysis have been abandoned due to unacceptable failure rates, caused by early loosening or an inferior locking mechanism. This will probably influence the survival of both cemented and uncemented cups included in this paper. Further, a decision was made not to adjust for the bone graft that was used. This was done due to a lack of data in the SHAR enabling differentiation

between cases undergoing surgery with impaction grafting and revisions in which minor osteolysis had been filled with a graft.

In Paper II, adjusting for the bone graft did not influence the survival of the uncemented and cemented cups included in the study. The mean follow-up in this paper was only 3.3 years. The main purpose of this study was to ascertain that the TM design was not afflicted with obvious early disadvantages. Clearly, further follow-up of this cup design is needed in order to illustrate whether there are any advantages in the long term from using the TM in acetabular revision surgery.

In observational studies based on data from the SHAR, re-operation or re-revision was used as an end-point. It could be argued that analyses of patient-reported outcome measures (PROM) and psycho-social factors might be of interest. Unfortunately, these data are not available for revisions in the SHAR. Further, according to Rothwell et al. (2010) there is a correlation between PROM and the risk of revision in hip arthroplasty. Although analysing patient-reported outcomes and psycho-social dimensions would have been of value, the lack of these data will definitely not influence the conclusions in the first two papers.

6.2 Clinical studies

In Paper III, analysing 312 acetabular revisions performed at Sahlgrenska University Hospital, the mean follow-up in the cemented group (12 years) was longer than that for the uncemented cases (seven years). In order to be certain about the influence of fixation method on the proximal migration pattern, a subgroup analysis of cemented and uncemented cups is required, preferably after a longer follow-up for the uncemented cases. However, in this paper performing a Cox regression analysis and calculating Schoenfeld residuals (Schoenfeld 1980) will partly compensate for differences in the follow-up of cemented and uncemented designs.

In the last two papers, the Gustilo-Pasternak bone defect classification system was used. This classification system does not describe the integrity of the acetabular rim and has been modified by Raut et al. (1995). In Paper V, all pre-operative radiographs were prospectively classified using bone defect classification systems described by Paprosky et al. (1994) and Saleh et al. (2001). There was moderate intra-observer validity and poor inter-observer reliability. These findings are similar to previously published reports (Campbell et al. 2001, Gozzard et al. 2003). Due to limitations in the inter- and intra-observer validity demonstrated by Paper V and the aforementioned publications, it could be argued that including patients in the last

two manuscripts, based on the host-bone implant, is equally relevant to using an existing bone defect classification system. This question requires further investigation.

In the clinical studies in this thesis, several surgeons contributed. The skills of individual surgeons might have contributed to the risk of late aseptic loosening. This might especially influence the outcome of bone impaction grafted cases. In the last paper, about half the surgeries were performed by a single surgeon (senior author). There was no significant difference in the proximal migration of the acetabular components in revisions performed by the senior author and the other eight surgeons. This finding indicates that the skills of individual surgeons performing revisions at our centre do not influence the proximal migration of the acetabular components and should not have any impact on the conclusions in Papers III-V.

7 DISCUSSION

The use of cemented fixation with bone impaction grafting introduced by Slooff et al. has shown promising long-term results. They report a cup survival of 87% at 20 years using re-revision due to aseptic loosening as the end-point (Schreurs et al. 2009, van Egmond et al. 2011).

Van Haaren et al. (2007) used the technique described by Slooff and Schreurs (Slooff et al. 1984) and reported a re-revision rate of 28% at nine years, with aseptic loosening as the end-point. In this study, the majority of failures (70%) occurred in hips with large bone defects.

To our knowledge, there are no published randomised trials comparing the results of cemented and uncemented fixation in acetabular revisions. In this thesis, there was no difference in the overall risk of re-revision based on the method of fixation. However, the method of fixation used for the acetabular component appears to influence the mode of failure in revision surgery. A higher risk of re-revision due to aseptic loosening in cemented acetabular revisions was demonstrated in the register-based study (Paper I). In the last two papers,

cemented cups showed a higher early proximal migration, indicating a higher risk of aseptic loosening when cemented designs are used. The trabecular metal cup appears to achieve good initial stability. Data from the SHAR indicate good short-term results for the TM cup.

According to the findings in Paper I, there is a higher risk of dislocation when uncemented fixation is used in acetabular revision. The increased risk of dislocation associated with uncemented fixation is not only observed in revision surgery. According to reports from the SHAR, the risk of revision due to dislocation increases when an uncemented cup is used. It is possible to argue that the increased risk of dislocation is associated with Swedish surgeons being more familiar with cemented fixation. This presumption is, however, debatable. During the last decade, the proportion of uncemented fixation in Sweden has increased and, in the last five years, uncemented designs have been used in about half of all cup revisions. Further, in several countries, such as the USA, where a higher proportion of uncemented designs are used, the most frequent cause of revision is dislocation. This is not the case in Sweden,

where aseptic loosening is the most common reason for revision after a primary THA. In paper I more than half of the uncemented and cemented revisions were performed in nine and 15 hospitals, respectively, as an effect of centralization of these procedures. For this reason, the Swedish surgeons being more familiar with cemented fixation should not play a major role in the increased risk of dislocation associated with uncemented fixation found in this thesis. Further studies investigating the reason for the increased risk of dislocation when uncemented designs are used are needed.

7.1 Acetabular revisions and the Swedish Hip Arthroplasty Register

Many questions related to acetabular revision surgery are difficult to address in randomised clinical trials. Due to the diversities in revisions, these studies require a comparatively large number of patients to be included and followed for a long period of time. Performing these studies in a timely manner, considering the evolution of implants and surgical techniques in hip revision surgery, is time consuming and in some instances impossible. The Swedish Hip Arthroplasty Register provides excellent opportunities to perform observational studies to address matters which would otherwise run the risk of remaining unresolved. In some instances, analysing data from a large national register generates different hypotheses which are possible to address in randomised clinical trials.

In observational register studies, many aspects need to be considered.

- The research is limited to variables available in the register.
- Missing data can be difficult to handle.
- The coverage and completeness of the data need to be analysed.
- The data gathered need to be validated.
- Differences in demographic and surgical data need to be adjusted for when comparing two different groups / implants.
- Time periods when different implants or techniques are employed must be kept in mind.
- Confounders that are not recorded, might influence the outcome being studied.

For example, in the SHAR, information about the use of bone grafts (yes/no) is extracted from the case records. Since data on the amount of bone graft used and the extent of bone defects are not consistently recorded in the register, adjusting for these variations is not possible. Despite the considerations mentioned above, the SHAR comprises a large number of revisions with detailed records of many parameters for each procedure. This register therefore offers excellent opportunities to address

questions regarding revision surgery raised by clinicians and researchers.

Cemented fixation was a common method in acetabular revisions in Sweden until the mid-2000s. During the first decade of this century, the use of cemented fixation decreased. Since 2010, the distribution between cemented and uncemented fixation appears to have stabilised. Reports indicating a lower survival of cemented cups (Table 10) are probably the reason for this decrease (Pulido et al. 2011).

During the last two decades, several authors have reported favourable results, using cemented fixation with bone impaction grafting in acetabular revision (Buttaro et al. 2008, Comba et al. 2009, Schreurs et al. 2009). The use of trabecular tantalum designs in cases with large bone defects has recently been advocated as an attractive alternative by several authors (Beckmann et al. 2014, Sternheim et al. 2012).

In the first paper analysing all first-time revisions reported to the SHAR in 1979 to

2011, there was no difference in the risk of overall survival when comparing the cemented and uncemented revision cups. It could be argued that the evolution of the cementing technique during the last two decades (Breusch & Malchau 2005), improved design of the uncemented cups (Pulido et al. 2011) and the introduction of highly cross-linked polyethylene (Muratoglu et al. 2001) is not reflected in the results when analysing all the revisions performed in 1979-2011. However, excluding specific designs would most probably be associated with introducing selection bias. The findings in Paper I describe the actual results based on the majority of acetabular revisions performed in Sweden during a period of about 35 years. Implant selection and surgical experience will develop over such a long time period. The results in Study I indicate that cemented fixation in acetabular revision is still a viable option in the second decade of this century.

The introduction of new trabecular designs and more wear-resistant polyethylene will probably influence the long-term results for

Table 10. Publications during years 1985 to 1996 reporting on survival of cemented revision cups

Author/year	No. of hips	Age	Follow-up	Re-operation
Pellicci et al. (1985)	99	64 (29-89)	8 (5-12)	19%
Engelbrecht et al. (1990)	138	59 (25-85)	7 (3-15)	9%
Marti et al. (1990)	60	71 (26-86)	8 (5-14)	13%
Garcia-Cimbrelo (1995)	148	59 (22-82)	11 (0-20)	13%
Strömberg & Herbets (1996)	53	47 (29-55)	7 (4-11)	15%

Numbers are given as median (maximum-minimum) unless otherwise stated. Re-operation is calculated using all surgical interventions reported in the publication divided by number of patients included.

acetabular revisions. However, due to the limited time of observation, these questions could not be addressed in this thesis.

In a recently published systematic review (Banerjee et al. 2014), analysing 2,083 revisions, the authors concluded that the short-term results are excellent when trabecular metal cups are used in acetabular revisions. In this publication, with a mean follow-up of 3.6 years, the survival of TM cups with aseptic re-revision as the endpoint was 97%. The overall survival of TM cups, regardless of the reason for revision, is not presented in this paper. When analysing 2,460 revisions in Paper II, with a mean follow-up of 3.3 years, the overall survival of the TM cup with re-revision as the endpoint was 92%. In this study, the short-term survival of the TM cup did not differ compared with two other frequently used revision cups in Sweden. Further, the use of bone grafts did not influence the outcome. The findings from this study indicate that bone grafting does not increase the risk of re-revision in the short term. There was a lower survival rate for the TM cup in Paper II, compared with the findings in the systematic review by Banerjee et al. This could be partly explained by re-revisions being performed for reasons other than aseptic loosening. As demonstrated in Paper II and by other publications reviewed in the paper by Banerjee et al., the short-term results for TM designs used in acetabular revision are promising. Further follow-up is needed to evaluate whether the increased cost of surgery associated with the use of a TM design can be justified from a longer perspective.

7.2 Liner revisions and the Swedish Hip Arthroplasty Register

Isolated liner revision has been the subject of debate in the literature. Boucher et al. (2003) reported on 25 patients who were liner revised due to wear. None of the patients included in the study had had problems with dislocation before the revision. At a mean follow-up of 4.7 years, six patients (25%) had suffered dislocations. The authors concluded that isolated liner exchange should be approached cautiously. Beaulé et al. (2004) treated 32 hips with the insertion of a new polyethylene liner or a metal liner, using cement. At a mean follow-up of 5.1 years, six hips had undergone re-operations due to aseptic failure (n=4), instability (n=1) and sepsis (n=1). The authors suggested that cementing a new liner into a well-fixed uncemented socket was an effective technique in acetabular revision. O'Brien et al. (2004) studied 24 hips which underwent isolated polyethylene liner exchange, followed for one to 8.3 years (mean three years). Only two patients (8.3%) required a second revision. The authors concluded that isolated polyethylene liner exchange is a viable option in revision surgery. They suggested that long-term studies are needed. Lie et al. (2007) analysed 318 liner revisions in the Norwegian Arthroplasty Register and compared them with patients in whom an uncemented cup had been revised with a new uncemented cup (n=1,331). With a mean follow-up of 7.5 years, the risk of a second revision was 80% higher in the liner-revised cases. Dislocation, necessitating a

second revision, was twice as common in the isolated liner revisions.

In Paper I, 928 liner revisions reported to the SHAR in 1979-2012 and followed for 0-19 years (mean 5.7 years) were analysed. These revisions were compared with a failed primary uncemented cup which was revised with an uncemented design (n=906). The analysis revealed an increased risk of a second revision (RR: 1.7; CI: 1.3–2.1) when an isolated liner exchange had been performed. The risk of re-revision was even higher when dislocation was used as the endpoint (RR: 2.9; CI: 1.7–5.0). These findings correspond to the results from the Norwegian Arthroplasty Register. Based on the findings in Paper I and aforementioned publications, isolated liner revision is associated with an increased risk of re-revision, especially due to dislocation, and should be utilised after thorough consideration.

7.3 RSA in predicting risk of loosening

Radiostereometry, which was introduced more than 40 years ago, offers an excellent opportunity to quantify implant motion in orthopaedic surgery (Kärrholm 1989). According to several reports, the migration of implants in primary hip arthroplasty is correlated with an increased risk of subsequent aseptic loosening (Kärrholm et al. 1994, Krismser et al. 1996, Pijls et al. 2012, Snorrason & Kärrholm 1990). Pijls et al. (2012) demonstrated that every millimetre of increment in proximal migration measured at two years increases

the risk of late revision due to aseptic loosening in THR by 10%. The correlation between migration measured with RSA and the risk of aseptic loosening in revision surgery has not been studied before. In Paper III, 312 acetabular revisions were followed two to 20 years post revision. Each millimetre of proximal migration increased the risk of aseptic loosening almost two fold. This risk increment was even higher when the data were adjusted for differences in demographics, bone defects and surgical approaches. The same correlation was detected when analysing the two-dimensional migration (the square root sum of proximal/ distal and medial/lateral migration) of the cup.

The risk increments for revision cups appear to be much larger than for primary cups (Pijls et al. 2012). It could be argued that the use of bone grafts and inferior bone stock in revisions contributes to larger proximal migration and thereby a higher risk of aseptic loosening. Further, Pijls et al. (2012) reported on different cohorts of patients, followed with RSA and long term respectively. Further studies, including the long-term follow-up of a sufficiently large cohort of patients followed with RSA, are probably necessary to evaluate whether the predictive value of early migration differs between primary and revision cups.

In 1995, Malchau wrote about the importance of stepwise introduction when new implants are introduced in THA. In his thesis, Malchau emphasised the use of RSA as one of the four necessary steps before new implants are launched. Three decades

later, new techniques and implants are being introduced in the market, both in THA and not least in acetabular revision surgery without proper evaluation. Some of these introductions have been associated with unacceptable failures (Langton et al. 2010, Luites et al. 2006), putting patient safety at risk, damaging the reputation of the implant industry and compromising the orthopaedic community (Meier 2011).

Based on the findings in Paper III, the use of RSA should be regarded as one of the necessary steps when new implants and surgical techniques are introduced in acetabular revision surgery. This enables a more controlled introduction of novel techniques and designs, benefiting patients, the implant industry and surgeons.

7.4 RSA and method of fixation in acetabular revision

Several authors (Nivbrant & Kärrholm 1997, Ornstein et al. 1999, Snorrason & Kärrholm 1990) have reported on early proximal migration measured with RSA in acetabular revisions. In 1990, Snorrason and Kärrholm reported on a group of 15 cemented acetabular revisions not requiring bone grafting. The patients were followed for two years. The authors reported a mean proximal migration of 0.6 millimetres. Ornstein et al. observed a mean proximal migration of 2.1 mm at two years in 21 cemented cup revisions with impaction bone grafting. Nivbrant et al (1996) followed sixty acetabular revisions in which a Harris

Galante cup was used and 31 hips required bone grafting. They reported a mean proximal migration of 0.2 mm at two years in hips not requiring bone grafting, while the use of morsellised bone grafts or bulk allografts was associated with significantly higher proximal migration (mean 0.4-0.6 mm). In Paper IV, all revisions were performed on patients with less than 50% bone-implant contact. In this paper, the uncemented cups showed a mean proximal migration of 0.71 mm at two years, about the same magnitude as that reported by Nivbrant et al. (1996). The cemented cups migrated substantially more (mean 1.39 mm). The higher proximal migration in the cemented group could be explained by several factors. The bone mill used at our institution in the mid-1990s (Tracer Design Inc.) produced relatively small bone chips. The bone was partially defatted in tepid water and the bone graft was impacted by reverse reaming. In 2000, Ullmark reported on an in-vitro study comparing the Tracer mill with a mill from Howex™ (Gävle, Sweden) which produced larger chips. The importance of defatting was analysed, comparing bone chips containing original bone marrow fat with bone chips defatted using warm saline solution. In this analysis, the maximum load required for rotating the cups was three times higher in defatted chips produced by the Howex mill compared with the defatted chips from the Tracer mill. The rotational stability of the cup increased two fold when the bone chips from the Howex mill were defatted. Bolder et al. (2003) performed a cadaveric study and concluded that using small bone chips and reverse reaming increased the proximal migration

of the cup. Due to these findings, the use of reverse reaming and small bone chips was abandoned at our centre in the late 1990s.

In Paper V, using the Noviomagus mill™ (Spierings Beheer B.V., Nijmegen, The Netherlands) and the impaction technique described by Slooff et al. (1984), the mean proximal migration of the cemented revision cups was significantly higher than that of the TM cup during the first two years ($p=0.02$). At two years, the median proximal migration of the cemented cups (1.45 mm) was almost six times higher than that of the TM cups (0.25 mm). Although the older drums for the Noviomagus mill produced somewhat smaller chips than hand-made chips (Bolder et al. 2003), by using the extra coarse milling drum in this study, the size of bone chips is comparable to that of hand-made chips measured by Bolder et al. (2003). Further, the same bone mill was used for both cemented and uncemented implants. The difference in proximal migration between the cemented and TM cups in this paper can therefore not be explained by smaller bone chips being inserted. According to the findings in Paper V, the TM cups achieve good initial stability while the migration of the cemented cups continues during the first two years post revision.

In both Paper IV and Paper V, the cemented acetabular components showed higher migration measured with RSA. The reasons why cemented revision cups, inserted with bone grafts, migrate more than uncemented designs are not known. The migration pattern and the failure mode in bone impaction grafted revisions might differ

based on the method of fixation. Although our findings indicate that cemented revision cups, inserted with bone impaction grafting, run a higher risk of late aseptic loosening, further studies are needed to analyse this issue.

In view of the meticulous surgical technique needed when employing bone impaction grafting and based on findings in this thesis, a deliberate approach towards cemented revision with bone impaction grafting is relevant.

7.5 Patient-reported outcomes and psychosocial determinants in revision surgery

There are a limited number of publications related to the psychosocial aspects of revision hip arthroplasty. Eisler et al. (2002) analysed the correlation between patient expectations and satisfaction in 66 consecutive revisions. According to their findings one year after revision, 12% were dissatisfied and 3% wished they had never had the surgery. In this paper, there was an association between the pre- and post-operative Harris hip score and the degree of patient satisfaction at one year post revision. Age, gender, co-morbidity (measured with the Charnley classification), the number of previous revisions and the occurrence of post-operative complications did not significantly influence satisfaction at one year. When analysing 609 revisions,

Dawson et al. (2001) reported that 13% of patients were not pleased with the result after revision surgery. In this study, patient satisfaction correlated with functional outcomes, measured with the Oxford Hip Score (Dawson et al. 1996) and patient-reported outcomes, evaluated with the EQ-5D (1990). Barrack et al. (2006) reported on 320 first-time revisions and 17% of the patients reported they were dissatisfied with the outcome of revision. In this study, patients older than 45 years and patients who were married or were living with a family were more satisfied.

In 2002, the SHAR introduced a PROM programme for patients undergoing THA in Sweden (Rolfson et al. 2011). One year post THA, 11% of patients reported that they were not fully satisfied with the outcome of surgery (Garellick et al. 2013). Numerous studies have been performed in order to identify psychosocial factors associated with patient satisfaction and patient-reported outcomes in the SHAR (Greene et al. 2014, Krupic et al. 2013, Rolfson et al. 2009). Analysing the association of educational attainment with patient-reported outcomes, Greene et al. (2014) found that patients with low and medium educational levels reported lower EQ-5D scores and a higher degree of pain at one year post THA. Krupic et al. (2013) studied the influence of ethnicity on the outcome after THA. In this analysis, patients born outside Sweden reported a higher degree of anxiety and depression and difficulties and more problems with self-care both pre- and post-operatively. Rolfson et al. (2009) reported on patient-related factors determining the outcome in THA.

According to their findings, pre-operative anxiety and depression were the strongest predictors of pain relief and satisfaction one year after surgery.

In this thesis, a biometric approach, analysing the fixation method and migration measured with RSA, was used to identify risk factors and predictors of re-revision in acetabular revision surgery. The influence of psychosocial aspects on the risk of re-revision and analyses of patient-reported outcomes after revision surgery are outside the scope of this thesis. Based on the aforementioned correlations between psychosocial factors and patient-reported outcomes after THA, further analysis of these factors in revision surgery is needed. Implementing PROMs for revision cases in arthroplasty registers will enable analyses of patient-reported outcomes and facilitate the identification of psychosocial determinants in revision surgery.

8 CONCLUSIONS

- I. The over-all risk of re- revision does not appear to be influenced by the method of fixation used for the acetabular revision component.
- II. Liner revision increases the risk of a second revision.
- III. The overall risk of early re-revision does not differ between the TM and the other two most frequently used revision cups in Sweden.
- IV. Early proximal migration, measured with radiostereometry is a predictor of late aseptic loosening in acetabular revision surgery.
- V. The TM design used with bone impaction grafting in revisions with less than 50% bone-implant contact results in significantly lower proximal migration compared with a cemented cup.

9 FUTURE PERSPECTIVES

Due to the multi-factorial nature of revision surgery, studies of this topic usually require more information than is commonly recorded in a joint register. Collecting data in a national joint register is in some instances a time-consuming process. Regarding revisions, the baseline data on surgery are recorded by a contact secretary at each hospital. The surgical records are sent to the SHAR and additional information is collected and entered by the co-ordinators in the register. Extending the data collection, by including more variables in a national joint register, might endanger the completeness and coverage of the SHAR. Refining the data collection process, based on recent advances made in information technology, will most certainly reduce the administrative burden for register co-ordinators, facilitate data collection, enable on-line feedback to patients and clinicians and increase the scientific validity of register studies.

The role of RSA in predicting late failure after THA requires further verification. This could preferably be done using a large enough cohort of patients undergoing THA and followed up for a minimum of 10 to 15 years.

The proximal migration in cemented revision cups is higher than in the uncemented

designs used in acetabular revision when bone impaction grafting is used. It might be that the cemented cups withstand a larger amount of proximal migration at least at an early stage corresponding to the first and perhaps also the second year after surgery. In order to study this hypothesis, a randomised trial with a larger number of revision patients than that included in this thesis is required.

One of the main arguments in favour of using bone impaction grafting is the ability of this method to restore bone stock. There are several histological studies supporting graft incorporation in cemented femoral revisions (Linder 2000, Nelissen et al. 1995, Ullmark & Obrant 2002). However, the scientific support regarding the fate of bone grafts in acetabular revisions is scarce.

The inhibition of bone resorption and the stimulation of osteoblasts using bisphosphonates has been shown to reduce the migration of implants (Hilding & Aspenberg 2006, Hilding et al. 2000) and improve component fixation (Hilding & Aspenberg 2007) in knee surgery. In a recently published study, Saari et al. (2014) did not find any beneficial effects on implant fixation or bone remodelling measured with DEXA in acetabular revision surgery

when risedronate was administered orally. The Role of bisphosphonates in acetabular revisions needs further investigations. The use of a fluoride-PET scan to study bone metabolism in a cohort of patients undergoing bone impaction grafting and a cemented or a TM design is an interesting opportunity to improve our knowledge of the fate of impacted bone in acetabular revisions. The role of bisphosphonates could also be analysed using fluoride-PET in randomised trials.

Conducting an in-vitro study, Schildhauer et al. (2006) demonstrated lower adhesion for *Staphylococcus aureus* when TM was compared with other metal alloys used in orthopaedic surgery. In 2009, the same group (Schildhauer et al. 2009) illustrated that the chemotactic response of white blood cells towards TM was significantly higher, indicating an enhanced local host defence mechanism when the TM design is used.

Tokarski et al. (2015) reported on 990 hips undergoing surgery with either a TM (n=454) or a titanium (n=536) design. In this study, the mean follow-up was 3.4 years. The incidence of infection in the TM group was lower although not statistically significant. An analysis of a cohort of 144 hips, revised initially for infection and controlling for baseline demographics and surgical factors, revealed that there was a significantly lower risk of infection in the TM group. In Paper II comparing 805 TM cups with 870 titanium revision shells, 39 hips had undergone re-operations due to infection. Infection necessitating surgical

intervention was almost three times more common in the titanium group compared with the TM group. Due to an overall low incidence of infection in this study, further analysis using a multivariate analysis was not performed. Although one of the main benefits of performing register studies is access to a large sample size, in some instances the number of patients in an individual register does not allow firm conclusions to be drawn.

In order to further improve and facilitate the research performed in the Nordic countries, the Nordic Arthroplasty Register Association (NARA), a collaboration between arthroplasty registers in Denmark, Finland, Norway and Sweden, was established in 2007. Studies using data from the NARA have provided the answers to several questions which would have been difficult to address using information from a single register (Bergh et al. 2014, Hailer et al. 2015, Robertsson et al. 2010, Schrama et al. 2015). Increasing collaboration between different arthroplasty registers will not only facilitate research.

Co-operation between registers worldwide, such as the initiative taken by the International Society of Arthroplasty Registries, offers an excellent opportunity to monitor new implants that are being introduced, promoting a safe and powerful pre-release clinical assessment of novel designs in joint arthroplasty (Malchau et al. 2015). This will clearly benefit the orthopaedic community and not least future patients in need of arthroplasty.

ACKNOWLEDGEMENTS

I would like to express my sincere gratitude to all those people who contributed to and, by supporting and encouraging me, made the completion of this thesis possible. In particular, I would like to thank following people.

Johan Kärrholm, my supervisor, for introducing me to science and following my every step on this journey. Your huge base of knowledge, humble attitude, great enthusiasm for research and excellent mentoring skills made this thesis possible.

Bengt Eriksson, my co-supervisor, for always being there, both as a mentor and as a friend. Your attitude to life is a never-ending source of inspiration, encouraging everybody around to continue with the hard work required to pursue science.

Henrik Malchau, co-author, and clinical mentor. Your pragmatic approach to life and your huge scientific knowledge, clinical skills and administrative expertise have been important key elements in facilitating my journey.

Magnus Karlsson, the head of the orthopaedic department, for your support and mentoring in leadership issues and for being a supportive boss in all matters.

Jonas Thanner, the head of the joint replacement unit, for providing me with the opportunity to pursue my research alongside everyday clinical work, encouraging me and guiding me in the right direction.

Peter Herbets, co-author and mentor. Your efforts and guidance are some of the crucial factors that made this thesis possible.

Göran Garellick, co-author and colleague, for your guidance and charismatic mentoring.

Jorma Styf, colleague and respected professor at The Sahlgrenska Academy, for your holistic perspective, wise comments, and insightful remarks. Your remarks during numerous dissertations in the last few years and not least during the writing of this thesis made a huge contribution to the final stages of my journey as a PhD student.

Ola Rolfson, co-author. Your enthusiasm and expertise regarding PROMs and value-based health care introduced me to a new and exciting field of science with which I was unacquainted. I look forward to continuing fruitful collaboration and friendship.

Per-Erik Johanson, co-author, valued colleague and friend.

Linda Johansson, research administrator, for your patience and enormous support.

Bitu Shareghi and Erna Andreasson, RSA technicians, without your efforts and commitment, this thesis would never be as complete.

Ola Vikersfors, my mentor during residency, for your guidance and your excellent approach to teaching me the manners most needed by a new orthopaedic resident.

Peter Grant, colleague, mentor and a dear friend. Your positive feedback and criticism relating to this thesis, my clinical pathway and way of life has been one of the refreshing elements facilitating this journey.

Szilard Nemes, valued friend and statistician at the SHAR. Your excellent teaching skills have been a cornerstone in my understanding of statistics.

Max Gordon, colleague, for introducing me to and teaching me the basics of R-software.

Kajsa Erikson, Karin Lindborg, Karin Pettersson & Karin Davidsson, for all your efforts with regard to the SHAR.

My parents, Mohammed & Nasrin, who never stopped being caring and loving human beings. During the last four decades. you have tutored me, encouraged me and most importantly taught me the sane moral aspects every individual needs, to be able to pursue life. If I could give you one thing

in life, I would give you the ability to see yourselves through my eyes. Only then would you realise how special you are to me.

And finally and foremost

My beloved wife, Somayeh, for standing right next to me. Your joy of life and sensible attitude have been the most important reasons for my success. Bringing me the most precious gifts, you have given me a second chance to experience all the good things in life I had once experienced but was unable to remember. I will always owe you a huge debt of gratitude for everything you have done ever since I laid eyes on you. My wonderful sons, **Sam** and **Benjamin**, for bringing me a new opportunity to learn, grow and blossom with no strings attached.

Institutional grants

This thesis was made possible by grants from the following foundations:

- Dr Félix Neuberghs stiftelse
- Göteborgs Läkaresällskap (Gothenburg Medical Society)
- IngaBritt och Arne Lundberg research foundation
- Stiftelsen Hjalmar Svensson

Zimmer Inc. provided institutional support with regard to Study V.

The publication of the results is not contingent on the sponsors' approval.

REFERENCES

- Ahnfelt L.** Re-Opererade Totala Höftledsplastiker I Sverige under Åren 1979-1983=[Re-Operated Total Hip Arthroplasties in Sweden 1979-1983] 1986.
- Akaike H.** Factor Analysis and Aic. Psychometrika 1987; 52 (3): 317-32.
- Banerjee S, Issa K, Kapadia B H, Pivec R, Khanuja H S, Mont M A.** Systematic Review on Outcomes of Acetabular Revisions with Highly-Porous Metals. Int Orthop 2014; 38 (4): 689-702.
- Barrack R L, McClure J T, Burak C F, Clohisy J C, Parvizi J, Hozack W.** Revision Total Hip Arthroplasty: The Patient's Perspective. Clin Orthop Relat Res 2006; 453: 173-7.
- Beaulé P E, Ebramzadeh E, LeDuff M, Prasad R, Amstutz H C.** Cementing a Liner into a Stable Cementless Acetabular Shell: The Double-Socket Technique. J Bone Joint Surg Am 2004; 86 (5): 929-34.
- Beckenbaugh R D, Ilstrup D M.** Total Hip Arthroplasty 1978.
- Beckmann NA, Weiss S, Klotz M, Gondan M, Jaeger S, Bitsch R G.** Loosening after Acetabular Revision: Comparison of Trabecular Metal and Reinforcement Rings. A Systematic Review. J Arthroplasty 2014; 29 (1): 229-35.
- Bergh C, Fenstad A M, Furnes O, Garellick G, Havelin L I, Overgaard S, Pedersen A B, Mäkelä K T, Pulkkinen P, Mohaddes M.** Increased Risk of Revision in Patients with Non-Traumatic Femoral Head Necrosis: 11,589 Cases Compared to 416,217 Cases with Primary Osteoarthritis in the Nara Database, 1995–2011. Acta Orthop 2014; 85 (1): 11-7.
- Bobyn J, Stackpool G, Hacking S, Tanzer M, Krygier J.** Characteristics of Bone Ingrowth and Interface Mechanics of a New Porous Tantalum Biomaterial. J Bone Joint Surg Br 1999; 81 (5): 907-14.
- Bobyn J D, Toh K-K, Hacking S A, Tanzer M, Krygier J J.** Tissue Response to Porous Tantalum Acetabular Cups: A Canine Model. J Arthroplasty 1999; 14 (3): 347-54.
- Bojan A J, Bragdon C, Jönsson A, Ekholm C, Kärrholm J.** Three-Dimensional Bone-Implant Movements in Trochanteric Hip Fractures: Precision and Accuracy of Radiostereometric Analysis in a Phantom Model. J Orthop Res 2015.
- Bolder S B, Schreurs B W, Verdonschot N, van Unen J M, Gardeniers J W,**

Slooff T J. Particle Size of Bone Graft and Method of Impaction Affect Initial Stability of Cemented Cups: Human Cadaveric and Synthetic Pelvic Specimen Studies. *Acta Orthop* 2003; 74 (6): 652-7.

Boucher H R, Lynch C, Young A M, Engh CA, Engh C. Dislocation after Polyethylene Liner Exchange in Total Hip Arthroplasty. *J Arthroplasty* 2003; 18 (5): 654-7.

Bragdon C R, Malchau H, Yuan X, Perinchieff R, Kärrholm J, Börlin N, Estok D M, Harris W H. Experimental Assessment of Precision and Accuracy of Radiostereometric Analysis for the Determination of Polyethylene Wear in a Total Hip Replacement Model. *J Orthop Res* 2002; 20 (4): 688-95.

Breusch S J, Malchau H. What Is Modern Cementing Technique? In: *The Well-Cemented Total Hip Arthroplasty*. Springer; 2005; 146-9.

Buttaro MA, Comba F, Pusso R, Piccaluga F. Acetabular Revision with Metal Mesh, Impaction Bone Grafting, and a Cemented Cup. *Clin Orthop Relat Res* 2008; 466 (10): 2482-90.

Börlin N, Röhrli S M, Bragdon C R. Rsa Wear Measurements with or without Markers in Total Hip Arthroplasty. *J Biomech* 2006; 39 (9): 1641-50.

Börlin N, Thien T, Kärrholm J. The Precision of Radiostereometric Measurements. Manual Vs. Digital

Measurements. *J Biomech* 2002; 35 (1): 69-79.

Campbell D G, Garbuz D S, Masri B A, Duncan C P. Reliability of Acetabular Bone Defect Classification Systems in Revision Total Hip Arthroplasty. *J Arthroplasty* 2001; 16 (1): 83-6.

Carlsson Å S. 351 Total Hip Replacements According to Charnley: A Review of Complications and Function. *Acta Orthop* 1981; 52 (3): 339-44.

Charnley J. Tissue Reaction to the Polytetrafluoroethylene. *The Lancet* 1963; 282 (7322): 1379.

Cohen J. A Coefficient of Agreement for Nominal Scales. *Educ Psychol Meas* 1960; 20 (1): 37-46.

Comba F, Buttaro M, Pusso R, Piccaluga F. Acetabular Revision Surgery with Impacted Bone Allografts and Cemented Cups in Patients Younger Than 55 Years. *Int Orthop* 2009; 33 (3): 611-6.

D'Antonio J. Periprosthetic Bone Loss of the Acetabulum. Classification and Management. *The Orthopedic clinics of North America* 1992; 23 (2): 279.

Davies J H, Laflamme G Y, Delisle J, Fernandes J. Trabecular Metal Used for Major Bone Loss in Acetabular Hip Revision. *J Arthroplasty* 2011; 26 (8): 1245-50.

Dawson J, Fitzpatrick R, Carr A, Murray D. Questionnaire on the Perceptions of Patients About Total Hip Replacement. *J Bone Joint Surg Br* 1996; 78 (2): 185-90.

DeLee J G, Charnley J. Radiological Demarcation of Cemented Sockets in Total Hip Replacement. *Clin Orthop Relat Res* 1976; (121): 20-32.

Dupont J A, Charnley J. Low-Friction Arthroplasty of the Hip for the Failures of Previous Operations. *J Bone Joint Surg Br* 1972; 54-B (1): 77-87.

Eftekhar N S, Smith D M, Henry J H, Stinchfield F E. Revision Arthroplasty Using Charnley Low Friction Arthroplasty Technic with Reference to Specifics of Technic and Comparison of Results with Primary Low Friction Arthroplasty*. *Clin Orthop Relat Res* 1973; 95: 48-59.

Eisler T, Svensson O, Tengström A, Elmstedt E. Patient Expectation and Satisfaction in Revision Total Hip Arthroplasty. *J Arthroplasty* 2002; 17 (4): 457-62.

Engelbrecht D, Weber F, Sweet M, Jakim I. Long-Term Results of Revision Total Hip Arthroplasty. *J Bone Joint Surg Br* 1990; 72 (1): 41.

Euroqol - a New Facility for the Measurement of Health-Related Quality of Life. *Health Policy* 1990; 16 (3): 199-208.

Garcia-Cimbrello E, Munuera L,

Diez-Vazquez V. Long-Term Results of Aseptic Cemented Charnley Revisions. *J Arthroplasty* 1995; 10 (2): 121-31.

Garellick G, Rogmark C, Kärrholm J, Rolfson O. The Swedish Hip Arthroplasty Register, Annual Report 2012. The Swedish Hip Arthroplasty Register, Annual Report 2012. http://www.shpr.se/Libraries/Documents/AnnualReport_2012_EngWEB.sflb.ashx; 2013.

Gomez PF, Morcuende JA. Early Attempts at Hip Arthroplasty: 1700s to 1950s. The Iowa orthopaedic journal 2005; 25: 25.

Gozzard C, Blom A, Taylor A, Smith E, Learmonth I. A Comparison of the Reliability and Validity of Bone Stock Loss Classification Systems Used for Revision Hip Surgery. *J Arthroplasty* 2003; 18 (5): 638-42.

Greene M E, Rolfson O, Nemes S, Gordon M, Malchau H, Garellick G. Education Attainment Is Associated with Patient-Reported Outcomes: Findings from the Swedish Hip Arthroplasty Register. *Clin Orthop Relat Res* 2014; 472 (6): 1868-76.

Gross A, Allan D, Catre M, Garbuz D, Stockley I. Bone Grafts in Hip Replacement Surgery. The Pelvic Side. The Orthopedic clinics of North America 1993; 24 (4): 679-95.

Gustilo RB, Pasternak HS. Revision Total Hip Arthroplasty with Titanium Ingrowth

Prosthesis and Bone Grafting for Failed Cemented Femoral Component Loosening. *Clin Orthop Relat Res* 1988; (235): 111-9.

Hailer N P, Lazarinis S, Mäkelä K T, Eskelinen A, Fenstad A M, Hallan G, Havelin L, Overgaard S, Pedersen A B, Mehnert F. Hydroxyapatite Coating Does Not Improve Uncemented Stem Survival after Total Hip Arthroplasty! An Analysis of 116,069 Thas in the Nordic Arthroplasty Register Association (Nara) Database. *Acta Orthop* 2015; 86 (1): 18-25.

Harris W H. Traumatic Arthritis of the Hip after Dislocation and Acetabular Fractures: Treatment by Mold Arthroplasty an End-Result Study Using a New Method of Result Evaluation. *J Bone Joint Surg Am* 1969; 51 (4): 737-55.

Hilding M, Aspenberg P. Postoperative Clodronate Decreases Prosthetic Migration: 4-Year Follow-up of a Randomized Radiostereometric Study of 50 Total Knee Patients. *Acta Orthop* 2006; 77 (6): 912-6.

Hilding M, Aspenberg P. Local Perioperative Treatment with a Bisphosphonate Improves the Fixation of Total Knee Prostheses: A Randomized, Double-Blind Radiostereometric Study of 50 Patients. *Acta Orthop* 2007; 78 (6): 795-9.

Hilding M, Ryd L, Toksvig-Larsen S, Aspenberg P. Clodronate Prevents Prosthetic Migration: A Randomized

Radiostereometric Study of 50 Total Knee Patients. *Acta Orthop* 2000; 71 (6): 553-7.

Hultmark P, Höstner J, Herberts P, Kärrholm J. Radiographic Evaluation of Charnley Cups Used in First-Time Revision: Repeated Observations for 7–15 Years. *J Arthroplasty* 2003; 18 (8): 1005-15.

Karrholm J, Borssen B, Lowenhielm G, Snorrason F. Does Early Micromotion of Femoral Stem Prostheses Matter? 4-7-Year Stereoradiographic Follow-up of 84 Cemented Prostheses. *The Journal of bone and joint surgery British volume* 1994; 76 (6): 912-7.

Kim W Y, Greidanus N V, Duncan C P, Masri B A, Garbuz D S. Porous Tantalum Uncemented Acetabular Shells in Revision Total Hip Replacement: Two to Four Year Clinical and Radiographic Results. *Hip Int* 2008; 18 (1): 17-22.

Krismer M, Stöckl B, Fischer M, Bauer R, Mayrhofer P, Ogon M. Early Migration Predicts Late Aseptic Failure of Hip Sockets. *J Bone Joint Surg Br* 1996; 78: 422-6.

Krupic F, Eisler T, Garellick G, Kärrholm J. Influence of Ethnicity and Socioeconomic Factors on Outcome after Total Hip Replacement. *Scand J Caring Sci* 2013; 27 (1): 139-46.

Kurtz S, Ong K, Lau E, Mowat F, Halpern M. Projections of Primary and Revision Hip and Knee Arthroplasty in the United States from 2005 to 2030. *J Bone Joint Surg Am*

2007; 89 (4): 780-5.

Kärrholm J. Roentgen Stereophotogrammetry: Review of Orthopedic Applications. *Acta Orthop* 1989; 60 (4): 491-503.

Lakstein D, Backstein D, Safir O, Kosashvili Y, Gross A E. Trabecular Metal™ Cups for Acetabular Defects with 50% or Less Host Bone Contact. *Clin Orthop Relat Res* 2009; 467 (9): 2318-24.

Langton D, Jameson S, Joyce T, Hallab N, Natu S, Nargol A. Early Failure of Metal-on-Metal Bearings in Hip Resurfacing and Large-Diameter Total Hip Replacement a Consequence of Excess Wear. *J Bone Joint Surg Br* 2010; 92 (1): 38-46.

Levine B R, Sporer S, Poggie R A, Della Valle C J, Jacobs J J. Experimental and Clinical Performance of Porous Tantalum in Orthopedic Surgery. *Biomaterials* 2006; 27 (27): 4671-81.

Lie S, Hallan G, Furnes O, Havelin L, Engesaeter L. Isolated Acetabular Liner Exchange Compared with Complete Acetabular Component Revision in Revision of Primary Uncemented Acetabular Components a Study of 1649 Revisions from the Norwegian Arthroplasty Register. *J Bone Joint Surg Br* 2007; 89 (5): 591-4.

Lindberg H O, Carlsson Å S, Gentz C-F, Pettersson H. Recurrent and Non-Recurrent Dislocation Following Total Hip Arthroplasty. *Acta Orthop* 1982; 53 (6):

947-52.

Linder L. Cancellous Impaction Grafting in the Human Femur: Histological and Radiographic Observations in 6 Autopsy Femurs and 8 Biopsies. *Acta Orthop* 2000; 71 (6): 543-52.

Luites J, Spruit M, van Hellemond G G, Horstmann W, Valstar E. Failure of the Uncoated Titanium Proxilock Femoral Hip Prosthesis. *Clin Orthop Relat Res* 2006; 448: 79-86.

Malchau H. On the Importance of Stepwise Introduction of New Hip Implant Technology: Assessment of Total Hip Replacement Using Clinical Evaluation, Radiostereometry, Digitised Radiography and a National Hip Registry. *Ortopedisk kirurgi* 1995.

Malchau H, Graves S E, Porter M, Harris W H, Troelsen A. The Next Critical Role of Orthopedic Registries. *Acta Orthop* 2015; 86 (1): 3.

Marti R K, Schüller H, Besselaar P P, Vanfrank H E L. Results of Revision of Hip Arthroplasty with Cement. A Five to Fourteen-Year Follow-up Study. *J Bone Joint Surg Am* 1990; 72 (3): 346.

Meier B. In Medicine, New Isn't Always Improved. In: *The New York Times In Medicine, New Isn't Always Improved.* http://www.nytimes.com/2011/06/26/health/26innovate.html?_r=0; 2011; 2015.

Mjoberg B, Selvik G, Hansson L, Rosenqvist R, Onnerfalt R. Mechanical Loosening of Total Hip Prostheses. A Radiographic and Roentgen Stereophotogrammetric Study. *J Bone Joint Surg Br* 1986; 68 (5): 770.

Mohaddes M, Garellick G, Kärrholm J. Method of Fixation Does Not Influence the Overall Risk of Rerevision in First-Time Cup Revisions. *Clin Orthop Relat Res* 2013; 1-10.

Mulier M, Rys B, Moke L. Hedrocel Trabecular Metal Monoblock Acetabular Cups: Mid-Term Results. *Acta Orthop Belg* 2006; 72 (3): 326.

Muratoglu O K, Bragdon C R, O'Connor D O, Jasty M, Harris W H. A Novel Method of Cross-Linking Ultra-High-Molecular-Weight Polyethylene to Improve Wear, Reduce Oxidation, and Retain Mechanical Properties: Recipient of the 1999 Hap Paul Award. *J Arthroplasty* 2001; 16 (2): 149-60.

Nelissen R, Bauer T W, Weidenhielm L, LeGolván D P, Mikhail W. Revision Hip Arthroplasty with the Use of Cement and Impaction Grafting. Histological Analysis of Four Cases. *J Bone Joint Surg* 1995; 77 (3): 412-22.

Nemes S, Gordon M, Rogmark C, Rolfson O. Projections of Total Hip Replacement in Sweden from 2013 to 2030. *Acta Orthop* 2014; 85 (3): 238-43.

Nivbrant B, Kärrholm J. Migration and

Wear of Hydroxyapatite-Coated Press-Fit Cups in Revision Hip Arthroplasty: A Radiostereometric Study. *J Arthroplasty* 1997; 12 (8): 904-12.

Nivbrant B, Kärrholm J, Önsten I, Carlsson Å, Snorrason F. Migration of Porous Press-Fit Cups in Hip Revision Arthroplasty: A Radiostereometric 2-Year Follow-up Study of 60 Hips. *J Arthroplasty* 1996; 11 (4): 390-6.

Nyström L, Söderkvist I, Wedin P-Å. A Note on Some Identification Problems Arising in Roentgen Stereo Photogrammetric Analysis. *J Biomech* 1994; 27 (10): 1291-4.

O'Brien J J, Burnett R S J, McCalden R W, MacDonald S J, Bourne R B, Rorabeck C H. Isolated Liner Exchange in Revision Total Hip Arthroplasty: Clinical Results Using the Direct Lateral Surgical Approach. 1 No Benefits or Funds Were Received in Support of This Study. *J Arthroplasty* 2004; 19 (4): 414-23.

Ornstein E, Franzén H, Johnsson R, Sandquist P, Stefansdottir A, Sundberg M. Migration of the Acetabular Component after Revision with Impacted Morselized Allografts: A Radiostereometric 2-Year Follow-up Analysis of 21 Cases. *Acta Orthop* 1999; 70 (4): 338-42.

Paprosky W G, Perona P G, Lawrence J M. Acetabular Defect Classification and Surgical Reconstruction in Revision Arthroplasty: A 6-Year Follow-up Evaluation. *J Arthroplasty* 1994; 9 (1): 33-

44.

Parrish T F, Jones J R. Fracture of the Femur Following Prosthetic Arthroplasty of the Hip 1964.

Pellicci P M, Wilson P D, Sledge C, Salvati E, Ranawat C, Poss R, Callaghan J. Long-Term Results of Revision Total Hip Replacement. *J Bone Joint Surg A* 1985; 67: 513-6.

Pijls B G, Nieuwenhuijse M J, Fiocco M, Plevier J W, Middeldorp S, Nelissen R G, Valstar E R. Early Proximal Migration of Cups Is Associated with Late Revision in Tha. *Acta Orthop* 2012; 83 (6): 583-91.

Pulido L, Rachala S, Cabanela M. Cementless Acetabular Revision: Past, Present, and Future. *Int Orthop* 2011; 35 (2): 289-98.

Raut V, Siney P, Wroblewski B. Cemented Revision for Aseptic Acetabular Loosening. A Review of 387 Hips. *J Bone Joint Surg Br* 1995; 77 (3): 357-61.

Richards C J, Garbuz D S, Duncan C P. Porous Metal Augments: An Attractive Alternative for Reconstructing Large Acetabular Defects. *Semin Arthroplasty* 2008; 19 (1): 164-7.

Ring P A. Total Replacement of the Hip Joint: A Review of a Thousand Operations. *J Bone Joint Surg Br* 1974; 56-B (1): 44-58.

Robertsson O, Bizjajeva S, Fenstad A

M, Furnes O, Lidgren L, Mehnert F, Odgaard A, Pedersen A B, Havelin L I. Knee Arthroplasty in Denmark, Norway and Sweden: A Pilot Study from the Nordic Arthroplasty Register Association. *Acta Orthop* 2010; 81 (1): 82-9.

Rolfson O, Dahlberg L E, Nilsson J-Å, Malchau H, Garellick G. Variables Determining Outcome in Total Hip Replacement Surgery. *J Bone Joint Surg Br* 2009; 91-B (2): 157-61.

Rolfson O, Kärrholm J, Dahlberg L, Garellick G. Patient-Reported Outcomes in the Swedish Hip Arthroplasty Register Results of a Nationwide Prospective Observational Study. *J Bone Joint Surg Br* 2011; 93 (7): 867-75.

Rothwell A, Hooper G, Hobbs A, Frampton C. An Analysis of the Oxford Hip and Knee Scores and Their Relationship to Early Joint Revision in the New Zealand Joint Registry. *J Bone Joint Surg Br* 2010; 92 (3): 413-8.

Saari T M, Digas G, Kärrholm J N. Risedronate Does Not Enhance Fixation or Bmd in Revision Cups: Randomised Study with Three Years Follow-Up. *Hip Int* 2014; 24 (1): 49-55.

Saleh K J, Holtzman J, Gafni A, Saleh L, Davis A, Resig S, Gross A E. Reliability and Intraoperative Validity of Preoperative Assessment of Standardized Plain Radiographs in Predicting Bone Loss at Revision Hip Surgery. *J Bone Joint Surg*

2001; 83 (7): 1040-6.

Schildhauer T, Peter E, Muhr G, Köller M. Activation of Human Leukocytes on Tantalum Trabecular Metal in Comparison to Commonly Used Orthopedic Metal Implant Materials. *Journal of Biomedical Materials Research Part A* 2009; 88 (2): 332-41.

Schildhauer T A, Robie B, Muhr G, Köller M. Bacterial Adherence to Tantalum Versus Commonly Used Orthopedic Metallic Implant Materials. *J Orthop Trauma* 2006; 20 (7): 476-84.

Schoenfeld D. Chi-Squared Goodness-of-Fit Tests for the Proportional Hazards Regression Model. *Biometrika* 1980; 67 (1): 145-53.

Schrama J C, Fenstad A M, Dale H, Havelin L, Hallan G, Overgaard S, Pedersen A B, Kärrholm J, Garellick G, Pulkkinen P. Increased Risk of Revision for Infection in Rheumatoid Arthritis Patients with Total Hip Replacements: A Study of 390,671 Primary Arthroplasties from the Nordic Arthroplasty Register Association. *Acta Orthop* 2015; 86 (3): 1-7.

Schreurs B, Keurentjes J, Gardeniers J, Verdonschot N, Slooff T, Veth R. Acetabular Revision with Impacted Morsellised Cancellous Bone Grafting and a Cemented Acetabular Component: A 20- to 25-Year Follow-Up. *J Bone Joint Surg Br* 2009; 91 (9): 1148-53.

Schreurs B, Slooff T, Buma P, Gardeniers J, Huiskes R. Acetabular Reconstruction with Impacted Morsellised Cancellous Bone Graft and Cement: A 10-to 15-Year Follow-up of 60 Revision Arthroplasties. *J Bone Joint Surg Br* 1998; 80 (3): 391-5.

Selvik G. Roentgen Stereophotogrammetry in Orthopedics. In: 26th Annual Technical Symposium Roentgen Stereophotogrammetry in Orthopedics. International Society for Optics and Photonics; 1983; 178-85.

Selvik G. Roentgen Stereophotogrammetry. *Acta Orthop* 1989; 60 (s232): 1-51.

Shinar A A, Harris W H. Bulk Structural Autogenous Grafts and Allografts for Reconstruction of the Acetabulum in Total Hip Arthroplasty. Sixteen-Year-Average Follow-up*. *J Bone Joint Surg* 1997; 79 (2): 159-68.

Siegmeth A, Duncan C P, Masri B A, Kim W Y, Garbuz D S. Modular Tantalum Augments for Acetabular Defects in Revision Hip Arthroplasty. *Clin Orthop Relat Res* 2009; 467 (1): 199-205.

Slooff T J J H, Huiskes R, van Horn J, Lemmens A J. Bone Grafting in Total Hip Replacement for Acetabular Protrusion. *Acta Orthop* 1984; 55 (6): 593-6.

Snorrason F, Kärrholm J. Primary Migration of Fully-Threaded Acetabular Prostheses. A Roentgen Stereophotogrammetric Analysis. *J Bone*

Joint Surg Br 1990; 72 (4): 647-52.

Soderman P, Malchau H, Herberts P, Zügner R, Regné H, Garellick G. Outcome after Total Hip Arthroplasty: Part II. Disease-Specific Follow-up and the Swedish National Total Hip Arthroplasty Register. *Acta Orthop* 2001; 72 (2): 113-9.

Sporer S M, Paprosky W G. Acetabular Revision Using a Trabecular Metal Acetabular Component for Severe Acetabular Bone Loss Associated with a Pelvic Discontinuity. *J Arthroplasty* 2006; 21 (6, Supplement): 87-90.

Sternheim A, Backstein D, Kuzyk P, Goshua G, Berkovich Y, Safir O, Gross A. Porous Metal Revision Shells for Management of Contained Acetabular Bone Defects at a Mean Follow-up of Six Years a Comparison between up to 50% Bleeding Host Bone Contact and More Than 50% Contact. *J Bone Joint Surg Br* 2012; 94 (2): 158-62.

Strömberg C N, Herberts P. Cemented Revision Total Hip Arthroplasties in Patients Younger Than 55 Years Old: A Multicenter Evaluation of Second-Generation Cementing Technique. *J Arthroplasty* 1996; 11 (5): 489-99.

Svanholm H, Starklint H, Gundersen H, Fabricius J, Barlebo H, Olsen S. Reproducibility of Histomorphologic Diagnoses with Special Reference to the Kappa Statistic. *APMIS* 1989; 97 (7-12): 689-98.

The New Zealand Joint Registry, Thirteen Year Report. The New Zealand Joint Registry, Thirteen Year Report. 2012; 2013.

Tokarski A, Novack T, Parvizi J. Is Tantalum Protective against Infection in Revision Total Hip Arthroplasty? *Bone & Joint Journal* 2015; 97 (1): 45-9.

Ullmark G. Bigger Size and Defatting of Bone Chips Will Increase Cup Stability. *Arch Orthop Trauma Surg* 2000; 120 (7): 445-7.

Ullmark G, Obrant K. Histology of Impacted Bone–Graft Incorporation. *J Arthroplasty* 2002; 17 (2): 150-7.

Unger A S, Lewis R J, Gruen T. Evaluation of a Porous Tantalum Uncemented Acetabular Cup in Revision Total Hip Arthroplasty: Clinical and Radiological Results of 60 Hips. *J Arthroplasty* 2005; 20 (8): 1002-9.

Wagenmakers E-J, Farrell S. Aic Model Selection Using Akaike Weights. *Psychonomic bulletin & review* 2004; 11 (1): 192-6.

Valstar E. Roentgen Stereophotogrammetric Analysis of the Mallory Head Prosthesis without Markers. *Acta Orthop* 1996; 67 (3).

Valstar E, De Jong F, Vrooman H, Rozing P, Reiber J. Model-Based Roentgen Stereophotogrammetry of Orthopaedic Implants. *J Biomech* 2001; 34 (6): 715-22.

Valstar E, Spoor C, Nelissen R, Rozing P. Roentgen Stereophotogrammetric Analysis of Metal-Backed Hemispherical Cups without Attached Markers. *J Orthop Res* 1997; 15 (6): 869-73.

Valstar E R, Gill R, Ryd L, Flivik G, Börlin N, Kärrholm J. Guidelines for Standardization of Radiostereometry (Rsa) of Implants. *Acta Orthop* 2005; 76 (4): 563-72.

van Egmond N, De Kam D, Gardeniers J, Schreurs B. Revisions of Extensive Acetabular Defects with Impaction Grafting and a Cement Cup. *Clin Orthop Relat Res* 2011; 469 (2): 562-73.

Van Haaren E, Heyligers I, Alexander F, Wuisman P. High Rate of Failure of Impaction Grafting in Large Acetabular Defects. *J Bone Joint Surg Br* 2007; 89 (3): 296-300.

Willert H G, Semlitsch M. Reactions of the Articular Capsule to Wear Products of Artificial Joint Prostheses. *J Biomed Mater Res* 1977; 11 (2): 157-64.

Önsten I, Åkesson K, Besjakov J, Obrant K J. Migration of the Charnley Stem in Rheumatoid Arthritis and Osteoarthritis. A Roentgen Stereophotogrammetric Study. *J Bone Joint Surg Br* 1995; 77 (1): 18-22.

