

# CLINICAL AND ARTHROSCOPIC ASSESSMENT OF WRIST LIGAMENT INJURIES AND INSTABILITY

JONNY ANDERSSON, MD

Department of Orthopaedics  
Institute of Clinical Sciences  
Sahlgrenska Academy at  
University of Gothenburg  
Gothenburg, Sweden, 2016

CLINICAL AND ARTHROSCOPIC  
ASSESSMENT OF WRIST LIGAMENT  
INJURIES AND INSTABILITY

Copyright © Jonny Andersson

This work is protected by the Act on  
Copyright in Literary and Artistic Works  
(1960:729). Detta verk skyddas enligt Lag  
(1960:729) om upphovsrätt till litterära och  
konstnärliga verk.

ISBN: 978-91-628-9672-0 (PRINT)  
ISBN: 978-91-628-9673-7 (PDF)  
<http://hdl.handle.net/2077/41546>  
Correspondence to: [jonny\\_a@telia.com](mailto:jonny_a@telia.com)

Printed in Gothenburg, Sweden, 2016,  
by Ineko AB

Book layout design: Gudni Olafsson

Illustrations: Pontus Andersson

Front cover art: "A brighter future for the  
SL ligament", illustration:  
Jonny Andersson, Pontus Andersson  
and Gudni Olafsson

**TO MY FAMILY**



# I ABSTRACT

Wrist ligament injuries are common after trauma, especially when concomitant dislocated radius fractures are present. The diagnostics of scapholunate (SL), lunotriquetral (LT) and triangular fibrocartilage complex (TFCC) injuries are challenging and most often dependent on magnetic resonance imaging (MRI) examination or invasive arthroscopy. In some circumstances, missed ligament injuries can lead to devastating sequelae, in terms of pain, reduced grip strength, range of motion and subsequent degenerative arthritis. In certain cases and under certain conditions, the choice of treatment for wrist ligament injuries can sometimes be the subject of debate.

An updated review of the diagnostic accuracy, a higher awareness of the injuries among orthopaedic surgeons, a surgically adaptable classification of the injuries and objective and clinically easily adapted diagnostic tools are essential.

This thesis demonstrates that a negative result from MRI cannot rule out the possibility of a clinically relevant injury to the SL ligament, the LT ligament or the TFCC. Clinical provocation wrist tests are of limited diagnostic value. The current gold standard, wrist arthroscopy, remains the preferred diagnostic technique with sufficient conclusive properties when it comes to wrist ligament injuries. Due to low accuracy and high costs, MRI can most often be abandoned, when it comes to wrist liga-

ment injuries. The cost of wrist MRI is three times higher than that of a clinical examination at the Hand Surgery Department, Sahlgrenska University Hospital.

The thesis emphasises the increased diligence required when dealing with wrist trauma in children and adolescents, as a substantial amount of delayed presentation of distal radio-ulnar joint (DRUJ) instability after wrist fractures or sprains in children and adolescents is found. The most striking finding is that several children and adolescents present with DRUJ instability with isolated TFCC tears. The long delay from injury to diagnosis and the severity of the injury in terms of solving the DRUJ instability problem among young people is also interesting and somewhat surprising.

Four distinct SL injury types can be identified and classified. This classification can be used in both open and arthroscopic surgery and in acute, subacute and chronic injuries. An arthroscopically assisted SL capsuloplasty and suture may not be possible in all patients, particularly not when the ligament has been completely avulsed from the bone (in approximately 60% of patients; Andersson-Garcia-Elias Type 1 and 2), leaving no ligament remnant on one side. Most patients with an SL injury will require ligament re-attachment techniques using transosseous sutures, bone anchors, or ligament reconstruction.

Distal radio-ulnar joint instability with an arthroscopically confirmed TFCC injury is associated with a 30% loss of pre-operative peak torque strength in pronation and supination – a measurement technique easily adapted in the clinical pre-operative setting.

**Keywords:** wrist; wrist arthroscopy; carpal ligaments; scapholunate ligament; lunotriquetral ligament; triangular fibrocartilage complex; distal radio-ulnar joint; instability; magnetic resonance imaging; forearm rotation torque; children; adolescents

**ISBN:** 978-91-628-9672-0 (PRINT)

**ISBN:** 978-91-628-9673-7 (PDF)







# I SAMMANFATTNING PÅ SVENSKA

Ledbandsskador i handleden är vanliga efter trauma och särskilt tillsammans med komplicerade handledsfrakturer. Diagnostiken av skador på en del av handledens ligament är speciellt svår. Det gäller inte minst de scapholunära (SL)- och lunotriquetrala (LT)- ledbanden samt triangulära fibrocartilaginära complexet (TFCC). En systematisk klinisk undersökning, magnetkamera (MRI) och framförallt titthålsoperation (diagnostisk artroskopi) krävs för att ställa rätt diagnos. Missade ledbandsskador kan leda till svåra följder i form av smärta, nedsatt rörelseomfång, nedsatt kraft och efterföljande slitageutveckling i brosket (artros). Behandlingsmetoderna av vissa ledbandsskador är också omdebatterade. Behovet av en uppdaterad genomgång av den diagnostiska säkerheten, ökad uppmärksamhet på skaderisken, förbättrad klassifikation av skadorna, samt bättre objektiva undersökningsmetoder är uppenbart.

Denna avhandling visar att uteblivna fynd vid MRI-undersökning inte utesluter förekomst av allvarliga skador på SL-, LT- eller TFCC. Kliniska undersökningsmetoder är också av begränsat diagnostiskt värde. Handledsartroskopi är fortfarande den säkraste metoden för diagnostik av handledens ledbandsskador. MRI med frågeställningen ledbandsskador bör undvikas på grund av den dåliga diagnostiska säkerheten samt på grund av kostnaden. MRI kostar tre gånger mer än en noggrann kli-

nisk undersökning av en erfaren specialist i handkirurgi.

Avhandlingen belyser och betonar också behovet av ökad uppmärksamhet avseende handläggning av handledsskador hos barn och ungdomar. En relativt stor andel av dessa uppvisar kvarstående dorso-ulnar handledssmärta och instabilitet i distala radioulnara leden (DRU) efter handledsfraktur eller stukning. Avhandlingen visar att barn och ungdomar faktiskt kan ha isolerade TFCC-skador och att det tar mycket lång tid att diagnosticera och korrekt åtgärda dessa svårbehandlade DRU-ledsproblem.

Fyra typer av SL-skada kan identifieras och klassificeras. Denna klassifikation kan användas både vid öppen och artroskopisk kirurgi samt för akuta och kroniska skador. Artroskopisk kirurgi av SL-skadan kan enligt denna klassifikation endast användas i ca 40% av fallen, eftersom cirka 60% utgörs av avulsions-skador med eller utan benfragment. Dessa skador (Andersson-Garcia-Elisas Typ 1 och 2) utan ledbandssubstans på bågge sidor kräver öppen återfästning med osteosuturer, benankare eller ledbandsrekonstruktion.

DRU-ledsinstabilitet med artroskopiskt säkerställd TFCC-skada är förenad med ungefär 30% minskning av vridkraften innan operation. Denna mätmetod är användbar och lätt att anpassa till den kliniska verksamheten.



# I LIST OF PAPERS

This thesis is based on the following studies, referred to in the text by their Roman numerals.

- I Andersson JK, Andernord D, Karlsson J, Fridén J  
**Efficacy of MRI and clinical tests in diagnostics of wrist ligament injuries: a systematic review**  
Arthroscopy. 2015, 31: 2014-20
- II Andersson JK, Lindau T, Karlsson J, Fridén J.  
**Distal radio-ulnar joint instability in children and adolescents after wrist trauma**  
J Hand Surg Eur. 2014, 39: 653-61
- III Andersson JK, Garcia-Elias M.  
**Dorsal scapholunate ligament injury: a classification of clinical forms**  
J Hand Surg Eur. 2013, 38: 165-9
- IV Andersson JK, Strömberg J, Karlsson J, Fridén J  
**Patients with triangular fibrocartilage complex injuries and distal radio-ulnar joint instability have reduced rotational torque in the forearm**  
J Hand Surg Eur. E-published, DOI: 10.1177/1753193415622342
- V Andersson JK, Hansson-Olofsson E, Karlsson J, Fridén J.  
**Cost analysis of magnetic resonance imaging and clinical examination in wrist ligament injuries**  
In manuscript

# CONTENTS

ABSTRACT

SAMMANFATTNING PÅ SVENSKA

LIST OF PAPERS

ABBREVIATIONS

DEFINITIONS

<b>1. INTRODUCTION</b>	<b>23</b>
1.1 Wrist ligament injuries – overview and incidence	23
1.2 Anatomy, types of injury and classification	28
1.2.1 Scapholunate ligament (SLL)	28
1.2.2 Lunotriquetral ligament (LTL)	31
1.2.3 Triangular fibrocartilage complex (TFCC)	32
1.2.4 Skeletal and joint anatomy	41
1.2.5 Distal radius fractures in younger non-osteoporotic patients	44
1.2.6 Forearm fractures and distal radius fractures in children	45
1.2.7 Carpal instability and symptoms	48
1.2.8 TFCC injuries – DRUJ instability and symptoms	50
1.2.9 Complications after wrist ligament injuries	52
1.2.10 Perilunar carpal dislocations and their complications	54
1.3 Diagnosis of injuries	57
1.3.1 Pathomechanisms of injuries	57
1.3.2 Clinical examination	58
1.3.3 Radiological examination	64
1.4 Wrist arthroscopy	74
1.4.1 History	74
1.4.2 Indications, contra-indications and complications	74

1.4.3 Equipment, portals and settings	76
1.4.4 Injury to the scapholunate and lunotriquetral ligaments	83
1.4.5 Injury to the triangular fibrocartilage complex	83
1.5 Treatment of wrist ligament injuries and its complications	85
1.5.1 Non-surgical treatment	85
1.5.2 Surgical treatment	86
1.5.3 Results and prognosis after surgical treatment	102
<b>2 AIMS</b>	<b>109</b>
2.1 Study I	109
2.2 Study II	109
2.3 Study III	109
2.4 Study IV	109
2.5 Study V	109
<b>3 PATIENTS AND METHODS</b>	<b>113</b>
<b>4 SUMMARY OF PAPERS</b>	<b>125</b>
<b>5 LIMITATIONS</b>	<b>145</b>
<b>6 DISCUSSION</b>	<b>149</b>
<b>7 CONCLUSIONS</b>	<b>161</b>
<b>8 FUTURE PERSPECTIVES</b>	<b>165</b>
<b>ACKNOWLEDGEMENTS</b>	<b>169</b>
<b>REFERENCES</b>	<b>173</b>
<b>APPENDIX</b>	<b>195</b>
<b>PAPERS I-V</b>	



# ABBREVIATIONS

<b>4CF</b>	Four-corner fusion
<b>APL</b>	Abductor pollicis longus
<b>CI</b>	Carpal instability
<b>CID</b>	Carpal instability dissociative
<b>CIND</b>	Carpal instability non-dissociative
<b>CT</b>	Computed tomography
<b>DIC</b>	Dorsal intercarpal ligament
<b>DISI</b>	Dorsal intercalated segment instability
<b>DRUJ</b>	Distal radio-ulnar joint
<b>ECRL/B</b>	Extensor carpi radialis longus/brevis
<b>ECU</b>	Extensor carpi ulnaris
<b>EDC</b>	Extensor digitorum communis
<b>EDQ</b>	Extensor digiti quinti
<b>EIP</b>	Extensor indicis proprius
<b>EPB</b>	Extensor pollicis brevis
<b>EPL</b>	Extensor pollicis longus
<b>FCR</b>	Flexor carpi radialis
<b>FCU</b>	Flexor carpi ulnaris
<b>LRL</b>	Long radio-lunate ligament
<b>LT</b>	Lunotriquetral
<b>LTL</b>	Lunotriquetral ligament
<b>MC</b>	Midcarpal joint
<b>MRA</b>	Magnetic resonance arthrography
<b>MRI</b>	Magnetic resonance imaging
<b>OA</b>	Osteoarthritis
<b>PRC</b>	Proximal row carpectomy
<b>RC</b>	Radiocarpal joint
<b>RCPI</b>	Resurfacing Capitate Pyrocarbon Implant

<b>RCT</b>	Randomised Controlled Trial
<b>ROM</b>	Range of motion
<b>RSC</b>	Radio-scapho-capitate ligament
<b>RSL</b>	Radio-scapho-lunate ligament (ligament of Testut)
<b>RTq</b>	Radiotriquetral ligament
<b>SRL</b>	Short radio-lunate ligament
<b>SL</b>	Scapholunate
<b>SLL</b>	Scapholunate ligament
<b>SLAC</b>	Scapholunate advanced collapse
<b>STT</b>	Scapho-trapezio-trapezoid ligament/joint
<b>T</b>	Tesla
<b>TFCC</b>	Triangular fibrocartilage complex
<b>UC</b>	Ulnocarpal
<b>UL</b>	Ulnolunate
<b>UT</b>	Ulnotriquetral
<b>VISI</b>	Volar intercalated segment instability

---







# I DEFINITIONS

<b>Accuracy</b>	The closeness of a measured value to a standard or known true value
<b>Bias</b>	A systematic error or deviation in results from the truth
<b>Carpal instability dissociative</b>	A major malfunction and instability of a joint between bones of the same carpal row (SL, LT)
<b>Carpal instability non-dissociative</b>	Midcarpal instability
<b>Carpus</b>	Anatomical assembly with the carpal bones – scaphoid, lunate, triquetrum, pisiform, trapezium, trapezoid, capitate and the hamate and their intermediate joints – connecting the hand to the forearm
<b>Case series</b>	An uncontrolled observational study with no control group
<b>Confidence interval</b>	A range of values within which it is possible to be sure that a whole population's true value lies
<b>Dynamic instability</b>	No permanent carpal malalignment exists – only under radiological stress and loading views a gap between carpal bones and/or a malalignment
<b>Extrinsic ligament</b>	Radiocarpal and ulnocarpal ligaments, located between the radius/ulna and carpus
<b>Heterogeneity</b>	Differences between studies. Studies not undertaken in the same way, or not according to the same experimental protocol
<b>Intrinsic ligament</b>	Intercarpal ligaments, located between the bones in the carpus
<b>ICC</b>	The intra- and inter-rater reliability and test/re-test of the measurements can be determined with the so-called intraclass correlation coefficient (ICC). The ICC is the ratio of the between-subject variability over the between-subject variability plus the within-subject variability
<b>Incidence</b>	The occurrence of new cases of disease or injury in a population within a specified period of time

<b>Instability</b>	The patient's symptoms of laxity (looseness)
<b>Inter-rater reliability</b>	The degree of stability shown when a measurement is repeated under identical conditions by different raters
<b>Intra-rater reliability</b>	The degree of stability shown when a measurement is repeated under identical conditions by the same rater
<b>Laxity</b>	Looseness. Clinical appearance of instability
<b>Level of evidence</b>	A hierarchical system grading different studies based on methodology in terms of quality
<b>Meta-analysis</b>	A systematic review using quantitative methods to summarise results
<b>Negative predictive value</b>	The probability that subjects with a negative investigation truly do not have the disease or injury. For example, the probability of an intact wrist ligament given a negative investigation
<b>Newtonmetre (Nm)</b>	A unit of torque, expressed as the energy expended, or work done, by a force of 1 Newton (N), acting through a distance of 1 metre (m)
<b>P-value</b>	The probability of obtaining a result equal to or more extreme than what was observed
<b>Positive predictive value</b>	The probability that subjects with a positive investigation truly have the disease or injury
<b>Prevalence</b>	The proportion of a population found to have a disease or injury at a specific point in time (point prevalence) or at some time during a given period (period prevalence)
<b>Randomised clinical trial</b>	Level 1 evidence experimental trial, where patients are randomly assigned to different treatment arms and followed prospectively
<b>Scapholunate advanced collapse</b>	Wrist OA, following a specific pattern after SLL injury
<b>Sensitivity</b>	True positive rate. Measures the proportion of positives that are correctly identified as such
<b>Specificity</b>	True negative rate. Measures the proportion of negatives that are correctly identified as such
<b>Static instability</b>	Permanently altered carpal alignment and kinematics, with no healing capacity or chance of reduction

**Systematic review**

A literature study in which an explicit and reproducible methodology is used to answer a specific question by analysis of evidence

**Ulnar impaction syndrome**

The impaction of the ulnar head against the TFCC and the ulnar part of the carpus, resulting in progressive degeneration of those structures and dorso-ulnar pain.

---

**”Εκπαιδεύοντας  
το μυαλό, χωρίς  
να εκπαιδεύσουμε  
την καρδιά, δεν  
είναι καθόλου  
εκπαίδευση”**

*Άριστοτέλης 384 - 322 BC*  
Γεννημένος στη Χαλκιδική

**“Educating the mind  
without educating the  
heart is no education  
at all”**

*Aristotle 384 - 322 BC*  
Born in Chalkidiki, Greece

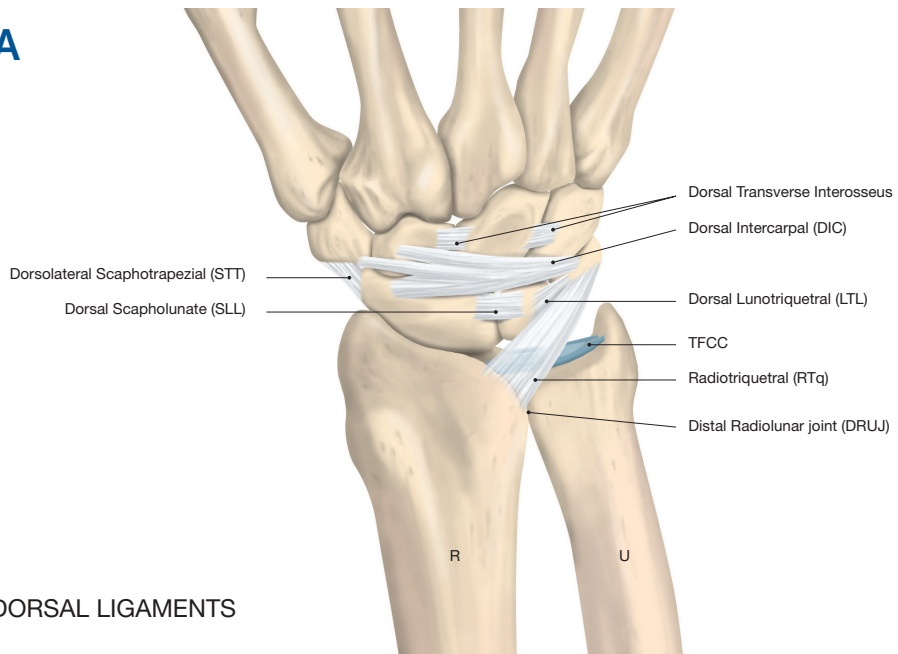
# INTRODUCTION

## 1.1 Wrist ligament injuries – overview and incidence

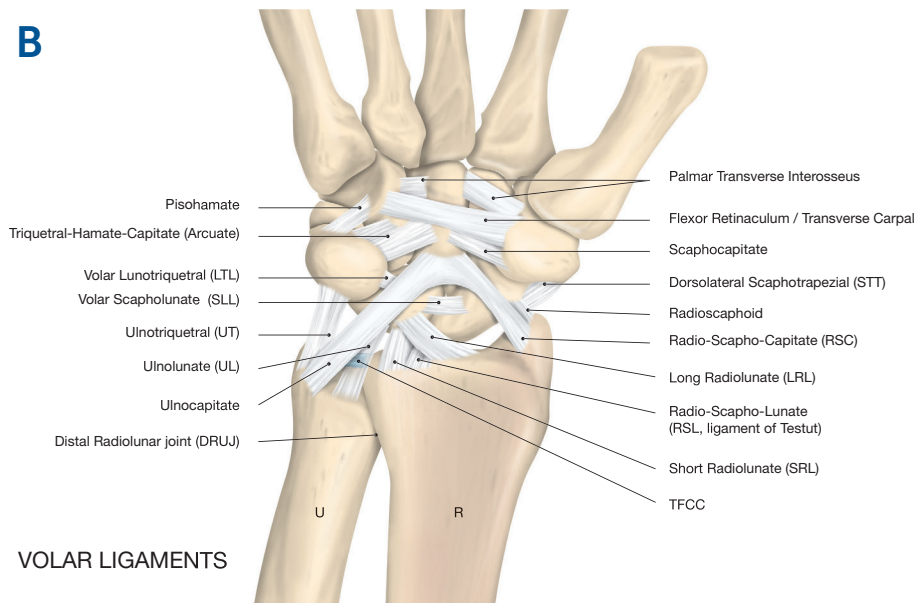
There are 20 anatomically distinct and in most persons consistently present ligaments in the wrist, all contributing to the integrity and stability of the radiocarpal (RC), midcarpal (MC) and distal radio-ulnar joints (DRUJ).

The most important of these are the scapholunate ligament (SLL), the lunotriquetral ligament (LTL) and the triangular fibrocartilage complex (TFCC). These three ligaments and their injuries are the focus of this thesis. The SLL, LTL and TFCC are the primary main stabilisers of the wrist and also the most studied of the wrist ligaments.

**A**



**B**



Figures 1. Schematic representation of the most consistently present dorsal (A) and volar ligaments (B) in the wrist (R= radius, U= ulna).

Copyright © Jonny Andersson



Wrist ligament injuries, especially triangular fibrocartilage complex tears (TFCC), scapholunate (SL) ligament tears and lunotriquetral (LT) ligament tears, are commonly observed after wrist trauma, particularly in asso-

ciation with dislocated distal radius fractures. More than 40% of dislocated distal radius fractures are in fact associated with injury to the triangular fibrocartilage complex (TFCC) [16, 24, 78, 92, 100, 138, 153, 168, 183].

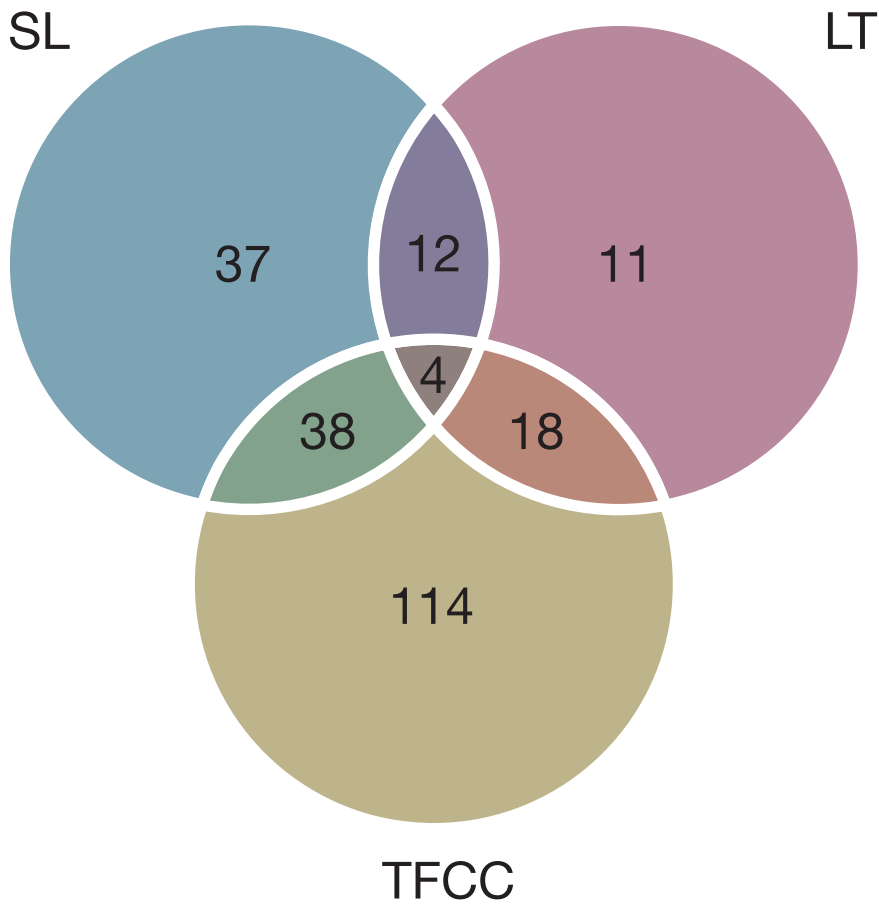


Figure 2. Combination of arthroscopically diagnosed injuries to the intrinsic ligaments (SL, LT) and the TFCC in 316 patients, with concomitant distal radius fracture; 234/316 (74%) had some ligament injury. A summary of the findings in the following five studies with sufficient data; Fontes et al., 1992 [78], Geissler et al., 1996 [92], Lindau et al., 1997 [138], Richards et al., 1997 [183], Araf et al., 2011 [24] is shown in this Venn diagram.

The frequency of arthroscopically diagnosed wrist ligament injuries (total and partial), associated with distal

radius fractures, reported in different studies is displayed in Table 1 below.

**Table 1.** The frequency of concomitant SL, LT, and TFCC injuries in patients with distal radius fractures.

STUDY	SL (%)	LT (%)	TFCC (%)
Hanker 1991 [100]	8%	12%	61%
Fontes et al., 1992 [78]	40%	17%	70%
Geissler et al., 1996 [92]	31%	15%	43%
Lindau et al., 1997 [138]	54%	16%	78%
Richards et al., 1997 [183]	18%	8%	40%
Mehta et al., 2000 [153]	85%	61%	58%
Ogawa et al., 2013 [168]	55%	35%	59%
Araf et al., 2014 [24]	37%	7%	77%
<b>Mean (%) value</b>	<b>41%</b>	<b>21%</b>	<b>61%</b>

Mehta et al. [153] differ pronouncedly from the other studies, by including SL and LT injuries stages I-II, according to Geissler's classification, i.e. very small and partial injuries. The difference in frequency in the other studies is mainly due to differences in age, type of trauma, type of distal radius fracture and the proportion of acute traumatic versus degenerative injuries.

Wrist ligament injuries are often not discovered initially because of a lack of knowledge and experience on the part of the examiner, as well as difficulties in the diagnostic procedure. The clinical diagnosis, including provocation and stability tests, is challenging and the radiological examinations

have still not shown sufficient sensitivity, specificity and accuracy [111]. In the acute stage, the diagnosis can be even more difficult, due to pain and an inability to perform provocation tests. Most of the patients with suspected carpal ligament injuries after an accident are not immediately referred to a hand surgeon for further diagnostic procedures [23]. This occurs in spite of the fact that many researchers [70, 88, 89, 217] emphasise the great importance of establishing an early diagnosis to enable the direct repair of SLL and LTL injuries within a few weeks after trauma.

The most frequent complaint after distal radius fractures is ulnar-sided wrist pain [53], present in approxima-

tely 20% of the patients [82]. Residual clinical symptoms after a distal radius fracture are common and cause significant impairment in approximately 10% of all patients, regardless of the treatment given [1, 124].

Little is still known in terms of post-traumatic distal radius fracture-related problems in younger non-osteoporotic patients [124] and children [31, 221]. Non-osteoporotic patients often suffer from more severe trauma, causing intra-articular fractures of the radius and associated ligament injuries. According to Hanker [100] and Lindau et al. [138], approximately 90% of dislocated distal radius fractures in young non-osteoporotic individuals are associated with a partial or total wrist ligament injury, the most common being TFCC rupture. Traumatic lesions of the ulnar-sided portion of the TFCC can be critical to the stability of the distal radio-ulnar joint (DRUJ) and to forearm function, as these structures, particularly the foveal insertion, are crucial for DRUJ stability and unrestricted forearm rotation [102, 213].

Isolated injuries to the TFCC without a fracture can occur after a twisting or rotation injury [6]. In patients with post-traumatic wrist pain, but normal standard radiographs, Adolfsson showed that approximately 40% had injuries to the TFCC [7]. Bergh et al. [40] showed that four out of five patients with normal standard radiographs, had pathological findings on MRI. Isolated SLL and LTL injuries also occur but slightly lesser frequently.

## HOW COMMON ARE WRIST LIGAMENT INJURIES?

If the wrist is radially deviated at the moment of dorsal extension impact, a scaphoid waist fracture is likely to occur. If the wrist is ulnarly inclined, an isolated SLL tear occurs more frequently. However, in some patients, associated co-existing injuries also occur. Complete SLL tears can be expected in almost 25% of the patients with a concomitant scaphoid waist fracture, according to Jørgsholm et al. [118]. In general, approximately 5% of “wrist sprains” involve an SL ligament tear [49, 116].

The mechanism of LT injury is generally thought to be multifactorial. In most cases, an isolated LTL tear is the result of a fall backwards onto an outstretched hand with the wrist in radial deviation, or it can be the result of a forced volar flexion [234]. The incidence of isolated LT ligament injury in wrist sprains is not known. The point prevalence of wrist ligament injuries in total is also not known.

According to Adolfsson and Povlsen, arthroscopy should be considered in patients with pronounced pain and dysfunction, such as pain, swelling, instability and reduced strength, which show no sign of recovery a few weeks after a significant wrist trauma [8].

Diagnostic arthroscopy should probably be performed within a few weeks after the index trauma in order to enable the direct

repair of potential ligament injuries within a reasonable time. Overlooked ligament injuries can subsequently result in persistent pain, instability, reduced grip strength and range of motion (ROM), as well as secondary degenerative arthritis [49, 234, 241]. The diagnosis of TFCC, SL and LT in-

juries is difficult and challenging using non-invasive methods and it is a fact that orthopaedists and hand surgeons still do not know the most optimal treatment in many patients with wrist ligament injuries.

## 1.2 Anatomy, types of injury and classification

### 1.2.1 Scapholunate ligament (SLL)

The scapholunate (SL) ligament is the most commonly injured intracarpal ligament [127]. The scapholunate ligament (SLL) is C-shaped and has three structurally distinct parts; volar, membranous and dorsal [35]. The dorsal part of the SLL is the strongest and the primary stabiliser of the SL joint and can resist forces of up to 260 N [88]. The avascular proximal membranous portion does not provide any significant laxity restraint (63 N), while the volar part of the SLL (118 N) plays an important role in terms of rotational stability [56, 57, 121]. The dorsal region of the SLL measures 2-3 mm in thickness and varies from 2-5 mm in length.

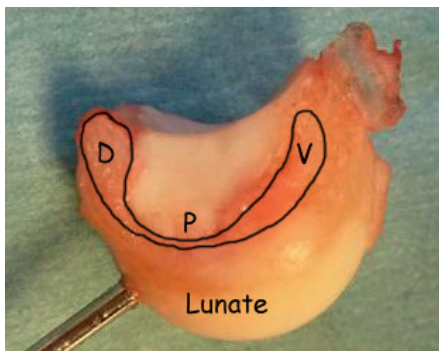


Figure 3. The SL ligament is C-shaped. Its dorsal (D) component is the strongest. Copyright © Jonny Andersson

The vascular supply to the scaphoid and SLL is delicate. The main vascular contribution comes from the radial artery. Extraosseous vessels enter the dorsal ridge of the scaphoid and supply two thirds of the bone. There is some collateral circulation from the anterior intraosseous artery [93]. The vessels supplying the proximal pole also enter through the dorsal ridge of the scaphoid and have an intraosseous retrograde vulnerable blood supply. It also appears that the radio-scapho-lunate ligament (RSL) provides a vascular supply directed at the SLL complex [39, 110].

The radial nerve, through the posterior interosseous nerve (PIN) and the superficial sensory branch, is a major contributor of innervation to the wrist joint. The PIN innervates the dorsal wrist capsule, the dorsal part of the SLL and LTL, as well as the dorsal radiocarpal and intercarpal ligament (DIC) [97].

There is a gradient of SL injury severity, when it is discovered. It ranges from occult, dynamic SL dissociation (gap), followed by carpal collapse with dorsal intercalated SL instability, final-

ly ending up in the disabling arthritic (scapholunate advanced collapse = SLAC) wrist [127]. It often takes three to 12 months after trauma until dynamic instability develops and SL dissociation is noted radiologically (SL angle  $> 60^{\circ}$  and SL gap  $> 3$  mm) on clenched-fist or ulnar-deviation radiographs. For this development and progression to occur, an additional tear or gradual, continuous elongation of the secondary stabilisers of the SL ligament is needed [202, 203, 204]. The SL ligament is an intrinsic ligament (e.g. located between carpal bones alone) and the major stabiliser of the scaphoid and lunate, while the RSC (radio-scapho-capitate ligament) and LRL and SRL (long and short radio-lunate ligaments) are extrinsic ligaments (e.g. located between carpal bones and the radius and/or ulna) and important secondary restraints [202]. These and other secondary stabilisers, which can be examined during wrist arthroscopy, are the STT (scapho-trapezio-trapezoid ligament) and DIC (dorsal intercarpal ligament), as visualised in Figure 1 A and B.

A complete tear of the dorsal component of the SL ligament and an additional tear or progressive attenuation of one or more secondary stabilisers will allow the scaphoid to rotate into flexion, while the lunate follows the triquetrum into dorsal extension. With time, this will always cause carpal instability (CI), carpal collapse, dorsal

intercalated segment instability (DISI) (Figure 4) and scapholunate advanced collapse (SLAC) wrist [241] (Figure 5 and Table 2).

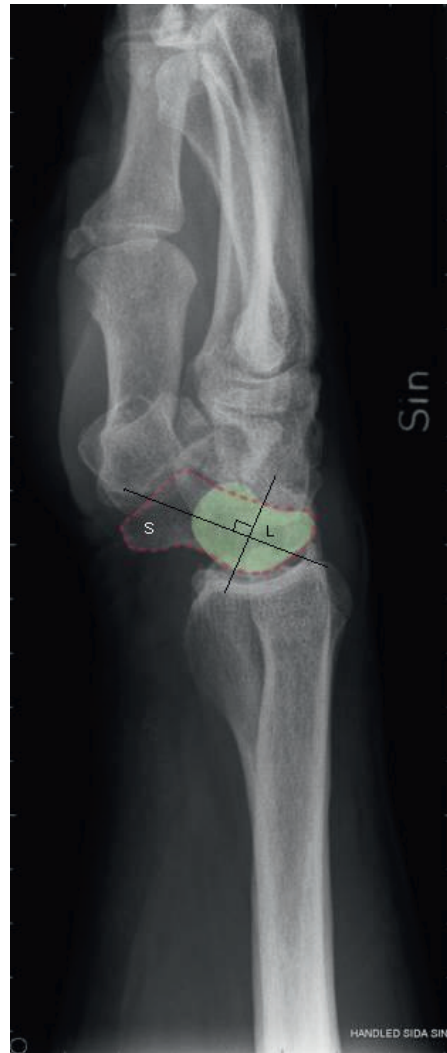


Figure 4. DISI – dorsal intercalated segment instability with an SL angle of approximately  $90^{\circ}$ . S =scaphoid. L =lunate (green).  
Illustration: Dr Per Fredriksson

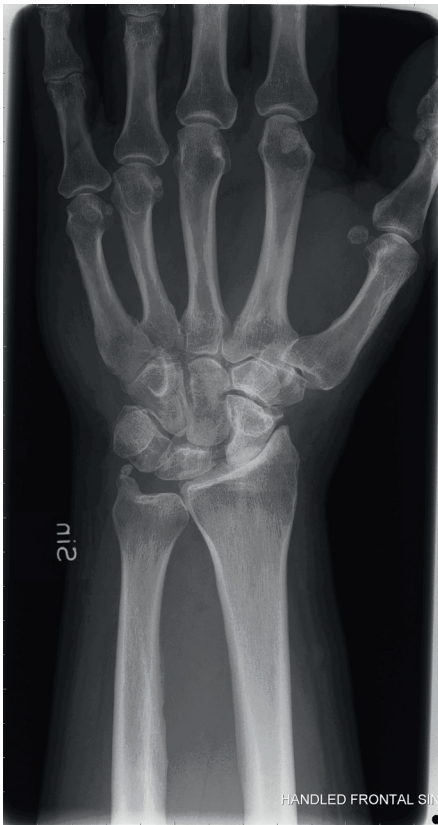

Figure 5. Scapholunate advanced collapse after an SL injury, with subsequent arthritic changes at the RC and MC joints (SLAC III).

Approximately 5% of all wrist sprains have an associated SL tear [49, 116]. SLL injuries are often associated with distal radius fracture (41% of the cases on average – see Table 1), particularly fractures of the radial styloid, the so-called Chauffeur’s fracture [104, 180].

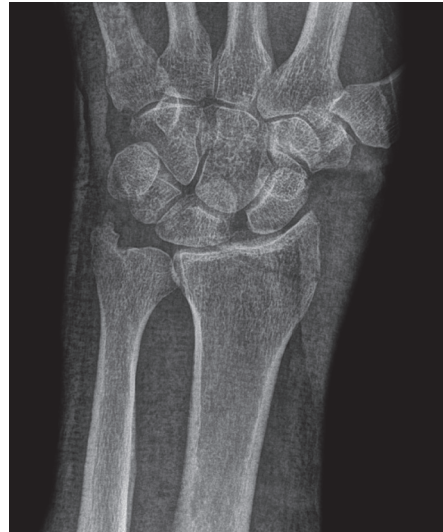

Figure 6. Chauffeur’s fracture with concomitant SL dissociation.

**Table 2.** Stages of scapholunate advanced collapse – SLAC wrist (after Watson and Ballet).

<b>STAGE I</b>	Arthritic changes and osteophyte formation at the radial styloid
<b>STAGE II</b>	Arthritis at the radioscaphoid joint
<b>STAGE III</b>	Arthritic involvement of the midcarpal joint (capitolunate and scaphocapitate joint)
<b>STAGE IV</b>	Arthritis involving all but the radiolunate joint

Radial styloid fractures and scapholunate disruption are common concomitant injuries. Mudgal and Hastings [161] retrospectively reviewed 11 patients with distal radius fractures and scapholunate disruption. In their study, the radial styloid fracture was displaced in six patients and non-displaced in three; they all had an SLL injury. The authors described how, in radial deviation and compression of the wrist, an impression fracture of the radial styloid occurs, followed by shearing of the scaphoid off the lunate, completing the SLL tear.

An SL injury can be classified as partial or total and the degree of instability is arthroscopically classified according to Geissler; this is described in detail in the chapter on wrist arthroscopy (1.4.2) in Table 7 [92].

### 1.2.2 Lunotriquetral ligament (LTL)

The lunotriquetral ligament (LTL) is V-shaped and the volar part is the strongest region of the ligament. The volar part of the LTL is able to resist forces of up to 301 N and the dorsal part 121 N [89]. The volar region of the LTL measures 4 mm in thickness.




Figure 7. The LT ligament is V-shaped. Its volar (V) part is the strongest.  
Copyright © Jonny Andersson

The vascular supply to the LTL is not described in detail in the literature, but the ligament receives its main blood supply from the volar capsule and volar-ulnar ligaments.

The median nerve, through the anterior interosseous nerve (AIN), contributes to the innervation of the central two-thirds of the volar wrist capsule (including the volar part of the LTL) and the RSL ligament, which in turn supplies the innervation to the volar aspect of the SLL [97].

The most important secondary stabiliser of the LTL is the RTq (radiotriquetral ligament). The LTL is an intrinsic ligament and is composed of three parts; the dorsal and volar ligament parts, of which the volar ligament part is the strongest [234], and a wedge-shaped proximal membrane. The different parts of the LTL ensure the stable arrangement of the LT joint itself. The RTq and other extrinsic ligaments connect the proximal carpus to the radius, ulna and mid-carpus and prevent the proximal row of the carpus from indirectly passively supinating or pronating beyond the normal range. Moreover, the triquetrum and its ligaments are regarded as the key elements in providing proprioceptive information for neuromuscular dynamic wrist stabilisation [95].

Compared with SLL and TFCC injuries, LTL injuries are less frequently associated with dislocated distal radius fractures (21% of the cases on avera-

ge – see Table 1) and some of them are actually asymptomatic. LTL injury is, however, often associated with TFCC injuries, particularly the degenerative ones, and with ulnar impaction syndrome (positive ulnar variance) (see Chapter 1.2.4 Skeletal and joint anatomy, Figure 12 and Table 5). The final stage of LT injury is also carpal collapse with volar intercalated segment instability (VISI) and finally degenerative arthritis.

An LT injury, which can be classified as partial or total, and the degree of instability are arthroscopically classified according to Geissler; this is described in detail in the chapter on wrist arthroscopy (1.4.2) in Table 7 [92].

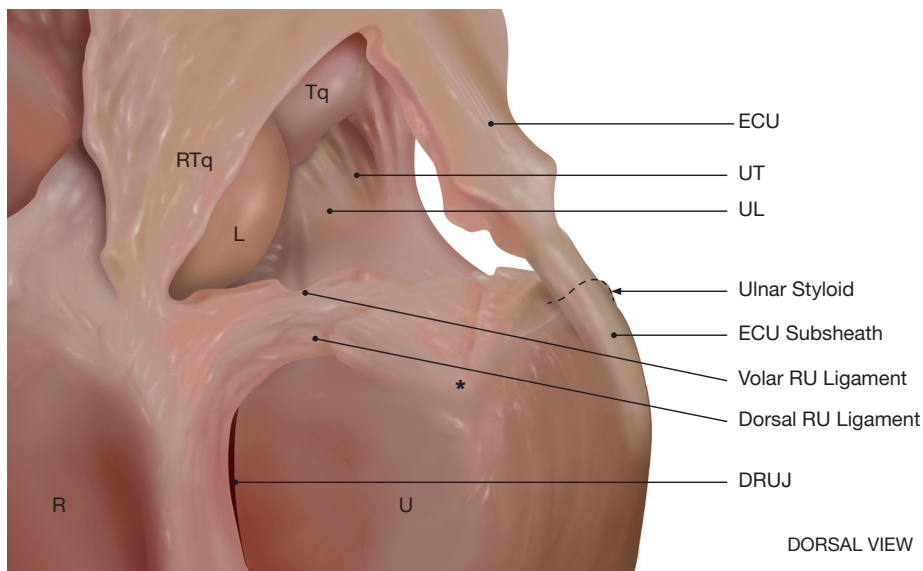
### **1.2.3 Triangular fibrocartilage complex (TFCC)**

The triangular fibrocartilage complex (TFCC) with its ulnar foveal attachment is the primary stabiliser of the distal radio-ulnar joint (DRUJ). The TFCC consists of a thin avascular central disc (normally only 1-2 mm thick) and the dorsal and volar radio-ulnar (RU) ligaments, localised and acting together with the ulnocarpal (UC) ligaments (ulnolunate – UL and ulnotriquetral – UL) and the extensor carpi ulnaris (ECU) subsheath. The ECU subsheath is a specific tendon sheath fixed to the distal ulna and surrounding the extensor carpi ulnaris exclusively. The RU ligaments act as stabilisers of the distal radio-ulnar joint (DRUJ) [213, 214]. Moreover, the dorsal joint capsule is tightened by the ECU



tendon sheath. The TFCC is composed of the “distal component”, formed by the ulnocarpal ligaments and the distal hammock structure, and of the

“proximal component”, which originates from the ulnar fovea and the base of the styloid [166].



Figures 8. TFCC anatomy. Palmar and dorsal radio-ulnar (RU) ligaments, ulnocarpal ligaments (UL, UT) are displayed. (ECU =extensor carpi ulnaris, DRUJ =distal radio-ulnar joint, R =radius, U =ulna, L =lunate, Tq =triquetrum, RTq= radiotriquetral ligament, \* ulnar fovea) Copyright © Jonny Andersson

The TFCC arises from the ulnar aspect of the radial lunate fossa. It covers and spans the distal part of the DRUJ [175]. The dorsal and palmar RU ligaments encase and surround the central avascular articular disc. As part of the TFCC, these fibres originate from the medial border of the distal radius and insert on the ulna at two separate and distinct sites. The radio-ulnar ligaments thus consist of both deep and superficial fibres. The deep fibres insert into the fovea [102, 122] and the superficial fibres insert into the base of the ulnar styloid process. Moreover, these ligaments have a spiral anat-

omical configuration and combined centric and epicentric insertions into the fovea and the ulnar styloid. Some resemblance to the anterior cruciate ligament in the knee is thus obvious [207]. A continuous shift in the tension of different parts of the ligaments takes place during pronation and supination [96]. As a centre of forearm rotation, the TFCC plays a key role in stabilisation, rotation, translation and loading transmission to the wrist and acts as an essential pivot point [194, 230].

Three main arterial branches supply

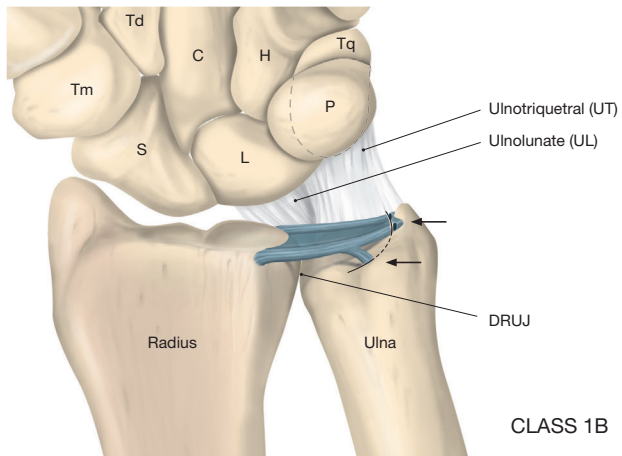
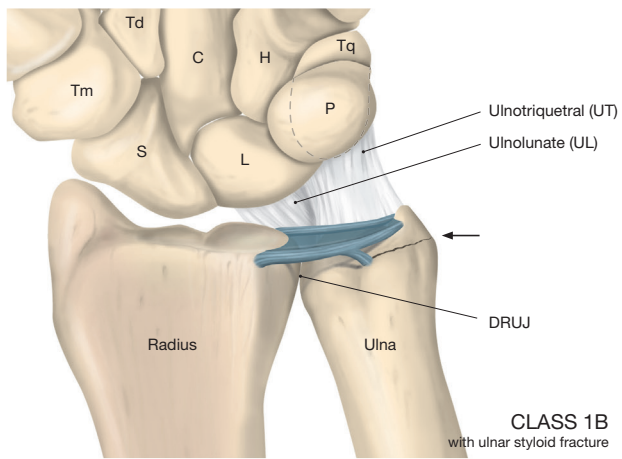
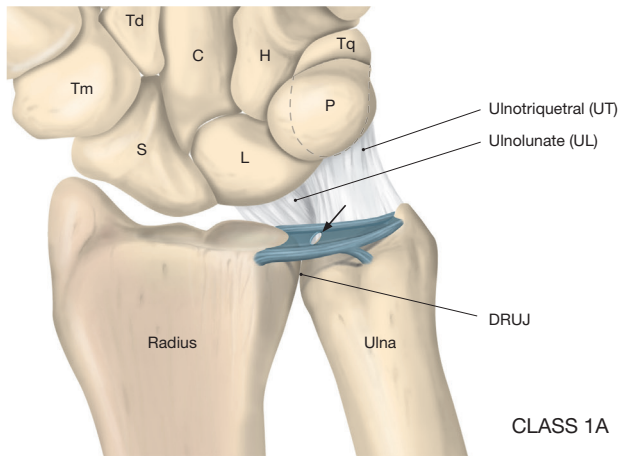
the TFCC: 1) the ulnar artery, 2) the palmar branch of the anterior interosseous artery and 3) the dorsal branch of the anterior interosseous artery. The dorsal branch of the anterior interosseous artery runs on the dorsal side, while the palmar branch and the ulnar artery run on the palmar side. These three arteries supply blood to the periphery of the TFCC in a radial fashion. Histological sections demonstrate that the vessels penetrate the peripheral 15-20% of the disc, while the central portion and radial attachment are avascular and consist mainly of chondrocytes in a fibrocartilaginous matrix. Tears of the TFCC in its vascular zone can therefore heal if repaired, while those in the central avascular zone cannot [223].

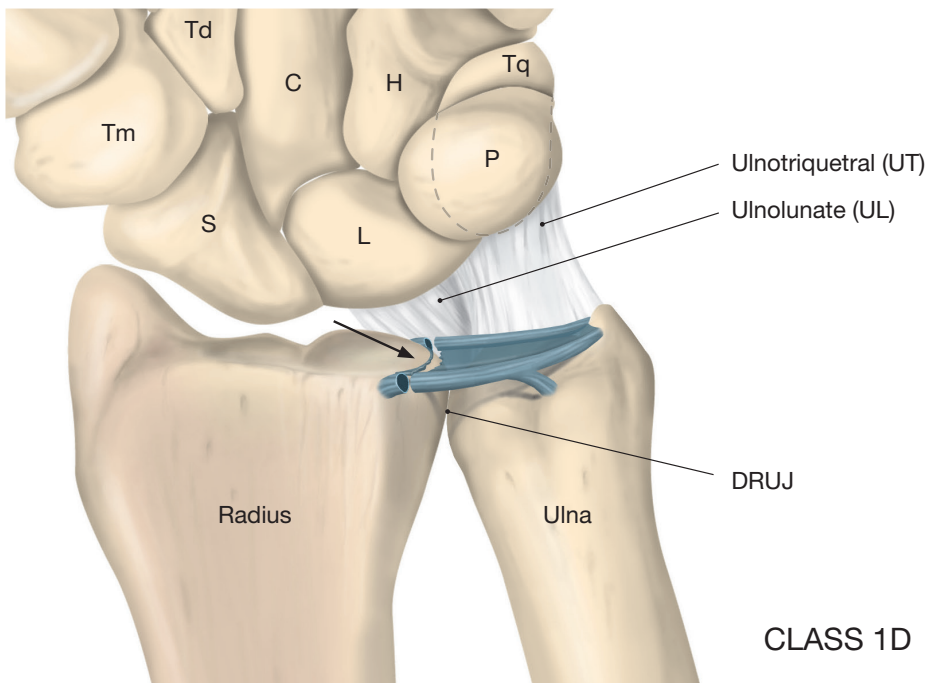
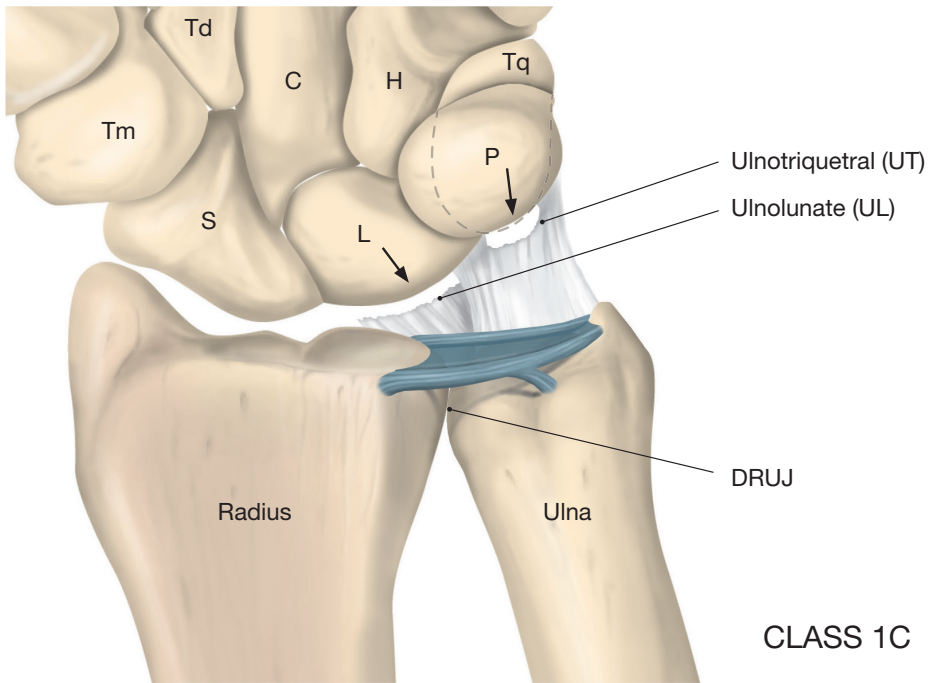
The ulnar nerve is the major contributor to the innervation of the TFCC.

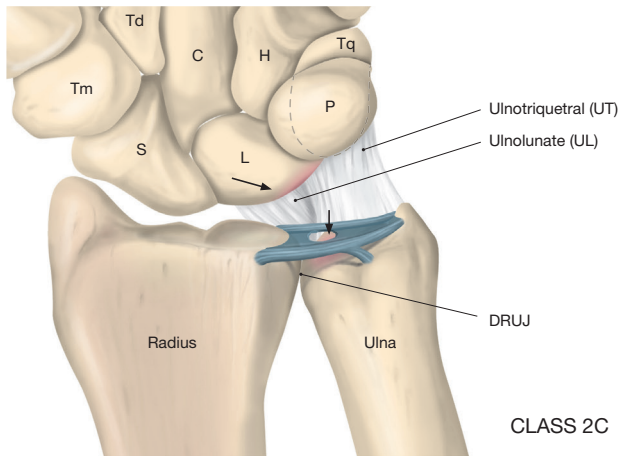
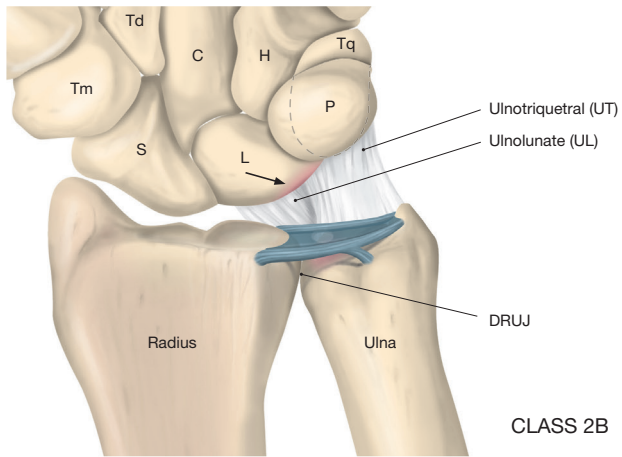
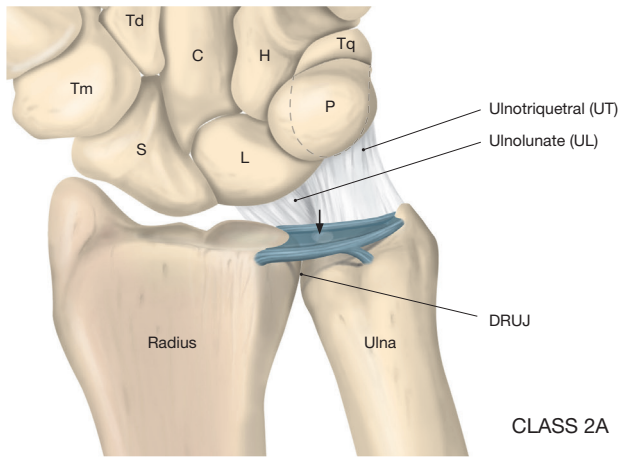
TFCC injuries are classified according to Palmer [173] and Atzei [26, 27]. Many different modifications of the Palmer classification have been presented during the last few years [74, 120]. The Palmer classification does not cover all cases of peripheral TFCC tears [237]. Estrella et al. [74] observed several dorsal tears of the TFCC, which cannot be categorised using the Palmer classification. For example, Henry stated that Class 1B injuries are broadly applied to lesions, irrespective of their origin and association with DRUJ instability [105]. However, the Palmer classification, sometimes in conjunction with the Atzei classification, is still the most used.

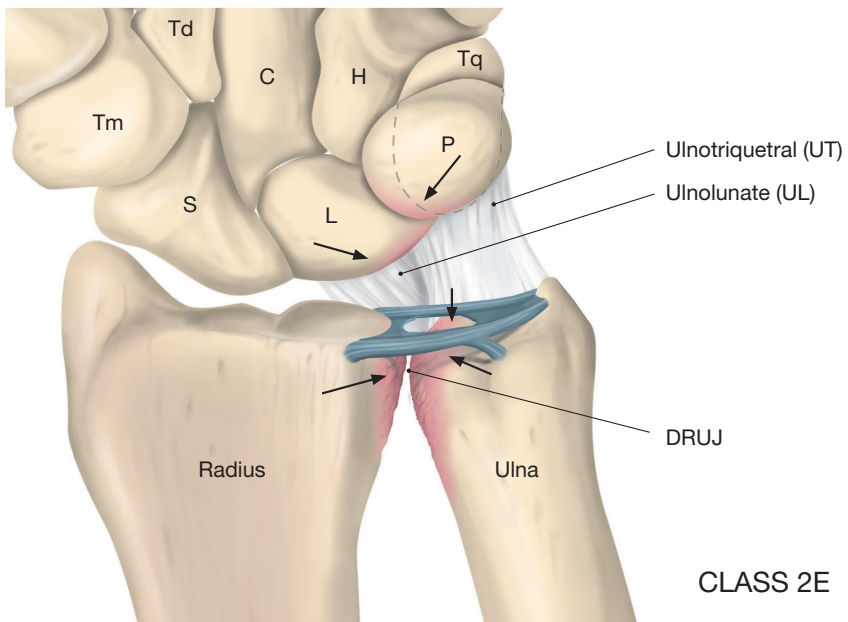
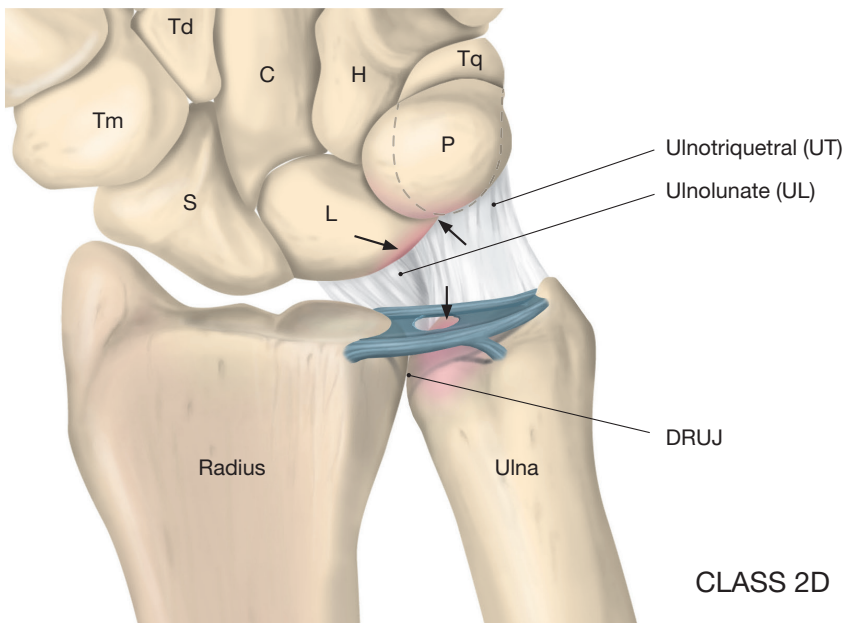
**Table 3.** Palmer's classification of TFCC injuries.

<b>Traumatic injuries</b>		
1 A	Central horizontal tear	<i>Common injury</i>
1 B	Ulnar avulsion. Avulsion from the foveal insertion at the distal ulna. => DRUJ instability	<i>Common injury</i>
1 C	Volar distal avulsion. Rupture of the ulnocarpal ligaments (UL/UT) => Ulnocarpal instability	<i>Uncommon injury</i>
1 D	Radial avulsion from the radius with/without sigmoid notch fracture => Possible DRUJ instability	<i>Uncommon injury</i>
<b>Degenerative injuries</b>		
2 A	Attenuation of the horizontal portion without perforation	
2 B	Attenuation of the horizontal portion without perforation + chondral injury of the lunate and/or ulnar head	
2 C	Progression of the degenerative attenuation => oval perforation of the TFCC in the avascular portion	
2 D	Progression of the degenerative process => rupture of the LT and further chondral injury of the ulnar head and the lunate	
2 E	Ulnocarpal arthritis + DRUJ arthritis	









Figures 9. Schematic description of Palmer's classification of TFCC injuries. (DRUJ= distal radio –ulnar joint, Tm= trapezium, Td= trapezoid, C= capitate, H= hamate, S= scaphoid, L= lunate, Tq= triquetrum, P= pisiform. Arrows show the typical injuries in each class.)  
 Copyright © Jonny Andersson

**Table 4.** Types, number and frequency of traumatic TFCC tears. A summary of five studies (171 patients) with sufficient data.

STUDY	TFCC 1 A	TFCC 1 B	TFCC 1 C	TFCC 1 D	TFCC 2 A-E DEGENERATIVE
Adolfsson et al., 1994 [7] – No concomitant distal radius fracture	13	11	3	4	32
Geissler et al., 1996 [92]	6	13	0	7	-
Lindau et al., 1997 [138]	13	17	5	17	-
Ogawa et al., 2013 [168]	27	2	0	5	15
Araf et al., 2014 [24]	4	8	14	2	-
Acute TFCC-injuries (n=171)	63 37%	51 30%	22 13%	35 20%	

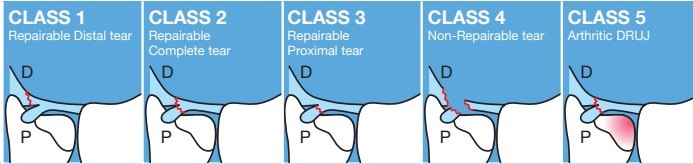
Palmer Class 1 injuries are traumatic. Class 1A lesion describes a central tear through the horizontal portion of the TFCC. A traumatic ulnar avulsion of the TFCC from its insertion at the distal ulna is referred to as a Class 1B lesion. These injuries are related to lesions of the ulnar styloid and DRUJ instability [213, 214]. Palmer classified distal volar avulsions of the TFCC as Class 1C lesions, such as ruptured ulnolunate (UL) and/or ulnotriquetral (UT) ligaments, which lead to ulnar carpal instability. Finally, Class 1D lesions represent radial avulsion of the TFCC with or without sigmoid notch fracture [173]. Palmer Class 2 injuries are degenerative. Class 2A represents the attenuation of the horizontal portion of the TFCC without perforation and the lesion may be located distally, proximally or both. Class 2B lesions are similar to 2A, with additional

chondral injury of the lunate or ulnar head or both. The progression of the degenerative attenuation results in the perforation of the TFCC, which is classified as a Class 2C lesion. These lesions usually occur in the avascular portion of the TFCC and tend to have an oval appearance. Class 2D lesions describe a further increment in the degenerative process with a rupture of the lunotriquetral ligament (LT) and chondral injury of the ulnar head and the lunate. A deterioration in Class 2D lesions coupled with ulnocarpal arthritis and possible DRUJ arthritis represents Class 2E lesions [173].

Central traumatic and degenerative TFCC injury is generally the most common type of injury. Ogawa et al. found 27 Class 1A injuries and 15 degenerative injuries among 49 cases with TFCC pathology [168]. Adolfsson

showed that 32 (52.5%) of the 61 TFCC injuries found in his series with severe wrist sprains were degenerative [7]. Many traumatic and degenerative injuries are combined. Araf et al. had

six combined traumatic TFCC injuries (1A+1B etc) in their series of 23 TFCC injuries [24], while Lindau et al. reported 16 combined injuries in a total of 39 TFCC injuries [138].



	<b>CLASS 1</b> Repairable Distal tear	<b>CLASS 2</b> Repairable Complete tear	<b>CLASS 3</b> Repairable Proximal tear	<b>CLASS 4</b> Non-Repairable tear	<b>CLASS 5</b> Arthritic DRUJ
<b>Clinical DRUJ Instability</b>	None/slight	Mild/severe	Mild/severe	Severe	Mild/severe
<b>Appearance of TFCC distal component</b> (RC arthroscopy)	Torn	Torn	Intact	Torn	Variable
<b>Status of TFCC proximal component</b> (hook test/ DRUJ arthroscopy)	Intact	Torn	Torn	Torn	/
<b>Healing potential of TFCC tear's margins</b>	Good	Good	Good	Poor	/
<b>Status of DRUJ cartilage</b>	Good	Good	Good	Good	Poor
<b>Treatment</b>	Repair Suture (lig-to-capsule)	Repair Foveal reinsertion	Repair Foveal reinsertion	Reconstruction Tendon graft	Salvage Arthroplasty or joint replacement

Figure 10. Atzei classification of TFCC peripheral tears (Atzei 2009 [26] and 2011 [27]).

Atzei published a new treatment-oriented classification of TFCC peripheral tears, in which he illustrated five classes (Figure 10) [26, 27]. Atzei described the ulnar-sided TFCC as three structures: the proximal triangular ligament, which represents the ligamentum subcrucium (deep ligaments), the distal hammock structure and the UC ligaments, which both make up the distal component of the TFCC [26, 27]. A Class 1 lesion corresponds to a repairable distal tear with an intact proximal TFCC component, which is recommended for treatment with traditional arthroscopic suture. If

there is a complete tear through the distal and proximal components of the TFCC, with combined DRUJ instability, the lesion is regarded as a Class 2 injury and requires foveal re-attachment of the TFCC. A proximal tear with an intact distal TFCC component is regarded as a Class 3 lesion, which also requires foveal re-attachment. Like Class 2 lesions, Class 4 injuries are characterised by a complete tear through the distal and proximal components of the TFCC, but they are not repairable and are always associated with severe DRUJ instability. As a result, Class 4 requires reconstruction

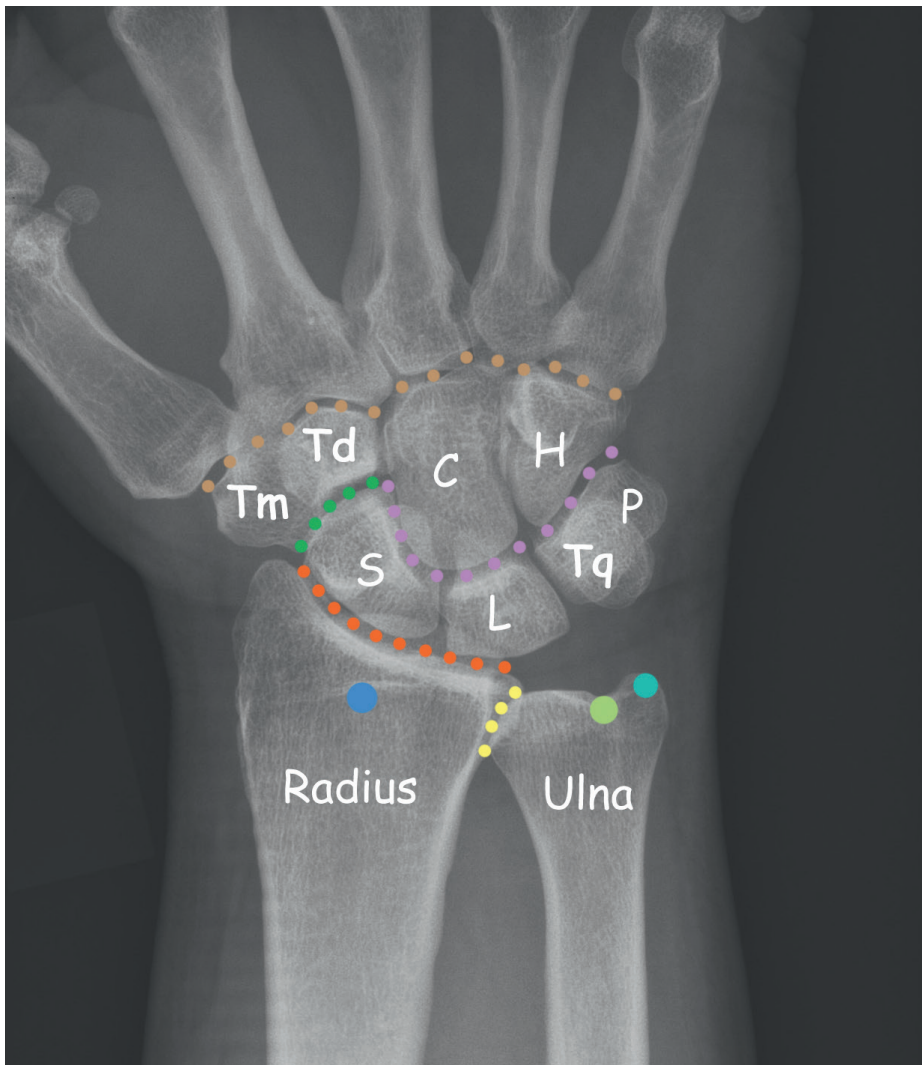

using a tendon graft. Adams described a technique, treating post-traumatic DRUJ instability with a reconstruction of the distal radioulnar ligaments using a tendon graft [3, 4]. Moreover, stabilisation of the DRUJ can be performed by dorsal capsular imbrication [231]. Finally, Class 5 lesions represent an arthritic DRUJ, the end result of long-standing TFCC injury with DRUJ instability, which should be treated by arthroplasty [26], with the Aptis-Schecker DRUJ replacement, for example [179].

#### **1.2.4 Skeletal and joint anatomy**

The wrist consists of the distal radius and ulna, the DRUJ, the RC joint, the carpus with the proximal row (scaphoid, lunate, triquetrum and the sesamoid pisiform), the MC joint, the distal carpal row (trapezium, trapezoid, capitate and the hamate) and also the carpometacarpal joints. The carpus is the anatomical assembly connecting the hand to the forearm. This term derives its meaning from the Greek καρπός (karpós), meaning "wrist". The carpus has 21 unique articulations kept together internally

by their shape and a ligamentous apparatus like an arch bridge. In the forearm, 19 muscles act to position the hand and only the flexor carpi ulnaris (FCU) specifically inserts on the carpus (pisiform and hook of hamate). The main role of the carpus in humans is to facilitate the effective positioning of the hand and the powerful use of the extensors and flexors of the forearm, but the mobility of individual carpal bones increases the freedom of movement at the wrist. The RC and MC joints facilitate the motions in flexion, extension, radial and ulnar deviation and, to some degree, even pro- and supination. This enables the hand to move functionally from dorsal extension and radial deviation to volar flexion and ulnar deviation – a human-specific and important motion called the "dart throwing motion" [85, 86]. The carpal motion is determined by the intricate articulations and the ligamentous insertions and attachments. The RC joint accounts for approximately 60% of the total ROM (range of motion), while the MC joint accounts for approximately 40%.



- |  |  |
|--|--|
| <span style="color: green;">■</span> Scapho-trapezio-trapezoidal joint (STT) | <span style="color: brown;">■</span> Carpo-metacarpal joints (CMC) |
| <span style="color: orange;">■</span> Radiocarpal joint (RC)                 | <span style="color: purple;">■</span> Midcarpal joint (MC)         |
| <span style="color: blue;">■</span> Lister's tubercle                        | <span style="color: lightgreen;">■</span> Ulnar fovea              |
| <span style="color: yellow;">■</span> Distal radioulnar joint (DRUJ)         | <span style="color: teal;">■</span> Ulnar styloid                  |

Figure 11. Normal wrist with its bones and joints (illustration Dr Per Fredrikson). Tm= trapezium, Td= trapezoid, C= capitate, H= hamate, S= scaphoid, L= lunate, Tq= triquetrum, P= pisiform

The forearm should be regarded functionally as one joint and one functional unit. The radius rotates around the ulnar head during the pronation and supination of the forearm [96]. The spheres of the two articular surfaces in the DRUJ differ and, as a result, approximately 60% of the joint surfaces are in contact in the neutral position, but in full pronation and supination the contact area is only 10%. The sigmoid notch is located on the ulnar side of the distal radius. The sigmoid notch rests on the ulnar head and rotates and slides around the 270° cartilage articular circumference of the ulnar head, during rotation [9, 96].

The DRUJ is only separated from the RC joint by the avascular articular disc of the TFCC [123].

There are three different DRUJ types, affecting the stability, ulnar variance and the possibility of developing dorso-ulnar pain, due to ulnar impaction syndrome [69, 226]. The three types of DRUJ are shown in Figure 12 and Table 5. In a normal wrist, without prior injuries and no positive ulnar variance, 80% of the load is transmitted between the carpus and radius and 20% between the carpus and ulna. In an ulnar-positive wrist, a significant increase in load is transmitted between the carpus and ulna, making the TFCC prone to injury.

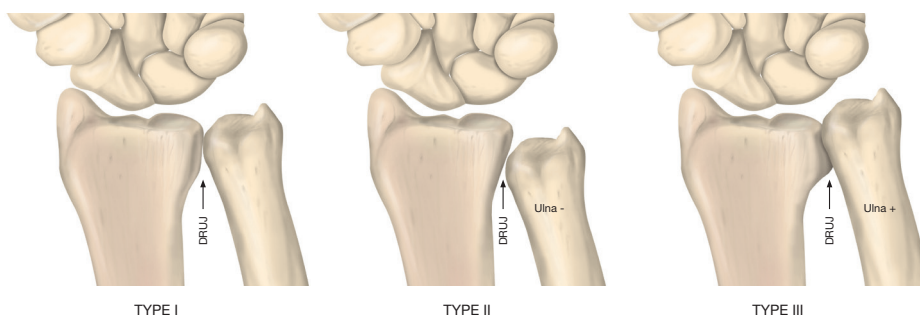


Figure 12. Different types of DRUJ. (DRUJ =distal radio-ulnar joint, ulna - = negative ulnar variance, ulna + = positive ulnar variance.)

Table 5. Types of DRUJ.

TYPE OF DRUJ	SIGMOID NOTCH	ULNAR VARIANCE	ASSOCIATED LIGAMENT INJURIES AND INSTABILITY
Type I	Parallel and cylindrical	Neutral (0) or slight (+/-)	-
Type II	Oblique proximal and hemispherical	Negative ulnar variance (-)	-
Type III	Reverse oblique and conical	Positive ulnar variance (+)	TFCC 2 A – 2 E. Degenerative LT SL Geissler III-IV

The type of DRUJ also influences the risk of traumatic TFCC injury, the degree of instability, the choice of surgical treatment and result after surgery.

### 1.2.5 Distal radius fractures in younger non-osteoporotic patients

Distal radius fracture is the most common fracture seen at the emergency department and accounts for approximately 15% of all fractures in adults. In general, residual dysfunction after a distal radius fracture is most often mild, but it may give rise to significant impairment, particularly in the younger active population. The residual symptoms often manifest around the distal ulna when rotating the forearm or loading the hand. Central-radial pain can also be present in patients with sequelae after a distal radius fracture. It is well known that associated ligament injuries, particularly TFCC injuries, are common in younger non-osteoporotic adults with dislocated distal radius fractures [16, 24, 78, 92, 100, 138, 153, 168, 183]. It has been

postulated in biomechanical studies that TFCC injuries can be expected in non-osteoporotic adults when the dorsal angulation of a distal radius fracture exceeds 32° from the anatomically correct position [196]. The degree and energy of impact is most often greater in younger patients. Intra-articular fractures and associated ligament injuries are more common in non-osteoporotic patients. In intra-articular distal radius fractures of all ages with an intra-articular incongruency greater than 2 mm, ligament injuries have been found in the majority (68%) of cases [92]. Lindau et al. [138] showed that 98% of the patients had ligament injuries with varying degrees of severity – however, most of them partial. One third of that cohort with distal radius fractures in younger adults (men 20-60 years, women 20-50 years) also had chondral lesions.

One specific type of distal radius fracture has been found to be associ-

ated with specific wrist ligament injuries. Radial styloid fractures (so-called "Chauffeur's fracture") and carpal dislocations are commonly concomitant injuries. Some of the associated ligament injuries in carpal dislocations are obvious, whereas others, such as an isolated SLL disruption, can be more subtle.

Mudgal and Hastings [161] hypothesised that, in wrist radial deviation and compression, an impression fracture of the radial styloid occurs, followed by shearing of the scaphoid off the lunate, completing the SLL tear. Conversely, they hypothesised that ulnar deviation results in high tensile forces and can cause transradial perilunate-type injuries, as described by Mayfield et al. [151]. Mudgal and Hastings concluded that, "the most important feature of all these fracture patterns appears to be the generation of a radial styloid fragment with extension of the fracture line to the crest between the scaphoid and lunate fossae" [161].

Total and subtotal SL ligament injury is also associated with a positive ulnar variance [80].

### **1.2.6 Forearm fractures and distal radius fractures in children**

Fractures of the distal third of the forearm are extremely common in children and represent approximately 75% of all forearm fractures [32, 44]. Distal radius fractures comprise approximately 30% of all fractures in children [50, 128]. The distal radial physis is in-

involved in approximately one third of these fractures and distal radial physal injuries account for up to 50% of all physal fractures in the body. The distal radial physis accounts for approximately 75% of the growth of the radius (approximately 8 mm per year on average) and this may predispose the distal radius to fracture, because the distal metaphysis is thin, due to its continuous remodelling.

Fractures in this area have large remodelling potential. It has been claimed in the past that 50% of translation, 25° of dorsal-volar angulation and 10° of radial-ulnar deviation in distal radial fractures can be expected to remodel with continued skeletal growth in young patients, with at least two years of skeletal growth remaining [81, 112, 115, 255]. Remodelling potential depends on many factors, including the remaining growth potential, the direction of deformity, the distance from the physis and the severity of angulation. A young patient with a fracture close to the physis in the plane of adjacent joint motion will remodel best. Plastic deformation ("bending") and rotational deformities (> 10°) on the other hand remodel less well. The ossification centre of the distal radius appears before the first birthday and the distal ulnar ossification centre appears between five and seven years of age, often developing from two distinct centres of ossification. The distal radial and ulnar physes close between 17 (girls) and 19 (boys) years of age [238], depending on gender and skele-

tal maturity. Injury-caused early closing of either of the growth plates may lead to a length discrepancy between the radius and ulna, in some cases rendering DRUJ laxity. This should be taken into account when planning for wrist surgery in children and ado-

lescents. Not much is known about the kind of fractures and the degree of displacement that would lead to increased awareness and a suspicion of associated wrist ligament injuries and a risk of long-term complications in children and adolescents.

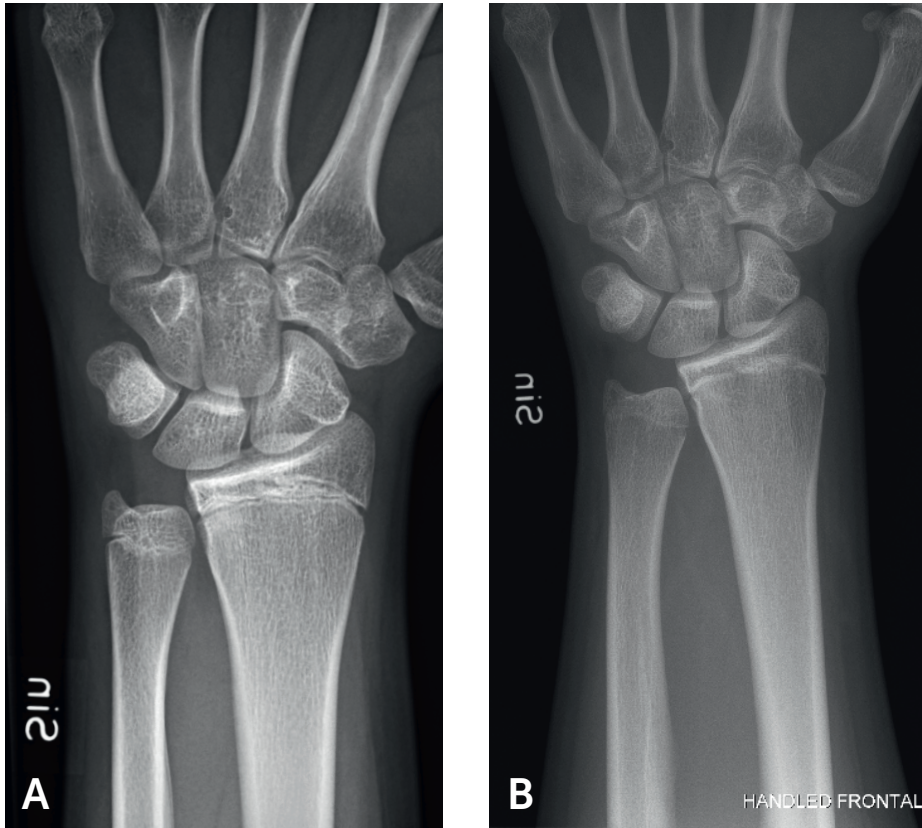
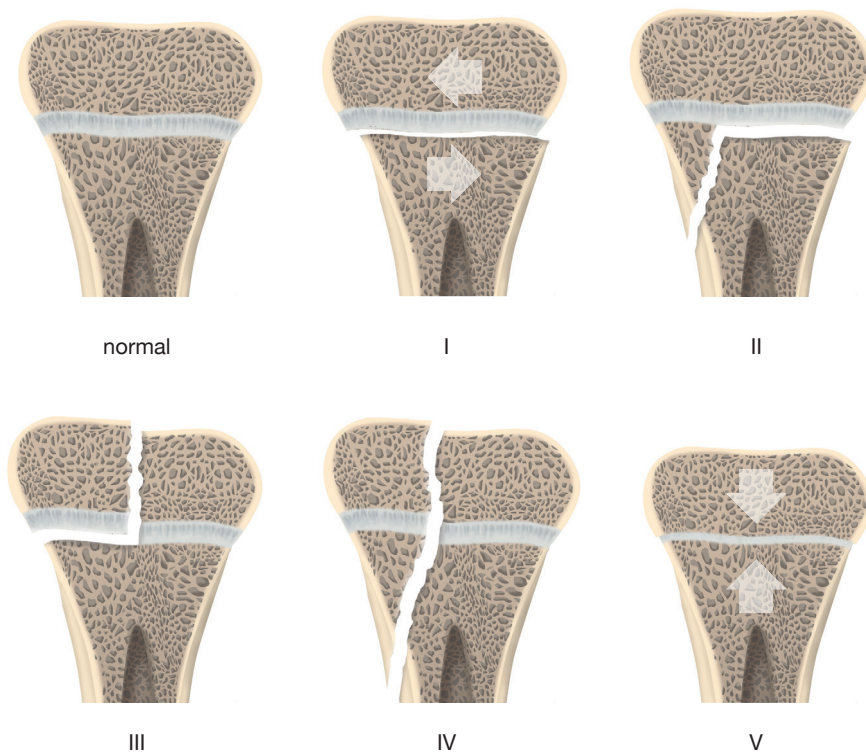


Figure 13. Closing of the physes in the distal radius and ulna. Open (A) and closed (B) distal radial and ulnar physes. The average age at closure of the distal radial and ulnar physis is 17 years for girls and 19 years for boys.

It is not clear why in some cases a metaphyseal fracture will occur and in others a physal injury. Salter-Harris

type I and II fractures are common, while types III, IV and V are very rare [190].



#### SALTER-HARRIS CLASSIFICATION

Figure 14. Salter-Harris classification of physal fractures.

Buckle fractures and minimally displaced fractures are often the result of low-energy injury, while displaced fractures result from high-energy trauma, such as accidents during sports, running, riding, biking and fall from heights [208]. Forearm fractures have been shown to migrate distally with increasing age, with adolescents more likely to sustain distal

radius fractures and younger children more likely to sustain diaphyseal shaft fractures [32, 62, 228].

Fractures of the distal radius, ulna and forearm in children are often treated non-surgically with a closed reduction and cast. Very little is known and published about children and post-traumatic wrist pain and poten-

tial DRUJ instability [31, 75, 221]. Isolated ligament injuries are generally considered to be uncommon in children, as their weakest point is the skeleton, as opposed to adults, where ligaments are more vulnerable.

## DO ISOLATED LIGAMENT INJURY EXIST IN CHILDREN?

### 1.2.7 Carpal instability and symptoms

Carpal instability (CI) is the end result of a wrist ligament injury [141, 151]. When carpal instability results in a major malfunction of a joint between the bones in the same carpal row (SL, LT), the case is defined as a carpal instability dissociative (CID). In mid-carpal instability (MCI), also known as carpal instability non-dissociative (CIND) [77, 251], which is not further described in this dissertation, there is no dissociation between SL or LT in the proximal row but instead a dysfunction of both RC and MC joints, where the latter tends to predominate and is not seldom associated with general hyperlaxity of the joints.

The failure of the injured ligament and the step-by-step attenuation and elongation of its secondary constraints [202] produces abnormal carpal kinetics (altered stress with the inability to bear functional loads) and abnormal kinematics (abnormal carpal motion). The degree of carpal instability can vary from minor micro-movements, due to ligament attenuation and partial ruptures, to gross carpal

displacement with abnormal radiographic carpal alignment [94]. After a significant wrist trauma, a spectrum of wrist ligament injuries can develop. When the injury is a mild sprain, an occult predynamic instability can be present. In more severe trauma, a dynamic instability (only possible to visualise in stress and load), characterised by the complete disruption of all parts of the proximal intercarpal ligament, can be present [38]. This dynamic instability is further characterised by the following; the ligaments are still repairable, not yet retracted or necrotic, with good healing potential, the secondary constraints and stabilisers are still intact or attenuated to a minor degree and there is no cartilage damage. No permanent carpal malalignment exists in the predynamic-dynamic instability – only under radiological stress and loading views will a gap (dissociation) or malalignment, such as an increased SL gap or increased SL angle, appear. Dynamic SL instability is present when an asymmetrically widened SL gap is present on stress radiographs, but not on neutral, static radiographs, in a patient with pain in the radial and central part of the wrist. This is the opposite of static instability, in which an asymmetrically widened SL gap is present on neutral, static radiographs with a clear and typical history and distinct physical examination. Empirically, static instability is most often found months to years after the index trauma.

When the SLL is injured, the scaphoid



tends to move into volarflexion, while the lunate, which is still fixed to the triquetrum, is forced, due to carpal kinematics, to follow the triquetrum into dorsal extension. The opposite happens with time when the LTL is injured. The injury may therefore take months to years to develop and culminate in static instability, with permanently altered carpal alignment and kinematics and with no healing capacity or chance of reduction. This static instability is often referred to radiologically as dorsal intercalated segment instability (DISI), following an SL ligament injury, and volar intercalated segment instability (VISI), following an LT ligament injury.

Scapholunate dissociation is the most common form of carpal instability. Patients with an SL ligament injury

often present with a “click” or “pain” on the dorso-radial aspect of the wrist and there is often an episode of clear injury preceding the symptoms. Swelling and limited grip strength and ROM are also common symptoms.

Acute LT ligament injury may result in ulnar wrist pain and swelling and limited strength and ROM. In chronic cases, patients frequently report instability, or crepitation and clicking upon ulnar deviation. Again, the severity of the symptoms differs substantially between each subtype of LT injury; ranging from pain and weakness in patients with partial tears, to wrist deformity and dysfunction in carpal collapse (VISI) and perilunate instability in patients with severe index trauma and total injuries or dislocations [234].

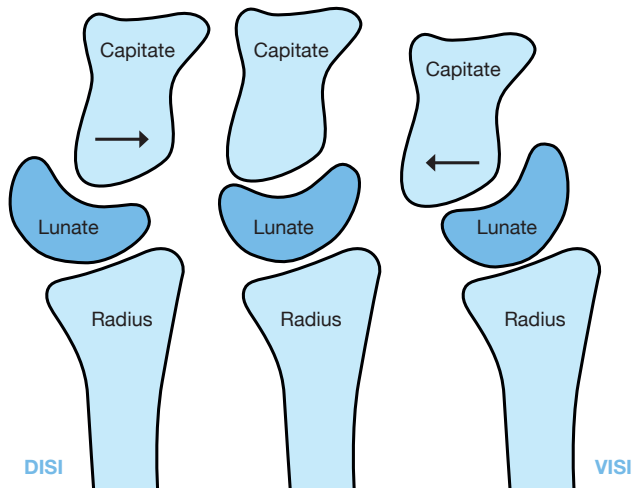


Figure 15. Schematic picture of dorsal intercalated segment instability (DISI), seen later after SL ligament injury, and volar intercalated segment instability (VISI), seen later after LT ligament injury.  
Copyright © Jonny Andersson

### 1.2.8 TFCC injuries – DRUJ – instability and symptoms

There are several anatomic structures that stabilise the distal radio-ulnar

joint (DRUJ), of which the triangular fibrocartilage complex (TFCC) is the most important, especially the foveal insertion [9,102].

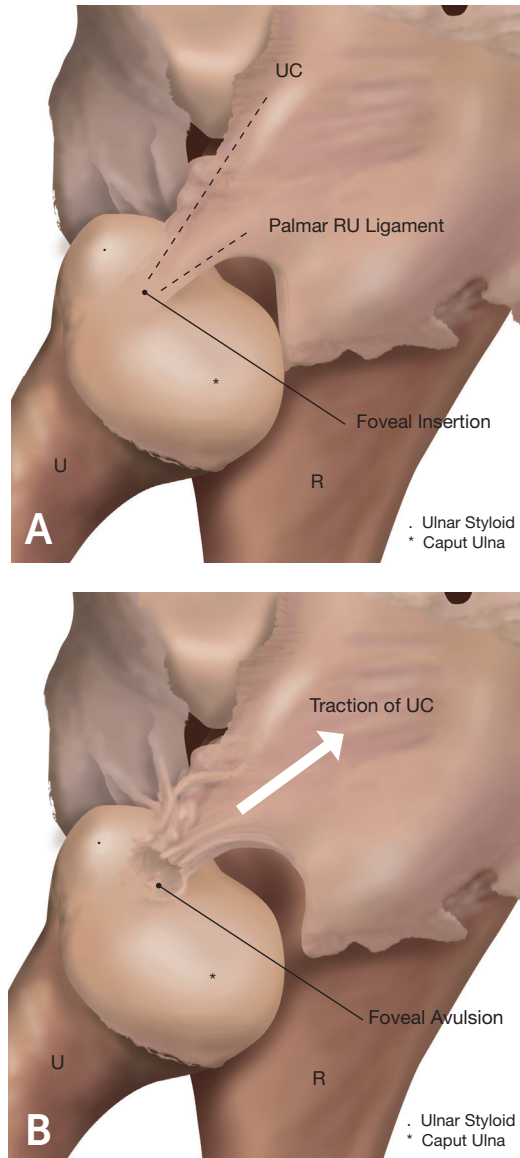


Figure 16. Foveal insertion of the TFCC – intact (A) and avulsed (B). (R = radius, U = ulna, UC = ulnocarpal ligaments)  
Copyright © Jonny Andersson

Other stabilising components of the DRUJ are the anatomical configuration of the distal radius and ulna, the DRUJ and its congruity, the interosseous membrane (IOM), particularly the

distal part and the central band [240], and muscular dynamic stabilisers (extensor carpi ulnaris, flexor carpi ulnaris, pronator quadratus).

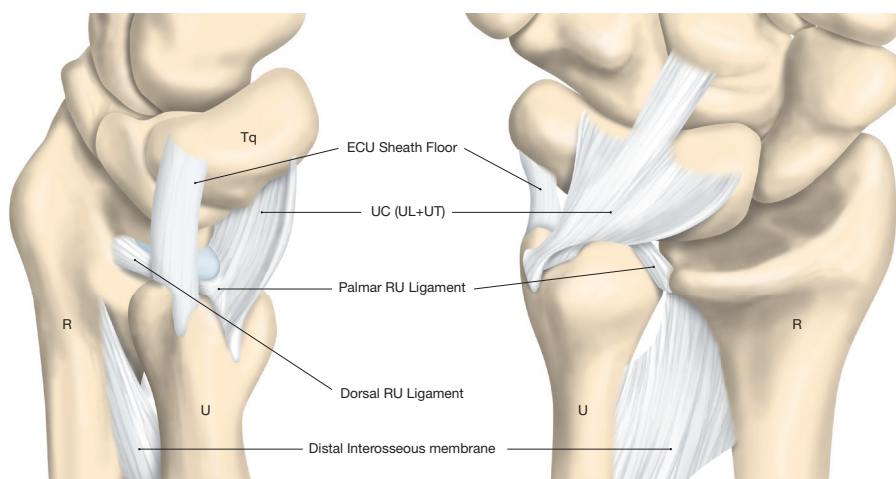


Figure 17. Schematic drawing of stabilising factors of the DRUJ (R= radius, U= ulna, RU= radioulnar, Tq= triquetrum).

Copyright © Jonny Andersson

It is well known that associated ligament injuries, especially TFCC injuries, are common in the event of dislocated distal radius fractures in adults [16, 24, 78, 92, 100, 138, 153, 168, 183]. Ulnar-sided wrist pain and DRU joint instability are the most common sequelae after distal radius fractures with concomitant TFCC injury in adults [135, 137, 139].

The RU ligaments consist of both a deep and a superficial portion. The deep fibres insert at the ulnar fovea and the superficial fibres attach to the base of the ulnar styloid process. DRUJ instability is present in total injuries, if the skeletal congruity and the muscu-

lar dynamic stability are not enough to stabilise and keep the DRUJ in the correct position.

Due to its anatomical location, as well as its functions of rotation and load bearing, the TFCC is highly prone to injuries and attritional wear [230].

Pain due to TFCC lesions is often present in relation to powerful rotatory hand movement, like squeezing a cloth, pouring from a jug or pushing down a doorknob. Ulnar-sided wrist pain, especially when lifting heavy objects, might also be related to a TFCC lesion and/or DRUJ instability [37].

### 1.2.9 Complications after wrist ligament injuries

The end result of long-standing scapholunate ligament injury with dissociation (SLD) is always dorsal intercalated segment instability – DISI and a so-called scapholunate advanced collapse – SLAC wrist (see Table 2) [241]. SLAC is the most common pattern of degenerative arthritis of the wrist. It develops following SLD with rotary subluxation of the scaphoid. The degenerative changes first affect the radial styloid, then the radio-scaphoid joint, followed by parts of the the MC joint (capitolunate and scapho-trapezio-trapezoidal joints). The head of the capitate in particular can erode fairly rapidly when it is subsequently dislocated into the gap between the lunate and the scaphoid. The radiolunate joint is not typically involved in SLAC arthritis, due to the spherical shape of the lunate and the congruity of the joint between the lunate and the lunate fossa of the radius.

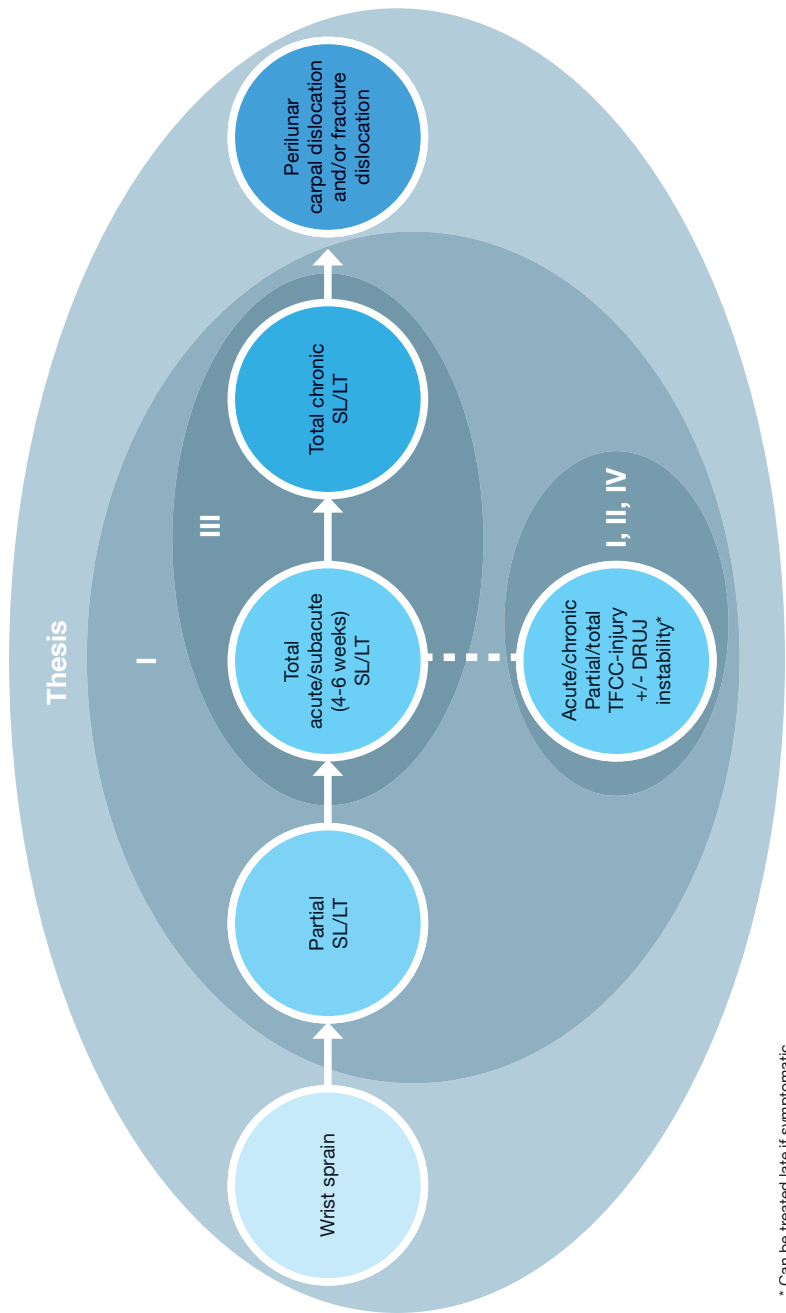
The average time from the initial trauma to SLAC development is unknown and variable, depending - among other things - on the amount of trauma, injured associated ligaments and secondary stabilisers, the initial step between the scaphoid and the lunate, and the individual configuration of the wrist. Empirically, SLAC wrist is most often found three to 15 years after the index injury. For the patient, SLAC wrist can be almost asymptomatic, but it is most often debilitating,

with pain, limited and restricted range of motion (ROM) and loss of strength [16, 243, 245].

An injury to the dorsal or palmar part of the LT ligament can cause significant kinematic dysfunction. This may potentially result in synovitis, a dynamic volar intercalated segmental instability (VISI) deformity and abnormal motion of the carpus. In the event of concomitant acute rupture or subsequent gradual injury of the secondary stabilisers/extrinsic ligaments, a highly dysfunctional static VISI deformity, carpal collapse and finally degenerative arthritis can develop [234].

Ulnar-sided TFCC ruptures in particular are inclined to cause DRUJ instability. This injury is classically classified as Class 1B lesions, according to the Palmer grading system [173] (see Figure 9). Missed DRUJ instability in injured patients may lead to pain, a feeling of giving-way, loss of function and in some cases secondary osteoarthritis of the DRUJ [177, 213].

Acute wrist ligament injuries can differ in nature and severity, ranging from distorsion and partial isolated injuries to the most severe perilunar carpal dislocation with several ligament injuries and possible fractures. Perilunate dislocations and transscaphoid perilunate fracture-dislocations render the most severe complications and sequelae.



\* Can be treated late if symptomatic

Figure 18. Schematic presentation of the different grades of severity in wrist ligament injuries – correlated to the Studies in this Thesis (Study I-IV).

### 1.2.10 Perilunar carpal dislocations and their complications

Perilunate dislocations (PLDs) and transscaphoid perilunate fracture-dislocations (PLFDs) are uncommon lesions (account for approximately 7% of all carpal injuries), usually occurring during high-energy trauma in young patients. Approximately 60% of these injuries are associated with scaphoid fractures and are referred to as transscaphoid perilunate dislocations. Specific patterns of these injuries, *greater arc*, with more widespread

injuries and fractures, and *lesser arc*, localised mainly around the lunate, have been described by Mayfield [151]. *Lesser arc* injuries are mainly ligament injuries and dislocations around the lunate, while *greater arc* injuries are mainly trans-carpal fracture dislocations. As many variants of these injuries exist and not all are explained by the patterns described above, Bain et al. have proposed that *translunate arc* and *inferior arc* injuries should be added [33].

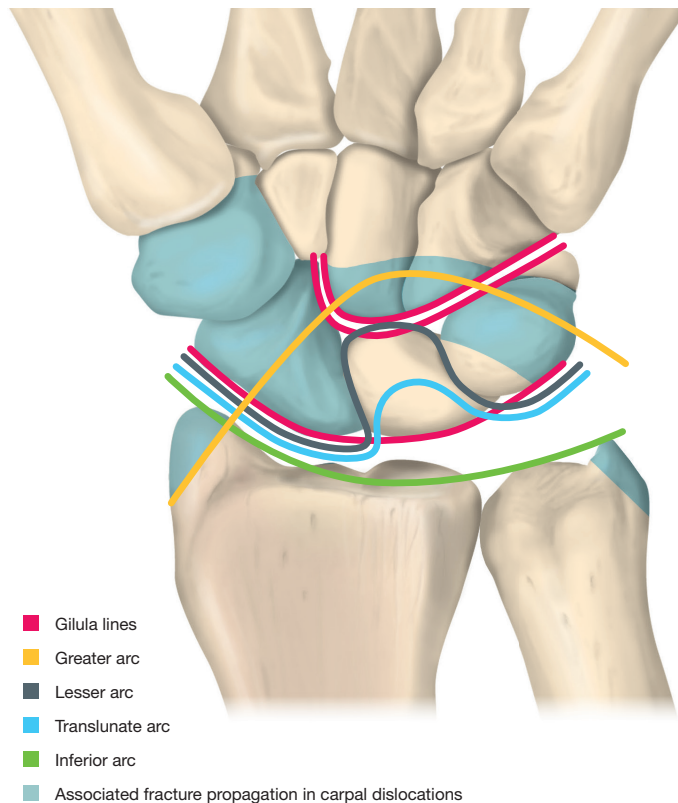


Figure 19. Schematic presentation of typical patterns of perilunate dislocations and transscaphoid perilunate fracture dislocations. Normal Gilula's lines are also displayed.

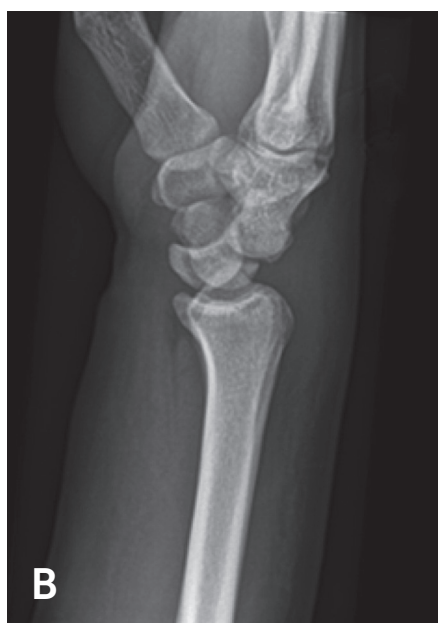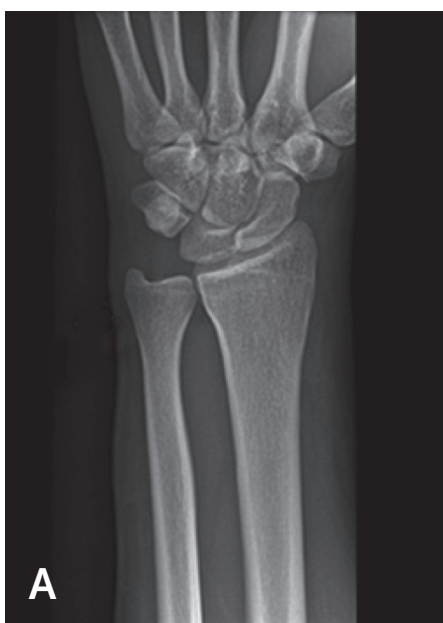Copyright © Jonny Andersson

Early treatment with open reduction, with dorsal and volar access and repair of the SL and LT ligaments, and internal fixation is always recommended [106].

A closed reduction should be attempted in the acute setting in all patients. Early closed reduction relieves pressure on the median nerve (associated acute carpal tunnel syndrome is present in one-third of the cases) and

other soft tissues while the patient is awaiting definitive surgical management. After a few days, closed reduction will not be successful [47].

Moreover, the diagnosis is initially missed in approximately 25% of the patients, because the dislocation is often hidden due to concomitant severe swelling. The pain is not always pronounced in these patients.



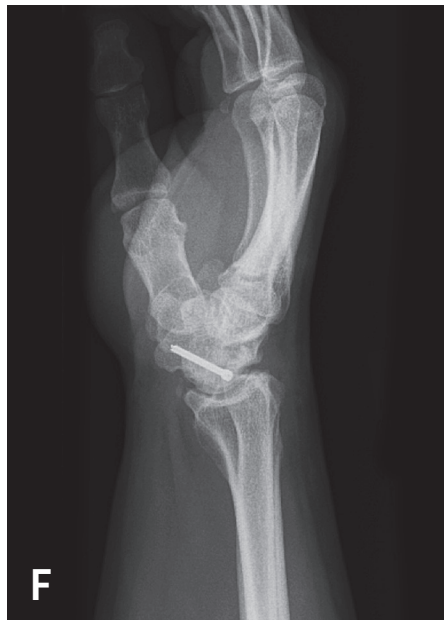
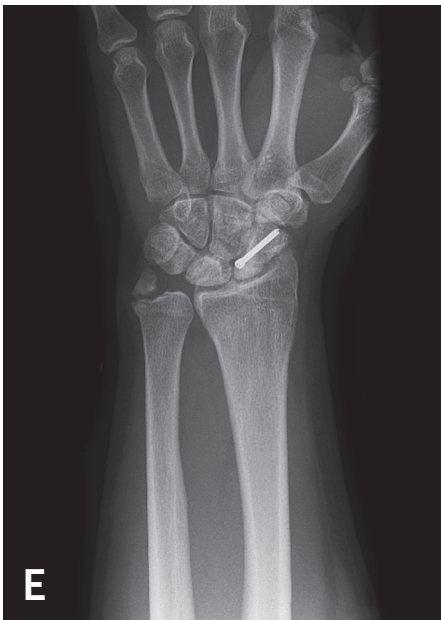
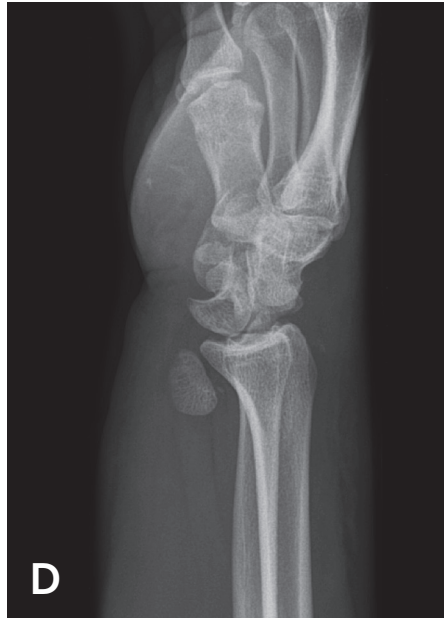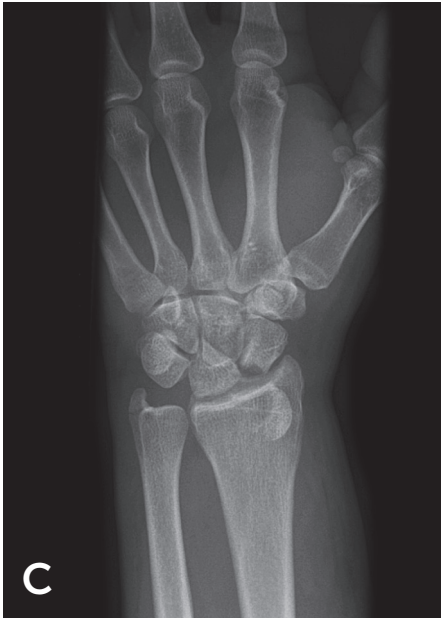Figure 20. Perilunar dislocation – AP view (A) is almost normal but observe the step in Gilula's linjes. The diagnosis is obvious in the lateral view (B). Transscaphoid perilunar fracture-dislocation with a gross dislocation of the proximal pole of the scaphoid and a fracture of the ulnar styloid at trauma (C, D) and one year postop (E, F).



When a patient presents with wrist swelling, pain and reduced motion, it is imperative to make sure, using a high-quality lateral wrist radiograph, that both the lunate and capitate are located in their fossae. It is critical that these injuries are identified at an early stage, as late presentation leads to a poorer outcome. PLDs and PLFDs diagnosed later than six weeks to six months after index trauma often necessitate a primary salvage operation, such as proximal row carpectomy (PRC), four-corner fusion (4CF) or a total wrist fusion, depending on the status of the cartilage.

According to the literature, PLDs and PLFDs are associated with a mean incidence of post-traumatic arthritis of almost 40% (range, 7%-92%) [79, 108]. Signs of post-traumatic arthritis after perilunate dislocations and transscaphoid perilunate fracture dislocations increase progressively, but some patients have minor symptoms at follow-up after more than 10 years [79]. However, approximately 30% of these patients are not able to return to heavy manual work [106].

## **I 1.3 Diagnosis of injuries**

### **1.3.1 Pathomechanisms of injuries**

It is very important to understand the pathomechanisms of wrist ligament injuries in order to establish a correct diagnosis of the different wrist ligament injuries.

SLL injury is common in young indi-

viduals and it is often the consequence of a fall forwards from a height, sport injuries or a motorcycle accident. In a fall from height, the dorsally extended hand hits the floor and becomes a fixed pivot point upon which the falling body rotates; in a head-on collision, the cyclist's hand remains blocked by the handle bar and the body's inertia is what causes the damage.

In both instances, violent torque is generated, forcing the wrist into extension and variable degrees of radio-ulnar inclination and/or intracarpal prono/supination. In these circumstances, the bones of the proximal row do not displace in similar directions; while the scaphoid is pulled distally by the scaphocapitate (SC) and scapho-trapezio-trapezoidal (STT) ligaments, the lunate remains solidly constrained against the radius by the two palmar, short and long radiolunate ligaments (S/LRL) [88]. If the wrist is radially deviated at the moment of impact, a scaphoid waist bending fracture is likely. If the wrist is ulnarly inclined, an SLL injury occurs more frequently. However, in some patients, co-existing injuries – waist fracture of the scaphoid and partial-total SLL injury – also occur. In the study by Jørgsholm et al., an arthroscopic evaluation of displaced and non-displaced scaphoid waist fractures showed that 71% had associated acute SL ligament injuries and 24% had a complete SL ligament rupture [118].

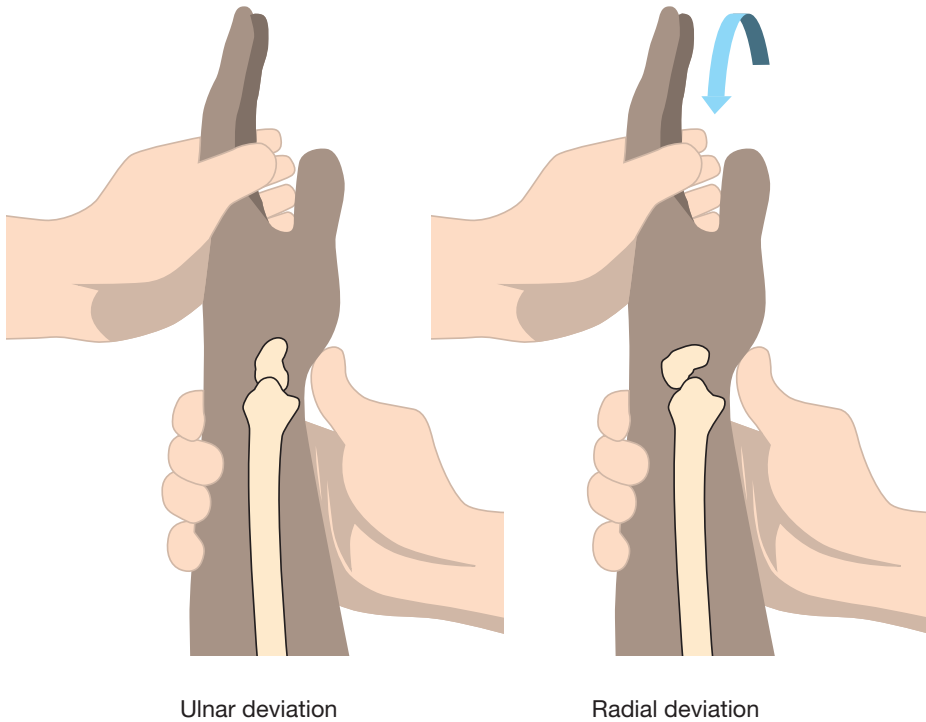
It is generally difficult to distinguish between traumatic and degenerative causes of LT instability. The exact mechanism of ligament injury is generally thought to be multi-factorial, although isolated LTL injury is often the result of a fall backwards onto an outstretched hand. If the arm is externally rotated and the wrist is in radial deviation and extension, this will cause the triquetrum, which is already in an extended position, to be translated dorsally without the lunate following. With significant force, the LTL will fail. Conversely, the degeneration of the LT ligament may be the result of arthritis, ulnar impaction syndrome, age or inappropriately treated ligament trauma. LT and TFCC injuries are often concomitant.

Lesions of the TFCC may be either degenerative or traumatic. Traumatic lesions are most often found together with a distal radius fracture. Isolated TFCC injuries are usually caused by rotational injuries or accidents while the patient is falling onto a pronated or hyperextended wrist [174]. Degenerative TFCC injuries are more common in patients with positive ulnar variance [227].

### **1.3.2 Clinical examination**

A clinical examination of wrist ligament injuries consists mainly of palpation and different laxity and provocation tests.

A positive Watson's test (scaphoid shift manoeuvre) indicates a total SL injury. However, positive tests occur in approximately 20% of the normal population, which contributes to diagnostic difficulties [88, 89, 253]. When performing the scaphoid shift manoeuvre, the examiner grasps the wrist from the radial side, placing the thumb on the palmar prominence of the scaphoid, while holding the fingers firmly around the distal radius. This enables the examiner's thumb to push on the scaphoid with counter-pressure provided by the fingers. The examiner's other hand grasps the patient's hand at the metacarpal level to control wrist position. Starting in ulnar deviation and slight extension, the wrist is moved radially with simultaneous slight flexion and with constant thumb pressure applied to the scaphoid. The Watson's test is positive if the scaphoid is unstable and can be subluxated dorsally and the patient experiences pain at the *dorsum* of the wrist [88, 89, 253]. The SLL can also be examined with the so-called finger extension test (maximum finger extension against resistance, during simultaneous volar flexion of the wrist), although this test can sometimes also be positive if the patient has dorsal synovitis or ganglia [73].



### WATSON'S TEST

Figure 21. Watson's test – scaphoid shift manoeuvre.  
Copyright © Jonny Andersson

The lunotriquetral ligament and joint (LT) is best examined by stabilising the RC joint, while forcing the pisiform/triquetrum in the volar-dorsal direction, and attempting to evaluate

the laxity and perceived pain (ballotement test or Shuck test), and the Derby wrist test, where the patient is told to perform a forceful dart throwing motion [88, 89, 234, 253].

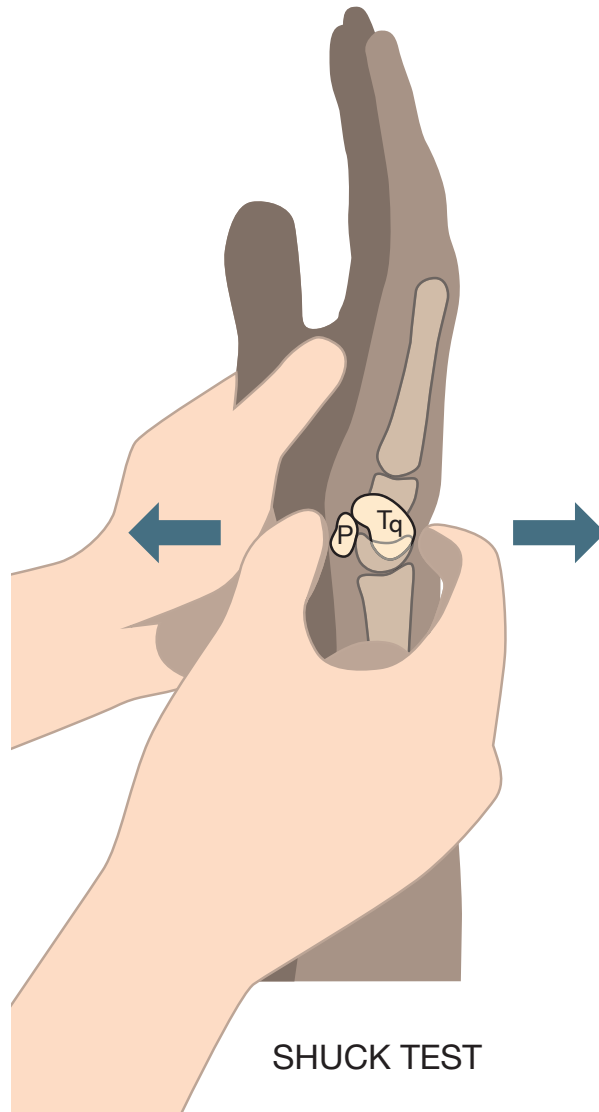
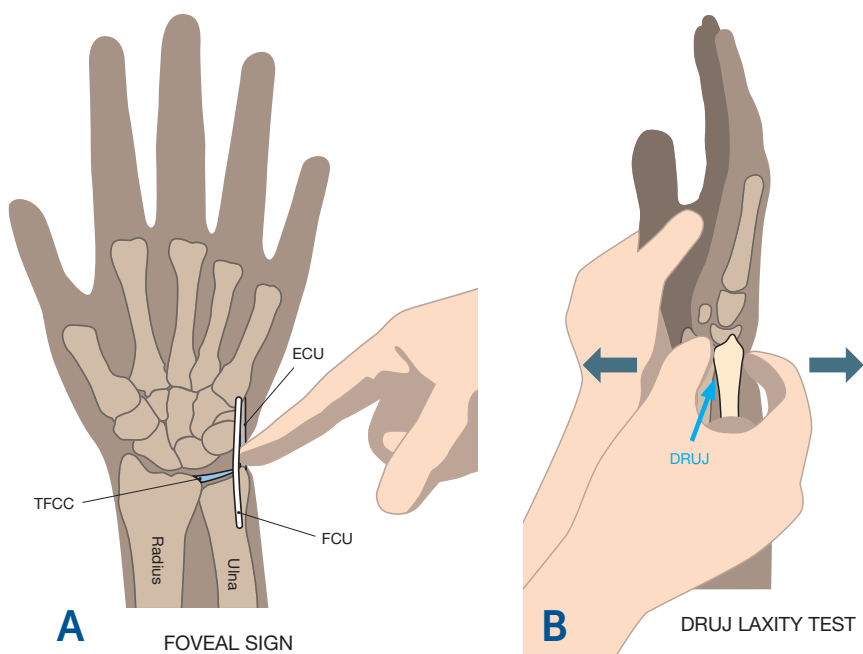


Figure 22. Shuck test – LT ballotement test (P= pisiform, Tq= triquetrum).  
Copyright © Jonny Andersson

A clinical examination of the TFCC and DRUJ should include clinical DRUJ laxity tests and a TFCC test called the “ulnar fovea sign” [220]; i.e. tenderness on the palmar aspect of the fovea located proximally to the pisiform and ulnar to the flexor carpi ulnaris tendon. DRUJ laxity is tested with the forearm held in neutral rotation by the examiner, who stabilises

the hand and the distal radius with a firm grip to make them one unit [160]. Then, using the other hand, the examiner forces the ulna as the second unit in a dorsal/palmar direction, relative to the stabilised unit of the hand and radius. The stability of the DRUJ is always compared with that of the uninjured wrist.



Figures 23. Foveal sign (A) and DRUJ laxity test (B)  
Copyright © Jonny Andersson

However, the diagnosis of TFCC lesions is often difficult and sometimes controversial. A physical examination on the ulnar side of the wrist may not be accurate due to a variety of lesions in this area, some of which may mimic similar symptoms [189].

All clinical and provocation tests of wrist ligaments should be performed by comparing the findings with the normal contralateral side.

In 1995, LaStayo and Howell [129] reported that wrist provocation tests were effective in identifying injuries

that required further investigation and, in patients requiring an arthroscopic diagnostic operation, the provocation tests proved to be more effective in predicting the absence of injury than its presence.

A thorough systematic examination by a dedicated experienced hand/wrist surgeon is mandatory in order to assess and evaluate the capability of wrist ligament injury.

**ARE NEGATIVE RESULTS OF PROVOCATION TESTS SUFFICIENT TO DISCONTINUE FURTHER DIAGNOSTIC EVALUATION?**

**Strength measurements**

The need for a reliable, readily accessible, non-invasive and inexpensive diagnostic tool for TFCC injury is obvious. Researchers have implied that there might be a correlation between strength in pronation/supination and TFCC injury with DRUJ instability [140]. Other authors have described slightly different methods and results for measuring torque in patients of different genders and ages, as well as normal

individuals, with the body and forearm in different positions [90, 107, 126, 149, 159, 170, 182, 206, 225]. It is known from previous studies [149] that the non-dominant left upper extremity has peak torque values between 85-95% of the peak torque values of the dominant right upper extremity. Several medical conditions can influence torque; they include epicondylitis [170, 171] and ulnar impaction syndrome [130].

The rationale for applying the forearm torque technique is logical because the test directly involves the affected TFCC joint complex. The grip strength test only indirectly addresses this issue since the wrist actuators are able to stabilise the wrist position, while extrinsic and intrinsic finger flexors exert maximum finger flexion torque. Earlier studies demonstrated that torque production varies with arm, body and joint positions and that consistent positioning is vital for reproducible results [159, 170, 171, 182]. To date, attempts to correlate the instability of the DRUJ after distal radial fractures to loss of strength have, however, failed [140].



Figure 24. Measurement of peak torque strength of the right wrist in supination, standing with the elbow fixed to the body and in 90° flexion. Measurement technique developed by Peter Axelsson. Photo: Tommy Holl.

**COULD PARAMETERS OTHER THAN CLINICAL PROVOCATION TESTS BE VALUABLE IN THE DIAGNOSTICS AND EVALUATION OF WRIST LIGAMENT INJURIES?**

**IS IT POSSIBLE TO FURTHER DEVELOP A RELIABLE MEASUREMENT TECHNIQUE FOR PEAK TORQUE STRENGTH?**

**DOES INJURY TO THE TRIANGULAR FIBROCARTILAGE COMPLEX COMPROMISE FOREARM ROTATION TORQUE?**

### 1.3.3 Radiological examination

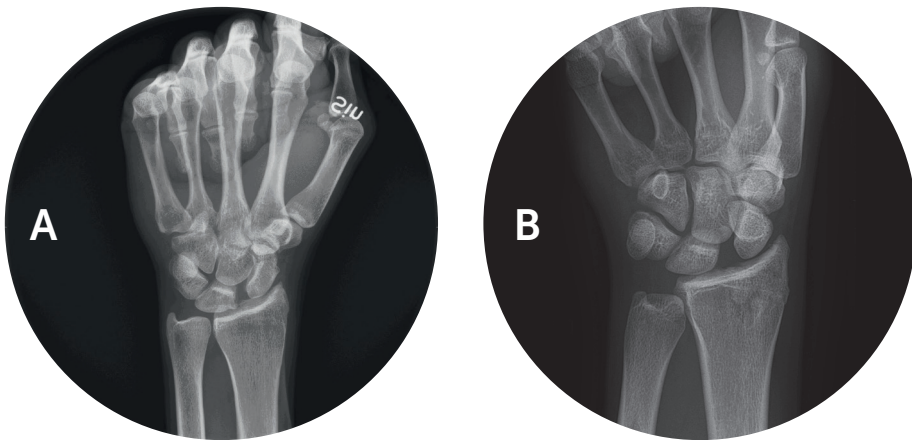
Although current non-invasive radiology may suggest several injury characteristics, the actual extent and nature of most ligament tears is not known until the patient is assessed using an arthroscope or by open surgery [8, 15, 16, 111, 135].

#### Plain radiographs

The initial diagnosis of SL injury can be difficult, as it often takes three to 12 months before dynamic instability is detected on plain radiographs (with clenched-fist films and ulnar deviation) with an SL gap of  $> 3$  mm and an SL angle of  $> 60^\circ$ . The radiological definition (plain films) of DISI is as follows:

– On an AP view, signs of scapholunate ligament dissociation, the normal trapezoidal configuration of the scaphoid, may be lost and it may appear triangular, sometimes with the so-called “ring sign” [48] (Figures 25).

– On lateral view, a dorsal tilt of the lunate is typically shown (Fig 26): scapholunate angle  $> 60^\circ$  and capitolunate angle  $> 30^\circ$  (the capitate is displaced posteriorly compared with the distal radius). Forward et al. [80] demonstrated that an increase of  $> 2$  mm in positive ulnar variance at the time of distal radial fracture in a young adult was associated with a fourfold increment in the risk of scapholunate ligament injury, if a sufficient wrist trauma was present.



Figures 25 A-B. Clenched fist (A) and ulnar deviation (B) showing dynamic SL dissociation and instability. (B) also reveals the so-called “ring sign” of the scaphoid, where the bone has moved into volar flexion.



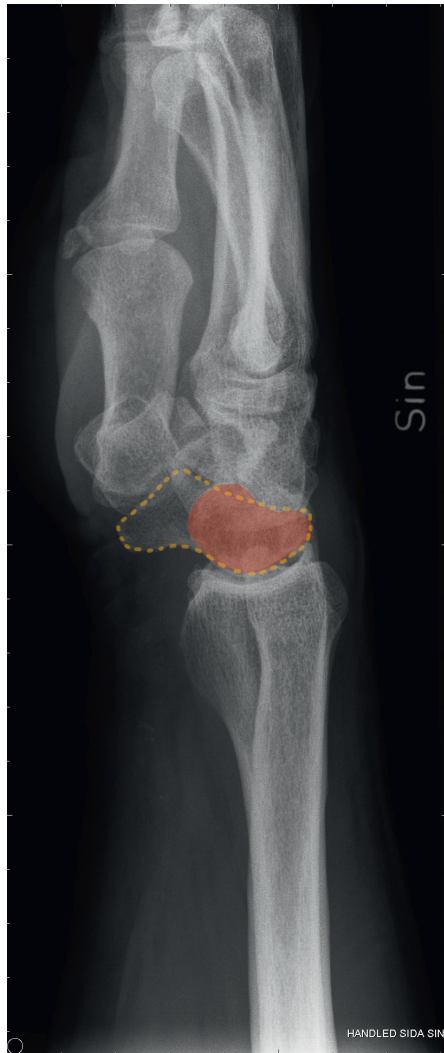

Figure 26. DISI with an SL angle of approximately  $90^{\circ}$ , as a result of static instability due to a total SL injury. (S= scaphoid, L= lunate, painted red).

Illustration: Dr Per Fredriksson

In LT injuries, it is sometimes, albeit infrequently, possible to see the lunate superimposed (Fig 27) on the triquetrum, with a step off between the two bones. The final static instability is also visualised as VISI (Fig 28).

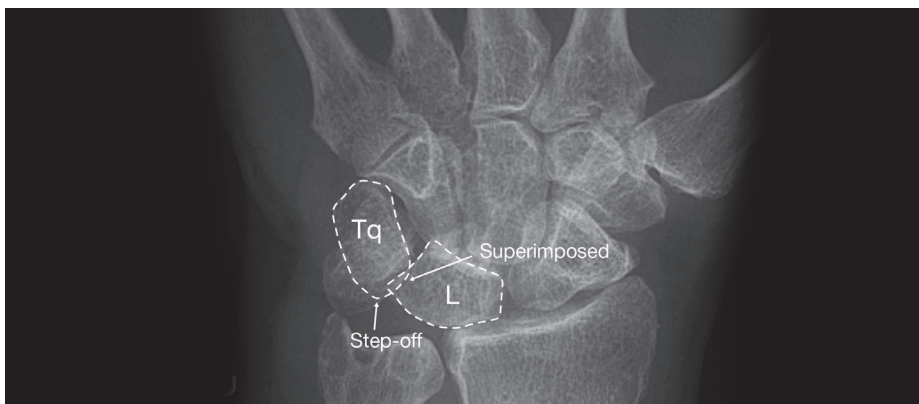


Figure 27. Triquetrum slightly superimposed on the lunate, with a step off between the two bones.

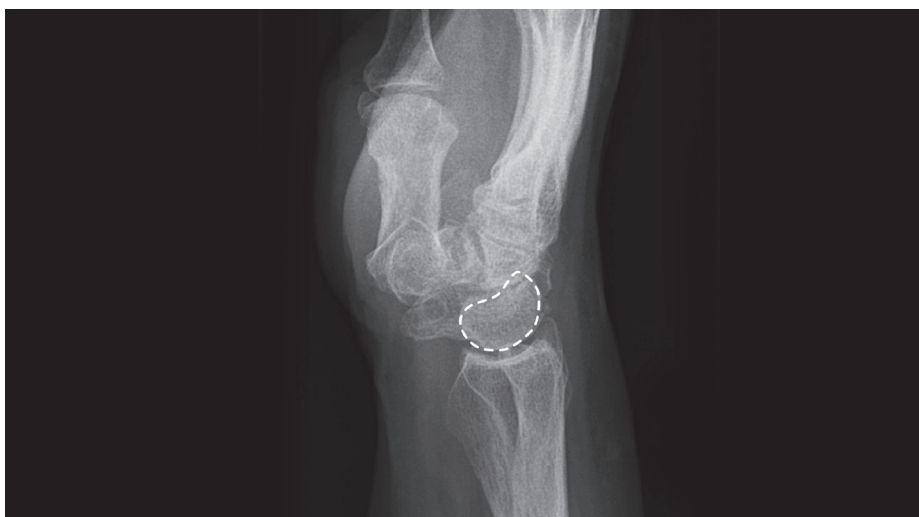

Figure 28. VISI as a result of static instability due to a total LT injury.

A distal radius fracture with a dorsal angulation of  $> 32^\circ$  (Fig 29) from its anatomical position is always associated with a TFCC injury [196], starting with a rift of the ECU subsheath. Sometimes, the so-called "bald ulnar head test" can be judged positive intra-operatively, estimating that a total TFCC

injury with DRUJ instability is present. In a lateral fluoroscopic view, with the wrist in extension, a positive "bald ulnar head test" is found if no carpal bones project over the dome of the ulnar head in the sector created between the extensions of the volar and dorsal cortices of the distal ulna [196].

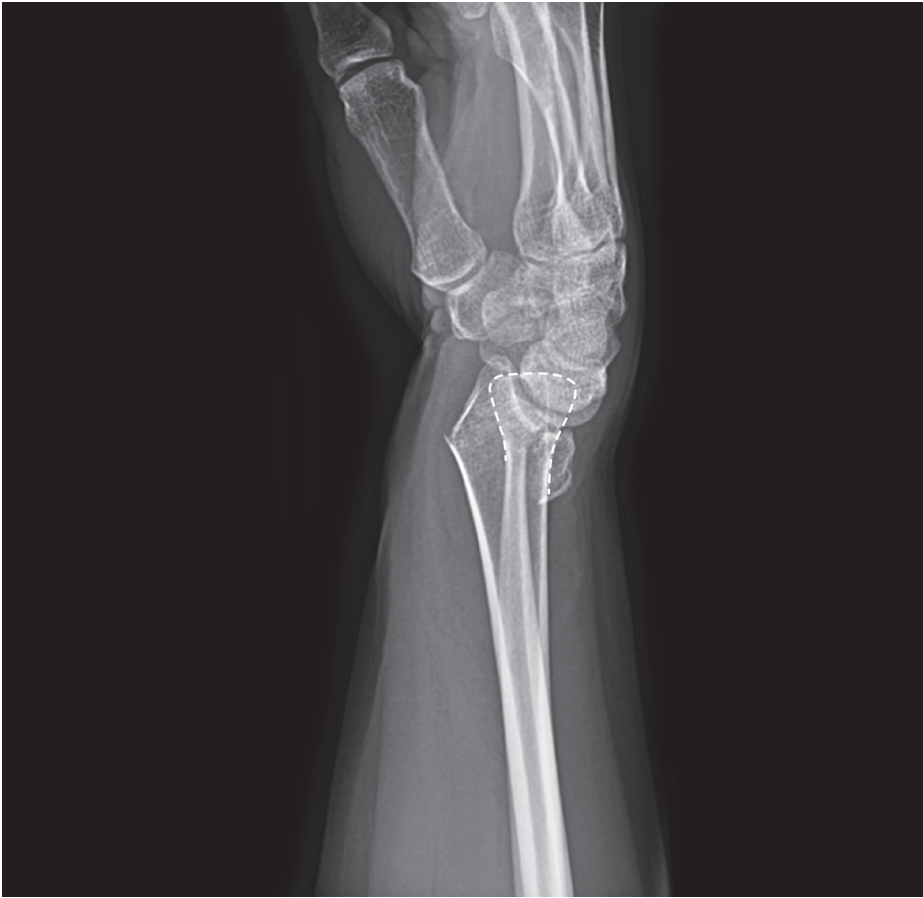

Figure 29. Distal radius fracture with a gross dorsal angulation.

It is also sometimes possible to see a widened DRUJ space and dorsal subluxation of the ulna, in acute traumatic TFCC injuries (Figure 30 A and B below). In actual fact, the radiographic finding of a normalised DRUJ gap on posteroanterior (AP) views is an im-

portant predictor for identifying DRUJ instability/stability accompanying unstable distal radius fractures. The relative risk of instability increases by 50% when the ratio of DRUJ widening increases by 1% [83].

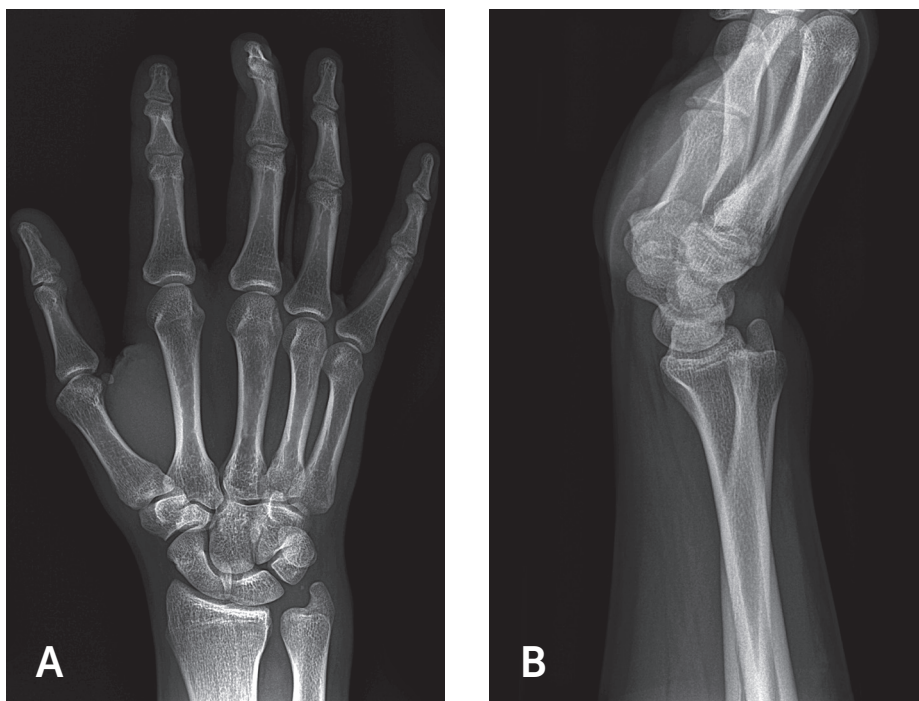


Figure 30. An obvious DRUJ gap on the AP view (A) and a dorsally displaced caput ulna on the lateral view (B) can indicate a TFCC injury.

A fracture at the ulnar styloid base and significant displacement of an ulnar styloid fracture increase the risk of distal radio-ulnar joint instability [150].

The diagnostic test accuracy of X-ray arthrography is limited for TFCC injuries [212]. It is even difficult to distinguish a TFCC Class 1-B injury with a foveal avulsion from a traumatic or degenerative central TFCC injury with

this diagnostic procedure.

Cineradiography or simple fluoroscopy can be a useful way of demonstrating abnormal kinematics of the scaphoid or lunate during wrist motion, especially with ulnar to radial deviation and with wrist flexion-extension. This can also be useful before choosing the type of partial carpal fusion recommended surgically [187].

### **Ultrasonography**

Ultrasonography has a sensitivity of 46%, a specificity of 100% and an accuracy of 89% for the evaluation of dynamic scapholunate ligamentous instability and should only be used as an adjunct to other diagnostic modalities, according to Dao et al., 2004 [59]. Ultrasonography can, however, be useful in determining other extra-articular pathology, such as ganglia, sometimes associated with wrist ligament injuries.

### **Computed tomography**

CT scanning is not helpful in terms of wrist ligament injuries. On the other hand, CT is valuable in terms of assessing the complications of ligament injuries, i.e. the stage of degenerative arthritis, such as SLAC.

Computed tomography (CT) scanning is of little use in terms of detecting the pathological subluxation of DRUJ in both acute and chronic cases of TFCC injury [197]. On the other hand, examination of the inclination and shape of the DRUJ [103] and side comparison of the DRUJ to detect early DRUJ arthritis

is managed effectively by CT. Occult carpal fractures, especially scaphoid fractures, as well as non-unions, can also often easily be revealed by CT.

### **Magnetic resonance imaging and magnetic resonance arthrography**

It has been generally accepted that appropriate parameter settings for magnetic resonance imaging (MRI) are most important for high accuracy [134, 184, 252]. In 2013, Ringler [184] proposed an MRI strategy for the wrist ligaments to increase accuracy in diagnosing wrist ligament injuries:

1. Magnetic strength  $\geq 1.5$ -T
2. Dedicated wrist coils
3. Field of view (FOV)  $\leq 10$  cm
4. Slice thickness  $\leq 2$  mm
5. Matrix  $\geq 384 \times 256$
6. MRI sequences including T1, fat-saturated PD or T2-weight fast spin echo (FSE)

The most important issue, however, is an experienced, dedicated radiologist, working closely with the hand surgeon.

**Table 6.** MR sequences and their importance.

SEQUENCE	EXPLANATION OF SEQUENCE	IMPORTANCE
T1- weighted	T1 relaxation time for protons	For anatomy. A true TFCC tear will appear as a linear band of increased signal intensity on T1-weighted sequences.
T2- weighted	T2 relaxation time for protons	For pathology. Fat, water and fluid are bright on T2 – ideal for picking up tissue oedema. Demonstrates ligament tears by visualising free fluid within the tear. A true TFCC tear will appear as a linear band of very increased signal intensity on T2, consistent with fluid.
PD	Proton density – a mixture of T1 and T2	A true TFCC tear will appear as a linear band of very increased signal intensity on PD, consistent with fluid.
FS	Fat saturation= signal from fat is nulled	A complete SL/LT tear is diagnosed when there is a distinct area of discontinuity with increased signal intensity on T2-weighted FS. T1-weighted FS is used after contrast administration.
GRE	Gradient-recalled echo T1 or T2 weighted	T2 weighted is used for cartilage assessment.
3D	Three-dimensional isovolumetric with contiguous thin slices (1 mm)	Can be reconstructed in any plane without a substantial loss of spatial resolution. Increases the diagnostic performance.
MRA	Magnetic Resonance Arthrography	Potential added benefits of joint distension, increased contrast-to-noise ratio- and documentation of abnormal patterns of compartmental communication or contrast extravasation. – Invasive technique.
STIR	Short-TI Inversion Recovery	T2 weighted with nulled signal from fat. Superior sequence near metallic foreign bodies.

The signal intensity on the MR image is determined by four basic parameters:

- 1) Proton density
- 2) T1 relaxation time
- 3) T2 relaxation time
- 4) Flow

Proton density is the concentration of protons in the tissue in the form of water and macromolecules (proteins, fat and so on). The T1 and T2 relaxation times define the way the protons revert to their resting states after the radiofrequency pulse. Signal intensities on T1, T2 and proton density-weighted images relate to specific

tissue characteristics.

### **Intrinsic ligaments – SLL and LTL**

The intrinsic ligaments are C-shaped (SLL) or V-shaped (LTL) and thin (2-4 mm). The MRI diagnostics of injuries can therefore be challenging and difficult. One comparative study [22] has shown that the sensitivity and specificity of an SL ligament injury are 64% and 87% overall, 57% and 81% using 1.5-T (Tesla) wrist MRI and 70% and 94% using 3-T wrist MRI. In the same study, the sensitivity and specificity of the LT ligament were 22% and 94% overall, 22% and 94% using 1.5-T wrist MRI and 50% and 94% using 3-T wrist MRI [22].

The intrinsic ligaments are best studied in the coronal plane. It is important not to misinterpret the normal low-signalling fibrocartilage attachment of the SLL or LTL to the higher signal articular hyaline cartilage of the proximal carpal row as a partial detachment [184]. A complete tear of intrinsic ligaments (SLL and LTL) is diagnosed on MRI when there is a distinct area of discontinuity with increased signal intensity on fluid-sensitive sequences (IR, inversion recovery and PD fat saturation) or a complete absence of the ligament [198, 256]. Other observations that may indicate an injury include severe distortion of ligament morphology, such as fraying, thinning, or abnormal course [257]. Partial SLL and LTL tears usually involve two adjacent components: either the dorsal and membranous components or the

volar and membranous components. Secondary findings on MRI, such as the presence of excessive midcarpal joint fluid and associated ganglia/synovitis, are sometimes important for an awareness of an existing ligament injury, but they are generally not helpful. The absence of scapholunate diastasis or DISI deformity cannot exclude even a complete SLL tear [222]. The one potential exception to this is the loss of the normal smooth convexity of the proximal carpal row. The presence of a slight lunotriquetral step-off should result in enhanced scrutiny of the LTL. A good knowledge of the MRI appearance of ligamentous anatomy, coupled with high-quality imaging and clinical history, is much more effective than MRI alone [15, 111, 184].

### **TFCC**

The sensitivity, specificity and accuracy of 3-T wrist MRI for the TFCC is consistently higher compared with those of 1.5-T wrist MRI. Some studies suggest that 3-T wrist MRI provides improved capability for the detection of TFCC injuries. In one comparative study, the sensitivity and specificity of TFCC injury [22] have been shown to be 84% and 69% overall, 82% and 59% using 1.5-T wrist MRI and 90% and 74% using 3-T wrist MRI.

The interpretation of peripheral attachment tears of the TFCC using MRI is much more difficult than that of central tears [99]. The small sizes and oblique orientations of the radio-ul-

nar ligaments, ulnar attachments and UL and UT ligaments make the visualisation of the important peripheral structures far more difficult than that of the central disc. A true tear or defect of the TFCC appears as a linear band of increased signal intensity on T1-weighted sequences, which increases on PD- and T2-weighted sequences, consistent with increased fluid content [198, 257]. A communicating defect (full-thickness tear) is suspected when the abnormal signal extends to both articular surfaces. A non-communicating defect is suspected when the abnormal signal involves only one articular surface, either the DRUJ or RC joint surface. Back in 1994, Sugimoto et al. [216] suggested that MRI was not able to differentiate a degenerative defect of the TFCC from a traumatic defect, which can be troublesome.

Magnetic resonance arthrography (MRA) may increase the sensitivity for small defects. Nevertheless, clinical correlation is critical because many of these defects are asymptomatic. While the MRI diagnosis of central and radial TFCC defects is relatively straightforward, the accurate detection of peripheral (Palmer 1B) tears can be substantially more challenging [99, 169]. Characteristic findings of TFCC 1B injuries include the separation of the TFCC from the distal ulna, with high signal intensity proximal to the TFCC, a change in the morphology of the ulnar attachments and localised fluid/synovitis. MRA with DRUJ injection

can be particularly helpful in these cases [188].

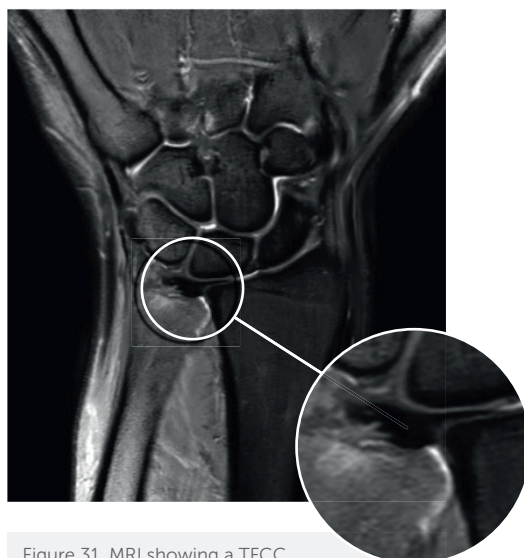


Figure 31. MRI showing a TFCC foveal avulsion.

High-resolution MRI with 3-T also has poor sensitivity and specificity for the detection of longitudinal tears of the UC ligament [185]. The subluxation of the ulnar head relative to the sigmoid notch of the radius, as assessed by MRI with the wrist in pronation, is a solid predictor of lesions of the foveal attachment of the TFCC [71].

In 2001, Hobby et al. [111] published a systematic review of the diagnostic performance of wrist MRI for lesions of the TFCC and the intrinsic carpal ligaments (SL and LT), among other things. For the diagnosis of a complete tear of the TFCC, the overall accuracy was 0.81, the sensitivity was 0.83 and the specificity was 0.80. The overall accuracy for SL injury was 0.85, the



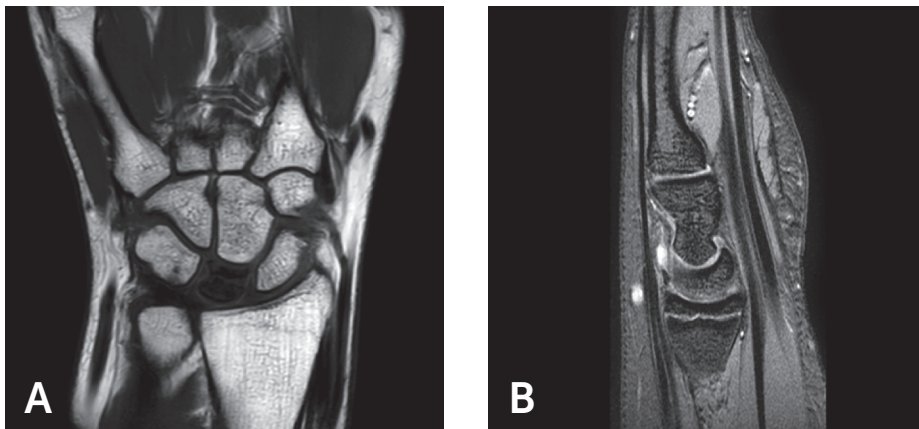
sensitivity was 0.70 and the specificity was 0.90. The overall accuracy for LT injury was 0.82, the sensitivity 0.56 and the specificity 0.91. In conclusion, these researchers reported that high-resolution MRI was an accurate means of diagnosing TFCC tears; although MRI was highly specific for SL and LT ligament injuries, its sensitivity was remarkably low. Arthroscopy was recommended as the gold standard to establish the diagnosis of wrist ligament injuries.

It is reasonable to assume that the diagnostic accuracy of MRI for wrist ligament injuries will improve in the

future.

However, when it comes to health economics, MRI is an expensive investigation (approximately 570 euros per MRI, according to Study V). There is also increasing demand for evidence of effectiveness in the planning, provision and resource allocation in the field of health care nowadays.

MRI is effective in terms of intra- and extra-articular differential diagnostics, such as Kienböck's disease (Figure 32 A) and ganglia (Figure 32 B). Ganglia in the SL joint can sometimes be a concomitant sign of occult SL injury [73].



Figures 32. MRI showing Kienböck's disease (A) and ganglia (B).

**ARE NEGATIVE RESULTS OF MRI SUFFICIENT TO DISCONTINUE FURTHER DIAGNOSTIC EVALUATION IN TERMS OF WRIST LIGAMENT INJURIES?**

**WHAT IS THE COST OF WRIST MRIs IN THE CATCHMENT AREA?**

## I 1.4 Wrist arthroscopy

Arthroscopy (from Greek; άρθρωση – “joint” and σκοπεῖν – “to look or see”) can be used to examine the inside of a joint. It is a minimally invasive technique, which can be utilised for diagnostic purposes, as well as for therapeutic interventions.

### 1.4.1 History

Wrist arthroscopy was initially used for diagnostic purposes when it was first introduced in 1979. Yung-Cheng Chen then reported on 90 arthroscopic examinations of the wrist and finger joints in 43 patients. F J Bora described the wrist arthroscope in a brief article in 1985 [45]. The techniques of wrist arthroscopy were refined throughout the early 1980s. Wrist arthroscopy became fully accepted as a diagnostic tool around the mid-1980s. At that time, arthroscopy of the wrist was an innovative technique to determine whether a patient’s problems and symptoms could be explained by pathological findings inside the wrist, but, a few years later, wrist arthroscopy became increasingly used as a therapeutic tool [224]. As a

temporal comparison, Professor Kenji Takagi in Tokyo has traditionally been credited with performing the first knee arthroscopy as early as in 1919.

### 1.4.2 Indications, contra-indications and complications

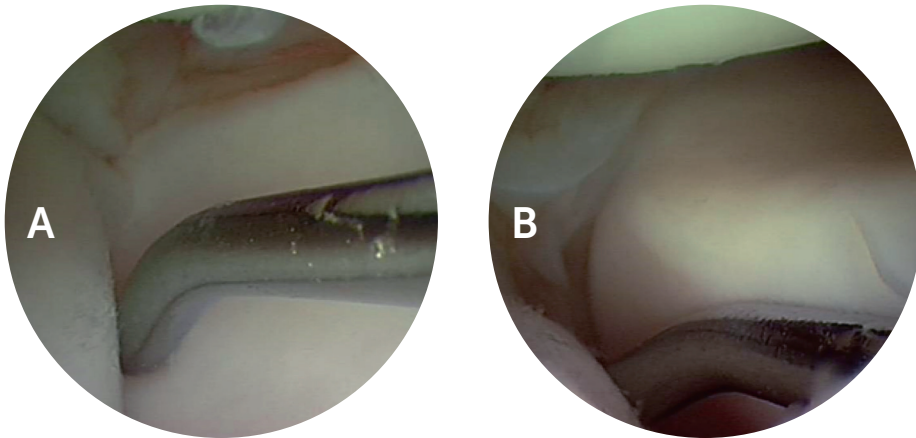
#### Indications

The indications for wrist arthroscopy are wide and vary considerably from performing a diagnostic procedure for chronic wrist pain to ligament reconstructive surgery and fracture reduction. Radiocarpal arthroscopy should always be accompanied by midcarpal arthroscopy, which is essential when making the diagnosis of SL and LT instability. The cartilage, ligaments and joint capsule can be assessed and the injuries can be evaluated in terms of dynamic instability, degree of injury (partial, total), quality of the tissue, reparability and healing capacity. The grading scale reported by Geissler et al. [92] provides a means of staging the degree of injury to the intrinsic ligaments and instability in order to choose the best type of treatment. Other similar grading scales are also described in the literature [138].

Table 7. Geissler's classification.

**EXPLANATION OF THE GEISSLER ARTHROSCOPIC CLASSIFICATION OF CARPAL INTEROSSEOUS LIGAMENT TEARS AND RECOMMENDATION OF TREATMENT:**

Grade I	Attenuation and/or haemorrhage of the interosseous ligament as observed from RC space. No incongruence of carpal alignment in MC space => Treatment by immobilisation.
Grade II	Attenuation and/or haemorrhage of the interosseous ligament as observed from RC space. Incongruence and/or step-off as observed from MC joint. A slight gap (less than the width of a probe, < 2 mm) between the carpal bones may be present. => Treatment by reduction and pinning.
Grade III	Incongruence and/or step-off of the carpal alignment are observed in both the RC and MC space. The probe may rotate and pass through the gap (> 2 mm) between the carpal bones. => Arthroscopic reduction or open reduction and pinning or repair.
Grade IV	Incongruence and/or step-off of the carpal alignment are observed in both the RC and MC space. Gross instability with manipulation is noted. A 2.7 mm arthroscope may be passed through the gap between the carpal bones ("drive through phenomena"). Total injury => Open reinsertion or ligament reconstruction.



Figures 33. No instability in the LT space, seen from the midcarpal view (A) and Geissler III instability (B) where the probe can be rotated in the LT space.

**COULD OTHER CLASSIFICATION SYSTEMS FOR INTRINSIC LIGAMENT INJURIES (SL, LT) BE RELEVANT IN TERMS OF HEALING CAPACITY AND CHOICE OF SURGICAL TREATMENT?**

### **Contra-indications**

Marked swelling, open wounds and large capsular tears that might lead to the extravasation of irrigation fluid are technical limitations and dry arthroscopy according to del Pinal et al. is then preferable [63, 65]. In their experience, this technique is as effective as the standard procedure, but without the disadvantages of fluid extravasation, which minimises the risk of acute compartment syndrome, especially during the arthroscopically assisted treatment of intra-articular radius fractures.

Bleeding disorders, neurovascular compromise and infection are other contra-indications for wrist arthroscopy.

### **Complications**

Wrist arthroscopy has the benefit of providing the surgeon with a tool for therapeutic intervention. Unlike MRI, it does, however, suffer from the limitation of being a surgical procedure, with associated risks of complications, however small, 2-5% in all [58, 67, 76, 239, 254], and the need for regional or general anaesthesia.

Complications in wrist arthroscopy are therefore rare. Severe complications such as deep infection and acute compartment syndrome are almost anecdotal. Dysesthesia and nerve damage in the area of the portals are, however, reported in approximately 2-3% of the patients

A systematic review in 2012 of studies related to complications of wrist arthroscopy in the literature yielded a complication rate of 4.7% [254], which is higher than the previously reported 2% [58, 67, 239]. A variety of complications have been reported, including nerve injuries, tendon injuries, tendon sheath fistulae, arterial injury, cyst development, development of carpal tunnel syndrome, de Quervain tenosynovitis, chronic loss of mobility, haematoma development, equipment-related burn injuries and local infections. It is possible that this rate may be an underestimation because of the small number of documented studies of wrist arthroscopy. Taken together, the complication rate is very low, if the surgeon is well experienced.

#### **1.4.3 Equipment, portals and settings**

Regional or general anaesthesia is needed. The RC and MC joints, together with the portals subcutaneously and the posterior interosseous nerve (PIN), are also pre-operatively injected with local anaesthesia. In general, a 2.4-2.7 mm 30°-angled scope attached to a fiberoptic light source and a digital camera system and monitor is used. In small wrists, a 1.9-mm arthroscope is sometimes necessary; the 1.9-mm arthroscope can also be used in thumb base arthroscopy. Traction (5-10 pounds) is needed, preferably using the ARC® tower, which greatly facilitates the instrumentation process, by various degrees of freedom in rotation and flexion/extension of the wrist and elbow, under control-

led conditions. A 2-mm hook probe is needed to palpate the intercarpal ligaments, TFCC, extrinsic ligaments, secondary stabilisers, capsule and cartilage. A motorised 2.9-3.5-mm shaver is used for debridement and a burr is needed for bony resection. VAPR for thermal shrinkage (partial SLL) [201] and suture repair kits (TFCC repair kit, Arthrex®) are also very useful for different treatment procedures. The arm is exsanguinated and a tourniquet is inflated (80 mmHg over the patient's pre-operative systolic blood pressure). The RC and MC joints are identified with a 22-gauge needle, inserted first in the RC joint sloped 10° palmar (normal volar inclination of a normal radius), and the joint is normally injected with 4-6 cc saline, which in the standard setting also flushes continuously through a pump.

The arthroscopic procedure described by Whipple et al. [247] is used. The standard portals for wrist arthroscopy are mostly dorsal (Figures 34-35), due partly to the good view of the important intercarpal ligaments and important volar structures and the relative lack of neurovascular structures on the dorsum of the wrist. The dorsal portals, which allow access to the RC joint, are named after their relationship to the ambient tendon sheaths (see below). The first portal to be established is the 3-4 portal, located at the soft spot in the interval between the third dorsal extensor compartment (extensor pollicis longus, EPL) and the fourth extensor compartment (extensor digi-

torum communis, EDC, and EIP). The 4-5 portal (between the EDC and the fifth compartment; extensor digiti quinti, EDQ) or the 6R portal (radial to the sixth compartment, ECU) is initially the "working portal" used for the hook and other instruments. Anatomic cadaver dissections have been performed, in order to measure the distances between the standard dorsal portals and neurovascular structures. The 1-2 portal (between the first extensor compartment, including the extensor pollicis brevis, EPB, and the abductor pollicis longus, APL, and the second extensor compartment, including the extensor carpi radialis brevis and longus, ECRB/L) was found to be the most dangerous, as branches of the superficial radial sensory nerve were located within a mean of 3 mm from that portal [2]. The MC joint is assessed through the midcarpal radial portal (RMC) and the often somewhat more available and accessible midcarpal ulnar portal (UMC). DRU portals, located 1-1.5 cm proximal to the 6R portal, are difficult to establish, but can be useful in assessing and estimating the quality of the DRUJ cartilage and the foveal insertion of the TFCC. An accessory 6R portal, located 1 cm distal to the 6R portal, is needed if arthroscopic re-insertion of the TFCC is planned. There is also a 6U portal, located ulnar to the ECU, and a specific portal for the STT joint. All the dorsal portals should always be established through a small transverse 4-5 mm long incision, just through the skin, followed by blunt dissection with a small pair of scis-

sors and a haemostat, to force other structures gently apart and to avoid unnecessary injury to sensory nerves and tendons.

Volar radial (VR) and volar ulnar (VU) portals can also be used, with an inside-out-technique through "safe zones" in the volar joint capsule, to assess the palmar aspects of the SLL and LTL and to repair dorsal capsular ligaments. Slutsky [210, 211] determined the safe landmarks for volar portals and showed that the median nerve is located within a mean of 8 mm ul-

nar to the VR portal, while the palmar cutaneous branch is located within a mean of 4 mm ulnar to that portal.

Dynamic assessment through careful provocation tests could be made through the whole arthroscopic procedure, if needed, together with laxity assessments in the MC joint (Geissler classification) of the SL and LT and estimations of steps and associated cartilage injuries. The TFCC is classified, according to Palmer and Atzei [26, 27, 173].

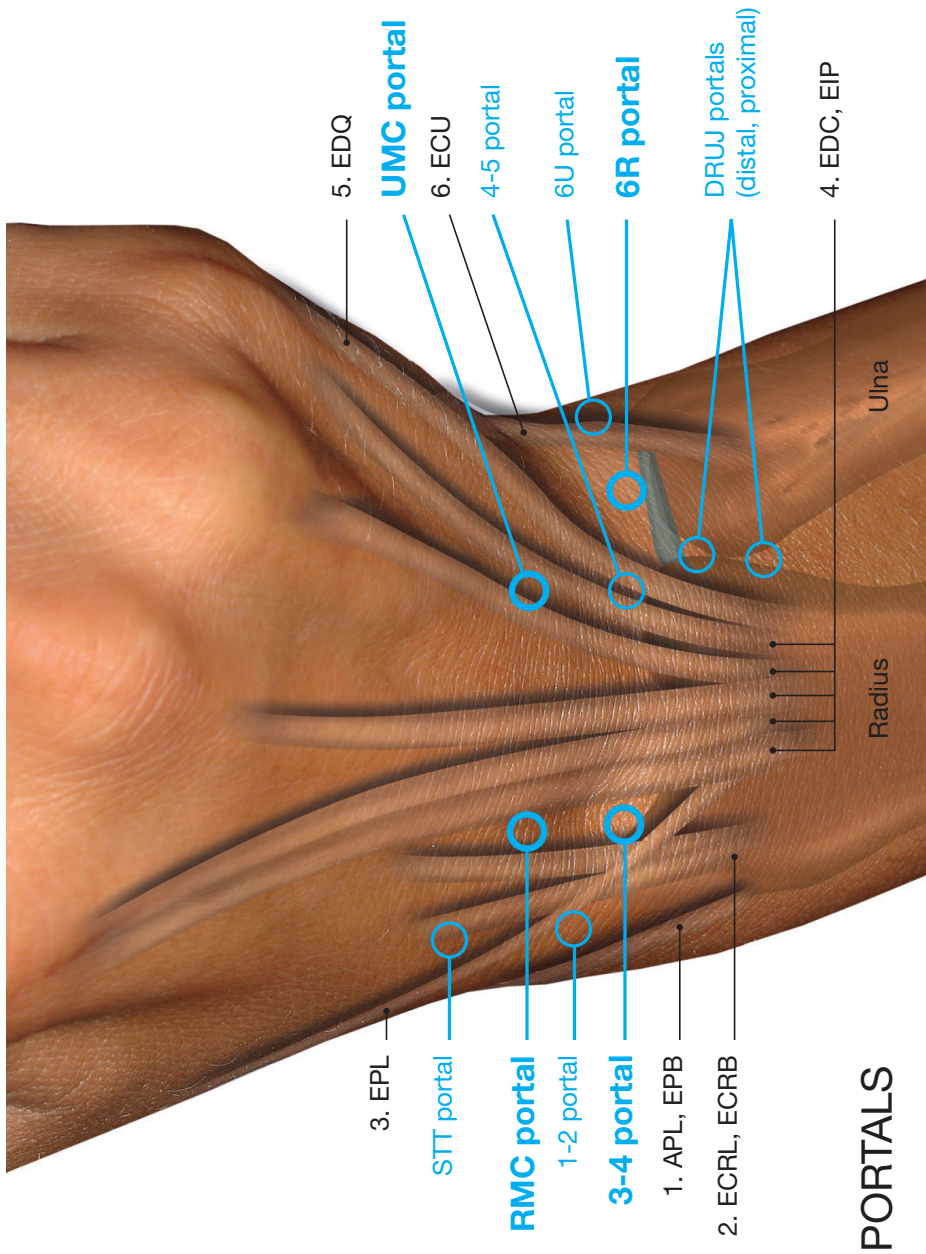
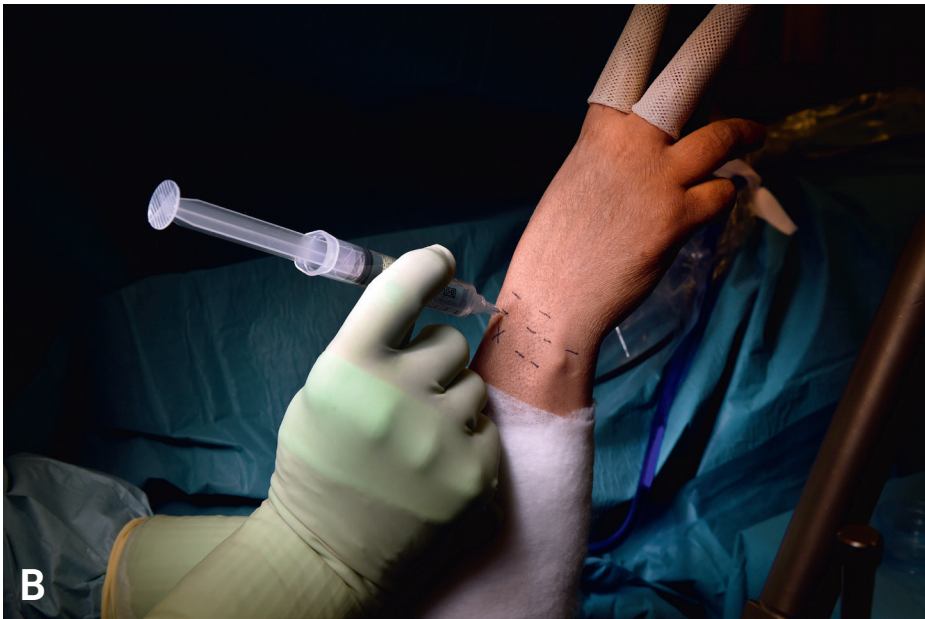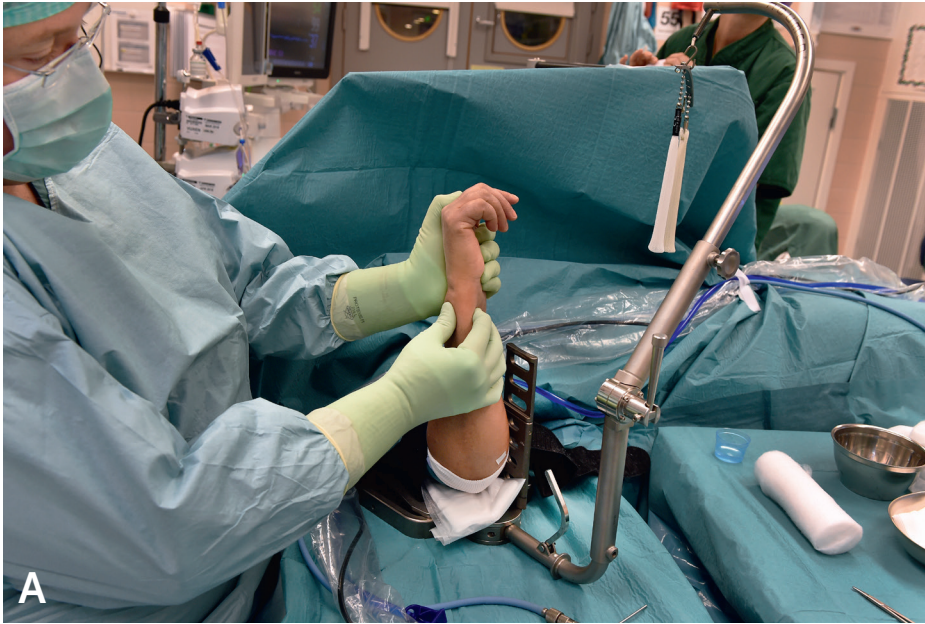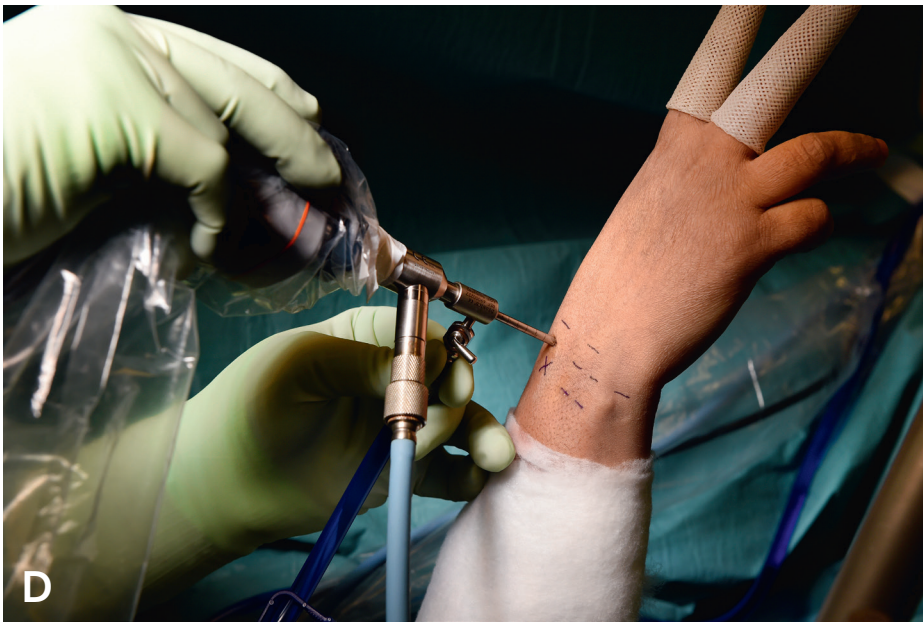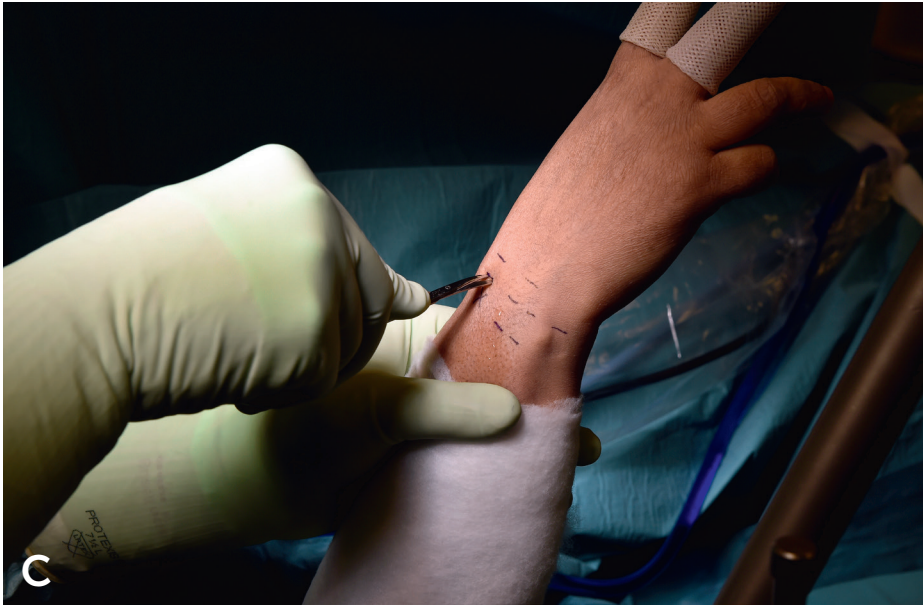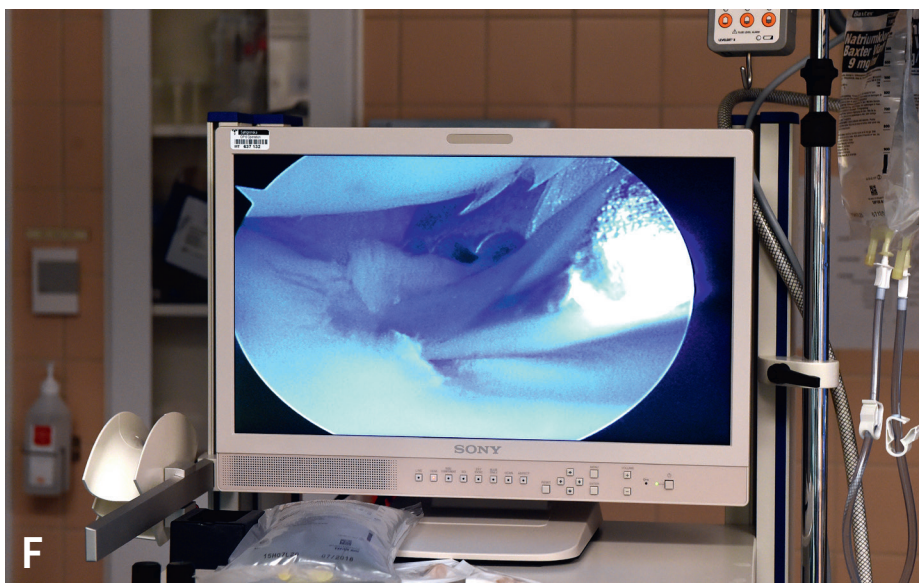


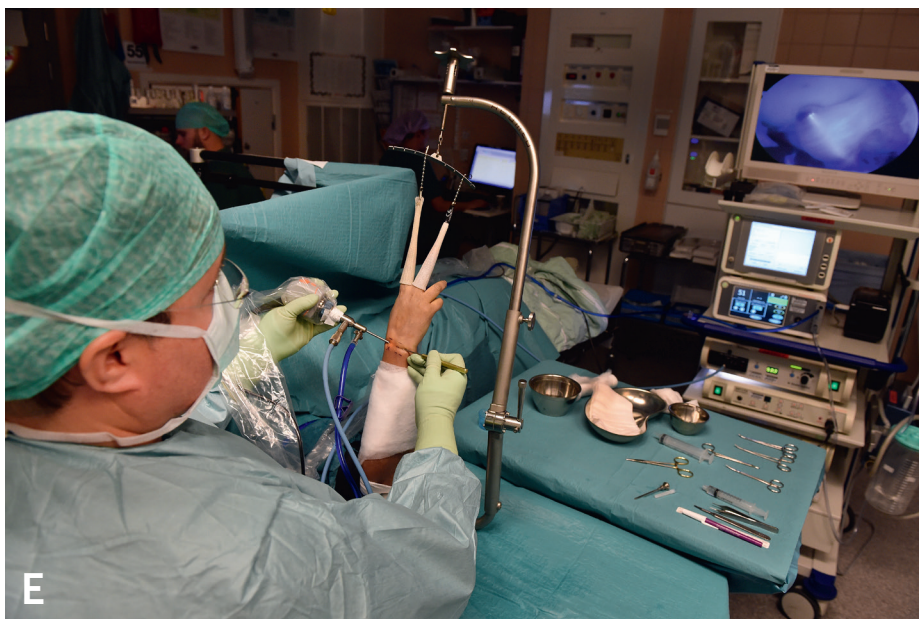Figure 34. The most used wrist arthroscopic dorsal portals. 3-4 portal (between the EPL and EDC, EIP), 4-5 portal (between the EDC, EIP and EDQ), 6R portal (radial of ECU), 6U portal (ulnar of ECU), RMC =radial midcarpal, UMC =ulnar midcarpal. The DRUJ portals and the STT portal are also shown.  
 Copyright © Jonny Andersson









Figures 35. Wrist arthroscopy technique. The DRUJ laxity test and other provocation tests are performed prior to surgery (A). The portals are marked and local anaesthesia is injected into the RC joint (B). A gentle blunt dissection is performed (C) before introducing the 2.4 - 2.7 mm arthroscope in the 3-4 portal (D) and the 2-3 mm probe in the 6R portal (E), followed by a small joint punch (F).

Photos: Tommy Hall

A thorough examination should be made, following a standardised protocol (for example see Appendix 3). Under direct vision, the different structures should be probed with a hook and stress tests ought to be performed in order fully to define ligament tears and the degree of mobility.

According to Lindau [136], there is convincing evidence supporting the role of arthroscopy in the diagnosis and assessment of factors involved in the development of carpal instability, but evidence of the effectiveness of arthroscopic treatment of the condition of carpal instability is weak.

#### 1.4.4 Injury to the scapholunate and lunotriquetral ligaments

Injuries to the intrinsic carpal ligaments can be visualised from the RC joint – the SLL from the 3-4 portal and the LTL preferably from the 6R portal. It is important not only to assess the unimportant and insignificant proximal membranous portion of SLL but also to proceed all the way up to distal, visualising the dorsal component of the SLL. Otherwise, it is easy to overestimate the degree and severity of the injury. The ligaments and the degree of laxity in the SL and LT joint can be assessed in a dynamic manner, adapting careful wrist provocation tests, during the arthroscopy.

Arthroscopy through the MC portals is always mandatory for the diagnosis of injury and the assessment of instability degree, when it comes to SL and LT ligament injuries.

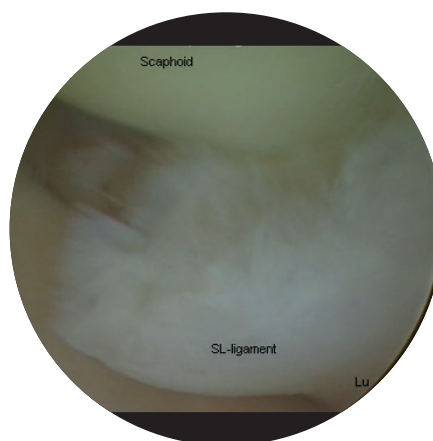


Figure 36. Avulsion injury of the SL ligament from the scaphoid with a steep step, diagnosed by arthroscopy from the RC view.

#### 1.4.5 Injury to the triangular fibrocartilage complex

The different parts of the TFCC (avascular disc, RU ligaments, UC ligaments) are examined and probed. An attempt is also made to assess the strength of the foveal insertion, by performing the so-called hook test (lifting up the TFCC with the hook) and the trampoline sign (testing the bounce and elasticity of the central portion of the ligament) [244], visualised in Figures 37-38. However, full examination of the foveal insertion can only be made through a DRU portal. It is important to note that laxity of the TFCC, demonstrated by the so-called trampoline test, does not necessarily translate into instability and laxity of the DRUJ.

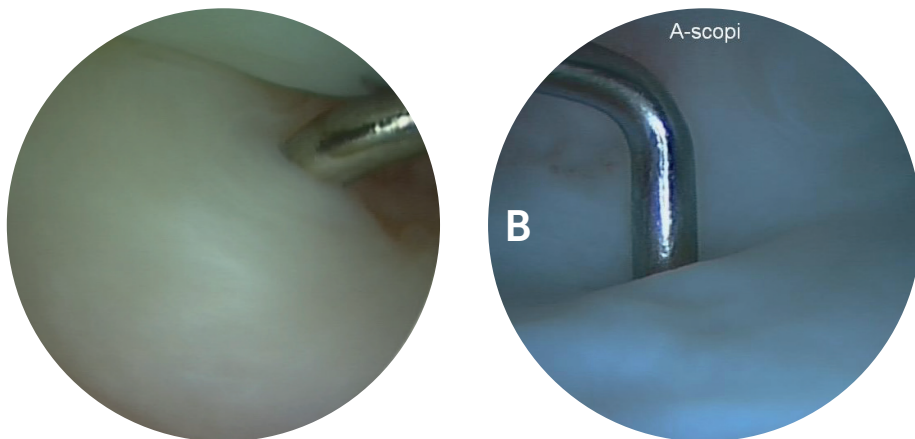
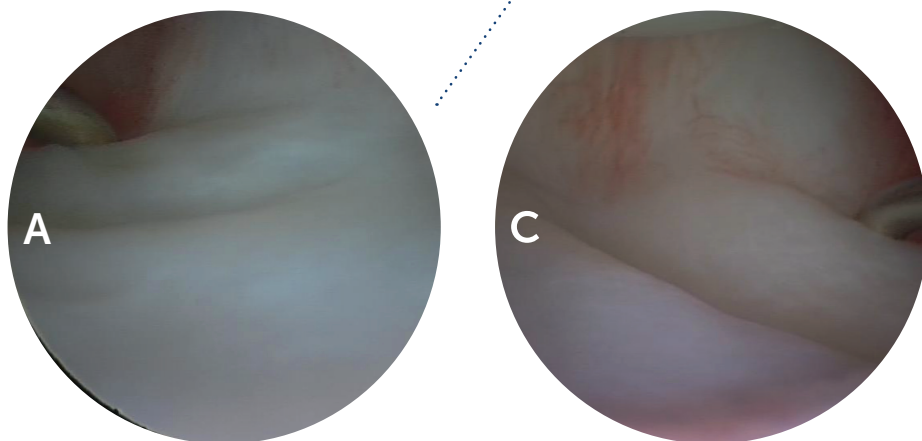


Figure 37. TFCC 1 B injury, with a positive hook sign. The hook at 2 o'clock is located under the TFCC. Right wrist.



Figures 38. Testing the trampoline effect, with the probe at 10 o'clock under the TFCC (A), above the TFCC (B) in a left wrist, and 3 o'clock (C), pushing the TFCC, establishing a so-called "wave phenomenon", in a right wrist.

Arthroscopy is the only reliable method for assessing the severity of ligament injuries of the wrist [15, 111], but surgical experience and skills differ somewhat between examiners and the inter- and intra-rater reliability

of arthroscopic evaluation is moderate [143, 144]. Rettig and Amadio [181] have reported an error rate, even for experienced arthroscopists, for wrist arthroscopy of 6% in 57 patients who also underwent open surgery.

## 1.5 Treatment of wrist ligament injuries and its complications

### 1.5.1 Non-surgical treatment

The muscles around the wrist act in different ways and play different roles in the neuromuscular control of the carpus. They can act as stabilisers or destabilisers of the joint, depending on whether or not the carpal ligaments are intact. The ECU and FCR generate a pronation moment of the distal carpal row, which is beneficial in most carpal instabilities and plays an important role in neuromuscular control and the dynamic stability of the DRU joint and the MC joint. Selective training of the FCU (i.e. maximum selective flexion of the little finger during maximum fist) and ECU and PQ is claimed to produce an increase in MC and DRUJ stability.

A combination of proprioceptive, neuromuscular training and physiotherapeutic treatment regimens appears to yield the greatest improvement in the sensorimotoric control and stability of joints in terms of both rehabilitation and treatment strategies [13, 250]. However, the more exact role of wrist proprioception and neuromuscular stability training after wrist ligament injuries and carpal instability and DRUJ instability needs to be further elucidated [232]. Studies of the role of proprioceptive training and training with neuromuscular control after ankle and knee ligament injuries [10, 11, 72, 250] have, however, suggested

that an effective re-educational neuromuscular training programme can reduce the need for later surgery, especially in patients with less exacting demands.

In terms of surgery of the wrist, it is important to minimise damage to the innervation of the wrist joint (i. e. posterior interosseous nerve in dorsal approach), to maintain the important mechanoreceptors and free nerve endings in the ligaments, which are important for sufficient neuromuscular reflex control [97] and accordingly the dynamic stability of the wrist. Free nerve endings and ligaments need blood supply for survival.

Functional forearm bracing may be effective in reducing the instability of the DRUJ without greatly restricting motion of the wrist, forearm, or elbow [154].

Injections of corticosteroids intra-articularly (if synovitis) or in the ECU tendon sheath (if tendonitis) can be helpful initially before physiotherapy training.

Hyaluronic acid (HA) is again recommended for the appropriate patients with knee OA, based on a recently published meta-analysis [229]. In terms of wrist pain, there is only one recent study which highlights treatment with HA in conjunction with wrist arthroscopy [199]. According to this study, the benefit of therapeutic wrist arthroscopy can be improved

by the intra-articular substitution of hyaluronan on two occasions. While patients with additional HA injections had significantly better values in one of two patient-reported outcome measurements, no significant differences were observed in absolute grip strength and pain intensity.

### **1.5.2 Surgical treatment**

#### ***Scapholunate ligament injury and instability***

##### **Treatment of acute-subacute SL injury**

SL injury and deficiency and its treatment remain an unsolved problem in wrist surgery. The rupture of all parts of the scapholunate interosseous ligament, including the strongest dorsal part, is likely to progress to carpal instability with a predictable pattern of degenerative osteoarthritis, known as SLAC (scapholunate advanced collapse) wrist [241]. Failure to diagnose and treat SL injuries, especially in the young adult with high demands, can lead to the progressive deterioration of function, instability, pain, loss of grip strength and finally articular damage [217, 242, 243]. Acute total SLL injuries need to be treated within four to six weeks after trauma with suture repair or re-insertion and pinning. Partial injuries are not best treated by open surgery. The treatment options are instead arthroscopic debridement or thermal shrinkage, pinning, or physiotherapy with the re-education of the FCR. It is crucial to diagnose the SLL injury in the acute stage, as chronic

SL instability is very difficult to treat because of its complexity. Many different methods have been suggested in the past [46, 56, 57, 87, 101, 133], some with promising results and some with less promising results. It is clinically difficult to treat SL ruptures and the results are inconsistent [142, 157]. The injury is often missed because of difficulties in the clinical diagnosis and initial normal plain radiographs. Even if the SLL injury is diagnosed acutely, the ligament remnants are often short and retracted, making it difficult to re-attach the ends. The SL complex is also exposed to great tension and torsion and must be able to sustain great loads. Because of these factors, it is not unusual for SL repairs to deteriorate with time. By all appearances, the best treatment for scapholunate dissociation is early surgical intervention performed directly when the diagnosis is made. This provides the best opportunity to restore the anatomy and prevents unfavourable attritional changes in the SLL and the secondary stabilisers of the wrist. The dorsal SLL plays a very important role in the stabilisation of the loaded carpus, but its importance should not be overemphasised. In low-demand patients, good status of the secondary stabilisers with compensatory effects from the adjacent capsule-ligamentous structures and the dynamic strength of specific muscles may sometimes effectively ensure good carpal stability, at least for some years [191]. In general, however, if an SLL rupture has not healed, the risk of progressive joint deterioration

and SLAC development is clear. The wrist ought to be better prepared to sustain loads if the SL is functional. Treatment options are based on clinical stage at presentation and the time that has elapsed since injury. Acute injuries are arbitrarily defined as those presented within four weeks after the initial trauma, subacute injuries as those presented at four weeks to six months and chronic injuries as six months after the initial trauma. While the ideal time for acute repair has not yet been defined, all intrinsic ligaments tend to undergo rapid degeneration in as short a time as two to six weeks, after which primary repair may be difficult or even impossible and meaningless [88]. Early diagnosis and open repair is still the gold standard and is strongly advocated. Capsulodesis is recommended for augmentation simultaneously with ligament repair but not as an isolated treatment. Direct open repair with ligament sutures, osteosutures, or bony fixation with bone anchors supplemented by K-wire fixation and/or capsulodesis [51, 52, 131] produces good results in the short and mid-term. Direct repair of the SLL is recommended for complete tears if there are no signs of arthritis and when the secondary wrist stabilisers remain normal. During open surgery, it is possible directly to inspect the cartilage and look for concomitant ligament and chondral lesions. The most important dorsal component of the SLL is the one that most often can be directly repaired. There are no ideal treatment options in the subacute set-

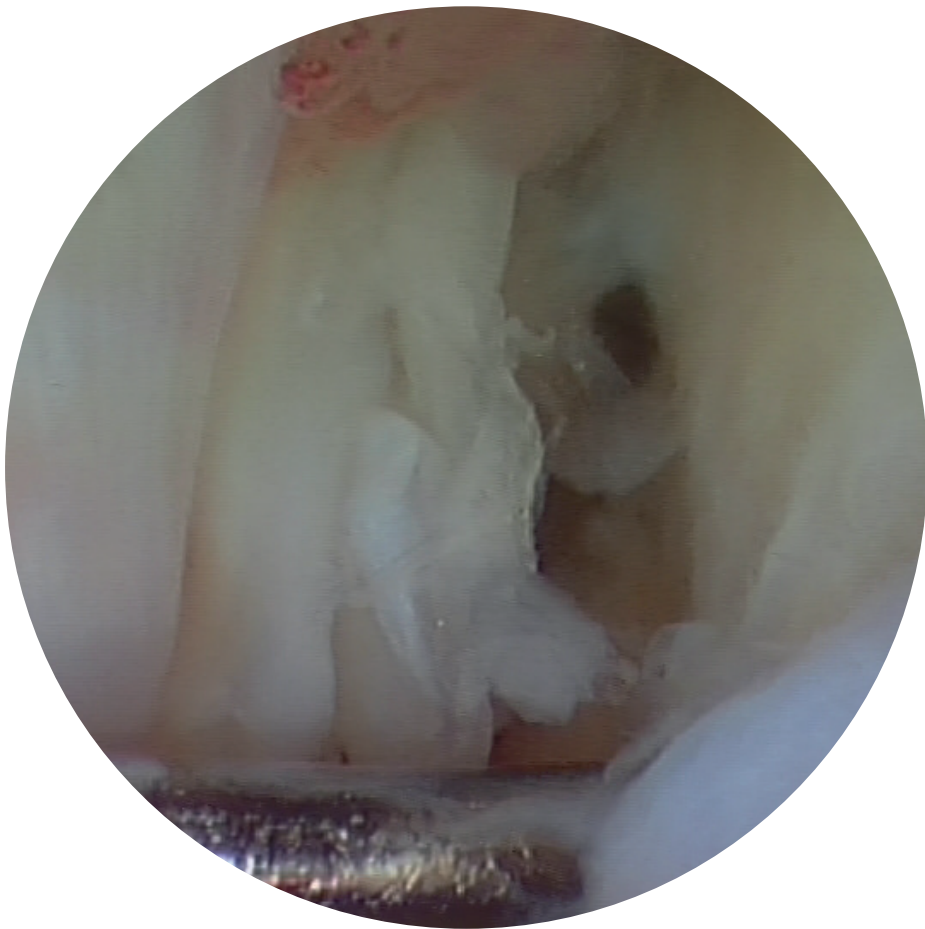
ting for the volar part of the SL, as an open volar approach requires incision through the important secondary stabilisers. A longitudinal dorsal incision centred over the scapholunate interval is used. The dorsal retinaculum is divided along the third compartment; the fourth compartment is subperiosteally reflected ulnarly. The wrist joint is exposed through a longitudinal capsular incision or with a ligament-sparing technique according to Berger and Bishop [36]. The dorsal and proximal membranous portion of the SLL is evaluated. Once reduced anatomically, percutaneous pin fixation from the scaphoid into the lunate and from the scaphoid into the capitate is performed. This pinning technique has been shown to be the strongest method [114]. The ligament is then repaired using free needles, sutures, osteo-sutures and/or bone anchor sutures, depending on the type of injury. In some cases, it is easier to place the sutures into the ligament prior to the final reduction and then simply tie them all once the SL joint has been reduced and stabilised. A straight direct repair with sutures or suture anchors has remained a reliable technique in the acute setting, but the open technique is limited to the correction of the dorsal part of the SLL. Biomechanical research has previously indicated that only the dorsal SLL needs to be repaired to achieve relatively normal carpal kinematics in cadavers, but this has subsequently been the subject of debate in recent studies [56, 57, 121, 127].

The mid-term outcome after open subacute SL repair overall shows that more than 70% of the patients will have a significant improvement in pain, grip strength will reach approximately 85% of the normal wrist and motion will become almost 80% of that of the normal side [51, 52, 131]. Radiographic degenerative changes in the long term occur in fewer than 30% of patients. Exact reduction and percutaneous K-wire fixation with or without augmentation with dorsal capsulodesis has also been recommended for acute partial and total tears. Exact reduction and K-wire fixation without open suture [60, 246, 248] has shown good to excellent results in patients with an acute or subacute presentation of SL rupture. Exact reduction, preferably under arthroscopic control in acute cases, is necessary when using this method of pinning alone. Pins should be left in situ for eight weeks. However, there are some inherent problems with pin fixation, including limited stability of fixation and the risk of pin migration, breakage and infection. Some studies have shown that the so-called RASL (reduction and association of the scaphoid and lunate) procedure, e.g. a temporary screw augmentation between the scaphoid and lunate, for four to six months, results in more effective SL-gap reduction and SL-angle correction [29, 186] both immediately and at the short-term follow-up compared with pin fixation. However, no long-term follow-up data related to

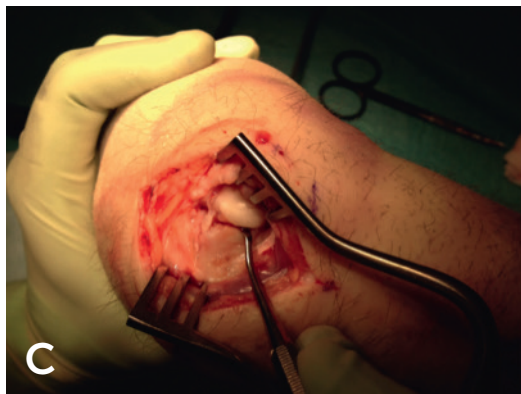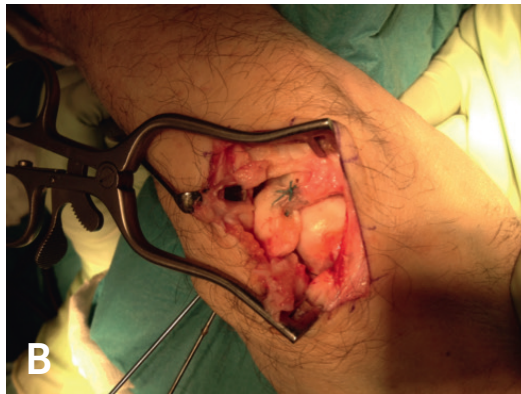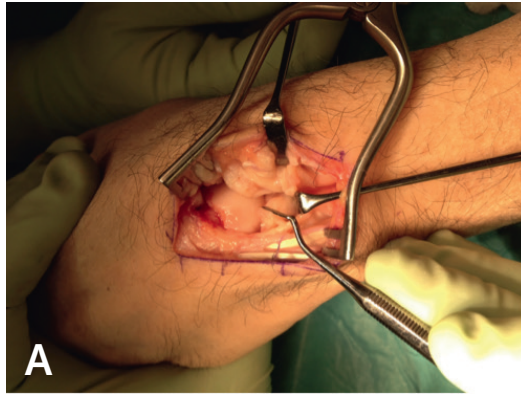
these techniques are available. It could be argued that it is not particularly appealing to have a large screw passing through the poorly vascularised scaphoid. The use of this technique is still the subject of debate. When the direct repair is weak and difficult because of poor quality in the ligamentous tissue remnants, dorsal capsulodesis has been recommended by some surgeons. After the acute phase (four to six weeks), the ligament is believed to heal poorly and it is therefore optimal to intervene soon after the injury. If the appropriate conditions in terms of reducibility and healing are met, direct ligament repair and capsular augmentation may be used in some cases, even if the injury is older [51, 52]. Direct repair and augmentation with a dorsal capsulodesis in chronic cases with dynamic scapholunate instability also appears to be favourable in the short term in some patients, according to Cohen and Taleisnik [51, 52], although the results appear to deteriorate both clinically and radiographically with time in patients who place high demands on their wrist.

Arthroscopic suture techniques of the SL and concomitant dorsal capsuloplasty have also recently been described [64, 66, 147, 148]. Some of these studies should, however, be critically analysed, as most of the included patients appear to have had partial injuries.

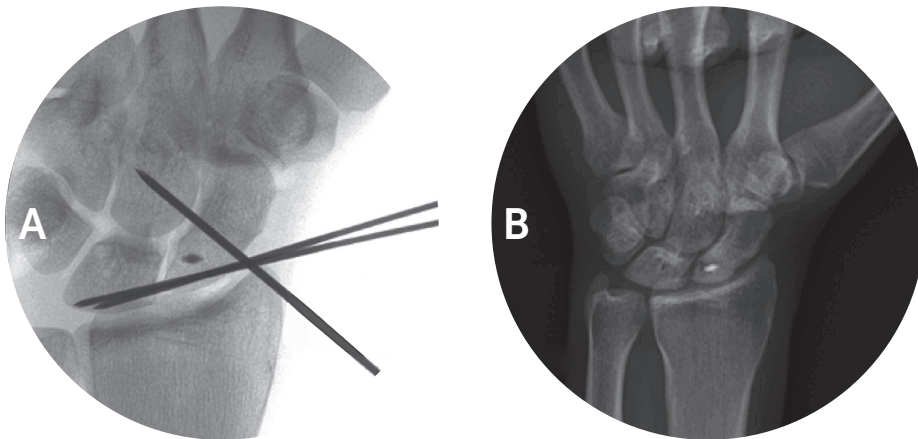




Figures 39. Arthroscopic diagnosis of a total SL injury in a left wrist, a so-called Andersson-Garcia-Elias Type 1 a – ligament avulsion off the scaphoid, according to our new proposed classification in Study III.



Figures 40. Open surgery diagnosis of an SL ligament avulsion injury, diagnosed as Type 1a, according to Andersson-Garcia-Elias classification (A). The SLL is repaired with suture anchor and osteosutures (B). (C) shows an SL elongation injury - Type 4, according to Andersson-Garcia-Elias. Right wrist.



Figures 41. Plain radiographs (A/P view) of open SL re-insertion (per-operative view) (A) and at the 1.5-year follow-up (B).

### WHICH OTHER FACTORS CONTRIBUTE TO THE CHOICE OF TREATMENT FOR AN SL INJURY?

#### Treatment for chronic scapholunate dissociation and SLAC wrist

The choice of procedure for SL injury [49, 121] in the absence of arthritis depends on the extent of the lesion, quality of the ligament remnants and reducibility of the joint.

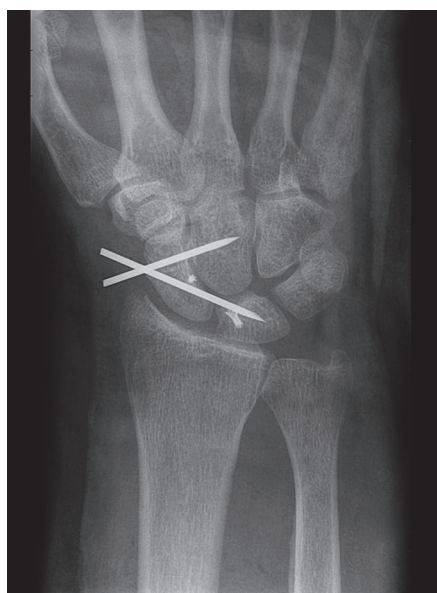
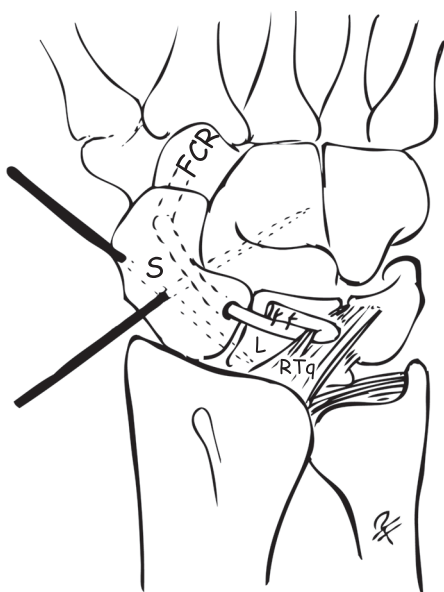
Older injuries with dynamic instability which is still reducible can be treated by some kind of ligament reconstruction.

Various tendon reconstruction techniques for the SL have been described in the past and the techniques have evolved considerably. In the early 1990s, a dynamic tenodesis using a strip of the extensor carpi radialis longus tendon (ECRL) [142] was reported to improve grip strength compared with pre-operative measurements.

A strip of the ECRL tendon is left attached distally and is passed through a drill hole made from the dorsal aspect of the distal scaphoid to the palmar tuberosity to create a dorsal tether, preventing scaphoid flexion collapse. Once in the palmar side, the tendon is passed intra-articularly around the scaphoid waist to emerge in the dorsal incision. To close the SL gap, the strip of tendon is passed under the dorsal fibres of the lunotriquetral ligament, looped around itself and then pulled tight to maintain the lunate reduced. In 1995, Brunelli and Brunelli [46] suggested the use of a strip of the flexor carpi radialis (FCR) tendon to adjust both the distal and proximal parts of the scaphoid instability with rotatory subluxation. The strip of FCR is passed through a transverse hole drilled

across the distal scaphoid to the dorsal part of the scaphoid neck and then anchored to the ulnar part of the distal radius. Van Den Abbeele [233] modified this technique and suggested anchoring the FCR onto the dorsal part of the lunate or the dorsal radiotriquetral (RTq) ligament instead of crossing over the radiocarpal joint. In chronic

cases (more than six months), tenodesis and ligament reconstruction of the SL with a part of the FCR tendon may be effective in the short term but often deteriorates with time. Incorporating features from three previously described techniques, the three-ligament tenodesis (3LT) technique (Figure 42) appears to be an improvement.



Figures 42. The three-ligament tenodesis (3LT). A - schematic drawing (Illustration: Dr Per Fredriksson). B - Radiological appearance. (S= scaphoid, L= lunate, RTq= dorsal radiotriquetral ligament, FCR= flexor carpi radialis).

Using this technique, the FCR tendon is used to augment the palmar-distal connections of the scaphoid (which enhances and replicates the STT ligaments), the dorsal SLL is reconstructed and the ulnar translation of the lunate is reduced (which enhances the dorsal RTq ligament) [87]. A longitudinal incision is made, centred over Lister's tubercle and the capitate. A distally based strip of the FCR tendon approximately

8 cm long and 3 mm wide is harvested and passed through a drill tunnel from the palmar tuberosity of the scaphoid to the point of insertion of the dorsal SLL. The lunate should be easy to reduce, otherwise this technique is not recommended. A channel over the reduced dorsum of the lunate is carved with a rongeur and an anchor suture is placed in the cancellous bone. The FCR strip is then tightened through a

slip in the RTq ligament and sutured once again to itself under tension. K-wire fixation between the scaphoid and lunate and scaphoid-capitate should remain in place for eight weeks. This 3LT technique has shown promising results, with significant improvements in pain and improved alignment but reduced motion and grip strength. In general, modified Brunelli ligament reconstruction and tenodesis using tendon grafts produces satisfactory results when it comes to correcting reducible chronic SL instability in wrists without pre-operatively notable osteoarthritis. This repair technique achieves a relatively pain-free wrist, with acceptable grip strength and normal SL distance, but with loss in the arc of motion and sometimes a loss of long-lasting correction of the SL angle. Garcia-Elias et al. reported a series of 3LT repairs involving 38 patients [87] with a follow-up of approximately four years, in which they found that 75% of the patients returned to their normal occupational/vocational activities and experienced significant pain relief at rest. The patients regained approximately 75% of flexion and extension motion on average compared with the non-injured contralateral side. The average grip strength was 65% relative to the contralateral side. A recurrence of carpal collapse and DISI occurred in only 5% of the patients.

There are now also arthroscopically assisted ligament reconstruction methods that aim to reconstruct both

the dorsal and volar part of the SLL, as described by Corella et al., for example [56, 57]. With this approach, it is possible to reconstruct the dorsal scapholunate ligament and the dorsal and volar secondary stabilisers while causing minimal damage to the soft tissues and avoiding injury to the volar secondary stabilisers, the posterior interosseous nerve and detachment of the dorsal intercarpal ligament.

The procedure of dorsal capsulodesis was previously used alone, when the SLL was not adequate for primary repair. This technique is now used in conjunction with primary SLL repair. Dorsal capsulodesis was first described by Blatt [42]. He used a proximally based strip of the dorsal wrist capsule to create a dorsal tether to the distal scaphoid for stabilisation and to prevent the tendency towards volar flexion and rotatory subluxation of the scaphoid. Alternatives are the method described by Linscheid and Dobyns [142], who used a strip of the dorsal intercarpal (DIC) ligament, and the Herberts method with a distally based capsular flap. However, the use of a dorsal capsulodesis [84, 209] alone for the treatment of chronic static scapholunate instability is not enough. In a recent study in 2012, Megerle et al. followed the mid-term (mean 8 years) results for 50 patients who underwent dorsal capsulodesis with a strip of the DIC ligament [152]. After significant improvement directly post-operatively, the mean scapholunate and radiolunate angles deteriorated to pre-ope-

rative values at final follow-up and the authors showed that capsulodesis alone was unable to maintain carpal reduction over time. They also found some evidence of early degeneration. Dorsal capsulodesis alone is not a recommended technique nowadays.

In cadaveric and clinical studies, the strength of bone-ligament-bone grafts [101, 165, 236] has been shown to be similar to that of the normal ligament. More commonly used grafts are bone-retinaculum-bone, second or third metacarpal-carpal bone, or hamate-capitate grafts, with or without screw augmentation. There is some lack of long-term results for this type of surgery, which makes it difficult for hand surgeons to determine its appropriate use. Early results have indicated that this method could play an important role in the treatment of scapholunate dissociation in the future [101], but the consolidation of the graft in this compromised area is difficult and this technique still needs further research. Van Kampen et al. state that they have abandoned the technique of bone-ligament-bone graft for scapholunate injury for other less technically demanding procedures [236].

A new method, the SL axis method (SLAM) for SL-ligament reconstruction, has also shown promising results in a cadaveric study. The SLAM appears to achieve an improved and closer SL interval and better SL-angle correction compared with conventional techniques of SL-ligament re-

construction, according to Lee et al. [133]. The method provides compression centrally and thereby improves the strength of both the dorsal and volar parts of the SL joint. No clinical results related to this method have so far been reported.

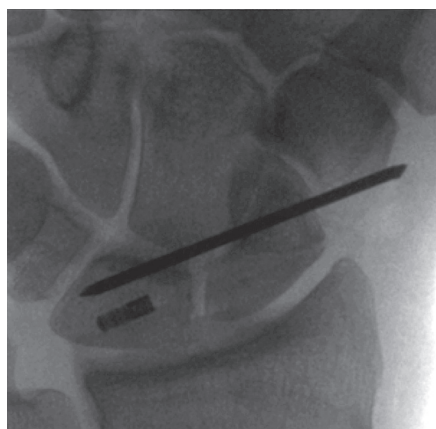


Figure 43. Plain radiograph (A/P view) of the SL axis method (SLAM), with a centrally fixed tendon graft in the lunate.

In symptomatic static irreducible scapholunate dissociation (SLD), the most commonly advocated treatment is partial fusion. SL fusion is probably the least reliable option, with small areas of bone contact and a high separating force in the SL interval by the capitate. Non-union has been reported in approximately 50% using this method. STT fusion is a more difficult but more reliable option, with an average rate of non-union in all reported series of 14% [88, 89, 241, 242, 243]. The goal is to re-align the proximal pole of the scaphoid with the scaphoid fossa of the radius. It is important to

maintain the external proportions of the bones and to achieve correct alignment of the scaphoid with a radioscapoid angle of between 40° and 60°. Over-reduction must be avoided because of restricted motion and impingement. Under-reduction with a preserved SL gap can also be a problem. SC arthrodesis has the same kinematic carpal behaviour and the consequences are the same as for STT fusion with abnormal load transfer and the loss of midcarpal range of motion. This means that one-third of the reduction in flexion and only half the radial deviation remain. Despite this, the results so far are fairly promising from the short experience to date, with 75% grip strength and little disability. Most daily activities involve the dart-throwing motion (extension-radial deviation to flexion-ulnar deviation) [85, 86] and this motion occurs in the midcarpal joint. Radioscapholunate (RSL) fusion and distal scaphoidectomy could therefore be a good choice, especially if there are degenerative cartilage changes in the radiocarpal joint and the midcarpal joint is normal. The early results of this fusion published so far are promising.

The surgical management of the degenerative wrist due to SLAC is still a challenging choice among several different surgical options. Total wrist fusion historically provides predictable pain relief at the cost of a complete loss of motion and shock absorption. The complication rate in total wrist fusion is also relatively high (approx-

imately 15%). In the event of an SLAC wrist, only some kind of salvage operation can be recommended. Wrist denervation can only be used selectively. In SLAC I, a radial styloidectomy may relieve the pain and postpone further surgery. In SLAC II, the most used options are proximal row carpectomy (PRC) or four-corner fusion (4CF). In the short term, these two operations produce similar results with pain relief and an ROM (range of motion) of flexion 30° to 40°, extension 30° to 40° and 75% maintained grip force [163, 192, 235].

In SLAC III (midcarpal arthritis), the only alternative is 4CF or perhaps PRC plus resurfacing of the proximal part of the capitate with RCPI (resurfacing capitate pyrocarbon implant). In older patients, with a low ROM pre-operatively and a round and blunt-shaped capitate, PRC can be recommended. In patients younger than 35 years or with a pointed, peaked and narrow capitate, 4CF can be recommended. Some scepticism is, however, in order in terms of the long-term viability of a joint with a completely mismatched articular surface between the capitate and the lunate fossa of the radius. Long-term radio-capitate degeneration after more than 10 years of follow-up is, however, often asymptomatic and generally only present in about 10%-20% of patients after PRC. However, several other studies have reported a significantly larger number of patients with secondary arthritic changes after PRC, although most are symptom free. There is a lack of

well-conducted studies, but Mulford et al. [163] reported and confirmed in a systematic review that both 4CF and PRC produce a clear improvement in pain and subjective outcome measurements for patients with symptomatic SLAC wrists. PRC can perhaps provide a better post-operative ROM, with less risk of the potential complications specific to 4CF (10% more complications occurring; such as non-union, hardware problems and dorsal impingement). This systematic review reported that the risk of subse-

quent osteoarthritis, albeit most often asymptomatic, is significantly higher after PRC. Subjective outcomes and quality of life, pain relief, motion and grip strength appear to be similar in both groups.

Total wrist fusion is an option in SLAC IV, but, particularly in the United States, total wrist replacement has increased in number in the last few years, as the survival rate of the new generation of arthroplasties has increased markedly [55].

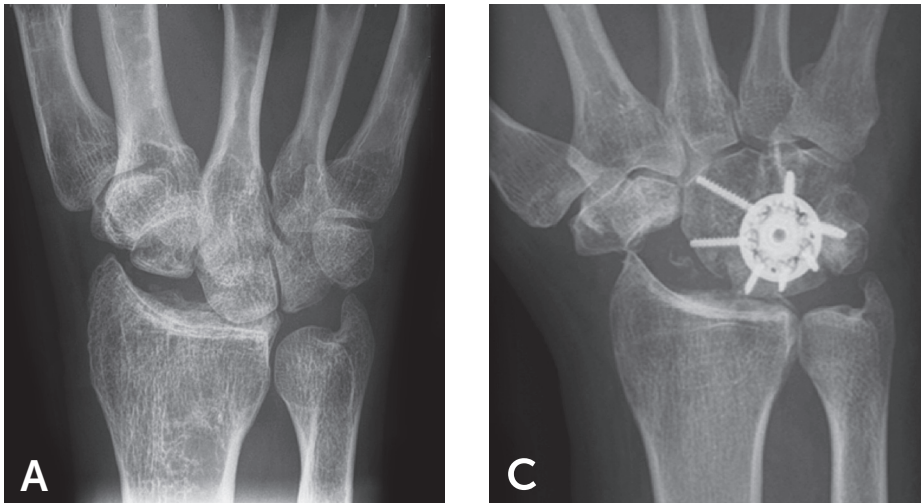


Figure 44. Plain radiographs (A/P view) of proximal row carpectomy (PRC) (A) and four-corner fusion (4CF) (B).



Table 8. Treatment of SL ligament injury in different stages.

SL-LIGAMENT INJURY -DIFFERENT STAGES	STAGE 1 PRE-DYNAMIC OC-CULT INSTABILITY, PARTIAL TEAR	STAGE 2 DYNAMIC INSTABILITY	STAGE 3 STATIC INSTABILITY, NO DISI AND EASILY REDUCIBLE	STAGE 4 DISI	STAGE 5 SLAC
Injured ligaments	Partial SL injury (volar)  Dorsal SL ligament intact	Incompetent dorsal SL ligament or  Total SL ligament complex injury + partial injury or  Attenuation of volar secondary stabilisers	Complete SL injury and injury or  Attenuation of volar or dorsal secondary stabilisers	Complete SL injury with secondary changes of all secondary stabilisers	As in Stage 4
Static radiographs	Normal	Usually normal	SL gap $\geq 3$ mm	SL gap $> 3$ mm  +  SL angle $> 60-80^\circ$	I Arthritis: radial styloid  II Arthritis: radioscapoid  III Arthritis: midcarpal  IV Panarthritis
Stress radiographs	Normal, but abnormal fluoroscopy	Abnormal	Grossly abnormal	Unnecessary examination	Unnecessary examination
Choices of treatment	Arthroscopic debridement or thermal shrinkage, pinning or capsulodesis, or  Physiotherapy with re-education of FCR	Open SL- repair or  Re-insertion with dorsal capsulodesis as an augmentation	Open SL- repair with capsulodesis or 3LT-ligament-reconstruction or other similar ligament reconstruction	<u>Reducible:</u> 3LT-ligament-reconstruction  <u>Fixed:</u> Some kind of intercarpal fusion	I Radial styloidectomy  II 4CF or PRC  II 4CF or PRC + RCPI  IV Total wrist fusion or total wrist replacement

Abbreviations: DISI= dorsal intercalated segment instability; FCR= flexor carpi radialis; 4CF= four-corner fusion; PRC= proximal row carpectomy; RCPI= resurfacing capitate pyrocarbon implant; SL= scapholunate; SLAC= scapholunate advanced collapse; 3LT= three-ligament tenodesis

### Lunotriquetral ligament injury and instability

The management of LT lesions should be based on both the chronicity of the injury and the laxity of the LT joint. Non-surgical treatment or minimally invasive approaches, such as temporary arthroscopic pinning of the LT joint in mild cases (i.e. without dissociation or VISI deformity), are emphasized [234]. Dissociative LT injuries without VISI deformity, either acute or chronic injuries not responding to non-surgical treatment, may benefit from surgical intervention. The available data suggest that ligament repair provides good outcomes in this group [234]. Accordingly, temporary arthroscopic pinning and debridement are minimally invasive procedures that can be recommended when it comes to acute or old partial to subtotal LT injuries. When more dissociative LT injury and instability is present, soft tissue repair of the LT ligament or reconstruction using a strip of the FCU or ECU through drill holes in the triquetrum and lunate bones could be effective procedures. Fusion of the LT joint could be a good choice in older injuries, but the rate of non-union appears to be high – a mean of approximately 30% but up to 57% has been reported [200, 234].

Ulnar shortening osteotomy can also be a valid treatment option when it comes to improving grip strength and reducing symptoms in patients with post-traumatic isolated LT injuries [155], as well as in patients with con-

comitant partial TFCC injuries, especially in those who have a concomitant positive ulnar variance.

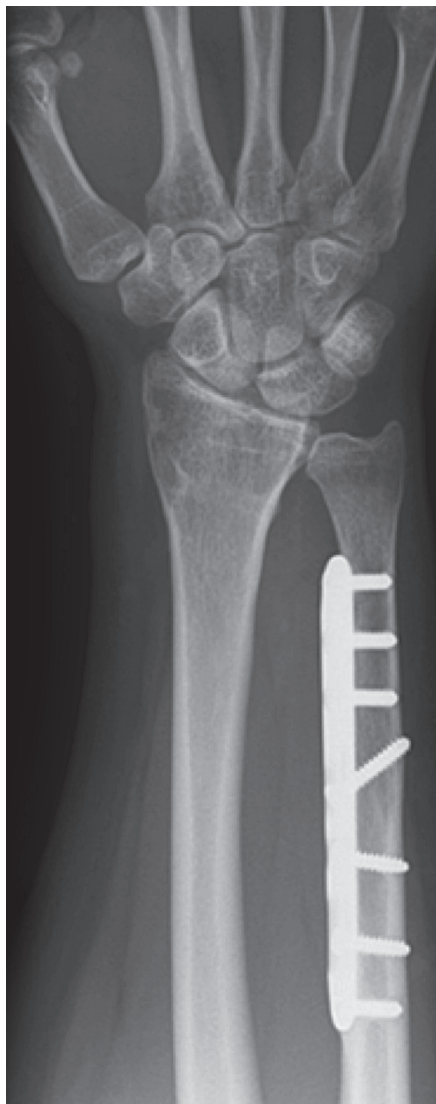


Figure 45. Ulnar shortening osteotomy of 4 mm, due to LT injury and a positive ulnar variance of 3 mm. Stability of the osteotomy secured by a compression LCP plate (Acumed®).

LT ligament quality is a decisive factor for the treatment options. In patients with chronic LT injuries (both partial and complete and in some studies accompanied by dynamic instability), arthroscopic debridement provides good functional and patient-reported outcomes in many patients. It has not been possible to find comparisons between debridement with or without thermal shrinkage in the literature. Although none of the studies in the literature [234] has made direct comparisons, arthroscopic procedures are less invasive and appear to be effective, preferably in mild LT instability. Fusion of the LT joint is a procedure with good clinical results in many patients but with a relatively high complication rate.

#### **TFCC injury and DRUJ instability**

The anatomical location of traumatic lesions of the TFCC is one of several factors that impact the surgical treatment [172, 174].

Evidence is lacking to support aggressive early surgical management when TFCC tears, especially partial ones, are diagnosed in association with distal radius fractures in adults [160].

In general, 15-20% of patients who have undergone re-insertion of the TFCC undergo a subsequent re-operation, due to re-instability of the DRUJ, regardless of an arthroscopic or open approach [21].

Female gender is significantly associated with a higher rate (4–5 times) of re-operation. In comparison, the re-operation rate in anterior cruciate ligament (ACL) reconstruction, due to re-instability, is 3–4%. Playing soccer, female gender and adolescence (age 13–19 years) at the time of ACL reconstruction predict revision surgery after ACL reconstruction and show, however, markedly higher revision rates [14].

Arthroscopic debridement, which leads to significant improvements in DASH and pain scores [164], appears to be a sufficient and reliable treatment option for the majority of patients with degenerative central TFCC injuries, i.e. Palmer type-2C lesions [173]. Patients with a positive ulnar variance of > 2 mm may be treated by arthroscopic wafer osteotomy [227] or open ulnar shortening [164], to spare them prolonged symptoms.

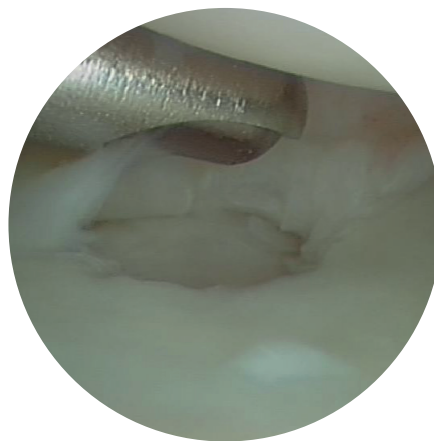


Figure 46. Central excision and debridement of a degenerative central TFCC lesion.

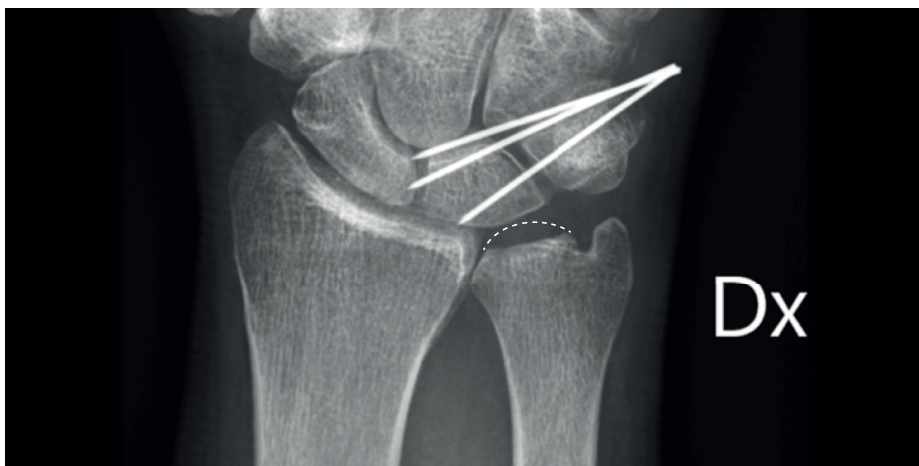

Figure 47. Radiological appearance after an arthroscopic wafer procedure and pin fixation of the LT, due to ulnar impaction syndrome and a degenerative TFCC injury and LT injury.

Ulnar-sided TFCC lesions, Palmer type 1B, which are predisposed to cause DRUJ instability can be treated using either an open approach [54, 91] or an arthroscopically assisted procedure with transosseous sutures or anchors [28, 34].

The TFCC can also be re-inserted in open surgery using bone anchors or arthroscopically using push-lock anchors. Before tightening the sutures firmly, the elbow should be flexed, the forearm elevated and in a neutral position and the ulnar head reduced. Stabilising procedures and suture techniques without prior reduction

may lead to persistent or recurrent DRUJ laxity with instability symptoms after surgery.

Re-operation for DRUJ instability is needed in 15-20% of the patients, regardless of whether open or arthroscopic re-insertion is performed [21]. There is an increased risk of re-operation in females, probably because of a physiological higher degree of laxity. There is also a slightly increased rate of post-operative superficial ulnar nerve injury leading to recurrent local dysesthesia and pain in open surgery, compared with arthroscopic TFCC-re-insertion techniques.

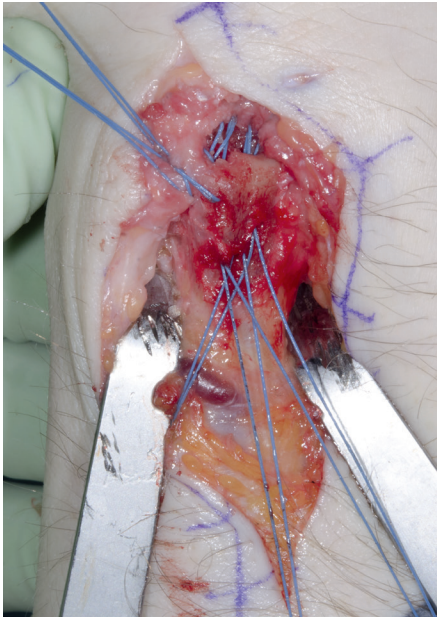


Figure 48. Open re-insertion of the TFCC with five transosseous sutures. Left wrist.

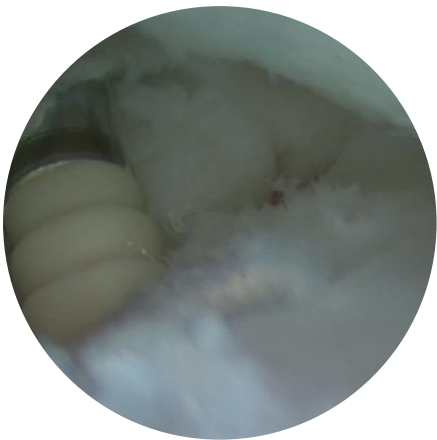


Figure 49. Arthroscopic re-insertion with push-lock suture anchor (Arthrex®). Left wrist.

Extra-articular ligament reconstruction, i. e. Adams reconstruction [3, 4, 5], is technically demanding, but it is primarily indicated in patients with global instability, including instability present also in supination and as an option for re-operation after less successful TFCC re-insertions.

DRUJ instability strictly in a neutral position is often best treated by ulnar shortening osteotomy, tensioning the ulnocarpal ligaments and the distal part of the interosseous ligament between the radius and ulna (IOM). At the same time, the ulnar shortening procedure can stabilise the DRUJ by increasing the intra-structural tension of the TFCC only when the radio-ulnar ligament (RUL) is attached at least partially to the ulnar fovea [167]. This procedure is also indicated if the patient has a positive ulnar variance, where it is known that the result of TFCC re-insertion alone is not encouraging [227].

The most common cause of post-traumatic disorders of the DRUJ is malunion of a distal radial fracture, which can be avoided by early treatment. If a patient comes with pain and/or stiffness of the wrist, as well as morphological alterations of the DRUJ, the following should be considered.

- Whenever there is a choice between a resection arthroplasty and radial osteotomy with or without ulnar shortening, the latter is to be preferred.

– Whenever there is a choice between a hemiresection arthroplasty and more extensive operations, the former is to be preferred.

– Darrach, resection of the distal end of the ulna [61], and Sauvé-Kapandji, distal radio-ulnar fusion with a pseudarthrosis of the ulna proximal to the fusion [195], are both salvage operations. The former is preferable in older patients, the latter in younger ones.

– Ulnar-head prostheses [30] and DRUJ-stabilising Aptis-Schecker pro-

stheses [179] are gaining in popularity, but they should only be used in selected cases and are still the last method of choice. The insertion of one of these implants should also be regarded as a salvage operation.

### 1.5.3 Results and prognosis after surgical treatment

The results and prognoses after the most used surgical techniques for wrist ligament injuries and their sequelae are shown in table 9-11 below.

### SL injury

**Table 9.** The results and prognosis after the most used surgical techniques for SL injury in different grades, types and stages are shown in the table below.

SURGICAL PROCEDURE	WHEN?	BENEFITS	FUNCTIONAL OUTCOME	PATIENT REPORTED OUTCOME	COMPLICATIONS
Arthroscopic debridement +/- shrinkage +/- pinning	Predynamic occult instability, partial tear, acute total tears	Easy Fast	Geissler grade 1-2: Arthroscopic debridement: Symptomatic improvement in 85%. Shrinkage: 80-90% improvement	Total injury: Pinning: 2/3 improvement, (follow-up two years) but long-term results are not satisfactory	-
Arthroscopic suture	<i>Study III:</i> Acute-subacute Andersson-Garcia-Elias Type 3 and possible 4. Partial tear or total with ligament remnants on both sides	Atraumatic Minimally invasive Less wrist stiffness	92% grip strength Excellent ROM Only short-term results	97% satisfied Pain score significantly reduced	25% uncorrected DISI
Open suture	<i>Study III:</i> Acute-subacute Andersson-Garcia-Elias Type 1 and 2 Acute-subacute injuries	Restores the anatomy	Grip strength – 85% of the normal wrist. ROM – almost 80% of that of the normal side	70% of the patients – significant improvement in pain	Radio-graphic degenerative changes in the long term: 25%

Dorsal capsulodesis, i.e. Blatt	Earlier by itself when the SLL is not adequate for primary repair Now preferably in conjunction with primary SL-repair		-	-	In short term, the same result as ligament reconstruction Deteriorates with time, carpal reduction is lost, DISI relapses and some degenerative findings are noted after eight years
Brunelli, Corella and 3LT-ligament-reconstruction	Static instability and no DISI or easily reducible DISI. No signs of degenerative arthritis.	Anatomic reconstruction	ROM- 75% of flexion and extension compared with the non-injured side. Grip strength- 65%	75% return to their normal occupational/vocational activities	Recurrence of carpal collapse and DISI: 5%- 25%
SLAM	Same as above	Stronger SL- fixation than ligament- reconstruction above	-	-	No clinical studies
Partial fusion (SL, STT, SC)	Fixed, not reducible DISI	Difficult!	Grip strength -75%		Non-union rate: SL-fusion: 50% STT-fusion: 14%
PRC	SLAC II (and III)	Not dependent on bony healing	ROM- flexion/ extension: 30°- 40° Grip strength- 75%	Good-fair pain relief. Clear improvement in outcome measurements	Overall complication rate 14% Long-term radiocarpitate degeneration > 10 years follow-up: 10% to 20%

4C- fusion	SLAC II-III	Carpal height preserved	ROM- flexion/ extension: 30°- 40° Grip strength-75% Radial deviation and grip strength better in 4CF than PRC	Good-fair pain relief Clear improvement in subjective outcome measurements	Overall complication rate: 29% More complications than PRC; such as nonunion (< 10%), hardware problems and dorsal impingement
Total wrist fusion	SLAC IV	Provides a stable joint that withstands the functional demands of heavy manual labour	ROM: 0 Grip strength improves, but ends most often at 65% of contralateral side Pain relief- Complete pain relief variable; 25-100%	Return to former employment: 52-85%	Complication rate 13-17% ROM: 0
Total wrist arthroplasty	SLAC IV	Preserved ROM	Preserved or slightly improved ROM Improved grip strength	High degree of satisfaction Significant pain relief	Complication rate 21-30% Survival rate of implant: 80% at 10 years



## LT injury

**Table 10.** LT injury. The results and prognosis after the most used surgical techniques for LT injury in different grades and stages.

PROCEDURE	WHEN?	BENEFITS	FUNCTIONAL OUTCOME	PATIENT REPORTED OUTCOME	COMPLICATIONS
Arthroscopic debridement +/- thermal shrinkage +/- pinning	Partial and chronic tears, above all	Fast All arthroscopic procedure	No statistical improvement in ROM Post-op grip strength: 67-96% of the normal side	Generally satisfactory: 72-100% relief of symptoms	4% neuropraxia of dorsal ulnar branch. 7% pin infections
Soft tissue reconstruction	Total chronic injury without carpal collapse	Enables anatomical reconstruction Possibility to repair total injuries	ROM: 85% of normal side Postop grip strength: 65-85% of the normal side	62-100% satisfied patients	13-25% complication rate 4-25% re-operation rate Neurapraxia of the dorsal ulnar branch, piso-triquetral problems, extensor carpi ulnaris tenderness <5% non-union
Ulnar shortening osteotomy	Post-traumatic isolated LT-injuries, LT injury + partial TFCC injury, especially when concomitant ulnar positive variance	Easy Almost 100% union rate (<5% non-union)	Almost 100% of patients improve significantly, including grip strength	Almost 100% of patients improve significantly including patient-reported outcome scores	Almost 50% require later removal of plates
LT arthrodesis	Chronic total injuries More severe and therapy-resistant LT-instability As a re-operation	The most studied procedure	ROM 85 % of normal side - 70-130° flexion-extension arc, 30-65° radial-ulnar-deviation arc Post-op grip strength 55-95% of normal side		Mean non-union rate: 31% (0-57%) Average satisfaction rate: 63%

## TFCC injury and DRUJ instability

**Table 11.** TFCC injury and DRUJ instability – The results and prognosis after the most used surgical techniques for TFCC injury in different classes and stages.

PROCEDURE	WHEN?	BENEFITS	FUNCTIONAL OUTCOME	PATIENT REPORTED OUTCOME	COMPLICATIONS
Debridement	Central 1A or degenerative (2A-D) TFCC injury	Fast All arthroscopic procedure	66-87% success rate	-	-
Wafer	Central 1A or degenerative (2B-D) TFCC injury + ulnar positive variance + no DRUJ instability	Can easily be performed arthroscopically No need for osteotomy	90% good-excellent outcome		Max 2-3 (5) mm positive ulnar variance can be corrected
Arthroscopic suture/re-insertion of TFCC	TFCC 1B injury with DRUJ instability	Less traumatic, minor scar, compared with open surgery	ROM: Sup/pro 81% Flex/ext 72% (of contralateral side) Grip strength: 71% (of contralateral side)		Post-operative nerve pain (ulnar nerve branch): 22% ECU-tendinitis 11% Re-operation rate: 25% Re-operation, due to DRUJ instability: 14%
Open re-insertion of TFCC	TFCC 1B injury with DRUJ instability		ROM: Sup/pro 79% Flex/ext 68% (of contralateral side) Grip strength: 73% (of contralateral side)		Post-operative nerve pain (ulnar nerve branch): 36% ECU tendinitis 26% Re-operation rate: 28% Re-operation, due to DRUJ instability: 20%
Adams ligament reconstruction	Global DRUJ instability Re-operation after less successful TFCC-reinsertions	Reconstructs both the volar and dorsal radio-ulnar ligaments	85% obtain DRUJ stability All patients achieve almost full forearm rotation (pro/sup), –if primary surgery		Persistent joint pain, recurrent instability, stiffness, and weakness can occur, particularly if re-operation after prior surgery

<b>Ulnar shortening osteotomy</b>	Partial TFCC avulsion Concomitant LT injury Positive ulnar variance	Extra-articular procedure Tightening up/ strengthening TFCC + LT + UC + IOM	Improved ROM and grip strength	90% patient satisfaction 90% good-excellent results 30% improved patient outcome scores	<5% non-union Almost 50% require hardware removal
<b>Darrach</b>	Alterations of the DRUJ in <i>elderly</i> patients with painful, arthritic DRUJ, chronic DRUJ instability or dislocation and incongruity with mechanical impediment of ulnar function	Easy	- Salvage procedure	- Salvage procedure	Radioulnar impingement in approximately 10% – symptomatic in less than 50% of these patients A very difficult condition to treat successfully
<b>Sauve-Kapandji</b>	Of advantage in <i>younger</i> patients with pain and DRUJ arthritis Chronic DRUJ dislocations	Unstable proximal ulnar stump can be avoided if the pseudarthrosis is created as distally as possible	- Salvage procedure	- Salvage procedure	Sometimes creates an unstable proximal ulnar stump
<b>DRUJ arthroplasty (Aptis-Scheker)</b>	DRUJ instability + painful DRUJ arthritis	Restores DRUJ stability and normal DRUJ kinematics	No significant improvement in ROM Significant improvement in Grip strength and pain relief	Significant improvement in patient reported outcomes	Five-year survival rate of implant: 96% ECU tendonitis 19%
<b>Ulnar head prosthesis</b>	Painful DRUJ arthritis		Preserved, unchanged ROM, but supination increased from 55° to 70° Grip strength 80%	High satisfaction rate	7.5- year survival rate: 100% Re-operation for painful instability: 5%

The results and prognosis after the treatment of SL, LT and TFCC injury in different stages are displayed in the three tables above, which is a compilation and summary of the common treatment guidelines, this Thesis and the following current studies and reviews: [4, 21, 30, 49, 60, 87, 109, 152, 155, 179, 192, 201, 218, 234, 246, 248].



# AIMS

The overall aim and purpose of this thesis was to evaluate the current diagnostics of wrist ligament injuries, to improve the clinical diagnostics and evaluation and to improve the classification of the injuries in order to determine whether surgery is necessary and, at the end of the day, the choice of surgical approach.

## 2.1 Study I

The aim of this study was to assess whether wrist arthroscopy was necessary in order to make a diagnosis of wrist ligament injuries or whether negative results of MRI and provocation tests were sufficient to discontinue further diagnostic evaluation. The hypothesis was that MRI and clinical provocation tests were unable to rule out the possibility of a clinically relevant ligament injury.

## 2.2 Study II

The aim of this study was to assess whether children and adolescents have a different pattern of injuries associated with DRUJ instability and the kind of injuries that could be associated with subsequent dorso-ulnar wrist pain and DRUJ instability. The hypothesis was that isolated TFCC ruptures are more common than previously assumed.

## 2.3 Study III

The aim of this study was to assess the relative incidence of the different failure modes of the dorsal SL ligament and to establish a new classification for SL tears, in order to contribute to the choice between the various surgical treatments available. In particular, the aim was to ascertain which patients might benefit from arthroscopic repair.

## 2.4 Study IV

The aim of this study was to correlate patients with DRUJ instability and arthroscopically verified TFCC injury with reduced peak torque during both pronation and supination on their injured side compared with their non-injured side.

## 2.5 Study V

The aim of this study was to perform an updated cost analysis, comparing the cost of referrals for MRI in Region Västra Götaland with a thorough clinical examination by an experienced hand surgeon. The purpose was also to calculate other costs, such as sick leave, and to present an algorithm for the diagnosis and treatment of suspected wrist ligament injuries.

Table 12. Study I–IV at a glance.

	STUDY I	STUDY II	STUDY III	STUDY IV
<b>Type of study</b>	Systematic review of wrist ligament diagnostics	Retrospective epidemiological study of TFCC injury and DRUJ instability in children	Retrospective methodological study of classification of SL ligament injury	Prospective methodological study of clinical assessment and evaluation of TFCC injury and DRUJ instability
<b>Years</b>	2000-2014	2006-2011	2003-2011	2013-2015
<b>Conclusion</b>	Wrist arthroscopy is needed for diagnosis of wrist ligament injuries	Awareness! Isolated TFCC injuries do exist in children	Four different types of SL injury => Decisive for the choice of surgical approach and healing conditions	New objective clinical addition to the diagnostics and evaluation of TFCC injury and DRUJ instability ↓ 30% torque if TFCC injury
<b>Numbers</b>	327 (MRI)  105 (clinical tests)	85  (among those 18 isolated TFCC injuries)	45  Acute: 10 Chronic: 35 Open classification: 27 Arthroscopic classification: 18	20  (18 TFCC –type 1B) and 15 normals (reliability test of measurement technique)
<b>Side</b>		64% non-dominant hand	71% dominant hand	65% non-dominant hand
<b>Gender</b>		55% female	67% male	60% female
<b>Age</b>	Mean age 35	Mean age 14 years	Mean age 38 years	Mean age 31 years
<b>Trauma</b>		48% high energy trauma	40% high energy trauma	
<b>Level of evidence</b>	Diagnostic level II, Systematic review of level II diagnostic studies	Case series, level of evidence IV	Case series, level of evidence IV	Prospective case series, level of evidence IV







# PATIENTS AND METHODS

## I Methods in Study I

A systematic review is a structured objective review of the literature, with a clear question formulated in advance. In a systematic review, it is crucial to assess the potential risks of bias in all terms. The inclusion and exclusion criteria should be predetermined and the data extraction should be standardised. A quality appraisal of included studies and a synthesis of data from the included studies should then be conducted. A pre-determined primary outcome measurement, cut-off values and data-extraction sheet (see Appendix 1) should be prepared before the beginning of the study.

Data items obtained from included articles are usually as follows: participants, interventions, comparisons, outcomes, study design and setting (PICOS), allocation, sample size and possible bias.

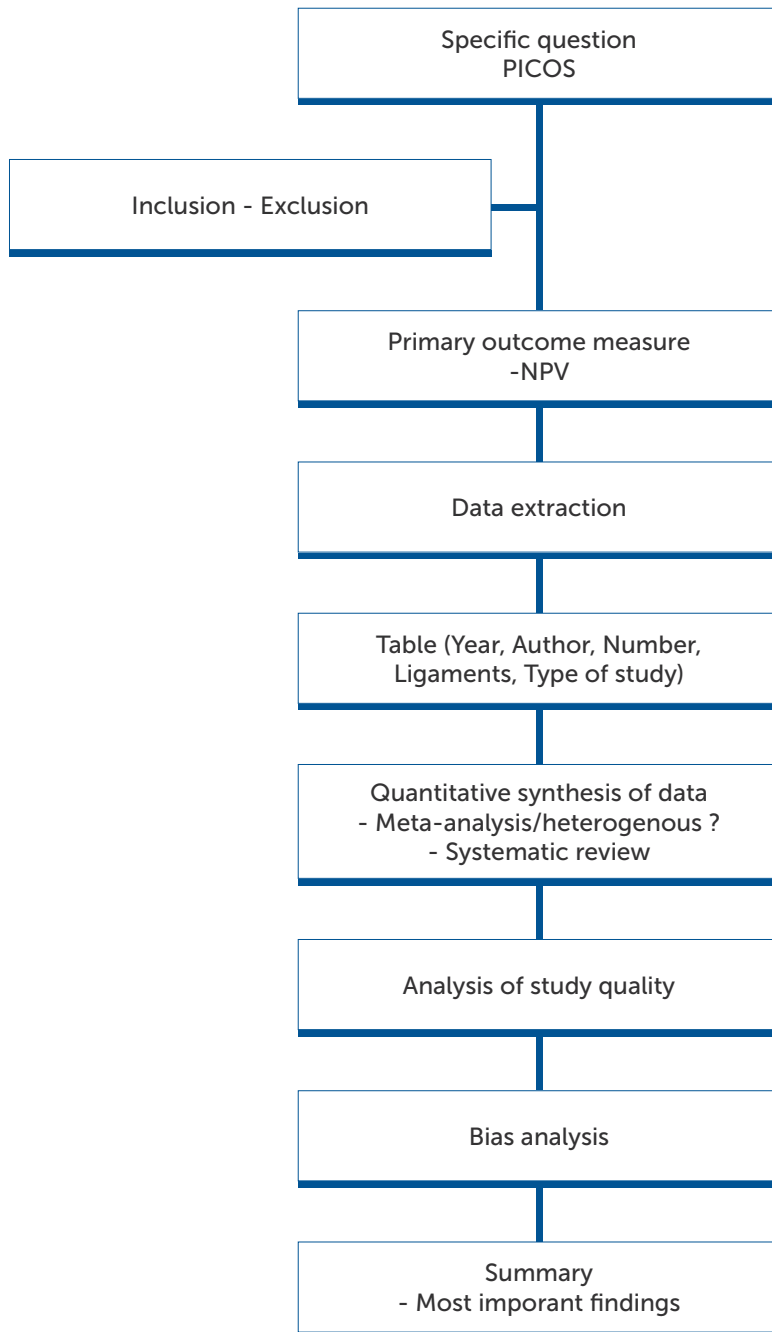
A systematic review should preferably be conducted and data should be extracted according to the Preferred Reporting Items for Systematic Re-

views and Meta-Analyses (PRISMA) statement [156] and the included studies should be quality assessed using the updated revised Quality Assessment of Diagnostic Accuracy Studies (QUADAS-2) tool [249], recommended by the Cochrane Collaboration. The PRISMA statement consists of a 27-item checklist and a four-phase flow diagram. The checklist includes items deemed essential for the transparent reporting of a systematic review. The QUADAS-2 has been developed and further modified specifically for systematic reviews of diagnostic accuracy studies. The QUADAS-2 tool consists of four domains: patient selection, index test, reference standard and flow and timing. Each domain should be assessed in terms of risk of bias and the first three domains should also be assessed in terms of applicability. Risk of bias and applicability are rated as low, high, or unclear. This quality assessment tool is applied in four phases: summarise the review question, tailor the tool and produce review-specific guidance, construct a flow diagram for the primary study and judge bias and applicability.

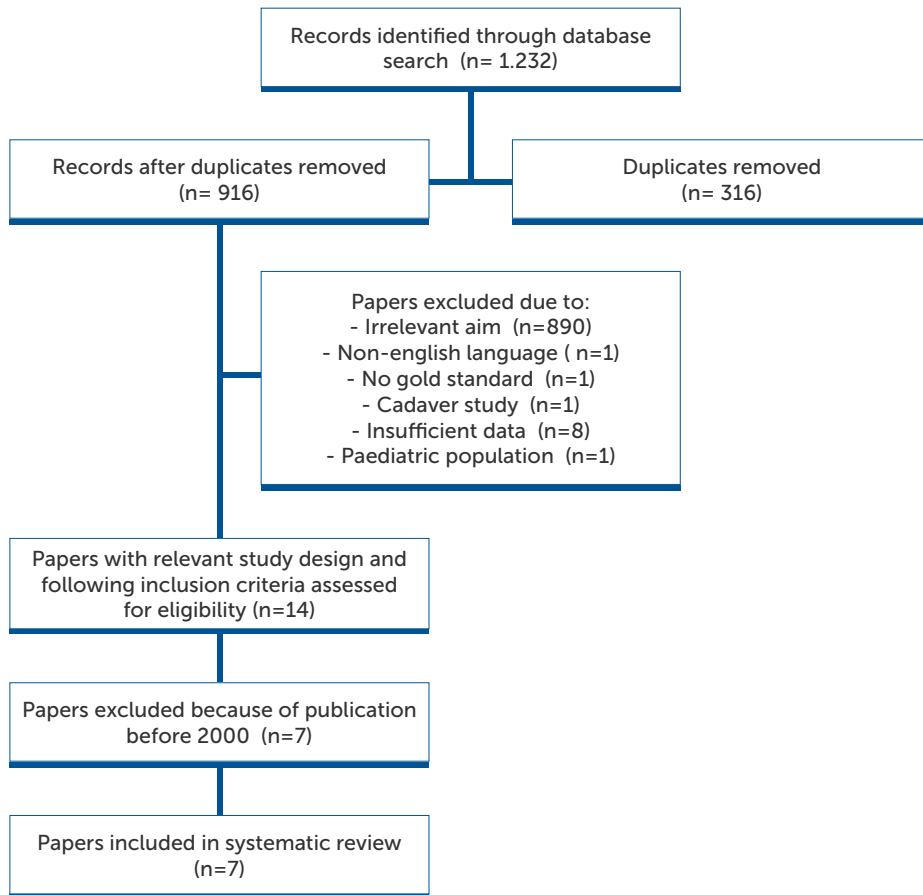
English-language articles published between 1 January 2000 and 28 February 2014 on the diagnostic performance of wrist MRI or provocative wrist tests of injuries to the wrist ligaments (TFCC, SL ligament and LT ligament) using wrist arthroscopy as the gold standard were eligible for inclusion. A systematic electronic search of Medline (Medical Literature Analysis and Retrieval System Online) –PubMed, Embase (Excerpta Medica Database) and the Cochrane Library (a database of systematic reviews and meta-analyses, which summarise and interpret results of medical research) was carried out on April 3-4 2014 by an expert in electronic search strategies (Electronic search strategies – see Appendix 2). Only studies with detailed data enabling the statistical

analysis of outcome measurements were eligible for inclusion. The exclusion criteria were expert opinions and case reports, skeletally immature participants, cadaveric or animal studies, therapeutic and prognostic studies, study protocols and re-injury and revision surgery, as well as studies of instrumentation and surgical technique. The primary outcome measurement in this updated systematic review was the negative predictive value (NPV) of wrist MRI and provocative wrist tests, which was defined as the probability of an intact wrist ligament given a negative investigation. Secondary outcome measurements were the sensitivity, specificity and positive predictive value (PPV). Values of at least 95% were considered satisfactory from a clinical perspective (1/20 false negative).

## The process of the systematic review



### Flow diagram of inclusion and exclusion in Study I



### Bias and level and quality of evidence (Study I)

The type of bias refers to systematic errors that arise from systematic differences in the groups compared (selection bias), difference in the care that is provided (performance bias), exclusion or withdrawals in the study (attrition bias), how outcomes are examined and assessed (detection bias) and how findings are reported or not reported (reporting bias).

Bias limits the accuracy or the degree to which a result is likely to be true (validity), but it does not limit the precision or consistency of the results

produced (reliability). The precision is represented by the CI (confidence interval), which is the range of values within which it is possible to be sure of finding the true value in the whole population. A wide CI thus reflects imprecision but not inaccuracy.

### Statistical analysis

#### Statistic correlation

The statistical correlation tests for binary dependent variables are calculated as follows: sensitivity (TP/TP+FN), specificity (TN/FP+TN), positive predictive value-PPV (TP/TP+FP) and negative predictive value-NPV (TN/FN+TN).

Table 13. Contingency table of possible diagnostic outcomes

		GOLD STANDARD	
		Positive	Negative
DIAGNOSTIC METHOD	Positive	True positive (TP)	False positive (FP)
	Negative	False negative (FN)	True negative (TN)

Positive = investigation shows ligament injury; negative = investigation shows no ligament injury

Many of the studies covered in terms of the MRI diagnostics of wrist ligament injuries refer to the term "accuracy". Accuracy refers to the closeness of a measured value to a standard or known value. In the author's opinion, NPV is a more clinically appropriate measurement, as, in the clinical setting, the aim is to exclude those with a negative MRI for further diagnostic procedures, including arthroscopy.

### Methods in Study II

In this study, the medical records and radiographs of patients younger than 25 years of age who were referred for a second opinion to our department during a five-year period (2006-2011) due to ulnar-sided wrist pain and persistent distal radio-ulnar (DRU) joint instability were retrospectively evaluated. All of them had had a significant wrist trauma before the age of 18. The injuries were classified clinically and

radiologically. All the injuries caused persistent ulnar-sided pain and instability.

This study also aimed to prove that isolated TFCC injuries do exist in children and adolescents and that DRUJ instability is fairly common in different typical fracture patterns, such as dislocated SH II fractures, Galeazzi type I fractures (fracture in the distal third of radius) [125] and after growth arrest in SH III-IV injuries. Problems with DRUJ instability and TFCC injuries are often un- or misdiagnosed or neglected for years in younger persons.

The time to diagnosis of DRUJ instability and TFCC injury, the frequency of primary operations for these injuries and the number of secondary procedures needed were also evaluated.

The median age at trauma was 14 (range 6.7-17.8) years. Forty-one of the 85 (48%) patients had sustained a high-energy trauma. The non-dominant side (54 cases, 64%) was more commonly injured. There were 47 girls (55%).

### **Methods in Study III**

This study was performed in Barcelona, Spain. All surgical reports that contained good quality images or videos

of an acute or chronic dorsal SL-ligament injury were retrospectively analysed. Four cases were excluded due to poor photo quality. The final series consisted of 45 patients with SL-ligament ruptures (30 men, 15 women; average age 38 years (range 18-70), all of them treated surgically between 2003 and 2011.

The dominant hand was involved in 32 patients. Ten patients had surgery within the first three months after trauma, while 35 had a chronic SL-ligament injury, 11 (30%) with signs of radioscaphoid cartilage degeneration. High-energy trauma was reported in 18 patients (40%). The dominant wrist was injured in 32 patients (71%), and 30 patients (67%) were men. The SL-ligament injury was managed arthroscopically in 18 patients, while the remaining 27 patients had had open surgery. All available audiovisual material from these cases was independently assessed and scrutinised by the two investigators, with the aim of identifying the type of ligament injury in each case. Full agreement was reached in all cases.

The aim was to establish a new classification of scapholunate ligament rupture that could be useful in the evaluation of the prognosis and to establish the treatment of choice.

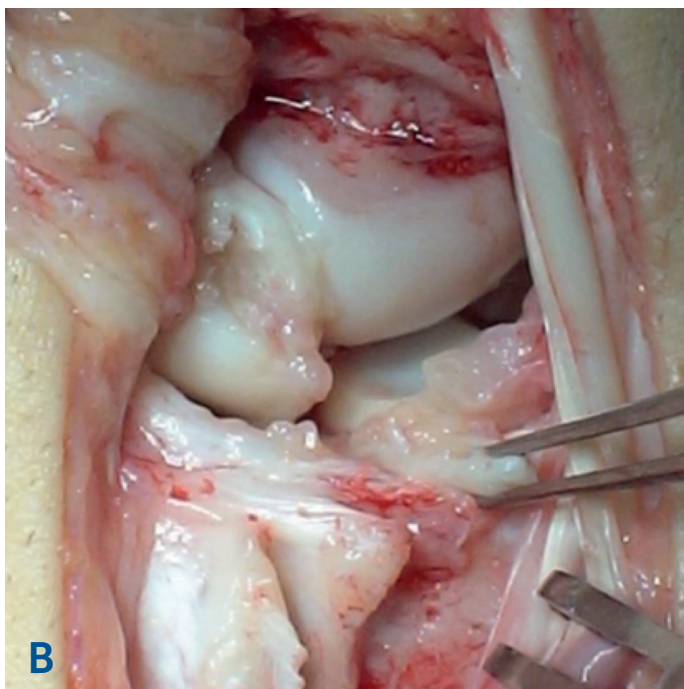
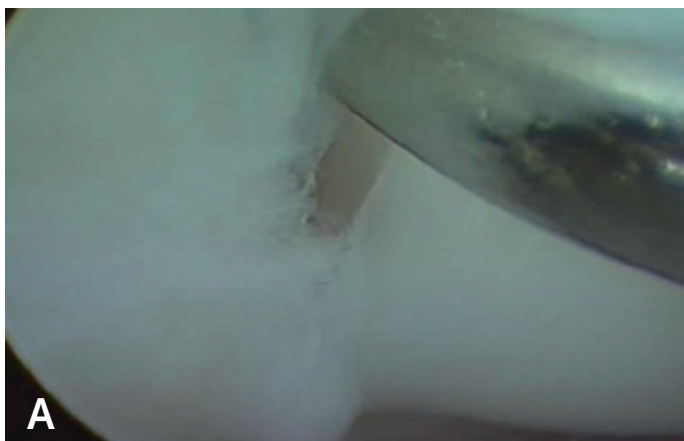


Figure 50. The diagnostic procedure of classification of the type of SL injury in (A) arthroscopic (Type 2a) and (B) open surgery (Type 1b).

### **Methods in Study IV**

The peak torque of twenty-one consecutive patients scheduled for wrist arthroscopy due to clinical signs of TFCC rupture (dorso-ulnar wrist pain and positive foveal sign) and DRUJ-instability was tested pre-operatively using a commercially available wrist dynamometer (Baseline®, White Plains, NY, USA).

The measurement technique of peak torque in supination and pronation was developed and adapted for clinical use by Peter Axelsson (submitted data to *J Hand Surg Am*, December 2015, and provisionally accepted 2016). The validity testing and calibration of the torque measurement device was performed at the SP (Statens Provningsanstalt) Technical Research Institute of Sweden on the initiative of Peter Axelsson.

The patients were tested according to a standardised protocol; standing straight

with the elbow against the waist and in 90 degrees of flexion. Peak supination followed by peak pronation were measured starting from a neutral position, with the examiner carefully ensuring that the patient did not lift his/her elbow in abduction or lean the body in any direction. The non-injured side was measured first, followed by the injured side.

This method of testing torque capacity was assessed by two independent raters (Peter Axelsson and Jonny Andersson) in 15 normal individuals for intra- and inter-rater reliability, before adapting it to the patients with suspected TFCC injuries in Study IV.

The patients were operated on, starting with wrist arthroscopy. Intra-operative photos of TFCC injuries were analysed and scrutinised by an independent reviewer (Joakim Strömberg), in terms of TFCC injury or not and its classification, according to Palmer.





Figure 51. Measurement of peak torque strength of the right wrist in pronation, standing with the elbow fixed to the body and in 90° flexion. Measurement technique developed by Peter Axelsson. Photo: Tommy Holl.

#### Statistical analysis (Study IV)

Descriptive data are reported as the mean and standard deviation (SD). The intra- and inter-rater reliability of the measurements was determined using the intra-class correlation coefficient (ICC). The ICC is the ratio of the between-subject variability and the between-subject variability plus the within-subject variability. To categorise the level of agreement between ICC values, the classification system proposed by Shrout and Fleiss was used [205]. ICC values of less than 0.40 represent poor reliability, values between 0.40 and 0.75 represent fair to good reliability and values above 0.75 represent excellent reliability. Bland-Altman plots

were used to visualize the reliability according to Bland and Altman [12, 41]. The agreements between two raters for categorising the TFCC were analysed as a percentage of the absolute agreement. For comparisons between injured and non-injured forearm torque, an independent two-sided t-test was performed. The alpha level was set a priori at  $p < 0.05$ .

The findings in the arthroscopic procedures included in Study II, III and IV, were registered in a specific wrist arthroscopy protocol (Appendix 3). A systematic wrist arthroscopy examination recorded in a specific protocol is mandatory, particularly at the beginning of a career as a wrist arthroscopist.

## Methods in Study V

The learning curve for radiologists to become dedicated wrist MRI examiners is long and approximately 100 surveys are considered necessary to assess. Blazar et al. [43] demonstrated that more experienced observers displayed more sensitive, specific and accurate radiological MRI interpretations than less experienced observers. No consistent trend towards increasing accuracy during an evaluation of 50 MRI scans could be demonstrated in that study. A learning curve nonetheless exists, but the slope appears to be gradual.

The total number of wrist MRIs in the catchment area of Region Västra Götaland (population 1,723,000) during one year, between July 2014 and June 2015, was analysed, together with the referrals and related questions, such as the estimated frequency and time for extra sick leave during the waiting time. The frequency of surveys at the six radiology departments in the catchment area was analysed and individually scrutinised, in terms of MRI investigations intended for wrist ligament injuries.

The average cost of a regular wrist MRI (axial T2 and T1, coronar STIR + PD FS + T1) was 567 euros and the time allotted to each investigation was 45 minutes. The cost of an out-patient clinical appointment and examination at the Department of Hand Surgery, Sahlgrenska University Hospital, was 188 euros.

The majority of patients with persistent and residual symptoms after a disloca-

ted distal radius fracture or wrist sprain are referred to a general practitioner (GP) or an orthopaedic surgeon without special knowledge of wrist injuries. The main additional investigation then used is an MRI, rendering approximately four weeks of waiting time. During one year, 411 patients in the catchment area were referred for MRIs with the question of a wrist ligament injury.

More than half of the population (57.5%) in Sweden is blue-collar workers, health-care or social-care workers or similar heavy-duty workers. Sick leave is probably needed after a significant wrist trauma for almost all of those patients with a heavy manual job. Sick leave included waiting time for MRI (26 days on average), time before statement (approximately seven days as an estimation) and during the waiting time for a clinical examination (28 days on average, if priority cases). However, for the calculation of the cost of sick leave, we estimated the proportion to be 50%.

The extra time for sick leave because of a suspected wrist ligament injury with MRI referral, consisted of the waiting time for MRI (four weeks) and its result and statement (estimated as one week) and was calculated to approximately five weeks. The average annual income in Sweden in 2014 was approximately 31,660 euros (300,000 SEK) according to Statistiska centralbyrån (SCB) (Statistics Sweden). According to the Swedish national health insurance fund office (Försäkringskassan), the cost of sick leave for five weeks for one person with an

average annual income of 31,660 euros was 3,900 euros. The total cost of sick leave during five weeks of prolonged leave from work for blue-collar workers, health-care or social-care workers or similar heavy-duty workers was 801,500 euros (7.6 M SEK).

The waiting time for a clinical examination at the Department of Hand Sur-

gery, Sahlgrenska University Hospital, is currently four weeks for priority cases and three to six months for non-priority cases. The cost of a diagnostic wrist arthroscopy, necessary for a wrist ligament injury diagnosis, is currently 3,588 euros (34,000 SEK). However, this process is necessary for all patients, independently of whether or not they had undergone prior MRIs.



# SUMMARY OF PAPERS

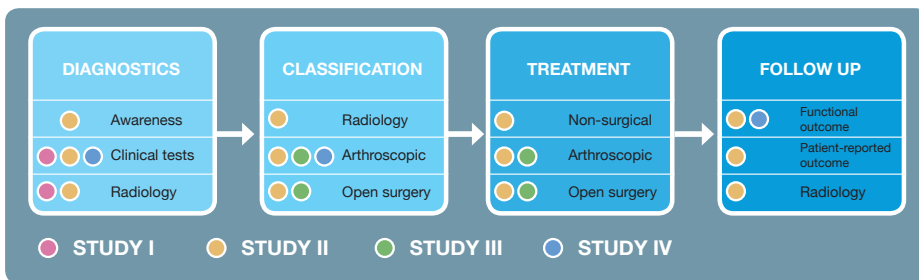


Figure 52. The process of wrist ligament injury diagnostics and the contribution of Studies I-IV.

## I Study I

A total of 1,232 articles were identified by the electronic search. After duplicate removal, subsequent study selection and exclusion because of publication dates before 1 January 2000, a total of seven studies [43, 68, 119, 145, 146, 158, 178] with a total of 377 patients (327 patients with MRI and 105 patients with tests) were included for final assessment in this systematic review. Five studies were retrospective and two were prospective. Four studies were

blinded. Six of the studies investigated the TFCC, of which one study also examined the accuracy of locating the injury. Three studies investigated the SLL, two examined the LTL and one evaluated the performance of diagnosing partial SL and LT ligament injuries. One study also compared the sensitivity, specificity and accuracy of standard-resolution 1.5-T MRI with high resolution MRI and one study investigated 3-T MRI compared with MRI arthrography.

**Table 14.** Study characteristics (Study I)

AU-THOR	YEAR	STUDY DE-SIGN	IN-VESTI-GATED LIGA-MENTS	DIAGNOSTIC METHOD *	SAMPLE SIZE	SAMPLE MEAN AGE	BLINDING
Blazar et al.	2001	Retro-spective	TFCC	MRI	51	34	Yes
De Smet	2005	Retro-spective	TFCC	MRI	35	33	?
Kato et al.	2000	Retro-spective	TFCC	MRI	33	35	Yes
Magee	2009	Retro-spective	TFCC SL LT	MRI	49	32	Yes
Manton et al.	2001	Retro-spective	SL part LT part	MRI	50	40	Yes
Morley et al.	2001	Pro-spective	TFCC SL	MRI	54	31	?
Prosser et al.	2011	Pro-spective	TFCC SL LT TFCC SL LT	MRI  Tests	MRI cohort: 55 105	37	No  Yes

\* Wrist arthroscopy was used as the diagnostic gold standard in all studies. The blinding of assessors was categorised as "yes", "no" or "unclear", presented as an "?". Unclear was used when insufficient data were reported to permit a judgement.

TFCC = triangular fibrocartilage complex. SL = scapholunate ligament. LT = lunotriquetral ligament. Part = partial injuries. MRI = magnetic resonance imaging

Only one study, by Magee [145], reached the predetermined cut-off value of 95% for the primary outcome measurement, the NPV, but only for MRI of the LT ligament. The study by Magee [145] also reached a borderline

cut-off NPV of 94% for MRI of the SL ligament. The study by Prosser et al. [178] reached a borderline cut-off NPVs of 94% both for MRI and for clinical tests of the LT.

**Table 15.** Results of individual studies (Study I)

STUDY	DIAG-NOSTIC METHOD	LIGA-MENT	SENSITI-VITY	SPECIFI-CITY	POSITIVE PREDICTIVE VALUE	NEGATIVE PREDICTIVE VALUE
Blazar et al.	MRI	TFCC	83%	54%	74%	66%
De Smet	MRI	TFCC	61%	88%	85%	68%
Kato et al.	MRI	TFCC	93% HR-MRI	56% HR-MRI	71% HR-MRI	86% HR-MRI
			72%	64%	71%	66%
Magee	MRI	TFCC	86%	100%	100%	90%
		SL	89%	100%	100%	<b>94%</b>
		LT	82%	100%	100%	<b>95%</b>
Manton et al.	MRI	SL-part	57%	55%	37%	73%
		LT-part	31%	76%	33%	74%
Morley et al.	MRI	TFCC	44%	87%	89%	37%
		SL	11%	93%	25%	84%
Prosser	MRI	TFCC	79%	86%	90%	72%
		SL	52%	88%	75%	72%
		LT	0%	96%	0%	<b>94%</b>
	Tests	TFCC	58%	69%	71%	55%
		SL	61%	79%	68%	74%
		LT	17%	84%	6%	<b>94%</b>

Sensitivity, specificity, positive predictive value and negative predictive value of the different studies and ligaments.

TFCC= triangular fibrocartilage complex. SL= scapholunate ligament. LT= lunotriquetral ligament. HR-MRI= high-resolution magnetic resonance imaging. Part= partial injury.

It is worth noting that all the referred studies were performed under close to optimal circumstances, i.e. the use of wrist coils, highly trained and specialised musculoskeletal radiologists and minimum accuracy of standard-resolution 1.5-T MRI. The clinical evaluation, MRI technology and surgical approach in all the seven included papers are easy to adapt to the clinical

hand surgery setting. One other important strength was the extensive literature search in three of the largest medical databases and the application of strict inclusion and exclusion criteria. Moreover, the PRISMA statement guided the extraction and reporting of data. The table below shows an overview of clinical important limitations in the seven included studies.

**Table 16.** Summary of the limitations of the studies included in the systematic review (Study I).

LIMITATION	NO OF TRIALS (TOTAL:7)	%
Patient selection bias	2	29
Reference standard	3	43
No blinding	1	14
No blinding stated	2	29
Sample size < 30	0	0
Sample size < 50	3	43
Retrospective study design	5	71
Studies not including clinical tests	6	86
Unknown gender ratio	2	29
Heterogeneity of MRI technique and/or multiple radiologists	2	29
Unknown time interval between MRI and arthroscopy	3	43
Multiple arthroscopic surgeons	2	29
Unknown number of surgeons and/or surgical experience	2	29



For comparison, there were many limitations in the study by Hobby et al. [111]. Only two databases were included in their study (Medline and Embase) and no clear gold standard was present. Moreover, none of their 12 included studies was blinded, four studies had an MRI field of < 1.5-T and three included studies were retrospective. Only two included studies of 12 had a sample size of > 50. Seven had a sample size of < 30, of which four even had a sample size of < 20. It has been suggested that a sample size of at

least 35 is required for the reliable estimation of diagnostic performance.

In general, patients with normal MRI imaging findings rarely have surgical confirmation and the included studies most often thus report on small samples with a reporting bias towards patients with lesions.

The assessment in this study, using the QUADAS-2 tool, showed that the risk of bias and applicability of patient selection were high or unclear in all the included studies in Study I.

Table 17. QUADAS-2 results (Study I)

STUDY	RISK OF BIAS *				RISK OF APPLICABILITY CONCERNS *		
	Patient selection	Index test	Reference standard	Flow and timing	Patient selection	Index test	Reference standard
Blazar et al.	?	Low risk	?	High risk	?	?	?
De Smet	?	High risk	High risk	?	High risk	High risk	High risk
Kato et al.	?	Low risk	Low risk	?	?	Low risk	Low risk
Magee	?	Low risk	High risk	High risk	?	Low risk	High risk
Manton et al.	High risk	Low risk	?	High risk	High risk	Low risk	?
Morley et al.	?	Low risk	High risk	?	?	Low risk	High risk
Prosser et al.	?	High risk	Low risk	Low risk	?	?	Low risk

\* Risk of bias and applicability are rated as "low", "high" or "unclear". The "unclear" category, presented as an "?", was used when insufficient data were reported to permit a judgement.

Taken together, a negative result from MRI cannot rule out the possibility of a clinically relevant injury to the TFCC, SL ligament, or LT ligament of the wrist. Clinical provocation wrist tests are of limited diagnostic value.

The current gold standard, wrist arthroscopy, remains the preferred diagnostic technique, with sufficient conclusive properties when it comes to wrist ligament injuries [15].

## **I Study II**

Sixty-seven (79%) of the 85 children and adolescents with ulnar-sided wrist pain and DRUJ instability symptoms after wrist trauma had sustained a fracture at the time of trauma. The two most common skeletal injuries related to the DRUJ instability were Salter-Harris type II fractures (24%) and distal radius fractures (19%). In 19 patients (22%), the secondary DRUJ instability was caused by malunion or growth arrest. Eighteen of the 85 patients (21%) presented with isolated DRUJ instability without any associated fracture or physeal injury at the

time of the index trauma. Fourteen of these 18 patients were diagnosed with a TFCC injury by MRI, arthroscopy or open surgery.

The main limitation of this study was its retrospective design and lack of conformity in assessing every patient in a reproducible manner. This was a selective cohort of patients, making it somewhat difficult to suggest data for the incidence and prevalence of these long-term problems with DRUJ instability. This is due to the fact that our cohort partly represents the local catchment area and partly represents tertiary referrals from our regional catchment area. Another study limitation is the lack of an independent radiologist to assess the radiographs and MRIs. It is also possible that there was an incomplete clinical diagnosis in the four cases with isolated TFCC injuries, which were not independently confirmed by arthroscopy, operation, or MRI.

The characteristics of the patients in Study II are presented in the table below.

Table 18. Injury pattern in the patient cohort in Study II.

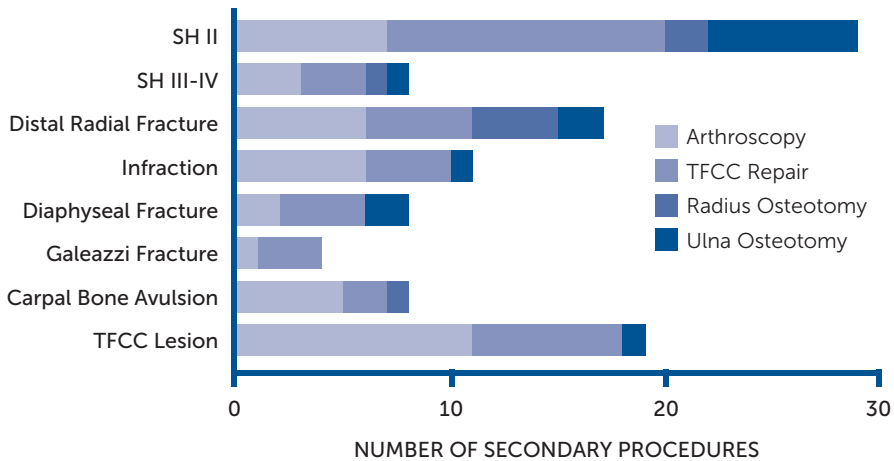
TYPE OF INJURY	PATIENTS (n) IN TOTAL	AMONG THOSE; SIGNIFICANT DISPLACEMENT	ULNAR STYLOID BASE FRACTURE	ULNAR STYLOID DISTAL TIP FRACTURE	SECONDARY SIGNIFICANT MALUNION OR GROWTH ARREST
SH II	20	9	3	9	6
SH III-IV	4	1	1	-	2
Distal radius fracture	16	3	8	4	6
Infraction/buckle fracture	10	-	-	5	-
Greenstick fracture	2	-	-	-	-
Distal forearm fracture	6	4	-	2	2
Diaphyseal forearm fracture	2	-	-	-	2
Galeazzi fracture	3	-	-	-	1
Minor carpal avulsion injury	2	-	-	1	-
Later found ulnar styloid fracture	2	-	2	-	-
No fracture or physeal injury - Isolated TFCC-injury/ DRUJ-instability	18	-	-	-	-
<b>Total</b>	<b>85</b>	<b>17 (20%)</b>	<b>14 (17%)</b>	<b>21 (25%)</b>	<b>19 (22%)</b>

*Injury pattern and aggravating factors in the 85 identified patients in Study II with significant trauma and persisting DRUJ problems. Discloses the complexity of the injuries but also the significant amount of isolated DRUJ instability without any associated fracture or physeal injury.*

The median age at trauma was 14 years and the median time between trauma and the diagnosis of DRUJ instability was three years. Primary surgical treatment was rare in all types of injury.

In all, 65 of 85 patients underwent 105 corrective secondary reconstructive procedures due to DRUJ laxity (average 1.3, SD 1.0, range 0-5 operations/patient).

**Figure 53. Secondary reconstructive procedures due to DRUJ instability (Study II).**



Taken together, this study emphasises the increased diligence required when dealing with wrist trauma in children and adolescents, as a substantial amount of delayed presentation of DRUJ instability after wrist fractures or sprains in children and adolescents was found [18]. The most striking find-

ings in this study were that several children and adolescents presented with DRUJ laxity with isolated TFCC tears, the long delay from injury to diagnosis and the severity of the injury in terms of treating the DRUJ-instability symptoms.

## Study III

### Four distinct SL-injury types could be identified.

- **Type 1:** The dorsal SLL is torn off the scaphoid and its lunate insertion remains intact. This category was subclassified as type 1a, if the avulsed ligament did not include an osteochondral fragment from the scaphoid, and type 1b, if there was an avulsion fracture.
- **Type 2:** The dorsal SLL had avulsed from the lunate. Pure ligament avulsions were subclassified as type 2a, while avulsion fractures were subclassified as type 2b.
- **Type 3:** Mid-substance rupture of the dorsal SLL with clear substantial ligament remnants at both sides of the joint.
- **Type 4:** The dorsal SLL ligament was only partially torn, but the most distal, non-ruptured fibres were elongated, allowing abnormal separation of the SL joint. The ligament between the scaphoid and triquetrum (part of DIC) was still intact.

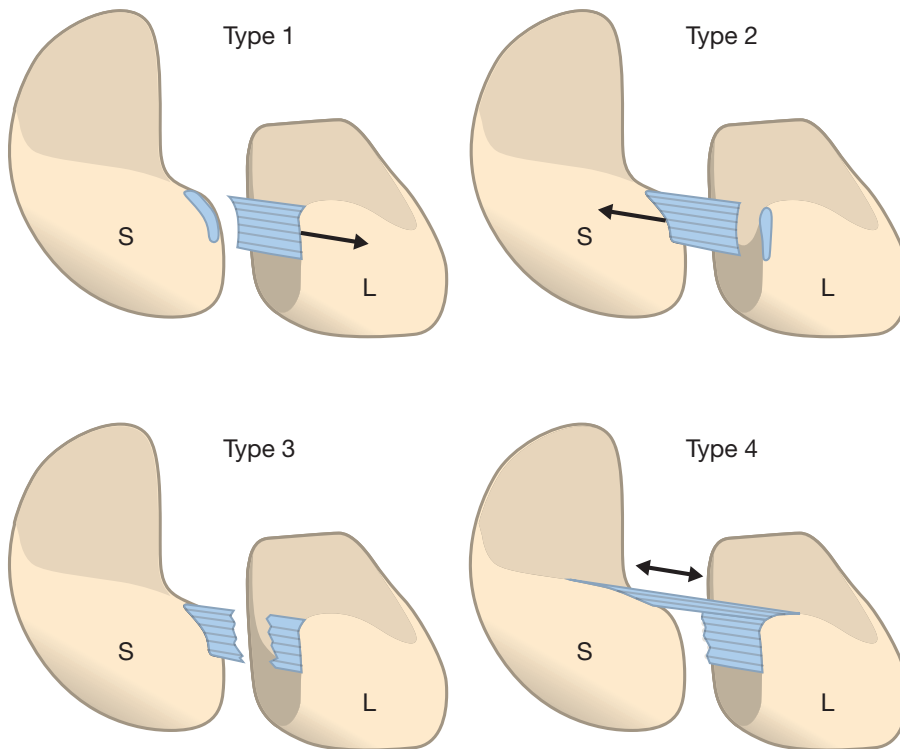


Figure 54. Classification of the dorsal SL-ligament injury, according to Andersson-Garcia-Elias in Study III.

Type 1: lateral avulsion; type 2: medial avulsion; type 3: mid-substance rupture; type 4: partial rupture plus elongation.

## SL CLASSIFICATION ACCORDING TO ANDERSSON – GARCIA-ELIAS

Four distinct SL-injury types could be identified.

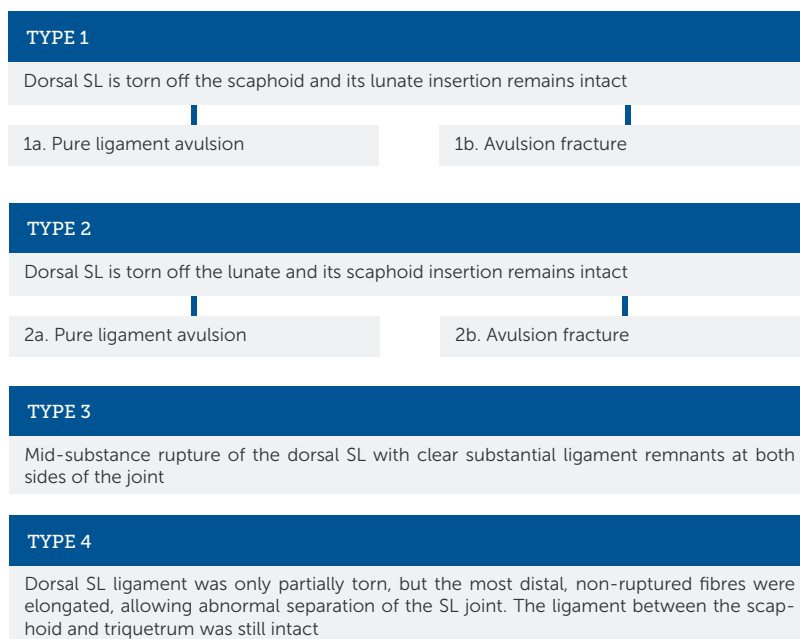


Table 19. Types of SL ligament injury.

TYPE OF SL LIGAMENT INJURY	PATIENTS, n	PATIENTS, %
<b>Type 1</b> (lateral avulsion off the scaphoid)	19	42
-Type 1a (pure avulsion)	14	
-Type 1b (avulsion fracture)	5	
<b>Type 2</b> (medial avulsion off the lunate)	7	16
-Type 2a (pure avulsion)	6	
-Type 2b (avulsion fracture)	1	
<b>Type 3</b> (mid-substance rupture)	9	20
<b>Type 4</b> (partial rupture + elongation)	10	22

The take-home message relating to this new proposed classification is that it can be used in both open and arthroscopic surgery and in acute, subacute and chronic injuries.

The retrospective design of this investigation did not enable the establishment of correlations between factors explaining the diversity of ligament failure modes and the type of ligament injury. Another limitation of this study was the inclusion criteria: four of the patients treated in the same period had to be excluded from the study because of a lack of good quality images that would permit the characterisation of the SL-ligament rupture.

An arthroscopically assisted SL capsuloplasty and suture may not be possible in all patients, particularly not when the ligament has avulsed off the bone (in approximately 60% of the patients; Andersson-Garcia-Elias Type 1 and 2), leaving no ligament remnant

on one side. Most patients will require ligament re-attachment techniques using transosseous sutures, bone anchors, or ligament reconstruction [17].

## Study IV

Arthroscopy revealed that 18 of 20 patients with DRUJ instability and a clinically assumed TFCC injury proved to have a type 1B TFCC injury. Agreement with the second reviewer's assessment was excellent in terms of a TFCC injury and its classification according to Palmer [173]. The absolute agreement between the surgeon and the second reviewer was 95%.

In seven patients, other injuries or pathological changes were found; partial SL injury (n=4), partial LT injury (n=1), chondral lesions (n=3) or synovitis (n=4). In eight patients with a type 1B TFCC injury, the TFCC also had small central ruptures with or without degenerative signs (Palmer's classification; 2A-2C or 1A).

Table 20. Patient characteristics (Study IV)

GEN- DER	SIDE	INJURY	TORQUE (NM) PRONA- TION INJU- RED SIDE	TORQUE (NM) PRONA- TION NON-IN- JURED SIDE	TORQUE (NM) SUPI- NATION INJURED SIDE	TORQUE (NM) SUPI- NATION NON-IN- JURED SIDE	OPERA- TION
M 30.0	Sin	TFCC 1A + synovi- tis	6.61	8.52	8.41	10.26	A-scopy + shaving
F 38.7	Dx	TFCC 1B	1.87	4.87	2.22	7.03	A-scopi- c re-inser- tion
F 47.0	Dx	TFCC 2B-C + minor chondral lesion lunate	2.64	2.86	1.80	2.80	A-scopy + central excision

F 15.8	Sin	TFCC 1B	2.70	3.74	5.22	6.24	A-scopic re-inser- tion
M 20.2	Sin	TFCC 1B + 1A	3.86	5.60	6.15	8.15	Open re-inser- tion
F 47.3	Sin	TFCC 1B + 2B + part SL + synovitis + minor chondral lesion lunate	2.70	3.46	2.58	5.34	A-scopic re-inser- tion + central excision
F 33.5	Sin	TFCC 1B + partial SL	2.86	3.46	5.05	7.30	Open re-inser- tion
M 25.5	Sin	TFCC 1B + 1A	4.87	7.64	6.54	7.04	Open re-inser- tion
F 26.8	Sin	TFCC 1B + 1A	4.66	5.44	5.82	7.25	A-scopic re-inser- tion
M 48.3	Sin	TFCC 1B + 1A + synovitis	3.70	4.56	6.32	8.04	A-scopic re-inser- tion
M 38.0	Dx	TFCC 1B + 2B-C + part SL	6.10	8.62	8.25	12.20	A-scopic + central excision
M 17.7	Sin	TFCC 1B + part SL + part LT + HALT + synovitis	2.54	4.18	4.45	5.61	A-scopic + shaving
F 29.8	Sin	TFCC 1B	2.65	3.68	2.80	4.92	A-scopic re-inser- tion
M 17.8	Sin	TFCC 1B	4.18	4.62	5.00	7.57	A-scopic re-inser- tion
F 17.6	Sin	TFCC 1B	2.86	5.60	4.62	6.14	A-scopic + radius corrective osteot- omy
F 23.2	Dx	TFCC 1B + 1A	1.76	2.54	2.01	3.13	A-scopic + Adams ligament re- construc- tion



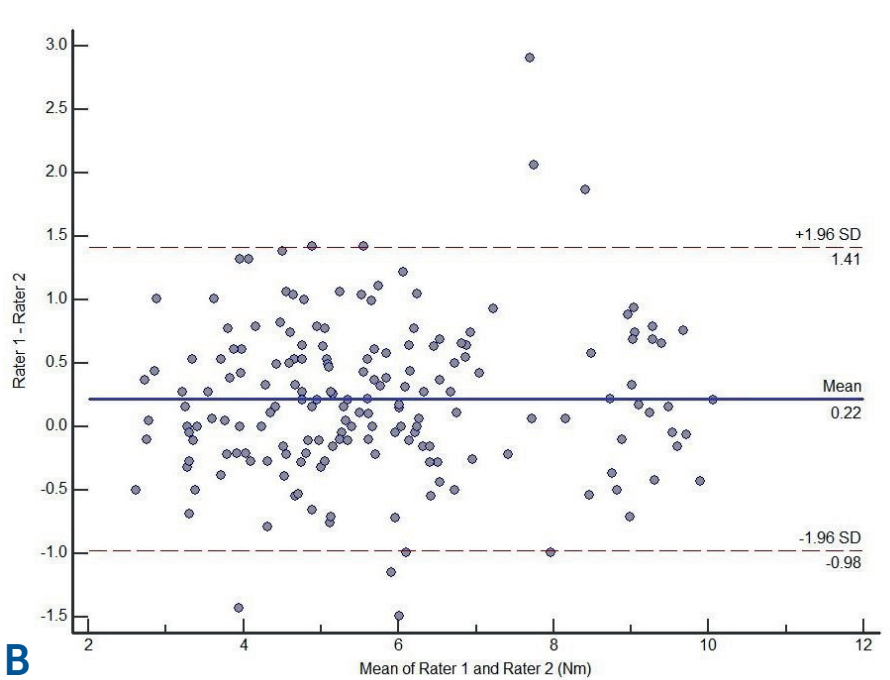
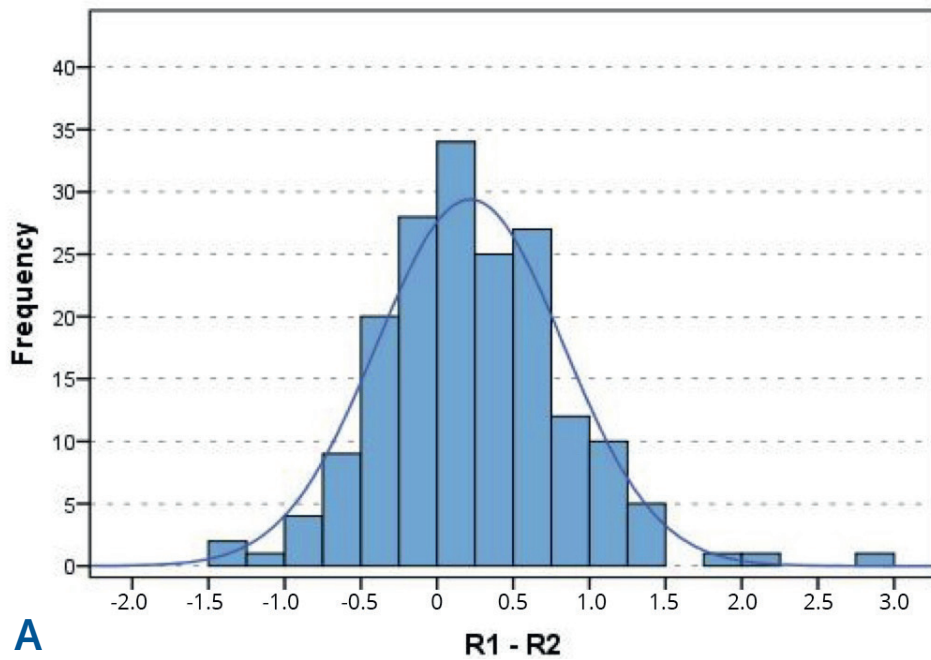
F 31.4	Sin	TFCC 1B	2.22	4.29	3.90	5.71	Open re-insertion
M 20.3	Sin	TFCC 1B	4.81	5.38	7.75	8.52	Open re-insertion
F 51.3	Sin	TFCC 1B + 2C	3.70	5.05	4.29	6.19	A-scopy + central excision
F 32.2	Dx	TFCC 1B	2.09	4.18	2.17	4.51	Open re-insertion
<b>Female 60%</b>	<b>Sin 75%</b>	<b>Signs of TFCC 1B: 90%</b>	<b>70.7% of uninjured side</b>		<b>71.2% of uninjured side</b>		7 a-scopy re-insertions 6 open re-insertions 1 radius corrective osteotomy 1 Adams 3 a-scopy + central excision 2 a-scopy + shaving
Mean age: 30.6 years (SD 11.3)		Part SL: 4 Part LT: 1 Chondral lesions: 3 Synovi- tis: 4					
Median age: 29.9 (range 15.8- 51.3)							

*M = male, F = female. Sin = left, Dx = right. TFCC = triangular fibrocartilage complex. Part SL/LT = partial SL/LT injury.*

*HALT = chondral lesion hamate. A-scopy = wrist arthroscopy.*

The intra-rater reliability was excellent for both investigators measuring forearm rotation torque, before the study, in 15 other healthy individuals, ICC=0.96, 95% CI: 0.93 to 0.97 and ICC=0.95, 95% CI: 0.93 to 0.97. The inter-rater agreement was also excellent for torsion in the same subjects.

The ICC was 0.95 with a 95% confidence interval from 0.93 to 0.96. The ICC was 0.90 in pronation and 0.95 in supination (excellent reliability). Accordingly, the torque measuring technique appeared to have high accuracy.



Figures 55. The difference between each pair of ratings for the two raters (A). The average difference was 0.22 Nm. Bland-Altman diagram (B) showing differences between the two raters plotted against the average of the raters. It also shows the outliers outside the limits of agreement.

There were limitations to this study. Other factors must be considered in relation to the reduced torque values: impaired DRUJ rotation movement; disuse-induced atrophy of forearm rotator muscles; fear of pain or real pain with maximum efforts; discomfort and clicking phenomena during forearm rotation and other concomitant intra-articular injuries. The influence of other associated injuries (ligament, chondral injuries; isolated or degenerative and synovitis) was not addressed in this study.

The surgeon was not blinded to the value of the pre-operative peak torque strength. The laxity of the DRU joint was tested manually only by the surgeon pre-operatively.

The patient's pre-operative peak torque strength was 70.7% on average in pronation compared with the non-injured contralateral side and 71.2% in supination. Exact values of the measurements including p-values are showed in the diagram below.

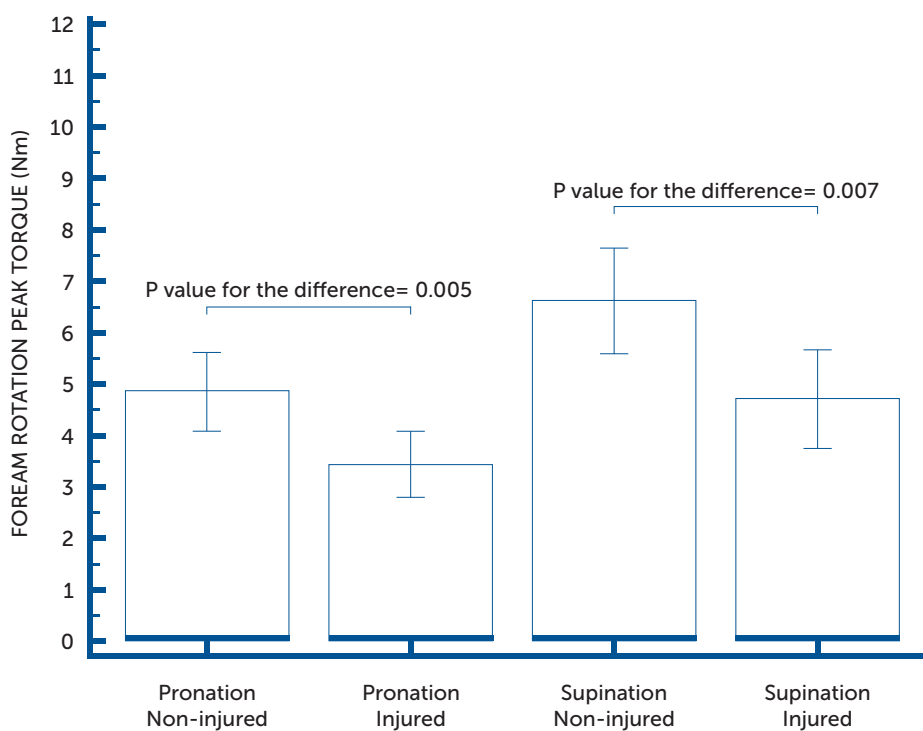


Figure 56. Statistical analysis using a t-test showing significant differences between the non-injured and injured side, with a decrease in peak torque strength of approximately 30%, i.e. 1.44 Nm in pronation ( $p=0.005$ ) and 1.93 Nm in supination ( $p=0.007$ ). Error bars representing 95% confidence interval for each group.

Taken together, distal radio-ulnar joint instability with an arthroscopically confirmed TFCC injury was associated with a significant loss of pre-operative peak torque strength (-30%) in pronation and supination [19].

## I Study V

The cost of MRI was three times higher (378 euros) than a referral and clinical evaluation by an experienced hand surgeon. The total cost of wrist MRIs in the catchment area was 429,000 euros during the study period (one year). On average, 54.3% of the examinations were dedicated to wrist ligament injuries and the cost of these assessments was 233,000 euros. The total difference in costs between an MRI and a systematic clinical wrist examination by an experienced hand surgeon in patients with suspected wrist ligament injuries was 155,500 euros.

More than three quarters of the MRI examinations were referred from non-wrist-specialised orthopaedic surgeons. The mean waiting time for an MRI investigation was 26 days. The mean waiting time for MRIs included the acute-subacute examinations for suspected scaphoid fractures. The annual total time consumed at the radiology departments by wrist MRIs (45 min each) with the question of a wrist ligament injury was 38.5 working days.

The mean age of the patients suffering from wrist ligament injuries is

approximately 30 years, according to this Thesis [20]. The majority of these patients are thus of working age.

The individual contribution to the investigation by the six radiology departments in the catchment area during one year is shown in Table 21.

The cost of sick leave for those patients with suspected wrist ligament injuries, regarded as unable to work, because of the waiting time for MRI and statement was 801,500 euros (7.6 M SEK). The annual total cost of MRIs and sick leave during five weeks because of wrist ligament injuries, was 1,034,500 euros (9.8 M SEK).

We recommend that MRI should only be used for cases other than wrist ligament injuries, such as suspect intraosseous- and extra-articular pathology. MRI when there is a question of wrist ligament injuries should be abandoned.

Taken together, more than three quarters (77.5%) of the MRI examinations were referred by non-wrist-specialised orthopaedic surgeons. It is known that acute/subacute SL ligament injuries need to be operated on within four to six weeks after the index trauma. To have a chance of repairing a significant SL or LT tear, the recommendation, is to re-examine patients who have marked swelling, pain and reduced range of motion (ROM) within two weeks after the index trauma and, if necessary, to perform a diagnostic wrist arthroscopy within four weeks.

**Table 21.** The individual contribution to the investigation by the six radiology departments in the catchment area of Region Västra Götaland (July 2014-June 2015) are displayed in Table 21 below.

DEPT OF RADIOLOGY	CATCHMENT AREA	WRIST MRI REFERRALS/YEAR (n)	MEAN WAITING TIME TO MRI (DAYS)	REFERRALS FROM ORTHOPAEDIC AND HAND SURGERY DEPARTMENTS (n)	FREQUENCY FROM ORTHOPAEDIC DEPARTMENTS (%)	AMONG THOSE HAND-SURGEONS, SS (n / %)	NUMBERS/FREQUENCY OTHER REFERRALS (GP, OTHER SPECIALITIES)	NUMBERS - WRIST LIGAMENT INJURY QUESTION (n)	FREQUENCY - WRIST LIGAMENT INJURY QUESTION (%)
Sahlgrenska University Hospital	700 000	175	?	167	95.4%	90 / 51.4%	8 / 4.6%	131	75.0%
Skaraborg Hospital (KSS + Lidköping)	265 000	214	23.8	193	90.2%	4 / 1.9%	21 / 9.8%	128	59.8%
Alingsås	100 000	33	22.8	31	93.9%	0	2 / 6.1%	19	57.6%
Borås	270 000	104	26.6	100	96.2%	0	4 / 3.8%	54	51.9%
Kungälv	118 000	76	31.9	50	65.8%	0	26 / 34.2%	17	22.4%
NUJ Hospital Group	270 000	155	26.6	141	91.0%	1 / 0.6%	14 / 9.0%	62	40.0%
<b>Total</b>	<b>1 723 000</b>	<b>757</b>	<b>26.0 days</b>	<b>682</b>	<b>90.1%</b>	<b>95</b>	<b>75 / 9.9%</b>	<b>411</b>	<b>54.3%</b>
<b>Costs</b>		<b>4.06 M SEK/ 429,000 Euro</b>		<b>587 ort =77.5%</b>		<b>95 hand surg. = 12.5%</b>		<b>2.21 M SEK/ 233,000 euros</b>	

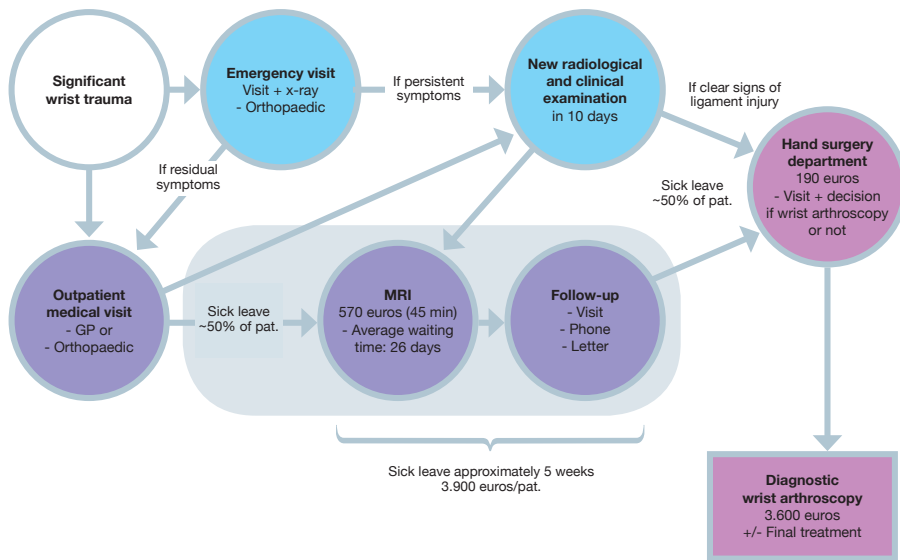
**Explanation – calculated costs:**

- Costs MRI (standard, 45 mins): 5,369 SEK - 566.6 euros
- Costs clinical examination: 1,784 SEK - 188.3 euros. => difference: 3,585 SEK = 378.3 euros
- Difference MRI - clinical wrist examination by an experienced hand surgeon: 2.71 M SEK/286,400 euros
- Difference MRI -clinical examination -" (ligament injuries): 1.47 M SEK/155,500 euros
- Time MRI examination of lig injuries; 411 x 45 min = 18,495 min = 308.25 hours = (12.84 days) = 38.5 working days

The proposed algorithm for the diagnosis and treatment of suspected wrist ligament injuries presented in Study V could save time both for the patient and for the radiology department and also apparently save costs. The algorithm may also be beneficial to pa-

tients because of reduced cost of sick leave and receiving the correct treatment at an early stage. The recommendations to clinicians are to follow the "blue pathway" in the algorithm but not the "purple and grey-shaded" one.

### COST ANALYSIS; MRI-ligament injuries



Proposed algorithm and cost analysis for the diagnosis and treatment of wrist ligament injuries, according to Study V. Our recommendations to clinicians are to follow the "blue pathway" in the algorithm not the "purple and grey-shaded" one.







# LIMITATIONS

Two of the studies (Study II and Study III) are retrospective and have level of evidence IV. Study IV is prospective but still level of evidence IV. In fact, there are very few randomised controlled trials (RCT) in the literature on orthopaedics and hand surgery. For example, RCTs represent 9% in the wide research area of anterior cruciate ligament reconstruction [193].

The patient populations in Study I represent only the results of an electronic search. To update the review, only articles published in English between January 2000 and February 2014 were included. As a result, only seven studies could be included. Statistical analysis of the data for the purpose of a meta-analysis was not possible because of heterogeneity among the seven included studies. A systematic review was therefore performed.

Study II has a retrospective design and lack of conformity for assessing every patient in a reproducible manner. A selective cohort of patients was included, making it somewhat difficult to suggest data for the incidence and prevalence of these long-term problems with DRUJ instability. Another limitation of Study II was the lack of an

independent radiologist assessing the radiographs and MRIs. In addition, it is possible that there was an incomplete clinical diagnosis in the four cases of 18 with isolated TFCC injuries, which were not independently confirmed by arthroscopy, operation, or MRI.

The retrospective nature of Study III did not enable the establishment of correlations between factors explaining the diversity of ligament failure modes and the type of ligament injury. Another limitation of Study III was the inclusion criteria: about one-tenth of the treated patients had to be excluded from the study because of a lack of good quality pictures that would permit the characterisation of the SLL rupture.

In Study IV, numerous other factors should be considered in relation to the reduced torque values: impaired DRUJ rotation movement; disuse-induced atrophy of forearm rotator muscles; pain or fear of pain with maximum efforts; discomfort [171] and clicking phenomena during forearm rotation; and other concomitant intra-articular injuries. The influence of other associated injuries was not addressed in Study IV. The surgeon was not blind

ded to the value of the pre-operative peak torque strength. The laxity of the DRU joint was tested manually only by the surgeon pre-operatively. Another limitation in Study IV was that the dominant wrist was affected in seven patients and the non-dominant in 13, which could possibly affect the significance of the measurement values.

The measurements in Study IV were performed by independent nurses or physiotherapists in the clinical setting after instruction given by the surgeon (Jonny Andersson). As the patients symptoms were significant, true inde-

pendency was difficult to achieve in terms of this matter in this setting.

In Study V, the time of sick leave during waiting time between MRI and statement of the results of the examination was estimation (one week). The amount of patients (50%) not able to work after a significant wrist sprain was also a qualified estimation. The mean waiting time for MRIs included the acute-subacute examinations for suspected scaphoid fractures. Study V is a cost analysis and not a cost-benefit analysis.

---





# DISCUSSION

## HOW COMMON ARE WRIST LIGAMENT INJURIES?

Wrist ligament injuries are common, especially with concomitant distal radius fractures. SLL and LTL injuries are present not only in severely comminuted intra-articular fractures but also in minimally displaced extra-articular fractures. The pathomechanics of combined intercarpal ligamentous injuries and fractures of the radius have been reported by Mudgal and Hastings [161]. Two mechanisms exist. One consists of compression loading with shear stress across the SLL and the mechanism involved in this SL injury is associated with die-punch fractures. The second mechanism consists of a combination of tensile stress and compression stress, resulting in a four-part fracture associated with SL injury. Although Mudgal and Hastings [161] only considered intra-articular fractures, similar mechanisms would explain the occurrence of ligamentous injuries in extra-articular fractures. Mudgal and Jones [162] described 10 fractures at the distal end of the radius associated with SL diastasis that were detected on plain radiographs. They postulated that, as the lunate is driven proximally, a shear stress is imposed on the SL, resulting

in either attenuation or rupture. Forward et al. [80] reported that grade III SL injuries can be associated with positive ulnar variance at the time of the initial presentation of a distal radius fracture and can be associated with increased SL joint pain after one year. These injuries could lead to SL dissociation at the time of follow-up, particularly in patients with intra-articular fractures [168].

More than 40% of dislocated distal radius fractures are associated with injury to the TFCC [16, 24, 78, 92, 100, 138, 153, 168, 183]. Ligament injuries do exist without a concomitant distal radius fracture. One hundred and forty-four patients with post-traumatic wrist pain but normal standard radiographs were examined using arthroscopy by Adolfsson in 1994 [7]. Ligamentous lesions were observed in 75 patients. TFCC lesions, classified according to the Palmer classification and including LTL lesions, were observed in 61 and SL injuries in 14. According to Figure 2 and Table 1 in this Thesis [20], approximately 40% of the patients with distal radius fractures have concomitant SLL injury, 20% have LTL injury and 60% have TFCC injury. It is also common with a combination of SLL, LTL and TFCC injury.

## DO ISOLATED LIGAMENT INJURY EXIST IN CHILDREN?

It is surprising that, according to Study II [18], TFCC lesions can occur in the absence of fractures in children, not least as it has previously been assumed that isolated ligament injuries are uncommon in relation to fractures in the growing bone. The approximate incidence of late DRUJ instability after wrist trauma among children and adolescents in the Gothenburg area appears to be approximately 2%, as 85 patients were included in Study II during a five-year period. Every year, approximately 800 children with wrist trauma are evaluated at the Queen Silvia Children's Hospital in Gothenburg; 50% of them are fractures and 50% are wrist sprains. Because Study II revealed a variety of causes of late DRUJ instability in children and adolescents, it is suggested that patients with these injuries should undergo extensive repeated examination of the wrist, repeated radiographs and wrist arthroscopy, as recommended in adults. Study II emphasises the increased diligence required when dealing with wrist trauma in children and adolescents, as a substantial amount of delayed presentation of DRUJ instability after wrist fracture and/or sprain in children and adolescents was found. The most striking finding in Study II was that several children and adolescents (n=18, 21%) presented with DRUJ instability with isolated TFCC tears, without fracture, which

is previously almost unknown in the scientific literature [31, 75, 221]. The long time from injury to diagnosis (three years on average) was also striking, necessitating a greater awareness of these fractures and ligament injuries and attention to the fact that they do exist.

The findings in Studies II (64%) and IV (65%) that the non-dominant side is more commonly injured in terms of TFCC injury and, in Study III (71%), that the dominant side is more commonly injured in terms of SL injury are in agreement with earlier reports [31, 87, 221]. The findings that TFCC injuries occur especially among females (55% in Study II, 60% in Study IV) and SL injury occurs especially among males (67% in Study III) are also in agreement with earlier reports.

## ARE NEGATIVE RESULTS OF MRI SUFFICIENT TO DISCONTINUE FURTHER DIAGNOSTIC EVALUATION IN TERMS OF WRIST LIGAMENT INJURIES?

## ARE NEGATIVE RESULTS OF PROVOCATION TESTS SUFFICIENT TO DISCONTINUE FURTHER DIAGNOSTIC EVALUATION?

In this Thesis [20], it has been demonstrated that a negative MRI result is unable to rule out the possibility of a clinically relevant injury to the TFCC, SL ligament, or LT ligament of the wrist [15]. The current gold standard, wrist arthro-

scopy, remains the preferred diagnostic technique with sufficient conclusive properties when it comes to wrist ligament injuries. Study I presented an updated and important addition to the results reported by Hobby et al. in 2001 [111]. Another important finding in Study I was that few studies have been carried out since Hobby et al. reviewed the literature in 2001. The studies are mainly of level of evidence IV, and no RCT was found. This is nothing unusual. For example, randomised controlled trials represent 9% in the wide research area of anterior cruciate ligament reconstruction [193].

The interpretation of peripheral attachment lesions of the TFCC with MRI is much more difficult than that of central lesions [99]. It is therefore more difficult to establish the diagnosis of an acute TFCC injury with DRUJ instability (peripheral ulnar injury with avulsion from fovea) than, for instance, a central tear. In spite of this, arthroscopic examination is the only method that is able dynamically to explore the extent of these injuries. A thorough systematic examination [213] by an experienced hand surgeon with a presumptive diagnosis and treatment plan in mind, including diagnostic/therapeutic wrist arthroscopy and open surgery, is recommended in terms of diagnostic efficacy and performance and in economic terms as well.

However, it is important to be aware that blinded studies, where the surgeon is not aware of the MRI findings, automatically produce less impressive results,

because it is easier to detect an injury arthroscopically if the results of previously performed MRIs are known. Five of seven studies included in the systematic review (Study I) were blinded.

It is reasonable to assume that the diagnostic accuracy of MRI for wrist ligament injuries will improve in the future. Further technological advances and increased experience may well improve the accuracy. For example, using 7-T MRI with a microscopy surface coil [219] or isovolumetric 3D-THRIVE (three-dimensional T1 high resolution isovolumetric examination) wrist magnetic resonance arthrography [132] increases the diagnostic performance. However, these distinguished and sophisticated techniques are not available and easy to use in clinical practice. In a common medical environment, the general use of MRI in diagnosis of dorsoulnar and ulnocarpal wrist pain, can not be recommended [98]. The most important issue, however, is an experienced, dedicated radiologist, working closely with the hand surgeon.

In 1995, LaStayo and Howell [129] stated that wrist provocation tests were effective in identifying patients who needed a more detailed diagnostic work-up and possible arthroscopic inspection and evaluation. Among those patients requiring an arthroscopic diagnostic operation, the provocation test according to LaStayo and Howell proved to be more effective in predicting the absence of injury rather than its presence.

According to Prosser et al. [178], provocative wrist tests are generally of limited value for diagnosing wrist ligament injuries, although they are sometimes useful in the diagnosis of SL-ligament injuries. However, we know from other studies that positive Watson's test occur in approximately 20% of the normal population [88, 89, 253]. If combined with provocation tests, MRI slightly sharpens and improves the diagnosis of TFCC injuries. However, negative results on a provocative wrist test are still not enough to avoid arthroscopic investigation for the diagnostics of wrist ligament injuries, according to Study I.

The incidence of pathological TFCC findings in MRIs of asymptomatic subjects is high, especially over the age of fifty [113]. Currently, a negative MRI is not an endpoint and not a contra-indication for further exploration of the wrist symptoms, in particular for arthroscopy.

#### **WHAT IS THE COST OF WRIST MRIs IN THE CATCHMENT AREA?**

According to Study V, the cost of MRI is three times higher (378 euros) than a referral and clinical evaluation at the Hand Surgery Department at Sahlgrenska University Hospital, Gothenburg, Sweden. A negative MRI is unable to rule out the possibility of an injury to the TFCC or the SL and LT ligaments and the current gold standard, arthroscopy, is still the preferred diagnostic tool. The total cost of unnecessary wrist MRIs last year, between July 2014 and June 2015 (12 months), in our catchment area was 233,000 euros, which is 155,500 euros more than a clinical

examination by an experienced hand surgeon. We therefore recommend that MRI should only be used in specific cases and for issues other than wrist ligament injuries, such as intraosseous and extra-articular pathology. MRI with the clinical question of wrist ligament injury alone should be abandoned. Isolated diagnostic arthroscopies should also be abandoned. Patients with suspected wrist ligament injuries should be assessed and evaluated thoroughly for the mechanism of their injury and then referred to an experienced hand surgeon, capable of performing a diagnostic arthroscopy and at the same time adjusting the arthroscopic surgery to the findings or converting to open surgery, in the operating theatre. It is also known that acute/subacute SL ligament injuries need to be operated on within six weeks after the index trauma [88, 89]. In Sweden at least, the algorithm (p. 142) could save time for the patient (mean waiting list for MRI is 26 days), for the radiology department (standard MRI without contrast is scheduled for 45 min; a total of 38.5 working days) and costs (233,000 euros). Some 77.5% of the wrist MRI examinations were referred from non-wrist-specialised orthopaedic surgeons. The injuries might probably also be treated within the appropriate period (within four to six weeks in terms of SL injury) with greater awareness and a faster decision to perform surgery. Avoiding unnecessary MRIs when wrist ligament injuries are suspected and the extra sick leave time consumed while waiting for an MRI investigation can result in health-economic savings of more than 1,000,000 euros (almost 10 M SEK) ever year in Region Västra Götaland.



Taken together, however, as arthroscopic surgeons prefer definitive pre-operative diagnoses and prefer not to perform exploratory surgery, future research could focus on the trinity of a thorough history, careful physical examination and careful consideration of imaging studies as an aggregate, rather than focusing solely on the MRI report. In terms of the clinical relevance, it is on the basis of this triad that arthroscopic surgeons formulate a pre-operative diagnosis.

**COULD PARAMETERS OTHER THAN CLINICAL PROVOCATION TESTS BE VALUABLE IN THE DIAGNOSTICS AND EVALUATION OF WRIST LIGAMENT INJURIES?**

**IS IT POSSIBLE TO FURTHER DEVELOP A RELIABLE MEASUREMENT TECHNIQUE FOR PEAK TORQUE STRENGTH?**

**DOES INJURY TO THE TRIANGULAR FIBROCARTILAGE COMPLEX COMPROMISE FOREARM ROTATION TORQUE?**

Researchers have implied that there could be a correlation between strength in pronation/supination and TFCC injury with DRUJ instability, but attempts to correlate the instability of the DRUJ after distal radial fractures to loss of strength have usually failed [140]. The torque measurement study (Study IV) revealed a significant association between reduced peak torque

on the injured side compared with the non-injured side and TFCC injuries as verified by arthroscopy performed on the injured wrist [19]. All the consecutive patients had a distinct laxity of the DRUJ and arthroscopically verified total TFCC injuries – 18/20 with 1B injuries. The peak torque strength was measured with the wrist in the neutral position once, with a minimal opportunity for patients to activate their dynamic secondary stabilisers. Lindau et al. [140] evaluated a selected cohort of 20 patients, six patients with laxity of the DRUJ and 14 stable. Their measurements were made three times in 30° of ulnar deviation firmly gripping the handle, probably with a greater opportunity for the patients to activate the secondary muscle-dependent DRUJ stabilisers, such as the extensor carpi ulnaris (ECU).

The intra- and inter-rater reliability of the developed torque measurement technique in Study IV was excellent for both investigators measuring forearm rotation torque in 15 other healthy individuals.

The rationale for applying the forearm torque technique, instead of grip strength, was logical, because the test directly involves the affected TFCC joint complex. The grip strength test only indirectly addresses this issue since the wrist actuators are able to stabilise the wrist position while extrinsic and intrinsic finger flexors exert maximum finger flexion torque. It is known from previous studies [149] that

the non-dominant left upper extremity has peak torque values between 85-95% of the peak torque values of the dominant right upper extremity. This is perhaps one explanation of why the non-dominant side is most often (60-70%) [18, 19, 221] affected when it comes to TFCC injury. In the clinical setting, the torque measurement technique is used exclusively when we suspect TFCC injury/DRUJ instability. In order better to isolate possible underlying mechanical changes in wrist joint integrity, it may be valuable to combine torque and grip strength in a general clinical approach to all patients with wrist problems. The rationale for testing the torque in only one measurement, was also logical, because several authors have found that testing grip in a single trial is as good as three or more, due to influence of learning and fatigue. According to Herzberg et al. [107] the first of three tests of forearm torque was always the strongest, both for pronation and supination

Theoretically, a future consequence of the torque measurement study could be that MRI and even diagnostic wrist arthroscopy could become less necessary in the diagnostics of TFCC injuries. This technique of measuring peak torque strength can be a valuable contribution when it comes to indicating whether or not an indication for surgical treatment, especially in terms of a re-insertion, exists. This information could be of great importance in the diagnostics and treatment of TFCC injuries but possibly also as an objec-

tive tool in the post-operative evaluation. The wrist dynamometer (Model BL-2000, Baseline, White Plains, NY, USA) used in Study IV is commercially available and, after development of the measurement technique by Peter Axelsson, the method can be easily adapted to the standard clinical setting and can now be used as an adjunct to clinical tests and imaging studies.

**COULD OTHER CLASSIFICATION SYSTEMS FOR INTRINSIC LIGAMENT INJURIES (SL, LT) BE RELEVANT IN TERMS OF HEALING CAPACITY AND CHOICE OF SURGICAL TREATMENT?**

**WHICH OTHER FACTORS CONTRIBUTE TO THE CHOICE OF TREATMENT FOR AN SL INJURY?**

Many factors contribute to the choice of treatment for SL injuries. Garcia-Elias et al. [87] developed a set of five questions that provide a useful framework for developing a stage-based treatment algorithm.

1. Is the dorsal SLL intact?
2. Does the dorsal SLL have sufficient tissue to be repaired?
3. Is the scaphoid posture normal?
4. Is any carpal malalignment reducible?
5. Is the cartilage on the radiocarpal and midcarpal surfaces normal?

Kitay and Wolfe [121] added one more question:

Does the abnormal SL relationship involve two distinct planes of deformity (widening and rotatory)?

According to this Thesis and Study III [17], we still need to take another factor into account. None of the questions above mention the different types of ligament rupture as a factor to consider. Any treatment algorithm that does not take account of whether the ligament has stretched out, ruptured, or torn off the bone is incomplete. In fact, for the treatment to be successful, it needs to be based on a detailed evaluation of all the factors influencing the outcome. Certainly, the type of ligament rupture is an important one.

The proposed classification of dorsal scapholunate ligament injury has both a descriptive and therapeutic value. By all accounts, different types of SLL injury require different types of surgery. If the healing potential of a torn SL ligament is optimal, repairing the lesion, if easily reduced, in order to recover its original functional strength is the most reasonable approach. This Thesis [20] and current opinions claim that repair should be performed in four to six weeks after the index trauma [8, 49, 121, 127]. After that, the ligament ends undergo fibrotic changes, degenerate and end up not being viable to suture. In SLL injuries, Andersson-Garcia-Elias Types 1 and 2 with avulsion injuries, the time to repair could perhaps be extended beyond

four to six weeks, due to better blood supply and ligamentous integrity to either the scaphoid or the lunate [35, 93]. In particular, the 1 b injury ought to be preferable from the point of view of healing, as it contains a bony fragment and is re-inserted to the dorsal ridge of the scaphoid, where the blood supply enters the scaphoid [35, 93, 117]. The healing potential of a torn SLL is probably more optimal in acute avulsion injuries with a bony fragment or in a mid-substance injury with fresh, but not attenuated or retracted ligament ends. In these cases, an open repair with ligament re-attachment or suture repair and augmented pin fixation is the most reasonable approach [17, 51, 87, 131].

Bone-to-bone healing is preferable compared with ligament to bone [176]. It is also known from anatomical and histological studies that the blood supply enters the scaphoid from the dorsal ridge [117] and that the SL ligament consists of three different parts [35]. The proximal part is avascular, but the collagen in the dorsal part is histologically oriented transversely and contains vessels. The different histological composition of the SL ligament may have numerous implications; the ability for biological healing to occur after traumatic disruption is one. It would therefore be attractive to believe in better healing capacity in Andersson-Garcia Elias Type 1 and 2 injuries, if the vascularity in the radioscapolunate (RSL) ligament is intact, with a possibly longer accep-

table time available for repairing subacute injuries. Needless to say, this only happens if no static deformity is present and reduction is easy [87]. Moreover, bone-to-bone healing is more advantageous and preferable than ligament-to-bone healing [176]. As we know [176], bone-to-bone healing is related to faster and initially stronger healing compared with ligament-to-bone healing, as described by Park et al., in 2001. The Andersson-Garcia-Elias Types 1b and 2b are therefore advantageous in terms of healing capacity, strength and ability for early controlled physiotherapeutic ROM, which could theoretically make the rehabilitation process more rapid and improve the final result, in terms of functional outcome, such as less stiffness and improved strength. That makes the sub-classification into avulsion only (1a, 2a) and avulsion fractures (1b, 2b) useful in terms of the healing potential and the choice of surgical technique. The proposed classification is easy to adapt in the clinical setting. The Andersson-Garcia-Elias classification of SL injuries can be used in both open and arthroscopic surgery and in acute, subacute and chronic injuries. It is also important to keep in mind that it is easy to overestimate the extent of SLL injury and the grade of laxity using only the Geissler classification [92], particularly in patients with joint hypermobility. Different types of SL-ligament in-

juries should probably be treated by different methods of surgery. While Type 3 mid-substance ruptures (only 20% of the cases) may allow a direct repair – also by arthroscopic technique, ensuring end-to-end contact of the two ligament stumps, Types 1 or 2 ligament avulsions do not allow this, however. In fact, if the entire ligament has been pulled off the bone, the only feasible solution is to re-attach the avulsed ligament to the denuded bone with transosseous sutures or, most commonly, with anchor sutures. Type 4 injuries, involving the elongation of a partially ruptured SL ligament, can be treated by detaching the elongated fascicle and advancing it to a more distal position over the dorsolateral ridge of the scaphoid, including the augmentation of the repair with some sort of capsulodesis or tenodesis. In some of the patients who have a Type 4 injury, arthroscopic plication may also be an alternative.

An arthroscopically assisted SL capsuloplasty and suture may not be possible in all patients, particularly not when the ligament has avulsed off the bone (60% of the cases, Andersson-Garcia-Elias Types 1 and 2), leaving no ligament remnant on one side [17]. Most patients will require ligament re-attachment techniques using transosseous sutures, bone anchors, or ligament reconstruction.

Table 22. Thesis in summary.

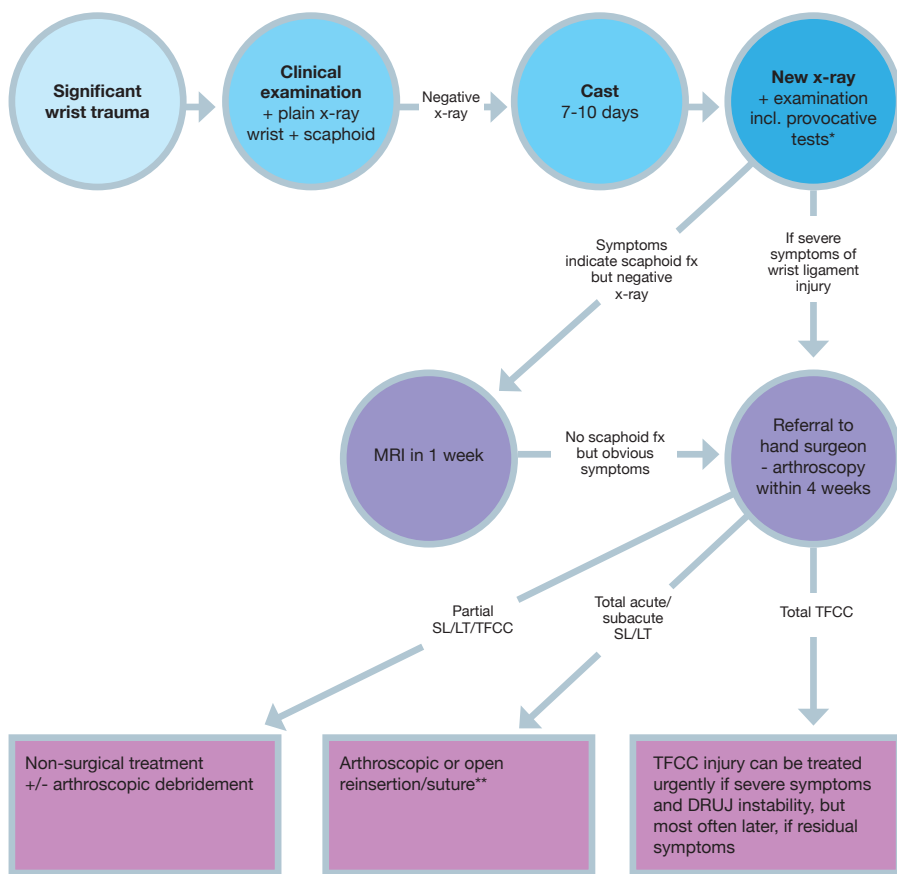
QUESTIONS IN INTRODUCTION	ANSWERS IN DISCUSSION
How common are wrist ligament injuries?	Common! A review of the literature shows that the mean value of concomitant wrist ligament injuries in patients with distal radius fracture is approximately: <b>SL</b> 40%, <b>LT</b> 20% and <b>TFCC</b> 60%. In patients with post-traumatic wrist pain after significant wrist trauma but normal standard radiographs, approximately 40% have injuries to the TFCC. In general, approximately 5% of wrist sprains involve an SL ligament tear.
Do isolated ligament injuries exist in children?	Yes, Study II shows that 21% of the children presented with isolated DRUJ instability and TFCC injury without any associated fracture or physeal injury at the time of the index trauma.
Are negative results of provocative tests sufficient to discontinue further diagnostic evaluation?	No, Study I shows that wrist arthroscopy is needed for diagnostics of wrist ligament injuries.
Could parameters other than clinical provocative tests be valuable in the diagnostics and evaluation of wrist ligament injuries?	Yes, the results in Study IV suggest that the technique for measuring peak torque strength can be a valuable contribution to indicate whether or not an indication of surgical treatment – especially in terms of a reinsertion – exists. This information can be of great importance in the diagnostics and treatment of TFCC injuries but possibly also as an objective tool in the post-operative evaluation.
Is it possible to further develop a reliable measurement technique for peak torque strength?	Yes, the torque strength device used in Study IV demonstrated excellent inter- and intra-rater reliability and test-retest values.
Does injury to the triangular fibrocartilage complex compromise forearm rotation torque?	Yes, Study IV shows that DRUJ instability with an arthroscopically confirmed TFCC injury was associated with a significant loss of pre-operative peak torque strength in pronation and supination (~30%).
Are negative results of MRI sufficient to discontinue further diagnostic evaluation in terms of wrist ligament injuries?	No, Study I shows that wrist arthroscopy is needed for diagnostics of wrist ligament injuries.
What are the costs of wrist MRIs in the catchment area?	The cost of wrist MRI is three times higher than that of a clinical examination by an experienced hand surgeon at the Department of Hand Surgery, Sahlgrenska University Hospital.
Could other classification systems for intrinsic ligament injuries (SL, LT) be relevant in terms of healing capacity and choice of surgical treatment?	Yes, probably. Study III shows that four different types of SL injury exist. The type of SL injury can probably be decisive for the choice of surgical approach and healing conditions.
Which other factors contribute to the choice of treatment for an SL injury?	According to the literature, the integrity and quality of the dorsal SLL, the posture of the scaphoid (widening and rotatory), carpal alignment and cartilage status contribute to the choice of treatment for SL injury.

MRI has sufficient accuracy in terms of scaphoid fracture [117] but not in terms of the diagnostics of wrist ligament injuries. The initial preferred treatment in all patients with significant wrist trauma and negative radiographic findings should therefore be that these patients are treated with wrist immobilisation and carefully followed up if there are persistent symptoms, such as pain, swelling, instability and reduced strength, after approximately 10 days. According to Adolfsson and Povlsen [8], arthroscopy should be considered in patients with pronounced pain and dysfunction that show no sign of recovery after a few weeks and it should probably be performed within three or four weeks in order to enable a direct repair [8, 20]. To have the chance to repair a significant SL or LT tear, the recommendation should

be to re-examine patients who have marked swelling, pain and reduced ROM 10 days after the index trauma and, if needed, to perform a diagnostic wrist arthroscopy within four weeks.

Performing a quick MRI to rule out a scaphoid fracture [117] or advocating free mobilisation after wrist sprains should be regarded as hazardous in terms of missing wrist ligament injuries. Clinical provocative wrist tests are not feasible and appropriate early after trauma [8].

The skills associated with the diagnosis and treatment of wrist ligament injuries must be centred in order to perform the correct interventions at the right time for all patients with wrist ligament injuries and to save costs.



\* Watson's test, Shuck test, Foveal sign, DRUJ laxity test  
 \*\* At the same time

Figure 57. Proposed algorithm of diagnostics and treatment of wrist ligament injuries. Based on current literature and this Thesis.





# CONCLUSIONS

- A negative result from MRI cannot rule out the possibility of a clinically relevant injury to the SL ligament, the LT ligament or the TFCC. Clinical provocation wrist tests are of limited diagnostic value.
- The current gold standard, wrist arthroscopy, remains the preferred diagnostic technique with sufficient conclusive properties when it comes to wrist ligament injuries.
- The cost of wrist MRI is three times higher than that of a clinical examination.
- Avoiding unnecessary MRIs when wrist ligament injuries are suspected and the extra sick leave time consumed while waiting for an MRI investigation can result in health-economic savings of more than 1,000,000 euros (almost 10 M SEK) every year in Region Västra Götaland.
- The two most common skeletal injuries related to the DRUJ instability in children and adolescents are Salter-Harris type II fractures (1/4, 24%) and distal radius fractures (1/5, 19%). Almost a quarter (22%) of the secondary DRUJ instability in children and adolescents is caused by malunion or growth arrest.
- Many children and adolescents with secondary DRUJ instability after trauma are diagnosed with isolated TFCC tears (21%).
- There is often a long delay from injury to the diagnosis of DRUJ instability in children and adolescents (three years on average).
- The non-dominant side seems to be more commonly injured in terms of TFCC injury and the dominant side in terms of SL ligament injury, which is in agreement with earlier reports.
- TFCC injuries occur especially among females (55% in Study II, 60% in Study IV) and SL ligament injuries occur especially among males (67% in Study III). This is in agreement with earlier reports.
- Four distinct SL ligament injury types can be identified and classified.
- This classification of SL ligament injuries can be used for both open and arthroscopic surgery and in acute, sub-acute and chronic injuries.
- Most of the patients (60%) with total SL ligament injury will require open surgery with ligament re-attachment techniques using transosseous sutures, bone anchors, or ligament reconstruction.

- Distal radio-ulnar joint instability with an arthroscopically confirmed TFCC injury is associated with a 30% loss of pre-operative peak torque strength in pronation and supination – a measurement technique now easily adapted in the clinical pre-operative setting.

**Table 23.** Main conclusions.

#### MAIN CONCLUSIONS

Wrist arthroscopy is crucial and is still the gold standard for diagnostics of wrist ligament injuries.

Isolated TFCC injuries do exist in children.

Four types of SL injury exist – different surgical methods should be recommended in different types of SL injury.

TFCC injury compromises forearm torque.





# FUTURE PERSPECTIVES

- I** It is reasonable to assume that the diagnostic accuracy of MRI for wrist ligament injuries will improve in the future. In order to improve the diagnostic strength of MRI, a number of prerequisites must be met: carefully calibrating the coil; specific training and interest of the musculoskeletal radiologist and, perhaps most importantly, continuous interaction between the clinician who performs the arthroscopy and the radiologist. Since arthroscopic and related surgeons prefer definitive pre-operative diagnoses, and prefer not to perform exploratory surgery, future research could focus on the trinity of a thorough history, careful physical examination and thoughtful consideration of imaging studies as an aggregate, rather than focusing solely on the magnetic resonance imaging report. In terms of clinical relevance, it is on the basis of this triad that arthroscopic and related surgeons formulate a pre-operative diagnosis. Further research should focus on the costs of MRIs and on finding the most appropriate setting for MRI series for wrist ligament injuries, in conjunction with greater accuracy in clinical tests performed by experienced surgeons.
- II** Increased diligence is required when dealing with wrist trauma in children and adolescents, as a substantial amount of delayed presentation of DRUJ instability after wrist fracture and/or sprain in children and adolescents is found. This is an important message to all clinicians dealing with wrist trauma among young people. Further research should focus on the difference in outcome in terms of the early treatment of TFCC injury and DRUJ instability in children compared with subsequent secondary surgery. The development of surgical methods should also focus on re-insertion methods that do not affect and harm the growth plate.
- III** A staging system for SL injuries was presented 10 years ago. This system was based on five prognostic factors, including the extent

of SLL rupture, reparability of the ligament tear, reducibility of the carpal displacements, status of secondary stabilisers and condition of the cartilage. None of them discussed the different types of ligament rupture as a factor to consider. Any treatment algorithm that does not take account of whether the ligament has stretched out, ruptured, or torn off the bone is incomplete. In fact, for the treatment to be successful, it needs to be based on a detailed evaluation of all the factors influencing the outcome. Certainly, the type of ligament rupture is an important one. This knowledge should be added in the clinical assessment of patients with SL injury. Attempting to establish correlations between the diversity of ligament failure modes and other factors, such as radiological diversity (i.e. ulnar variance, carpal height, lunate type), type of trauma and patient factors, would favour further professional knowledge and a more diverse and improved choice of treatment for patients. Further research should focus on assessments of the possibility and outcome of delayed re-insertion of SL Types 1 and 2 injuries. Further ligament reconstruction technique development is also desirable.

- IV** An association between the decrease in torque strength of approximately 30% and arthroscopically diagnosed TFCC injuries has been established. The method can be easily adapted to the standard clinical setting and can now be used as an adjunct to clinical tests and imaging studies. However, numerous other factors must be considered in relation to the reduced torque values. Further research should focus on testing the validity of the measurement technique. The patients in this cohort should be followed up to see whether peak torque strength normalises after the surgical repair of the TFCC. This would then strengthen the validity of the torque measurement method.
- V** Further studies on the costs and associated risks for unnecessary examinations for patients with suspected wrist ligament injuries are needed. Studies in terms of associated health economic benefits when implementing a strict algorithm for diagnosis and treatment of these injuries are particularly desirable.







# ACKNOWLEDGEMENTS

## **My wife and son**

You are the light of my life. Thank you for your never-ending support, joy and love and for reminding me of what really is most important and meaningful in life. Αγάπη!

## **My parents**

For your strong belief in me and for your never-ending unconditional love and invaluable support in good and bad times during life.

## **Jan Fridén**

Professor of Hand Surgery, MD, PhD, my supervisor. For your empathy, calmness, joy, energy, wisdom, positive thinking and never-ending strong support. Oral presentations at meetings and publishing articles are so much easier with your name, reputation and mutual respect, to back me up.

## **Jón Karlsson**

Professor of Orthopaedics, MD, PhD, my co-supervisor. For your enthusiasm, hospitality, amazing speed, generosity in providing me with contacts, such as statisticians and illustrators, and for humble strong support, and mutual respect.

## **Marc Garcia-Elias**

For your knowledge, wisdom, mutual respect and eye-opening manner in wrist kinematics, wrist surgery issues and their research.

## **Jörg Bahm**

For your hospitality and for teaching me other areas and surgery in the upper extremities, more important than wrist ligaments.

## **Elisabeth Hansson-Olofsson**

PhD, senior lecturer, Institute of Health and Care Sciences, Sahlgrenska Academy. For your diligent support, knowledge, patience and interest in helping me with my questions on health economics.

## **Arvid Ejeskär**

Senior hand surgery consultant. My mentor. For your valuable clinical advice, wisdom, solid manner, continuing thirst for knowledge and never-ending interest in patients and their problems.

## **Eythór Stefansson**

Senior hand surgery consultant. For teaching me your technique for the open re-insertion of the TFCC.

**Ann Nachemson**

Head of the Department of Hand Surgery, Sahlgrenska University Hospital. For your energy, joy, financial support and for making me believe in a bright future for the Hand Surgery Department.

**Christer Sollerman**

Professor of Hand Surgery. For your diligent reading of one of my papers and for your rewarding positive and negative feedback and, not least, for your generous introduction to insurance medicine.

**Bo Rööser**

Associate Professor of Orthopaedics. For proof-reading my papers and thesis and for your experience, support and fruitful discussions during our golf rounds.

**Mikael Etzner**

Senior orthopaedic consultant. For teaching me wrist arthroscopy techniques and providing me with the results of your arthroscopically re-inserted TFCC patients. Also many thanks for giving me self-confidence in my surgical skills. I admire your surgical skills.

**Daniel Andernord**

MD, PhD. My friend and colleague. For your wisdom and knowledge and patience in terms of systematic review issues and my never-ending statistical questions.

**Joakim Strömberg**

Senior orthopaedic and hand surgery consultant. My friend and colleague. For your trustworthiness, hospitality and mutual respect.

**Crister Swenson**

Senior orthopaedic consultant. My friend. For your humanity, kind heart, hospitality and for a mutual interest in soccer – “the most important not important thing”, according to the former Pope, John Paul II.

**Peter Axelsson**

Senior orthopaedic and hand surgery consultant. For your enthusiasm, many ideas and for assistance with measurements of torque strength, reliability testing and development of the torque measurement technique.

**Barbro Danielsson**

Senior radiology consultant. For your advice, prompt answers and valuable information in the field of radiology, especially MRI.

**Per Fredrikson**

Resident in orthopaedic surgery. For help with some great illustrations.

**Gudni Olafson**

Lay-out artist. For making my thesis a beautiful piece of work.

**Tommy Holl**

Photographer. For your attentive and sensitive eye and for your capacity for taking 1,000 images in five minutes.

**Pontus Andersson**

Illustrator. For your beautiful drawings, prudence and quickness and for your ability to make some masterpieces of illustrations.

**Christer Johansson**

Statistician. For statistical help, information and teaching.

**Jeanette Kliger**

Linguistic editor and expert. For correcting my Gothenburgian type of English.

**Linda Johansson**

Administrator. For your great routine and never-ending patience with all my questions about administrative and practical issues.

**Therese Svanberg**

Librarian at Sahlgrenska University Hospital Library. For your help with the electronic search strategies.

---



# REFERENCES

1. Abramo A, Tagil M, Geijer M, Kopylov P. Osteotomy of dorsally displaced malunited fractures of the distal radius: no loss of radiographic correction during healing with a minimally invasive fixation technique and an injectable bone substitute. *Acta Orthop.* 2008, 79: 262-8.
2. Abrams RA, Petersen M, Botte MJ. Arthroscopic portals of the wrist: An anatomic study. *J Hand Surg Am.* 1994, 19: 940-44.
3. Adams BD. Anatomic reconstruction of the distal radioulnar ligaments for DRUJ instability. *Tech Hand Up Extrem Surg.* 2000, 4: 154-60.
4. Adams BD, Berger RA. An anatomic reconstruction of the distal radioulnar ligaments for posttraumatic distal radioulnar joint instability. *J Hand Surg Am.* 2002, 27: 243-51.
5. Adams BD, Divilbiss BJ. Reconstruction of the posttraumatic unstable distal radioulnar joint. *Orthop Clin North Am.* 2001, 32: 353-63.
6. Adams BD, Samani JE, Holley KA. Triangular fibrocartilage injury: a laboratory model. *J Hand Surg Am.* 1996, 21: 189-93.
7. Adolfsson L. Arthroscopic diagnosis of ligament lesions of the wrist. *J Hand Surg Br.* 1994, 19: 505-12.
8. Adolfsson L, Povlsen B. Arthroscopic findings in wrist with severe post-traumatic pain despite normal standard radiographs. *J Hand Surg Br.* 2004, 29: 208-13.
9. Af Ekenstam F, Hagert CG. Anatomical studies on the geometry and stability of the distal radio ulnar joint. *Scand J Plast Reconstr Surg.* 1985, 19: 17-25.
10. Ageberg E. Consequences of a ligament injury on neuromuscular function and relevance to rehabilitation – using the anterior cruciate ligament-injured knee as model. *J Electromyogr Kinesiol.* 2002, 12: 205-12.
11. Ageberg E, Pettersson A, Friden T. 15-year follow-up of neuromuscular function in patients with unilateral non-reconstructed anterior cruciate ligament injury initially treated with rehabilitation and activity modification: a longitudinal prospective study. *Am J Sports Med.* 2007, 35: 2109-17.
12. Altman RD. *Practical Statistics for Medical Research.* London: Chapman Hall. 1991.

13. Aman JE, Elangovan N, Yeh IL, Konczak J. The effectiveness of proprioceptive training for improving motor function: a systematic review. *Front Hum Neurosci.* 2014, 8: 1075.
14. Andernord D, Desai N, Björnsson H, Ylander M, Karlsson J, Samuelsson K. Patient predictors of early revision surgery after anterior cruciate ligament reconstruction: a cohort study of 16,930 patients with 2-Year follow-up. *Am J Sports Med.* 2015, 43:121-7.
15. Andersson JK, Andernord D, Karlsson J, Fridén J. Efficacy of magnetic resonance imaging and clinical tests in diagnostics of wrist ligament injuries: a systematic review. *Arthroscopy.* 2015, 31: 2014-20.
16. Andersson J, Axelsson P. Wrist ligament injuries – diagnostics. *Lakartidningen.* 2011, 42: 2096-101.
17. Andersson JK, Garcia-Elias M. Dorsal scapholunate ligament injury: A classification of clinical forms. *J Hand Surg Eur.* 2013, 38: 165-9.
18. Andersson JK, Lindau T, Karlsson J, Fridén J. Distal radioulnar joint instability in children and adolescents after wrist trauma. *J Hand Surg Eur.* 2014, 39: 653-61.
19. Andersson JK, Strömberg J, Karlsson J, Fridén J. Patients with triangular fibrocartilage complex injuries and distal radioulnar joint instability have reduced rotational torque in the forearm. *J Hand Surg Eur.* E-published, DOI: 10.1177/1753193415622342.
20. Andersson J. Clinical and arthroscopic assessment of wrist ligament injuries and instability. Gothenburg: Sahlgrenska Academy, Institute of Clinical Sciences, Gotheburg, Sweden, 2016 (dissertation).
21. Anderson ML, Larson AN, Moran SL, Cooney WP, Amrami KK, Berger RA. Clinical comparison of arthroscopic versus open repair of triangular fibrocartilage complex tears. *J Hand Surg Am.* 2008, 33: 675-82.
22. Anderson ML, Skinner JA, Felmlee JP, Berger RA, Amrami KK. Diagnostic comparison of 1.5 Tesla and 3.0 Tesla preoperative MRI of the wrist in patients with ulnar-sided wrist pain. *J Hand Surg Am.* 2008, 33: 1153-9.
23. Angermann P, Lohmann M. Injuries to the hand and wrist. *J Hand Surg Br.* 1993, 18: 642-4.
24. Araf M, Mattar Junior R. Arthroscopic study of injuries in articular fractures of distal radius extremity. *Acta Ortop Bras.* 2014, 22:144-50.
25. Atesok K, Jupiter J, Weiss AP. Galeazzi fracture. *J Am Acad Orthop Surg.* 2011, 19: 623–33.

26. Atzei A. New trends in arthroscopic management of type 1-B TFCC injuries with DRUJ instability. *J Hand Surg Eur.* 2009, 34: 582–91.
27. Atzei A, Luchetti R. Foveal TFCC tear classification and treatment. *Hand Clin.* 2011, 27: 263–72.
28. Atzei A, Rizzo A, Luchetti R, Fairplay T. Arthroscopic foveal repair of triangular fibrocartilage complex peripheral lesion with distal radioulnar joint instability. *Tech Hand Up Extrem.* 2008, 12: 226–35.
29. Aviles AJ, Lee SK, Hausman MR. Arthroscopic reduction-association of the scapholunate. *Arthroscopy* 2007, 23: 105.e1–105.e5.
30. Axelsson P, Sollerman C, Kärrholm J. Ulnar Head Replacement: 21 Cases; Mean Follow-Up, 7.5 Years. *J Hand Surg Am.* 2015, 40:1731-8.
31. Bae DS, Waters PM. Pediatric distal radius fractures and triangular fibrocartilage complex injuries. *Hand Clin.* 2006, 22: 43–53.
32. Bailey DA, Wedge JH, McCulloch RG, Martin AD, Bernhardson SC. Epidemiology of fractures of the distal end of the radius in children as associated with growth. *J Bone Joint Surg Am.* 1989, 71: 1225–31.
33. Bain GI, Pallapati S, Eng K. Translunate perilunate injuries – a spectrum of this uncommon injury. *J Wrist Surg.* 2013, 2: 63-8.
34. Bednar JM, Osterman AL. The role of arthroscopy in the treatment of traumatic triangular fibrocartilage injuries. *Hand Clin.* 1994, 10: 605-14.
35. Berger RA. The gross and histologic anatomy of the scapholunate interosseous ligament. *J Hand Surg Am.* 1996, 21: 170-8.
36. Berger RA, Bishop AT. A fiber-splitting capsulotomy technique for dorsal exposure of the wrist. *Tech Hand Up Extrem Surg.* 1997, 1: 2-10.
37. Berger RA, Dobyns JH. Physical examination and provocative maneuvers of the wrist. In: Gilula LA, Yin Y, eds. *Imaging of the wrist and hand.* Philadelphia: WB Saunders, 1996.
38. Berger RA, Imaeda T, Berglund L, An KN. Constraint and material properties of the subregions of the scapholunate interosseous ligament. *J Hand Surg Am.* 1999, 24: 953–62.
39. Berger RA, Kauer JMG, Landsmeer JMF. Radioscapholunate ligament: a gross anatomic and histologic study of fetal and adult wrists. *J Hand Surg Am.* 1991, 16: 350-5.
40. Bergh TH, Lindau T, Bernardshaw SV et al. A new definition of wrist sprain necessary after findings in a prospective MRI study. *Injury.* 2012, 43: 1732–42.

41. Bland JM, Altman DG. Statistical methods for assessing agreement between two methods of clinical measurement. *Lancet*. 1986, 327: 307-10.
42. Blatt G. Capsulodesis in reconstructive hand surgery. Dorsal capsulodesis for the unstable scaphoid and volar capsulodesis following excision of the distal ulna. *Hand Clin*. 1987, 3: 81-102.
43. Blazar PE, Chan PSH, Kneeland JB, Leatherwood D, Bozentka DJ, Kowalchick R. The effect of observer experience on magnetic resonance imaging interpretation and localization of triangular fibrocartilage complex lesions. *J Hand Surg Am*. 2001, 26: 742-8.
44. Blount WP. Forearm fractures in children. *Clin Orthop Relat Res*. 1967, 51: 93-107.
45. Bora FJ. Wrist arthroscope. *J Hand Surg Am*. 1985, 10: 308.
46. Brunelli GA, Brunelli GR. A new technique to correct carpal instability with scaphoid rotary subluxion: a preliminary report. *J Hand Surg Am*. 1995, 20: 82-5.
47. Budoff JE. Treatment of Acute Lunate and Perilunate Dislocations. *J Hand Surg Am*. 2008, 33: 1424-32.
48. Cautilli GP, Wehbe MA. Scapho-lunate distance and cortical ring sign. *J Hand Surg Am*. 1991, 16: 501-3
49. Chennagiri RJR, Lindau TR. Assessment of scapholunate instability and review of evidence for management in the absence of arthritis. *J Hand Surg Eur*. 2013, 38: 727-38.
50. Cheng JCY, Shen WY. Limb fracture pattern in different age groups: a study of 3,350 children. *J Orthop Trauma*. 1993, 7: 15-22.
51. Cohen MS, Taleisnik J. Direct ligamentous repair of scapholunate dissociation with capsulodesis augmentation. *Tech Hand Up Extrem Surg*. 1998, 2: 18-24.
52. Cohen MS, Taleisnik J. Ligamentous repair for scapholunate instability and dissociation. In: Watson HK, Weinzweig J. eds. *The Wrist*. Philadelphia: Lippincott, Williams & Wilkins; 2001: 491-9.
53. Cooney WP, Dobyns JH, Linscheid RL. Complications of Colles' fractures. *J Bone Joint Surg Am*. 1980, 62: 613-9.
54. Cooney WP, Linscheid RL, Dobyns JH. Triangular fibrocartilage tears. *J Hand Surg Am*. 1994, 19: 143-54.
55. Cooney W, Manuel J, Froelich J, Rizzo M. Total wrist replacement: a retrospective comparative study. *J Wrist Surg*. 2012, 1: 165-72.



56. Corella F, Del Cerro M, Larrainzar-Garrijo R, Vázquez T. Arthroscopic ligamentoplasty (bone-tendon-tenodesis). A new surgical technique for scapholunate instability: preliminary cadaver study. *J Hand Surg Eur.* 2011, 36: 682-9.
57. Corella F, Del Cerro M, Ocampos M, Larrainzar-Garrijo R. Arthroscopic ligamentoplasty of the dorsal and volar portions of the scapholunate ligament. *J Hand Surg Am.* 2013, 38: 2466-77.
58. Culp RW. Complications of wrist arthroscopy. *Hand Clin* 1999, 15: 529-35.
59. Dao KD, Solomon DJ, Shin AY, Puckett ML. The efficacy of ultrasound in the evaluation of dynamic scapholunate ligamentous instability. *J Bone Joint Surg Am.* 2004, 86: 1473-8.
60. Darlis NA, Kaufmann RA, Giannoulis F, Sotereanos DG. Arthroscopic debridement and closed pinning for chronic dynamic scapholunate instability. *J Hand Surg Am.* 2006, 31: 418-24.
61. Darrach W. Partial excision of lower shaft of ulna for deformity following Colles' fracture. *Ann Surg.* 1913, 57: 764-5.
62. Davis DR, Green DP. Forearm fractures in children: pitfalls and complications. *Clin Orthop Relat Res.* 1976, 120: 172-83.
63. del Piñal F. Dry arthroscopy and its applications. *Hand Clin.* 2011, 27: 335-45.
64. del Piñal F, García-Bernal FJ, Cagigal L, Studer A, Regalado J, Thams C. A technique for arthroscopic all-inside suturing in the wrist. *J Hand Surg Eur.* 2010, 35: 475-9.
65. del Piñal F, García-Bernal FJ, Pisani D, Regalado J, Ayala H, Studer A. Dry arthroscopy of the wrist: surgical technique. *J Hand Surg Am* 2007, 32: 119-23.
66. del Piñal F, Studer A, Thams C, Glasberg A. An all-inside technique for arthroscopic suturing of the volar scapholunate ligament. *J Hand Surg Am.* 2011, 36: 2044-6.
67. De Smet L. Pitfalls in wrist arthroscopy. *Acta Orthop Belg.* 2002, 68: 325-9.
68. De Smet L. Magnetic resonance imaging for diagnosing lesions of the triangular fibrocartilage complex. *Acta Orthop Belg.* 2005, 71: 396-8.
69. De Smet L, Fabry G. Orientation of the sigmoid notch of the distal radius: determination of different types of the distal radioulnar joint. *Acta Orthop Belg.* 1993, 59: 269-72.
70. Dobyns JH, Linscheid RL. Carpal instability classification and historical perspective. In: Cooney III WP, ed. *The wrist: Diagnosis and Operative Treatment.* 2nd ed. Lippincott Williams & Wilkins, 2010: 608-16.

71. Ehman EC, Hayes ML, Berger RA, Felmlee JP, Amrami KK. Subluxation of the distal radioulnar joint as a predictor of foveal triangular fibrocartilage complex tears. *J Hand Surg Am.* 2011, 36: 1780-4.
72. Eils E, Rosenbaum D. A multistation proprioceptive exercise program in patients with ankle instability. *Med Sci Sports Exerc.* 2001, 33: 1991-8.
73. el-Noueam KI, Schweitzer ME, Blasbalg R, Farahat AA, Culp RW, Osterman LA, Malik A. Is a subset of wrist ganglia the sequela of internal derangements of the wrist joint? MR imaging findings. *Radiology.* 1999, 212: 537-40.
74. Estrella EP, Hung LK, Ho PC, Tse WL. Arthroscopic repair of triangular fibrocartilage complex tears. *Arthroscopy.* 2007, 23: 729-37.
75. Farr S, Grill F, Ganger R, Graf A, Girsch W. Pathomorphologic findings of wrist arthroscopy in children and adolescents with chronic wrist pain. *Arthroscopy.* 2012, 28: 1634-43.
76. Farr S, Grill F, Girsch W. Wrist arthroscopy in children and adolescents: a single surgeon experience of thirty-four cases. *Int Orthop.* 2012, 36: 1215-20.
77. Feinstein WK, Lichtman DM, Noble PC et al. Quantitative assessment of the midcarpal shift test. *J Hand Surg Am.* 1999, 24: 977-83.
78. Fontes D, Lenoble E, de Somer B, Benoit J. Lesions of the ligaments associated with distal fractures of the radius. 58 intraoperative arthrographies. *Ann Chir Main Memb Super.* 1992, 11: 119-25.
79. Forli A, Courvoisier A, Wimsey S, Corcella D, Moutet F. Perilunate dislocations and transscaphoid perilunate fracture-dislocations: a retrospective study with minimum ten-year follow-up. *J Hand Surg Am.* 2010, 35: 62-8.
80. Forward DP, Lindau TR, Melsom DS. Intercarpal ligament injuries associated with fractures of the distal part of the radius. *J Bone Joint Surg Am.* 2007, 89: 2334-40.
81. Friberg KS. Remodeling after distal forearm fractures in children. III. Correction of residual angulation in fractures of the radius. *Acta Orthop Scand.* 1979, 50: 741-9.
82. Frykman G. Fracture of the distal radius including sequelae - shoulder-hand-finger syndrome, disturbance in the distal radio-ulnar joint and impairment of nerve function. A clinical and experimental study. *Acta Orthop Scand.* 1967, Suppl: 3+.
83. Fujitani R, Omokawa S, Akahane M, Iida A, Ono H, Tanaka Y. Predictors of Distal Radioulnar Joint Instability in Distal Radius Fractures. *J Hand Surg Am.* 2011, 36:1919-25.

84. Gajendran VK, Peterson B, Slater RR Jr, Szabo RM. Long-term outcomes of dorsal intercarpal ligament capsulodesis for chronic scapholunate dissociation. *J Hand Surg Am.* 2007, 32: 1323-33.
85. Garcia-Elias M. The non-dissociative clunking wrist: a personal view. *J Hand Surg Eur.* 2008, 33: 698-711.
86. Garcia-Elias M, Alomar Serrallach X, Monill Serra J. Dart-throwing motion in patients with scapholunate instability: a dynamic four-dimensional computed tomography study. *J Hand Surg Eur.* 2014, 39: 346-52.
87. Garcia-Elias M, Lluch AL, Stanley JK. Three-ligament tenodesis for the treatment of scapholunate dissociation: indications and surgical technique. *J Hand Surg Am.* 2006, 31: 125-34.
88. Garcia-Elias M. Carpal instability. In: Wolfe SW, Hotchkiss RN, Pederson WC, Kozin S, eds. *Green's operative hand surgery.* Vol 1. 6th ed. New York: Elsevier Churchill Livingstone, 2011: 465-522.
89. Garcia-Elias M, Geissler WB. Carpal instability. In: Green DP, Hotchkiss RN, Pederson WC, Wolfe SW, eds. *Green's Operative Hand Surgery.* Vol 1. 5th ed. Philadelphia: Elsevier Churchill Livingstone, 2005: 535-604.
90. Garcia-Elias M, Lluch AL, Ferreres A, Lluch A, Lhamby F. Transverse loaded pronosupination test. *J Hand Surg Eur.* 2008, 38: 765-7.
91. Garcia-Elias M, Smith DE, Llusá M. Surgical approach to the triangular fibrocartilage complex. *Tech Hand Up Extrem Surg.* 2003, 7: 134-40.
92. Geissler WB, Freeland AE, Savoie FH, McIntyre LW, Whipple TL. Intracarpal soft-tissue lesions associated with an intra-articular fracture of the distal end of the radius. *J Bone Joint Surg Am.* 1996, 78: 357-65.
93. Gelberman RH, Menon J. The vascularity of the scaphoid bone. *J Hand Surg Am.* 1980, 5: 508-13.
94. Gilula LA. Carpal injuries: analytic approach and case exercises. *AJR. Am J Roentgenol.* 1979, 133: 503-17.
95. Hagert E. Proprioception of the wrist joint: A review of current concepts and possible implications on the rehabilitation of the wrist. *J Hand Ther.* 2010, 23: 2-16.
96. Hagert E, Hagert C. Understanding stability of the distal radioulnar joint through an understanding of its anatomy. *Hand Clin.* 2010, 26: 459-66.
97. Hagert E, Lluch A, Rein S. The role of proprioception and neuromuscular stability in carpal instabilities. *J Hand Surg Eur.* 2016, 41: 94-101.

98. Hahn P, Häusler A, Bruckner T, Unglaub F. Quality rating of MRI regarding TFCC lesions in the clinical practice. *Handchir Mikrochir Plast Chir.* 2012, 44: 310-3.
99. Haims AH, Schweitzer ME, Morrison WB, Deely D, Lange R, Osterman AL, Bednar JM, Taras JS, Culp RW. Limitations of MR imaging in the diagnosis of peripheral tears of the triangular fibrocartilage of the wrist. *AJR Am J Roentgenol.* 2002, 178: 419-22.
100. Hanker GJ. Diagnostic and operative arthroscopy of the wrist. *Clin Orthop Relat Res.* 1991, 263: 165-74.
101. Harvey EJ, Berger RA, Osterman AL, Fernandez DL, Weiss AP. Bone-tissue-bone repairs for scapholunate dissociation. *J Hand Surg Am.* 2007, 32: 256-64.
102. Haugstvedt JR, Berger RA, Nakamura T, Neale P, Berglund L, An KN. Relative contributions of the ulnar attachments of the triangular fibrocartilage complex to the dynamic stability of the distal radioulnar joint. *J Hand Surg Am.* 2006, 31: 445-51.
103. Heiss-Dunlop W, Couzens GB, Peters SE, Gadd K, Di Mascio L, Ross M. Comparison of plain x-rays and computed tomography for assessing distal radioulnar joint inclination. *J Hand Surg Am.* 2014, 39: 2417-23.
104. Helm RH, Tonkin MA. The Chauffeur's fracture: simple or complex. *J Hand Surg Br.* 1992, 17: 156-9.
105. Henry MH. Management of acute triangular fibrocartilage complex injury of the wrist. *J Am Acad Orthop Surg.* 2008, 16: 320-9.
106. Herzberg G. Perilunate and axial carpal dislocations and fracture-dislocations. Current concepts. *J Hand Surg Am.* 2008, 33: 1659-68.
107. Herzberg G, Berthounaud E, Bestion A, Dimnet J. Testing of pronation and supination strength in the outpatient setting: a preliminary study. *Chirurgie de la main.* 2007, 26: 40-3.
108. Herzberg G, Comtet JJ, Linscheid RL, Amadio PC, Cooney WP, Stalder J. Perilunate dislocations and fracture-dislocations: a multicenter study. *J Hand Surg Am.* 1993, 18: 768-79.
109. Hirsh L, Sodha S, Bozentka D, Monaghan B, Steinberg D, Beredjikian PK. Arthroscopic electrothermal collagen shrinkage for symptomatic laxity of the scapholunate interosseous ligament. *J Hand Surg Br.* 2005, 30: 643-7.
110. Hixson ML, Stewart C. Microvascular anatomy of the radioscapholunate ligament of the wrist. *J Hand Surg Am.* 1990, 15: 279-82.

111. Hobby JL, Torn BD, Bearcroft PW, Dixon AK. Magnetic resonance imaging of the wrist: Diagnostic performance statistics. *Clin Radiol*. 2001, 56: 50–7.
112. Houshian S, Holst AK, Larsen MS, Torfing T. Remodeling of Salter-Harris type II epiphyseal plate injury of the distal radius. *J Pediatr Orthop*. 2004, 24: 472–6.
113. Iordache SD, Rowan R, Garvin GJ, Osman S, Grewal R, Faber KJ. Prevalence of triangular fibrocartilage complex abnormalities on MRI scans of asymptomatic wrists. *J Hand Surg Am*. 2012, 37: 98–103.
114. Jakubietz MG, Zahn R, Gruenert JG, Waschke J, Meffert RH, Jakubietz RG. Kirschner wire fixations for scapholunate dissociation: a cadaveric, biomechanical study. *J Orthop Surg (Hong Kong)*. 2012, 20: 224–9.
115. Johari AN, Sinha M. Remodeling of forearm fractures in children. *J Pediatr Orthop Br*. 1999, 8: 84–7.
116. Jones WA. Beware the sprained wrist. The incidence and diagnosis of scapholunate instability. *J Bone Joint Surg Br*. 1988, 70: 293–7.
117. Jørgsholm P. Scaphoid fractures - Epidemiology, diagnosis and treatment. Lund: Department of Hand Surgery, Skåne University Hospital, Malmö, Clinical Science, Faculty of medicine, Lund University, Lund, Sweden, 2015 (dissertation).
118. Jørgsholm P, Thomsen NO, Bjorkman A, Besjakov J, Abrahamsson SO. The incidence of intrinsic and extrinsic ligament injuries in scaphoid waist fractures. *J Hand Surg Am*. 2010, 35: 368–74.
119. Kato H, Nakamura R, Shionoya K, Makino N, Imaeda T. Does high-resolution MR imaging have better accuracy than standard MR imaging for evaluation of the triangular fibrocartilage complex? *J Hand Surg Br*. 2000, 25: 487–91.
120. Kirchberger MC, Unglaub F, Mühldorfer-Fodor M, Pillukat T, Hahn P, Müller LP, Spies CK. Update TFCC: histology and pathology, classification, examination and diagnostics. *Arch Orthop Trauma Surg*. 2015, 135: 427–37.
121. Kitay A, Wolfe SW. Scapholunate instability: current concepts in diagnosis and management. *J Hand Surg Am*. 2012; 37: 2175–96.
122. Kleinman WB. Stability of the distal radioulnar joint: biomechanics, pathophysiology, physical diagnosis, and restoration of function. What we have learned in 25 years. *J Hand Surg Am*. 2007, 32: 1086–1106.
123. Kleinman WB, Graham TJ. The distal radioulnar joint capsule: clinical anatomy and role in posttraumatic limitation of forearm rotation. *J Hand Surg Am*. 1998, 23: 588–99.

124. Kopylov P, Johnell O, Redlund-Johnell I, et al. Fractures of the distal end of the radius in young adults: a 30-year follow-up. *J Hand Surg Br.* 1993, 18: 45-9.
125. Korompilias AV, Lykissas MG, Kostas-Agnantis IP, Beris AE, Soucacos PN. Distal radioulnar joint instability (Galeazzi type injury) after internal fixation in relation to the radius fracture pattern. *J Hand Surg Am.* 2011, 36: 847-52.
126. Kramer JF, Nusca D, Bisbee L, MacDermid J, Kemp D, Boley S. Forearm pronation and supination: reliability of absolute torques and nondominant/dominant ratios. *J Hand Ther.* 1994, 7: 15-20.
127. Kuo CE, Wolfe SW. Scapholunate instability: current concepts in diagnosis and management. *J Hand Surg Am.* 2008, 33: 998-1013.
128. Landin LA. Fracture patterns in children. *Acta Orthop Scand.* 1983, 54 (Suppl 202): 1-109.
129. LaStayo P, Howell J. Clinical provocative tests used in evaluating wrist pain: a descriptive study. *J Hand Ther.* 1995, 8: 10-7.
130. LaStayo P, Weiss S. The GRIT: A quantitative measure of ulnar impaction syndrome. *J Hand Ther.* 2001, 14: 173-9.
131. Lavernia CJ, Cohen MS, Taleisnik J. Treatment of scapholunate dissociation by ligamentous repair and capsulodesis. *J Hand Surg Am.* 1992, 17: 354-9.
132. Lee YH, Choi YR, Kim S, Song HT, Suh JS. Intrinsic ligament and triangular fibrocartilage complex (TFCC) tears of the wrist: Comparison of isovolumetric 3D-THRIVE sequence MR arthrography and conventional MR image at 3 T. *Magn Reson Imaging.* 2013, 31: 221-6.
133. Lee SK, Zlotolow DA, Sapienza A, Karia R, Yao J. Biomechanical comparison of 3 methods of scapholunate ligament reconstruction. *J Hand Surg Am.* 2014, 39: 643-50.
134. Lenk S, Ludescher B, Martirosan P, Schick F, Claussen CD, Schlemmer HP. 3.0 T high-resolution MR imaging of carpal ligaments and TFCC. *Rofo.* 2004, 176: 664-7.
135. Lindau T. Distal radial fractures and effects of associated ligament injuries. Lund: Department of Orthopedics, Lund University Hospital, Lund, Sweden, 2000 (dissertation).
136. Lindau TR. The role of arthroscopy in carpal instability. *J Hand Surg Eur.* 2016, 41: 35-47.

137. Lindau T, Adlercreutz C, Aspenberg P. Peripheral tears of the triangular fibrocartilage complex cause distal radioulnar joint instability after distal radial fractures. *J Hand Surg Am*. 2000, 25: 464-8.
138. Lindau T, Arner M, Hagberg L. Chondral and ligamentous wrist lesions in young adults with distal radius fractures. A descriptive, arthroscopic study in 50 patients. *J Hand Surg Br*. 1997, 22: 638-43.
139. Lindau T, Aspenberg P, Adlercreutz C, Jonsson K, Hagberg L. Instability of the distal radioulnar joint is an independent worsening factor after distal radial fractures. *Clin Orthop*. 2000, 376: 229-35.
140. Lindau T, Runnquist K, Aspenberg P. Patients with laxity of distal radioulnar joint after distal radial fractures have impaired function, but no loss of strength. *Acta Orthop Scand*. 2002, 73: 151-6.
141. Linscheid RL, Dobyns JH, Beabout JW, Bryan RS. Traumatic instability of the wrist: Diagnosis, classification and pathomechanics. *J Bone Joint Surg Am*. 1972, 54: 1612-32.
142. Linscheid RL, Dobyns JH. Treatment of scapholunate dissociation. Rotatory subluxation of the scaphoid. *Hand Clin*. 1992, 8: 645-52.
143. Loew S, Herold D, Muhldorfer-Fudor, Pillukat T. The effect of labeling photo documents in wrist arthroscopies on intra- and interobserver reliability. *Arch Orthop Trauma Surg*. 2012, 132: 1813-8.
144. Loew S, Prommersberger KJ, Pillukat T, von Schoonhoven J. Intra- and interobserver reliability of digitally photodocumented findings in wrist arthroscopy. *Handchir Mikrochir Plast Chir*. 2010, 42: 287-92.
145. Magee T. Comparison of 3-T MRI and arthroscopy of intrinsic wrist ligament and TFCC tears. *AJR Am J Roentgenol*. 2009, 192: 80-5.
146. Manton GL, Schweitzer ME, Weishaupt D, et al. Partial interosseous ligament tears of the wrist: Difficulty in utilizing either primary or secondary MRI signs. *J Comput Assist Tomogr*. 2001, 25: 671-6.
147. Mathoulin C, Dauphin N, Sallen V. Arthroscopic dorsal capsuloplasty in chronic scapholunate ligament tears: a new procedure; preliminary report. *Chirurgie de la main*. 2011, 30: 188-97.
148. Mathoulin CL, Dauphin N, Wahegaonkar AL. Arthroscopic dorsal capsuloligamentous repair in chronic scapholunate ligament tears. *Hand Clin*. 2011, 27: 563-72.

149. Matsuoka J, Berger RA, Berglund LJ, An KN. An analysis of symmetry of torque strength of the forearm under resisted forearm rotation in normal subjects. *J Hand Surg Am.* 2006, 31: 801-5.
150. May MM, Lawton JN, Blazar PE. Ulnar styloid fractures associated with distal radius fractures: incidence and implications for distal radioulnar joint instability. *J Hand Surg Am.* 2002, 27: 965-71.
151. Mayfield JK, Johnson RP, Kilcoyne RK. Carpal dislocations: Pathomechanics and progressive perilunar instability. *J Hand Surg Am.* 1980, 5: 226-41.
152. Megerle K, Bertel D, Germann G, Lehnhardt M, Hellmich S. Long-term results of dorsal intercarpal ligament capsulodesis for the treatment of chronic scapholunate instability. *J Bone Joint Surg Br* 2012, 94: 1660-5.
153. Mehta JA, Bain GI, Heptinstall RJ. Anatomical reduction of intra-articular fractures of the distal radius. An arthroscopically-assisted approach. *J Bone Joint Surg Br.* 2000, 82: 79-86.
154. Millard GM, Budoff JE, Paravic V, Noble PC. Functional bracing for distal radioulnar joint instability. *J Hand Surg Am.* 2002, 27: 972-7.
155. Mirza A, Mirza JB, Shin AY, Lorenzana DJ, Lee BK, Izzo B. Isolated lunotriquetral ligament tears treated with ulnar shortening osteotomy. *J Hand Surg Am.* 2013, 38: 1492-7.
156. Moher D, Liberati A, Tetzlaff J, Altman DG. Preferred reporting items for systematic reviews and meta-analyses: The PRISMA statement. *J Clin Epidemiol.* 2009, 62: 1006-12.
157. Moran SL, Garcia-Elias M. Acute scapholunate injuries. In: Cooney III WP, ed. *The Wrist: Diagnosis and Operative Treatment.* 2nd ed. Philadelphia: Wolters Kluwer, Lippincott, Williams & Wilkins; 2010: 617-41.
158. Morley J, Bidwell J, Bransby-Zachary M. A comparison of the findings of wrist arthroscopy and magnetic resonance imaging in the investigation of wrist pain. *J Hand Surg Br.* 2001, 26: 544-6.
159. Morse JL, Jung MC, Bashford GR, Hallbeck MS. Maximal dynamic grip force and wrist torque: The effects of gender, exertion direction, angular velocity, and wrist angle. *Applied Ergonomics.* 2006, 37: 737-42.
160. Mrkonjic A, Geijer M, Lindau T, Tägil M. The natural course of traumatic triangular fibrocartilage complex tears in distal radial fractures: a 13–15 year follow-up of arthroscopically diagnosed but untreated injuries. *J Hand Surg Am.* 2012, 37: 1555–60.



161. Mudgal C, Hastings H. Scapho-lunate diastasis in fractures of the distal radius. Pathomechanics and treatment options. *J Hand Surg Br.* 1993, 18: 725-9.
162. Mudgal CS, Jones WA. Scapholunate diastasis: a component of fractures of the distal radius. *J Hand Surg Br.* 1990, 15: 503-5.
163. Mulford JS, Ceulemans LJ, Nam D, Axelrod TS. Proximal row carpectomy vs four corner fusion for scapholunate (SLAC) or scaphoid nonunion advanced collapse (SNAC) wrists: a systematic review of outcomes. *J Hand Surg Eur.* 2009, 34: 256-63.
164. Möldner M, Unglaub F, Hahn P, Müller LP, Bruckner T, Spies CK. Functionality after arthroscopic debridement of central triangular fibrocartilage tears with central perforations. *J Hand Surg Am.* 2015, 40: 252-8.
165. Nakamura T, Abe K, Iwamoto T, Ochi K, Sato K. Reconstruction of the scapholunate ligament using capitohamate bone-ligament-bone. *J Wrist Surg.* 2015, 4: 264-8.
166. Nakamura T, Yabe Y, Horiuchi Y. Functional anatomy of the triangular fibrocartilage complex. *J Hand Surg Br.* 1996, 21: 581-6.
167. Nishiwaki M, Nakamura T, Nakao Y, Nagura T, Toyama Y. Ulnar shortening effect on distal radioulnar joint stability: a biomechanical study. *J Hand Surg Am.* 2005, 30: 719-26.
168. Ogawa T, Tanaka T, Yanai T, Kumagai H, Ochiai N. Analysis of soft tissue injuries associated with distal radius fractures. *BMC Sports Sci Med Rehabil.* 2013, 5: 19
169. Oneson SR, Timins ME, Scales LM, Erickson SJ, Chamoy L. MR imaging diagnosis of triangular fibrocartilage pathology with arthroscopic correlation. *AJR Am J Roentgenol.* 1997, 168: 1513-18.
170. O'Sullivan LW, Gallwey TJ. Upper-limb surface electro-myography at maximum supination and pronation torques: the effect of elbow and forearm angle. *J Electromyogr Kinesiol.* 2002, 12: 275-85.
171. O'Sullivan LW, Gallwey TJ. Forearm torque strengths and discomfort profiles in pronation and supination. *Ergonomics.* 2005, 6: 703-21.
172. Osterman AL. Arthroscopic debridement of triangular fibrocartilage tears. *Arthroscopy.* 1990, 6: 120-4.
173. Palmer AK. Triangular fibrocartilage complex lesions: A classification. *J Hand Surg Am.* 1989, 14: 594-606.

174. Palmer AK. Triangular fibrocartilage disorders: injury patterns and treatment. *Arthroscopy*. 1990, 6: 125–32.
175. Palmer AK, Werner FW. The triangular fibrocartilage complex of the wrist: anatomy and function. *J Hand Surg Am*. 1981, 6: 153-62.
176. Park MJ, Lee MC, Seong SC. A comparative study of the healing of tendon autograft and tendon-bone autograft using patellar tendon in rabbits. *Int Orthop*. 2001, 25: 35-9.
177. Pillukat T, van Schoonhoven J. The hemiresection-interposition arthroplasty of the distal radioulnar joint. *Oper Orthop Traumatol*. 2009, 21: 484-97.
178. Prosser R, Harvey L, LaStayo P, Hargreaves I, Scougall P, Herbert RD. Provocative wrist tests and MRI are of limited diagnostic value for suspected wrist ligament injuries: A cross-sectional study. *J Physiother*. 2011, 57: 247-53.
179. Rampazzo A, Gharb BB, Brock G, Scheker LR. Functional Outcomes of the Aptis-Scheker Distal Radioulnar Joint Replacement in Patients Under 40 Years Old. *J Hand Surg Am*. 2015, 40: 1397-1403.e3.
180. Reichel LM, Bell BR, Michnick SM, Reitman CA. Radial styloid fractures. *J Hand Surg Am*. 2012, 37: 1726-41.
181. Rettig ME, Amadio PC. Wrist injuries correlation of clinical and arthroscopic findings. *J Hand Surg Br*. 1994, 19: 774-7.
182. Richards LG, Olson B, Palmiter-Thomas P. How forearm position affects grip strength. *Am J Occup Ther*. 1996, 2: 133-8.
183. Richards RS, Bennett JD, Roth JH, Milne K Jr. Arthroscopic diagnosis of intra-articular soft tissue injuries associated with distal radial fractures. *J Hand Surg Am*. 1997, 22: 772-6.
184. Ringler MD. MRI of wrist ligaments. *J Hand Surg Am*. 2013, 38: 2034-46.
185. Ringler MD, Howe BM, Amrami KK, Hagen CE, Berger RA. Utility of magnetic resonance imaging for detection of longitudinal split tear of the ulnotriquetral ligament. *J Hand Surg Am*. 2013, 38: 1723-27.
186. Rosenwasser MP, Miyasajsa KC, Strauch RJ. The RASL procedure: reduction and association of the scaphoid and lunate using the Herbert screw. *Tech Hand Up Extrem Surg*. 1997, 1: 263-72.
187. Rotman MB, Manske PR, Pruitt DL, Szerzinski J. Scaphocapitolunate arthrodesis. *J Hand Surg Am*. 1993, 18: 26–33.

188. Ruegger C, Schmid MR, Pfirrmann CWA, Nagy L, Gilula LA, Zanetti M. Peripheral tear of the triangular fibrocartilage: depiction with MR arthrography of the distal radioulnar joint. *AJR Am J Roentgenol.* 2007, 188: 187-92.
189. Ruston J, Konan S, Rubinraut E, Sorene E. Diagnostic accuracy of clinical examination and magnetic resonance imaging for common articular wrist pathology. *Acta Orthop Belg.* 2013, 79: 375-80.
190. Salter RB, Harris WR. Injuries involving the epiphyseal plate. *J Bone Joint Surg Am.* 1963, 45: 587-622.
191. Salva-Coll G, Garcia-Elias M, Leon-Lopez MT, Llusà-Perez M, Rodríguez-Baeza A. Effects of forearm muscles on carpal stability. *J Hand Surg Eur.* 2011, 36: 553-9.
192. Saltzman BM, Frank JM, Slikker W, Fernandez JJ, Cohen MS, Wysocki RW. Clinical outcomes of proximal row carpectomy versus four-corner arthrodesis for post-traumatic wrist arthropathy: a systematic review. *J Hand Surg Eur.* 2015, 40: 450-7.
193. Samuelsson K, Desai N, McNair E, van Ech CF, Petzold M, Fu FH, Bhandari M, Karlsson J. Level of evidence in anterior cruciate ligament reconstruction research. *Am J Sports Med.* 2013, 41: 924-34.
194. Sauerbier M, Hahn ME, Berglund LJ, An K-N, Berger RA. Biomechanical evaluation of the dynamic radioulnar convergence after ulnar head resection, two soft tissue stabilization methods of the distal ulna and ulnar head prosthesis implantation. *Arch Orthop Trauma Surg.* 2011, 131: 15-26.
195. Sauvé L, Kapandji M. Nouvelle technique de traitement chirurgical des luxations recidivantes isolees de l'extremite inferieure du cubitus. *J Chir.* 1936, 47: 589-94.
196. Scheer JH. Perilunar injuries associated with distal radius fractures. Linköping Faculty of health sciences, Linköping University, Linköping, Sweden, 2011 (dissertation).
197. Scheer JH, Hammerby S, Adolfsson LE. Radioulnar ratio in detection of distal radioulnar joint instability associated with acute distal radius fractures. *J Hand Surg Eur.* 2010, 35: 730-4.
198. Schweitzer ME, Brahme SK, Hodler J, Hanker GJ, Lynch TP, Flannigan BD, Godzik CA, Resnick D. Chronic wrist pain: spin-echo and short tau inversion recovery MR imaging and conventional and MR arthrography. *Radiology.* 1992, 182: 205-11.

199. Schütz A, Dobner P. Effect of wrist arthroscopy with intraarticular hyaluronan substitution therapy: a randomised, controlled, prospective, non-blinded, single-centre, comparative trial. *Handchir Mikrochir Plast Chir.* 2013, 45: 277-84.
200. Sennwald GR, Fischer M, Mondl P. Lunotriquetral arthrodesis: a controversial procedure. *J Hand Surg Am.* 1995, 20: 775-80.
201. Shih JT, Lee HM. Monopolar radiofrequency electrothermal shrinkage of the scapholunate ligament. *Arthroscopy.* 2006, 22: 553-7.
202. Short WH, Werner FW, Green JK, Maasaoka S. Biomechanical evolution of ligamentous stabilizers of the scaphoid and lunate. *J Hand Surg Am.* 2002, 27: 991-1002.
203. Short WH, Werner FW, Green JK, Sutton LG, Brutus JP. Biomechanical evaluation of the ligamentous stabilizers of the scaphoid and lunate: part III. *J Hand Surg Am.* 2007, 32: 297-309.
204. Short WH, Werner FW, Sutton LG. Dynamic biomechanical evaluation of the dorsal intercarpal ligament repair for scapholunate instability. *J Hand Surg Am.* 2009, 34: 652-9.
205. Shrout PE, Fleiss JL. Intraclass correlations: Uses in assessing rater reliability. *Psychol Bull.* 1979, 86: 420-8.
206. Silman AJ, Haskard D, Day S. Distribution of joint mobility in a normal population: results of the use of fixed torque measuring devices. *Ann Rheum Dis.* 1986, 45: 27-30.
207. Skelley NW, Castile RM, York TE, Gruev V, Lake SP, Brophy RH. Differences in the microstructural properties of the anteromedial and posterolateral bundles of the anterior cruciate ligament. *Am J Sports Med.* 2015, 43: 928-36.
208. Skillern PG. Complete fracture of the lower third of the radius in childhood with greenstick fracture of the ulna. *Ann Surg.* 1915, 61: 209-25.
209. Slater RR Jr, Szabo RM. Scapholunate dissociation: treatment with the dorsal intercarpal ligament capsulodesis. *Tech Hand Up Extrem Surg.* 1999, 3: 222-8.
210. Slutsky DJ. Wrist arthroscopy through a volar radial portal. *Arthroscopy.* 2002, 18: 624-30.
211. Slutsky DJ. Clinical applications of volar portals in wrist arthroscopy. *Tech Hand Up Extrem Surg.* 2004, 8: 229-38.
212. Smith, T O; Drew, B T; Toms, A P; Chojnowski, A J. The diagnostic accuracy of x-ray arthrography for triangular fibrocartilaginous complex injury: a systematic review and meta-analysis. *J Hand Surg Eur.* 2012, 37: 879-87.

213. Spies CK, Müller LP, Oppermann J, Hahn P, Unglaub F. Instability of the distal radioulnar joint-an overview of clinical and radiological procedures regarding their efficacies. *Handchir Mikrochir Plast Chir.* 2014, 46: 137–50.
214. Spies CK, Müller LP, Unglaub F, Hahn P, Klum M, Oppermann J. Anatomical transosseous fixation of the deep and superficial fibers of the radioulnar ligaments. *Arch Orthop Trauma Surg.* 2014, 134: 1783-8.
215. Stuffmann ES, McAdams TR, Shah RP, Yao J. Arthroscopic repair of the scapholunate ligament. *Tech Hand Up Extrem Surg.* 2010, 14: 204-8.
216. Sugimoto H, Shinozaki T, Ohsawa T. Triangular fibrocartilage in asymptomatic subjects: investigation of abnormal MR signal intensity. *Radiology.* 1994, 191: 193-7.
217. Taleisnik J. Post-traumatic carpal instability. *Clin Orthop Relat Res.* 1980, 149: 73-82.
218. Tambe AD, Trail IA, Stanley JK. Wrist fusion versus limited carpal fusion in advanced Kienbock's disease. *Int Orthop.* 2005, 29: 355-8.
219. Tanaka T, Yoshioka H, Ueno T, Shindo M, Ochiai N. Comparison between high-resolution MRI with a microscopy coil and arthroscopy in triangular fibrocartilage complex injury. *J Hand Surg Am.* 2006, 31: 1308-14.
220. Tay SC, Tornita K, Berger RA. The "ulnar fovea sign" for defining ulnar wrist pain: An analysis of sensitivity and specificity. *J Hand Surg Am.* 2007; 32: 438-44.
221. Terry CL, Waters PM. Triangular fibrocartilage injuries in pediatric and adolescent patients. *J Hand Surg Am.* 1998, 23: 626–34.
222. Theumann NH, Etehami G, Duvoisin B, et al. Association between extrinsic and intrinsic carpal ligament injuries at MR arthrography and carpal instability at radiography: initial observations. *Radiology.* 2006, 238: 950-7.
223. Thiru RG, Ferlic DC, Clayton ML, McClure DC. Arterial anatomy of the triangular fibrocartilage of the wrist and its surgical significance. *J Hand Surg Am.* 1986, 11: 258-63.
224. Thurston AJ. The scope of wrist arthroscopy. *Current Orthopaedics.* 1999, 13: 120-30.
225. Timm WN, O'Driscoll SW, Johnson ME, An KN. Functional comparison of pronation and supination strengths. *J Hand Ther.* 1993, 6: 190-3.
226. Tolat AR, Stanley JK, Trial IA. A cadaveric study of the anatomy and stability of the distal radioulnar joint in the coronal and transverse planes. *J Hand Surg Br.* 1996, 21: 587-94.

227. Tomaino MM, Weiser RW. Combined arthroscopic TFCC debridement and wafer resection of the distal ulna in wrists with triangular fibrocartilage complex tears and positive ulnar variance. *J Hand Surg Am.* 2001, 26: 1047-52.
228. Tredwell SJ, Van Peteghem K, Clough M. Pattern of forearm fractures in children. *J Pediatr Orthop.* 1984, 4: 604-8.
229. Trojian TH, Concoff AL, Joy SM, Hatzenbuehler JR, Saulsberry WJ, Coleman CI. AMSSM scientific statement concerning viscosupplementation injections for knee osteoarthritis: importance for individual patient outcomes. *Br J Sports Med.* 2016, 50: 84-92.
230. Trumble TE, Gilbert M, Vedder N. Arthroscopic repair of the triangular fibrocartilage complex. *Arthroscopy.* 1996, 12: 588-97.
231. Unglaub F, Manz S, Bruckner T, Leclercq FM, Hahn P, Wolf MB. Dorsal capsular imbrication for dorsal instability of the distal radioulnar joint. *Oper Orthop Traumatol.* 2013, 25: 609-14.
232. Valdes K, Naughton N, Algar L. Sensorimotor interventions and assessments for the hand and wrist: a scoping review. *J Hand Ther.* 2014, 27: 272-85
233. Van Den Abbeele KL, Loh YC, Stanley JK, Trail IA. Early results of a modified Brunelli procedure for scapholunate instability. *J Hand Surg Br.* 1998, 23: 258-61.
234. van de Grift TC, Ritt MJPF. Management of lunotriquetral instability: a review of the literature. *J Hand Surg Eur.* 2016, 41: 72-85.
235. Vanhove W, De Vil J, Van Seymortier P, Boone B, Verdonk R. Proximal row carpectomy versus four-corner arthrodesis as a treatment for SLAC (scapholunate advanced collapse) wrist. *J Hand Surg Eur.* 2008, 33: 118-25.
236. van Kampen RJ, Bayne CO, Moran SL, Berger RA. Outcomes of capitohamate bone-ligament-bone grafts for scapholunate injury. *J Wrist Surg.* 2015, 4: 230-8.
237. van Schoonhoven. Arthroscopy of the wrist and hand. *J Oper Orthop Traumatol.* 2014, 26: 537-8.
238. von Lanz, T, Wachsmuth W. *Praktische Anatomie*, Berlin, Julius Springer. 1938: 28.
239. Warhold LG, Ruth RM. Complications of wrist arthroscopy and how to prevent them. *Hand Clin.* 1995, 11: 81-9.
240. Watanabe H, Berger RA, Berglund LJ, Zobitz ME, An KN. Contribution of the interosseous membrane to distal radioulnar joint constraint. *J Hand Surg Am.* 2005, 30: 1164-71.

241. Watson HK, Ballet FL. The SLAC wrist: scapholunate advanced collapse pattern of degenerative arthritis. *J Hand Surg Am.* 1984, 9: 358-65.
242. Watson HK, Ryu J. Evolution of arthritis of the wrist. *Clin Orthop Relat Res.* 1986, 202: 57-67.
243. Watson HK, Weinzweig J, Zeppieri J. The natural progression of scaphoid instability. *Hand Clin.* 1997, 13: 39-49.
244. Weintraub J, Osterman AL, Yao J. Arthroscopic treatment of radial-sided TFCC lesions. In: Slutsky D, Nagle D, eds. *Techniques in wrist and hand arthroscopy.* Philadelphia: Churchill Livingstone Elsevier, 2007: 32-41.
245. Weiss KE, Rodner CM. Osteoarthritis of the wrist. *J Hand Surg Am.* 2007, 32: 725-46.
246. Weiss AP, Sachar K, Glowacki KA. Arthroscopic debridement alone for intercarpal ligament tears. *J Hand Surg Am.* 1997, 22: 344-9.
247. Whipple TL. Techniques of wrist arthroscopy. *Arthroscopy.* 1986, 2: 244-52.
248. Whipple TL. The role of arthroscopy in the treatment of scapholunate instability. *Hand Clin.* 1995, 11: 37-40.
249. Whiting PF, Rutjes AW, Westwood ME, et al. QUADAS-2: A revised tool for the quality assessment of diagnostic accuracy studies. *Ann Intern Med.* 2011, 155: 529-36.
250. Winter T, Beck H, Walther A, Zwipp H, Rein S. Influence of a proprioceptive training on functional ankle stability in young speed skaters – a prospective randomised study. *J Sports Sci.* 2015, 33: 831-40.
251. Wright TW, Dobyns JH, Linscheid RL et al. Carpal instability non dissociative. *J Hand Surg Br.* 1994, 19: 763-73.
252. Yoshioka H, Burns JE. Magnetic resonance imaging of triangular fibrocartilage. *J Magn Reson Imaging.* 2012, 35: 764-78.
253. Yao J, Skirven T, Osterman AL, Culp RW. Clinical assessment of the wrist. In: Cooney WP III, ed. *The wrist: Diagnosis and operative treatment.* 2nd ed. Philadelphia: Lippincott Williams & Wilkins, 2010: 119-50.
254. Zahab S, Ahsan BS, Yao J. Complications of wrist arthroscopy. *Arthroscopy.* 2012, 28: 855-9.
255. Zimmermann R, Gschwentner M, Pechlaner S, Gabl M. Remodeling capacity and functional outcome of palmarly versus dorsally displaced pediatric radius fractures in the distal one-third. *Arch Orthop Trauma Surg.* 2004, 124: 42-8.

256. Zlatkin MB, Chao PC, Osterman AL, Schnall MD, Dalinka MK, Kressel HY. Chronic wrist pain: evaluation with high-resolution MR imaging. *Radiology*. 1989, 173: 723-9.

257. Zlatkin MB, Rosner J. MR imaging of ligaments and triangular fibrocartilage complex of the wrist. *Radiol Clin N Am*. 2006, 44: 595-623.

---







# APPENDIX 1

Data extraction sheet  
– Systematic review – Study I

Author			Year		
Study type / Level of evidence (CEBM)			Sample size / Follow-up (%)		
Ligaments	Total/Partial	Wrist coil	Tesla	MRI examiner	
Patients			Time interval between diagn assessments		
Material and methods					
Bias (gender, selection, attrition, confirmation) and limitations			Blinding		
Results  <b>TFCC</b>	MRI / Clinical test	Arthroscopy		Sensitivity	Specificity
		TP	FP	PPV	NPV
		FN	TN		
Results  <b>SL</b>	MRI / Clinical test	Arthroscopy		Sensitivity	Specificity
		TP	FP	PPV	NPV
		FN	TN		
Results  <b>LT</b>	MRI / Clinical test	Arthroscopy		Sensitivity	Specificity
		TP	FP	PPV	NPV
		FN	TN		



# APPENDIX 2

## Electronic search strategies – Study I

### PubMed

April 3, 2014

#### Wrist + MRI, 278 hits

Search	Query	Hits
#19	Search #14 NOT #17 Filters: English	278
#18	Search #14 NOT #17	331
#17	Search #15 OR #16	5132061
#16	Search ((animals[mh]) NOT (animals[mh] AND humans[mh]))	3874066
#15	Search Editorial[ptyp] OR Letter[ptyp] OR Comment[ptyp]	1307281
#14	Search #11 AND #12 AND #13	340
#13	Search magnetic resonance imaging[mesh] OR (magnetic[tiab] AND resonance[tiab] AND imag*[tiab]) OR MRI[tiab] OR (mr[tiab] AND imag*[tiab])	384429
#12	Search tfcc[tiab] OR triangular fibrocartilage complex OR lunotriquetral OR interosseous OR scapholunate OR lt[tiab] OR sl[tiab] OR lti[tiab] OR slii[tiab] OR wrist ligament*[tiab]	22906
#11	Search "Wrist Joint"[Mesh] OR "Wrist"[Mesh] OR wrist[tiab] OR tear[tiab] OR tears[tiab] OR injury[tiab] OR injuries[tiab] OR rupture[tiab] OR ruptures[tiab] OR sprain[tiab] OR sprains[tiab]	615512

#### Wrist + clinical tests, 205 hits

Search	Query	Hits
#17	Search #12 NOT #15 Filters: English	205
#16	Search #12 NOT #15	226
#15	Search #13 OR #14	5132061
#14	Search ((animals[mh]) NOT (animals[mh] AND humans[mh]))	3874066
#13	Search Editorial[ptyp] OR Letter[ptyp] OR Comment[ptyp]	1307281
#12	Search #1 AND #11	229
#11	Search watson's test OR scaphoid shift test OR finger extension test OR shuck test OR lunotriquetral ballotement test OR lt ballotement test OR derby wrist test OR foveal sign OR DRUJ instability test OR clinical test*[tiab] OR clinical wrist test*[tiab]	10404
#1	Search "Wrist Joint"[Mesh] OR "Wrist"[Mesh] OR wrist[tiab] OR carpal instability OR tfcc[tiab] OR triangular fibrocartilage complex OR lunotriquetral OR interosseous OR scapholunate OR lt[tiab] OR sl[tiab] OR lti[tiab] OR slii[tiab] OR wrist ligament*[tiab]	50533

## EMBASE (OvidSP) 1980 to present

April 3, 2014

### Wrist + MRI, 306 hits

Search	Query	Hits
1	(wrist or tear\$1 or injur\$3 or rupture\$1 or sprain\$1).ti,ab.	753524
2	exp wrist/	16308
3	exp wrist injury/	3793
4	1 or 2 or 3	759322
5	exp triangular fibrocartilage/	241
6	(tfcc or triangular fibrocartilage complex or lunotriquetral or interosseous or scapholunate or lt or sl or ltii or slil or wrist ligament\$1).ti,ab.	39559
7	5 or 6	39637
8	exp nuclear magnetic resonance imaging/	519418
9	(magnetic adj3 resonance adj3 imag\$3).ti,ab.	175474
10	MRI.ti,ab.	203761
11	(mr adj3 imag\$3).ti,ab.	54423
12	8 or 9 or 10 or 11	558289
13	4 and 7 and 12	440
14	limit 13 to (english and (article or conference paper or note or "review"))	306

### Wrist + clinical tests, 92 hits

Search	Query	Hits
1	exp wrist/	16308
2	exp wrist injury/	3793
3	exp triangular fibrocartilage/	241
4	(tfcc or triangular fibrocartilage complex or lunotriquetral or interosseous or scapholunate or lt or sl or ltii or slil or wrist ligament\$1 or wrist or carpal instability).ti,ab.	65743
5	1 or 2 or 3 or 4	72139
6	(watson's test or scaphoid shift test or finger extension test or shuck test or lunotriquetral ballottement test or lt ballottement test or derby wrist test or foveal sign or DRUJ instability test or clinical test\$3 or clinical wrist test\$3).ti,ab.	11961
7	5 and 6	137
8	limit 7 to (english and (article or conference paper or note or "review"))	92

## I The Cochrane Library

April 4, 2014

### Wrist + MRI, 66 hits

Cochrane other reviews: 4

Trials: 61

Economic evaluations: 1

Search	Query	Hits
#1	MeSH descriptor: [Wrist] explode all trees	233
#2	MeSH descriptor: [Wrist Joint] explode all trees	187
#3	wrist or tear or tears or injury or injuries or rupture or ruptures or sprain or sprains	31473
#4	#1 or #2 or #3	31473
#5	tfcc or triangular fibrocartilage complex or lunotriquetral or interosseous or scapholunate or lt or sl or ltll or slil or wrist:ti,ab,kw (Word variations have been searched)	3024
#6	#4 and #5	1904
#7	MeSH descriptor: [Magnetic Resonance Imaging] explode all trees	5552
#8	magnetic resonance imag* or MRI or MR:ti,ab,kw (Word variations have been searched)	9465
#9	#7 or #8	9594
#10	#6 and #9	66

### Wrist + clinical tests, 285 hits

Cochrane other reviews: 8

Trials: 277

Search	Query	Hits
#1	MeSH descriptor: [Wrist Joint] explode all trees	187
#2	MeSH descriptor: [Wrist] explode all trees	233
#3	wrist or carpal instability or tfcc or triangular fibrocartilage complex or lunotriquetral or interosseous or scapholunate or lt or sl or ltll or slil:ti,ab,kw (Word variations have been searched)	3026
#4	#1 or #2 or #3	3026
#5	watson's test or scaphoid shift test or finger extension test or shuck test or lunotriquetral ballottement test or lt ballottement test or derby wrist test or foveal sign or DRUJ instability test or clinical test* or clinical wrist test*:ti,ab,kw (Word variations have been searched)	56240
#6	#4 and #5	285





# APPENDIX 3

## Wrist arthroscopy protocol – Study II, III and IV.

Namn, personnummer

NR

Operatör

Operationsdatum

Sida

### Radiocarpalt

Radius-scaphoideumfasett	
Radius-lunatumfasett	
Scaphoideums broskyta	
Lunatum	
Triquetrum	
Caput ulna (vid TFCC perforation)	

RSC	
LRL	
SRL	
Ulnocarpala ligament (UL, UT)	
TFCC	
SL	
LT	

Synovit

### Midcarpalt

SL-led	
LT-led	
Broskyta hamatum (HALT)	
Broskyta capitatum	
Broskyta STT	
Broskyta scaphoideum	
Broskyta lunatum (typ I/II)	
Broskyta triquetrum	

Synovit

ÖVRIGT

Brosk (Outerbridge)
0 – Normalt
1 – Mjukt (svullet, missfärgat)
2 – Fibrillationer
3 – Krackeleringar
4 – Blottat ben

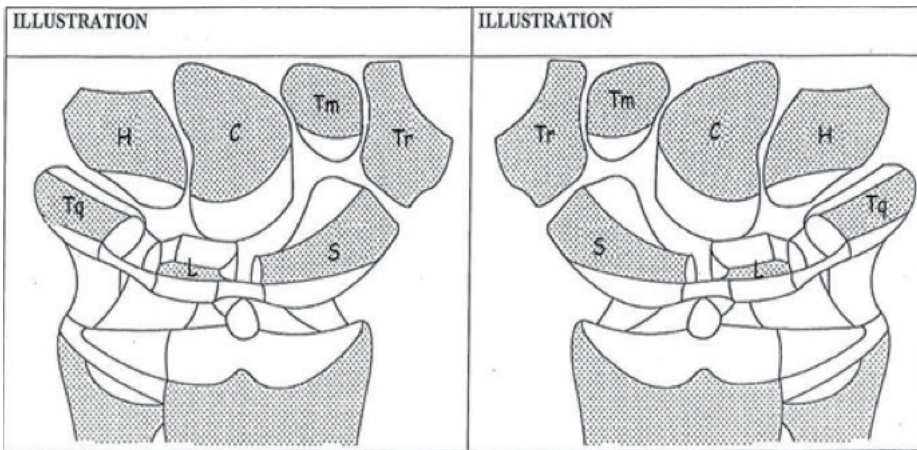
<u>TFCC</u> (Palmers klassifikation)
0 – Normal
1 A – <u>Central</u> perforation (minst 1 mm kvar av menisk fram till sigmoid notch)
1 B – <u>Ulnar</u> avulsion (Hooktest, Trampolineffekt/Vågfenomen)
1 C – <u>Volar</u> , distal avulsion
1 D – <u>Radial</u> avulsion (Dorsala och volara portionen av RU-lig. avlöst från radius)
2 A – Tunn TFCC centralt
2 B – Tunn TFCC centralt + degenerativa broskförändringar på lunatum eller caput ulna
2 C – Central TFCC-perforation + broskförändringar enligt 2 B.
2 D – Som 2 C + LT-skada
2 E – Som 2 D + UC-artros

<u>Intrinsic ligament (SL, LT) (Lindau)</u>		
	Midcarpal diastas	A-skopi step-off
0 – Normal	0	0
1 – Hematom/Distension	0	0
2 – Som 1 o/el partiell ruptur	0-1 mm	< 2 mm
3 – Partiell el total ruptur	1-2 mm	< 2 mm
4 – Total ruptur	> 2 mm	> 2 mm

<u>Extrinsic ligament (RSC, LRL, SRL UL, UT)</u>
0 – Normalt
1 – Skadat

Synovit
0 – Ingen
1 – Förekomst (+ lokalstation)

Jonny Andersson 120102



Markera lokalisation och typ av skada.