

MIKAEL SANSONE

OUTCOMES OF ARTHROSCOPIC HIP SURGERY IN PATIENTS WITH FEMORO- ACETABULAR IMPINGEMENT

Institute of Clinical Sciences
at Sahlgrenska Academy
University of Gothenburg

Cover illustration: **Pontus Andersson**

Outcomes of arthroscopic
hip surgery in patients with
femoro-acetabular impingement

© **Mikael Sansone**, 2016, by **Ineko AB**
mikael.sansone@gmail.com

ISBN: 978-91-628-9704-8 (print)

ISBN: 978-91-628-9705-5 (e-pub)

Printed in Gothenburg, Sweden, 2016, by
Ineko AB

Book layout by **Guðni Ólafsson**

"The test of a first-rate intelligence is the ability to hold two opposed ideas in the mind at the same time, and still retain the ability to function."

**SCOTT F
FITZGERALD**

CONTENTS

ABSTRACT	7
SAMMANFATTNING PÅ SVENSKA	9
LIST OF PAPERS	13
ADDITIONAL PUBLICATIONS	15
ABBREVIATIONS	17
BRIEF DEFINITIONS	19
01 INTRODUCTION	21
1.1 Historical perspective	21
1.2 Anatomy	22
1.3 Aetiology of FAI	30
1.4 Epidemiology	33
1.5 Gender differences in FAI	34
1.6 Osteoarthritis development connected to FAI	34
1.7 Clinical picture	40
1.7.1 Clinical introduction	40
1.7.2 The core issue of FAI	40
1.7.3 Clinical evaluation	41
1.7.4 Hip instability and the ileopsoas	46
1.7.5 Radiographic evaluation	46
1.8 Treatment of FAI	49
1.8.1 Non-surgical treatment	50
1.8.2 Surgical treatment	51
1.8.3 Complications	54
1.9 Surgical treatment of FAI in the setting of hip OA	55
1.10 Evaluation of treatment of FAI	55

<i>1.10.1 Database and registry research</i>	55
<i>1.10.2 FAI registries</i>	56
<i>1.10.3 FAI outcome scores</i>	56
<i>1.10.4 Composite outcomes</i>	58
<i>1.11 Why is this thesis needed?</i>	58
02 AIMS	61
<i>2.1 Overall aims</i>	61
<i>2.2 Specific aims</i>	61
03 SUBJECTS	63
04 METHODS	67
<i>4.1 Development of a registry for hip arthroscopy</i>	67
<i>4.2 Patient Reported Outcome Measures (PROMs)</i>	68
<i>4.3 Clinical evaluation</i>	70
<i>4.4 Radiological evaluation</i>	71
<i>4.5 Surgical technique</i>	72
05 STATISTICAL METHODS	79
06 SUMMARY OF PAPERS	83
07 STRENGTHS AND LIMITATIONS	103
08 DISCUSSION	107
09 CONCLUSIONS	123
10 FUTURE PERSPECTIVES	125
11 ACKNOWLEDGEMENTS	127
12 REFERENCES	131
13 APPENDIX	141
14 PAPERS	157

MIKAEL SANSONE

ABSTRACT

Hip and groin problems are common, especially among athletes. The treatment of hip and groin problems has undergone rapid change during the latest 15 years, mainly due to our understanding of femoro-acetabular impingement (FAI). FAI consists of skeletal changes of the hip, which lead to a mismatch between the femoral head and pelvic socket, leading to collision and impingement. These changes are called cam when placed on the femoral side and pincer on the pelvic side. Technical advances have led to arthroscopic treatment as a standard procedure for treating FAI. The results after this treatment have, however, not been well investigated.

This thesis aims to investigate the results after arthroscopic treatment for FAI. A clinical register was created in order to evaluate and follow this patient category over time.

A long-term follow-up was made of patients who had undergone tenotomy in the groin region. This study showed that three out of four patients experienced good results after surgery. The patients with a poorer outcome had a significantly higher prevalence of FAI.

A database was created with the aim of evaluating patients treated arthroscopically for FAI. In an assessment of the first 606 patients in the database, it was seen that,

when measured with modern and validated outcome measures, these patients reported substantial clinical symptoms.

A one-year follow-up of 85 elite athletes after arthroscopic treatment revealed good results, including less pain, improved function, quality of life and return to sports. A two-year follow-up of 289 patients with FAI treated arthroscopically showed significant improvements in terms of pain, function and quality of life. A two-year follow-up of 75 patients with FAI and concomitant mild to moderate osteoarthritis of the hip showed significant improvements in terms of pain, function and quality of life.

In a case report of two cases of total hip dislocation after hip arthroscopy and psoas tenotomy referred to us, the importance of dynamic and static stabilisers of the hip was highlighted.

A study of different outcomes used to evaluate patients with FAI reported on the use of composite outcomes to better evaluate this patient category.

Keywords: hip joint, hip, hip arthroscopy, femoro-acetabular impingement, register, cam, outcome, PROM, osteoarthritis, athlete

ISBN: 978-91-628-9704-8

MIKAEL SANSONE



SAMMANFATTNING PÅ SVENSKA

Höft- och lumsksbesvär är vanliga i befolkningen, framför allt hos idrottsaktiva. Behandling av höft- och lumsksbesvär har senaste 15 åren genomgått en snabb förändring, som främst beror på utveckling av behandling av Femoroacetabulärt impingement (FAI).

FAI består av skeletala förändringar inuti höftleden, som leder till en dålig passform mellan höftkula och höftskål, vilket skapar kollision och inklämning med smärta som följd. Dessa förändringar kallas cam då de sitter på lärbenshalsen och pincer då de sitter på kanten av höftskålen. Tekniska framsteg har inneburit att artroskopisk behandling av FAI har blivit ett standardgrepp och är numera den vanligaste behandlingen vid FAI. Metoderna för att utvärdera resultaten efter denna behandling och själva resultaten är dock ännu inte tillräckligt utvärderade.

Denna avhandling syftar till att utvärdera resultat efter artroskopisk behandling av

patienter med FAI. För att möjliggöra detta skapades ett kliniskt register.

En långtidsuppföljning som utvärderade en tidigare klassisk metod med senavskärning i lumsken som behandling för lumsksmärta visade att tre av fyra patienter hade gott resultat av operationen. De med sämre resultat hade klart ökad förekomst av höftbesvär och tecken på FAI vid röntgenundersökning.

En databas skapades med syfte att utvärdera patienter som behandlats med artroskopi av höftleden. I en utvärdering av de första 606 patienterna i databasen sågs att dessa hade avsevärda besvär med smärta och funktionsnedsättning, mätta med moderna och validerade utvärderingsinstrument.

En ett-årsuppföljning av 85 elitidrottare visade goda resultat av artroskopisk behandling av patienter med FAI med minskad smärta, högre funktion, högre livskvalité samt hög frekvens av återgång till idrott. En två-årsuppföljning av en grupp med 289 patienter med FAI samt en två-årsuppföljning av 75 patienter med FAI och samtidig lindrig eller måttlig höftartros visade för båda grupperna signifikanta förbättringar avseende smärta,

funktion och livskvalité efter artroskopisk behandling.

I en fallrapport av två patienter opererade på andra orter i Sverige, beskrivs urladdning av höftleden som en ovanlig komplikation till artroskopisk kirurgi. I dessa fall hade samtidig avskärning av psoassenan gjorts och dess roll som stabilisator av höften diskuteras.

Multipla utfallsmått för att utvärdera behandling av patienter med FAI beskrivs och diskuteras som en möjlighet att förbättra forskningen kring detta tillstånd.

Sammanfattningsvis kan artroskopisk behandling förbättra tillståndet för patienter med FAI avseende smärta, funktion och livskvalité. Det är möjligt att med ringa resurser skapa en databas med moderna validerade utfallsmått i syfte att utvärdera behandling av patienter med FAI.

LIST OF PAPERS

This thesis is based on the following studies, referred to in the text by their Roman numerals.

I. Sansone M, Ahldén M, Jónasson P, Swärd L, Thomeé C, Thomeé R, Baranto A, Karlsson J (2013). A Swedish hip arthroscopy registry - demographics and development. *Knee Surg Sports Traumatol Arthrosc* 22 (4):774-780

II. Sansone M, Ahldén M, Jónasson P, Thomeé C, Swärd L, Öhlin A, Baranto A, Karlsson J, Thomeé R (2016). Outcomes after hip arthroscopy for femoroacetabular impingement in 289 patients with minimum 2 years follow up. *Scand Journal of Medicine and Science in Sports* DOI: 10.1111/sms.12641

III. Sansone M, Ahldén M, Jónasson P, Thomeé C, Swärd L, Baranto A, Karlsson J, Thomeé R (2015). Good Results After Hip Arthroscopy for Femoroacetabular Impingement in Top-Level Athletes. *Orthopaedic Journal Sports Medicine* 3 (2):2325967115569691

IV. Sansone M, Ahldén M, Jónasson P, Thomeé C, Swärd L, Baranto A, Collin D, Karlsson J, Thomeé R (2015). Outcome of hip arthroscopy in patients with mild to moderate osteoarthritis - A prospective study. *Journal of Hip Preservation Surgery* DOI: 10.1093/jhps/hnv07

V. Sansone M, Ahldén M, Jónasson P, Thomeé R, Falk A, Swärd L, Karlsson J (2014). Can hip impingement be mistaken for tendon pain in the groin? A long-term follow-up of tenotomy for groin pain in athletes. *Knee Surg Sports Traumatol Arthrosc* 22 (4):786-792

VI. Sansone M, Ahldén M, Jónasson P, Swärd L, Eriksson T, Karlsson J (2013). Total dislocation of the hip joint after arthroscopy and ileopsoas tenotomy. *Knee Surg Sports Traumatol Arthrosc* 21 (2):420-423

VII. Ayeni OR, Sansone M, de Sa D, Simunovic N, Bedi A, Kelly BT, Farrokhyar F, Karlsson J (2016). Femoro-acetabular impingement clinical research: is a composite outcome the answer? *Knee Surg Sports Traumatol Arthrosc* 24 (1):295-301

ADDITIONAL PUBLICATIONS

Additional relevant papers by the author not included in this thesis.

I. Ahldén M, Sansone M, Jónasson P, Swärd L, Karlsson J (2014) Hip arthroscopy, new technique against hip pain. *Läkartidningen* 111 (36):1445-1449

II. Sansone M, Ahldén M, Jónasson P, Karlsson J, Sandberg J, Swärd L (2012) Interventionell höftartroskopi - potentiell nytta kan finnas - men: ännu saknas evidens. *Ortopediskt Magasin* 3: 46-50

III. Jónasson P, Thoreson O, Sansone M, Svensson K, Swärd A, Karlsson J, Baranto A (2015). The morphologic characteristics and range of motion in the hips of athletes and non-athletes. Submitted to *Journal of Hip Preservation Surgery*

IV. Jónasson P, Ekström L, Swärd A, Sansone M, Ahldén M, Karlsson J, Baranto A (2014). Strength of the porcine proximal femoral epiphyseal plate: the effect of different loading directions and the role of the perichondrial fibrocartilaginous complexes and epiphyseal tubercle - an experimental biomechanical study. *Journal of Experimental Orthopaedics*; 1:4.

V. Jónasson P, Baranto A, Karlsson J, Swärd L, Sansone M, Thomeé C, Ahldén M, Thomeé R (2014). A standardised outcome measure of pain, symptoms and physical function in patients with hip and groin disability due to femoroacetabular impingement: cross-cultural adaptation and validation of the international Hip Outcome Tool (iHOT12) in Swedish. *Knee Surg Sports Traumatol Arthrosc* 22(4): 826-834.

VI. Thomeé R, Jónasson P, Thorborg K, Sansone M, Ahldén M, Thomeé C, Karlsson J, Baranto A (2014). Cross-cultural adaptation to Swedish and validation of the Copenhagen Hip and Groin Outcome Score (HAGOS) for pain, symptoms, and physical function in patients with hip and groin disability due to femoro-acetabular impingement. *Knee Surg Sports Traumatol Arthrosc* 22(4): 835-842.

VII. Jónasson P, Ekström L, Hansson H-A, Sansone M, Karlsson J, Swärd L, Baranto A (2015). Cyclical loading causes injury in and around the porcine proximal femoral physeal plate: proposed cause of the development of cam deformity in young athletes. *Journal of Experimental Orthopaedics* 2:6.

ABBREVIATIONS

ADL	<i>Activity of Daily Living</i>	MACI	<i>Matrix-induced Autologous Chondrocyte Implantation</i>
AIIS	<i>Anterior inferior iliac spine</i>	MIC	<i>Minimal Important Change</i>
AMIC	<i>Autologous Matrix-Induced Chondrogenesis</i>	MRI	<i>Magnetic Resonance Imaging</i>
AVN	<i>Avascular Necrosis</i>	OA	<i>Osteoarthritis</i>
AP	<i>Anteroposterior</i>	NSAID	<i>Nonsteroidal Anti-Inflammatory Drug</i>
ASES	<i>Arthritis Self-Efficacy Scale</i>	Pincer	<i>Not an abbreviation, description of an acetabular lesion causing an impinging effect. See also definitions</i>
BOA	<i>Bättre Ombändertagande av patienter med Artros (Improved care of patients with osteoarthritis)</i>	PROM	<i>Patient Reported Outcome Measure</i>
CT	<i>Computed Tomography</i>	QoL	<i>Quality of Life</i>
Cam	<i>Not an abbreviation, but a description of a cam effect or a lesion causing a cam effect. See also definitions</i>	RCT	<i>Randomised Controlled TRIAL</i>
dGEMRIC	<i>delayed Gadolinium Enhanced MRI of Cartilage</i>	ROM	<i>Range of motion</i>
DVT	<i>Deep Vein Thrombosis</i>	SCFE	<i>Slipped Capital Femoral Epiphysis</i>
EQ-5D	<i>Euro QoL-5 Dimensions</i>	SD	<i>Standard Deviation</i>
EQ-VAS	<i>EuroQoL - VAS</i>	SDC	<i>Smallest Detectable Change</i>
FABER	<i>Flexion Abduction External Rotation</i>	THA	<i>Total Hip Arthroplasty</i>
FAI	<i>Femoro-acetabular impingement</i>	VAS	<i>Visual Analogue Scale</i>
HAGOS	<i>Copenhagen Hip and Groin Outcome Score</i>		
HO	<i>Heterotopic Ossification</i>		
HOOS	<i>Hip disability and Osteoarthritis Outcome Score</i>		
HOS	<i>Hip Outcome Score</i>		
HSAS	<i>Hip Sports Activity Score</i>		
IHOT	<i>International Hip Outcome Tool</i>		
mHHS	<i>modified Harris Hip Score</i>		

BRIEF DEFINITIONS

Alpha angle	<i>The angle between a line from the centre of the femoral head through the middle of the femoral neck and a line through a point where the contour of the femoral head-neck junction exceeds the radius of the femoral head. A radiographic measurement describing the extent of a cam lesion.</i>
Cam	<i>Deformity of the femoral neck which, when rotated, can abut against the acetabulum causing a cam effect.</i>
Contre-coup	<i>A contre-coup injury occurs on the side opposite the area that was hit.</i>
Ehler-Danlos syndrome	<i>An inherited connective tissue disorder characterised by unstable, hypermobile joints, loose, "stretchy" skin and fragile tissues</i>
Dunn's view	<i>Radiographic view used for assessment of femoral head sphericity</i>
Dysplasia of the hip	<i>A congenital or developmental deformation or misalignment of the hip joint, where the acetabulum (socket) is too shallow or deformed, sometimes leading to abnormal wear on the cartilage and early OA.</i>
Heterotopic Ossification	<i>Formation of bone at a non-physiological site. In the hip, this can occur postoperatively.</i>
Pincer	<i>General or local acetabular over-coverage causing the acetabular rim to contact (or impact) the femoral head, metaphysis, or neck when the hip flexes or rotates.</i>
Pubalgia	<i>Pain arising around the area of the pubic symphysis. This entity includes several possible causes of pain like adductor tendon pain, pain from the rectus abdominis, symphysisitis or other.</i>
Ileopsoas	<i>The combination of the psoas major muscle and the iliacus muscle at their inferior ends</i>
Impingement test	<i>A clinical examination test to assess the occurrence of FAI. The patient is placed supine and the hip is flexed and internally rotated. The test is considered positive if it reproduces the patient's pain in the groin and hip area.</i>
Item	<i>A single question or statement in a PROM</i>
Osteoarthritis (OA)	<i>A progressive disorder of the joints caused by gradual loss of cartilage and resulting in the development of bony spurs and cysts at the margins of the joints, often causing pain and loss of function.</i>
Physis	<i>The growth plate or epiphyseal plate. The physis is located between the epiphysis and metaphysis in long bones of growing individuals. Most of the growth in length occurs in the physis through enchondral ossification.</i>
Randomised controlled trial	<i>A type of scientific experiment, where the subjects being studied are randomly allocated to one of the different treatments. The RCT is often considered the gold standard for a clinical trial.</i>
Range of movement	<i>The measured movement over a joint in degrees</i>
Tönnis classification	<i>Radiographic grading system for osteoarthritis of the hip</i>
Validity	<i>The degree to which a PROM instrument measures the construct(s) it is intended to measure</i>
Visual analogue scale	<i>A measurement instrument for subjective phenomena that cannot be directly measured. Agreement level with a statement is indicated by a mark on a continuous line between two end-points.</i>

01

MIKAEL SANSONE

01. INTRODUCTION

1.1 HISTORICAL PERSPECTIVE

The art form called arthroscopy, meaning inspecting human joints using optical instruments, began in the early 20th century. The technique was based on the use of other earlier endoscopes such as cystoscopes. The first to describe the use of an arthroscope to see inside a joint were Hans Christian Jacobeus, from Sweden, (1910) and Severin Norden-toft, from Denmark (1912).

Pioneers such as Watanabe and Burman contributed to the development of the arthroscope from an experimental technique to a not only a diagnostic tool, but also one capable of treating a wide range of injuries and disorders. Technical advances, such as the use of external fibre-optics and miniature television cameras in the 1970:ies, were the major technological development that led to the current widespread use of arthroscopy.

In 1932, Burman reported on arthroscopic techniques applied to various joints in the human body [23]. With regard to the hip, he felt that “*visualization of the hip joint is limited to the intracapsular part of the joint. It is manifestly impossible to insert a needle between the head of the femur and the acetabulum*”. With subsequent technical advances, the hip became accessible for arthroscopic inspection.

Until the late 1990s, hip arthroscopy was mainly used as a diagnostic tool and for the removal of loose bodies. With the emergence of the concept of femoro-acetabular impingement (FAI) in the late 1990s, hip arthroscopy developed into a widespread tool.

Historically, there have been several reports describing the phenomenon of FAI or hip impingement. In 1936, Norwegian-born Smith-Petersen described hip impingement and also its treatment with surgical acetabuloplasty [146]. Unfortunately, not until Ganz et al. popularised the concept of FAI in the late 1990s did this knowledge lead to widespread general acceptance in the medical society, thereby enabling treatment strategies to develop.

Ganz et al. developed an open surgical dislocation approach to decompress and treat the bony abnormality in order to relieve symptoms [47]. This approach was shown to be safe and to lead to a significant improvement in symptoms in the treatment of FAI [17,15,107].

After Ganz et al. popularised the concept of FAI, a rapid development in the use of hip arthroscopy took place and led to the performance of the same procedures as with the open technique but with less surgical trauma.

In a systematic review by Matsuda et al., the open, mini-open and arthroscopic approach were compared in terms of surgical efficacy and complications [94]. The authors concluded that the arthroscopic method had surgical outcomes equal to or better than the other methods, with a lower rate of major complications, when performed by experienced surgeons. In Sweden, Professor Einar Eriksson was a pioneer in developing the basics of hip arthroscopy in the 1980s.

1.2 ANATOMY

1.2.1 Normal anatomy of the hip

The hip joint is a synovial, ball-and-socket joint, between the acetabulum of the pelvic bone and the head of the femur. With a deep socket and a strong ligamentous apparatus, the anatomy of the hip suggests that its function is mainly weight-bearing and stability.

The combination of the large head of the femur and the narrow neck enables a wide range of motion in the directions of flexion/extension, abduction/adduction and internal/external rotation. In addition to the acetabular depth, orientation and the shape of the femoral neck, other structures limiting the range of motion are muscles and ligaments.

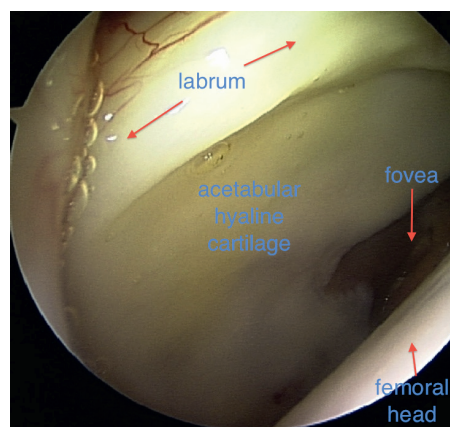


Figure 1. Arthroscopic view of the hip joint with normal cartilage.

The articular part of the acetabular fossa consists of a broad C-shaped hyaline cartilage, with its opening anterior-inferiorly. Along the rim of the acetabulum, a fibro-cartilagenous collar, the acetabular labrum, helps deepen the acetabulum and thereby improve the stability of the joint. In addition, the labrum also functions as a shock absorber, distributing pressure and playing a role in effective fluid joint lubrication. Over the acetab-

ular notch, inferiorly in the acetabulum, the acetabular labrum passes over as the transverse acetabular ligament, making the notch a foramen. The non-articular part of the acetabulum is the acetabular fossa, where the ligamentum teres attaches (Figure 2). During childhood (0-15 years), the ligamentum teres plays an important role in the vascular supply of the femoral head. Thereafter, the ligamentum teres has more of a stabilising function.

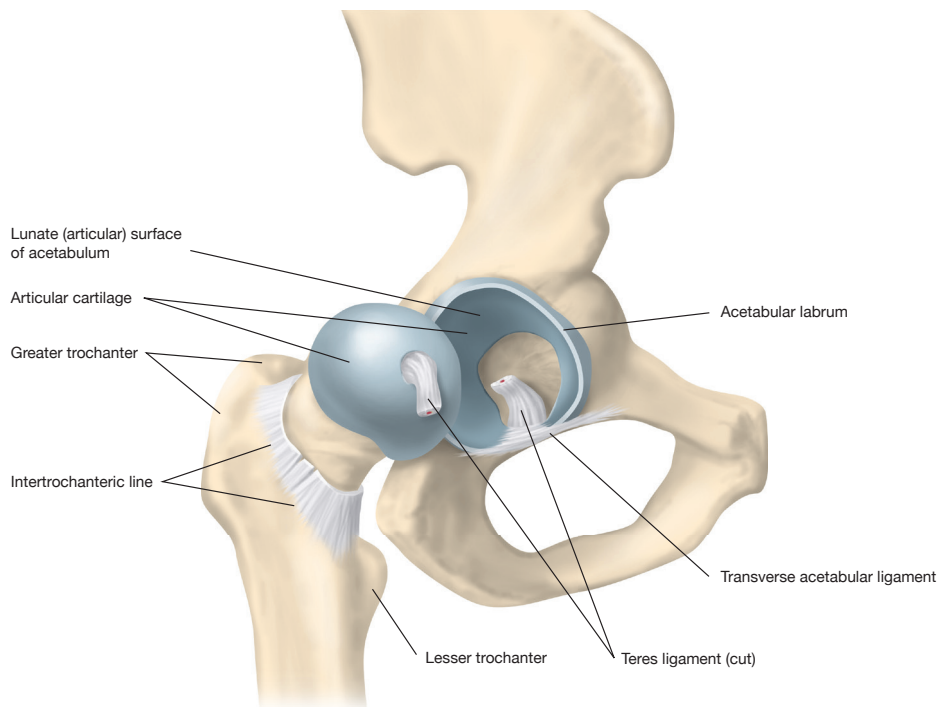


Figure 2. Lateral view of the right hip showing the bony anatomy, the labrum and the teres ligament(cut). The joint capsule has been removed and the femoral head is dislocated posteriorly to show the acetabulum and its anatomy.

Three ligaments encapsulate and stabilise the hip joint. Proximally, these ligaments attach all around the acetabulum. Distally, on the femur, they attach anteriorly on the intertrochanteric line and posteriorly along the femoral neck. The ilio-femoral ligament is located anteriorly to the hip joint, the pubo-femoral ligament is located anterior-inferiorly to the hip joint and the ischio-femoral ligament is located posteriorly to the hip joint (Figure 3 and 4).

The iliopsoas is a muscle which originates on the lower lumbar spine and the inside of the pelvis and inserts on the lesser trochanter below the hip. It functions as a hip flexor and stabiliser of the hip. In the distal part of the muscle-tendon complex, it becomes more ten-

dinous so that, at the level of the joint, 45% is tendinous [9]. The tendon here lies in a groove in the anterior part of the acetabulum and movement in and out of this groove can occur with flexion or external rotation of the joint, causing a snapping sound. This is often referred to as “internal snapping hip” and is usually asymptomatic.

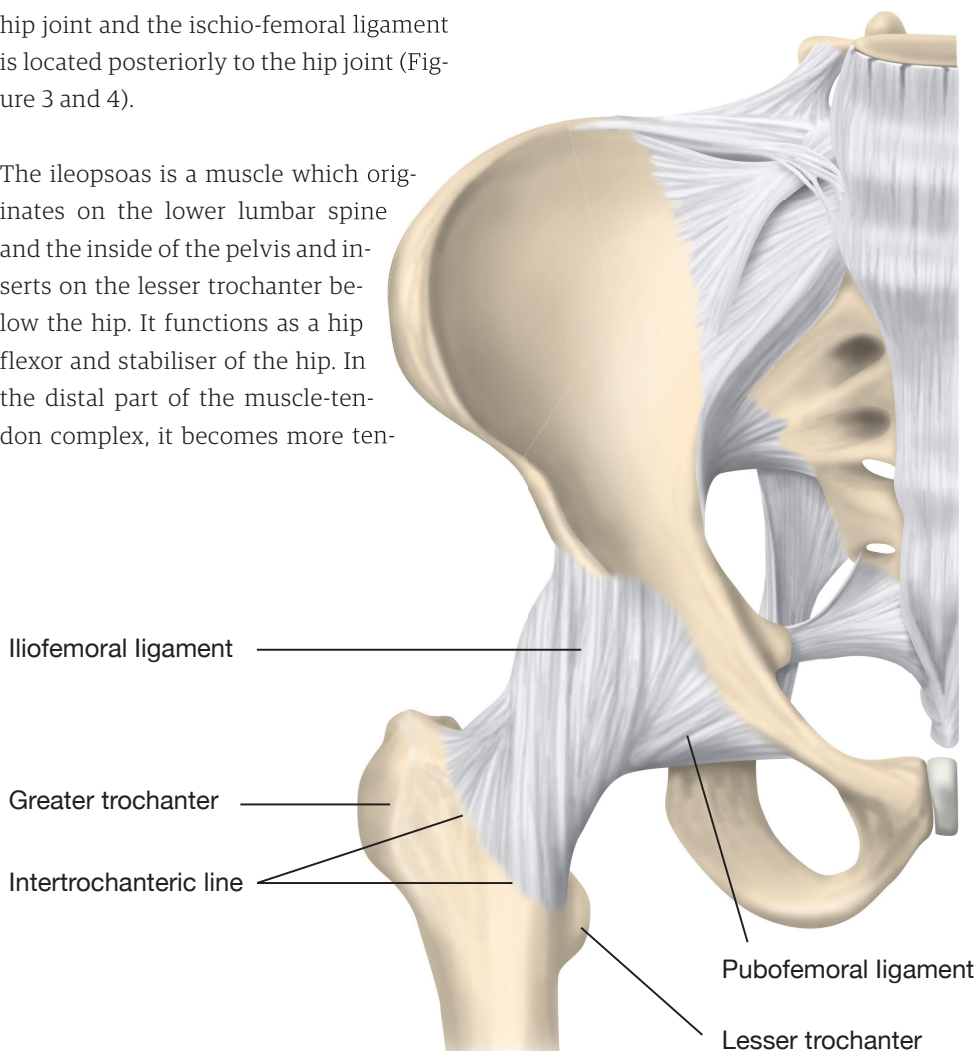


Figure 3. Anterior view of the right hip showing the bony anatomy and the ligaments of the hip joint.

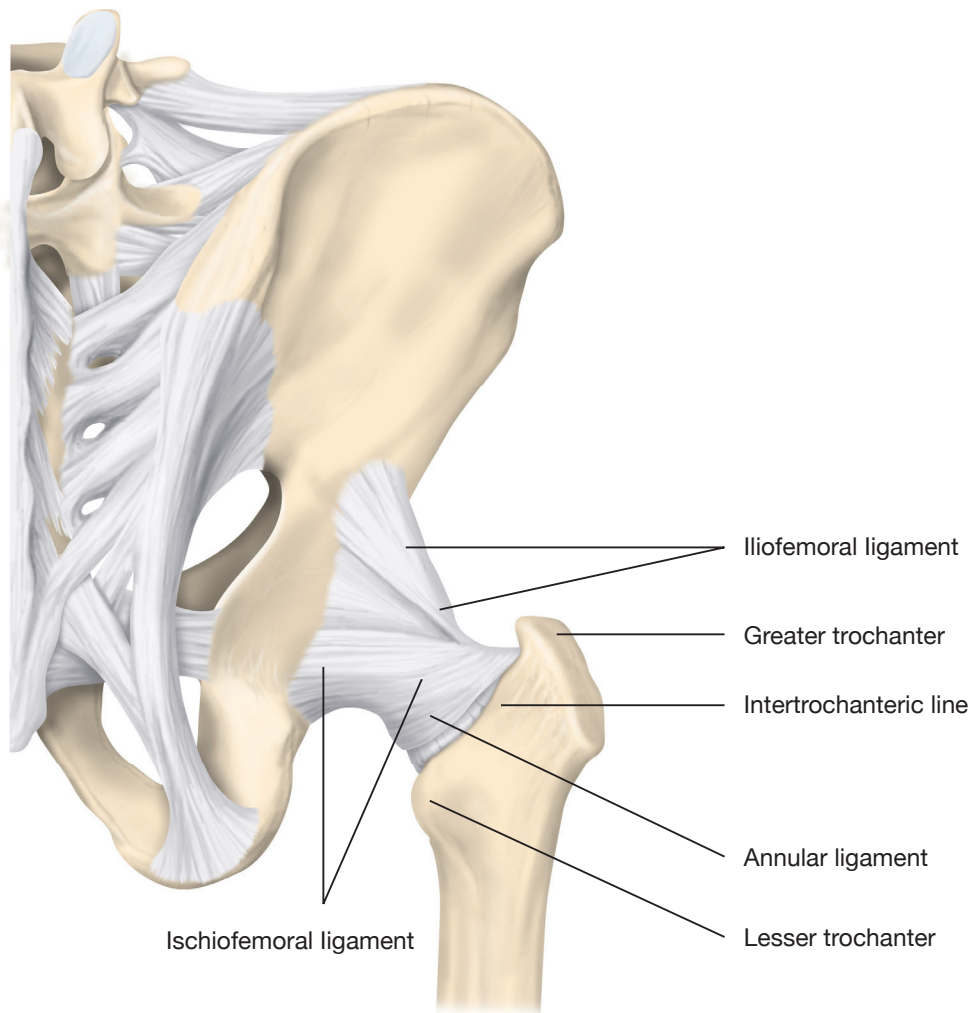
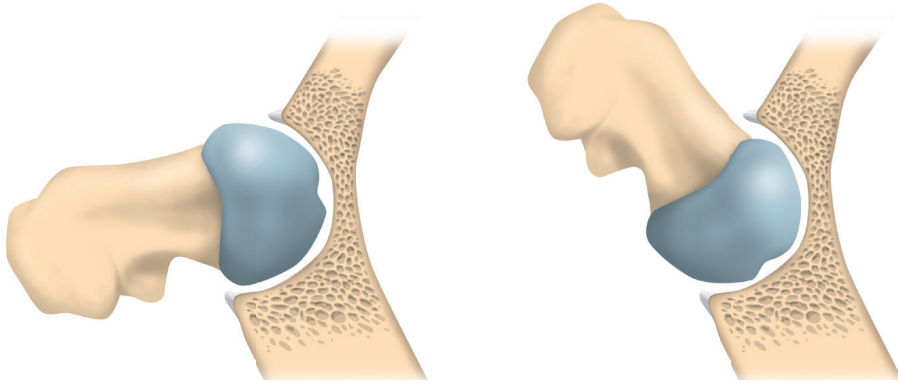


Figure 4. Posterior view of the right hip showing the bony anatomy and the ligaments of the hip joint.

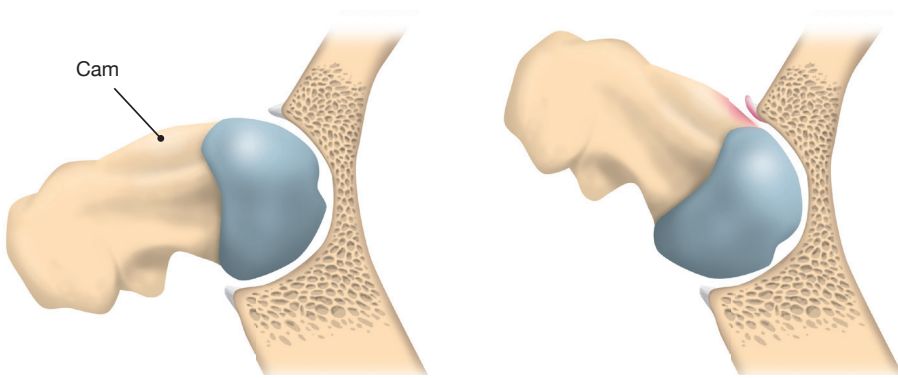
1.2.2 ANATOMY AND BIOMECHANICS OF THE HIP JOINT WITH REGARD TO FAI

In humans, the shape of the femoral neck is sometimes aspherical [50]. This is called cam lesion, as it produces a cam effect when the hip is moved in the outer degree of its range of motion (ROM) and impinges against the acetabulum (Figure 5). This impingement leads to shear forces on the anterior chondrolabral junction, leading to softening of the cartilage, fissuring, cartilage delamination and breakdown. Another source of impingement is when the orientation of the acetabulum has a version, which restricts the normal motion of the femur, resulting in impingement, called pincer deformity. A globally deep acetabulum, such as coxa profunda, can also lead to a pincer impingement (Figure 5).

Normal hip



Cam impingement



Pincer impingement

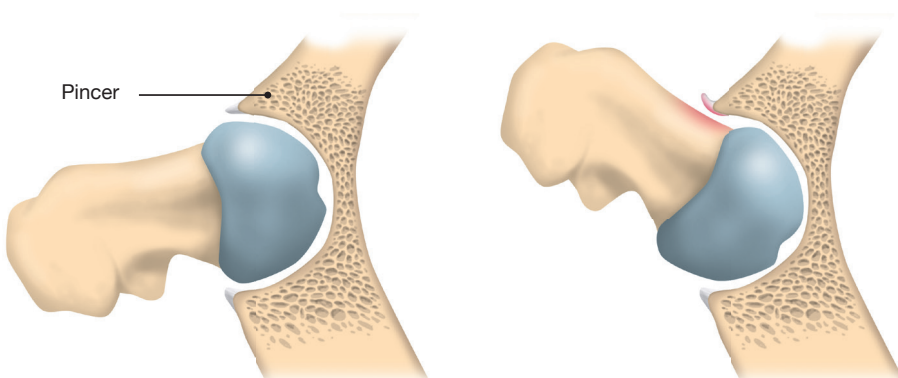


Figure 5. Horizontal view of the hip joint showing different types of femoroacetabular impingement.

The exact cause of pain in patients with FAI is not known. It is reasonable to suppose that cartilage or chondrolabral damage is an important element in pain generation. Cartilage is not innervated, while the labrum is. Shear forces affecting the labrum, such as in cam-type impingement, or crushing forces, such as in pincer-type impingement, could generate pain through the direct stimulus of these free nerve endings. Another theory is that synovitis, perhaps triggered by continuous cartilage wear and breakdown due to impingement, could lead to pain [11]. Moreover, bone is well innervated and a cartilage defect with increased focal loading of the subchondral bone, sometimes with oedema formation, can generate pain.

Other types of FAI have also been described. In subspine impingement, the anterior inferior iliac spine (AIIS) is pathologically prominent, causing impingement in flexion between the AIIS and the femoral neck. Moreover, femoral retroversion can contribute to the development of FAI, as a more retroverted femoral neck allows for less ROM in flexion [15].

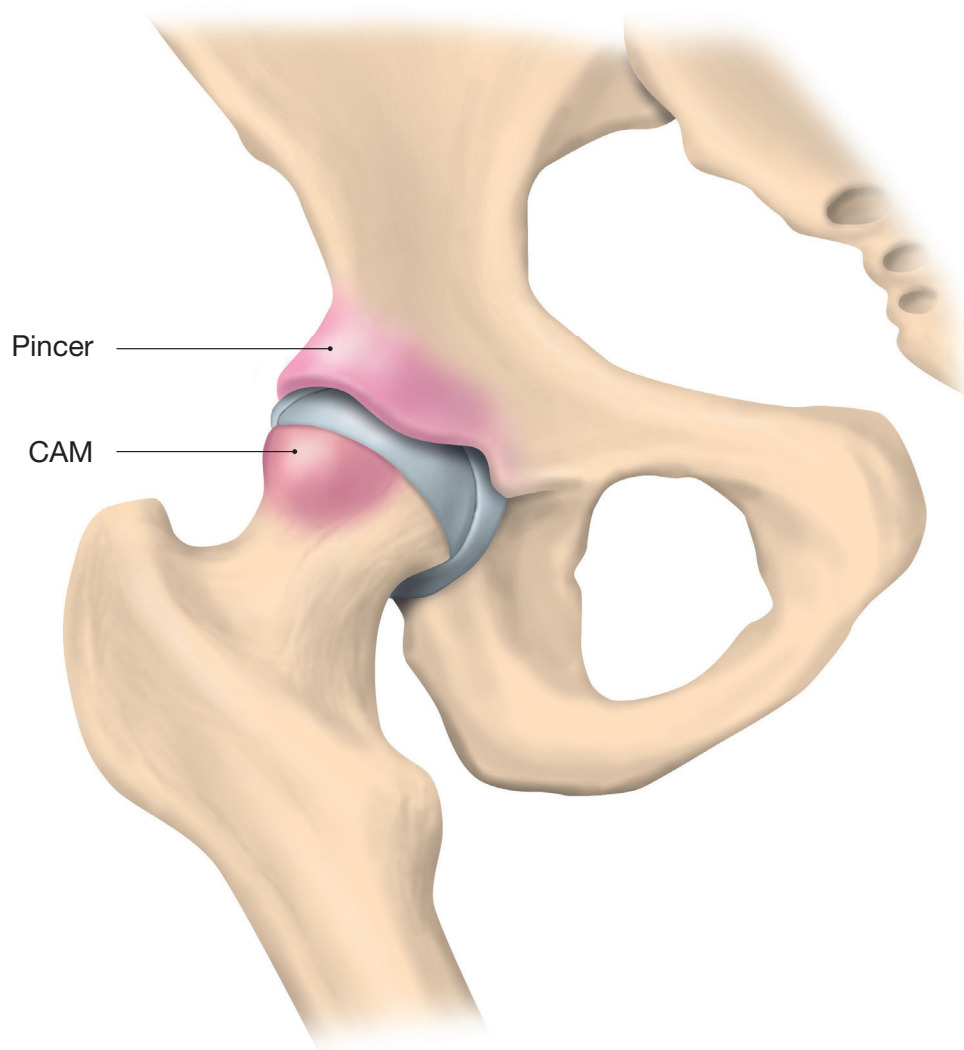


Figure 6. *Cam and pincer deformities highlighted.*

1.3 AETIOLOGY OF FAI

Following the general recognition of the importance of FAI, there has been interest in why these deformities appear. Although Pollard et al. showed in a sibling study that there is a genetic component to the aetiology of FAI, the shape of the human skeleton is not predetermined by birth [120]. Nutrition, hormones, trauma, general health and mechanical factors affect bone formation during the growth process of youth [99].

The effect of pressure on bone growth can be summarised in two laws.

Hueter-Volkman's law proposes that physal growth is retarded by increased pressure and accelerated by decreased pressure. This leads to the physis aligning itself perpendicularly to the force applied and usually at a right angle to the longitudinal axis of the bone.

Wolff's law proposes that the bone in a healthy individual will adapt to the loads under which it is placed. Under increased pressure, the bone becomes stronger and thicker through appositional growth, while decreased pressure leads to weakening of the bone.

Several theories have been proposed to explain FAI morphology. Initially, a sub-clinical slipped capital femoral epiphysis (SCFE) was believed to cause FAI, as the form after SCFE constitutes a cam deformity. Lately, however, the focus has been changed towards the importance of loading the growing skeleton, especially during the growth spurt in early adolescence [3].

Studies have been performed, in which young athletes were followed intermittently with radiographs and compared with a control group with less physical activity [3,141,154]. They conclude that cam morphology appears to a higher degree in athletes during adolescence (12-14 years) due to high-impact sports practice. This could explain why groin and hip pain are more commonly seen among athletes and why a substantial percentage of patients seeking care for long-standing groin and hip pain are athletes.

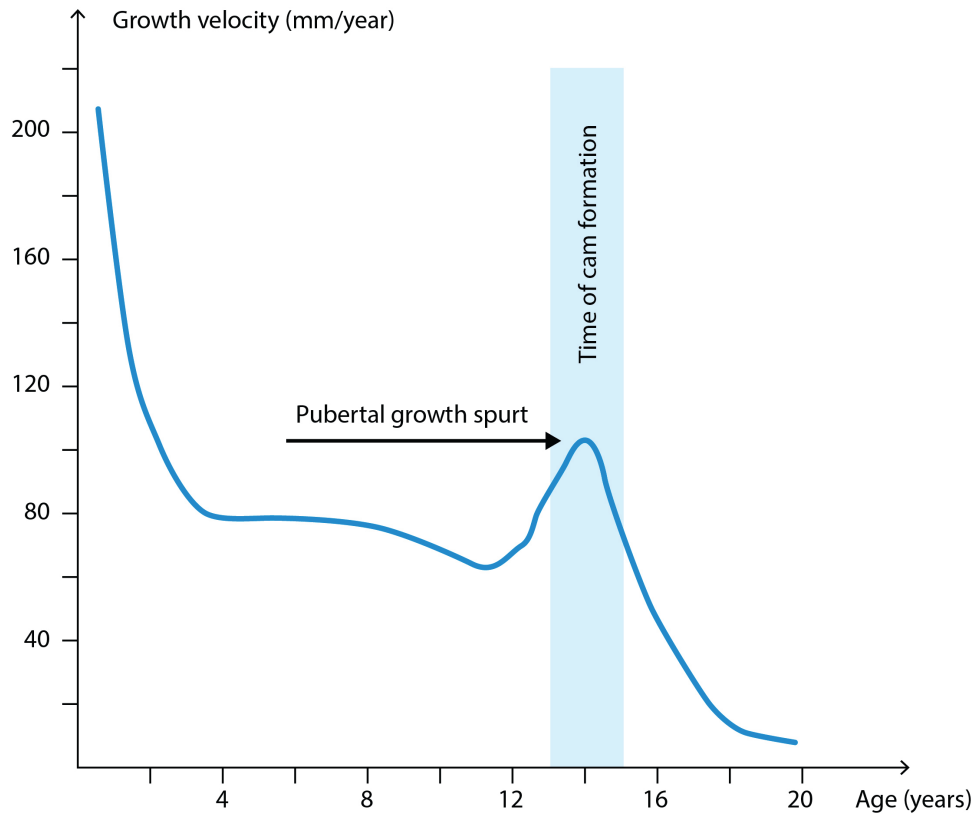


Figure 7. Pubertal growth spurt coincides with formation of cam deformity.

One proposed mechanism is that excessive loading affects the vascular supply to the metaphysis of bones, inhibiting the normal apoptosis of cartilage cells, which in turn creates local hypertrophy of bone as in morbus Osgood-Schlatter or in this case cam deformity [99,83].

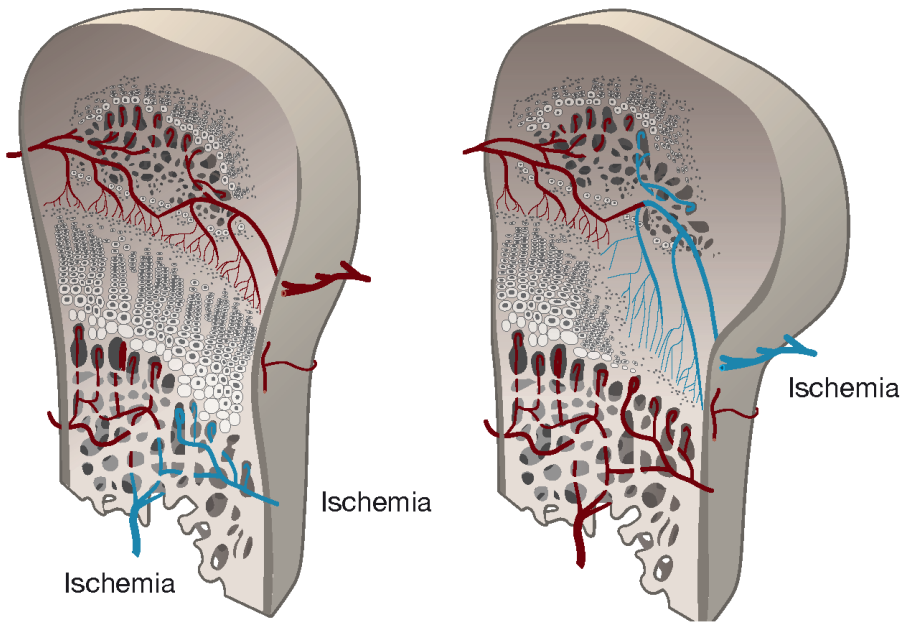


Figure 8. A compromised blood supply on the metaphyseal side causes the continued widening of the physis, but growth cessation and narrowing of the physis occurs if the blood supply is compromised on the epiphyseal side.

Moreover, there are indications suggesting that the incidence of adolescent sports-related injuries is increasing [2,35,143,91]. This may be due to greater demands on young people active in sports to perform and compete at a high level before skeletal maturity is reached. Knowledge of other growth disturbances and chronic physal damage in the upper and lower extremities and the spine of adolescent elite athletes is well established [152,153,88].

Experimental studies by Jónasson et al.

have shown that, in a young porcine hip as a model, repeated loading leads to microscopic injuries to the proximal femoral physal plate [64,67]. These injuries can cause growth disturbances and may cause the growth disturbances seen in adolescent athletes.

The aetiology of pincer deformity, however, is more unclear. Local pincer formation, such as os acetabuli, often seen in athletes, may arise from either acute or chronic traction or impaction injuries to the at-

tachment of the rectus femoris in the area directly above the anterior labrum [31].

1.4 EPIDEMIOLOGY

FAI morphology is common, especially in people with hip pain but also in asymptomatic individuals. A Danish study of 3,620 subjects revealed a prevalence of cam deformity in 20% of men and 5% of women [51]. In a study using MRI on younger asymptomatic subjects, 14% had at least one hip with cam deformity [56]. A study based on computed tomograms of 50 asymptomatic hips concluded that 52% of males and 33% of females had at least one factor predisposing for FAI [69].

The prevalence of symptomatic FAI in society is, however, unknown. In a cross-sectional epidemiological study of 2,368 adolescents in Germany, Spahn et al. found occasional hip pain in 3%, 2.9% suffered from permanent hip pain during physical activity and 0.5% reported permanent pain at rest [148]. Hip pain is more common in older people, where the reported prevalence is around 12-14% for those over 60 years of age [26,28].

In athletes, the prevalence of FAI morphology is even higher. In a study of American elite football players, 72% of men and 50% of women had femoral or acetabular abnormalities associated with FAI. Another study compared young hockey players with young skiers. Seventy-five per cent of the hockey players and 42% of the skiers had an alpha angle of > 55 degrees. The difference was main-

ly due to very high alpha angles among hockey players aged 16-18, which was not seen in the skiers. This implies that load can be a factor in the genesis of FAI morphology.

The highest prevalence of FAI deformity is seen in subjects with hip pain [40]. Many cross-sectional studies have shown an association between cam lesions and hip pain [12,8,112,85]. Siebenrock et al. examined a group of hockey players in which 20% had hip pain and a positive impingement test [142]. They reported that the alpha angle was larger in those with hip pain.

In a magnetic resonance imaging (MRI) study, 170 subjects were followed for more than four years [72]. It reported a relative risk of 4.3 of developing hip pain when a cam deformity was present. Limited internal rotation at the time of initial examination increased the risk of developing pain.

In the original article describing the alpha angle, Nötzli et al. reported that the alpha angle was 74 degrees in patients with groin pain, reduced internal rotation and positive clinical impingement tests, compared with 42 degrees in a control group [112].

In a multicentre study, Clohisy et al. reported on 1,076 consecutive patients undergoing surgical treatment for FAI. The pre-operative clinical scores (pain, function, activity level and overall health) indicated a major dysfunction related to the hip [29].

1.5 GENDER DIFFERENCES IN FAI

Female patients with FAI present with significantly more disability, despite generally having less severe deformities and fewer signs of intra-articular disease [106]. Moreover, female patients with symptomatic FAI demonstrated milder femoral head-neck offset deformities, with only 34% (compared with 72% of males) having a maximum alpha angle of > 60 degrees. In addition, internal rotation in flexion was greater in females, with only 12% (compared with 66% of males) showing < 10 degrees. These data indicate that the diagnostic criteria for males and females are different. Pincer deformity and coxa profunda are more common in women [106].

Regarding the outcomes after arthroscopic treatment for FAI, no clear differences in terms of patient-reported outcomes have been reported [68].

1.6 OSTEOARTHRITIS DEVELOPMENT CONNECTED TO FAI

The aetiology of osteoarthritis (OA) is mainly unclear, although both systemic factors and local biomechanical factors are known to play a role [45].

In a study investigating patients undergoing total hip arthroplasty (THA) for OA, it was found that cam-type morphology occurred more frequently in younger patients with advanced arthritis requiring hip arthroplasty [80].

FAI leads to cartilage damage in the hip joint [127,16,155,89,5,156,49,75]. Chondral damage is mainly located on the acetabular side. Damage to the femoral head is usually only seen in the advanced stages of OA. Many researchers have shown that the pattern of chondral damage is dependent on the type of impingement [16,48,127,155]. Cam deformity is most often located in the anterior part of the femoral neck. When the cam deformity in cam-type FAI or the femoral neck in pincer-type FAI abuts against the anterior part of the acetabulum, repetitive shear forces develop and damage the anterior or lateral part of the acetabular cartilage (Figure 9). Patients with symptomatic hips have a high degree of cartilage and chondrolabral damage [40]. In pincer-type impingement, the impaction of the femoral neck can cause a contre-coup injury to the posterior cartilage of the acetabulum, due to leverage of the femoral head.

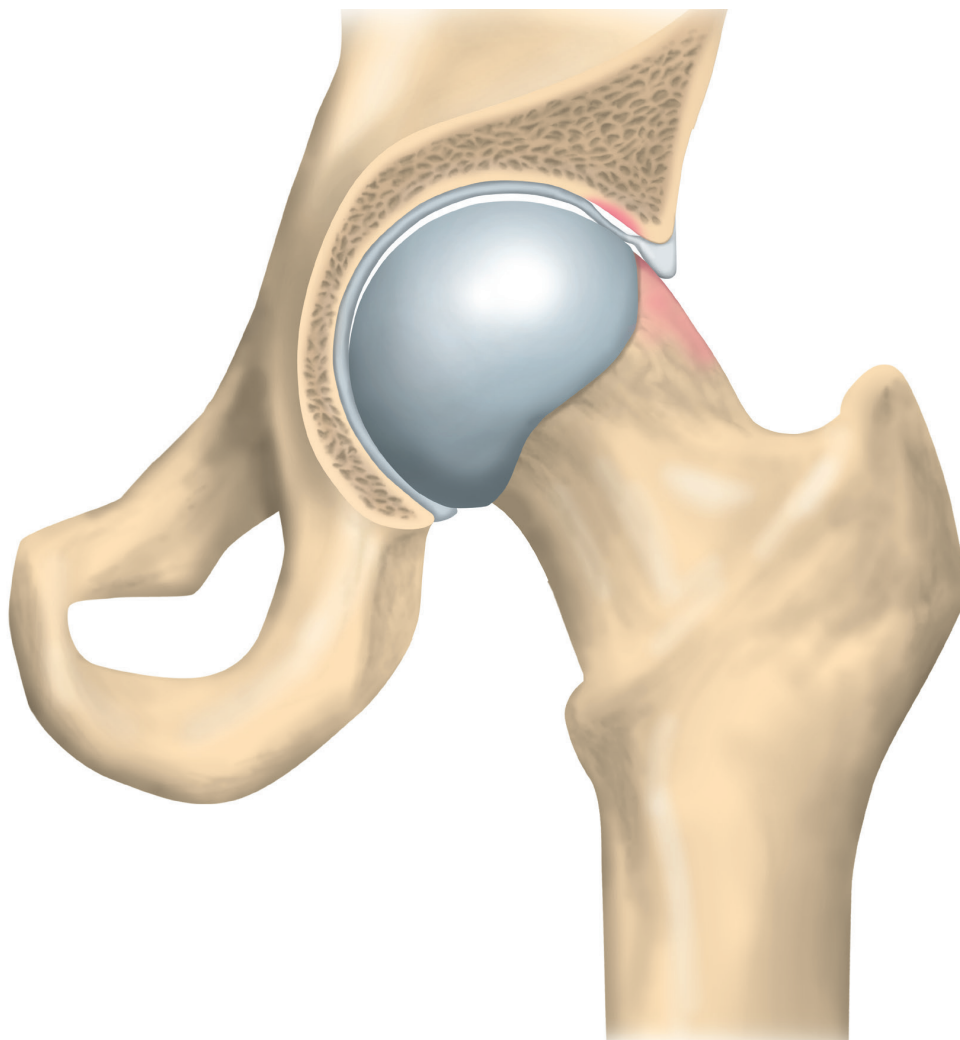


Figure 9. *Cartilage damage due to cam impingement. In this case a wave phenomenon of the cartilage is created due to horizontal shear forces from the cam deformity.*

Cartilage damage is a risk factor for the development of OA [22]. In the knee, Spahn et al. found that the occurrence and extent of tibial cartilage damage was the most important risk factor for OA progression [147]. In another study of young athletes, Messner et al. found a high frequency of OA in the same compartment as initial cartilage damage at the long-term follow-up [97].

Cam deformity is an important risk factor for OA [134,161,5,38]. A longitudinal study of 1,003 subjects showed that cam-type FAI and mild acetabular dysplasia are predictive of subsequent OA and THA [161].

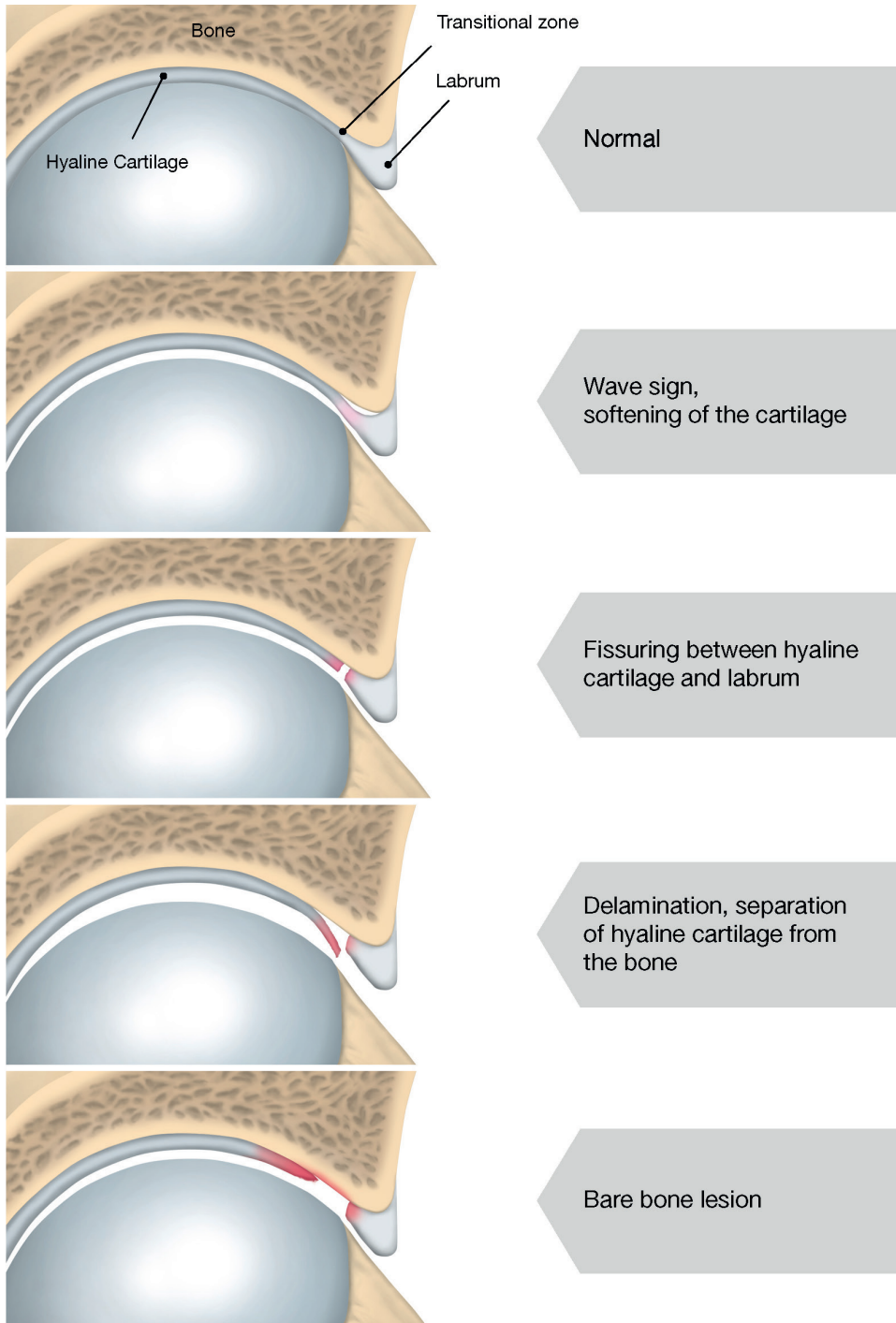


Figure 10. Various and progressing stages of cam-related chondral damage of the acetabulum.

An abnormal shape of the acetabulum may also lead to OA, such as acetabular undercoverage (dysplasia) or acetabular overcoverage, known as pincer. Acetabular overcoverage can be global, as in coxa profunda, or local, as in acetabular retroversion [149].

In terms of pincer deformity, Agricola et al. showed that acetabular dysplasia was significantly associated with OA in a study of 1,002 subjects with symptoms of early OA. However, no increased risk of OA was seen for pincer-type deformity [6]. On the other hand, pincer deformity like acetabular retroversion is difficult to define on plain radiographs [176]. Three-dimensional computed tomography (CT) better estimates the acetabular morphology, but it is difficult to use in routine health care due to the high radiation dose.

A recent systematic review by Kowalczyk et al. concludes that certain morphological features of cam-type FAI, particularly an elevated alpha angle, do appear to predispose selected patients to the radiographic progression of hip OA [78]. In comparison with pincer-type impingement, the association between cam-type impingement and hip OA is better understood [78].

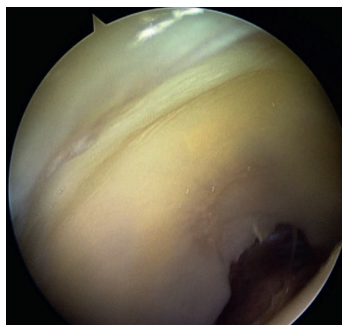


Figure11. *Intraarticular arthroscopic view. A wave sign is seen in the peripheral cartilage. This would be classified as a chondral damage grade 1 A according to Konan et al.*

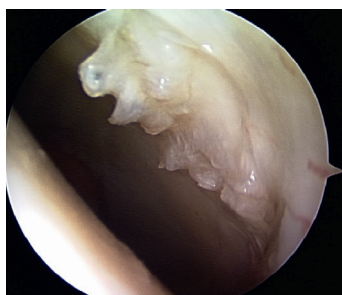

Figure12. *Intraarticular arthroscopic view. Delamination and crushing of the peripheral cartilage is seen. This would be classified as a chondral damage grade 3 A according to Konan et al.*

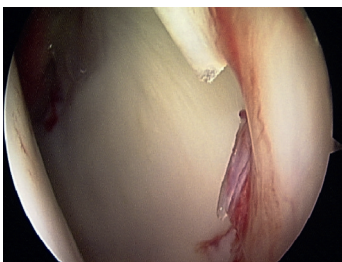


Figure13. *Intraarticular arthroscopic view. Delamination is seen of the peripheral cartilage. This would be classified as a chondral damage grade 3 A according to Konan et al.*

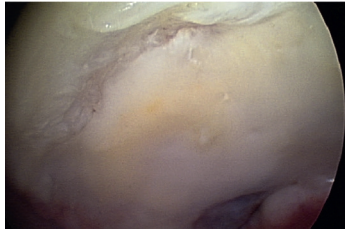


Figure 14. Intraarticular arthroscopic view. Destruction and thinning of the peripheral cartilage is seen. This would be classified as a chondral damage grade 3 A according to Konan et al, however, the cartilage damage has the appearance of more of a chronic degenerative condition such as OA.

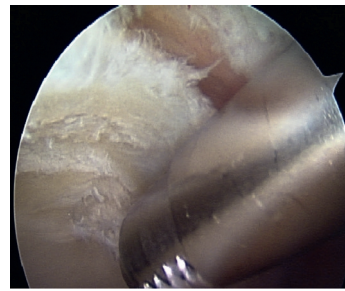


Figure 17. Intraarticular arthroscopic view. Bare bone is seen at the periphery of the joint and cartilage central to that consists of a large delaminated flap in this young patient. This would be classified as a chondral damage grade 4 A according to Konan et al.

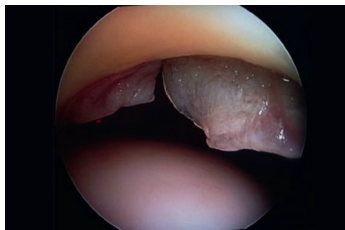


Figure 15. Intraarticular arthroscopic view. Large flaps of hyaline cartilage are seen hanging down inside the labrum. This would be classified as a chondral damage grade 3 A according to Konan et al.

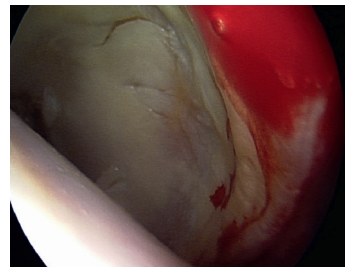


Figure 18. Intraarticular arthroscopic view. Thinning and fragmentation is seen of the peripheral cartilage. This could be seen as that the FAI cartilage damage has progressed to osteoarthritis. This would be classified as a chondral damage grade 4 A according to Konan et al. However, this may represent a mix between cartilage damage and OA, which is difficult to classify as there are no validated arthroscopic classifications for OA.

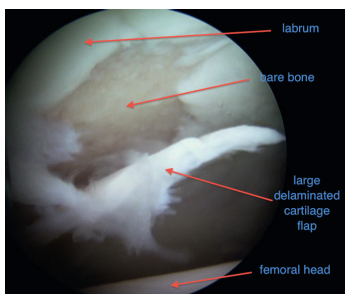


Figure 16. Intraarticular arthroscopic view. The patient is a 23 year old football payer. A large delaminated hyaline cartilage flap is seen due to cam impingement. This would be classified as a chondral damage grade 4 B according to Konan et al.

1.7 CLINICAL PICTURE

1.7.1 CLINICAL INTRODUCTION

Femoro-acetabular Impingement (FAI) of the hip can lead to cartilage damage and symptoms of stiffness, pain and discomfort around the hip and groin. This is accentuated in patients with abnormal use of the joint, such as sports including repetitive flexion or large skeletal abnormalities. The prevalence of these abnormalities has been reported to be as high as 17-35% and numerous studies have shown a relationship between FAI-specific radiological parameters and the development of OA of the hip [87,110,74,69,50,51].

OA of the hip is a major cause of pain, reduced function and reduced quality of life in society [1,86,54]. Moreover, it is a cause of a massive economic burden on society due to health-care costs and reduced work capacity [129,108]. Some studies estimate that hip OA can be secondary to joint malformations in a large percentage of patients [161,80].

According to Clohisy et al., 73% of the patients experienced the pain as sharp, 73% as itchy and 25% as burning. In 46% of the patients, the pain is constantly experienced, while in 42% of the patients the pain is experienced as intermittent. Sixty-five per cent of patients experience a mechanical symptom, which is a "pop" sensation in 65% and a "snap" in 46% [30]. Provocative activities are running 69%, sitting 65%, walking 58% and standing in 44% of the patients. According to Kuhl-

man et al., patients experience problems getting up from a chair, sitting for a long time, getting in and out of a car and leaning forward [79].

1.7.2 THE CORE ISSUE OF FAI

There are several problems when it comes to FAI. First, there is evidence that FAI leads to OA of the hip, especially in young individuals. In a thesis from Lund University in 2013, it is stated that football players run a double risk and hockey players a triple risk of developing hip OA [169]. FAI could be one important factor behind this development.

Second and perhaps more importantly, FAI leads to pain, stiffness, discomfort and reduced physical ability. This may be moderate in some persons, but it leads to severe symptoms, disability and reduced quality of life for some individuals. For athletes, FAI often leads to an inability to perform sports activity and can end their sporting career. In Study I, it was shown that, when measured using valid patient-reported outcome measures (PROMs), patients undergoing hip arthroscopy, mainly for FAI, report severe symptoms preoperatively, including pain, reduced physical capacity and poor quality of life.

Although FAI is common in patients active in sports, people with a more sedentary lifestyle can also suffer from symptoms caused by FAI. Even in patients with low physical demands, common FAI-related symptoms such as pain when sitting can be troublesome.

1.7.3 CLINICAL EVALUATION

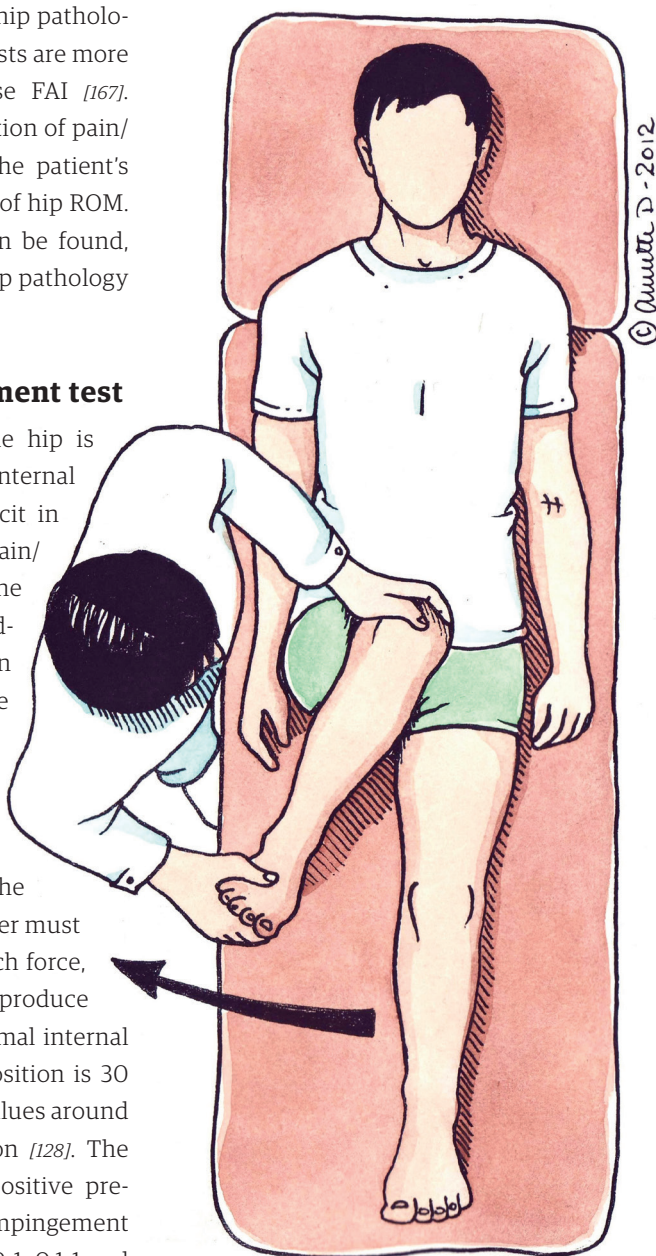
The position and innervation of the hip joint makes the examination and interpretation of the clinical findings difficult. Referred pain is common and patients report a variety of symptoms. The most common symptoms of FAI are pain or discomfort and restricted ROM. Common locations of pain are the groin, the lateral aspect of the hip, posteriorly and occasionally in the knee. Patients can experience symptoms in specific situations such as sitting, flexion and internal rotation like a karate kick or any end-of-range hip motion. Moreover, unspecific pain can be experienced during or after physical activity.

Sometimes, FAI is coupled with extra-articular pain, such as symphysisitis, adductor-related pain or trochanteritis. Theoretically, a restriction of ROM may place increased stress on surrounding structures such as the pubic symphysis, the lower back and stabilising muscles around the pelvis. In a CT model, FAI morphology gave rise to increased rotational forces in the pubic symphysis when the hip was flexed. This could be a cause of symphysisitis seen in sports with repetitive flexion such as football or ice-hockey [171]. Through the same mechanism, reduced hip ROM has been suggested as an aetiological factor in the occurrence of adductor strain in athletes [61]. Feeley et al. described the “sports hip triad” (consisting of labral tear, adductor strain and rectus strain) [44]. These connections are discussed in Study V.

Many tests are described for hip pathology, but two specific clinical tests are more commonly used to diagnose FAI [167]. They are based on the elicitation of pain/discomfort that resembles the patient's problems in the outer extent of hip ROM. Different clinical pictures can be found, depending on the patient's hip pathology [7].

The anterior impingement test

With the patient supine, the hip is flexed to 90 degrees and internal rotation is then added. Deficit in internal rotation, as well as pain/discomfort that resembles the patient's problems, is regarded as positive, indicating an impingement between the anterior part of the femoral neck against the anterior part of the acetabulum. It is always mandatory to compare the ROM with that in the contralateral hip. The examiner must be careful not to use too much force, as rotation of the pelvis can produce a falsely high value. The normal internal rotation of the hip in this position is 30 degrees, but cases with FAI values around -5 to 10 degrees are common [128]. The sensitivity, specificity and positive predictive value of the anterior impingement test have a wide range of 0.59-1, 0.1-1 and 0.53-1 respectively, depending on the cited study [167].



© Annette D - 2012

Figure 19. The anterior impingement test. The hip is flexed to 90 degrees and internally rotated. The reproduction of patient symptoms means the test is positive. The angle between the longitudinal body axis and the final internal rotation can be registered as an indication of range of motion. In this maneuver, care must be taken to avoid pelvic rotation, which gives falsely high internal rotation.

The FABER (Flexion-Abduction-External Rotation) test

With the patient supine, the ipsilateral foot is placed on the contralateral knee in a “figure-of-four” position. The distance between the knee and the examining table mirrors the ROM of the hip in FABER. It is always mandatory to compare with the contralateral hip.

A deficit in ROM coupled with pain/discomfort that resembles the patient’s problems is regarded as a positive test, indicating an impingement of the lateral part of the femoral neck against the lateral/posterior part of the acetabulum. The sensitivity, specificity and positive predictive value of the FABER test have a wide range of 0.41-0.97, 0.18-1 and 0.18-1 respectively, depending on the cited study [167].

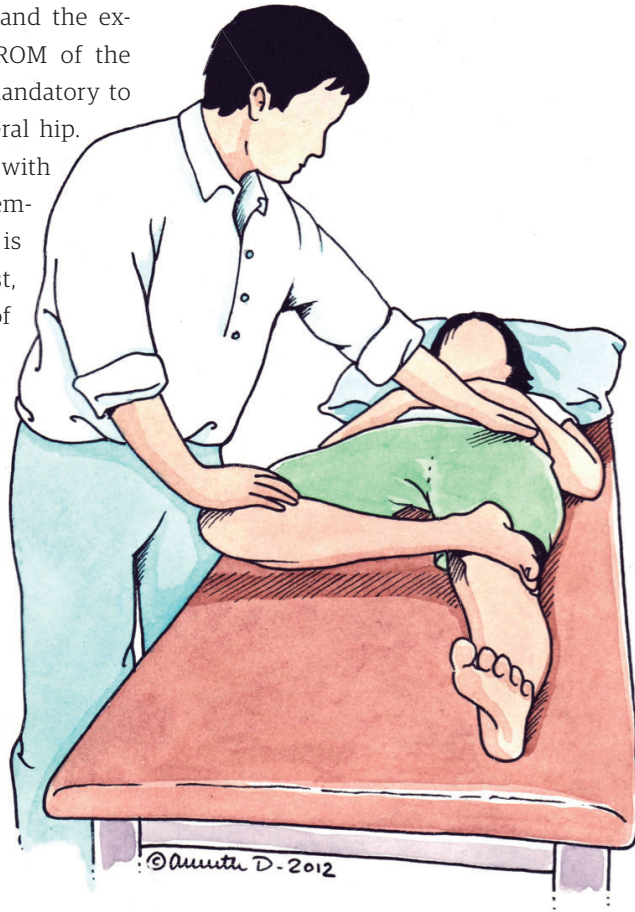


Figure 20. The FABER test is performed with the patient supine. The lateral malleolus of the examined hip is placed superiorly to the patella of the contralateral knee. The hip is abducted with one hand, while the pelvis is stabilised with the other hand. The reproduction of symptoms means the test is positive. The angle or distance between the table and lower leg/knee can be registered as an indication of range of motion.

The “typical” FAI patient

The typical patient is predominantly male, young and active in sports. In Sweden, sports like ice-hockey, especially among goalkeepers, and football players are more commonly associated with FAI [131]. Symptom onset was gradual without traumatic events and has often persisted for months to years before the problem has become troubling enough to seek aid. The main symptoms are pain and stiffness. Pain is most often located in the groin, but lateral and posterior symptoms can also be seen. The pain is worsened by physical activity such as normal practice and game play, and, when patients seek help, they are often unable to participate in their sport any more. Sometimes, pain arises after physical activity, for example, when they sit down for a minute in the locker room, the hip joint freezes up and they experience great pain and stiffness when taking the first few steps.

Hip joint stiffness is also perceived as an increasing problem, although they often mention that they have “always” had stiff hips.

Clinically, reduced ROM, especially in internal rotation and the FABER test, is found. A hip anterior impingement test and the FABER test reproduce the patient's symptoms. Pain cannot be elicited by palpation. However, concomitant symphysis or adductor-related pain often exists [136].

Another typical sign of FAI is the “sitting sign”. Patients often complain of pain and discomfort after a certain time in a sitting position with the hip flexed.

Usually, extending the hip by leaning backwards eases symptoms. This finding can be compared with the “movie sign” often reported in patients with patellofemoral pain syndrome.

If the patients cease their sporting activity, the symptoms may decrease or disappear, but they will often return if they resume their sports. However, many patients experience a progression of symptoms affecting their activities of daily living as well. Some patients experience pain at rest or during the night.

Even though this is a typical patient, FAI can present itself in other ways. Referred pain is common in the hip and groin area. Other entities that are similarly difficult to diagnose can co-exist with FAI, making diagnostics difficult. Examples include back pain, adductor-related pain, pubalgia or abdominally related pain and trochanteric pain. Furthermore, the diagnostics are even more challenging when there is concomitant OA, whose symptoms may be similar to those of FAI.

It is also important to stress that, although FAI is common in athletes, non-athletes can also suffer from symptoms due to FAI.



Figure 21. Hockey goalie, standing with hip flexed and internally rotated. This is a critical position for a hip with FAI morphology. Photograph from S. Yume.

1.7.4 HIP INSTABILITY AND THE ILEOPOAS

Its bony anatomy, muscle envelope, load, suction-seal effect of the labrum and thick ligamentous apparatus make the hip a highly stable joint. However, in recent years, hip instability as a potential problem has been discussed [139,145].

Unfortunately, very little is known about hip instability and there is no established way to either establish the diagnosis or treat symptomatic hip instability.

The ileopsoas tendon has many potential functions. It is a hip flexor, mostly at higher flexion angles, and also a hip adductor [175]. In extension or near extension, it is pressed against the anterior part of the femoral head, a construction similar to the biceps tendon in the shoulder, which also plays a dynamic stabilising role [41].

Multiple risk factors have been suggested as predisposing to post-operative instability of the hip joint [135,139,145] (see Table 1). It therefore appears reasonable to exercise caution when altering these parameters, especially when one or more are present in the actual case.

Table 1. Potential risk factors for post-operative joint instability

<i>Dysplasia</i>
<i>Excessive acetabular rim trimming</i>
<i>Joint hyperlaxity (Ehler-Danlos syndrome)</i>
<i>Muscular deficiency</i>
<i>Excessive capsulotomy</i>
<i>Long distraction time, resulting in ligament elongation</i>
<i>Ileopsoas tenotomy</i>
<i>Ligamentum teres resection</i>

1.7.5 RADIOGRAPHIC EVALUATION

Clinical findings should correlate to radiological findings. Radiological findings indicating FAI are based on a mismatch between the femoral head and the acetabulum, creating possibilities for impingement.

Cam is defined by an alpha angle over 50-55 degrees [112,56,104,121]. However, it is theoretically possible for FAI to exist even in the presence of smaller alpha angles in individuals where the hip is repeatedly moved to the extreme of motion, such as ballet or martial arts [27,76]. As a result, cam-type FAI cannot only be defined by radiological measurements, which is a challenge in FAI research.

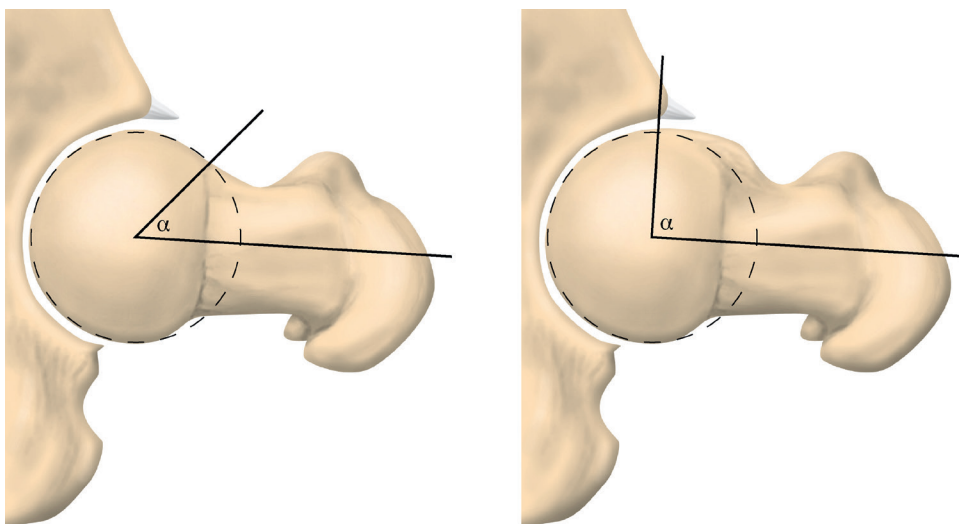


Figure 22. The alpha angle quantifies the cam deformity. It is the angle between two lines drawn from the centre of the femoral head. One line is drawn along the centre of the femoral neck and the other to the point where the bone breaks through a best-fit circle around the femoral head.

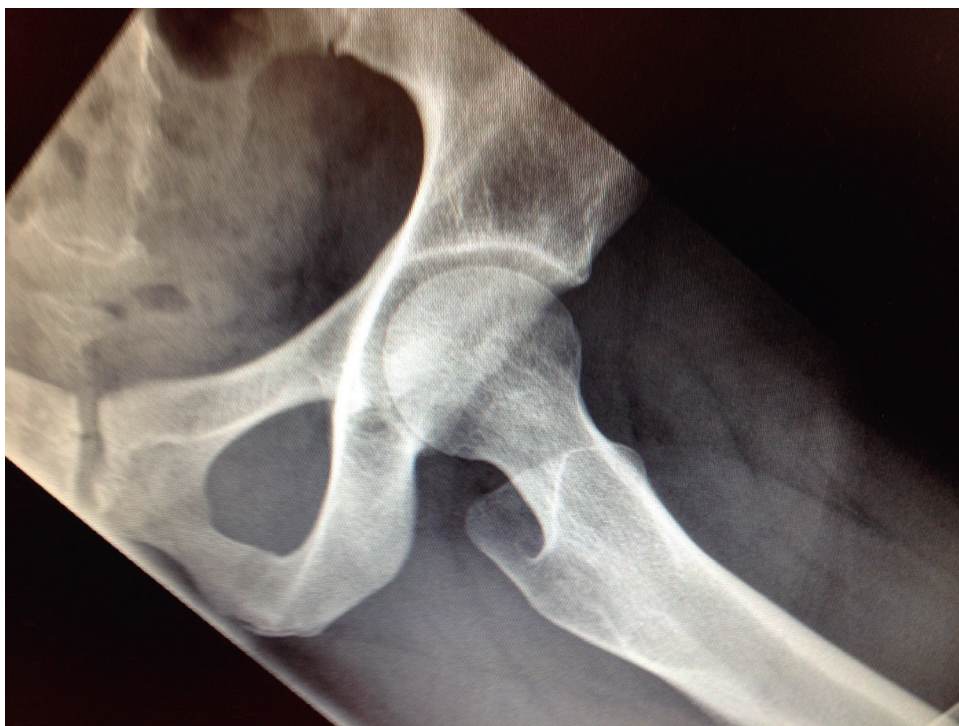

Figure 23. Normal hip. Low alpha angle.

Pincer is general or local acetabular over-coverage of the acetabulum causing the acetabular rim to contact (or impact on) the femoral head, metaphysis, or neck when the hip flexes. Several plain radiographic findings are thought to indicate pincer deformity. They include the cross-over sign (focal acetabular retroversion), coxa profunda, protrusion acetabuli, lateral centre edge angle of > 39 degrees, posterior wall sign, pit formation in the femoral head or neck and ischial spine sign. However, the imaging of the orientation of the acetabulum is complex

and dependent on the rotation of the pelvis during imaging. CT can provide additional information on the acetabulum, but it transmits high doses of radiation to the patient and care must therefore be taken. In a study by Zaltz et al. of patients with symptomatic FAI, it was shown that plain radiographs may overestimate the presence of pincer findings, since the acetabular anatomy is complex [176].

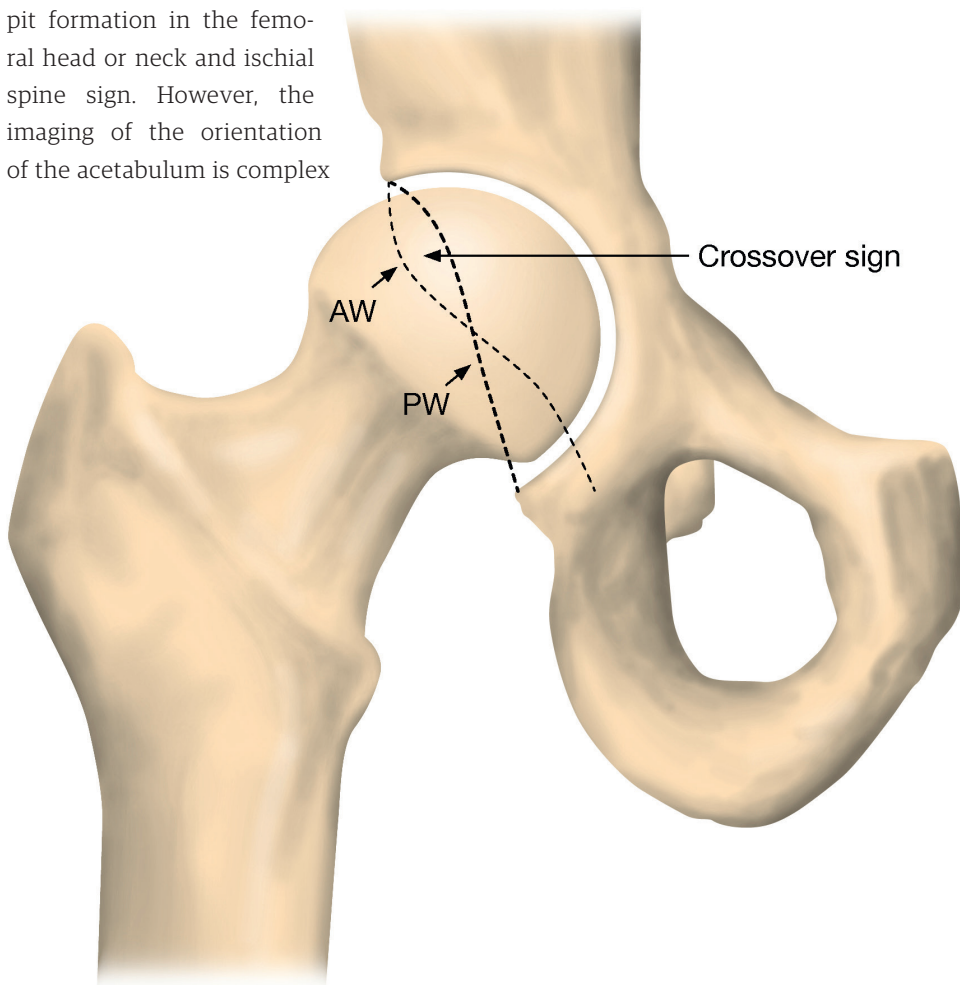


Figure 24. An AP image of a right hip. AW is the anterior wall of the acetabulum and PW is the posterior wall. If the anterior wall is overprojected over the posterior on a truly neutral AP pelvic radiograph, it is regarded as a positive crossover sign, indicative of a retroverted acetabulum.

CT makes use of computer-processed combinations of many radiographic images taken from different angles to produce cross-sectional (tomographic) images (virtual slices) of specific areas of a scanned object. Although associated with greater exposure to radiation for the patient, three-dimensional (3D) information about hip geometry can be obtained.

MRI can be useful in cases of hip pain. MRI has unique potential to detect soft-tissue pathology as well as pathology not seen on plain radiographs such as bone oedema and cyst formation. Using MRI, 3D information can be obtained but with low image resolution compared with CT.

In terms of OA, current radiological techniques have low specificity [155,73,70]. In a study by Keeney et al. comparing magnetic resonance arthrography versus hip arthroscopy in the evaluation of intra-articular pathology, sensitivity with respect to cartilage damage was found to be 47% and it was concluded that a negative imaging study does not exclude important intra-articular pathology that can be identified and treated arthroscopically [70]. Plain radiographs are the gold standard for detecting hip OA. MRI can add information, such as oedema and cartilage status, but a negative radiograph or MRI cannot fully rule out low-grade OA [138]. This fact is often evident in hip arthroscopy. The dGEMRIC (delayed gadolinium enhanced MRI of cartilage) technique is a new technique used to estimate the GAG content of cartilage. In a recent thesis from Lund University, it was shown that dGEMRIC could be used to predict OA [114]. However, dGEMRIC is not always readily available for clinical use.

When examining radiographs, clinicians must always bear in mind that radiological findings must be correlated to patient history and clinical findings, as FAI deformities can exist in asymptomatic patients. This means that the diagnosis of FAI is often complex and requires a thorough clinical evaluation of each patient.

1.8 TREATMENT OF FAI

There are several arthroscopic approaches and treatment algorithms to the hip. Many surgeons perform surgery with the patient placed in the lateral position. Traction is commonly obtained by axial leg traction against a well-padded perineal counterpost. Some surgeons use distraction by external fixators placed in both the pelvis and the femur.

The management of pincer lesions and management of the labrum vary among surgeons. A comprehensive definition of pincer impingement is yet to be established. In some publications, the cross-over sign is equated with a pincer lesion. Other publications argue that the definition of a pincer lesion is more complex, as the rotation of the pelvis greatly affects the cross-over sign [132,176].

Moreover, the management of labral damage is the subject of debate. Randomised studies have shown better functional outcomes with labral repair than debridement or resection of the labrum [137,84]. There is no established practice when it comes to treating cartilage damage. The available options are to resect the delam-

inated cartilage and microfracture or to preserve the cartilage. Some publications report on the use of autologous matrix-induced chondrogenesis (AMIC) or matrix-induced autologous chondrocyte implantation (MACI) techniques for treating cartilage damage. Recent studies of acetabular cartilage flaps have shown high viability for the chondrocytes, suggesting their preservation in some patients [98].

There is no clear evidence to indicate when to suture the labrum or how many anchors to use.

The management of the hip capsule is also the subject of debate. Many hip arthroscopic surgical descriptions recommend transverse sectioning of the capsule or a T-incision including a transverse incision. This particularly jeopardises the integrity of the ileofemoral ligament, a main stabiliser of the anterior part of the hip capsular ligament complex [18,159,158]. There are reports emphasising the importance of the capsule, warning of a risk of iatrogenic instability [135,124,93]. Lately, some surgeons have advocated capsular closure at the end of surgery [55].

1.8.1 NON-SURGICAL TREATMENT

Very few studies report on the outcome of the non-surgical treatment of FAI and the quality of evidence is low or very low [172]. Emara et al. reported on a cohort of patients with mild FAI, where conservative treatment did not improve the range of hip movement, but improvements were

seen in function and symptoms, as long as the patients modified their activities of daily living to adapt to their hip morphology [42]. The general recommendation for the non-surgical treatment of FAI is activity modification, emphasising the avoidance of impingement positions of the hip like sitting and squatting, patient education, non-steroidal anti-inflammatory drugs (NSAIDs) and physiotherapy. Descriptions of recommended physiotherapy focus on pelvic muscle strengthening and core stability [172]. Patients presenting with FAI may benefit from non-surgical treatment, but further research is needed to identify specific treatment regimens and their effectiveness.

In terms of patients with FAI with concomitant OA, as reported in Study IV, there is no literature describing non-surgical treatment or outcome. However, there is a national Swedish registry, the BOA (Bättre Omhändertagande av patienter med Artros, Improved care of patients with Osteoarthritis) study, including patients with general hip OA, reporting on outcome after non-surgical interventions such as physiotherapy and information [126]. Before intervention, patients with hip OA in the BOA registry report EQ-5D values of 0.65 compared with 0.62 in Study IV. After 12 months of intervention in the BOA registry, roughly the same number of patients report positive and negative results on the EuroQol-5D (EQ-5D), visual analogue scale (VAS), arthritis self-efficacy scale (ASES) and desire to have THA. The majority of patients report unchanged outcomes regarding these PROMs. This means that patients with symptoms of OA have few effective treat-

ment options other than THA. In the case of a patient who is “too young” for THA, there are few effective treatment options. Identifying the patients in whom OA is minor and secondary to FAI and where FAI is the main cause of symptoms, and treating the FAI arthroscopically, could lead to symptom relief in this patient category.

1.8.2 SURGICAL TREATMENT

There are currently numerous reviews, systematic reviews and meta-analyses summarising the results after hip arthroscopy for FAI [107,10,57,36,113,90]. These studies generally conclude that hip arthroscopy or the arthroscopic treatment of FAI yield good results in the short to medium term.

In a recent review of the outcomes of the surgical treatment of FAI, MacFarlane et al. state that the use of arthroscopy shows promising results in a range of studies [90]. However, only short-term outcome data are available and a range of different outcome measures have been used in studies to date. This review, which was published in 2014, includes studies of the outcome after open surgical treatment, arthroscopic treatment and combined procedures. Some of the studies are prospective, while most are retrospective, limiting the reliability of the data. To date, there are no comparative data comparing surgical treatment with other treatment modalities such as non-surgical interventions.

A controlled study of FAI surgery by Espinosa et al. compared FAI surgery with resection of the torn labrum with FAI surgery with re-attachment of the labrum to the acetabular rim [43]. Both groups improved compared with pre-operatively. The group with labral refixation showed a greater improvement than the group with labral resection, but the resection group had a higher degree of OA. Moreover, Schilders et al. reported that labral repair produced superior results compared with labral resection in a study of 151 patients with FAI and labral tears who had been treated arthroscopically [137]. These studies suggest that labral refixation is superior to labral resection. However, no studies randomising the two procedures have been performed and these studies might therefore be subject to bias.

In a systematic review by Ayeni et al. including studies comparing labral repair with labral debridement, five of six studies reporting statistically significant improvements from repair compared with debridement [13]. However, the authors concluded that, given the lack of high quality evidence and associated limitations in study design, these results should be interpreted with caution.

There is emerging evidence of the long-term effectiveness of FAI surgery. Mef-tah et al. reported on 50 consecutive patients who underwent hip arthroscopy and labral debridement with a mean follow-up of 8.4 years. Good to excellent results were seen in 62% [95]. Byrd et al. evaluated 50 patients 10 years after index hip arthroscopy. Significant improvements were shown at group level, but the

presence of arthritis at the time of the index procedure was an indicator of poor prognosis [25].

There is a trend towards better results after arthroscopic surgery as compared to open surgery with better outcome scores and fewer complications [113]. In a systematic review by De SA et al., no significant differences in outcomes for FAI treated with surgical hip dislocation or arthroscopy were reported. However, with regard to health-care resource utilisation, hip arthroscopy uses substantially fewer resources than surgical hip dislocation [37].

In a recent study from Ilizaliturri et al. [62], the "over-the-top" technique is described and evaluated in a prospective series of patients treated arthroscopically for FAI. This technique involves osteoplasty of the acetabular rim without detaching the labrum. Good results have been reported using this technique. Redmond et al. did not find any differences in outcome between arthroscopic acetabuloplasty and labral refixation with or without detachment [125]. No studies that compare labral takedown or the "over-the-top" technique can be found in the literature.

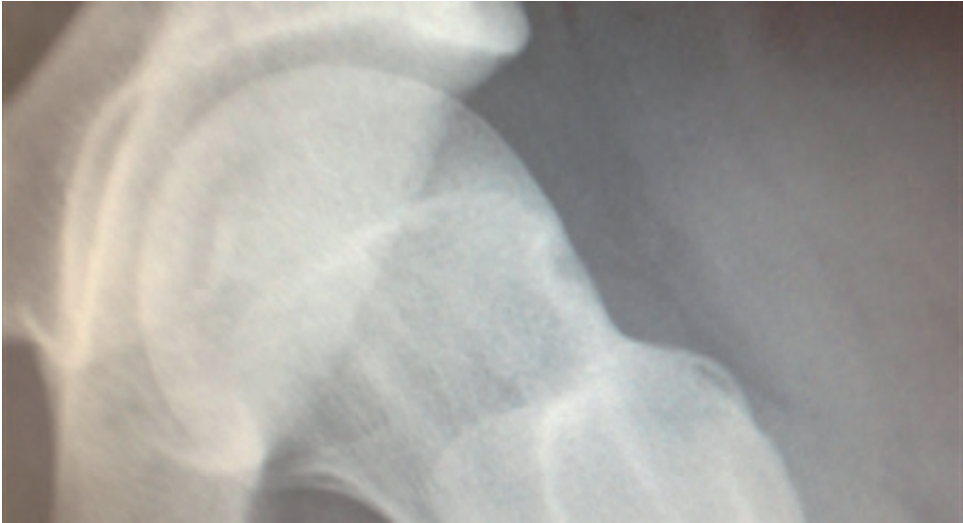

Figure 25 a. *Pre-operative images of cam deformity.*

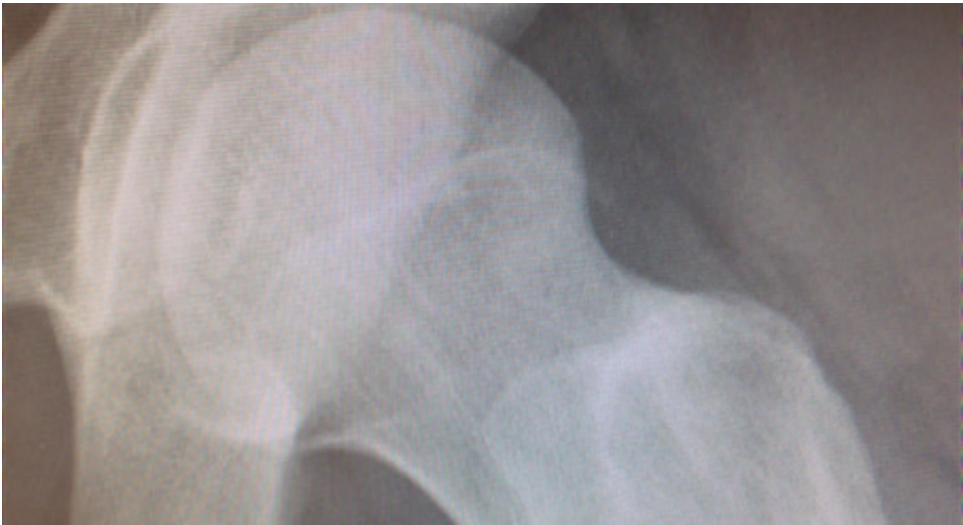

Figure 25 b. *Post-operative image after cam resection in (a).*

1.8.3 COMPLICATIONS

The type and rate of complications after arthroscopic treatment have been investigated in several series involving patients undergoing arthroscopic treatment. A meta-analysis by Kowalczyk et al. included 66 studies with a total of 6,962 patients. The overall complication rate was found to be 4.0%. Of the 287 complications identified in the literature, 20 were deemed major, constituting a rate of 0.3%.

Another systematic review of more than 6,000 patients by Harris et al. reported an overall complication rate of 8%, of which 0.58% were major and 7.5% minor.

Minor complications include heterotopic ossification (HO), cartilage scuffing, superficial nerve neuropraxia of the hip or foot, adhesions, labia minora blistering and scuffing of the femoral head cartilage.

Major complications include femoral neck fracture, deep vein thrombosis (DVT), septic arthritis, avascular necrosis (AVN) of the femoral head, intra-abdominal fluid extravasation and post-operative dislocation.

A systematic review by Yeung et al. examining the efficacy of NSAID drug prophylaxis for heterotopic ossification after hip arthroscopy found a 13% incidence without NSAID and 3% with NSAID [174]. NSAID is therefore generally recommended as prophylaxis against HO in hip arthroscopy.

In this thesis, we present a case report on post-operative dislocation after hip arthroscopy. The report includes two cases of post-operative dislocations. In both cases, a

psoas tenotomy was performed in conjunction with hip arthroscopy. There have been a few other previous reports of dislocations after hip arthroscopy, but, in these cases, dysplasia or laxity has been a contributory factor and no psoas tenotomy was performed [19,96,93,124].

Table 2. Complications after hip arthroscopy according to a review by Harris et al. (2013).

COMPLICATION	% (OF TOTAL 6,334 HIP SURGERIES)
MAJOR	
<i>Deep infection</i>	0.02%
<i>AVN</i>	0.2%
<i>Femoral neck fracture</i>	0.05%
<i>Permanent nerve injury</i>	0.02%
<i>Extra-articular fluid extravasation</i>	0.02%
<i>Hip dislocation</i>	0.06%
<i>Pulmonary embolism</i>	0.02%
MINOR	
<i>Transient nerve injury</i>	1%
<i>DVT</i>	0.1%
<i>Heterotopic ossification</i>	0.7%
<i>Superficial infection</i>	0.1%
<i>Skin damage</i>	0.2%
<i>Iatrogenic chondral injury</i>	5%
<i>Hypothermia</i>	0.1%
<i>Broken instruments</i>	0.1%
<i>Vascular injury</i>	0.03%
<i>Reflex sympathetic dystrophy</i>	0.04%

1.9 SURGICAL TREATMENT OF FAI IN THE SETTING OF HIP OA

Surgical treatment, including both open and arthroscopic, is not indicated for OA per se. However, when there is a concomitant FAI, it is difficult to discern whether it is the OA or the FAI that gives rise to symptoms. In two recent review studies, it is concluded that patients with concomitant OA had a post-operative clinical outcome improvement in pain and function in a short-term evaluation [119,71]. Increasingly poor outcomes were seen as the severity of OA increased. However, these studies report on the outcomes of hip arthroscopy for OA and not specifically FAI, as in Study IV in this thesis. The included studies report on a variety of procedures for FAI, OA, labral tears, cartilage damage and other conditions associated with OA. This leads to a validity problem. Surgical treatment for FAI has become a common treatment in modern health care, whereas the arthroscopic treatment of OA per se is still controversial and even contra-indicated.

In a recent review study by Domb et al. (2015), the authors asked how much arthritis is too much for hip arthroscopy. They found insufficient data to define any cut-off, but poorer results, as measured by PROMs, and higher conversion rates to THA are seen with higher degrees of OA. Post-operative scores using patient-reported outcome instruments were lower in the arthritic population at follow-up compared with their non-arthritic counterparts.

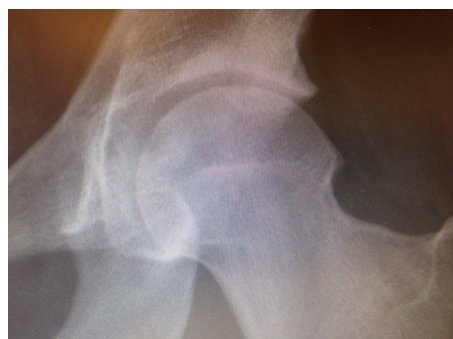

Figure 26. 19-year old patient with osteoarthritis, in this image radiograph shown as slight lateral joint space narrowing, increased sclerosis and osteophyte formation. Arthroscopy showed advanced cartilage deterioration and thinning as well as typical osteophyte formation intra- and extraarticularly.

1.10 EVALUATION OF TREATMENT OF FAI

1.10.1 DATABASE AND REGISTRY RESEARCH

Today, patient-based treatment evaluation (PROM) is the mainstay of surgical outcome research. Over the last few decades, clinical registries using PROMs have emerged worldwide to enable the aggregation of patient data and tracking over time. They are a powerful tool for examining the long-term outcomes and complications, as well as evaluating different subgroups, improving diagnostics and refining treatments. In Sweden, registries such as the Swedish total knee registry and total hip registry were the first major joint registries. The quality and usability of a registry is dependent on the compliance and measured variables.

The strengths include the large number of possible participants, especially in national registries, outcomes relevant to the specific disease and the opportunity to follow variables over time. The weaknesses include problems with compliance and follow-up, cost, risk of bias due to lack of randomisation and multiple confounding variables [122].

1.10.2 FAI REGISTRIES

Since the arthroscopic treatment of FAI was popularised, several registries monitoring surgical outcome have been established. They include both local, single-unit or single-surgeon registries, and national registries.

In this thesis, we present the creation of and results from the Gothenburg hip arthroscopy registry. This is a local clinical registry created for research and clinical development.

The Danish hip arthroscopy registry is a nationwide project including all centres at which hip arthroscopy is performed. It originated from the same group as the Gothenburg hip arthroscopy registry and therefore has the same outcome scores.

The Non-Arthroplasty Hip Registry (NAHR) is a British nationwide registry that currently includes around 30 surgeons organised by the British Hip Society.

The strengths of a national registry are the large amount of collectible data, the opportunity to study geographical variation and easier funding.

The surgical outcome system (SOS) is an industry project aiming to collect data from hip arthroscopists worldwide to build a global registry.

Moreover, many high-volume surgeons and hip arthroscopists around the world have created local registries documenting the outcome of their patients.

1.10.3 FAI OUTCOME SCORES

A wide array of outcomes have been used historically to evaluate the outcome of surgical treatment for FAI [13,57]. A systematic review by Hetaimish et al. on the consistency, or lack thereof, of clinical and radiographic outcomes reported across 29 studies addressing FAI found that the most common clinical outcomes reported were the Harris Hip Score (HHS) (45%) and the Non-Arthritic Hip Scale (NAHS) (28%), range of motion (ROM) (34%), pain scores (24%) and patient satisfaction (using visual analogue scales) (28%) [60]. Other primary clinical outcomes cited in the literature to assess post-operative outcomes include the use of the anterior impingement test (flexion, adduction, internal rotation), modified HHS (mHHS), Short Form 12 (SF-12), Hip Outcome Score-Activities of Daily Living (HOS-ADL) and/or Hip Outcome Score-Sport-Specific (HOS-SS) [84].

Some of these scores have been developed for use in more senior patient cohorts, mainly for use in arthroplasty research, and their validity for use on a young and very active population such as

athletes can therefore be questioned.

In recent years, new outcome measures have been developed and validated for use in younger, active patients; they include the International Hip Outcome Tool (iHOT) and the Copenhagen Hip and Groin Outcome Score (HAGOS). The Hip Sports Activity Scale (HSAS) was adapted after the Tegner activity scale and modified to measure physical activity in a pop-

ulation with hip disorders.

In a recent review by Harris-Hayes et al., the HAGOS and iHOT-33 were recommended for use in young and middle-aged, active patients suffering from FAI [59].

Table 3 summarises the currently most used PROMs for FAI research

<i>Patient-reported outcome measures currently in use for patients undergoing hip arthroscopy</i>				
<i>SCORE</i>	<i>TYPE</i>	<i>Number of items</i>	<i>DOMAINS</i>	<i>Developed for patient group</i>
<i>HHS [58] (Harris Hip Score)</i>	<i>Likert scale, a single total score is calculated.</i>	<i>10</i>	<i>4 (pain, function, range of movement and absence of deformity)</i>	<i>Traumatic arthritis after hip dislocation and acetabular fractures</i>
<i>mHHS [24] (modified Harris Hip Score)</i>	<i>Likert scale, a single total score is calculated.</i>	<i>8</i>	<i>3 (pain, function and ADL)</i>	<i>From the HHS, for young to middle-aged patients undergoing hip arthroscopy</i>
<i>HOOS [111] (Hip disability and Osteoarthritis Outcome Score)</i>	<i>Likert scale, a total score is calculated for each of five subscales.</i>	<i>40</i>	<i>5 (pain, symptoms, ADL, sport/recreation function, hip-related quality of life (QOL))</i>	<i>Middle-aged and older patients with hip OA</i>
<i>HOS [92] (Hip Outcome Score)</i>	<i>Likert scale, a total score is calculated for each of two subscales.</i>	<i>28</i>	<i>2 (ADL and sports)</i>	<i>Young and middle-aged patients undergoing hip arthroscopy</i>
<i>HAGOS [165]</i>	<i>Likert scale, a total score is calculated for each of six subscales.</i>	<i>37</i>	<i>6 (pain, symptoms, physical function in daily living, physical function in sport and recreation, participation in physical activities and hip-related QOL)</i>	<i>Young and middle-aged adult patients with hip and/or groin pain</i>
<i>iHOT33 [101]</i>	<i>VAS scale, a single total score is calculated.</i>	<i>33</i>	<i>4 (symptoms and functional limitation, sports and recreational activities, job-related concerns and social, emotional and lifestyle concerns)</i>	<i>Young and middle-aged active patients with hip disorders</i>
<i>iHOT12 [53]</i>	<i>VAS scale, a single total score is calculated.</i>	<i>12</i>	<i>4 (symptoms and functional limitation, sports and recreational activities, job-related concerns and social, emotional and lifestyle concerns)</i>	<i>Adapted from the iHOT33, for young and middle-aged, active patients with hip disorders</i>

1.10.4 COMPOSITE OUTCOMES

In the hunt for the perfect outcome measurement, a composite of outcome measures could be a way to reduce the sample size needed for statistical power by examining more study end-points [133,81,82], especially when they are rare. Montori et al. have clarified that the important considerations for a composite outcome measurement include the following: (1) the outcomes are of similar relevance to patients; (2) the outcomes occur with similar frequency; and (3) the relative risks are similar across all components of the composite. So, in order to develop a “composite outcome” applicable to FAI, first ascertaining patient-important outcomes, evaluating which instruments are most commonly used and assessing their validity to patients with FAI is paramount. Several outcomes have been reported following the surgical management of FAI. They include clinical outcomes, gait and biomechanics, imaging and biomarkers. In Study VII, the composite outcome or end-points that may be applicable for FAI are discussed.

1.11 WHY IS THIS THESIS NEEDED?

1. There is a large patient population suffering from long-standing hip and/or groin pain. Many of these patient symptoms may be caused by femoro-acetabular impingement (FAI).

2. Until recently, no effective treatment methods have been available. Hip arthroscopy is a relatively new method for treating hip disorders. Internationally, there has been a dramatic increase in the number of FAI-related publications in recent years [14]. Several studies report improved outcomes after the arthroscopic treatment of FAI for patients with long-standing hip and/or groin pain. However, most studies are retrospective or prospective with small cohorts.

3. The outcome measures used for evaluating patients with long-standing hip and/or groin pain have been of limited validity, such as the Modified Harris Hip Score, which is the most commonly used.

4. Analyses of common subgroups with FAI, such as athletes and patients with concomitant OA, are few in number and often use older and non-valid outcome measures.

5. Valid PROMs are thus lacking in most literature, but they have been available for the past few years and include the iHOT12, HAGOS, HSAS and EQ-5D.

6. As long-standing hip and/or groin pain due to FAI is seen among both women and men, among young and older patients, among elite and recreational athletes and with or without osteoarthritis, large populations of patients are needed in order to be able to sub-group patients into more homogeneous groups.

02

MIKAEL SANSONE

02. AIMS

2.1 OVERALL AIMS

The overall aim of this thesis was to evaluate, using valid methods, the results for various groups of patients with long-standing hip and/or groin pain undergoing arthroscopic hip surgery.

2.2 SPECIFIC AIMS

Study I

To describe the development of a hip arthroscopy registry, its function and impact. A secondary aim was to describe demographic baseline data collected during a 14-month period relating to the first 606 patients in the registry.

Study II

To evaluate the results, using PROMs, two years after arthroscopic surgery for a mixed group of patients with FAI.

Study III

To evaluate the results 12 months after arthroscopic surgery for FAI in a group of top-level athletes using PROMs.

Study IV

To evaluate the results 12 months after arthroscopic surgery for FAI in a group of patients with concomitant OA using PROMs.

Study V

To evaluate the long-term outcome for patients undergoing tenotomy for pubalgia in terms of PROMs. A secondary aim in this study was to examine whether athletes with signs of FAI had different outcomes using PROMs compared with patients without signs of FAI.

Study VI

To present two cases of post-operative total hip dislocation after hip arthroscopy and psoas tenotomy and report on potential causes and implications

Study VII

To present and examine a variety of endpoints currently used to examine FAI patients and discuss the possibility to combine these outcomes to evaluate FAI patients.

03

MIKAEL SANSONE

03. SUBJECTS

The patients included in Studies I, II, III and IV were included and evaluated in a similar way through the database described in Study I. Depending on the research question, patients were obtained through this hip arthroscopy registry.

Study I

All patients undergoing arthroscopic hip surgery from the start of the registry (n=606) in November 2011 to January 2013 were included in Study I. Their mean age was 36.6 years (standard deviation, SD, 13.1).

Study II

Between November 2011 and February 2013, 289 patients (males=190, females=99, total hips=359) underwent arthroscopic surgery for FAI and were prospectively included in Study II. The follow-up was performed two years post-operatively. The mean age was 37 years (SD 13).

The inclusion criterion was arthroscopic surgery for suspected FAI. The number of eligible patients was 394, of which 22 were excluded due to prior hip surgery and 83 did not complete the follow-up.

All hip arthroscopies were performed at two centres by three surgeons. Indication for surgery was an established diagnosis of FAI and failed non-surgical treatment. Contra-indications included advanced osteoarthritis (OA), with joint space below 2 mm, and severe dysplasia of the hip.

Study III

Between 2011 and 2012, a total of 85 top-level athletes (68 males, 17 females) who underwent arthroscopic surgery for FAI (total number of hips 115) were followed prospectively for one year. All athletes who met the inclusion criteria during the study period were prospectively included. The mean age of the study participants was 25 years (SD 5). The inclusion criteria were HSAS activity level 7 or 8 (range, 0-8) prior to symptom onset and age < 40 years. HSAS level 7 corresponds to alpine skiing, skating and dancing at a national elite level or football, ice-hockey, tennis, martial arts and track and field sports at a sub-elite level, while level 8 corresponds to sports such as football, martial arts, tennis and track

and field at a national and international top level. Patients who had undergone hip surgery prior to the index operation were excluded. All hip arthroscopies were performed at two centres by three surgeons. Indications for surgery were an established diagnosis of FAI and failed non-surgical treatment.

Study IV

Pre-operative radiographs of all primary hip arthroscopies performed by three surgeons due to FAI between November 2011 and December 2012 (n=569) at two centres were assessed prospectively by a single observer. The inclusion criterion was signs of OA, defined as Tönnis grade 1 or 2. The exclusion criteria were re-operation (n=10), non-FAI cases (n=2) and diabetes (n=1). A total of 80 hips in 75 patients (males n=59, females n=16) were included and followed prospectively with regard to PROMs for two years. Indications for surgery were a clinical and radiological diagnosis of FAI and failed non-surgical treatment consisting of structured physiotherapy for a minimum of three months, sometimes adding cortisone injections. The mean age was 47 years (SD 10).

Study V

Between 1998 and 2010, 46 athletes with chronic groin pain underwent tenotomy of either the adductor longus and/or rectus abdominis. Surgery was performed either at the Orthopaedic Department, Sahlgrenska University Hospital, or at a private clinic in Gothenburg, Sweden. The indications for surgery were long-standing groin pain and the inability to participate in sport due to pain over

the adductor origin and/or the pubic attachment of the rectus abdominis. In all these athletes, conservative treatment including unspecified physiotherapy had failed. Fourteen athletes were unable to participate in the follow-up and were excluded. Three athletes had moved abroad and 11 had other reasons for not wanting to participate in the study. All the athletes were male and, at the time of surgery, they were all active medium- or high-level football players, except for two, who were high-level ice-hockey players, and one, who was a long-distance runner. The athletes' median age at follow-up was 30 years (range 21-56). The same PROMs as in Studies I, II, III and IV were used to evaluate outcome.

Study VI

The two patients included in Study VI were operated on at other institutions in Sweden. We became aware of these cases through referrals. Both patients were 26 years old at the time of surgery.

Study VII

No patients were included.

04

MIKAEL SANSONE

04. METHODS

4.1 DEVELOPMENT OF A REGISTRY FOR HIP ARTHROSCOPY

During an expert group meeting in 2011, five patient-reported outcome measures (PROMs) were identified as being suitable for use in a Scandinavian setting for patients undergoing hip arthroscopy. The PROMs were the international hip outcome tool (iHOT-12), the Copenhagen hip and groin outcome score (HAGOS), the EQ-5D quality-of-life scale, the hip sports activity scale (HSAS) and a visual analogue scale (VAS) for global hip function (see appendix) [52,164,123,105,103].

The iHOT-12 and HAGOS scores were chosen, as they are modern scores that were developed specifically for this young and active patient group. These scores have also been shown to be reliable and valid and to have good responsiveness [164,52,162,66].

In all, the questionnaires contain 57 items, which was considered sufficient to cover important aspects of patients with hip and/or groin symptoms qualifying for hip arthroscopy.

An effort was made to organise a large multi-centre, cross-border Scandinavian registry. However, concerns related to technical difficulties paved the way for the decision that separate registries were of benefit but with uniform outcome measures, as stated above.

At that time, only the EQ-5D had been translated, culturally adapted and validated into Swedish. In order to identify and use valid outcome measures, the iHOT-12, HAGOS and HSAS scores were therefore translated, culturally adapted and validated into Swedish [162,66].

A web-based online protocol that offers online surveys and analyses was created in order to collect all patient-related information. Patients scheduled for hip

arthroscopy were asked to complete the web-based protocol on the clinical visit, or online at any time before the actual surgery. The clinic was equipped with tablet computers for easy access. All data extraction was readily accessible in the form of output files for different data options.

Follow-ups took place at four months, one year and two years after the hip arthroscopy, using the web-based online protocol. Five-year follow-ups are planned for future research.

All data related to the clinical examination, pre-operative findings, diagnosis and range of motion measurements were recorded using a specific protocol (see appendix). This protocol followed the patient notes to the operating room. The protocol was completed with all the necessary peri-operative data, such as the procedure performed, clinical findings, operation time measured from skin incision to skin closure, traction time, complications and post-operative diagnosis. Moreover, a description of cartilage status was made according to the classification by Konan et al. (see appendix) [77].

4.2 PATIENT REPORT-ED OUTCOME MEASURES (PROMS)

The following PROMs were used in Studies I, II, III, IV and V. The scores were presented to patients as a web-based online protocol.

iHOT-12

The international Hip Outcome Tool 12 (iHOT-12), first published in 2012 [52], is a shorter version of the iHOT-33 [100] that was developed by the Multicentre Arthroscopy of the Hip Outcomes Research Network (MAHORN group) to evaluate young and active patients with hip disorders. Patients answer each item by marking a VAS between two anchor statements. Each item gives a score between 0 (worst) and 100 (best), whereafter a total score is calculated as a mean from all 12 items. The iHOT-33 was developed for research and may therefore have been better suited, but the size of the complete web-based protocol might then influence patient compliance. The iHOT-12 has been shown to be valid, reliable and responsive and to have characteristics that are very similar to the originally validated 33-item questionnaire [52]. The iHOT-12 has been translated and adapted to Swedish by Jónasson et al. [66].

For the iHOT-12 score, the smallest detectable changes have been found to be 3.6 points at group level and 17 at individual level [65,162]. Moreover, minimally important changes (MIC) have been shown to be 9 for the iHOT-12 [66,163].

(For a full version of the score, see appendix.)

HAGOS

The HAGOS, first published in 2011 by Thorborg et al., was developed to evaluate hip and/or groin pain in young or middle-aged patients. The HAGOS comprises 37 items in six subscales; symptoms (7 items), pain (10 items), function of daily living (5 items), function in sports and recreation (8 items), participation in physical activities (2 items) and hip- and/or groin-related quality of life. Each item is answered on a five-level Likert scale, which produces a score from 0 (best) to 4 (worst). The total score for each subscale is calculated and transformed to a score ranging from 0 (worst) to 100 (best). There is no aggregate score for all six subscales, as these are independent scores. The HAGOS has been translated and adapted to Swedish by Thomeé et al. [163].

For the HAGOS scores, the smallest detectable changes (SDC) have been found to be 1.6-3.2 points at group level and 8-16 at individual level, depending on subscore [65,162]. Moreover, minimally important changes (MIC) have been shown to be 9 to 17 points (depending on subscore) for the HAGOS subscores [66,163].

(For a full version of the score, see appendix.)

HSAS

The HSAS is a validated adaptation of the Tegner activity level scale [157] that has been reworked to better match an active patient population with regard to hip

function. It is created to measure sports activity level. The HSAS comprises only one item where patients have a scale of nine levels where 0 represents no competitive or recreational sports and level 8 represents sports at national and international elite level. The different sports are weighted so that some sports, such as golf and swimming, albeit at elite international level, qualify as level 6, whereas football and athletics at international level qualify as level 8.

Although not yet published, the HSAS has been translated, culturally adapted and validated into Swedish, using the same procedure as with the iHOT-12 and HAGOS scores [66,163].

We are not aware of the SDC and MIC for the HSAS and we are therefore unable to comment on the clinical relevance of these scores.

(For a full version of the score, see appendix.)

EQ-5D

The EQ-5D is a standardised, generic PROM for use as a measurement of general health outcome (Euroqol 1990). It is applicable to a wide range of treatments and conditions and delivers a simple profile and index value for health status. It measures five constructs (mobility, self-care, usual activities, pain/discomfort and anxiety/depression) on five levels (no problems, slight problems, moderate problems, severe problems and extreme problems). The score ranges from -0.594 to 1, with 1 representing full health and values of less than 1 considered worse

than death. The patient also records his or her self-rated health on a 20 cm vertical VAS marked from 0 to 100, with 0 equalling the worst imaginable health and 100 the best imaginable health. The results from the five items and the VAS are reported separately.

The EQ-5D was chosen to be part of the FAI registry, as it is a commonly used and validated quality-of-life score.

For the EQ-5D, the SDC and MIC have been reported to be 0.04 and 0.07-0.12 respectively [173,170]. For the EQ-VAS, the MIC has been reported as 4.2-14.8 points [32].

(For a full version of the score, see appendix.)

VAS FOR OVERALL HIP FUNCTION

This item is a question on how the patients rate their hip function on a scale from 0-100, where 100 is the best possible function. This question is not validated but was chosen due to its simplicity.

The VAS for overall hip function has not been validated.

(For a full version of the score, see appendix.)

SATISFACTION

This item is a question about whether the patient would undergo the operation again under the same circumstances. The "satisfaction" item has not been validated.

(For a full version of the score, see appendix.)

4.3 CLINICAL EVALUATION

Defining FAI in Studies I, II, III and IV

FAI is a medical condition that is difficult to define, as there are no clinical tests that confirm the condition with 100% sensitivity and specificity. FAI is based on the theoretical grounds that a bony incongruence in the hip joint leads to a non-physiological abutment between the femur and the acetabulum, leading to damage to either cartilage or labrum. The clinical diagnosis of FAI is based on patient history, clinical signs and radiographic evaluation (see Sections 1.7.3 and 1.7.5 for details). In addition, there must be no other plausible diagnosis for the patient in question. If these parameters point towards the FAI syndrome in a patient, a clinical diagnosis is made.

Generally, a diagnosis of FAI is based on the following diagnostic criteria.

- Positive impingement and FABER sign, especially if they reproduce the patient's symptoms.
- Reduced ROM of the hip, especially in internal rotation in conjunction with the anterior impingement test or in the FABER position.
- Radiological signs of FAI, either cam or pincer. Cam deformity is defined as an alpha angle of > 50 degrees on a modified Dunn's view on plain radiographs. Pincer deformity is defined by the cross-over

sign and with other signs of excessive acetabular version or global acetabular overcoverage.

- A correlation between the reduced ROM, findings of the impingement tests and the radiographic signs.
- A patient history matching FAI (see Section 1.7.3)
- Absence of signs of other hip conditions indicating other primary pathology

Study V

All the athletes were examined in the supine position by the same examiner with regard to hip impingement tests [16]. Deep pain from the groin/hip area elicited in the extreme range of motion in internal rotation with the hip flexed at 90 degrees and with no adduction was regarded as a positive test.

This pain was differentiated from other extra-articular pain sources by means of a thorough standardised hip examination.

4.4 RADIOLOGICAL EVALUATION

Study IV

All radiographs were reviewed and classified according to Tönnis [168] by an independent radiologist, expert in musculo-skeletal radiology. Moreover, the joint space was measured at three locations pre-operatively and at the one-year follow-up on an anteroposterior (AP) pelvic

radiograph (lateral sourcil, middle sourcil and above the level of the fovea) [118]. If a THA had been performed, this was registered.

Study V

At follow-up, a standard pelvic radiograph with an AP view and a modified Dunn's view was performed on all the athletes. In seven athletes, radiographs were obtained on only the affected side, while 25 athletes were examined bilaterally. The alpha angle was measured using Osirix software (Pixmeo, Geneva, Switzerland) on the modified Dunn's view as the angle between a line drawn through the femoral neck and the point at which the femoral head loses its sphericity. An alpha angle of more than 50 degrees was considered to indicate a cam lesion [2].

4.5 SURGICAL TECHNIQUE

The surgical technique utilised is described in brief in Studies I, II, III and IV.

The patient is fully sedated or in spinal analgesia if there are contra-indications for general anaesthesia.

The patient is placed supine in a hip arthroscopy-specific traction table with a well-padded perineal post.

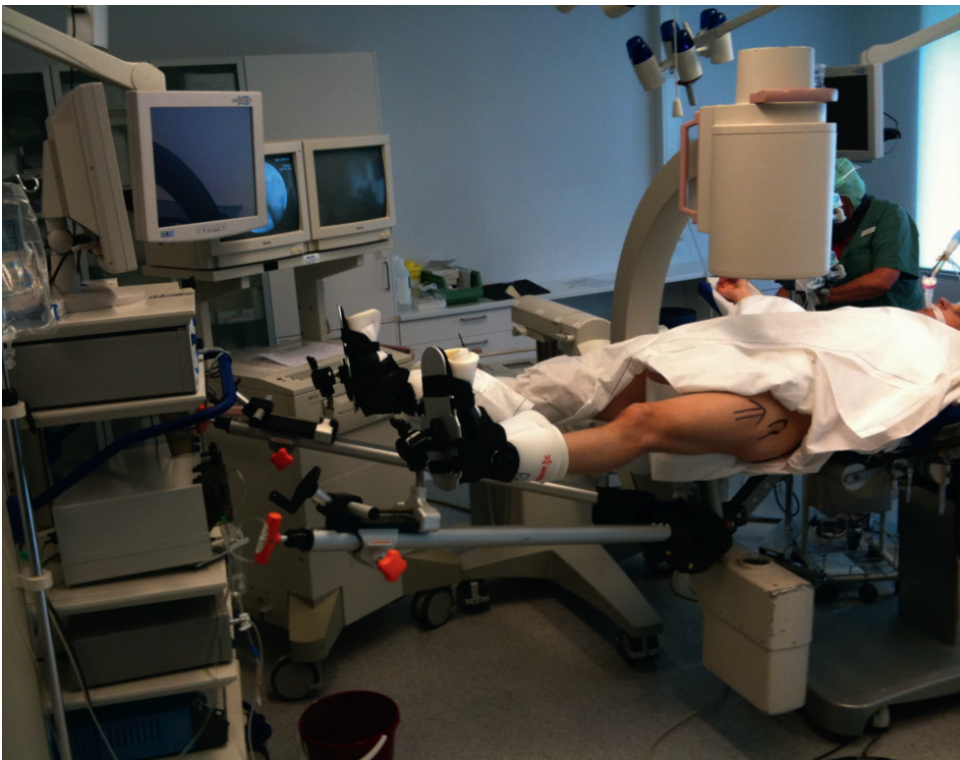

Figure 27. Setup of hip arthroscopy in the operating theatre. Legs are attached to traction devices. C-arm in place for fluoroscopy.

Our preferred technique is to use two portals, an antero-lateral portal and a mid-anterior portal. Additional portals can be added when needed.

Surgery starts with the visualisation of the central compartment. To achieve this, traction is applied and the needle is first inserted in the peripheral compartment. This facilitates partial distraction of the central compartment. The needle is then redirected to the central compartment, under fluoroscopic control, aiming between the femoral head and the labrum, which can often be visualised. Removing the gauge with the needle in the central compartment will achieve the correct distraction of the hip in order to view the central compartment (Figure 28).

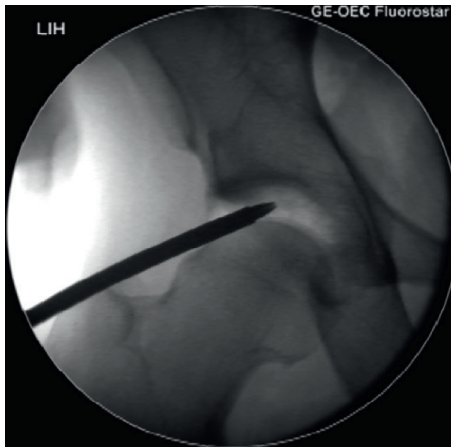


Figure 28. Fluoroscopic image of the arthroscope entering the distracted joint. Hip with pistol-grip deformity.

All accessible parts of the central compartment are then carefully visualised, including the acetabular and femoral cartilage, the labrum, the chondro-labral junction, the cotyloid fossa, the ligamentum teres and the transverse ligament. In addition, for diagnostic reasons, surgical procedures can be performed in the central compartment, i.e. free body removal, soft tissue removal, cartilage debridement and microfracture. An accessory portal can be established under visual control using a needle and guide wire. A hook for probing the surfaces, a grasping forceps or a shaver can be introduced through the additional portal. The central compartment is viewed using air as the medium. If work is done centrally, water is added and outflow is secured through an additional portal.

Some hips are difficult to distract. Repeated attempts can achieve distraction and it is important first to distract the opposite leg to prevent the pelvis from tilting. However, the technique used in this thesis does not rely on distraction in order to perform pincer resection or labral work. This is done with the hip non-distracted, which is beneficial to the patient, as distraction is related to an increased risk of complications [160,46,115].

After the completion of diagnostics and central compartment work, the needle is re-inserted in the peripheral compartment through the anterolateral portal under fluoroscopic control. The point in the capsule where the needle enters the peripheral compartment is carefully selected in order to obtain ligament-sparing access. The arthroscope is then inserted

into the peripheral compartment over a guide wire. The needle is then re-inserted through the mid-anterior portal under visual control. Again, the entry point in the capsule is carefully selected, as its location determines the starting point of the capsulotomy. A soft-tissue shaver is introduced over a guide wire and a small incision is made in the capsule, 1-2 cm below the labrum. The instruments are then switched using guide wires so that the scope is now positioned in the mid-anterior portal and the shaver in the anterolateral portal. A capsulotomy is then made connecting the two entry points in the capsule using the shaver. The goal is to achieve a longitudinal cleavage placed in the direction of the fibres of the capsular ligaments. The capsulotomy is extended caudally/laterally to the zona orbicularis. This creates a 2-3 cm cleavage in the capsule through which most of the femoral neck can be accessed. The accessible area of the femoral neck can be further increased by rotating the leg.

We place the capsulotomy in the “rotator interval of the hip”, which lies between the ileofemoral and the pubofemoral ligaments. The reason is that we believe that the ligaments of the hip capsule, mainly the ileofemoral, pubofemoral and the ischiofemoral ligaments, perform important functions, the functions and impact of which are still largely unknown. Increased interest has recently been shown in the concept of hip instability and the importance of the capsule. Transverse cuts in the capsule could therefore jeopardise its function. Many surgeons recom-

mend repairing the capsule at the end of the procedure. We believe that, by minimising the damage to the ligaments and capsule, the risk of an iatrogenic increase in laxity of the hip can be reduced [135,93].

A diagnostic evaluation of the peripheral compartment is then made, including the labrum, the synovium, the lateral and medial synovial folds and the perilabral sulcus. If psoas pathology is suspected, a small incision can be made in the capsule directly underneath the psoas through which the tendon or tendons can be accessed.

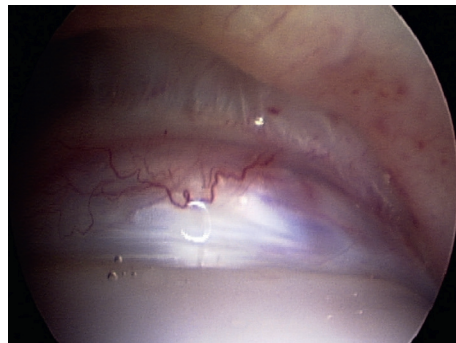


Figure 29. Arthroscopic image of the external hip compartment. Transversely the labrum is seen, with the capsule above. Below the labrum is the femoral head. The joint is not distracted.

In the case of pincer impingement, the acetabular edge can be accessed for burring with the burr in the mid-anterior portal. Acetabuloplasty can usually be achieved using an “over-the-top” technique with the labrum in situ as long as the chondrolabral junction is intact. In the case of large pincer deformities, such as coxa profunda, the labrum can be detached

initially with a banana knife or else it detaches itself during resection. Following the resection of a localised pincer, the labrum is checked for stability with a probing hook. If the labrum is unstable, it can be re-attached to the edge of the acetabulum using anchors. The sutures are placed between the acetabular edge and around or through the labrum. A cannula is introduced through the mid-anterior portal to facilitate anchor placement and knot tying. If the labrum is perceived to be stable, no sutures are needed.

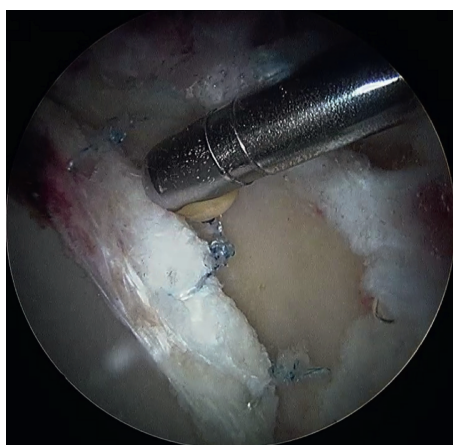


Figure 30. Suture of the labrum with 3 sutures.
Photo: F Ayeni

Any femoral deformity can then be addressed. Since the exact area of impingement can be difficult to establish, we aim to resect any deformity that could lead to impingement. We aim at achieving a low alpha angle without over-resection. In or-

der to achieve this, our resection usually spans from far posterior, usually behind the lateral retinacular vessels, to far medial, close to the medial retinacular fold. The resection is performed under repeated fluoroscopic control. The extent of the resection in the proximal/caudal direction is therefore determined by the fluoroscopic image. We also believe in correcting eventual pistol-grip deformities, which necessitates resection far posterior. This puts the lateral retinacular vessels at risk of damage. We have developed a technique to resect the bone directly in front of, behind and proximal to the lateral retinacular fold. An intra-surgical dynamic assessment of impingement can also be made to assess the result.

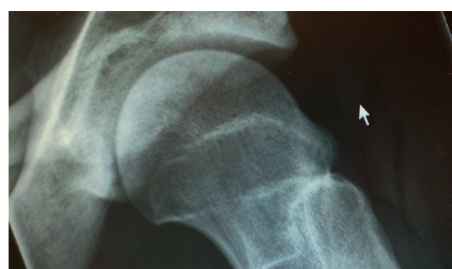

Figure 31 a. Pre-operative images of large cam deformity

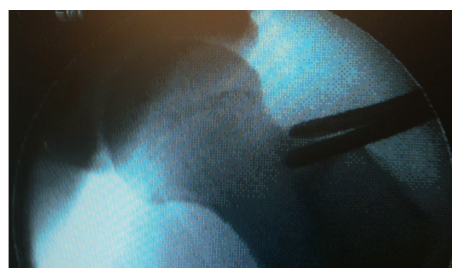

Figure 31 b. Post-operative image after large cam resection in (a)

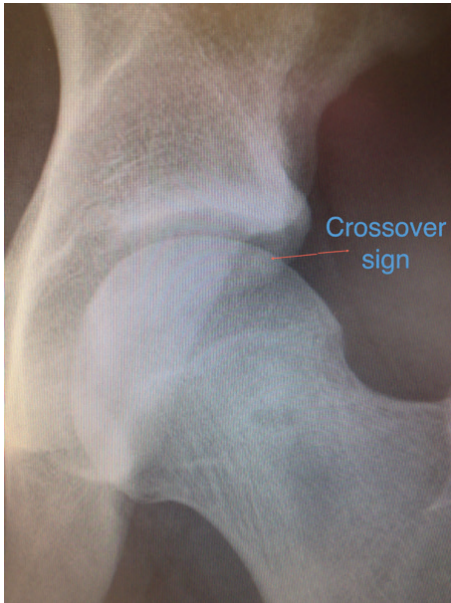

Figure 32 a. *Pincer seen by a crossover sign preoperatively.*

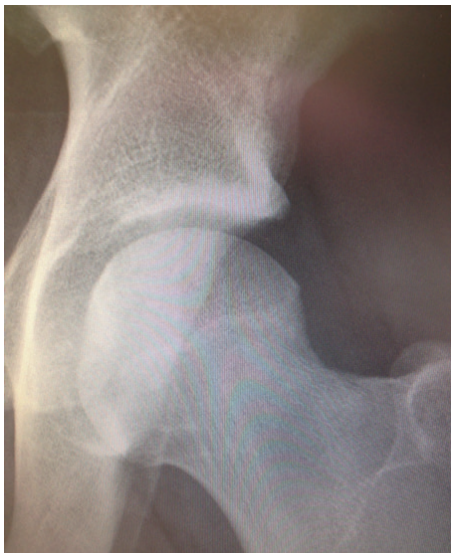

Figure 32 b. *postoperative image after resection of pincer deformity in figure 32 a above. Note that as this is only a left hip AP radiograph, some of the disappearance of the crossover sign could be due to different pelvic rotation.*

Post-operatively, patients were allowed free ROM and full weight-bearing during the early rehabilitation phase. Crutches were recommended for outdoor and longer ambulation for one month. Physiotherapy was started directly post-operatively, with a protocol of rehabilitation exercises for ROM, strength, endurance, balance and co-ordination. The intensity of the protocol was gradually increased, as tolerated by the patient, and carefully monitored by the physiotherapist. Patients were prescribed non-steroidal anti-inflammatory (NSAID) medication for one month post-operatively in order to minimise the risk of heterotopic ossification. Antibiotic prophylaxis was not routinely used.

We advocate “à-la-carte” arthroscopic hip surgery, i.e. individualised patient care. This calls for high diagnostic accuracy. The identification of the cause of pain is demanding and calls for a careful evaluation of patient history, clinical findings, radiology and intra-surgical findings [144,166]. Although it is not possible to ensure the diagnosis of FAI, by performing a thorough and meticulous diagnostic process, a probable diagnosis can be established in all patients.

05

MIKAEL SANSONE

05. STATISTICAL METHODS

Study I

Statistical analysis was performed using the Statistical Package for the Social Sciences (SPSS) (version 20, 2010 SPSS Inc., Chicago, Illinois, USA). Descriptive statistics were used for patient demographics and scores. Descriptive data are reported as the mean, median, SD and range. The data were not found to be normally distributed and non-parametric statistical testing was therefore employed. The Wilcoxon signed rank test was used to compare the current HSAS level with the level perceived before symptom onset. The level of significance was set at $p < 0.05$.

Study II

Statistical analysis was performed using the Statistical Package for the Social Sciences (SPSS) (version 20, 2010 SPSS Inc., Chicago, Illinois, USA). Descriptive statistics were used for patient demographics. Descriptive data were reported as the mean, median, SD and range. The Wilcoxon signed rank test was used to compare all PROM values used pre-operatively with those obtained at follow-up. The data were not normally distributed and non-parametric statistical testing was therefore employed. We chose two subscores, the HAGOS-Quality of Life (QoL)

subscore and the iHOT-12, to correlate to age, cartilage status and symptom duration.

Age and symptom duration were correlated to the iHOT-12 and HAGOS-QoL using Spearman's rank correlation test. Cartilage status was correlated to the iHOT-12 and HAGOS-QoL using analysis of variance (ANOVA). The level of significance was set at $p < 0.05$.

Study III

Statistical analysis was performed using the Statistical Package for the Social Sciences (SPSS, version 20; IBM Corp). Descriptive statistics were used for patient demographics. Descriptive data were reported as the mean, median, SD and range. The Wilcoxon signed rank test was used to compare all PROM values used pre-operatively with those obtained at follow-up. The data were not normally distributed and non-parametric statistical testing was therefore employed. The level of significance was set at $p < 0.05$.

Study IV

The sample size calculations with an α -value of 0.05, 75 subjects, 10 points as a clinically relevant difference on the iHOT12 score (based on data from a previous study) and a standard deviation (SD) of difference in the response of matched pairs of 21 points give a power of > 90% [66]. Statistical analysis was performed using the Statistical Package for the Social Sciences (SPSS) (version 20, 2010 SPSS Inc., Chicago, Illinois, USA). Descriptive statistics were used for patient demographics. The data were not normally distributed and non-parametric statistical testing was therefore employed. Wilcoxon's signed rank test was used to evaluate differences between PROM values used pre-operatively with those obtained at follow-up. Differences between patients with a progression of Tönnis grade and those without a progression were evaluated with the Mann-Whitney U-test. Differences between patients with 1-2 mm of any joint space and those with three mm or more were evaluated with the Mann-Whitney U-test. Differences in terms of medial, central and lateral joint space from pre-operative to post-operative radiographs were evaluated with the Mann-Whitney U-test. The level of statistical significance was set at $p < 0.05$.

Study V

Statistical analysis was performed using the Statistical Package for the Social Sciences (SPSS) (version 20, 2010 SPSS Inc., Chicago, Illinois, USA). Descriptive statistics were used for patient demographics, subjective scores and objective results. Descriptive data are reported as the mean,

median, SD and range. The data were not considered to be normally distributed and non-parametric statistical testing was therefore employed. The Mann-Whitney U-test was used for continuous variables to compare different groups. For dichotomous variables, the chi-square test (Fisher's exact test) was used for comparisons between groups. The level of significance was set at $p < 0.05$.

Study VI

No statistical methods were applied.

Study VII

No statistical methods were applied.

ETHICS

Ethical approval for the studies was granted by the regional ethical review board in Gothenburg, Sweden (registration numbers 071-12 and 472-10).

06

MIKAEL SANSONE

06. SUMMARY OF PAPERS

Study I

A SWEDISH HIP ARTHROSCOPY REGISTRY: DEMOGRAPHICS AND DEVELOPMENT

INTRODUCTION

Hip arthroscopy is a rapidly expanding field in orthopaedics. Indications and surgical procedures are increasing. Although several studies report favourable clinical outcomes, further scientific evidence is needed for every aspect of this area. Accordingly, a registry for hip arthroscopy was developed. The purpose of this study is to describe the development of the registry and present its baseline data.

METHODS

A Scandinavian expert group agreed to use a set of functional outcome scores for the evaluation of hip arthroscopy patients. They were the international Hip Outcome Tool-12 (iHOT-12), hip and groin outcome score, EQ-5D, hip specific activity level scale (HSAS) and visual analogue scale (VAS) for overall hip function. These scores have been validated and culturally adapted to Swedish. A database was created for web-based, self-administered questionnaires and all patients completed the PROMs mentioned above. Peri-operative data were also collected. Cartilage injury

was recorded and assessed according to the classification of Konan et al. [77].

RESULTS

The process leading to the registry is reported. Baseline data from the first 606 patients collected during a 14-month period are presented. The preferred surgical technique is presented. The mean operation time was 69 (SD 14) minutes. In 333 procedures, mixed cam and pincer pathology were addressed, compared with 223 procedures with the treatment of isolated cam pathology. Outpatient surgery was performed in all patients.

The pre-operative compliance with the web-based questionnaire was 88%.

The most common type of chondral damage was type 2a, constituting a cleavage tear at the chondrolabral junction (35.8%), and type 3a damage, representing type 2 damage with additional delamination of the cartilage (22.2%). In the 324 hips where the acetabular cartilage was classified, a total of 23.8% of the hips had bare bone in the acetabulum, corresponding to type 4 damage.

Table 4. Distribution by type of acetabular cartilage damage according to the classification of Konan et al. (see appendix)

CARTILAGE DAMAGE CLASSIFICATION (KONAN ET AL.)	NUMBER
0	1 (0.3%)
1a	31 (9.6%)
1b	4 (1.2%)
1c	3(0.9%)
2a	116 (35.8%)
2b	N/A (3)
2c	N/A (1)
3a	72 (22.2%)
3b	17 (5.2%)
3c	3 (0.9%)
4a	42 (13%)
4b	22 (6.8%)
4c	13 (4%)
Total	324 (100%)

N/A: Not applicable

Table 5. Patient demographics

DEMOGRAPHICS	TOTAL
Total number of patients	606
Operated side R/L/BILATERAL (%)	38/31/30
Male/female (%)	67/33
Symptom duration	
Median/range	2 / 0.1 - 25
Mean (SD) (years)	3.9 (4.4)
Percentage day surgery (%)	100
Age - mean (SD) (years)	36.6 (13.1)
Operation time - mean (SD) (minutes)	69.2 (14.2)
Traction time - mean (SD) (minutes)	9.9 (8.2)
Joint could not be distracted (%)	8.1

Table 6. Pre-operative mean result for the various PROMs

OUTCOME SCORE	PRE-OPERATIVE VALUE MEAN (SD)
iHOT-12	39 (18)
EQ-5D	0.54 (0.30)
EQ-VAS	65 (20)
HAGOS - pain	54 (19)
HAGOS - symptoms	50 (24)
HAGOS - daily activity	57 (24)
HAGOS - sports	37 (22)
HAGOS - physical activity	26 (26)
HAGOS - quality of life	30 (18)
VAS - overall hip function	48 (21)
HSAS	
Pre-operatively vs before symptom debut (mean (SD))	3.1 (2.4) vs 5.7 (2.0)

CONCLUSION

It is possible to create a local registry for evaluating hip arthroscopy with limited resources. Patients undergoing hip arthroscopy report significant problems with pain, reduced function, reduced activity level and quality of life.

Study II

OUTCOME AFTER HIP ARTHROSCOPY FOR FEMORO-ACETABULAR IMPINGEMENT IN 289 PATIENTS WITH MINIMUM TWO-YEAR FOLLOW-UP

INTRODUCTION

Femoro-acetabular impingement (FAI) is a common cause of hip pain and dysfunction. Arthroscopic treatment is an established treatment method for patients with symptoms of FAI.

Several case series have reported good results for the arthroscopic treatment of FAI; however, older PROMs, often not valid for this patient category, have frequently been used.

The purpose of the present study was to report outcome in a large cohort two years after the arthroscopic treatment of FAI using validated outcome measures adapted for this specific patient category.

METHODS

Two hundred and eighty-nine patients (males=190, females=99, total hips=359) who underwent arthroscopic surgery for FAI were included prospectively and followed prospectively for two years.

The inclusion criterion was arthroscopic surgery for suspected FAI. The number of eligible patients was 394, of which 22 were excluded due to prior hip surgery and 83 did not complete the follow-up.

The indication for surgery was an established diagnosis of FAI and failed non-surgical treatment. Contra-indications included advanced osteoarthritis (OA), with joint space below 2 mm, and severe dysplasia. The diagnosis of FAI was made from patient history, physical examination and radiological findings consistent with FAI of cam type, pincer type or mixed. Per-operative data were registered at the time of surgery. A description of cartilage status was made according to the classification by Konan et al. The number of re-operations, including total hip arthroplasty (THA), was assessed from patient journals and documented.

All the athletes completed self-administered web-based patient-reported outcomes (PROMs), including the International Hip Outcome Tool (iHOT-12), the Copenhagen Hip and Groin Outcome Score (HAGOS, six subscales), the Hip Sports Activity Scale (HSAS), a VAS for overall hip function and a standardised instrument (EQ-5D, two subscales) for use as a measurement of health outcome. Furthermore, the patients reported whether or not they were satisfied with the surgery.

RESULTS

The mean age was 37 years (SD 13). The average time to follow-up was 25 months (SD 2). The average time of symptom duration prior to surgery was 3.8 years (SD 4.2).

Of the included procedures, 149 were isolated cam resections, 201 were cam and pincer combined procedures and nine were isolated pincer resections. The labrum was re-attached in 26 hips and a microfracture was performed in 19 hips.

A comparison of pre-operative scores compared with those obtained at the two-year follow-up revealed statistically and clinically significant improvements ($p < 0.05$) for all measured outcomes; iHOT-12 (43 vs 66), VAS for global hip function (50 vs 71), HSAS (2.9 vs 3.6), EQ5D index (0.58 vs 0.75), EQ VAS (67 vs 75) and HAGOS different subscales (56 vs 76, 51 vs 69, 60 vs 78, 40 vs 65, 29 vs 57, 33 vs 58. Patient satisfaction with surgery was 82%.

Seventeen re-operations (5%) were performed. At follow-up, fourteen patients (4%) had received a THA.

There were reports of chondral damage in 202 of 359 hips (56%). The most common type of cartilage damage was type 2 (34%), followed by type 3a (20%). Twenty-four (12%) hips had bare bone in the acetabulum.

Symptom duration correlated significantly and negatively with the iHOT-12 and HAGOS-QoL, ($r = -0.189$ and -0.209 , $p = 0.012$ and 0.004 respectively).

Table 7. Patient demographics and per-operative data

DEMOGRAPHICS	TOTAL
Total number of patients	289
Total number of hips	359
Operated side R/L/bilateral (%)	42/32/26
Male/female (%)	66/34
Symptom duration	
Median/range/IQR (months)	24/2-252/12-60
Percentage day surgery (%)	100
Age - mean (SD)	37 (13)
Operation time - mean (SD) (minutes)	73 (17)
Traction time - mean (SD) (minutes)	10 (7)
Joint could not be distracted (%)	10%

Table 8. Mean and standard deviation (SD) for the outcome scores for the entire group (n=85) pre-operatively and at the 12-month follow-up

<i>OUTCOME</i>	<i>PRE-OPERATIVE</i>	<i>24 MONTHS</i>	<i>CHANGE (Δ)</i>	<i>P-VALUE</i>
<i>iHOT-12</i> <i>Mean (SD)</i>	43 (17)	66 (27)	23	<0.05
<i>EQ-5D</i> <i>Mean (SD)</i>	0.58 (28)	0.75 (26)	0.17	<0.05
<i>EQ-VAS</i> <i>Mean (SD)</i>	67 (20)	75 (20)	0.08	<0.05
<i>HAGOS - pain</i> <i>Mean (SD)</i>	56 (18)	76 (21)	20	<0.05
<i>HAGOS - symptoms</i> <i>Mean (SD)</i>	51 (19)	69 (22)	18	<0.05
<i>HAGOS - daily activity</i> <i>Mean (SD)</i>	60 (22)	78 (22)	18	<0.05
<i>HAGOS - sports</i> <i>Mean (SD)</i>	40 (20)	65 (29)	25	<0.05
<i>HAGOS - physical activity</i> <i>Mean (SD)</i>	29 (26)	57 (34)	28	<0.05
<i>HAGOS - quality of life</i> <i>Mean (SD)</i>	33 (18)	58 (29)	25	<0.05
<i>VAS - overall hip function</i> <i>Mean (SD)</i>	50 (20)	71 (23)	21	<0.05
<i>HSAS</i> <i>Mean (SD)</i>	2.9 (2.2)	3.6 (2.1)	0.7	<0.05
<i>Satisfied with surgery</i> <i>n (%)</i>	NA	82%	NA	NA

CONCLUSION

Two years after surgery, arthroscopic treatment for FAI resulted in statistically significant and clinically relevant improvements in all outcomes for pain, symptoms, function, physical activity level and quality of life in the majority of patients.

Study III

GOOD RESULTS AFTER HIP ARTHROSCOPY FOR FEMORO-ACETABULAR IMPINGEMENT IN TOP-LEVEL ATHLETES

INTRODUCTION

Femoro-acetabular impingement (FAI) is a common cause of hip pain and dysfunction among athletes. Although arthroscopic surgery is an established treatment option for FAI, there are few studies reporting detailed outcome using validated outcome measures specifically designed for young and active athletes. The purpose of this study was to report outcome one year after the arthroscopic treatment of FAI in top-level athletes using validated outcome measures adapted for a young and active population.

METHODS

Eighty-five top-level athletes (males=68, females=17) with a mean age of 25 years (SD 5) underwent arthroscopic surgery for FAI. All athletes who reported Hip Sports Activity Scale (HSAS) levels 7 or 8 (0-8) and were under the age of 40 prior to symptom onset were included.

Indications for surgery were an established diagnosis of FAI and failed non-surgical treatment. Per-operative data were registered at the time of surgery. A description of cartilage status was made according to the classification by Konan et al.

All the athletes completed self-administered web-based health-related patient-reported outcomes (PROMs), including the iHOT-12, the HAGOS (six subscales), the

HSAS, a VAS for overall hip function and the EQ-5D (two subscales) for use as a measurement of health outcome. Moreover, the athletes reported whether or not they were satisfied with the surgery. All the scores have previously been validated and culturally adapted to Swedish. The questionnaires were completed pre-operatively and 12 months post-operatively.

RESULTS

Of the included procedures, 54 were isolated cam resections and 49 were combined cam and pincer procedures. The average time to follow-up was 12.3 months (SD 0.6). The reported average time of symptom duration prior to surgery was 2.8 years (SD 3.4). The most common sporting activity was football, followed by ice-hockey.

A comparison of pre-operative scores compared with those obtained at the 12-month follow-up revealed statistically significant and clinically relevant improvements ($p < 0.0001$) for all measured outcomes; iHOT-12 (42 vs 73), VAS for global hip function (52 vs 77), HSAS (4.3 vs 5.7), EQ-5D index (0.60 vs 0.83), EQ-VAS (68 vs 82), HAGOS different subscales (60 vs 83, 50 vs 73, 66 vs 86, 39 vs 75, 27 vs 70, 34 vs 67) (Table 10). Figure X shows the change in the iHOT-12 from pre-operatively to post-operatively at individual level. Patient satisfaction with surgery was 93%.

The mean HSAS level improved from 4.3 (SD 2.5) pre-operatively to 5.7 (SD 2.2) at the 12-month follow-up. At follow-up, 62 athletes (73%) had returned to competitive sports (HSAS levels 5-8) and 44 (52%)

to their previous HSAS level of activity (HSAS level 7 or 8). Twenty-three athletes (27%) did not return to competitive sports (HSAS level 4). Significantly lower levels of return to sports were seen with longer symptom duration ($p < 0.05$).

There were reports of chondral damage in 71 of 115 hips (62%).

Table 9. Patient demographics and per-operative data

<i>DEMOGRAPHICS</i>	<i>TOTAL</i>
<i>Total number of patients</i>	85
<i>Total number of hips</i>	115
<i>Operated side R/L/bilateral (%)</i>	33/30/37%
<i>Male/female (%)</i>	82%/18%
<i>Symptom duration Median/range/IQR (months)</i>	24/238/32.5
<i>Percentage day surgery (%)</i>	100%
<i>Age - mean (SD)</i>	25 (5)
<i>Operation time - mean (SD) (minutes)</i>	74 (15)
<i>Traction time - mean (SD) (minutes)</i>	9 (8)
<i>Joint could not be distracted (%)</i>	8

Table 10. Mean and standard deviation (SD) for the outcome scores for the entire group (n=85) pre-operatively and at the 12-month follow-up

<i>OUTCOME</i>	<i>PRE-OPERATIVE</i>	<i>12 MONTHS</i>	<i>CHANGE (Δ)</i>	<i>p-VALUE</i>
<i>iHOT-12</i> <i>Mean (SD)</i>	42 (18)	73 (24)	31	<0.0001
<i>EQ-5D</i> <i>Mean (SD)</i>	0.60 (0.27)	0.83 (0.19)	0.23	<0.0001
<i>EQ-VAS</i> <i>Mean (SD)</i>	68 (19)	82 (15)	14	<0.0001
<i>HAGOS - pain</i> <i>Mean (SD)</i>	60 (18)	83 (17)	23	<0.0001
<i>HAGOS - symptoms</i> <i>Mean (SD)</i>	50 (20)	73 (19)	23	<0.0001
<i>HAGOS - daily activity</i> <i>Mean (SD)</i>	66 (22)	86 (17)	20	<0.0001
<i>HAGOS - sports</i> <i>Mean (SD)</i>	39 (21)	75 (23)	36	<0.0001
<i>HAGOS - physical activity</i> <i>Mean (SD)</i>	27 (28)	70 (30)	43	<0.0001
<i>HAGOS - quality of life</i> <i>Mean (SD)</i>	34 (21)	67 (26)	33	<0.0001
<i>VAS - overall hip function</i> <i>Mean (SD)</i>	52 (21)	77 (21)	25	<0.0001
<i>HSAS</i> <i>Mean (SD)</i>	4.3 (2.5)	5.7 (2.2)	1.4	<0.0001
<i>Satisfied with surgery</i> <i>n (%)</i>	NA	79 (93%)	NA	NA

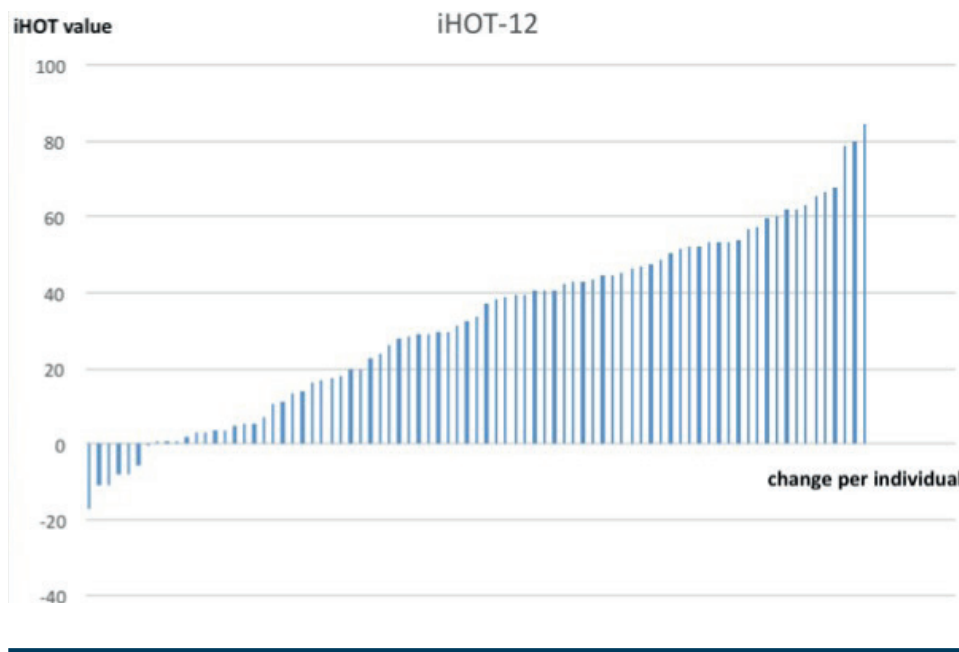


Figure 33. Change per individual on the International Hip Outcome Tool-short version (iHOT-12) between preoperative and 12-month follow-up.

CONCLUSION

Twelve months after surgery, arthroscopic treatment for FAI in top-level athletes resulted in statistically significant and clinically relevant improvements at group level in all outcome parameters for pain, symptoms, function, physical activity level, quality of life and general health. One year after surgery, approximately three out of four top-level athletes had returned to sports.

Study IV

OUTCOME OF HIP ARTHROSCOPY IN PATIENTS WITH MILD TO MODERATE OSTEOARTHRITIS - A PROSPECTIVE STUDY

INTRODUCTION

Osteoarthritis (OA) of the hip is a common

cause of hip pain. The arthroscopic management of patients with femoro-acetabular impingement (FAI) has been reported to yield good outcomes. Femoro-acetabular impingement (FAI) has been regarded as a causal factor in the development of hip osteoarthritis (OA). Only a few studies have specifically evaluated patients with FAI and OA. The purpose of this study was to report on outcome following the arthroscopic treatment of patients with FAI in the presence of mild to moderate OA.

METHODS

Seventy-five patients (80 hips, males, n=59, females, n=16) undergoing arthroscopic surgery for FAI, all with pre-operative radiological signs of mild to moderate OA, were prospectively included in this study.

A two-year follow-up, using web-based patient-reported outcome measures, including the iHOT-12, HAGOS, EQ-5D, HSAS for physical activity level, satisfaction with surgery and a VAS for overall hip function, was performed. A radiographic evaluation using Tönnis grade, alpha angle and measurements of joint space was performed by an independent radiologist one year post-operatively.

The inclusion criterion was FAI with concomitant signs of OA, defined as Tönnis grade 1 or 2. The exclusion criteria were re-operation (n=10), non-FAI cases (n=2) and diabetes (n=1). All procedures were performed in an out-patient setting.

Indications for surgery were a clinical and radiological diagnosis of FAI and failed non-surgical treatment. Per-operative data were registered at the time of surgery. The number of re-operations and post-operative THA were recorded.

RESULTS

The patients' mean age was 47 years (SD 10). The first follow-up was made at an average of 12.8 months (SD 1.7), including radiographs, where all 71 available patients responded (four had undergone THA). The second follow-up was made at an average of 26 months (SD 5), where 68 patients responded (97%) and, at this time point, a total of five patients had undergone THA. The mean symptom duration prior to surgery was 5.8 years (SD 5.7).

Of the included procedures, 28 were isolated cam resections and 57 were combined cam and pincer resections. The labrum was sutured in six hips and a microfracture was performed in four hips.

A comparison of pre-operative scores compared with those obtained at the 24-month follow-up revealed improvements ($p < 0.0001$) for all measured outcomes; the iHOT-12 (42 vs 65), VAS for global hip function (48 vs 68), HSAS (2.5 vs 3), EQ5D index (0.62 vs 0.76), EQ VAS (69 vs 75) and different HAGOS subscales (54 vs 72, 47 vs 67, 56 vs 75, 40 vs 61, 33 vs 56, 31 vs 55) (Table 13). Patient satisfaction with surgery was 82%.

Ten re-operations (13%), of which one was a fascia lata release, were performed during follow-up. The mean alpha angle pre-operatively was 74 degrees (SD 12), as compared with 46 (SD 9) degrees post-operatively ($p < 0.05$).

At follow-up, the PROMs did not differ significantly in patients with any joint space of 1-2 mm compared with those with any joint space of 3+ mm.

At follow-up, when comparing medial, central and lateral joint space, only the lateral space decreased to a statistically significant degree ($p < 0.05$) from a mean of 3.6 mm (SD 1.2, median 4, range 1-6) to 3.2 mm (SD 1.3, median 4, range 0-6). There were no significant differences in PROM results in terms of Tönnis grade progression vs no progression (n=10, 13% vs n=75, 87%).

Table 11. Patient demographics and per-operative data

DEMOGRAPHICS	TOTAL
Total number of patients	75
Total number of hips	80
Operated side R/L/bilateral (%)	40/53/7
Male/female (%)	77/23
Symptom duration Median/range/IQR (months)	48/6- 252/78
Percentage day surgery (%)	100
Age - mean (SD) (years)	47 (10)
Operation time - mean (SD) (minutes)	77 (18)
Traction time - mean (SD) (minutes)	11 (8)
Joint could not be distracted (%)	13

Table 12. Radiographic evaluation

MEASUREMENT	PRE- OP	12 MO POST- OP
Alpha angle (degrees)	74 (SD 12)	46 (SD 9)
CE angle (SD) degrees	32 (7)	NA
Tönnis grade 1 (no)	48	41
Tönnis grade 2 (no)	31	34
Tönnis grade 3 (no)	0	1
Tönnis progression grade 1 to 2	NA	7
Tönnis progression grade 2 to 3	NA	2
Tönnis progression grade 1 to 3	NA	1
Any joint space of 1 (mm)	3	10
Any joint space of 2 (mm)	17	14
Any joint space of 3+ (mm)	57	52

Table 13. Mean and standard deviation (SD) for the outcome scores for the entire group pre-operatively and at the 12/24-month follow-up

<i>OUTCOME</i>	<i>PRE-OPERATIVE (N=75)</i>	<i>12 MONTHS (N=71)</i>	<i>CHANGE (Δ)</i>	<i>24 MONTHS (N=68)</i>	<i>CHANGE (Δ)</i>	<i>P-VALUE</i>
<i>iHOT-12</i> <i>Mean (SD)</i>	42 (18)	61 (25)	19	65 (27)	23	<0.0001
<i>EQ-5D</i> <i>Mean (SD)</i>	0.62 (25)	77(15)	0.13	0.76 (23)	0.14	<0.0001
<i>EQ-VAS</i> <i>Mean (SD)</i>	69 (15)	76 (17)	7	75 (20)	6	<0.001
<i>HAGOS - pain</i> <i>Mean (SD)</i>	54 (19)	72 (18)	18	72 (22)	18	<0.0001
<i>HAGOS - symptoms</i> <i>Mean (SD)</i>	47 (19)	66 (17)	19	67 (23)	20	<0.0001
<i>HAGOS - daily activity</i> <i>Mean (SD)</i>	56 (23)	75 (19)	19	75 (23)	19	<0.0001
<i>HAGOS - sports</i> <i>Mean (SD)</i>	40 (21)	58 (26)	18	61 (30)	21	<0.0001
<i>HAGOS - physical activity</i> <i>Mean (SD)</i>	33 (26)	52 (34)	19	56 (33)	23	<0.0001
<i>HAGOS - quality of life</i> <i>Mean (SD)</i>	31 (16)	54 (25)	23	55 (28)	24	<0.0001
<i>VAS - overall hip function</i> <i>Mean (SD)</i>	48 (21)	67 (22)	19	68 (25)	20	<0.0001
<i>HSAS</i> <i>Mean (SD)</i>	2.5 (2.2)	3.1 (1.8)	0.6	3 (1.6)	0.5	<0.005
<i>Satisfied with surgery n (%)</i>	NA	83 (%)	NA	82%	NA	NA
<i>Undergone THA</i>	NA	4 (5%)	NA	5 (7%)	NA	NA

CONCLUSION

Arthroscopic treatment for FAI in patients with concomitant mild to moderate OA resulted in statistically significant and clinically relevant improvements in all outcomes for pain, symptoms, function, physical activity level and quality of

life. Five of 75 (7%) patients had undergone or were planned for a THA at the two-year follow-up. A longer follow-up is needed for this cohort due to the nature of OA.

Study V

CAN HIP IMPINGEMENT BE MISTAKEN FOR TENDON PAIN IN THE GROIN? A LONG-TERM FOLLOW-UP OF TENOTOMY FOR GROIN PAIN IN ATHLETES

INTRODUCTION

Chronic tendon pain in the adductor longus and rectus abdominis, with pain and impaired function, is common among athletes. Tenotomy on one or both of these tendons has commonly been performed and has been considered to be a valid treatment option. In recent years, the focus has turned towards femoro-acetabular impingement (FAI) as a common cause of groin pain in athletes. The purpose of this study was to evaluate the long-term outcome in athletes who underwent tenotomy due to long-standing groin pain. A secondary purpose was to evaluate the frequency of femoro-acetabular impingement (FAI) and its impact on the long-term outcome.

METHODS

Between 1998 and 2010, 46 high-level male athletes with chronic groin pain underwent tenotomy of either the adductor longus and/or rectus abdominis following the failure of conservative treatment. The indications for surgery were long-standing groin pain and the inability to participate in sport because of pain over the adductor origin and/or the pubic attachment of the rectus abdominis.

The median age at follow-up was 30 years (range 21-56) and the median time from surgery to follow-up was six years (range 1-25).

Thirty-two of the 46 patients were available for follow-up. All the athletes were examined with regard to the hip impingement tests. At follow-up, a standard pelvic radiograph with an AP view and a modified Dunn's view was performed on all the athletes in order to measure the alpha angle.

All the athletes completed self-administered web-based patient-reported outcomes (PROMs), including the iHOT12, the HAGOS, the HSAS, a VAS for overall hip function, the EQ5D, patient satisfaction and return to pre-injury sport.

RESULTS

Of 32 athletes, 24 were satisfied with the functional outcome. Twenty-three athletes were able to return to their pre-injury sport.

Of the 24 athletes who were satisfied with the functional result, eight had positive impingement tests (33%) and 22 athletes were able to return to their pre-injury sports activity.

Of the eight athletes who were not satisfied with the functional outcome, five had positive impingement tests and only one returned to his/her pre-injury sports activity level. Three had undergone hip arthroscopy with resection of a cam lesion.

In the entire group, 15 athletes had positive impingement tests. Fourteen of them had an alpha angle of more than 50 degrees (93%). The group with positive impingement tests obtained significantly lower results in five of the 11 measured

scores ($p=0.019 - 0.04$). The non-satisfied group had a positive impingement test significantly more frequently compared with the satisfied group ($p=0.008$).

The mean alpha angle for the entire group was 63.3 degrees (SD 11.9). There were no significant differences in the alpha angle between the satisfied and the non-satisfied groups.

Table 14 - Mean and standard deviation (SD) for the outcome scores for the entire group (n=32) relating to athletes with a negative hip impingement test at follow-up (n=27) and athletes with a positive hip impingement test at follow-up (n=15)

Frequency (n) and per cent (%) are shown for athletes who were satisfied with surgery and athletes who returned to sport after surgery.

OUTCOME	TOTAL (N=32)	NEGATIVE HIP IMPINGEMENT TEST (N=17)	POSITIVE HIP IMPINGEMENT TEST (N=15)	P-VALUE
iHOT12 Mean (SD)	81 (20.7)	84.9 (15.9)	77.2 (25.1)	n.s
EQ-5D Mean (SD)	86 (15.1)	86.9 (10.5)	85.6 (19.8)	n.s
EQ-VAS Mean (SD)	83 (15.0)	85 (12)	81 (18)	n.s
HAGOS - pain Mean (SD)	86 (15.9)	91.9 (10.5)	79.5 (18.7)	0.03
HAGOS - symptoms Mean (SD)	80 (17.9)	86.1 (12.2)	72.3 (20.8)	0.04
HAGOS - daily activity Mean (SD)	88 (15.2)	93.2 (9.8)	83 (18.5)	0.06
HAGOS - sports Mean (SD)	78 (22.5)	85.1 (17.6)	69.7 (25.3)	0.04
HAGOS - physical activity Mean (SD)	67 (31.2)	76.6 (31.1)	56.7 (28.7)	0.03
HAGOS - quality of life Mean (SD)	73 (24.8)	83.1 (20.0)	62.3 (25.6)	0.02
VAS - overall hip function Mean (SD)	82 (15.0)	84.2 (10.5)	80 (19.1)	n.s
HSAS Mean (SD)	4.6 (2.3)	4.8 (2.7)	4.5 (1.9)	n.s
Satisfied with surgery n (%)	24 (75%)	16* (94%)	8* (53%)	NA
Not satisfied with surgery n (%)	8 (25%)	0* (0%)	8* (100%)	NA
Return to sports n (%)	23 (72%)	15 (88%)	8 (53%)	n.s

* Significant difference between satisfied and non-satisfied groups, $p=0.01$

NA: Not applicable

CONCLUSION

Tenotomy for pubalgia yielded a satisfactory long-term outcome, with three out of four athletes being able to return to their pre-in-

jury sport. The athletes that did not return to their pre-injury sport had a higher frequency of positive hip impingement tests.

Study VI

TOTAL DISLOCATION OF THE HIP JOINT AFTER ARTHROSCOPY AND ILEOPOAS TENOTOMY

INTRODUCTION

The hip is a highly stable joint. Non-traumatic dislocation of the hip is extremely uncommon. In this article, we report on two cases of non-traumatic hip dislocations following hip arthroscopy. In both patients, capsulotomy and ileopsoas tenotomy had been performed. These cases raise questions about the importance of the natural stabilisers of the hip.

CASE REPORT

This article reports on two similar cases, both operated on at institutions other than ours.

Both patients were 26 years old, one male and one female. They suffered from unilateral hip pain, which was diagnosed as cam impingement. There was no record of hyperlaxity of the joint and the CE angle was 38 and 37 degrees.

In both patients, cam resection and ileopsoas tenotomy (at the level of the hip joint) were performed. No acetabular rim resection was performed in either case. A large capsulotomy was reported in one of the cases. No excessive traction time was reported.

In both cases, approximately three months post-operatively, the operated hips dislocated. No excessive trauma was involved in the dislocations. One patient turned and ran and the other threw a

javelin, both externally rotating the hip, which appears to have precipitated the dislocations.

In both cases, reduction under general anaesthesia was successful and no further dislocations have been recorded.

CONCLUSION

Hip dislocation is a potential complication after hip arthroscopy and psoas tenotomy. These two cases highlight the importance of careful patient selection and the fact that meticulous handling of soft tissues is warranted, especially in cases with predisposing factors for hip instability.

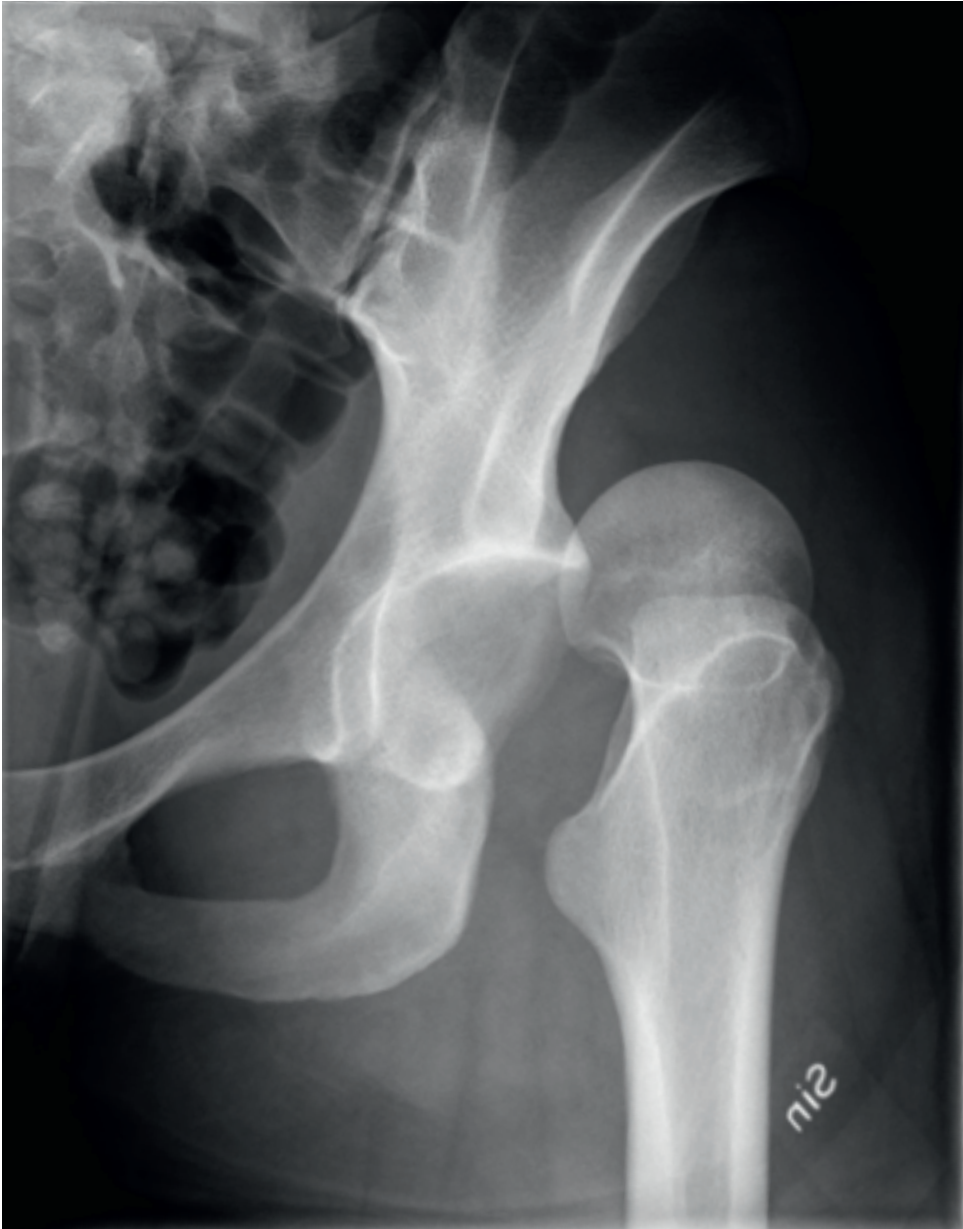

Figure 34. *Left hip dislocation 3 months postoperatively after hip arthroscopy and iliopsoas tenotomy.*

Study VII

FEMORO-ACETABULAR IMPINGEMENT
CLINICAL RESEARCH: IS A COMPOSITE
OUTCOME THE ANSWER?

INTRODUCTION

Femoro-acetabular impingement (FAI) is increasingly recognised as an important cause of hip pain in the young adult. However, the methods for evaluating the efficacy of surgical intervention are often not validated and are inconsistently reported. Important clinical, gait, radiographic and biomarker outcomes are discussed. This article presents the rationale for considering a composite outcome for FAI patients and examines a variety of important endpoints currently used to evaluate FAI surgery, such as clinical outcomes, gait, radiographic and biomarker outcomes.

OUTCOMES

CLINICAL OUTCOMES

The most common scores in FAI research, such as the HHS, NAHS, ROM and pain scores, have low validity. Newer PROMs, such as the iHOT12/33, the HAGOS and the HSAS, have recently been developed to better describe the outcome after surgery for FAI. Even though valid PROMs express patients' sentiments on the outcome of their treatment, they do not always mirror all patient categories but are affected by factors such as patient expectations and do not include complications. Accordingly, a composite outcome in which PROMs are a part may improve research in this area.

GAIT AND KINEMATIC OUTCOMES

Evaluating both pelvic and gait kinematics to assess post-operative efficacy appears relevant, given the FAI osseous morphology and its mechanical nature. There are studies indicating that statistically significant kinematic improvements can be achieved after FAI surgery, most noticeably in terms of hip flexion. Connecting the outcomes of FAI surgery to structural changes may help us to better understand the mechanics of this treatment.

RADIOGRAPHIC OUTCOMES

Diagnostic imaging plays a major role in outcome assessment after corrective surgery for FAI. The alpha angle remains the most validated imaging parameter for assessing cam-type FAI. However, more radiographic parameters of FAI need to be investigated and in greater detail.

Moreover, the connection between FAI, cartilage deterioration and the development of osteoarthritis makes cartilage-mapping techniques, such as dGEMRIC, interesting for evaluating FAI treatment.

BIOMARKERS

There is an interest in establishing a link between mechanical hip impingement and accelerated articular damage, with increasing efforts focusing on defining a characteristic serum and/or synovial “molecular signature” for patients with FAI. Using biomarkers, we may be able to quantify surgical efficacy and elucidate the connection between FAI and the development of FAI.

GENERAL

There are several important FAI-related outcomes, each with its pros and cons. The appeal of using composite outcomes is that they capture more study end-points, especially when they are rare, and subsequently reduce the sample size needed for a proposed level of statistical power. However, several problems, such as cost and the interpretation of the results, must be further investigated before a composite outcome can be readily used in FAI research.

CONCLUSION

A composite outcome of patient-related and important end-points may be a useful way to obtain comprehensive information about the efficacy of FAI surgery. Input from both patients and clinicians will be most important to ensure that a comprehensive and inclusive approach is generated.

07

MIKAEL SANSONE

07. STRENGTHS AND LIMITATIONS

The weaknesses of Studies II, III, IV and V include the non-randomised study design, lack of control group and the short time to follow-up. On the other hand, prospective register studies describe the outcome without some types of selection bias, which increases the external validity of the results. The prospective study design does not answer the question of whether arthroscopic treatment is better than placebo, but it does tell us in a valid manner whether or not the patients we are treating improve with this treatment. A well-designed and well-conducted RCT minimises bias in answering the question of whether a certain treatment is better than placebo, but mainly in the setting where the actual trial takes place. The results of an RCT of this kind may not be valid for another setting, with different patient cohorts, surgical technique and post-operative rehabilitation. To answer the question of whether a certain treatment is better than placebo, a well-designed and well-conducted RCT is the study design of choice. However, the results of a prospective study design may be more interesting to a patient undergoing a procedure at the actual institution under the same circumstances as in the study. So RCTs and prospective studies complement one another and both are

needed in the scientific evaluation of surgical procedures. Moreover, the quality of studies must be assessed, such as with the consort criteria for RCTs [33].

Three RCTs evaluating the arthroscopic treatment of FAI are currently ongoing [116,102,34]. One difficulty these studies have encountered is that other effective or proven treatment options to randomise against are lacking. Other than surgical treatment, there have been very few other publications on alternative treatments. In a review by Harris et al. in 2013, including one trial that prospectively evaluated patients with FAI after non-surgical treatment, patients improved in terms of functional outcome [42].

Study I

The strengths of Study I were the large number of patients that were included and the fact that the reporting of the results was performed by the patients (PROMs). Moreover, the PROMs were carefully selected and must be regarded as valid for this patient category. A first-hand account of the process of building a hip arthroscopy registry can be conveyed. The strengths are the high compliance rate (89%) and the high level of inclusion in the registry, as most patients can

be included. The major limitations are that no comparisons are made with other registries or patient categories. Moreover, the cohort that was studied was heterogeneous, consisting of several different underlying diagnoses, mainly FAI, but also other conditions. Moreover, diagnostic hip arthroscopies have been performed where the diagnosis remains unclear. There were also problems with the reporting of cartilage damage with a somewhat small number of recordings. Study I was one of the first to use the then newly developed iHOT-12 and HAGOS scores, which have been found to be valid for this patient category [66,163].

Study II

The main strengths of Study II are the large number of included patients and the use of modern validated outcome measures, such as the iHOT-12, HAGOS, EQ-5D, HSAS for physical activity level, satisfaction with surgery and the VAS for overall hip function, adapted for a young and active population. Further strengths are the multitude of outcome measures covering many aspects. The non-randomised study design and lack of control group are limitations in Study II. On the other hand, its prospective design, based on a registry, increases the external validity of the results. Further limitations are the limited frequency of reporting chondral damage and that the method for determining whether a THA had been performed was incomplete.

Study III

The main strength of Study III is the use of a multitude of modern validated out-

come measures adapted to and thus valid in this young and active population. A further strength is the relatively large number of top-level athletes included. The limitations include the non-randomised study design and the lack of a control group. On the other hand, its prospective design, based on the large registry cohort, increases the external validity of the results. Further limitations are the short time to follow-up and difficulty interpreting return to sports.

Study IV

The main strength of Study IV is the use of a multitude of modern validated outcome measures. Another strength is the prospective collection of a relatively large number of patients with FAI and concomitant mild to moderate OA, as previous similar studies often include a mixed cohort of which only a part had OA.

The limitations of this study are the non-randomised study design and the lack of a control group. However, its prospective design, based on a large cohort, increases the external validity of the results. The time to follow-up, even if adequate for most studies, could be regarded as short, as these patients all had OA. A longer follow-up would therefore be of interest in this cohort, as OA can progress and affect the long-term results. Moreover, the number of patients included may be too limited for sub-group analyses. Lastly, inherent problems related to radiology and the interpretation of OA may affect the results, as the radiological evaluation of OA has its limitations.

Study V

The main strength of Study V is the long follow-up and the use of a multitude of modern validated outcome measures adapted for a young and active population. The main limitations are the limited number of athletes included, the retrospective design and the fact that patients were lost to follow-up. Another limitation is that FAI was only measured using the clinical impingement tests and a radiographic measurement of the alpha angle. Equating a positive impingement test and alpha angle to FAI has its limitations, as FAI is a complex diagnosis.

Study VI

Study VI is a case report of two cases, which limits the opportunity to draw general conclusions. However, the reported complication is very rare and the close relationship between the hip dislocation and the performed surgery warrants reflection.

Study VII

Study VII is an expert opinion, with its inherent limitations in terms of design, which describes various outcome measures for evaluating FAI and the use of composite outcomes to evaluate this patient category.

08

MIKAEL SANSONE

08. DISCUSSION

8.1 INTRODUCTION AND EVALUATION OF NEW METHODS

When a new surgical method is introduced, it is necessary to evaluate as many aspects of the procedure as possible. These aspects include the effectiveness of the new method as perceived by both clinicians and patients, complications, learning curve and health economics.

There are several ways to evaluate a surgical procedure and they all have their pros and cons.

Well-designed and well-conducted RCTs are regarded as strong evidence in showing the effectiveness of an intervention, as the randomisation minimises confounding factors. However, RCTs are difficult, time consuming and costly to perform. Moreover, RCTs show the effect of a certain procedure under the specific circumstances that exist when the trial is performed. The RCT may not be as valid if country, surgeon, technique or indications are changed. This is important for the interpretation of the results of an RCT for colleagues in other countries to decide whether or not they should apply a technique. Moreover, since a surgical technique will probably evolve, the RCT loses its validity over time. Ross et al. recently investigated the willingness of high-volume hip arthroscopists to participate in RCTs for the treatment of FAI [130]. Surgeons were generally willing to participate, but they were reluctant to offer surgical treatment to patients with FAI without the correction of osseous deformity, particularly for cam-type pathomorphology. This highlights the inherent problems these issues have. After a period of development of a technique, it is either discarded or found to be effective by

surgeons and the medical community. At this stage, it is important to perform RCTs to produce evidence of the effectiveness of the procedure. However, when surgeons believe they have an effective treatment for a certain condition, they may be reluctant to offer a placebo treatment or no treatment for patients with considerable symptoms seeking treatment. The reasons could be that the surgeon feels it is unethical to offer a treatment option that he or she does not actually believe in. This “Catch 22” situation is an obstacle to the scientific development of new surgical methods. On the other hand, it could be considered unethical to establish a new procedure without a well-designed, well-conducted RCT or with a registry study of large cohorts followed over time with validated outcome measures.

Prospective observational studies, such as register studies, have several advantages. It is possible to collect a large amount of data on the patients and follow them longitudinally. This enables researchers to analyse patient factors associated with outcomes, subgroups and poor procedures in order to change or exclude poor prognostic factors at an early stage. The positive or negative effects of changes in treatment can be evaluated. Events with a low prevalence can be studied more effectively, as RCTs may not be adequately powered for this purpose. Selection bias can be low if the registry has a high compliance level and information or recall bias is minimised as registry PROM data are prospectively collected. Registry studies thus have high validity in terms of the effectiveness of the outcome of a certain procedure, especially for the patients in-

cluded in the registry. Every change in circumstances in a registry could diminish the validity for patients in other countries or clinics.

Study I shows that it is possible to create a hip arthroscopy registry with limited resources, using modern, validated outcome measures, and with high compliance. It was possible to collect data on 606 patients in a relatively short time frame, which has to be considered important for a procedure of relative infrequency. Studies II, III and IV show that this registry enables the evaluation of groups or subgroups of patients. The outcome of these studies must be regarded as valid and representative regarding the outcome for Swedish patients treated arthroscopically for FAI with the surgical technique used at this centre.

Registry studies can be seen as an important piece in the puzzle when it comes to evaluating the effectiveness of a new method. To complete this puzzle, many pieces are needed. In the case of hip arthroscopy, RCTs, registry studies, biomechanical studies, qualitative studies and studies of health economics are needed, among others. When more pieces have been identified, new methods can be accepted, discarded or modified. A step-wise introduction can eliminate failures associated with new technology or techniques. Performing RCTs on new, not fully developed methods may underestimate their potential. The design of observational studies is not intended to determine causation but longitudinally to evaluate procedures and provide evidence-based monitoring of these procedures.

“Registry studies can be seen as an important piece in the puzzle to evaluate the effectiveness of a new method. To complete this puzzle, many pieces are needed.”

8.2 PROMS IN HIP RESEARCH

The selection and use of valid and reliable outcome measures is of the utmost importance when performing a clinical study. Early orthopaedic research was based on either surgeon-based outcome or measurements of radiographic, biomechanical studies or patients. PROMs have been used more frequently in the last few decades and are now the basis of many studies. PROMs provide information on pain, disability and function from the patient's perspective. PROMs can be chosen to mirror many aspects of the outcomes of the intervention that is going to be studied. PROMs that measure the most important aspects of an intervention can be chosen, or several PROMs can be combined. For example, a score that evaluates activities of daily life used to evaluate athletes undergoing an intervention to regain function in sports may show a good outcome, which is of course important information. However, this may be of little importance to the athlete who most of all wants to regain function in his/her sport and, for this reason, return to sports or function in sports must be measured to evaluate the intervention

more adequately. Quality of life (QoL) scores can be used to measure several combined aspects of outcome that the patients “summarise” to produce a general outcome. In the case above, if the athlete has a poor outcome, this may be reflected in a QoL score, but perhaps not always. So general scores may not cover all the aspects of the outcome. In order to evaluate as many aspects of an outcome as possible, several PROMs can be chosen, as in the studies in the present thesis. This provides an opportunity to evaluate the outcomes perceived as the most important for the observed patient category. However, there is a limit to the number of items that can be presented to a patient, as too many or too difficult items can induce fatigue and reduce compliance and the quality of the patients' answers.

In order to achieve the benefits mentioned above in terms of PROMs, it is important that PROMs are designed in an appropriate, scientific manner to achieve high validity and reliability.

Some of the PROMs in this thesis may be subject to ceiling effects. This phenomenon occurs when a large proportion of subjects in a study have maximum scores for the observed variable. This makes discrimination among subjects at the top end of the scale impossible. The EQ-5D and HAGOS ADL may be subject to ceiling effects, as the nature of FAI, especially among athletes, is associated with physical activity. If patients maintain a low physical activity level and avoid sports, the symptoms may be minor. These patients may obtain high scores for ADL, but, on the other hand, they may obtain low scores for sports-related items. Another problem is high-level athletes who have a high functional level but not high enough to be able to participate at elite level, for example, professionals. They may score 90 out of 100 and still be in need of surgery,

as their functional level is not good enough to perform their sport. A 10-point post-operative increment in these patients may be a good result to them but not significantly different. These effects may be mirrored in the results of Studies II, II and IV, where increments in PROMs from pre- to post-operative are higher in sports-related PROMs and lower on the EQ-5D. Having several PROMs to evaluate a patient category is therefore beneficial. However, the EQ-5D has the benefit of allowing comparisons between different studies and patient categories, as this score has been so commonly used in previous scientific work.

8.3 PROMS IN ARTHROSCOPIC SURGERY FOR FEMORO-ACETABULAR IMPINGEMENT

In early studies of hip arthroscopy, the modified Harris Hip Score (mHHS) was the most commonly used score. The mHHS has, however, low validity for the patient characteristics of hip arthroscopy. Over time, the need for more valid PROMs has led to the development of the NAHS, HOS, HAGOS and iHOT-33 and iHOT-12. These new PROMs are specifically designed for research on patients without hip OA and for patients undergoing hip arthroscopy. However, no single PROM can be expected to cover all the aspects of outcome after hip arthroscopy. The use of multiple PROMs covers a wider array of aspects of the outcome after hip arthroscopy. Looking ahead, we hope that the optimal PROMs for this patient category will be found, either existing or new PROMs. If these can be identified, and more researchers

use these PROMs, the results worldwide can be evaluated and compared. This opens the door to the use of worldwide registries and databases. This development has already begun, in the Surgical Outcome System (SOS), for example, which is a global, web-based registry. There are, however, still problems that remain unresolved. The evaluation of return to sports is suboptimal, not only in hip research but also in most fields of sports traumatology. In this field, it may also be beneficial to combine classic PROMs, such as the Tegner scale, with others, such as measures of training or competition time or performance. These measures may not even be patient reported, in order to reduce patient-related bias.

One important question in PROM evaluation is how important or valid a certain change in a PROM is. We have compared these results with the minimally important change and smallest detectable change in the used scores, where these were available. For the iHOT-12 and HAGOS scores, the smallest detectable changes have been found to be 3.6 and 2.2 points respectively, in this group of patients. Moreover, minimally important changes have been shown to be 8.9 points for the iHOT-12 and 9 to 17 points for the HAGOS subscales. The reported changes with regard to PROMs in Studies II, III and IV are often around 20-40. Is this a valid or important change? These increments in terms of PROMs in Studies II, III and IV exceed the MIC and SDC for the iHOT-12 and the six HAGOS subscales and should thus be considered valid and clinically relevant. Despite this, it can be discussed whether the end PROM level, 65 points in terms of the iHOT-12 and 55-75 points in terms of HAGOS subscales, is a good result, even if significant improvements were reported. Unfortunately, there are few data that describe the normal values for this population.

“However, no single PROM can be expected to cover all the aspects of outcome after hip arthroscopy.”

8.4 PROMS IN THIS THESIS

The PROMs used in Studies I, II, III, IV and V were selected during a pan-Scandinavian expert meeting on hip arthroscopy. It was agreed that there is a benefit in using the same PROMs to evaluate hip arthroscopy to be able to compare results and perform multi-centre, multi-national studies. The included PROMs (HAGOS, iHOT-12, HSAS, EQ-5D, EQ-VAS, VAS of overall function and satisfaction) were selected to cover a wide array of outcome, such as pain, function, QoL, ADL, sports participation and level. The number of items was felt to be adequate, but the iHOT-12 was chosen instead of the iHOT-33 in order to avoid too many items. Several of these PROMs are new, such as the iHOT-12 and the HAGOS, but they were designed specifically for the patient category. Others, such as the EQ-5D and EQ-VAS, mirror general QoL and health. In the case in which all the used PROMs show improvements after a certain procedure, this is a strong indicator of a positive outcome.

8.5 FAI

FAI is a theoretical and clinical concept with strong emerging support in the form of

biomechanical, radiographic, pathological, epidemiological and clinical research. However, it is still a condition that can be difficult to diagnose and treat. The connection between FAI and cartilage damage or OA is an important factor to consider. The fact that FAI is common among asymptomatic individuals, even athletes, can be confusing. This phenomenon is, however, not uncommon in general orthopaedics and may be multifactorial. Factors such as the amount of cartilage damage, neural transmission and sensitivity, pain threshold, genetic factors, cartilage properties and strength and alignment or other biomechanical issues may have an effect. Many of these factors are currently unknown or researchers are unable to measure them. Many of the factors behind the development of OA are, however, still unknown. Furthermore, the way a hip with biomechanical FAI is used or exposed may affect the development of joint damage and/or symptoms. Athletes in certain sports, such as ice-hockey (especially goal-keepers), football players or martial arts fighters are more at risk than others due to higher degrees of flexion patterns in these sports [131]. Similarly, in some sports, such as dancing, athletes can present with FAI-like symptoms in the absence of radiographic changes. This could be attributed to the extreme ranges of movement into which these hips are forced, eliciting FAI-like cartilage damage even without skeletal abnormalities [76,27]. Future research should focus on the activities that can induce FAI-related joint damage and on identifying preventive strategies in FAI. Prevention could be applied both in the case of patients with manifest FAI or to active adolescents in order to prevent the formation of FAI-inducing deformities such as cam [4,141,140].

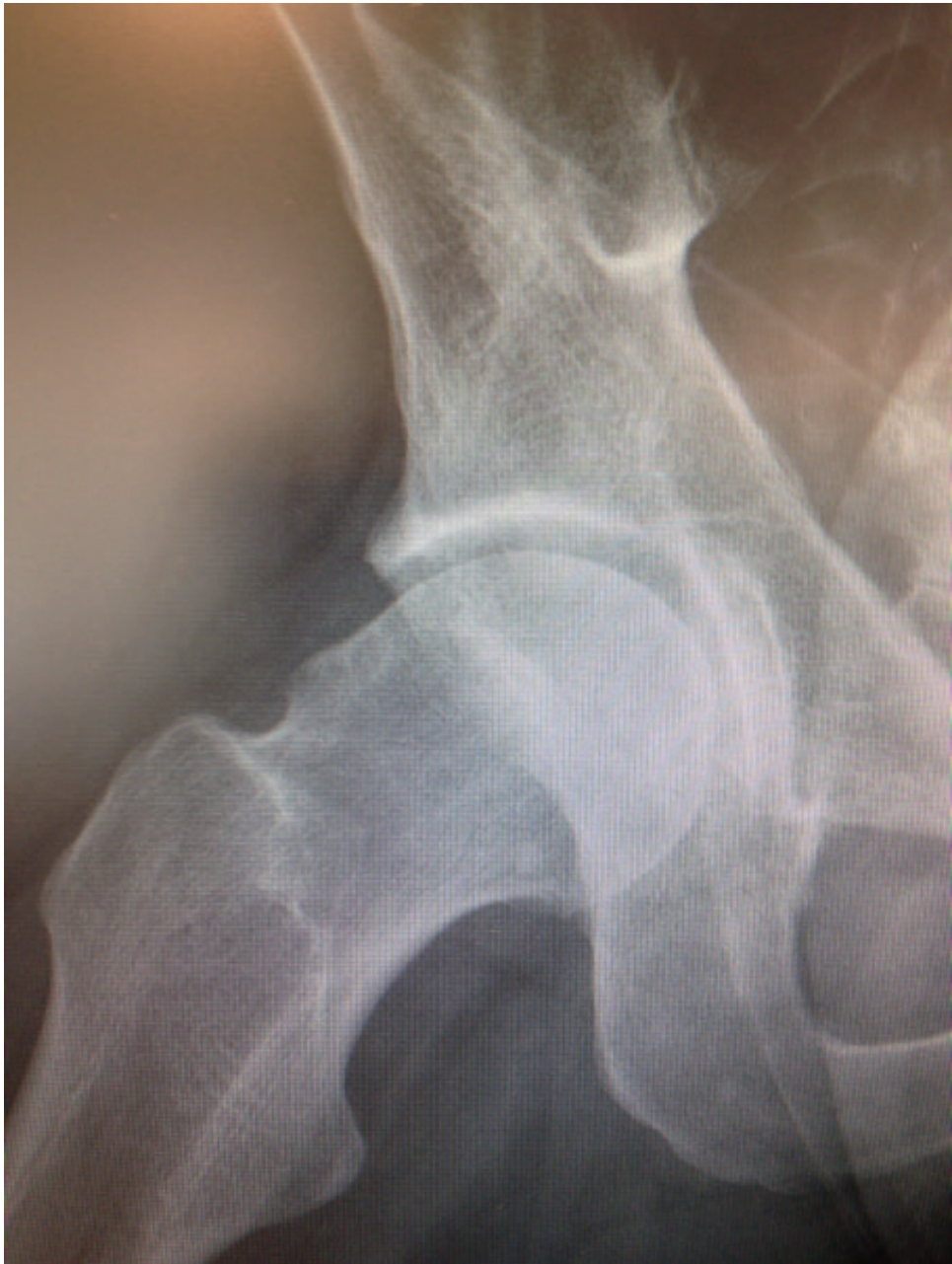

Figure 35a. *Pre-operative images of large cam deformity*

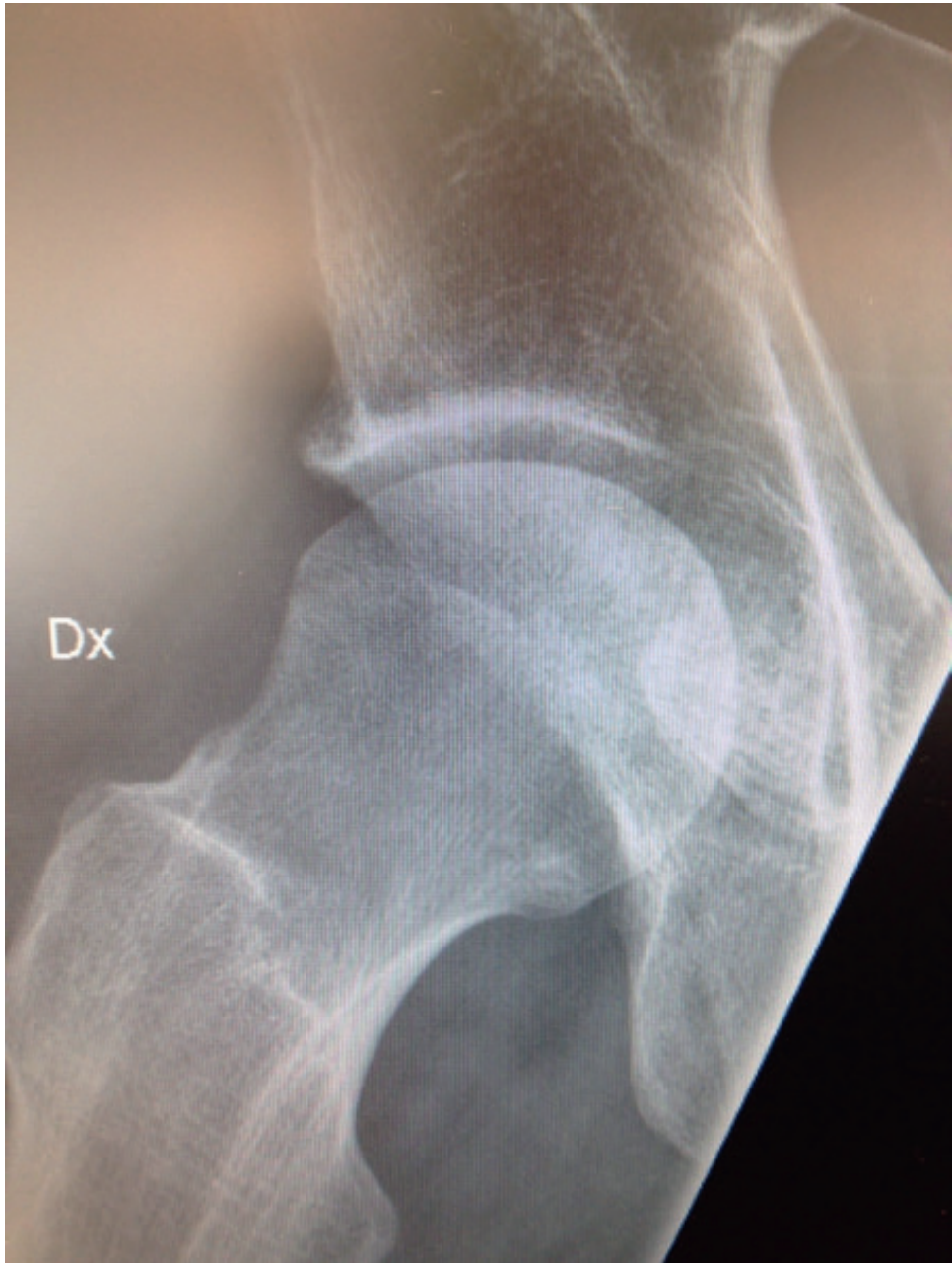

Figure 35b. *Post-operative image after cam resection in (a)*

In Study II, the results following the arthroscopic treatment of FAI were evaluated prospectively in a mixed cohort of patients with a two-year follow-up. The most important finding in Study II was that the outcome after the arthroscopic treatment of FAI in this cohort was favourable, with statistically significant and clinically relevant improvements in all outcome measures.

Most pre-operative values in Study II, such as the iHOT-12, HAGOS sports and HAGOS physical activity scores, were low, indicating disabling degrees of symptoms and major disabilities in the studied cohort pre-operatively.

In Study II, a long symptom duration was correlated to inferior outcome as measured by the iHOT-12 and HAGOS QoL. No correlation was seen between age, cartilage status and outcome. These last findings can be regarded as unexpected, as higher age is connected to a higher degree of OA. Other studies have shown a correlation between OA and inferior results [39]. However, this could be explained by the different baseline values of these groups. It could be that patients experience a similar benefit from the treatment of FAI, regardless of their baseline status, as measured by the PROMs. Patients with lower pre-operative scores are less affected by the ceiling effects.

In Studies II, III and IV, even though significant improvements were found in terms of the iHOT-12, HAGOS and VAS for overall hip function and the EQ-5D, only a modest improvement was found for the HSAS compared with the pre-operative levels. This could be interpreted as patients maintaining the same physical level or lifestyle despite

PROM improvements. Patients may reduce their activity level despite satisfaction with the surgical results, which may constitute a risk of bias. A reduction in activity level could be due to social or other reasons, especially in a group with long symptom duration, like that in Studies II, III and IV. We therefore claim that this is a major cause of the moderate increment in activity level in these studies, as compared with larger increments in hip-specific PROMs like the iHOT-12 and HAGOS. The post-operative outcome or activity level could perhaps be enhanced if patients had a shorter delay to treatment. Many patients may have a treatment delay due to a lack of knowledge of FAI in the community or a lack of resources in the health-care system.

To date, there are no RCTs showing that the arthroscopic treatment of FAI produces superior results compared with sham surgery or other treatment modalities. There are a few such ongoing studies, but unless otherwise demonstrated, it can be argued that the positive results seen in this thesis and other similar prospective studies may have other causes. A placebo effect of surgery is one; information and pre- and post-operative care are other such reasons. Moreover, a long rehabilitation post-operatively, the avoidance of impingement positions and situations, ADL modifications and the time span surgery entails could all improve patient symptoms. However, in Studies II, III and IV, symptom duration is long and pre-operative outcomes were very poor, factors that question the possibility of the natural resolution of these symptoms. Moreover, many of these patients have already tried most of the spectrum of non-surgical treatment modalities pre-operatively, such as ADL and

activity modification, physiotherapy and the avoidance of impingement situations. The present thesis therefore suggests superior results from the arthroscopic treatment of FAI compared with non-surgical treatment.

8.6 EVALUATION OF ATHLETES

Evaluating athletes has other inherent problems. They frequently only focus on athletic performance, possibly overrating items relating to athletic ability and underrating other items. For example, a significant post-operative improvement may not be correctly mirrored in the PROMs if full participation in their sports is not possible.

In Study III, the results after the arthroscopic treatment of FAI were evaluated prospectively with a one-year follow-up in a cohort of top-level athletes. The most important finding in Study III was that the outcome after the arthroscopic treatment of FAI in top-level athletes was favourable, with statistically and clinically significant improvements in all outcome measures.

Despite long-standing hip and/or groin pain, one in two top-level athletes was able, within one year after surgery, to return to the same sport and the same level as before symptom onset. These results must be regarded as valid for athletes, especially football and ice-hockey players, who constituted the majority of patients, as these are common sports in Sweden.

One important factor is how to evaluate return to sports after surgery. In Study III, the

HSAS, HAGOS sports and HAGOS physical activity were used to evaluate post-operative improvements in sports performance. At follow-up, 62 athletes (73%) had returned to competitive sports (HSAS levels 5-8) and 44 (52%) to their previous HSAS level of activity (HSAS level 7 or 8). Twenty-three athletes (27%) did not return to competitive sports (HSAS level <5). These results are difficult to interpret, as they can be seen as both positive and negative. It is positive that a large number of athletes are able to return when non-surgical treatment has failed and no other treatment modalities are available. In the literature, some studies report similar percentages of return to sports and some higher [21,117,109,10]. However, comparisons between studies are difficult, as different PROMs have been used and the definition of return to sports is lacking in some publications. Moreover, the symptom duration can affect the possibility of patients returning to sports. In Study III, the mean period of symptom duration was 2.8 years (SD 3.4). After several years of not being able to perform at the top level in your sports, the possibility of returning may be diminished for several reasons. This is further supported by the findings in Study III that return to sports was significantly higher in patients with short symptom duration (<12 months).

The definition of return to sports in sports research is a commonly unresolved problem. This problem also exists in FAI research. It is possible to conclude that a single PROM is not sufficient adequately to measure return to sports. A score such as the Tegner (for knee patients) or HSAS (for hip patients) needs to be coupled to a measurement of the amount and intensity of training or competition the athlete is capable of participat-

ing in. This is especially important in the case of FAI, where symptoms may be underestimated, as they may be dose dependent. Some patients with FAI or chondral damage to the hip may be able to complete practices or even parts of games and therefore report

a full score, but, when the same patients are forced to participate in every practice and full games, the symptoms may be so severe that low scores are now reported. This constitutes a bias in these studies.



Figure 36. Zlatan Ibrahimovic. Photo: Tommy Holl

8.7 FAI AND OSTEOARTHRITIS

The arthroscopic management of patients with FAI has generally been reported to produce a good outcome. Moreover, femoro-acetabular impingement (FAI) has been regarded as a causal factor in the development of hip osteoarthritis (OA) [49,16,75,150,78]. Athletes have also been reported to have an increased risk of developing hip OA. Only a few studies have specifically evaluated patients with FAI and OA. These studies report generally positive results in terms of PROMs but higher conversion rates to total hip arthroplasty (THA) in patients who have a joint space of two mm or less, suggesting inferior results in this patient category. The results of the arthroscopic treatment of FAI in patients with varying degrees of OA are still largely unknown.

In Study IV, the results after the arthroscopic treatment of FAI in the presence of mild to moderate osteoarthritis are evaluated. These patients showed significant improvements in all outcome measures at the two-year follow-up. It is important to point out that it is not the OA that is treated in these patients but FAI. As explained in the introduction to this thesis, the diagnosis of FAI is complex. For example, in these patients, it is not known whether their symptoms are due to OA or to FAI, since these conditions have a similar clinical picture. It is possible that surgery in cases where the problem is predominantly due to OA may aggravate the condition. On the other hand, treating FAI may have a positive effect, even in the presence of mild to moderate OA, especially in patients where the OA may be caused by FAI.

In Study IV, 82% of the patients were satisfied with the outcome of the surgery. These are encouraging results, as few other treatment modalities are available for this patient category. These patients have already undergone non-surgical treatment. A common interpretation of the Hippocratic oath says that the practice of medicine is to “sometimes cure, often relieve, but always comfort”. Many conditions are not treatable, even in modern medicine. Since its introduction, THA has revolutionised the treatment of OA. However, for younger patients, concern about loosening and future complications often means that these patients lack effective treatment. Hip arthroscopy is not a treatment for hip OA. However, a subgroup of patients may have symptoms from either an underlying FAI with concomitant OA or from symptomatic osteophytes leading to FAI. FAI may even be the cause of OA in some patients. The use of surgical FAI correction, either open or arthroscopic, could relieve symptoms in some patients. In science, the long-term outcome is often measured and evaluated. Implant survival is often measured as a sign of success. However, in some instances, such as the young patient with OA, symptom relief to delay the need for THA could be of benefit to many patients. On the other hand, this treatment must be safe. It is therefore important to measure and monitor the effects of these treatments, for example hip arthroscopy, in patients with FAI with concomitant mild OA. A registry such as the one described in this thesis is an example of this.

Most pre-operative PROM values were low, reflecting the fact that patients in the studied cohort had major pre-operative symptoms and disability. Coupled with long symptom

duration in many patients, this could have affected the result negatively. No statistically significant differences in outcomes were shown when the group with 1-2 mm of joint space width was compared with patients with 3+ mm joint space width. However, the group size (n=16) may be too limited to enable any definitive conclusions.

In the present study, lateral joint space was reduced, when comparing pre-operative and post-operative radiographs, from 3.6 to 3.2 mm ($p<0.05$). Given the finding of a reduction in lateral joint space between the pre-operative and post-operative time points, it is important to understand whether the surgery itself contributed to this finding, or if it is related to the natural history of the disease or possible measurement error. Future studies comparing surgical with non-surgical treatment are needed to answer this question. Osteophytes can theoretically be seen as the body's own attempt to fuse the joint in order to reduce symptoms. With increased joint motion, cartilage stress and wear could increase. Likewise, patients with fewer symptoms can perform at a higher level of physical activity, which may increase cartilage wear. On the other hand, cartilage nutrition and structural properties benefit from joint motion and loading. In Study IV, no statistically significant changes in PROMs were found in the group with reduced lateral joint space post-operatively.

In Study IV, five patients (7%) underwent THA during follow-up, which is a low rate compared with other similar studies. It is important to monitor the patients in this study with a longer follow-up.

8.8 EVALUATION OF TENOTOMY FOR GROIN PAIN IN ATHLETES

There are several reports on the association between pubalgia or tendon pain around the groin and intra-articular hip disorders. Historically, some of these patients were treated with tenotomy for long-standing groin pain. At that time, FAI was an unknown concept, yet many of these patients improved. Study V was performed to evaluate the long-term outcome in athletes who underwent tenotomy due to long-standing groin pain but also to evaluate the frequency of femoro-acetabular impingement (FAI) and its impact on the long-term outcome.

The most important finding in Study V was that most patients improved; 75% of the athletes were satisfied with the outcome of the tenotomy and 69% were able to return to their pre-injury sport. However, the athletes that did not return to their pre-injury sport had a higher frequency of a positive hip impingement test and an inferior functional outcome compared with the athletes that did return to their pre-injury sport. Moreover, the patients with a positive hip impingement test reported significantly more pain and symptoms, more hip problems during sports and physical activity, as well as lower hip-related quality of life.

These results could suggest that patients without FAI fared better after the surgical treatment of the tendon pain than patients with FAI. The possibility cannot be excluded that patients with a poor outcome had more symptoms related to FAI, which affected the outcome negatively.

However, the impact of FAI on extra-articular pain is not fully understood. FAI may be asymptomatic in many cases, even in athletes, and may therefore be an incidental finding in some patients. This could be seen in Study V, where 28 of 32 patients had radiographic signs of a cam deformity.

On the basis of these findings, it is recommended that a thorough examination is performed, including the hip joint, in athletes with long-standing tendon pain around the groin. In the case of a positive impingement test, FAI should be considered before tenotomy is chosen as treatment. When no signs of FAI are present, the long-term results of tenotomy can be expected to be positive.

8.9 HIP JOINT INSTABILITY

Interest in instability of the hip, both macro- and micro-instability, is rapidly increasing. However, very little knowledge and evidence has yet been acquired [139,20]. Iliopsoas tenotomy has been described as a treatment option for iliopsoas pain or internal snapping of the hip [63]. However, iliopsoas pain is a diffuse condition, which is difficult to diagnose. Internal snapping of the hip is common and is often an incidental finding. This makes the indications for iliopsoas tenotomy difficult. In some patients with diffuse hip pain, possible micro-instability of the hip may be misinterpreted as iliopsoas pain. As the iliopsoas is a stabiliser of the hip, sectioning of the iliopsoas may be detrimental to the stability of the hip, either worsening the symptoms of instability or even inciting episodes of hip dislocation.

In Study VI, the most important message was that macro-instability of the hip in the form of dislocation exists as a potential complication of hip arthroscopy. This highlights the importance of considering both the static and dynamic stabilisers of the hip prior to surgery.

8.10 GENERAL DISCUSSION

After some years of experience with the hip arthroscopy registry and analysing its results, some reflections can be made. For example, evaluating return to sports (using the HSAS) needs to be improved. An alternative is to add a measurement of time spent in training or competition and at what level. We propose that the iHOT-12 and HAGOS scores are good and valid for evaluating this patient category. The EQ-5D has limited value due to ceiling effects, but it has the advantage of making comparisons with other hip studies possible. On the other hand, adding more items may reduce compliance.

In future research, there is a need to take gender differences into account. A study by Joseph et al. showed no gender differences in terms of outcome after arthroscopic treatment for FAI [68]. Despite the fact that the data show that women have different pathology, more pre-operative symptoms indicate that it might not be scientifically correct to evaluate both genders together. In Studies I, II, III and IV, men and women are evaluated as a group, but these studies contain 66-82% male subjects, which may be a confounding factor.

In Study VII, a variety of end-points currently used to evaluate patients with FAI are discussed and the possibility of combining these outcomes to evaluate patients with FAI is examined. This highlights the fact that the optimal outcomes for evaluating treatment for patients with FAI have not yet been identified nor has consensus been reached. There is also an opportunity to combine outcomes in order optimally to evaluate these patients. Composite outcomes may reduce sample sizes and thereby reduce the cost and the time needed for a certain study.

The state of orthopaedic research at the present time is such that there are extremely few treatments that have solid high-level evidence to support their use. In spite of extensive research, this still applies, even after the introduction of evidence-based medicine. We must draw the conclusion that either surgical treatment is of no benefit, or that the scientific methods need to be improved. The next stage in this process may be to improve our outcome measures or use multiple outcome measures to evaluate results. Further use of prospective registry research can help surgeons to individualise surgical treatment to obtain the optimal result.

It is concluded that most patients treated arthroscopically for FAI in this thesis experience significant and clinically relevant improvements in terms of pain, symptoms, function, physical activity level and quality of life. These are good results, as other treatment options are few or unproven. Hip arthroscopy is the new frontier in orthopaedics and it is undergoing rapid development both clinically and scientifically. Lessons from this development can be used in other fields of orthopaedics. It is important that scientific and clinical developments are interconnected so that their development can benefit other areas.

09

MIKAEL SANSONE

09. CONCLUSIONS

It is possible to create a local registry for evaluating hip arthroscopy patients.

Prior to surgery, patients undergoing arthroscopic surgery for FAI report considerable pain, loss of function, reduced activity level and reduced quality of life pre-operatively as measured by multiple PROMs.

Two years after surgery, in a mixed group of 289 patients with FAI, arthroscopic treatment resulted in statistically significant and clinically relevant improvements in all outcome parameters.

Twelve months after surgery, arthroscopic treatment for top-level athletes with FAI resulted in statistically significant and clinically relevant improvements at group level in all outcome parameters for pain, symptoms, function, physical activity level, quality of life and general health. One year after surgery, approximately three in four top-level athletes had returned to sports.

Arthroscopic treatment for patients with FAI in the presence of mild to moderate OA resulted in statistically significant and clinically relevant improvements in outcome measures related to pain, symptoms, function, physical activity level and quality of life in the majority of patients. Patients undergoing tenotomy for pub-

algia reported a satisfactory long-term outcome in three in four cases. Non-satisfied athletes had signs of FAI to a higher degree. It is recommended that the hip should be carefully evaluated for FAI before tenotomy is considered as treatment for athletes with pubalgia.

Hip dislocation is a very rare, but it is a possible complication after hip arthroscopy with concomitant psoas tenotomy.

A composite outcome of patient-related and important end-points may be helpful in obtaining comprehensive information about the efficacy of surgery for patients with FAI.

10

MIKAEL SANSONE

10. FUTURE PERSPECTIVES

Today, there are numerous health-related registries using PROM data to evaluate patients. There are many advantages to PROMs, as they make data in numerical form easily available and collectible using web-based online questionnaires. However, it is important to be aware of the pitfalls. Filling out PROM questionnaires and describing your health with a number is not always easy. Patients can misread the question and put 90 where they mean 10 and some people tend to put a number “in the middle”, whereas others express themselves with extreme numbers. The extent of this problem is, however, unknown. Even if a great deal of work has been put into creating and validating the PROM instruments, and they are regarded as sound, there are many aspects of human experience they do not capture. For the clinician, a personal interview with a patient gives additional information and is an important complement to the patient results related to the PROMs. Qualitative studies would make it possible to add new and important aspects for patients with FAI and could thus be an important complement to quantitative studies. Moreover, there are other parameters that affect the outcome of surgery for patients with FAI, such as complications and the development of osteoarthritis (OA).

During the work on this thesis, it has become more and more clear that a combination of outcomes could provide an enhanced understanding of the subjects' experience.

In terms of FAI research, at this time, there is a need for multiple RCTs in order to describe this treatment without several biases. There are a few such studies in progress. However, RCTs are unable to answer all the questions related to the treatment of patients with FAI, as treatment has and probably will continue to change over time, patients and patient selection will differ between countries, physicians will learn more and technical aids will be developed. The addition of observational studies adds knowledge to this area, complementing studies of other types.

With a growing body of research on patients with FAI, this area could be a good example of how to evaluate a new treatment modality scientifically. However, FAI research needs to be of high quality, with sound outcome measures and including several types of study, including RCTs, observational studies, qualitative studies and basic science.

11

MIKAEL SANSONE

11. ACKNOWLEDGEMENTS

I am grateful to several people for help, assistance and support in the work behind this thesis.

Jón Karlsson, Professor, MD, PhD, my main supervisor. For constant support, guidance and concern, both professionally and in life and for being a very dear friend.

Mattias Ahldén, MD, PhD and research colleague and co-author. For invaluable advice on everything and for being a true friend.

Leif Swärd, Associate Professor, MD, PhD and my clinical mentor. For being the foundation on which our clinical and scientific work is based. Without you, this thesis would not have happened. Thank you for great friendship and many OR memories.

Roland Thomeé, Professor, RPT, PhD, friend and co-supervisor on this thesis. For great guidance, discussions and encouragement.

Adad Baranto, Associate Professor, MD, PhD, my co-supervisor. For help and guidance.

Páll Jónasson, MD, PhD, research colleague and friend. Thank you for great help, co-operation and friendship.

Christoffer Thomeé, for fantastic work with the registry. Always helpful and skilled.

Anders Falk, MD, colleague and co-author. For help with Study V and great discussions.

Nicklas Olsson, MD, PhD, research colleague and friend. For being a good friend and always having good advice on everything.

Linda Johansson, administrator, for academic guidance and knowledge and patience in all matters relating to the Sahlgremska Academy.

Christer Johansson, statistical consultant. For help with statistics and good scientific advice.

Jüri Kartus, Professor, MD, PhD. For great advice and discussions on many subjects and fun times in GC.

Femi Ayeni, MD, research colleague, co-author. For great co-operation, past and future .

Fredrik Einarsson, MD, PhD, for teaching me so many things in sports surgery as well as science and for being a great friend.

Katarina Nilsson-Helander, MD, PhD, colleague. For being a good friend and exemplary colleague.

Monica Bengtsson, for fantastic help in keeping track of me and all the records.

Ingela Lindgren, for great help with everything, always with great spirit.

Helena Brisby, Professor, MD, PhD, Chairman of the Department of Orthopaedics, Sahlgrenska Academy. For giving me the opportunity to do research.

Axel Öhlin, co-author. For great help with Study II. Best of luck with future research.

Magnus Karlsson, MD, present head of the Orthopaedic Department at Sahlgrenska University Hospital, Mölndal, for giving me the opportunity to combine research and clinical work.

David Collin, MD, research colleague, co-author. For great help with Study IV.

Bertil Romanus, MD, for support, encouragement and fruitful discussions.

Pontus Andersson, Pontus Art Production. For beautiful illustrations.

Guðni Ólafsson, IT Designer. For help

with the design and layout of this thesis.

Jeanette Kliger, for excellent editing of the English language in this thesis.

Anette Dahlström, for beautiful illustrations.

Thomas Eriksson, MD, co-author. For help with Study VI and good clinical discussions.

Anders Johnsson, automotive engineer. For helping me with calculations.

All my colleagues and staff at **Orthocenter/IFK-kliniken**, for great help with the registry and fantastic clinical work every day.

All my colleagues and staff at the arthroscopic team, **Orthopaedic Department at Sahlgrenska University Hospital, Mölndal**, for support.

Annabel Ekberg and **Nima Peyravi Latif**, for helping me with data compilation.

The Gran Canaria research group, for fun and productive discussions.

Nina and **Carl Bennet**, for financial support for the research project.

My family, **Christian**, **Ann-Sofie** and their **families**. For being there.

My parents, **Giuseppe** and **Ann-Marie**. For giving me your everything.

My wife, **Martina**, and my children, **Saga** and **Elias**, for making every day worth living.

13

MIKAEL SANSONE

13. REFERENCES

1. Ackerman IN, Ademi Z, Osborne RH, Liew D (2013) Comparison of health-related quality of life, work status, and health care utilization and costs according to hip and knee joint disease severity: a national Australian study. *Phys Ther* 93 (7):889-899.
2. Adirim TA, Cheng TL (2003) Overview of injuries in the young athlete. *Sports Med* 33 (1):75-81
3. Agricola R, Bessems JH, Ginai AZ, Heijboer MP, van der Heijden RA, Verhaar JA, Weinans H, Waarsing JH (2012) The Development of Cam-Type Deformity in Adolescent and Young Male Soccer Players. *Am J Sports Med*;40(5):1099-106.
4. Agricola R, Bessems JH, Ginai AZ, Heijboer MP, van der Heijden RA, Verhaar JA, Weinans H, Waarsing JH (2012) The development of Cam-type deformity in adolescent and young male soccer players. *Am J Sports Med* 40 (5):1099-1106.
5. Agricola R, Heijboer MP, Bierma-Zeinstra SM, Verhaar JA, Weinans H, Waarsing JH (2013) Cam impingement causes osteoarthritis of the hip: a nationwide prospective cohort study (CHECK). *Annals of the rheumatic diseases* 72 (6):918-923.
6. Agricola R, Heijboer MP, Roze RH, Reijman M, Bierma-Zeinstra SM, Verhaar JA, Weinans H, Waarsing JH (2013) Pincer deformity does not lead to osteoarthritis of the hip whereas acetabular dysplasia does: acetabular coverage and development of osteoarthritis in a nationwide prospective cohort study (CHECK). *Osteoarthritis Cartilage* 21 (10):1514-1521.
7. Ahlden M, Sansone M, Jonasson P, Sward L, Karlsson J (2014) [Hip arthroscopy, new technique against hip pain]. *Lakartidningen* 111 (36):1445-1449
8. Allen D, Beaulé PE, Ramadan O, Doucette S (2009) Prevalence of associated deformities and hip pain in patients with cam-type femoroacetabular impingement. *J Bone Joint Surg Br* 91 (5):589-594.
9. Alpert JM, Kozanek M, Li G, Kelly BT, Asnis PD (2009) Cross-sectional analysis of the iliopsoas tendon and its relationship to the acetabular labrum: an anatomic study. *Am J Sports Med* 37 (8):1594-1598.
10. Alradwan H, Philippon MJ, Farrokhyar F, Chu R, Whelan D, Bhandari M, Ayeni OR (2012) Return to preinjury activity levels after surgical management of femoroacetabular impingement in athletes. *Arthroscopy* 28 (10):1567-1576.
11. Atchia I, Kane D, Reed MR, Isaacs JD, Birrell F (2011) Efficacy of a single ultrasound-guided injection for the treatment of hip osteoarthritis. *Annals of the rheumatic diseases* 70 (1):110-116.
12. Audenaert EA, Peeters I, Vigneron L, Baelde N, Pattyn C (2012) Hip morphological characteristics and range of internal rotation in femoroacetabular impingement. *Am J Sports Med* 40 (6):1329-1336.
13. Ayeni OR, Adamich J, Farrokhyar F, Simunovic N, Crouch S, Philippon MJ, Bhandari M (2014) Surgical management of labral tears during femoroacetabular impingement surgery: a systematic review. *Knee Surg Sports Traumatol Arthrosc* 22 (4):756-762.
14. Ayeni OR, Chan K, Al-Asiri J, Chien T, Sprague S, Liew S, Bhandari M (2013) Sources and quality of literature addressing femoroacetabular impingement. *Knee Surg Sports Traumatol Arthrosc* 21 (2):415-419.
15. Beaulé PE, Le Duff MJ, Zaragoza E (2007) Quality of life following femoral head-neck osteochondroplasty for femoroacetabular impingement. *J Bone Joint Surg Am* 89 (4):773-779.
16. Beck M, Kalhor M, Leunig M, Ganz R (2005) Hip morphology influences the pattern of damage to the acetabular cartilage: femoroacetabular impingement as a cause of early osteoarthritis of the hip. *J Bone Joint Surg Br* 87 (7):1012-1018.
17. Beck M, Leunig M, Parvizi J, Boutier V, Wyss D, Ganz R (2004) Anterior femoroacetabular impingement: part II. Midterm results of surgical treatment. *Clin Orthop Relat Res* (418):67-73
18. Bedi A, Galano G, Walsh C, Kelly BT (2011) Capsular management during hip arthroscopy: from femoroacetabular impingement to instability. *Arthroscopy* 27 (12):1720-1731.

19. Benali Y, Katthagen BD (2009) Hip subluxation as a complication of arthroscopic debridement. *Arthroscopy* 25 (4):405-407.
20. Boykin RE, Anz AW, Bushnell BD, Kocher MS, Stubbs AJ, Philippon MJ (2011) Hip instability. *J Am Acad Orthop Surg* 19 (6):340-349
21. Brunner A, Horisberger M, Herzog RF (2009) Sports and recreation activity of patients with femoroacetabular impingement before and after arthroscopic osteoplasty. *Am J Sports Med* 37 (5):917-922.
22. Buckwalter JA, Martin JA, Brown TD (2006) Perspectives on chondrocyte mechanobiology and osteoarthritis. *Biorheology* 43 (3-4):603-609
23. Burman MS (2001) Arthroscopy or the direct visualization of joints: an experimental cadaver study. 1931. *Clin Orthop Relat Res* (390):5-9
24. Byrd JW, Jones KS (2000) Prospective analysis of hip arthroscopy with 2-year follow-up. *Arthroscopy : the journal of arthroscopic & related surgery : official publication of the Arthroscopy Association of North America and the International Arthroscopy Association* 16 (6):578-587.
25. Byrd JW, Jones KS (2011) Arthroscopic management of femoroacetabular impingement in athletes. *Am J Sports Med* 39 Suppl:7S-13S.
26. Cecchi F, Mannoni A, Molino-Lova R, Ceppatelli S, Benvenuti E, Bandinelli S, Lauretani F, Macchi C, Ferrucci L (2008) Epidemiology of hip and knee pain in a community based sample of Italian persons aged 65 and older. *Osteoarthritis Cartilage* 16 (9):1039-1046.
27. Charbonnier C, Kolo FC, Duthon VB, Magnenat-Thalmann N, Becker CD, Hoffmeyer P, Menetrey J (2011) Assessment of congruence and impingement of the hip joint in professional ballet dancers: a motion capture study. *Am J Sports Med* 39 (3):557-566.
28. Christmas C, Crespo CJ, Franckowiak SC, Bathon JM, Bartlett SJ, Andersen RE (2002) How common is hip pain among older adults? Results from the Third National Health and Nutrition Examination Survey. *The Journal of family practice* 51 (4):345-348
29. Clobisoy JC, Baca G, Beaule PE, Kim YJ, Larson CM, Millis MB, Podeszwa DA, Schoenecker PL, Sierra RJ, Sink EL, Sucato DJ, Trousdale RT, Zaltz I (2013) Descriptive epidemiology of femoroacetabular impingement: a North American cohort of patients undergoing surgery. *Am J Sports Med* 41 (6):1348-1356.
30. Clobisoy JC, Knaus ER, Hunt DM, Lesher JM, Harris-Hayes M, Prather H (2009) Clinical presentation of patients with symptomatic anterior hip impingement. *Clin Orthop Relat Res* 467 (3):638-644.
31. Corten K, Ganz R, Chosa E, Leunig M (2011) Bone apposition of the acetabular rim in deep hips: a distinct finding of global pincer impingement. *J Bone Joint Surg Am* 93 Suppl 2:10-16.
32. Coteur G, Feagan B, Keininger DL, Kosinski M (2009) Evaluation of the meaningfulness of health-related quality of life improvements as assessed by the SF-36 and the EQ-5D VAS in patients with active Crohn's disease. *Aliment Pharmacol Ther* 29 (9):1032-1041.
33. Cowan J, Lozano-Calderon S, Ring D (2007) Quality of prospective controlled randomized trials. Analysis of trials of treatment for lateral epicondylitis as an example. *J Bone Joint Surg Am* 89 (8):1693-1699.
34. D G UK Full Randomised Controlled Trial of Arthroscopic Surgery for Hip Impingement versus best conventional care (UKFASHION). <http://publicukcrnorguk/search/StudyDetails.aspx?StudyID=16806>
35. Damore DT, Metz J, Ramundo M, Pan S, Van Amerongen R (2003) Patterns in childhood sports injury. *Pediatric emergency care* 19 (2):65-67
36. de Sa D, Cargnelli S, Catapano M, Bedi A, Simunovic N, Burrow S, Ayeni OR (2015) Femoroacetabular impingement in skeletally immature patients: a systematic review examining indications, outcomes, and complications of open and arthroscopic treatment. *Arthroscopy* 31 (2):373-384.
37. de Sa D, Horner NS, MacDonald A, Simunovic N, Slobogean G, Philippon MJ, Belzile EL, Karlsson J, Ayeni OR (2015) Evaluating healthcare resource utilization and outcomes for surgical hip dislocation and hip arthroscopy for femoroacetabular impingement. *Knee Surg Sports Traumatol Arthrosc*.
38. Doherty M, Courtney P, Doherty S, Jenkins W, Maciewicz RA, Muir K, Zhang W (2008) Nonspherical femoral head shape (pistol grip deformity), neck shaft angle, and risk of hip osteoarthritis: a case-control study. *Arthritis Rheum* 58 (10):3172-3182.
39. Domb BG, Gui C, Lodhia P (2015) How much arthritis is too much for hip arthroscopy: a systematic review. *Arthroscopy* 31 (3):520-529.
40. Domb BG, Jackson TJ, Carter CC, Jester JR, Finch NA, Stake CE (2014) Magnetic Resonance Imaging Findings in the Symptomatic Hips of Younger Retired National Football League Players. *Am J Sports Med* 42 (7):1704-1709.

41. Elser F, Braun S, Dewing CB, Giphart JE, Millett PJ (2011) Anatomy, function, injuries, and treatment of the long head of the biceps brachii tendon. *Arthroscopy* 27 (4):581-592.
42. Emara K, Samir W, Motasem el H, Ghafar KA (2011) Conservative treatment for mild femoroacetabular impingement. *J Orthop Surg (Hong Kong)* 19 (1):41-45
43. Espinosa N, Beck M, Rothenfluh DA, Ganz R, Leunig M (2007) Treatment of femoro-acetabular impingement: preliminary results of labral refixation. Surgical technique. *J Bone Joint Surg Am* 89 Suppl 2 Pt.1:36-53.
44. Feeley BT, Powell JW, Muller MS, Barnes RP, Warren RF, Kelly BT (2008) Hip injuries and labral tears in the national football league. *Am J Sports Med* 36 (11):2187-2195.
45. Felson DT, Lawrence RC, Dieppe PA, Hirsch R, Helmick CG, Jordan JM, Kington RS, Lane NE, Nevitt MC, Zhang Y, Sowers M, McAlindon T, Spector TD, Poole AR, Yanovski SZ, Ateshian G, Sharma L, Buckwalter JA, Brandt KD, Fries JF (2000) Osteoarthritis: new insights. Part 1: the disease and its risk factors. *Ann Intern Med* 133 (8):635-646
46. Flierl MA, Stabel PF, Hak DJ, Morgan SJ, Smith WR (2010) Traction table-related complications in orthopaedic surgery. *J Am Acad Orthop Surg* 18 (11):668-675
47. Ganz R, Gill TJ, Gautier E, Ganz K, Krugel N, Berlemann U (2001) Surgical dislocation of the adult hip a technique with full access to the femoral head and acetabulum without the risk of avascular necrosis. *J Bone Joint Surg Br* 83 (8):1119-1124
48. Ganz R, Leunig M, Leunig-Ganz K, Harris WH (2008) The etiology of osteoarthritis of the hip: an integrated mechanical concept. *Clin Orthop Relat Res* 466 (2):264-272.
49. Ganz R, Parvizi J, Beck M, Leunig M, Notzli H, Siebenrock KA (2003) Femoroacetabular impingement: a cause for osteoarthritis of the hip. *Clin Orthop Relat Res* (417):112-120.
50. Gosvig KK, Jacobsen S, Sonne-Holm S, Gebuhr P (2008) The prevalence of cam-type deformity of the hip joint: a survey of 4151 subjects of the Copenhagen Osteoarthritis Study. *Acta Radiol* 49 (4):436-441.
51. Gosvig KK, Jacobsen S, Sonne-Holm S, Palm H, Troelsen A (2010) Prevalence of malformations of the hip joint and their relationship to sex, groin pain, and risk of osteoarthritis: a population-based survey. *J Bone Joint Surg Am* 92 (5):1162-1169.
52. Griffin DR, Parsons N, Mohtadi NG, Safran MR (2012) A short version of the International Hip Outcome Tool (iHOT-12) for use in routine clinical practice. *Arthroscopy* 28 (5):611-616; quiz 616-618.
53. Griffin DR, Parsons N, Mohtadi NG, Safran MR (2012) A short version of the International Hip Outcome Tool (iHOT-12) for use in routine clinical practice. *Arthroscopy : the journal of arthroscopic & related surgery : official publication of the Arthroscopy Association of North America and the International Arthroscopy Association* 28 (5):611-616; quiz 616-618.
54. Grotle M, Hagen KB, Natvig B, Dahl FA, Kvien TK (2008) Prevalence and burden of osteoarthritis: results from a population survey in Norway. *J Rheumatol* 35 (4):677-684
55. Gupta A, Suarez-Ahedo C, Redmond JM, Gerhardt MB, Hanypsiak B, Stake CE, Finch NA, Domb BG (2015) Best Practices During Hip Arthroscopy: Aggregate Recommendations of High-Volume Surgeons. *Arthroscopy* 31 (9):1722-1727.
56. Hack K, Di Primio G, Rakhra K, Beaulé PE (2010) Prevalence of cam-type femoroacetabular impingement morphology in asymptomatic volunteers. *J Bone Joint Surg Am* 92 (14):2436-2444.
57. Harris JD, Erickson BJ, Bush-Joseph CA, Nho SJ (2013) Treatment of femoroacetabular impingement: a systematic review. *Current reviews in musculoskeletal medicine* 6 (3):207-218.
58. Harris WH (1969) Traumatic arthritis of the hip after dislocation and acetabular fractures: treatment by mold arthroplasty. An end-result study using a new method of result evaluation. *J Bone Joint Surg Am* 51 (4):737-755
59. Harris-Hayes M, McDonough CM, Leunig M, Lee CB, Callaghan JJ, Roos EM (2013) Clinical outcomes assessment in clinical trials to assess treatment of femoroacetabular impingement: use of patient-reported outcome measures. *J Am Acad Orthop Surg* 21 Suppl 1:S39-46.
60. Hetaimish BM, Khan M, Crouch S, Simunovic N, Bedi A, Mohtadi N, Bhandari M, Ayeni OR (2013) Consistency of reported outcomes after arthroscopic management of femoroacetabular impingement. *Arthroscopy* 29 (4):780-787.
61. Ibrahim A, Murrell GA, Knapman P (2007) Adductor strain and hip range of movement in male professional soccer players. *J Orthop Surg (Hong Kong)* 15 (1):46-49
62. Ilizaliturri C. JP, Acuna M (2015) Description and mid-term results of the 'over the top' technique for the

treatment of the pincer deformity in femoroacetabular impingement. *Journal of hip preservation surgery*. doi:10.1093/jhps/hnv058

63. Ilizaliturri VM, Jr., Camacho-Galindo J (2010) Endoscopic treatment of snapping hips, iliotibial band, and iliopsoas tendon. *Sports Med Arthrosc* 18 (2):120-127.

64. Jonasson (2014) Strength of the porcine proximal femoral epiphyseal plate: the effect of different loading directions and the role of the perichondrial fibrocartilaginous complex and epiphyseal tubercle - an experimental biomechanical study. *Journal of Experimental Orthopaedics* 1 (4):

65. Jonasson P, Baranto A, Karlsson J, Sward L, Sansone M, Thomee C, Ahlden M, Thomee R (2014) A standardised outcome measure of pain, symptoms and physical function in patients with hip and groin disability due to femoro-acetabular impingement: cross-cultural adaptation and validation of the international Hip Outcome Tool (iHOT12) in Swedish. *Knee Surg Sports Traumatol Arthrosc*. 22 (4):826-834.

66. Jonasson P, Baranto A, Karlsson J, Sward L, Sansone M, Thomee C, Ahlden M, Thomee R (2014) A standardised outcome measure of pain, symptoms and physical function in patients with hip and groin disability due to femoro-acetabular impingement: cross-cultural adaptation and validation of the international Hip Outcome Tool (iHOT12) in Swedish. *Knee Surg Sports Traumatol Arthrosc* 22 (4):826-834.

67. Jónasson P EL, Hansson H-A, Sansone M, Karlsson J, Sward L, Baranto A. (2015) Cyclical loading causes injury in and around the porcine proximal femoral physeal plate: proposed cause of the development of cam deformity in young athletes. *Journal of Experimental Orthopaedics* 2 (6)

68. Joseph R, Pan X, Cenkus K, Brown L, Ellis T, Di Stasi S (2015) Sex Differences in Self-Reported Hip Function Up to 2 Years After Arthroscopic Surgery for Femoroacetabular Impingement. *Am J Sports Med*.

69. Kang AC, Gooding AJ, Coates MH, Goh TD, Armour P, Rietveld J (2010) Computed tomography assessment of hip joints in asymptomatic individuals in relation to femoroacetabular impingement. *Am J Sports Med* 38 (6):1160-1165.

70. Keeney JA, Peelle MW, Jackson J, Rubin D, Maloney WJ, Clobis JC (2004) Magnetic resonance arthrography versus arthroscopy in the evaluation of articular hip pathology. *Clin Orthop Relat Res* (429):163-169

71. Kemp JL, MacDonald D, Collins NJ, Hatton AL, Crossley KM (2015) Hip arthroscopy in the setting of

hip osteoarthritis: systematic review of outcomes and progression to hip arthroplasty. *Clin Orthop Relat Res* 473 (3):1055-1073.

72. Khanna V, Caragianis A, Diprimio G, Rakhra K, Beaulé PE (2014) Incidence of hip pain in a prospective cohort of asymptomatic volunteers: is the cam deformity a risk factor for hip pain? *Am J Sports Med* 42 (4):793-797.

73. Kim C, Nevitt MC, Niu J, Clancy MM, Lane NE, Link TM, Vlad S, Tolstykh I, Jungmann PM, Felson DT, Guermazi A (2015) Association of hip pain with radiographic evidence of hip osteoarthritis: diagnostic test study. *Bmj* 351:h5983.

74. Klit J, Gosvig K, Jacobsen S, Sonne-Holm S, Troelsen A (2011) The prevalence of predisposing deformity in osteoarthritic hip joints. *Hip Int* 21 (5):537-541.

75. Kohl S, Hosalkar HS, Mainil-Varlet P, Krueger A, Buechler L, Siebenrock K (2011) Histology of damaged acetabular cartilage in symptomatic femoroacetabular impingement: an observational analysis. *Hip Int* 21 (2):154-162.

76. Kolo FC, Charbonnier C, Pfirrmann CW, Duc SR, Lubbeke A, Duthon VB, Magnenat-Thalmann N, Hoffmeyer P, Menetrey J, Becker CD (2013) Extreme hip motion in professional ballet dancers: dynamic and morphological evaluation based on magnetic resonance imaging. *Skeletal Radiol* 42 (5):689-698.

77. Konan S, Rayan F, Meermans G, Witt J, Haddad FS (2011) Validation of the classification system for acetabular chondral lesions identified at arthroscopy in patients with femoroacetabular impingement. *J Bone Joint Surg Br* 93 (3):332-336.

78. Kowalczyk M, Yeung M, Simunovic N, Ayeni OR (2015) Does Femoroacetabular Impingement Contribute to the Development of Hip Osteoarthritis? A Systematic Review. *Sports Med Arthrosc* 23 (4):174-179.

79. Kuhlman GS, Domb BG (2009) Hip impingement: identifying and treating a common cause of hip pain. *Am Fam Physician* 80 (12):1429-1434

80. LaFrance R, Williams R, Madsen W, Maloney M, Drinkwater C, Giordano B (2014) The prevalence of radiographic criteria of femoral acetabular impingement in patients undergoing hip arthroplasty surgery. *Geriatric orthopaedic surgery & rehabilitation* 5 (1):21-26.

81. Lamy A, Devreux PJ, Prabhakaran D, Taggart DP, Hu S, Paolasso E, Straka Z, Piegas LS, Akar AR, Jain AR, Noiseux N, Padmanabhan C, Bahamondes JC, Novick RJ, Vijayanath P, Reddy S, Tao L, Olavegoeascoechea

- PA, Airan B, Sulling TA, Whitlock RP, Ou Y, Ng J, Chrolavicius S, Yusuf S (2012) Off-pump or on-pump coronary-artery bypass grafting at 30 days. *N Engl J Med* 366 (16):1489-1497.
82. Lamy A, Devereaux PJ, Prabhakaran D, Taggart DP, Hu S, Paolasso E, Straka Z, Piegas LS, Akar AR, Jain AR, Noiseux N, Padmanabhan C, Bahamondes JC, Novick RJ, Vajjyanath P, Reddy SK, Tao L, Olavegogeochea PA, Airan B, Sulling TA, Whitlock RP, Ou Y, Pogue J, Chrolavicius S, Yusuf S (2013) Effects of off-pump and on-pump coronary-artery bypass grafting at 1 year. *N Engl J Med* 368 (13):1179-1188.
83. Laor T, Wall EJ, Vu LP (2006) Physeal widening in the knee due to stress injury in child athletes. *AJR Am J Roentgenol* 186 (5):1260-1264.
84. Larson CM, Giveans MR (2008) Arthroscopic management of femoroacetabular impingement: early outcomes measures. *Arthroscopy* 24 (5):540-546.
85. Larson CM, Sikka RS, Sardelli MC, Byrd JW, Kelly BT, Jain RK, Giveans MR (2013) Increasing alpha angle is predictive of athletic-related "hip" and "groin" pain in collegiate National Football League prospects. *Arthroscopy* 29 (3):405-410.
86. Laslett LL, Quinn SJ, Winzenberg TM, Sanderson K, Cicuttini F, Jones G (2012) A prospective study of the impact of musculoskeletal pain and radiographic osteoarthritis on health related quality of life in community dwelling older people. *BMC musculoskeletal disorders* 13:168.
87. Leunig M, Beck M, Dora C, Ganz R (2006) [Femoroacetabular impingement: trigger for the development of coxarthrosis]. *Orthopade* 35 (1):77-84.
88. Lundin O, Hellstrom M, Nilsson I, Sward L (2001) Back pain and radiological changes in the thoracolumbar spine of athletes. A long-term follow-up. *Scand J Med Sci Sports* 11 (2):103-109
89. Lung R, O'Brien J, Grebenyuk J, Forster BB, De Vera M, Kopec J, Ratzlaff C, Garbuz D, Prlic H, Esdaile JM (2012) The prevalence of radiographic femoroacetabular impingement in younger individuals undergoing total hip replacement for osteoarthritis. *Clinical rheumatology* 31 (8):1239-1242.
90. MacFarlane RJ, Konan S, El-Huseinny M, Haddad FS (2014) A review of outcomes of the surgical management of femoroacetabular impingement. *Ann R Coll Surg Engl* 96 (5):331-338.
91. Maffulli N, Longo UG, Spiezia F, Denaro V (2011) Aetiology and prevention of injuries in elite young athletes. *Medicine and sport science* 56:187-200.
92. Martin RL, Kelly BT, Philippon MJ (2006) Evidence of validity for the hip outcome score. *Arthroscopy* 22 (12):1304-1311.
93. Matsuda DK (2009) Acute iatrogenic dislocation following hip impingement arthroscopic surgery. *Arthroscopy* 25 (4):400-404.
94. Matsuda DK, Carlisle JC, Arthurs SC, Wierks CH, Philippon MJ (2011) Comparative systematic review of the open dislocation, mini-open, and arthroscopic surgeries for femoroacetabular impingement. *Arthroscopy* 27 (2):252-269.
95. Meftah M, Rodriguez JA, Panagopoulos G, Alexiades MM (2011) Long-term results of arthroscopic labral debridement: predictors of outcomes. *Orthopedics* 34 (10):e588-592.
96. Mei-Dan O, McConkey MO, Brick M (2012) Catastrophic failure of hip arthroscopy due to iatrogenic instability: can partial division of the ligamentum teres and iliofemoral ligament cause subluxation? *Arthroscopy* 28 (3):440-445.
97. Messner K, Maletius W (1996) The long-term prognosis for severe damage to weight-bearing cartilage in the knee: a 14-year clinical and radiographic follow-up in 28 young athletes. *Acta Orthop Scand* 67 (2):165-168
98. Meulenkamp B, Gravel D, Beaulé PE (2014) Viability assessment of the chondral flap in patients with cam-type femoroacetabular impingement: a preliminary report. *Canadian journal of surgery Journal canadien de chirurgie* 57 (1):44-48
99. Mirtz TA, Chandler JP, Evers CM (2011) The effects of physical activity on the epiphyseal growth plates: a review of the literature on normal physiology and clinical implications. *Journal of clinical medicine research* 3 (1):1-7.
100. Mohtadi NG, Griffin DR, Pedersen ME, Chan D, Safran MR, Parsons N, Sekiya JK, Kelly BT, Werle JR, Leunig M, McCarthy JC, Martin HD, Byrd JW, Philippon MJ, Martin RL, Guanche CA, Clohisy JC, Sampson TG, Kocher MS, Larson CM (2012) The Development and validation of a self-administered quality-of-life outcome measure for young, active patients with symptomatic hip disease: the International Hip Outcome Tool (iHOT-33). *Arthroscopy* 28 (5):595-605; quiz 606-510 e591.
101. Mohtadi NG, Griffin DR, Pedersen ME, Chan D, Safran MR, Parsons N, Sekiya JK, Kelly BT, Werle JR, Leunig M, McCarthy JC, Martin HD, Byrd JW, Philippon MJ, Martin RL, Guanche CA, Clohisy JC, Sampson TG, Kocher MS, Larson CM (2012) The Development and validation of a self-administered quality-of-life outcome

- measure for young, active patients with symptomatic hip disease: the International Hip Outcome Tool (iHOT-33). *Arthroscopy* 28 (5):595-605;
102. A multi-centre randomized controlled trial comparing arthroscopic osteochondroplasty and lavage with arthroscopic lavage alone on patient important outcomes and quality of life in the treatment of young adult (18-50) femoroacetabular impingement (2015). *BMC musculoskeletal disorders* 16:64.
103. Naal FD, Miozzari HH, Kelly BT, Magennis EM, Leunig M, Noetzi HP (2013) The Hip Sports Activity Scale (HSAS) for patients with femoroacetabular impingement. *Hip Int* 23 (2):204-211.
104. Naal FD, Miozzari HH, Schar M, Hesper T, Notzli HP (2012) Midterm results of surgical hip dislocation for the treatment of femoroacetabular impingement. *Am J Sports Med* 40 (7):1501-1510.
105. Naal FD, Miozzari HH, Wyss TF, Notzli HP (2011) Surgical hip dislocation for the treatment of femoroacetabular impingement in high-level athletes. *Am J Sports Med* 39 (3):544-550.
106. Nepple JJ, Riggs CN, Ross JR, Clobisy JC (2014) Clinical presentation and disease characteristics of femoroacetabular impingement are sex-dependent. *J Bone Joint Surg Am* 96 (20):1683-1689.
107. Ng VY, Arora N, Best TM, Pan X, Ellis TJ (2010) Efficacy of surgery for femoroacetabular impingement: a systematic review. *Am J Sports Med* 38 (11):2337-2345.
108. Nho SJ, Kymes SM, Callaghan JJ, Felson DT (2013) The burden of hip osteoarthritis in the United States: epidemiologic and economic considerations. *J Am Acad Orthop Surg* 21 Suppl 1:S1-6.
109. Nho SJ, Magennis EM, Singh CK, Kelly BT (2011) Outcomes after the arthroscopic treatment of femoroacetabular impingement in a mixed group of high-level athletes. *Am J Sports Med* 39 Suppl:14S-19S.
110. Nicholls AS, Kiran A, Pollard TC, Hart DJ, Arden CP, Spector T, Gill HS, Murray DW, Carr AJ, Arden NK (2011) The association between hip morphology parameters and nineteen-year risk of end-stage osteoarthritis of the hip: a nested case-control study. *Arthritis Rheum* 63 (11):3392-3400.
111. Nilsson AK, Lohmander LS, Klassbo M, Roos EM (2003) Hip disability and osteoarthritis outcome score (HOOS)--validity and responsiveness in total hip replacement. *BMC Musculoskelet Disord* 4:10.
112. Notzli HP, Wyss TF, Stoecklin CH, Schmid MR, Treiber K, Hodler J (2002) The contour of the femoral head-neck junction as a predictor for the risk of anterior impingement. *J Bone Joint Surg Br* 84 (4):556-560
113. Nwachukwu BU, Rebolledo BJ, McCormick F, Rosas S, Harris JD, Kelly BT (2015) Arthroscopic Versus Open Treatment of Femoroacetabular Impingement: A Systematic Review of Medium- to Long-Term Outcomes. *Am J Sports Med*. doi:10.1177/0363546515587719
114. Owman H, Ericsson YB, Englund M, Tiderius CJ, Tjornstrand J, Roos EM, Dahlberg LE (2014) Association between delayed gadolinium-enhanced MRI of cartilage (dGEMRIC) and joint space narrowing and osteophytes: a cohort study in patients with partial meniscectomy with 11 years of follow-up. *Osteoarthritis Cartilage* 22 (10):1537-1541.
115. Pailhe R, Chiron P, Reina N, Cavaignac E, Lafontan V, Laffosse JM (2013) Pudendal nerve neuralgia after hip arthroscopy: retrospective study and literature review. *Orthop Traumatol Surg Res* 99 (7):785-790.
116. Palmer AJ, Ayyar-Gupta V, Dutton SJ, Rombach I, Cooper CD, Pollard TC, Hollinghurst D, Taylor A, Barker KL, McNally EG, Beard DJ, Andrade AJ, Carr AJ, Glyn-Jones S (2014) Protocol for the Femoroacetabular Impingement Trial (FAIT): a multi-centre randomised controlled trial comparing surgical and non-surgical management of femoroacetabular impingement. *Bone & joint research* 3 (11):321-327.
117. Philippon M, Schenker M, Briggs K, Kuppersmith D (2007) Femoroacetabular impingement in 45 professional athletes: associated pathologies and return to sport following arthroscopic decompression. *Knee Surg Sports Traumatol Arthrosc* 15 (7):908-914.
118. Philippon MJ, Briggs KK, Yen YM, Kuppersmith DA (2009) Outcomes following hip arthroscopy for femoroacetabular impingement with associated chondrolabral dysfunction: minimum two-year follow-up. *J Bone Joint Surg Br* 91 (1):16-23.
119. Piuze NS, Slullitel PA, Bertona A, Onativia IJ, Albergio I, Zanotti G, Buttaro MA, Piccaluga F, Comba FM (2015) Hip arthroscopy in osteoarthritis: a systematic review of the literature. *Hip Int-O*. doi:10.5301/hipint.5000299
120. Pollard TC, Villar RN, Norton MR, Fern ED, Williams MR, Murray DW, Carr AJ (2010) Genetic influences in the aetiology of femoroacetabular impingement: a sibling study. *J Bone Joint Surg Br* 92 (2):209-216.
121. Pollard TC, Villar RN, Norton MR, Fern ED, Williams MR, Simpson DJ, Murray DW, Carr AJ (2010) Femoroacetabular impingement and classification of the cam deformity: the reference interval in normal hips. *Acta Orthop* 81 (1):134-141.

122. Pugely AJ, Martin CT, Harwood J, Ong KL, Bozic KJ, Callaghan JJ (2015) Database and Registry Research in Orthopaedic Surgery: Part 2: Clinical Registry Data. *J Bone Joint Surg Am* 97 (21):1799-1808.
123. Rabin R, de Charro F (2001) EQ-5D: a measure of health status from the EuroQol Group. *Annals of medicine* 33 (5):337-343
124. Ranawat AS, McClincy M, Sekiya JK (2009) Anterior dislocation of the hip after arthroscopy in a patient with capsular laxity of the hip. A case report. *J Bone Joint Surg Am* 91 (1):192-197.
125. Redmond JM, El Bitar YF, Gupta A, Stake CE, Vemula SP, Domb BG (2015) Arthroscopic acetabuloplasty and labral refixation without labral detachment. *Am J Sports Med* 43 (1):105-112.
126. BOA-registry (2014), annual report. www.boaregistret.se
127. Reichenbach S, Leunig M, Werlen S, Nuesch E, Pfirrmann CW, Bonel H, Odermatt A, Hofstetter W, Ganz R, Juni P (2011) Association between cam-type deformities and magnetic resonance imaging-detected structural hip damage: a cross-sectional study in young men. *Arthritis Rheum* 63 (12):4023-4030.
128. Roach KE, Miles TP (1991) Normal hip and knee active range of motion: the relationship to age. *Phys Ther* 71 (9):656-665
129. Rolfson O, Strom O, Karrholm J, Malchau H, Garellick G (2012) Costs related to hip disease in patients eligible for total hip arthroplasty. *J Arthroplasty* 27 (7):1261-1266.
130. Ross JR, Bedi A, Clohisy JC, Gagnier JJ, Larson CM (2015) Surgeon Willingness to Participate in Randomized Controlled Trials for the Treatment of Femoroacetabular Impingement. *Arthroscopy*. doi:10.1016/j.arthro.2015.07.003
131. Ross JR, Bedi A, Stone RM, Sibilsky Enselman E, Kelly BT, Larson CM (2015) Characterization of symptomatic hip impingement in butterfly ice hockey goalies. *Arthroscopy* 31 (4):635-642.
132. Ross JR, Tannenbaum EP, Nepple JJ, Kelly BT, Larson CM, Bedi A (2015) Functional Acetabular Orientation Varies Between Supine and Standing Radiographs: Implications for Treatment of Femoroacetabular Impingement. *Clin Orthop Relat Res*. doi:10.1007/s11999-014-4104-x
133. Saksena S, Slee A, Waldo AL, Freemantle N, Reynolds M, Rosenberg Y, Rathod S, Grant S, Thomas E, Wyse DG (2011) Cardiovascular outcomes in the AFFIRM Trial (Atrial Fibrillation Follow-Up Investigation of Rhythm Management). An assessment of individual antiarrhythmic drug therapies compared with rate control with propensity score-matched analyses. *J Am Coll Cardiol* 58 (19):1975-1985.
134. Sankar WN, Nevitt M, Parvizi J, Felson DT, Agricola R, Leunig M (2013) Femoroacetabular impingement: defining the condition and its role in the pathophysiology of osteoarthritis. *J Am Acad Orthop Surg* 21 Suppl 1:S7-S15.
135. Sansone M, Ahlden M, Jonasson P, Sward L, Eriksson T, Karlsson J (2013) Total dislocation of the hip joint after arthroscopy and ileopsoas tenotomy. *Knee Surg Sports Traumatol Arthrosc* 21 (2):420-423.
136. Sansone M, Ahlden M, Jonasson P, Thomee R, Falk A, Sward L, Karlsson J (2014) Can hip impingement be mistaken for tendon pain in the groin? A long-term follow-up of tenotomy for groin pain in athletes. *Knee Surg Sports Traumatol Arthrosc* 22 (4):786-792.
137. Schilders E, Dimitrakopoulou A, Bismil Q, Marchant P, Cooke C (2011) Arthroscopic treatment of labral tears in femoroacetabular impingement: A comparative study of refixation and resection with a minimum two-year follow-up. *J Bone Joint Surg Br* 93 (8):1027-1032. doi:10.1302/0301-620X.93B8.26065
138. Schmid MR, Notzli HP, Zanetti M, Wyss TF, Hodler J (2003) Cartilage lesions in the hip: diagnostic effectiveness of MR arthrography. *Radiology* 226 (2):382-386.
139. Shu B, Safran MR (2011) Hip instability: anatomic and clinical considerations of traumatic and atraumatic instability. *Clin Sports Med* 30 (2):349-367.
140. Siebenrock KA, Behning A, Mamisch TC, Schwab JM (2013) Growth plate alteration precedes cam-type deformity in elite basketball players. *Clin Orthop Relat Res* 471 (4):1084-1091.
141. Siebenrock KA, Ferner F, Noble PC, Santore RF, Werlen S, Mamisch TC (2011) The cam-type deformity of the proximal femur arises in childhood in response to vigorous sporting activity. *Clin Orthop Relat Res* 469 (11):3229-3240.
142. Siebenrock KA, Kaschka I, Frauchiger L, Werlen S, Schwab JM (2013) Prevalence of cam-type deformity and hip pain in elite ice hockey players before and after the end of growth. *Am J Sports Med* 41 (10):2308-2313.
143. Siewers M (1998) [Injury profile in school sports. A sports medicine analysis in an annual report on schools]. *Sportverletz Sportschaden* 12 (1):31-35.

144. Silvis ML, Mosher TJ, Smetana BS, Chinchilli VM, Flemming DJ, Walker EA, Black KP (2011) High prevalence of pelvic and hip magnetic resonance imaging findings in asymptomatic collegiate and professional hockey players. *Am J Sports Med* 39 (4):715-721.
145. Smith MV, Sekiya JK (2010) Hip instability. *Sports Med Arthrosc* 18 (2):108-112.
146. Smith-Petersen MN (2009) *The classic: Treatment of malum coxae senilis, old slipped upper femoral epiphysis, intrapelvic protrusion of the acetabulum, and coxa plana by means of acetabuloplasty. 1936.* *Clin Orthop Relat Res* 467 (3):608-615.
147. Spahn G, Hofmann GO (2014) [Focal cartilage defects within the medial knee compartment. predictors for osteoarthritis progression]. *Z Orthop Unfall* 152 (5):480-488.
148. Spahn G, Schiele R, Langlotz A, Jung R (2005) Hip pain in adolescents: results of a cross-sectional study in German pupils and a review of the literature. *Acta Paediatr* 94 (5):568-573.
149. Steppacher SD, Lerch TD, Gharanizadeh K, Liechti EF, Werlen SF, Puls M, Tannast M, Siebenrock KA (2014) Size and shape of the lunate surface in different types of pincer impingement: theoretical implications for surgical therapy. *Osteoarthritis Cartilage* 22 (7):951-958.
150. Stulberg SD, Cooperman DR, Wallensten R (1981) The natural history of Legg-Calve-Perthes disease. *J Bone Joint Surg Am* 63 (7):1095-1108
151. Sutter R, Dietrich TJ, Zingg PO, Pfirrmann CW (2012) Femoral antetorsion: comparing asymptomatic volunteers and patients with femoroacetabular impingement. *Radiology* 263 (2):475-483.
152. Sward L, Hellstrom M, Jacobsson B, Nyman R, Peterson L (1990) Acute injury of the vertebral ring apophysis and intervertebral disc in adolescent gymnasts. *Spine* 15 (2):144-148
153. Sward L, Hellstrom M, Jacobsson B, Peterson L (1990) Back pain and radiologic changes in the thoracolumbar spine of athletes. *Spine* 15 (2):124-129
154. Tak I, Weir A, Langhout R, Waarsing JH, Stubbe J, Kerkhoffs G, Agricola R (2015) The relationship between the frequency of football practice during skeletal growth and the presence of a cam deformity in adult elite football players. *Br J Sports Med.* doi:10.1136/bjsports-2014-094130
155. Tannast M, Goricki D, Beck M, Murphy SB, Siebenrock KA (2008) Hip damage occurs at the zone of femoroacetabular impingement. *Clin Orthop Relat Res* 466 (2):273-280.
156. Tanzer M, Noiseux N (2004) Osseous abnormalities and early osteoarthritis: the role of hip impingement. *Clin Orthop Relat Res* (429):170-177
157. Tegner Y, Lyschold J (1985) Rating systems in the evaluation of knee ligament injuries. *Clin Orthop Relat Res* (198):43-49
158. Telleria JJ, Lindsey DP, Giori NJ, Safran MR (2011) An anatomic arthroscopic description of the hip capsular ligaments for the hip arthroscopist. *Arthroscopy* 27 (5):628-636.
159. Telleria JJ, Lindsey DP, Giori NJ, Safran MR (2014) A quantitative assessment of the insertional footprints of the hip joint capsular ligaments and their spanning fibers for reconstruction. *Clin Anat* 27 (3):489-497.
160. Telleria JJ, Safran MR, Harris AH, Gardi JN, Glick JM (2012) Risk of sciatic nerve traction injury during hip arthroscopy-is it the amount or duration? An intraoperative nerve monitoring study. *J Bone Joint Surg Am* 94 (22):2025-2032.
161. Thomas GE, Palmer AJ, Batra RN, Kiran A, Hart D, Spector T, Javaid MK, Judge A, Murray DW, Carr AJ, Arden NK, Glynn-Jones S (2014) Subclinical deformities of the hip are significant predictors of radiographic osteoarthritis and joint replacement in women. A 20 year longitudinal cohort study. *Osteoarthritis Cartilage* 22 (10):1504-1510.
162. Thomee R, Jonasson P, Thorborg K, Sansone M, Ahlden M, Thomee C, Karlsson J, Baranto A (2013) Cross-cultural adaptation to Swedish and validation of the Copenhagen Hip and Groin Outcome Score (HAGOS) for pain, symptoms and physical function in patients with hip and groin disability due to femoroacetabular impingement. *Knee Surg Sports Traumatol Arthrosc.* Apr;22(4):835-42.
163. Thomee R, Jonasson P, Thorborg K, Sansone M, Ahlden M, Thomee C, Karlsson J, Baranto A (2014) Cross-cultural adaptation to Swedish and validation of the Copenhagen Hip and Groin Outcome Score (HAGOS) for pain, symptoms and physical function in patients with hip and groin disability due to femoroacetabular impingement. *Knee Surg Sports Traumatol Arthrosc* 22 (4):835-842.
164. Thorborg K, Holmich P, Christensen R, Petersen J, Roos EM (2011) The Copenhagen Hip and Groin Outcome Score (HAGOS): development and validation according to the COSMIN checklist. *Br J Sports Med* 45 (6):478-491.

165. Thorborg K, Hölmich P, Christensen R, Petersen J, Roos EM (2011) *The Copenhagen Hip and Groin Outcome Score (HAGOS): development and validation according to the COSMIN checklist*. *British journal of sports medicine* 45 (6):478-491.
166. Tibor LM, Leunig M (2012) *The pathoanatomy and arthroscopic management of femoroacetabular impingement*. *Bone & joint research* 1 (10):245-257.
167. Tijssen M, van Cingel R, Willemsen L, de Visser E (2012) *Diagnostics of femoroacetabular impingement and labral pathology of the hip: a systematic review of the accuracy and validity of physical tests*. *Arthroscopy* 28 (6):860-871.
168. Tonnis D, Heinecke A (1999) *Acetabular and femoral anteversion: relationship with osteoarthritis of the hip*. *J Bone Joint Surg Am* 81 (12):1747-1770
169. Tveit M, Rosengren BE, Nilsson JA, Karlsson MK (2012) *Former male elite athletes have a higher prevalence of osteoarthritis and arthroplasty in the hip and knee than expected*. *Am J Sports Med* 40 (3):527-533.
170. van Leeuwen KM, Bosmans JE, Jansen AP, Hoogendijk EO, van Tulder MW, van der Horst HE, Ostelo RW (2015) *Comparing measurement properties of the EQ-5D-3L, ICECAP-O, and ASCOT in frail older adults*. *Value in health : the journal of the International Society for Pharmacoeconomics and Outcomes Research* 18 (1):35-43.
171. Verrall GM, Hamilton IA, Slavotinek JP, Oakeshott RD, Spriggins AJ, Barnes PG, Fon GT (2005) *Hip joint range of motion reduction in sports-related chronic groin injury diagnosed as pubic bone stress injury*. *J Sci Med Sport* 8 (1):77-84
172. Wall PD, Fernandez M, Griffin DR, Foster NE (2013) *Nonoperative treatment for femoroacetabular impingement: a systematic review of the literature*. *Pm R* 5 (5):418-426.
173. Walters SJ, Brazier JE (2005) *Comparison of the minimally important difference for two health state utility measures: EQ-5D and SF-6D*. *Quality of life research : an international journal of quality of life aspects of treatment, care and rehabilitation* 14 (6):1523-1532
174. Yeung M, Jamshidi S, Horner N, Simunovic N, Karlsson J, Ayeni OR (2015) *Efficacy of Nonsteroidal Anti-Inflammatory Drug Prophylaxis for Heterotrophic Ossification in Hip Arthroscopy: A Systematic Review*. *Arthroscopy*. doi:10.1016/j.arthro.2015.08.007
175. Yoshio M, Murakami G, Sato T, Sato S, Noriyasu S (2002) *The function of the psoas major muscle: passive kinetics and morphological studies using donated cadavers*. *Journal of orthopaedic science : official journal of the Japanese Orthopaedic Association* 7 (2):199-207.
176. Zaltz I, Kelly BT, Hetsroni I, Bedi A (2013) *The crossover sign overestimates acetabular retroversion*. *Clin Orthop Relat Res* 471 (8):2463-2470.

13

MIKAEL SANSONE

APPENDIX



GÖTEBORGS UNIVERSITET

Höftenkät

*Förnamn:

*Efternamn:

*Personnummer: (ååååmmdd-xxxx)

*Telefonnummer:

*E-Mail:

*Skadad sida: Höger Vänster Båda


iHOT¹²

INTERNATIONAL
HIP OUTCOME TOOL


FORMULÄR OM LIVSKVALITÉ HOS UNGA AKTIVA MÄNNISKOR MED HÖFTPROBLEM

Instruktioner

- Nedan följer 12 frågor om de besvär som du kan uppleva i din höft, hur dessa besvär påverkar ditt liv och de känslor du känner som följd av dessa besvär.
- På varje fråga skall du flytta markören till det läge på skalan som du anser bäst överensstämmer med dina besvär.
 - Om du markerar längst ut till vänster betyder det att du känner dig påtagligt begränsad.



- Om du markerar längst ut till höger betyder det att du inte har några problem alls.



- Om markeringen placeras mitt på skalan betyder det att du är måttligt begränsad, eller med andra ord, mitt emellan 'påtagligt begränsad' och 'inga problem alls'. Det är viktigt att du markerar ända ut i kanten av skalan om det är ytterligheten som bäst beskriver din situation.

- Vänligen låt dina svar beskriva den typiska situationen **senaste månaden**.

- **TIPS** Om du inte utför en aktivitet, föreställ dig hur det skulle kännas i din höft om du var tvungen att utföra aktiviteten.

När du ställt in markören för en fråga i önskat läge, tryck på "Klar med frågan" så att det står "Klar!" i rutan bredvid.

F1. Totalt sett, hur mycket smärta har du i din höft/ljumske?

EXTREM
SMÄRTA



INGEN SMÄRTA
ALLS

Klar med frågan

Ej klar

EQ-5D

Hälsoenkät

Svensk version

(Swedish version)

Markera, genom att klicka i ett alternativ i varje nedanstående grupp vilket påstående som bäst beskriver Ditt hälsotillstånd i dag.

1. Rörlighet

- Jag går utan svårigheter
- Jag kan gå men med viss svårighet
- Jag är sängliggande

2. Hygien

- Jag behöver ingen hjälp med min dagliga hygien, mat eller påklädning
- Jag har vissa problem att tvätta eller klä mig själv
- Jag kan inte tvätta eller klä mig själv

3. Huvudsakliga aktiviteter (t ex arbete, studier, hushållssysslor, familje- och fritidsaktiviteter)

- Jag klarar av mina huvudsakliga aktiviteter
- Jag har vissa problem med att klara av mina huvudsakliga aktiviteter
- Jag klarar inte av mina huvudsakliga aktiviteter

4. Smärtor/besvär

- Jag har varken smärtor eller besvär
- Jag har måttliga smärtor eller besvär
- Jag har svåra smärtor eller besvär

5. Oro/nedstämdhet

- Jag är inte orolig eller nedstämd
- Jag är orolig eller nedstämd i viss utsträckning
- Jag är i högsta grad orolig eller nedstämd

HAGOS

Frågeformulär om höft- och/eller lumskeproblem

VÄGLEDNING: Detta frågeformulär innehåller frågor om hur din höft och/eller lumske fungerar. Du skall ange hur din höft och/eller lumske har fungerat under den **senaste veckan**.

Svaren skall hjälpa oss att kunna förstå hur du har det och hur bra du klarar dig i vardagen.

Du skall besvara frågorna genom att markera det alternativ som passar dig bäst.

Om en fråga inte gäller dig eller om du inte upplevt besväret under den senaste veckan, så ange det alternativ som passar bäst in och som du känner dig mest nöjd med.

Symptom

Tänk på de **symptom** och besvär du har haft i din höft och/eller lumske under den **senaste veckan** när du svarar på följande frågor.

S1. Har du malande/obehag i höften och/eller lumsken?

Aldrig Sällan Ibland Ofta Alltid

S2. Har du hört klickande eller andra ljud från höften och/eller lumsken?

Aldrig Sällan Ibland Ofta Hela tiden

S3. Har du problem med att få benen långt ut åt sidan?

Inga Lite Måttliga Stora Mycket stora

S4. Har du problem med att ta steget fullt ut när du går?

Inga Lite Måttliga Stora Mycket stora

S5. Får du plötsliga stickande/pirrande förmimmelser i höften och/eller lumsken?

Aldrig Sällan Ibland Ofta Hela tiden

Stelhet

Följande frågor handlar om stelhet i höften och/eller lumsken. Stelhet medför besvär att komma

HAGOS

Smärtor

P1. Hur ofta har du ont i höften och/eller lumsken?

Aldrig Varje månad Varje vecka Varje dag Alltid

P2. Hur ofta har du ont på andra ställen än i höften och/eller lumsken som du tycker hänger ihop med dina höft- och/eller lumskproblem?

Aldrig Varje månad Varje vecka Varje dag Alltid

Följande frågor handlar om hur mycket smärta i höften och/eller lumsken under den **senaste veckan**. Ange **graden av höft- och/eller lumsksmärta du har upplevt i följande situationer**.

P3. Sträcka ut höften helt och hållet

Ingen Lätt Måttlig Svår Mycket svår

P4. Böja höften helt och hållet

Ingen Lätt Måttlig Svår Mycket svår

P5. Gå upp- eller nedför trappor

Ingen Lätt Måttlig Svår Mycket svår

P6. Om natten när du ligger ned (smärtor som förstör din sömn)

Ingen Lätt Måttlig Svår Mycket svår

P7. Sitta eller ligga

Ingen Lätt Måttlig Svår Mycket svår

P8. Stående

Ingen Lätt Måttlig Svår Mycket svår

HAGOS

Fysisk funktion, dagliga aktiviteter

Följande frågor handlar om din fysiska funktion. Ange graden av besvär du har haft i följande situationer under den senaste veckan, på grund av din höft och/eller ljumske.

A1. Gå uppför trappor

Inga	Lätta	Måttliga	Stora	Mycket stora
<input type="radio"/>	<input type="radio"/>	<input type="radio"/>	<input type="radio"/>	<input type="radio"/>

A2. Böja dig ner, tex för att plocka upp något från golvet

Inga	Lätta	Måttliga	Stora	Mycket stora
<input type="radio"/>	<input type="radio"/>	<input type="radio"/>	<input type="radio"/>	<input type="radio"/>

A3. Kliva i/ur bil

Inga	Lätta	Måttliga	Stora	Mycket stora
<input type="radio"/>	<input type="radio"/>	<input type="radio"/>	<input type="radio"/>	<input type="radio"/>

A4. Ligga i sängen (vända dig eller hålla höften i samma läge under lång tid)

Inga	Lätta	Måttliga	Stora	Mycket stora
<input type="radio"/>	<input type="radio"/>	<input type="radio"/>	<input type="radio"/>	<input type="radio"/>

A5. Utföra tungt hushållsarbete (tvätta golv, dammsuga, flytta tunga lådor eller liknande)

Inga	Lätta	Måttliga	Stora	Mycket stora
<input type="radio"/>	<input type="radio"/>	<input type="radio"/>	<input type="radio"/>	<input type="radio"/>

Nästa

HAGOS

Funktion, sport och fritid

Följande frågor handlar om din fysiska förmåga. Om en fråga inte gäller dig eller om du inte upplevt besväret under den senaste veckan, så ange det alternativ som passar bäst in och som du känner dig mest nöjd med.

Ange vilken grad av besvär du har haft i följande aktiviteter under den senaste veckan, på grund av problem med din höft och/eller ljumske.

SP1. Sitta på huk

Inga	Lätta	Måttliga	Stora	Mycket stora
<input type="radio"/>	<input type="radio"/>	<input type="radio"/>	<input type="radio"/>	<input type="radio"/>

SP2. Springa

Inga	Lätta	Måttliga	Stora	Mycket stora
<input type="radio"/>	<input type="radio"/>	<input type="radio"/>	<input type="radio"/>	<input type="radio"/>

SP3. Vrida/snurra kroppen när du står på benet

Inga	Lätta	Måttliga	Stora	Mycket stora
<input type="radio"/>	<input type="radio"/>	<input type="radio"/>	<input type="radio"/>	<input type="radio"/>

SP4. Gå på ojämnt underlag

Inga	Lätta	Måttliga	Stora	Mycket stora
<input type="radio"/>	<input type="radio"/>	<input type="radio"/>	<input type="radio"/>	<input type="radio"/>

SP5. Springa så snabbt du kan

Inga	Lätta	Måttliga	Stora	Mycket stora
<input type="radio"/>	<input type="radio"/>	<input type="radio"/>	<input type="radio"/>	<input type="radio"/>

SP6. Föra benet framåt kraftigt och/eller till sidan, exempelvis som vid en spark, skridskosteg eller liknande

Inga	Lätta	Måttliga	Stora	Mycket stora
<input type="radio"/>	<input type="radio"/>	<input type="radio"/>	<input type="radio"/>	<input type="radio"/>

SP7. Plötsliga, explosiva rörelser som involverar snabba fotrörelser, exempelvis accelerationer, uppbromsningar, riktningförändringar eller liknande

HAGOS

Delta i fysisk aktivitet

Följande frågor handlar om din förmåga att delta i fysiska aktiviteter. Med fysiska aktiviteter menas idrottsaktiviteter, men även andra aktiviteter, där man blir lätt andfädd.

Ange i vilken grad din förmåga att delta i önskade fysiska aktiviteter har varit påverkade under senaste veckan, på grund av dina problem med din höft och/eller lumske.

PA1. Kan du delta i dina önskade fysiska aktiviteter så länge du vill?

Alltid Ofta Ibland Sällan Aldrig

PA2. Kan du delta i dina önskade fysiska aktiviteter på din normala prestationsnivå?

Alltid Ofta Ibland Sällan Aldrig

Livskvalitet

Q1. Hur ofta blir du påmind om dina problem med höften och/eller lumsken?

Aldrig Varje månad Varje vecka Varje dag Alltid

Q2. Har du ändrat ditt sätt att leva för att undgå att påfresta höften och/eller lumsken?

Inget alls Något Måttligt I stor utsträckning Totalt

Q3. Hur stora problem har du generellt med din höft och/eller lumske?

Inga Lätta Måttliga Stora Mycket stora

Q4. Påverkar dina problem med höften och/eller lumsken ditt humör i en negativ riktning?

Aldrig Sällan Ibland Ofta Alltid

Q5. Känner du dig begränsad på grund av problem med din höft och/eller lumske?



GÖTEBORGS UNIVERSITET

Höftenkät

Hur skulle du skatta din höfffunktion på en skala 0 - 100?
0 = extremt dålig funktion och 100 = perfekt funktion.

Skulle du göra om operationen om du var i samma situation igen?

- Ja
- Nej
- Ej opererad

HSAS

Hip Sports Activity Scale - Swedish

Uppskatta din aktivitetsnivå vid olika tidpunkter enligt skalan nedan. Fyll i den siffra som stämmer bäst.

Uppskatta din nuvarande aktivitetsnivå (oavsett om du är opererad eller inte). (0-8)

Uppskatta din aktivitetsnivå som den var innan du fick symptom från höften. (0-8)

Uppskatta din aktivitetsnivå som den var i yngre tonåren (10-15 års ålder). (0-8)

Nästa

8	Tävlingsidrott (nationell och internationell elitnivå) Fotboll, Ishockey, Innebandy, Kampsport, Tennis, Friidrott, Inomhusaktiviteter, Beachvolleyboll
7	Tävlingsidrott (nationell och internationell elitnivå) Alpin skidåkning, Snowboard, Konståkning, Skridsko, Dans Tävlingsidrott (lägre divisioner) Fotboll, Ishockey, Innebandy, Kampsport, Tennis, Friidrott, Inomhusaktiviteter, Beachvolleyboll
6	Tävlingsidrott (nationell och internationell elitnivå) Golf, Cykel, Mountainbike, Simning, Rodd, Längdskidåkning, Ridning Tävlingsidrott (lägre divisioner) Alpin skidåkning, Snowboard, Konståkning, Skridsko, Dans
5	Tävlingsidrott (lägre divisioner) Golf, Cykel, Mountainbike, Simning, Rodd, Längdskidåkning, Ridning Motionsidrott Ishockey, Innebandy, Kampsport, Fotboll, Friidrott, Beachvolleyboll
4	Motionsidrott Tennis, Alpin skidåkning, Snowboard, Inomhusaktiviteter
3	Motionsidrott Jympa/Aerobics, Jogging, Styrketräning av benen, Ridning
2	Motionsidrott Cykel, Mountainbike, Längdskidåkning, skridsko, Golf, Dans, Inlines
1	Motionsidrott Simning, Promenader, Gång
0	Ingen motions- eller tävlingsidrott

Höftregisterparametrar

Dagens datum

Personnummer

Namn

 Hö Vä

Ev idrott

Symtomduration:

år

mån

Re-operation:

Ja

Nej

Diagnos:

CAM

Pincer

Mixed

Chondromatos

Psoastendinos

Teres

Fri kropp

Labrumskada

Artros

Annan orsak _____

Intern snapping hip

Extern snapping hip

Cystor acetabulum

Cystor caput/collum

Broskskada:

Ingen brotskada

Lokal:

ACETABULUM

Orsak:

Impingement

Trauma

OA

OCD

Iatrogen

Annat.....

Konans broskklassifikation:

0 Normal

1 Softening
or wave sign

2 Cleavage
lesion

3 Delamination

4 Exposed bone

a b c

a b c

a b c

a = < 1/3 av avståndet mellan labrum och fossan.
c = > 2/3 av avståndet mellan labrum och fossan.

b = > 1/3 av avståndet mellan labrum och fossan

Lokal:

CAPUT

Orsak:

Impingement Trauma OA OCD Iatrogen Annat.....

ICRS:

0 Normal 1 Nearly normal 2 Ab-normal 3 Sverely abnormal >50% djup 4 Seveverely abnormal, ned till ben

Åtgärder:

Resektion: CAM Pincer Mediala osteofyter
Labrum: Sutur Debridering Resektion
Psoas: Debridering Tenotomi
Teres: Resektion Debridering
Excision : Fri kropp Lat plica

Mikrofrakturering
 Synovektomi
 Trochanterburssektomi
 Annat

Op-datum Längd..... Vikt.....

Op-tid:.....

Sträcktid:.....

Dagkir: Ja Nej

Avvikelse: Mycket blödning Leden gick ej att se Annat

Komplikationer: beskriv.....
.....
.....

Operatör:.....

Assistent:.....

Övrigt:.....

Classification system for acetabular chondral lesions according to Konan et al. (Konan, Rayan 2011).

Cartilage damage classification	Description
0	Normal cartilage
1	Wave sign
2	Cleavage tear between labrum and articular cartilage
3	Delamination of articular cartilage
4	Exposed bone in the acetabulum
A	< one-third of the distance from the acetabular rim to the cotyloid fossa
B	One-third to two-thirds of distance above
C	> two-thirds of distance above

14

MIKAEL SANSONE

PAPERS
