

**SHOULDER IMPINGEMENT;
EVALUATION OF THE CLINICAL
OUTCOME, RADIOGRAPHIC
FINDINGS, HISTOLOGY,
ULTRASTRUCTURE AND
BIOCHEMISTRY**

Stefanos Farfaras

Department of Orthopaedics
Institute of Clinical Sciences
Sahlgrenska Academy, University of Gothenburg
Sweden



UNIVERSITY OF GOTHENBURG

Gothenburg 2018

Shoulder impingement; evaluation of the clinical outcome, radiographic findings, histology, ultrastructure and biochemistry.

© Stefanos Farfaras 2018

stefanos.farfaras@vgregion.se/farfarasst@gmail.com

ISBN 978-91-7833-215-1(PRINT)

ISBN 978-91-7833-216-8 (PDF)

<http://hdl.handle.net/2077/56890>

Printed in Gothenburg, Sweden, 2018

BrandFactory AB

Graphic design: Max Kartus, Maxitup AB

Cover illustration: Catarina Kartus

“Ο βίος βραχύς,
η δε τέχνη μακρή,
ο δε καιρός οξύς,
η δε πείρα σφαλερή,
η δε κρίσις χαλεπή.”
Ιπποκράτης

“Life is short,
art long,
opportunity fleeting,
experiment dangerous,
judgment difficult.”
Hippocrates

To my family

CONTENT

I	ABSTRACT	6
II	SAMMANFATTNING PÅ SVENSKA	7
III	ΠΕΡΙΛΗΨΗ ΣΤΑ ΕΛΛΗΝΙΚΑ	8
IV	LIST OF PAPERS	10
V	ABBREVIATIONS	11
VI	BRIEF DEFINITIONS	12
1	INTRODUCTION	14
1.1	SUMMARY	14
1.2	ANATOMY OF THE SHOULDER	14
1.3	EPIDEMIOLOGY	18
1.4	CLASSIFICATION AND PATHOPHYSIOLOGY	18
1.5	TREATMENT ALTERNATIVES	23
2	AIMS	25
3	PATIENTS	26
4	METHODS	29
4.1	CLINICAL EVALUATION OF DIFFERENT TREATMENTS (STUDIES I & II)	29
4.2	SURGICAL TECHNIQUES (STUDIES I & II)	29
4.3	CLINICAL ASSESSMENTS (STUDIES I & II)	32
4.4	PATHOPHYSIOLOGY OF SAIS (HISTOLOGY, ULTRASTRUCTURE AND BIOCHEMISTRY (STUDIES III & IV)	36
4.5	STATISTICAL METHODS	40
4.6	ETHICS	41
5	RESULTS	42
5.1	STUDY I	42
5.2	STUDY II	42
5.3	STUDY III	43
5.4	STUDY IV	43

6	DISCUSSION	46
6.1	CLINICAL OUTCOME IN THE SHORT TERM	46
6.2	CLINICAL OUTCOME IN THE LONG TERM	47
6.3	PROMS IN THE SHORT TERM	48
6.4	PROMS IN THE LONG TERM	48
6.5	ROTATOR CUFF TEARS IN THE LONG TERM	49
6.6	OSTEOARTHRITIS DEVELOPMENT IN THE LONG TERM	49
6.7	SOFT-TISSUE DEGENERATION	49
6.8	SOFT-TISSUE INFLAMMATION	52
7	STRENGTHS AND LIMITATIONS	54
8	CONCLUSIONS	56
9	FINAL CONSIDERATIONS - FUTURE PERSPECTIVES	57
10	ACKNOWLEDGEMENTS	59
11	REFERENCES	61
12	PAPERS I-IV	71

I. ABSTRACT

This thesis had two main purposes: on the one hand, to assess and evaluate the clinical outcome of different treatment strategies for subacromial impingement syndrome (SAIS), in both the short and the long term and, on the other hand, to investigate and illuminate the pathophysiology of the syndrome in terms of the radiographic, histological, ultrastructural and biochemical appearance.

In Study I, the clinical outcome was assessed two to three years after intervention, in patients with SAIS who underwent either surgical (subacromial decompression using the open or arthroscopic technique) or non-surgical treatment. Eighty-seven patients with SAIS were randomised to three groups: open acromioplasty (OSG), arthroscopic acromioplasty (ASG) or physical treatment (PTG). The main outcome measurement, the Constant Score, showed no significant difference when comparing the three groups before intervention and at follow-up. However, when comparing each group separately over time, the two surgical groups had improved significantly at follow-up. The Watson & Sonnabend score had improved significantly for more parameters in the OSG, compared with both the ASG and PTG. Furthermore, the OSG revealed a better outcome for strength measurement at follow-up. In Study II, the same group of patients was assessed, a minimum of 10 years after intervention, for the same clinical outcomes. In addition, the development of osteoarthritis (OA) and rotator cuff tears was assessed. In the long term, the surgical groups revealed a better outcome. The Constant Score increased significantly more over time (baseline vs follow-up), for

both the OSG and the ASG compared with the PTG. Moreover, the OSG had a significantly better Constant Score compared with the PTG, when comparing the three groups. Both surgical groups also revealed better strength and better active elevation. Radiographically, no differences in OA or rotator cuff tears were found between the three treatment groups.

In Study III, the histological and ultrastructural appearance of tissue samples from the subscapularis tendon and joint capsule were assessed. Male patients with SAIS were compared with male patients with recurrent shoulder dislocations, in terms of degenerative signs. The fibril diameter and the Total Degeneration Score (TDS) were assessed. The SAIS group was significantly older than the instability group, but the correlation coefficient between age and fibril diameter was $r = -0.20$ for the subscapularis tendon and $r = -0.25$ for the capsule. The instability group had significantly “thicker” fibrils compared with the SAIS group and a better TDS. This indicates the presence of a degenerative process in patients with SAIS. In Study IV, the expression of different inflammatory markers in the same population was assessed. The analysis of the samples revealed a significantly larger amount of interleukin-6 (IL-6) and tumour necrosis factor- α (TNF- α) in the subscapularis tendon of patients with SAIS. In the capsular samples, a significantly higher TNF- α and cluster of differentiation 72 (CD 72), a marker of B-cell activity, was found. This indicates that an inflammatory process is present in patients with SAIS, both in the subscapularis tendon and in the adjacent joint capsule.

II. SAMMANFATTNING PÅ SVENSKA

Denna avhandling hade två huvudsyften. Det första var att utforska och utvärdera det kliniska utfallet av olika behandlingsalternativ för subakromiell inklämningsmärta (SAIS) på kort- och lång sikt. Det andra var att undersöka patofysiologin hos patienter med SAIS avseende såväl radiologiska som histologiska, ultrastrukturella och biokemiska förändringar.

I Studie I, en kliniskt randomiserad studie, analyserades det kliniska utfallet hos patienter med SAIS 2 till 3 år efter behandlingen. Patienterna behandlades med akromioplastik (antingen öppet eller artroskopiskt) eller med fysioterapi. Åttiosju patienter med SAIS randomiserades i tre grupper; öppen akromioplastik (OSG), artroskopisk akromioplastik (ASG) eller fysioterapi (PTG). Det primära utfallsmåttet, Constant score, uppvisade ingen signifikant skillnad mellan de tre grupperna både före behandling och vid uppföljning. Däremot, när man analyserade varje grupp separat över tid, visade det sig att båda kirurgiska grupperna signifikant förbättrat sin Constant score. Avseende Watson & Sonnabend score hade OSG signifikant förbättrats i flera parametrar jämfört med både ASG och PTG. Dessutom hade OSG bättre utfall avseende styrkemätningar vid uppföljningen jämfört med de andra två grupperna. I Studie II analyserades samma grupp av patienter för samma utfallsmått, minimum 10 år efter behandlingen. Dessutom undersöktes förekomsten av artros och rotatorckuff rupturer. Constant score var signifikant högre över tid, för OSG och ASG men inte för PTG.

OSG hade även signifikant bättre Constant score jämfört PTG när resultat mellan grupperna analyserades. Dessutom hade de två kirurgiska grupperna bättre styrka och aktiv elevation vid uppföljningen. Däremot förelåg ingen skillnad vad gäller utveckling av artros och rotatorckuff rupturer mellan de tre grupperna.

I Studie III undersöktes biopsier från subskapularis senan och ledkapseln histologiskt och ultrastrukturellt. Enbart manliga individer inkluderades i denna studie. Patienter med SAIS jämfördes med patienter med recidiverande axelluxationer avseende tecken till degeneration. Fibrilldiameter och Total Degeneration Score (TDS) analyserades. Patienterna i SAIS gruppen var signifikant äldre. Korrelationskoefficienten mellan ålder och fibrilldiameter var dock låg, ($r = -0,20$ för subskapularis senan och $r = -0,25$ för ledkapseln). Patienter med recidiverande axelluxation hade signifikant grövre fibriller jämfört med SAIS patienter och även bättre TDS. I Studie IV undersöktes samma grupp av patienter avseende olika inflammatoriska markörer i subskapularis senan och ledkapseln. Signifikant högre Interleukin-6 (IL-6) och tumor necrosis factor- α (TNF- α) förelåg i subskapularis senan hos patienter med SAIS. I ledkapseln förelåg signifikant mer TNF- α och Cluster of Differentiation 72 (CD 72), som är en specifik markör för B-cells aktivitet. Detta indikerar att det finns en inflammatorisk process hos patienter med SAIS både i subskapularis senan och i ledkapseln.

III. ΠΕΡΙΛΗΨΗ ΣΤΑ ΕΛΛΗΝΙΚΑ

Η παρούσα διατριβή είχε δύο κύριους σκοπούς. Απ' τη μια μεριά να αναλύσει και να εκτιμήσει το κλινικό αποτέλεσμα διαφόρων μεθόδων θεραπείας για το σύνδρομο υπακρωμιακής προστριβής (SAIS), βραχυπρόθεσμα και μακροπρόθεσμα. Απ' την άλλη να διερευνήσει και να διαφωτίσει τους παθοφυσιολογικούς μηχανισμούς που εμπλέκονται στη δημιουργία του συνδρόμου, τόσο σε μικροσκοπικό (ιστολογικό, δομικό, βιοχημικό) όσο και σε μακροσκοπικό επίπεδο (εμφάνιση οστεοαρθρίτιδας και ρήξεων του τενοντίου πετάλου των στροφένων του ώμου).

Στη Μελέτη I διερευνήθηκε το κλινικό αποτέλεσμα 2-3 χρόνια μετά την έναρξη της θεραπείας, σε ασθενείς με σύνδρομο υπακρωμιακής προστριβής, οι οποίοι έλαβαν είτε χειρουργική θεραπεία (ακρωμοπλαστική, είτε με ανοιχτή μέθοδο είτε αρθροσκοπικά), είτε μη-χειρουργική θεραπεία. Ογδόντα-εφτά ασθενείς με σύνδρομο υπακρωμιακής προστριβής συμπεριλήφθηκαν σε τυφλή τυχαιοποιημένη μελέτη και χωρίστηκαν σε τρεις ομάδες: ομάδα ανοιχτής ακρωμοπλαστικής (OSG), ομάδα αρθροσκοπικής ακρωμοπλαστικής (ASG) και ομάδα φυσιοθεραπείας (PTG). Κατά τη μέτρηση του κύριου μέτρου έκβασης, του Constant score, δε βρέθηκε καμία στατιστικά σημαντική διαφορά ανάμεσα στις 3 ομάδες θεραπείας, συγκρίνοντάς τες κατά την έναρξη της μελέτης και κατά τον επανέλεγχο. Κατά τη σύγκριση όμως κάθε μιας ομάδας χωριστά και οι δύο χειρουργικές ομάδες εμφάνισαν κατά τον επανέλεγχο (follow-up) στατιστικώς σημαντική βελτίωση στο Constant score, γεγονός που δεν παρατηρήθηκε για την ομάδα της φυσιοθεραπείας. Επιπλέον,

το Watson & Sonnabend score ήταν στατιστικώς σημαντικά αυξημένο για περισσότερες ερωτήσεις στην ομάδα της ανοιχτής ακρωμοπλαστικής. Παρομοίως, η ομάδα της ανοιχτής ακρωμοπλαστικής είχε καλύτερες μετρήσεις, όσον αφορά τη δύναμη, κατά τον επανέλεγχο. Στη Μελέτη II οι ίδιες ομάδες ασθενών ελέγχθηκαν κατ'ελάχιστον 10 χρόνια μετά την έναρξη της θεραπείας για τις ίδιες παραμέτρους όπως και στη Μελέτη I. Στη Μελέτη II ερευνήθηκε επιπλέον και η πιθανότητα εμφάνισης οστεοαρθρίτιδας και ρήξης του τενοντίου πετάλου των στροφένων του ώμου. Όπως και στην πρώτη μελέτη έτσι και στη δεύτερη οι δύο χειρουργικές ομάδες εμφάνισαν καλύτερο κλινικό αποτέλεσμα. Το Constant score ήταν σημαντικά καλύτερο στατιστικά στις ομάδες ανοιχτής και αρθροσκοπικής ακρωμοπλαστικής, κατά τη σύγκριση κάθε ομάδας στην αρχή της θεραπείας και κατά τον επανέλεγχο. Επιπλέον κατά τη σύγκριση των 3 ομάδων στην έναρξη της μελέτης και στον επανέλεγχο, η ομάδα ανοιχτής ακρωμοπλαστικής είχε σημαντικά καλύτερο Constant score σε σύγκριση με την ομάδα της φυσιοθεραπείας. Επίσης οι δύο χειρουργικές ομάδες είχαν καλύτερη δύναμη και κάμψη του ώμου. Όμως, όσον αφορά την εμφάνιση οστεοαρθρίτιδας και ρήξης του τενοντίου πετάλου των στροφένων του ώμου, δε βρέθηκε καμία διαφορά.

Στη Μελέτη III εξετάστηκε η μικροσκοπική δομή βιοψιών από τον τένοντα του υποπλατίου μυός και από τον αρθρικό θύλακο του ώμου, για την ανεύρεση εκφυλιστικών αλλαγών. Άρρηνες ασθενείς με σύνδρομο υπακρωμιακής προστριβής συγκρίθηκαν με άρρηνες ασθενείς που

υπέφεραν από υποτροπιάζον εξάρθρημα του ώμου. Αναλύθηκαν η διάμετρος των ινιδίων αυτών των ιστών καθώς και ένας δείκτης εκφύλισης ιστών, το Total Degeneration Score (TDS). Ανάμεσα στα δύο γκρουπ υπήρχε σημαντική διαφορά ηλικίας. Το γκρουπ της υπακρωμιακής προστριβής ήταν σημαντικά πιο ηλικιωμένο. Η ανάλυση όμως του συντελεστή συσχέτισης (correlation coefficient) ανάμεσα στην ηλικία των ασθενών και τη διάμετρο των ινιδίων ήταν $r = -0.20$ για τον τένοντα του υποπλάτιου μύος και $r = -0.25$ για τον αρθρικό θύλακο. Το γκρουπ των ασθενών με υποτροπιάζον εξάρθρημα ώμου είχε ινίδια με σαφώς μεγαλύτερη διάμετρο καθώς και σημαντικά καλύτερο Total Degeneration Score (TDS) σκορ. Αυτά τα αποτελέσματα υποδεικνύουν μια αυξημένη εκφυλιστική διαδικασία σε ασθενείς με σύνδρομο υπακρωμιακής προστριβής. Υπάρχουν ενδείξεις ότι αυτή η εκφυλιστική διαδικασία δεν αναπτύσσεται λόγω της γήρανσης, καθόσον ο συντελεστής συσχέτισης για τη ηλικία και τη διάμετρο των ινιδίων ήταν χαμηλός, οπότε θα πρέπει να συσχετιστεί με την ανάπτυξη του συνδρόμου υπακρωμιακής προστριβής. Στη Μελέτη IV εξετάστηκε

η τοπική έκφραση διαφόρων παραμέτρων φλεγμονής στον ίδιο πληθυσμό. Η ανάλυση των βιοψιών έδειξε σημαντικά αυξημένα επίπεδα Ιντερλευκίνης-6 (IL-6) και του παράγοντα νέκρωσης όγκων-α (TNF-α) στον τένοντα του υποπλάτιου μύος. Όσον αφορά τον αρθρικό θύλακο, βρέθηκαν επίσης αυξημένα επίπεδα του TNF-α καθώς και του Cluster of Differentiation 72 (CD 72), το οποίο είναι δείκτης δραστηριότητας των Β-λεμφοκυττάρων. Αυτά τα αποτελέσματα υποδεικνύουν πως μια φλεγμονώδης διαδικασία είναι παρούσα τόσο στον τένοντα του υποπλάτιου μύος, όσο και στον αρθρικό θύλακο του ώμου, σε ασθενείς με σύνδρομο υπακρωμιακής προστριβής. Με άλλα λόγια, υπάρχουν ενδείξεις ότι μια διάχυτη φλεγμονώδης διαδικασία, που δεν περιορίζεται στον υπακρωμιακό χώρο αλλά επεκτείνεται σε όλη την ωμική ζώνη, αναπτύσσεται στους ασθενείς αυτούς. Συμπερασματικά, οι Μελέτες III και IV παρέχουν στοιχεία ότι υπάρχει μια χρόνια εκφυλιστική διαδικασία και φλεγμονώδης αντίδραση, τόσο υπακρωμιακά όσο και στους περιβάλλοντες ιστούς.

IV. LIST OF PAPERS

This thesis is based on the following studies, referred to in the text by their Roman numerals.

- I. Comparison of open acromioplasty, arthroscopic acromioplasty and physiotherapy in patients with subacromial impingement syndrome: a prospective randomised study.**
Farfaras S, Sernert N, Hallström E, Kartus J.
Knee Surg Sports Traumatol Arthrosc. 2016 Jul;24(7):2181-91.
- II. Subacromial decompression yields a better clinical outcome than therapy alone: a prospective randomized study of patients with a minimum 10-year follow-up.**
Farfaras S, Sernert N, Rostgard Christensen L, Hallström EK, Kartus JT.
Am J Sports Med. 2018 May;46(6):1397-1407.
- III. More histologic and ultrastructural degenerative signs in the subscapularis tendon and the joint capsule in male patients with shoulder impingement.**
Farfaras S, Ejerhed LE, Hallström EK, Hultenby K, Meknas K, Movin T, Papadogiannakis N, Kartus JT.
Knee Surg Sports Traumatol Arthrosc. 2018 Jan;26(1):79-87.
- IV. Increased amount of inflammatory markers in the subscapularis tendon and joint capsule in patients with subacromial impingement.**
Farfaras S, Roshani L, Mulder J, Mitsios N, Hallström E, Kartus J.
Submitted Am J Sport Med.

V. ABBREVIATIONS

AC joint	Acromio-clavicular joint
ACL	Anterior cruciate ligament
ADL	Activities of daily living
ASG	Arthroscopic surgery group
BP	Bodily pain
CT	Computed tomography
DJD	Degenerative joint disease
GAGs	Glycosaminoglycans
GH	General health
HPF	High power field
H&E	Haematoxylin and eosin
MH	Mental health
MRI	Magnetic resonance imaging
N	Newton
n	Number of subjects
NSAIDs	Non-steroidal anti-inflammatory drugs
n.s.	Non-significant
OA	Osteoarthritis
OSG	Open surgery group
PF	Physical functioning
PROM	Patient-reported outcome measurement
PTG	Physiotherapy group
PBS	Phosphate-buffered saline
QoL	Quality of life
RCT	Randomised controlled trial
RE	Role emotional
ROM	Range of motion
RP	Role physical
SAIS	Subacromial impingement syndrome
SD	Standard deviation
SF	Social functioning
SF-36	36-item short form survey
TDS	Total degeneration score
TEM	Transmission electron microscopy
VT	Vitality

VI. BRIEF DEFINITIONS

Acromioplasty	A surgical procedure in which the under surface of the acromion is removed, together with the coraco-acromial ligament
Bankart injury (bony)	Impaction fracture of the glenoid margin (usually the anterior part of the rim) in association with a labral injury, after shoulder dislocation
Cytokines	Small immunoactive proteins released by cells. They play a role in intra-cellular communication, cell signalling and regulation
Glucosaminoglycans	Polysaccharides, highly negatively charged, a major component of the extracellular matrix
Joint capsule	A dense fibrous connective tissue, attached to the bones. It is vital to the function of the synovial joints, as it seals the joint space and provides passive and active stability. It plays an important role in diseases such as rheumatoid arthritis and degenerative osteoarthritis
Null hypothesis	The type of hypothesis used in statistics that proposes that no statistical significance exists in a set of given observations
P-value	The probability, under the null hypothesis, of obtaining a result equal to or more extreme than what was actually observed
Power	The probability of finding a significant association when one truly exists
Sensitivity	Percentage of patients with a condition who are classified as having positive results
Shoulder dislocation	A dislocation of the humeral head from the glenoid cavity, usual traumatic
Specificity	Percentage of patients without a condition who are classified as having negative results

Subacromial impingement	A shoulder syndrome involving pain in abduction or elevation of the shoulder, usually above the horizontal level
Tendon	The part of tissue that muscles insert to the bone. They consist of collagen (mostly type I collagen) and elastin and are composed of tenocytes and tenoblasts
Tendon fibres	The basic unit of a tendon. Several bundles of fibres form the tendon
Tendon fibrils	Electron microscopically clearly visible units. A bunch of collagen fibrils form a collagen fibre
Tenocytes and tenoblasts	Elongated fibrocytes and fibroblasts which produce the collagen fibres and the elastin of the tendons
Type I error	Incorrect rejection of a true null hypothesis (“false positive”)
Type II error	Incorrect acceptance of a false null hypothesis (“false negative”), often because of a lack of power, frequently due to too few studied patients

01 INTRODUCTION

1.1 SUMMARY

Subacromial impingement syndrome (SAIS) is a common cause of persisting and invalidating shoulder pain (1, 2). It can change a person's behaviour and lead to long-lasting sick-leave periods. The syndrome may affect people in all age categories. This emphasises the need for broad and

effective treatment algorithms. Many different treatment alternatives, both surgical and non-surgical, with varying results, have been proposed and reported in the literature. However, a true consensus on which treatment to propose has yet not been established.

1.2 ANATOMY OF THE SHOULDER

The anatomy of the shoulder joint is extremely advanced (3-8). It consists of three bones (the clavicle, the scapula and the humerus) and four joints (sterno-clavicular, acromio-clavicular, gleno-humeral and scapulo-thoracic joint, which is in fact a "false" joint), as demonstrated in Figure 1. The most important joint is the gleno-humeral joint. It is formed between the scapula glenoid and the caput humeri. The joint is surrounded by the joint capsule, a dense fibrous connective tissue, attached to the bones. It is vital to the function of the synovial joints, as it seals the joint space and provides passive and active stability. It plays an important role in diseases such as rheumatoid arthritis and degenerative osteoarthritis (9). The gleno-humeral joint has an extremely wide range of motion in different directions. Practically, in combination with the movement in the scapulo-thoracic "joint", it has an almost hemispherical range of motion: 0-180° in elevation and abduction from the vertical position, 0-90° of internal and external rotation from the horizontal position and approximately 0-45° in extension, as well as 0-360° circumduction (10). The

acromio-clavicular joint also participates, to a minor extent, in the movement of the humerus, while the sterno-clavicular joint is practically the only bony connection of the arm to the torso (Figure 1).

The glenoid fossa is small compared with the caput humeri and, as a result, they do not fit one another exactly (4-8). There is therefore a discrepancy between the articular surfaces of the gleno-humeral joint. The concavity of the fossa glenoidale covers a minimal area of the corresponding caput humeri surface, in order to avoid any bony constraint by the caput humeri. This results in an inherent anatomic instability. The gleno-humeral joint is a ball-socket joint and has been described as a golf ball on its base (Figure 2). To achieve the stabilisation and centring of the caput humeri in the fossa glenoidale and thus permit a vast range of motion in the joint and the development of strength vectors in different directions, without dislocating the humerus, a complex system of passive and dynamic stabilisers is present. The passive stabilisation of the joint is achieved by numerous ligaments around the joint (superior glenohumeral

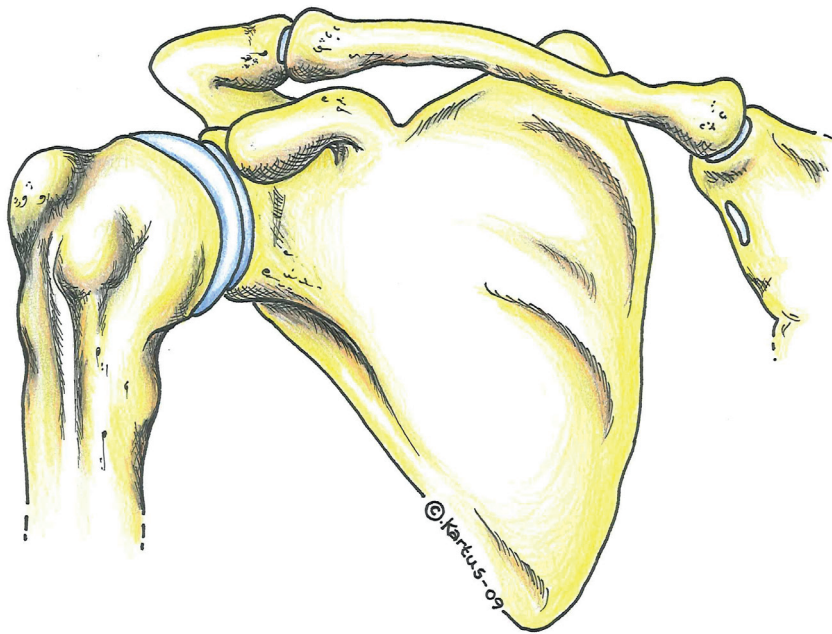


Figure 1. *The shoulder joint and its four articulations: the sterno-clavicular, the acromio-clavicular, the gleno-humeral and the scapulo-thoracic joint.*

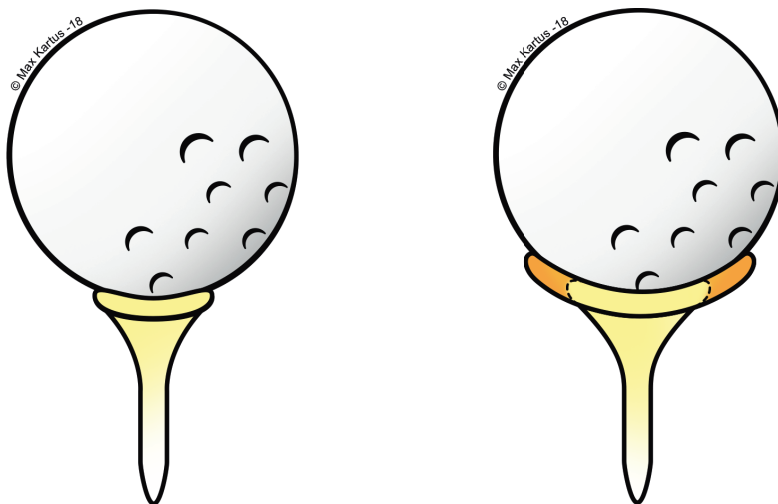


Figure 2. *The caput humeri and the glenoid fossa illustrated as a "golf ball on a peg".*

ligament-SGHL, middle glenohumeral ligament-MGHL, inferior glenohumeral ligament-IGHL) (3-8, 10), (Figure 3). Furthermore, there are ancillary ligaments above the joint, the coraco-acromial and the coraco-humeral ligaments, which preserve the caput humeri from cranial translation. Adjacent ligaments, which play a role in joint function, are the acromio-clavicular and the coraco-clavicular ligaments. The latter consists of two parts, the trapezoid and the conoid ligaments. In addition to the stabilising function of the ligaments, the gleno-humeral joint is deepened by the presence of a circumferential tissue, the glenoidale labrum, in the periphery of the glenoid fossa (Figure 4). The passive stabilisation is reinforced by dynamic stabilisation factors, the voluminous and numerous

muscles of the scapular girdle (4-8). These muscles include the rotator cuff (supraspinatus, infraspinatus, subscapularis and teres minor muscles), the deltoid muscle and the teres major (Figure 5). The most important of these muscles is the supraspinatus, which practically maintains the caput humeri centred in the glenoid, in connection with different positions of the arm. The infraspinatus is responsible for the outward rotation of the arm, but it also has an auxiliary stabilising function. Auxiliary function in the centring of the humerus is also provided by the pectoralis major and latissimus dorsi. These two muscles play an important part in decreasing the position of the caput humeri in the glenoid during elevation and abduction.

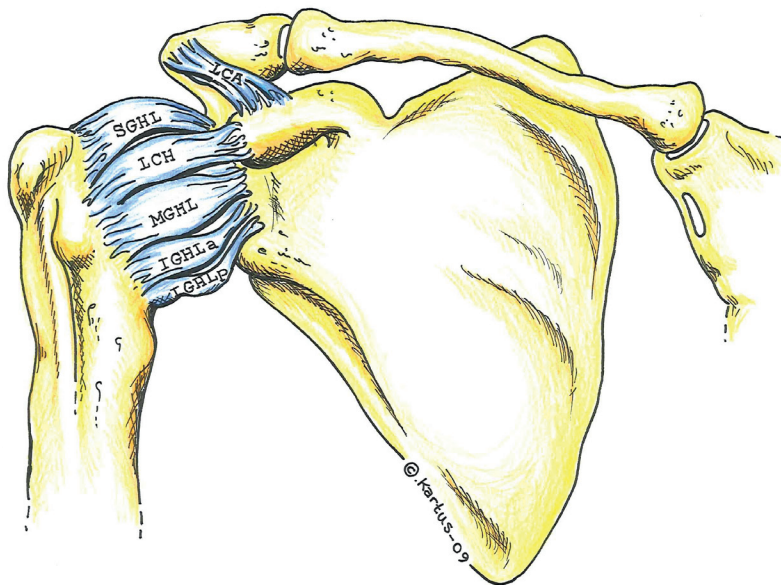


Figure 3. *The ligaments of the gleno-humeral joint. LCA=ligamentum coracoacromiale, SGHL=superior glenohumeral ligament, LCH=ligamentum coracobumerale, MGHL= middle glenohumeral ligament, IGHLa= inferior glenohumeral ligament (anterior part), IGHLP= inferior glenohumeral ligament (posterior part).*

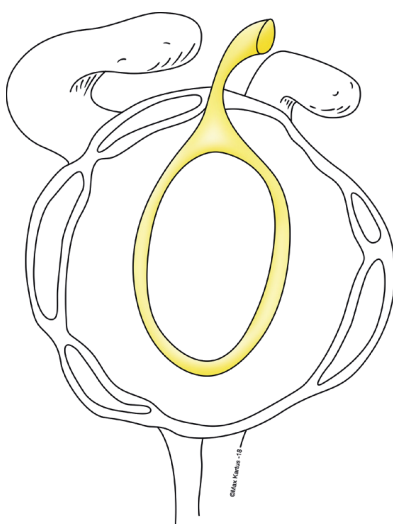


Figure 4. *The labrum of the gleno-humeral joint (yellow colour).*

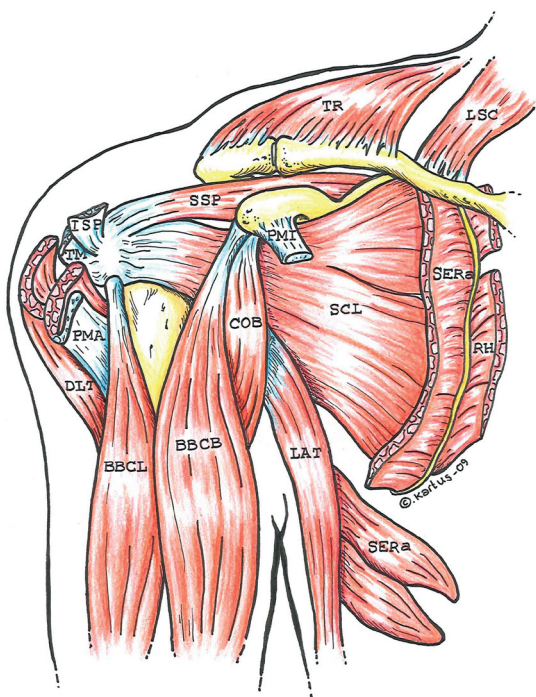


Figure 5. *The muscles of the shoulder .TR=trapezius m., LSC=sternocleidomastoid m., SSP=supraspinatus m., ISP=infraspinatus m., SCL=subscapularis m., PMI=pectoralis minor m., TM=teres minor m., PMA= pectoralis major m., DLT=deltoid m., BBCL=biceps brachialis long head m., BBCE=biceps brachialis short head m., COB=coracobrachialis m., LAT=latissimus dorsi m., SERa=serratus anterior m.*

1.3 EPIDEMIOLOGY

One of the most common reasons for consulting a physician is pain in the shoulder girdle. This pain may involve different conditions, such as rotator cuff disease and ruptures, subacromial impingement syndrome, primary or secondary shoulder instability and adhesive capsulitis. Sometimes, the clinical picture may contain a mixture of two or more conditions simultaneously, for example, subacromial impingement and rotator cuff rupture (11-14), shoulder instability with secondary subacromial impingement or rotator cuff arthropathy with cranial caput humeri migration (15-19), eventually resulting in subacromial friction and pain. It appears that superior glenoid inclination is a critical factor in developing superior caput humeri migration (20, 21). SAIS accounts for the most of these cases. In the general population, the prevalence of shoulder pain may be as high as six to

11% under the age of 50 years, increasing to 16-25% in the elderly (22-24). Estimates of the annual incidence of shoulder disorder encountered in general practice varies from seven to 25 per 1,000 registered patients per year (25). Inability to work and carry out household activities, in addition to loss of productivity, can become a considerable burden for the patient as well as to society (26). A study from the late 1980s reported a prevalence of 14% for shoulder pain in the Swedish population (27). SAIS is therefore one of the most common reasons for shoulder problem consultations (1, 2). Risk factors for the appearance of the symptoms are hobbies and/or working with lifts and movements above the head, sports including overhead activities, working with hand tools, especially vibrating tools, and working in industry (24, 27-32).

1.4 CLASSIFICATION AND PATHOPHYSIOLOGY

Even though its prevalence is high in the population, the aetiology of the syndrome is not well known. In the past, many authors described abnormal conditions in the subacromial space, but the real reason why impingement syndrome develops remains unclear (33-38). In 1931, Meyer suggested that, because of the friction between the rotator cuff and the under surface of the acromion, tears to the rotator cuff could develop secondary to attrition (39). He also described tears close to the greater tuberosity, but he did not explain their aetiology. In 1934, Codman focused on a specific, vulnerable location on the rotator cuff, situated one centimetre medial to the insertion of the supraspinatus on the greater tuberosity, where most of the degenerative changes were found (38). In 1972, Neer described shoulder impingement as a mechanical phenomenon corresponding to impingement of the rotator cuff tendon

beneath the anterior-inferior acromion (35), (Figure 6a, 6b). This condition occurs when the shoulder is placed in forward flexion and internal rotation. He hypothesised that the rotator cuff is impinged by the anterior one-third of the acromion, the coraco-acromial ligament and the acromioclavicular joint. Neer also proposed that the insertion of the supraspinatus tendon on the greater tuberosity is involved in impingement conditions. In addition, he suggested that these tears could be caused by bony spurs in the coraco-acromial ligament.

In 1983, Neer characterised three stages of impingement. Stage I is described as oedema and haemorrhage of the bursa and the rotator cuff, a common disorder among patients who are less than 25 years old (36). Stage II represents permanent changes, such as fibrosis and tendinitis of the rotator cuff, and is normally found in patients who are 25-40 years old. Stage III corresponds

to more chronic changes, such as partial or complete tears of the rotator cuff. It is usually seen in patients who are more than 40 years old. Although the more advanced stages of this process, including rotator cuff tears, are more common in older individuals,

impingement and rotator cuff pathology are also frequently seen in younger, athletic individuals, who are engaged in repetitive overhead activities, or in young workers, who expose their rotator cuff to similar conditions (29-31, 40).

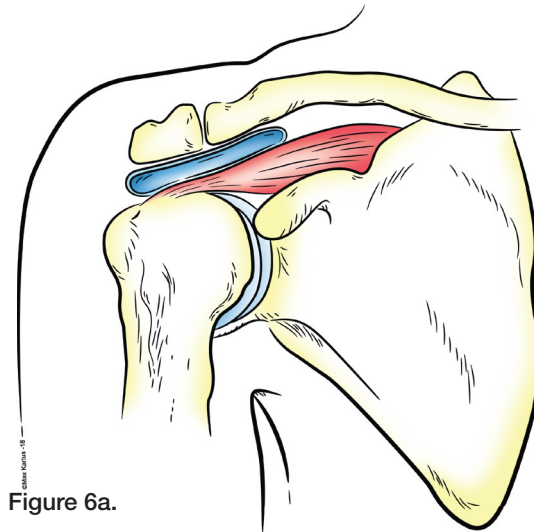


Figure 6a.

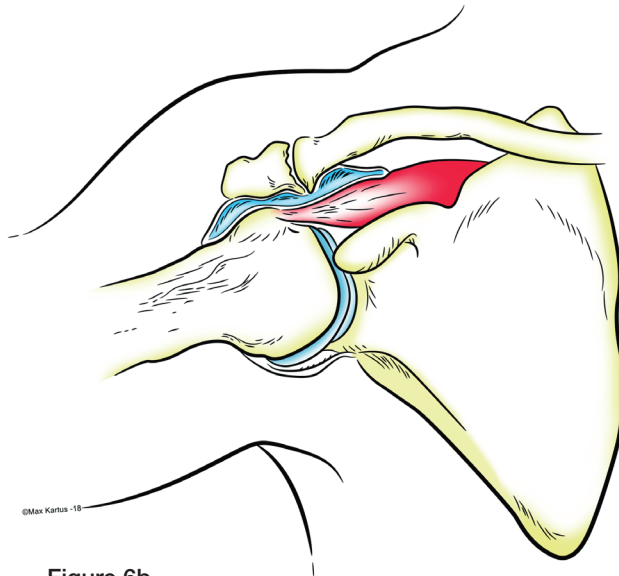


Figure 6b.

The subacromial space in the neutral position (a) and in abduction (b) illustrating impingement.

As mentioned above, according to Neer, the impingement area is located between the frontal part of the acromion, the coraco-acromial ligament and the acromioclavicular joint (35, 36). This chronic mechanical conflict results in inflammation of the subacromial bursa. The inflammation and the associated “swelling” of the bursa result in a vicious circle which increases the pressure on the upper surface of the rotator cuff and may cause secondary rotator cuff injury, as the acromion acts as a hypomochlion and develops pressure on the supraspinatus tendon. Neer’s theory to explain SAIS presupposes an anatomic irregularity of the acromion. This theory is known as the “extrinsic” theory (35, 36). Bigliani et al. described three frequently observed variations in the morphology of the acromion based on cadaveric dissections and radiographs (41). In 139 shoulders from 71 cadavers, they identified three types of morphology. Twenty-four (17%) were fairly flat, 60 (43%) were described as curved and 55 (40%) as hooked. Recently, another type of acromion, type 4, has been described by Gagey et al., in which the acromion is convex in its middle third (42). The four acromion types are illustrated in Figure 7. Natsis et al. analysed 423 scapulae and found the following prevalence of acromion types: type I (flat) 12.1%, type II (curved) 56.5%, type III (hooked) 28.8% and type IV (convex) 2.6% (43). Neer suggested that differences in the shape and slope of the anterior portion of the acromion could explain subacromial impingement and associated tears of the rotator cuff. These conclusions were based on his own clinical remarks as well as the dissection of more than 100 cadaveric scapulae (35). These results are supported by other authors (14, 44, 45). In addition, a spur on the coraco-acromial ligament was often found distally directed into the subacromial area. A higher prevalence of full-thickness tears of the rotator cuff was noted in association with the hooked or type III acromion. This observation was

confirmed by Morrison et al. in 1987 when they studied 200 consecutive patients with supra outlet radiographs (46). Sixty-six (80%) of the 82 patients who had rotator cuff tears according to arthrography had a hooked acromion.

Nicholsson et al. studied 420 specimens and noted that the prevalence of spur formation at the anterior part of the acromion increased after 50 years of age, whereas the morphology of the acromion did not appear to change with age (47). In the large study by Natsis et al., the prevalence of enthesophytes was 15.6% and all of them were located at the site of the coraco-acromial ligament insertion on the acromion (43).

The hypothesis that the anterior part of the acromion is associated with the pathogenesis of tears in the rotator cuff was supported by Zuckerman et al. (48). They studied 140 cadaveric shoulders and found that the supraspinatus outlet was 22.5% smaller and the anterior projection of the acromion was larger in the specimens with a rotator cuff tear.

Furthermore, it is reported that changes in the acromio-clavicular joint (AC joint) can provoke the impingement of the rotator cuff. In advanced AC degeneration, large spurs can appear on the under surface of the AC joint and result in direct conflict with the supraspinatus tendon (49).

Several researchers have described the subacromial contact areas as consisting of critical zones for the supraspinatus tendon, the long biceps tendon, bone impingement between the tuberculum majus and the acromion and seldom between the rotator cuff and the processus coracoideus (37, 50, 51).

Bigliani and Morisson have demonstrated a correlation between acromion morphology and the incidence of rotator cuff injuries in clinical and cadaver studies (41, 46). Moreover, Nasca et al. found that subacromial contact with the supraspinatus tendon correlates with associated areas with tendon injuries in the subacromial space (51). This finding does not explain the aetiology of the syndrome but provides evidence of

disturbances in the subacromial space which may result in friction due to the swelling of the subacromial soft tissue and bursa.

The “extrinsic” theory dominated the pathophysiology of the syndrome for decades. The friction and pressure in the narrow subacromial space is possibly caused by a curved or hook-shaped acromion and results in micro trauma to, and sometimes even inflammation in, the rotator cuff, thereby provoking the pain. Subacromial decompression in patients not responding to conservative treatment has therefore been the treatment of choice for about four decades.

The friction and pressure theory does not explain the appearance of SAIS in individuals with a normal, flat acromion configuration. Another theory, the intrinsic theory, has therefore been proposed. This theory is that subacromial pain is multifactorial, due, among other factors, to the chronic inflammation and degeneration of the rotator cuff and the subacromial bursa (52-58). With time, its thickening causes conflict and pain

between the acromion and the rotator cuff. The pathophysiology of shoulder impingement, according to this theory, is similar to the tendinopathy in other joints of the body, such as Achilles tendinopathy and tendinosis-like changes in the patellar tendon (59-61). Studies of torn rotator cuff tendons have revealed that degenerative changes also appear medially from the tear, indicating the presence of degeneration before the tear occurs (62-64). Other factors leading to a manifest subacromial syndrome are rotator cuff weakening, tendinitis and bursitis (65-67). The degeneration and chronic inflammation of the subacromial structures (subacromial bursa, rotator cuff tendons, coraco-acromial ligament) and joint capsule lead to a change in the function and kinematics of the shoulder in abduction and elevation (66, 68, 69). Secondary to this, osteophytes and spurs in the acromion may occur, changing its anatomy (49).

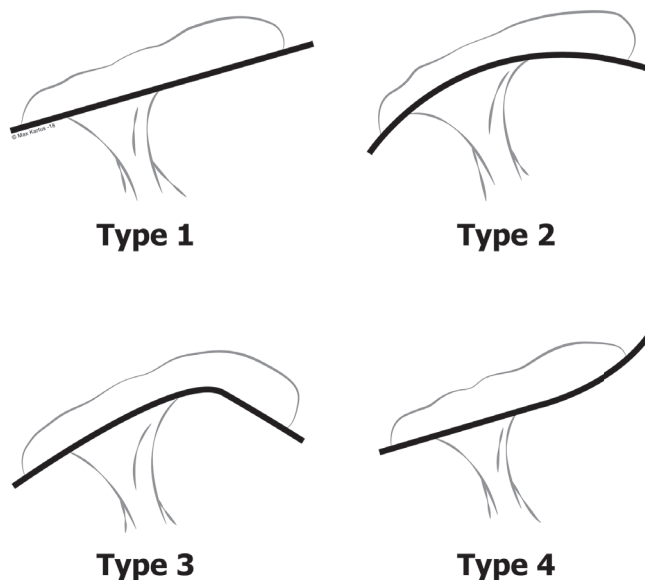


Figure 7. *The four types of acromion morphology.*

A critical zone of the rotator cuff is localised approximately 1 cm medially to the supraspinatus insertion in the tuberculum majus, as shown in Figure 8. This zone is believed to have decreased vascularisation (70, 71). This fact, in association with increased local pressure, which occurs in abduction and elevation, results in decreased blood flow, which in its turn leads to the local degeneration of collagen. Factors that may be associated with this degeneration and chronic inflammation procedure are: a) the proximal translation of caput humeri due to weakness in the external rotators of the shoulder, b) constant pressure in the critical area, due to anatomical changes or secondary alterations (osteophytes, spurs, ligament calcifications), and c) hypovascularisation (29, 72-76).

Rathburn and Macnab showed less vascularity in the insertion of the supraspinatus tendon and the intra-articular portion of the long biceps tendon, compared with adjacent areas of the rotator cuff (76). The decrease in vascularity became more profound in active abduction of the humerus. Järvholm

found significantly higher intramuscular pressure in the supraspinatus and infraspinatus muscles compared with the trapezius and deltoideus (77, 78). Furthermore, when the intramuscular pressure exceeds 30mm Hg, the intramuscular blood flow may be impaired. Järvholm reported a pressure over 50 mmHg in the supraspinatus in just 30° of abduction.

The chronic inflammation and degeneration of several structures subacromially and in the adjacent tissues reinforces the vicious circle of inflammation-degeneration-swelling-friction-inflammation. There is evidence that an inflammation occurs in the subacromial bursa, due to pro-inflammatory cytokine activation (57, 79-82). Cytokines are proteins, small in size, which are secreted by different cells and play a role in communication and interaction between the cells (83). However, poor evidence exists as to whether or not an inflammatory process is present in the subacromial space or whether it also is present in the adjacent humeroscapular joint.

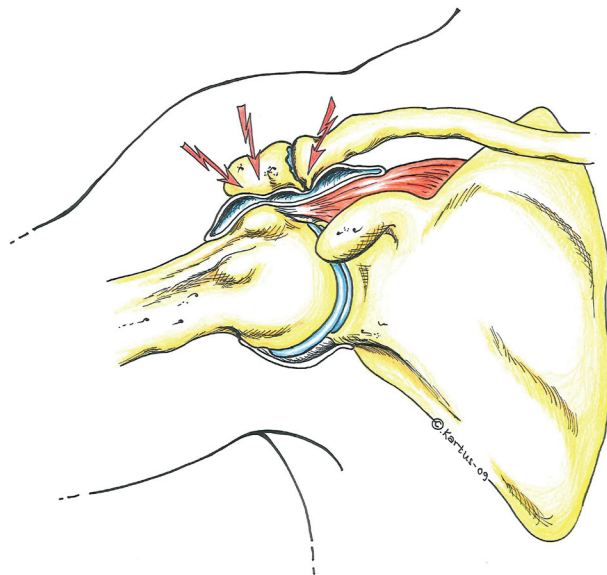


Figure 8. *The critical area near the supraspinatus insertion on the tuberculum majus.*

1.5 TREATMENT ALTERNATIVES

Traditionally, subacromial impingement has been assessed with non-invasive treatment, such as NSAIDs per os, local injections in the subacromial space (with corticosteroids, sometimes prolotherapy or PRP (84-86)) and physiotherapy. Various protocols for physiotherapy have been reported in the literature with varying results (87-93). One such protocol is Böhmer's supervised exercise programme for patients with subacromial pain. It was developed at Oslo University Hospital, Ulleval (91, 94). It includes two sixty-minute sessions under supervision twice a week and home exercises in five sessions on the remaining days of the week. When non-surgical treatment is unsuccessful, acromioplasty is proposed. This procedure involves the widening of the subacromial space by removing the frontal and lateral part of the under surface of the acromion, the dissection of the coraco-acromial ligament, a partial bursectomy of the subacromial bursa and the removal of any concomitant spurs. In some cases, it may be accompanied by AC-joint resection, in the event of concomitant AC osteoarthritis (OA) and spurring (15, 35, 36, 95).

The acromioplasty was proposed by Neer as an open procedure, with the concomitant resection of the coraco-acromial ligament (35, 36, 95). It was regarded as the gold standard procedure for SAIS not responding to non-surgical treatment. Rockwood and Lyons emphasised the importance of the anterior prominence of the acromion in impingement syndrome (96). They suggested a two-step acromionectomy, the resection of the anterior part of the acromion at the level of the clavicle and the removal of bone from the inferior aspect of the acromion.

Another problem that has to be addressed is impingement by the coraco-acromial ligament. The "snapping shoulder," a condition starting with shoulder pain, is believed to be caused by the inflammation and

swelling of the subacromial bursa, which becomes squeezed under the edge of the coraco-acromial ligament, was described by McLaughlin and Asherman (97). At a later stage, Neer incorporated the resection of the coraco-acromial ligament as an essential part of the anterior acromioplasty procedure (35, 36). This procedure has also been recommended by others and especially in athletes engaged in overhead activities (40, 72, 98, 99).

In a cadaveric study, Burns and Whipple noted that the supraspinatus and biceps tendons were stabbed against the lateral edge of the coraco-acromial ligament as the arm was flexed forward to 90° and then forcibly rotated internally (100). Soslowsky proposed that the enlargement of the coraco-acromial ligament could result in subacromial impingement (101). However, this hypothesis is questioned by Sarkar and Uthoff who, in histological studies, only found degenerative changes without any swelling of this ligament (102, 103). Furthermore, the degeneration of the AC joint is often present in these patients. Degenerative changes in the AC joint are a widely accepted reason for subacromial impingement (35, 36, 104-106). When the cuff passes underneath the joint, osteophytes from the lateral end of the clavicle or from the medial part of the acromion in the AC joint extend beyond the AC joint and interfere with the rotator cuff.

Kessel and Watson found that the pain disappeared in about 2/3 of 97 patients with "painful arch" syndrome after the local injection of anaesthetics and a steroid or after the division of the coraco-acromial ligament (104). These patients had lacerations to either the anterior or posterior part of the rotator cuff. In the remaining patients with degenerative changes in the AC joint, the excision of the distal part (1 cm) of the clavicle resulted in pain relief for patients.

OA of the AC joint may be one reason for the unsuccessful surgical treatment of subacromial impingement. However, resection of the lateral clavicle should only be performed if the patient has symptoms localised to the AC joint, in combination with radiographic changes in this region (107). Since Ellman performed the procedure arthroscopically (108) in the 1990s, the arthroscopic procedure has attracted more attention in clinical practice and currently dominates among orthopaedic surgeons (109, 110), as studies have shown good results after the arthroscopic technique (108, 111, 112). There are also a large number of studies comparing acromioplasty with physical treatment protocols with varying results (11, 92, 113-120). In some cases, the physiotherapy appears to be as good as the surgical treatment, whereas, in some other studies, subacromial decompression appears to be more advantageous. As the different physiotherapy protocols vary in terms of the duration of the programme and the exercises involved (87, 88, 121), it is difficult to evaluate and compare these two treatments. Likewise, several studies have compared the clinical outcome after open and arthroscopic acromioplasty (122, 123). In some of them, the open technique appears to produce a better functional outcome, whereas in others the arthroscopic technique appears more beneficial, mostly in terms of a shorter surgical time, a better aesthetic result, less wound morbidity postoperatively and a shorter period of sick leave (122, 124).

While the clinical outcome of different treatments has been thoroughly investigated, especially in the short term, few studies of the development of rotator cuff tears and OA, secondary to SAIS, have been published. A rotator cuff evaluation is easy to perform using an ultrasound examination or magnetic resonance imaging (MRI). Ultrasound is a relatively inexpensive examination. It has the advantage of enabling a dynamic evaluation of the rotator cuff during motion and estimation of the impingement area. On the other hand, it is strictly examiner dependent and requires a well-trained radiologist. MRI has the advantage of reproducibility, re-evaluation/cross-evaluation from different radiologists, but the disadvantages are its high cost and the fact that it is time consuming. OA development can easily be investigated with plain X-rays, an inexpensive and effective examination. Although the assessment of rotator cuff rupture and OA development is relatively easy, little evidence exists as to whether or not subacromial acromioplasty renders a prophylactic effect in patients with SAIS in the long term. Ketola et al. studied patients with SAIS in the mid-term (five years of follow-up) (125) and found no significant difference in developing secondary rotator cuff tears, in patients treated surgically and non-surgically. To the knowledge of the author, no evidence exists on whether the risk of rotator cuff tears and OA after subacromial decompression decreases in the long term.

02 AIMS

Study I

The aim of this prospective randomised study was to compare the clinical and subjective results two to three years after the interventions, using either surgical (arthroscopic or open subacromial decompression) or non-surgical (physiotherapy ad modum Böhmer) treatment (91, 94).

The hypothesis was that patients with SAIS examined two to three years after intervention would do better after arthroscopic subacromial decompression compared with open acromioplasty and physiotherapy treatment, in terms of the clinical outcome.

Study II

The aim of this prospective randomised study was to compare the long-term outcomes after the interventions, using either surgical (arthroscopic or open subacromial decompression) or non-surgical (physiotherapy ad modum Böhmer) treatment (91, 94).

The hypothesis was that, at a minimum of 10 years after the initial treatment, patients who had undergone acromioplasty would have a better clinical outcome and run a lower risk of developing rotator cuff ruptures and OA as compared with those treated with physical therapy.

Study III

The aim of this study was to analyse biopsy samples from the subscapularis tendon and from the joint capsule (i.e. not directly adjacent to the subacromial space) from male patients with SAIS and compare them with samples from male patients with post-traumatic recurrent shoulder instability, to detect degenerative changes that might be present. The hypothesis was that patients with SAIS would have more histological and ultrastructural degenerative changes in their subscapularis tendon and joint capsule than patients with post-traumatic recurrent shoulder instability.

Study IV

The aim of this study was to analyse biopsy samples from the subscapularis tendon and from the joint capsule (i.e. not directly adjacent to the subacromial space) from male patients with SAIS and compare them with samples from male patients with post-traumatic recurrent shoulder instability, to detect increased inflammatory activity that might be present inside the humeroscapular joint. The hypothesis was that patients with SAIS would have an increase in inflammatory mediator expression in their subscapularis tendon and joint capsule compared with patients with post-traumatic recurrent shoulder instability.

03 PATIENTS

The allocation of patients to the studies

	Total number	Age at operation/interventions (years) Mean (SD)	Female/male
Study I	Group OSG n=15 Group ASG n=19 Group PTG n=21	Group OSG 52.4 (9.5) Group ASG 48.9 (8.9) Group PTG 49.9 (9.3)	Group OSG 8/7 Group ASG 12/7 Group PTG 8/13
Study II	Group OSG n=23 Group ASG n=23 Group PTG n=31	Group OSG 52.1 (8.4) Group ASG 47.0 (9.1) Group PTG 49.1 (9.7)	Group OSG 12/11 Group ASG 13/10 Group PTG 14/17
Study III	Group SAIS n=8 Group shoulder instability n=12	Group SAIS 57.5 (10.7) Group shoulder Instability 30.4 (8.0)	Group SAIS 0/8 Group shoulder Instability 0/12
Study IV	Group SAIS n=8 Group shoulder instability n=12	Group SAIS 57.5 (10.7) Group shoulder Instability 30.4 (8.0)	Group SAIS 0/8 Group shoulder Instability 0/12

Studies I & II

Between November 1998 and January 2002, 95 consecutive patients with SAIS were asked to participate in the study. The patients were referred to the orthopaedic department at the NU-Hospital Group from the region's primary care units. The patients had subacromial pain persisting after conservative therapy (non-structured physiotherapy, NSAID drugs and local corticosteroid injections). They tested positive for impingement (Neer sign and Hawkins test). After the initial assessment, 87 met the inclusion criteria for subacromial pain for at least six months and gave their written consent. The patients were randomised to the open surgery group (OSG), arthroscopic surgery group (ASG), or non-surgical treatment group (PTG). The duration of

symptoms from the shoulder suffering from SAIS is presented in Tables 1 and 2. The exclusion criteria were diabetes mellitus, as it is well known that diabetes mellitus may cause loss of motion, as well as any neurological or spinal disorder, radiographic OA, the presence of chronic joint disorders, such as rheumatoid arthritis, full-thickness rotator cuff rupture, and SAIS stage III. The presence of comorbidities and a careful medical history were assessed. All patients underwent an ultrasound examination of their shoulder to identify total rotator cuff ruptures, as well as a standard radiographic examination to identify OA. The mean follow-up was 30.8 (SD 6.0) and 166.1 (SD 17.9) months after intervention in Study I and Study II respectively.

Duration of symptoms	OSG (n=15)	ASG group (n=19)	PTG (n=21)	p-value between groups
6-12 months	2	2	0	n.s. (0.24)
13-36 months	7	8	7	
> 36 months	6	9	14	

Duration of symptoms	OSG (n=23)	ASG group (n=23)	PTG (n=31)	p-value between groups
6-12 months	2	2	0	n.s. (0.24)
13-36 months	13	9	10	
> 36 months	8	11	17	
Missing values	0	1	4	

Randomisation procedure

As age and gender were regarded as confounding factors, the randomisation process was designed to adjust for this (120). One hundred and twenty envelopes were placed in four boxes: males < 55 years, males ≥ 55 years, females

< 55 years and females ≥ 55 years. Each box contained 30 envelopes, 10 for each treatment group. The patients were asked to choose one envelope from the box corresponding to their age and gender. The randomisation process is shown in Figures 9 and 10.

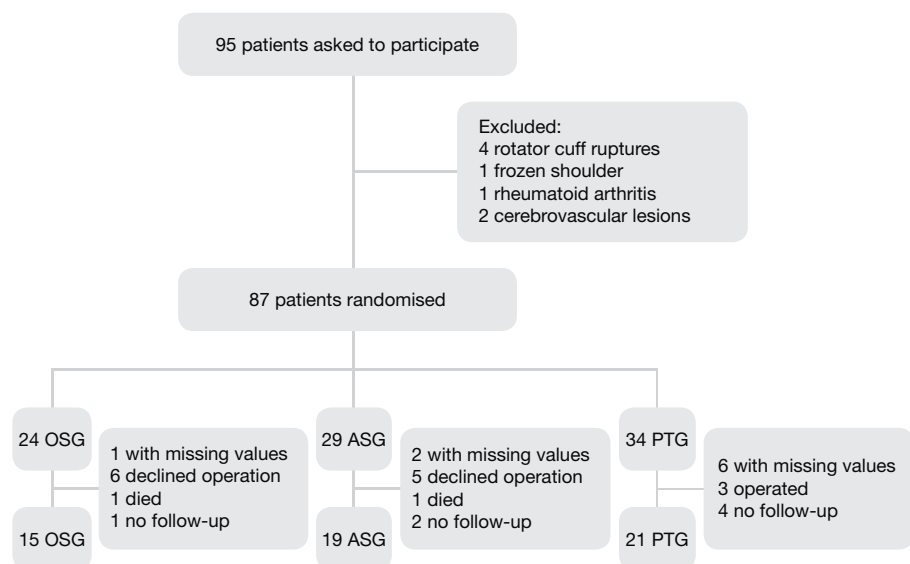


Figure 9. *Flow chart of patients included in Study I.*

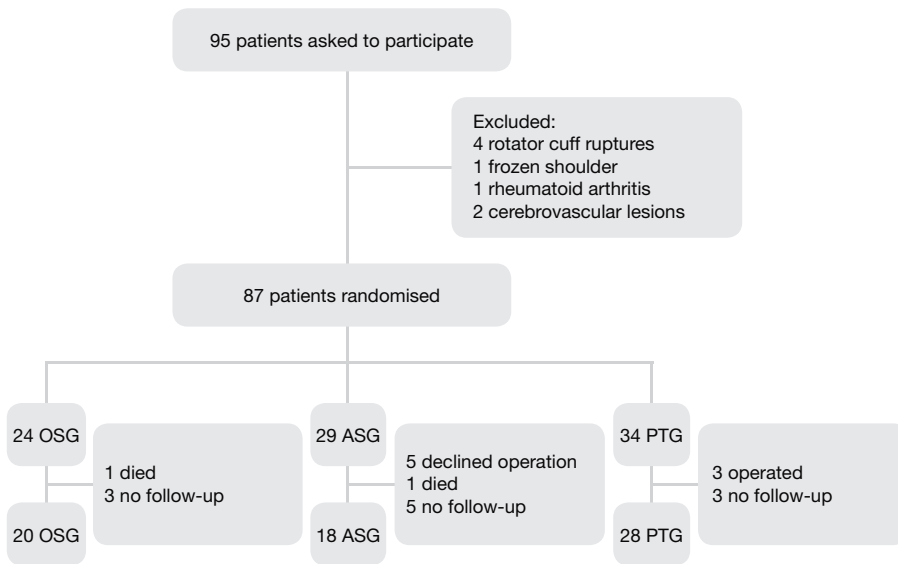


Figure 10. Flow chart of patients included in Study II.

Studies III & IV

To reduce one cause of bias, such as cyclic variations in hormones and their metabolites in pre-menstrual women, only male patients referred from primary care units and scheduled for surgery, with either subacromial decompression or Bankart reconstruction, were eligible to participate in these studies. The exclusion criteria were female gender, age < 18 years, full-thickness supra- and/or infraspinatus tendon tears and/or macroscopic intra-articular subscapularis tendon tears for the acromioplasty group and a glenoid fracture larger than a bony Bankart lesion for the patients planned for Bankart repair. Twenty patients were recruited to the study. The enrolment of the patients started in April 2012 and finished in June 2013. Group A consisted of eight consecutive patients with SAIS, who were scheduled for arthroscopic subacromial decompression, after having been treated conservatively for at least three months with NSAIDs, subacromial corticosteroid

injections and/or physiotherapy. The diagnosis was determined with history and clinical tests with a positive painful arc test and positive impingement tests (40, 126-129). None of the patients had a full-thickness rotator cuff tear, as determined preoperatively with MRI or ultrasound examination and confirmed macroscopically during arthroscopy. Group B, the control group, consisted of 12 consecutive patients with post-traumatic recurrent shoulder instability. These patients were the subject of surgical stabilisation due to recurrent dislocations. All the subjects had dislocated their shoulder at least three times before referral to the orthopaedic specialist. None of the control patients had macroscopic rotator cuff tears. In both groups, none of the patients had diabetes or rheumatoid arthritis or OA as co-morbidities. The patients in the instability group were inevitably significantly younger ($p < 0.0001$) (page 82 in publication III, Table 1).

04 METHODS

4.1 CLINICAL EVALUATION OF DIFFERENT TREATMENTS (STUDIES I & II)

Intervention (Studies I & II)

All surgery was performed on an outpatient basis. At discharge, the patients received a prescription for pain medication and an ice pack in a sling to be used during the first post-operative weeks to reduce pain and

swelling. The post-operative rehabilitation supervised by five local physiotherapists was the same as in the PTG (91, 94). The rehabilitation started as soon as the pain permitted.

4.2 SURGICAL TECHNIQUES (STUDIES I & II)

Open surgery

The procedure was performed according to Rockwood and Lyons with the patient in the beach chair position (96). The acromioplasty technique according to Neer and modified by Rockwood is illustrated in Figure 11a, 11b. The procedure started with an anterior, lateral 5-cm skin incision. The deltoid muscle was split and detached from the anterior third of the acromion and the acromioclavicular joint capsule. After exposing the anterior edge of the acromion, the tendinous anterior third of the acromion was elevated dorsally prior to removing bone. This manoeuvre exposed the coraco-acromial ligament. An osteotome was used to remove the anterior edge and the lateral portion of the under surface of

the acromion. The removed bone included the attachment of the coraco-acromial ligament. The piece of bone was about 6-9 mm wide and 20 mm long. Proximal to the coracoid, the coraco-acromial ligament was cut. Palpation of the under surface of the acromion was performed to detect any fragments of bone or prominences. The under surface of the acromioclavicular joint was palpated and inspected. If osteophytes were present, they were excised. No acromioclavicular joint resections were performed. Finally, the medial flap of the deltoid was sutured to the capsule of the acromioclavicular joint and the lateral flap was sutured to the origin of the deltoid before closing the wound.

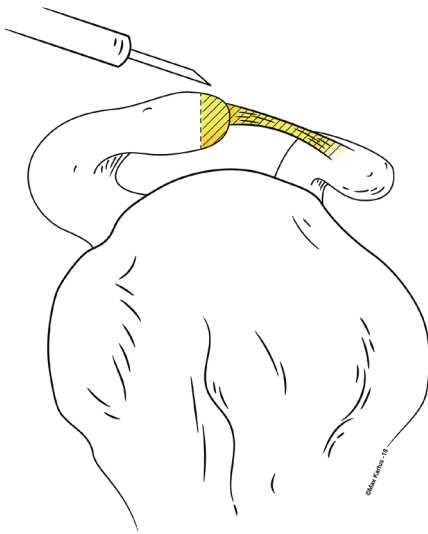


Figure 11a.

The open acromioplasty procedure according to Neer and modified by Rockwood.

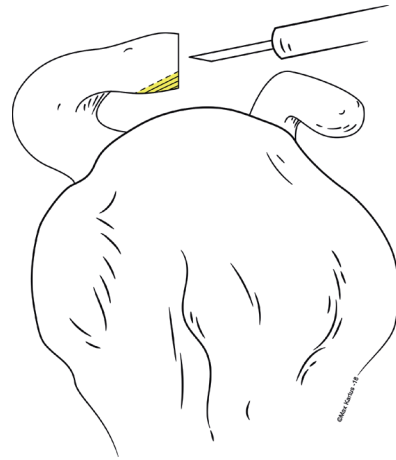

Figure 11b.

Arthroscopic surgery

The arthroscopic subacromial decompression was performed according to Ellman with the patient in the lateral decubitus position (108). Ellman's arthroscopic procedure is shown in Figures 12-14. A traction device was applied to the arm and a tension to the arm corresponding to 40 N was applied. The shoulder was in 10° of flexion and 40° of abduction. The bony landmarks of the shoulder (the acromion, the clavicle, the acromioclavicular joint, the coracoid and the coraco-acromial ligament) were marked with a pen.

A portal for the arthroscope was created on the dorsal side of the shoulder. The glenohumeral joint was first evaluated for cartilage changes, disorder of the biceps tendon, labrum and the rotator cuff. Using the same arthroscopic portal, the subacromial space was visualised and a bursectomy was performed with a shaver introduced from a lateral portal. A resection of the anterior edge of the acromion of about 5-8 mm was then carried out, followed by a resection of about 5-8 mm of the anterior-inferior third of the

under surface of the acromion all the way to the acromioclavicular joint.

Non-surgical treatment

The physiotherapy group (PTG) received treatment according to the method described by Böhmer (91, 94). The purpose of the treatment is to enable the patients to find their normal kinematics of the shoulder, without experiencing pain. The gravitational forces on the arm were removed by suspending the arm in a sling fixed to the ceiling (Figure 15). The training programme started with rotational movements of the arm. As soon as the patient was able to perform these motions without pain, flexion/extension movements were added, followed by abduction/adduction exercises. The training programme proposes everyday practice of at least 60 min. The load was gradually increased in order to strengthen the rotator cuff and the scapula-stabilising muscles. In the final stage of the programme, the patients replaced some exercises with corresponding leisure activities. The programme was performed twice

a week under the supervision of a physiotherapist and the rest of the days at home for a period of three to six months. In order to ensure similar treatment, all the patients

were trained at five local physiotherapy centres by physiotherapists using the same standardised protocol.

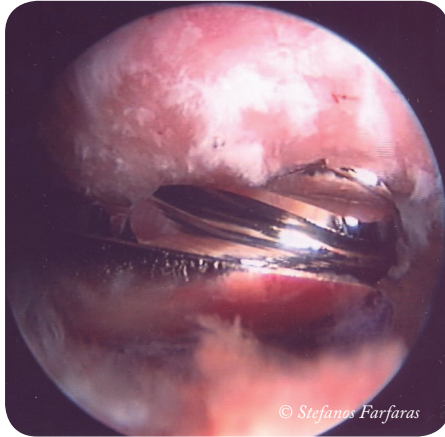

Figure 12. Arthroscopic view of the acromioplasty, using the “bone cutter”.

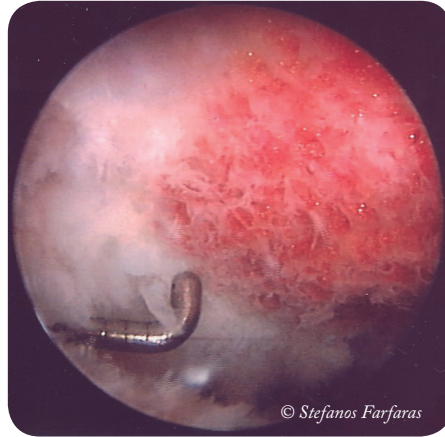


Figure 13. Arthroscopic view of the result of an arthroscopic acromioplasty.

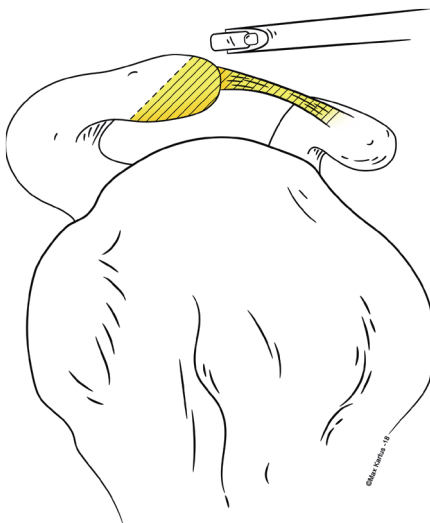


Figure 14. The arthroscopic procedure for acromioplasty according to Ellman (schematic).



Figure 15. The Böhmer program for eliminating the gravitational forces.

4.3 CLINICAL ASSESSMENTS (STUDIES I & II)

For the range of motion (ROM), a transparent handheld universal goniometer was used (Figure 16). Active ROM in flexion and abduction was measured while standing during the enrolment of the patients and sitting at follow-up (Figure 17), due to the different methods used by each physiotherapist (130).

For the measurement of functional internal rotation, the level of the vertebra reached with the thumb of the hand on the ipsilateral side was used (Figure 18).

For the Constant Score, the measurement of strength was made with the patient in a standing position at enrolment and at sitting position at follow-up, also due to the different preferences of each physiotherapist (131, 132). A dynamometer which was adapted to the patient's foot was used (Figure 19). The individual performed three attempts by lifting his/her arm in the plane of the scapula and the mean value was registered in Newtons (N).

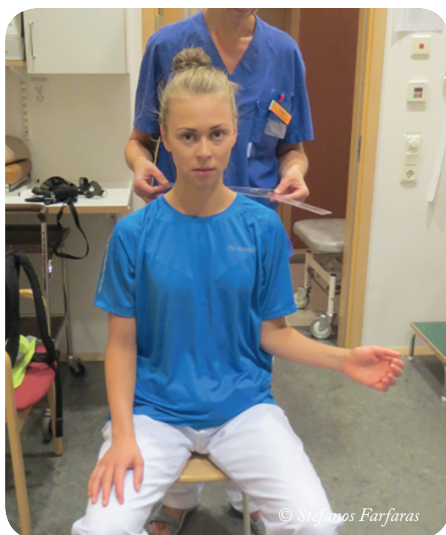

Figure 16. Measurement of the external rotation of the shoulder using a transparent handheld universal goniometer.

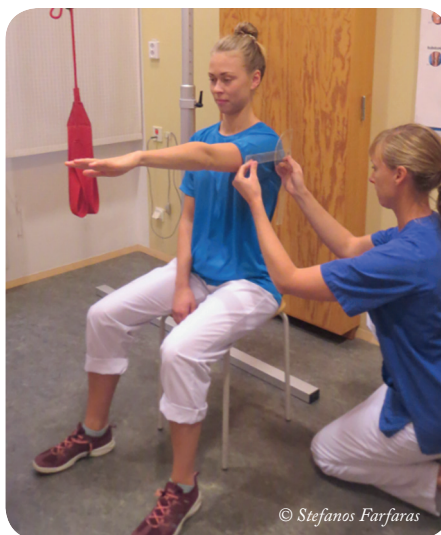

Figure 17. Measurement of active elevation.

Questionnaires

The Constant Score is a shoulder-specific score from 0 (minimum/worst) to 100 (maximum/best) (131, 132). Thirty-five points are allocated to subjective (patient-determined) assessments of pain and activities of daily living, while 65 points are allocated to objective (observer-dependent) measurements of movement and strength. The SF-36 is a questionnaire to assess the general health of individuals in daily activities in eight domains: physical functioning

(PF), role physical (RF), bodily pain (BP), general health (GH), vitality (VT), social functioning (SF), role emotional (RE) and mental health (MH) (133, 134).

The Watson and Sonnabend score is a shoulder-specific questionnaire that evaluates the outcome after open rotator cuff repair. It is composed of 14 questions graded from 0 to 3 (135). The present results include a summary of the number of questions that improved per treatment group.

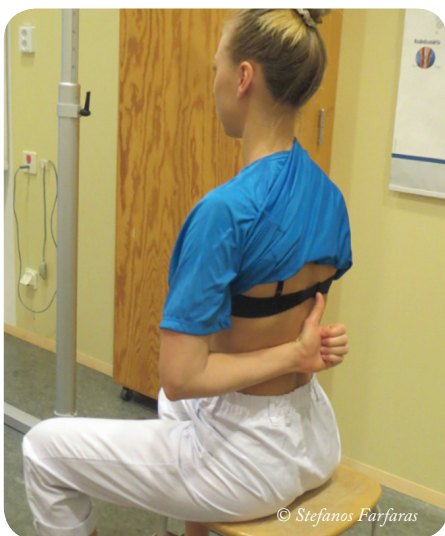


Figure 18. *Measurement of internal rotation.*

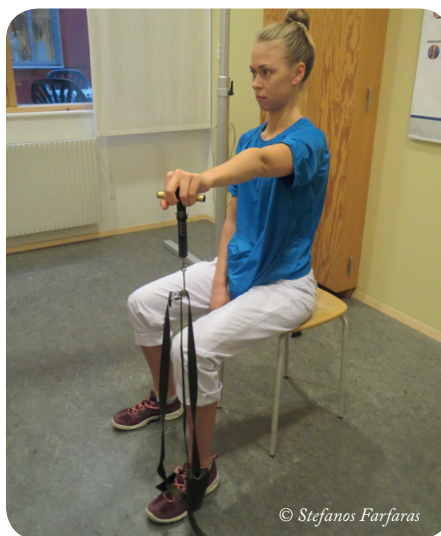

Figure 19. *Measurement of strength in the sitting position, using a “hand-held” dynamometer.*

Imaging assessments (Study II)

Patients from all three groups underwent ultrasound and radiographic examinations at baseline and follow-up.

The purpose of the ultrasound examination at baseline was to identify rotator cuff ruptures, while the purpose at follow-up was to evaluate impingement dichotomously (yes/

no), i.e. if the bursa and/or the rotator cuff was in conflict with the acromion during the impingement manoeuvre while the patient experienced pain, to identify rotator cuff ruptures and biceps tendinitis, to measure the acromion caput humerus distance at 60° of elevation and to detect subacromial bursitis (Figures 20 and 21).

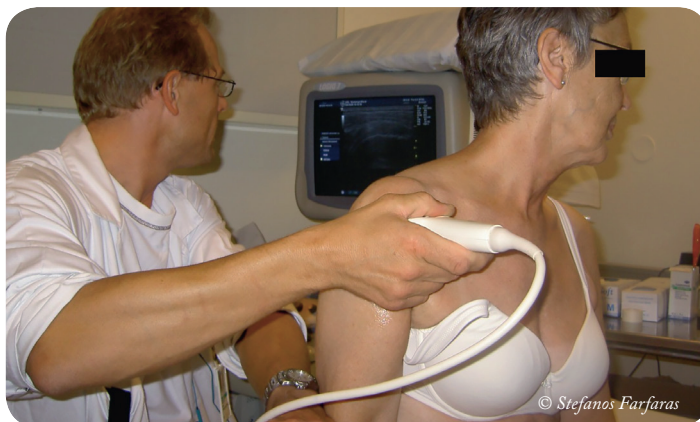

Figure 20. *Ultrasound examination of a patient at the long term follow-up.*

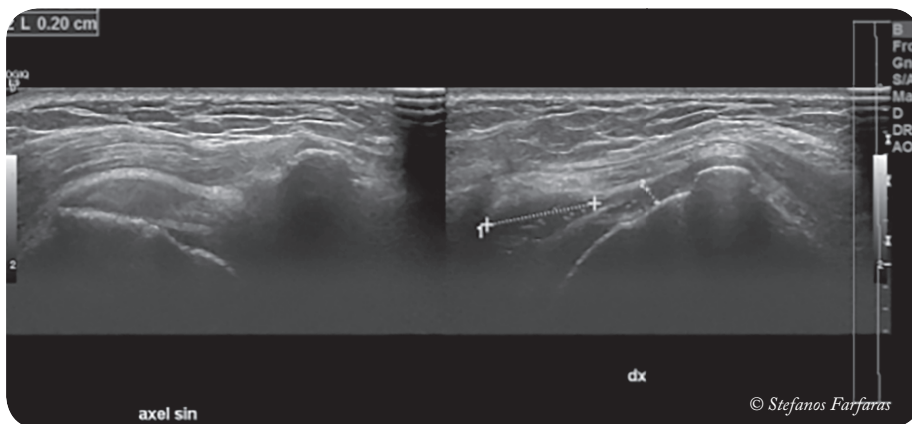


Figure 21. *Bilateral ultrasound image of a patient. To the right a full thickness supraspinatus tear is visualized (left shoulder, index side). To the left (contralateral side) an intact supraspinatus tendon is visualized.*

Standard radiographic examination

The radiographic examination performed at baseline aimed to identify the presence of OA or other joint disorders (Figures 22 and 23). At follow-up, the aim was to detect arthrosis in the acromio-clavicular joint, classify the configuration of the acromion, measure the distance between the acromion and the caput humerus, assess the proximal migration of the caput humerus and classify glenohumeral OA according to Rosenberg et al. (136).

Contralateral side

The contralateral side was also examined with ultrasound and radiographs as a control.

Examiners (Studies I & II)

In Study I, the same independent physiotherapist performed all measurements pre-operatively and at follow-up and was not involved in the rehabilitation. In Study II, one physiotherapist (the same as in Study I) made the measurements at baseline and another at follow-up. All the patients wore a t-shirt during the follow-up examination, to conceal surgical scars from the examiner. An experienced radiologist performed all radiographic and ultrasound examinations at baseline. A different radiologist examined all the patients with radiographs and ultrasound at follow-up. It was not possible to utilise the first radiologist at follow-up, as he had retired.

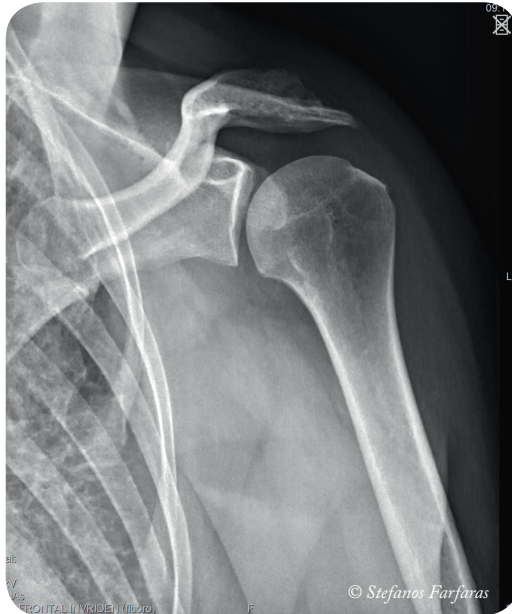

Figure 22. *X-ray of a shoulder at the long term follow-up with no signs of osteoarthritis.*

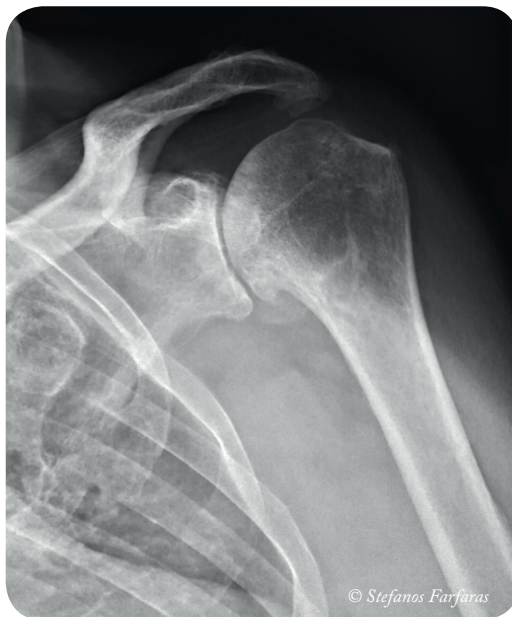

Figure 23. *X-ray of a shoulder at long term follow-up with severe osteoarthritis according to Rosenberg classification.*

4.4 PATHOPHYSIOLOGY OF SAIS (HISTOLOGY, ULTRASTRUCTURE AND BIOCHEMISTRY) (STUDIES III & IV)

Intervention

Before the arthroscopic intervention (sub-acromial decompression for Group A and Bankart reconstruction for Group B), a complete diagnostic arthroscopy was performed on each subject (Figures 14, 24 and 25). After the diagnostic arthroscopy, four full-thickness biopsies were obtained from

the cranial part of the mid-portion of the subscapularis tendon and four from the joint capsule just below the caudal part of the subscapularis tendon. The biopsy samples for Studies III and IV were harvested with an arthroscopic punch (Figures 26 and 27). Their size was approximately 1-2 × 1-2 mm.

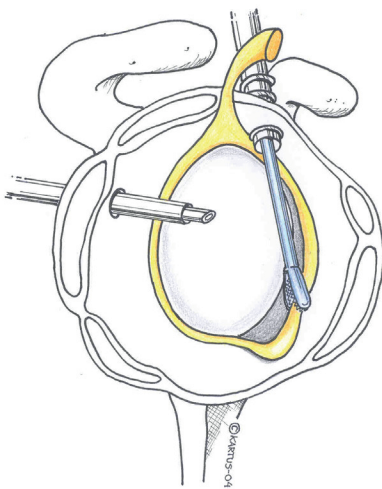


Figure 24. *The Bankart operation, step 1, mobilization of the capsulolabral complex*

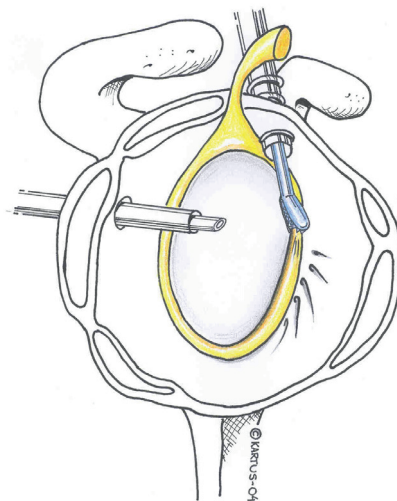


Figure 25. *The Bankart operation, step 2, proximal and lateral shift of the capsulolabral complex*

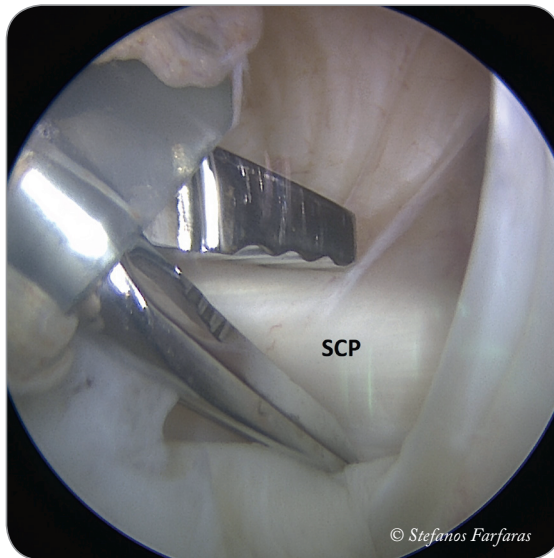


Figure 26. *Biopsies were obtained from the subscapularis tendon.*
**SCP=subscapularis tendon*

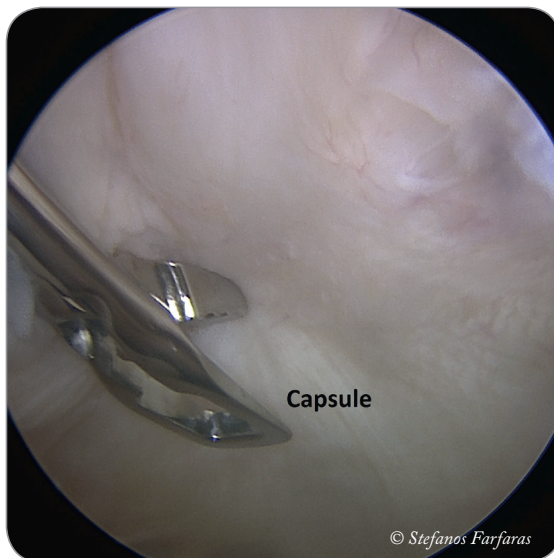


Figure 27. *Biopsies were obtained from the joint capsule.*
**Capsule=joint capsule*

Ultrastructural evaluation using transmission electron microscopy (Study III)

Specimens were collected and immediately fixed in 2% glutaraldehyde and 1% paraformaldehyde in 0.1 M sodium cacodylate buffer containing 0.1 M sucrose and 3 mM CaCl₂ (pH 7.4) at room temperature for 30 min, followed by 24 h at 4°C. They were then rinsed in 0.1 M sodium cacodylate buffer containing 3 mM CaCl₂ (pH 7.4) and post-fixed in 2% osmium tetroxide in 0.1 M sodium cacodylate buffer containing 1.5 mM CaCl₂ (pH 7.4) at 4°C for 2 h and then dehydrated in ethanol followed by acetone and embedded in LX-112 (Ladd, Burlington, Vt), for transverse sectioning. Ultra-thin sections (approximately 40-50 nm) were cut and contrasted with uranyl acetate followed by lead citrate and examined in a Tecnai 10 microscope (Fei Company, Eindhoven, the Netherlands) at 80 kV. From transverse-oriented specimens, two to four randomly selected areas were taken and the fibril diameter was measured, with an accuracy of 1 nm, on digital images using a semi-automatic measuring program at a magnification of ×101,000 (Soft Imaging System GmbH, Münster, Germany). The fibrils were grouped in intervals of 10 nm and presented as the relative distribution. One hundred fibrils were analysed in each specimen and the mean value was calculated with an accuracy of 1/10th of a nanometre. Two biopsy specimens from each patient were scanned; however, the fibril diameters were only measured in the biopsy with the best transverse orientation, while the other biopsy was left unmeasured.

Histological evaluation using the light microscope (Study III)

The samples were fixed in 10% neutral-buffered formalin, embedded in paraffin and

sectioned at 4-5 µm, according to routine procedures. The sections were stained with haematoxylin and eosin (H&E) to evaluate fibre structure, cellularity and vascularity and with Alcian blue (pH 2.5)-Periodic Acid-Schiff (AB/PAS) for the detection of glycosaminoglycan (GAG)-rich areas. A pathologist and an orthopaedic surgeon examined the tendon specimens together using a light microscope (Leica DMRBE, Wetzlar, Germany). The examiners were blinded in terms of both the group of the patient and the location from which the biopsy was obtained. This procedure and this evaluation system have been performed in multiple previous studies (60, 61, 137-139). Fibre structure, cellularity, vascularity and the level of GAGs were graded after examining the whole section. The number of cells was estimated in a high-power field (HPF) representative of the section. The results of the light-microscopic analysis were classified according to a semi-quantitative, four-point scoring system (0-3) and the total degeneration score (TDS). In each patient, two biopsies from the tendon and two biopsies from the capsule were graded. The TDS is similar to a scoring concept previously described by Movin et al. and used in a biopsy analysis of the Achilles tendon (59). It consists of four different elements, such as the fibre structure, cellularity, vascularity and GAGs. Each element can obtain between 0 and 3 points, depending on the degree of degeneration observed in the light microscope. For each sub-score, no signs of degeneration render 0 points and strong signs of degeneration 3 points. The score can result in values between 0 (no degeneration at all) and 12 points (extremely high degeneration), Fig 28.

Figure 28. *The four-point scoring system (TDS)*

	Grade 0	Grade 1	Grade 2	Grade 3
Fibre structure	Straight parallel, packed fibres, with slight waviness	Slight separation of fibres, increased waviness	Separation of fibres, deterioration of fibres	Complete loss of fibre structure and hyalinisation
Cellularity	< 100 cells/ high-power field (HPF)	100-199 cells/HPF	200-299 cells/HPF	> 300 cells/HPF
Vascularity	Vessels run parallel to the collagen fibre bundles in the septa	Slight increase in vessels, including transverse vessels in the tendon tissue	Moderate increase in vessels within the tendon tissue	Markedly increased vascularity with clusters of vessels
Glycosaminoglycans	No alcianophilia	Slight alcianophilia between the collagen fibers	Moderate increase in alcianophilia	Markedly increased alcianophilia forming blue lakes

Multiplex fluorescence immunohistochemistry (Study IV)

Each specimen was cut using a sliding microtome and mounted on SuperFrost slides (Histolab Products AB, Sweden). Two identical slides were sectioned and mounted from the most representative sample from each patient. Each specimen was analysed for TNF- α , IL-6, CD-3 and CD-72. TNF- α and IL-6 are pro-inflammatory cytokines which are expressed early and play a central role in the inflammatory process (140). CD-3 and CD-72 are cell surface molecules (Clusters of Differentiation-CD) aiming at T-cells and B-cells respectively (141, 142). T-cells are important in the initial stages of inflammation by activating B-cells, through the expression of various cytokines, or killing infected cells by transformation into killer T-cells (natural killer cells). The B-cells are activated and produce various antibodies in the inflammation process. Multiplex fluorescence immunohistochemistry was performed on histological sections from capsule and tendon sections to demonstrate the level of inflammatory markers. All the sections were initially treated on an automated Leica Biosystems (Worldwide) Bond RX system as follows. Briefly, sections were deparaffinised (Bond Dewax solution AR9222, Leica Biosystems, Worldwide), rehydrated and treated for 40 min in an ethylenediaminetetraacetic acid (EDTA)-based pH 9.0 solution (Bond Epitope Retrieval solution 2 AR9640, Leica

Biosystems, Worldwide) to unmask the antigens. Slides were subsequently incubated in normal donkey serum for 30 min. Two identical slides from each patient were treated separately using different primary antibodies in two experiments. The slides were incubated overnight at 4°C. The primary antibodies used in experiment 1 were the T-cell marker CD3E (HPA043955, Atlas Antibodies, Sweden), B-cell marker CD72 (HPA044658, Atlas Antibodies, Sweden) and IL-6 (HPA060030, Atlas Antibodies, Sweden). In experiment 2, endothelial cell marker CD31 (sc-1506, Santa Cruz Biotechnology, Dallas, USA), TNF-alpha (TNF- α) (HPA064998, Atlas Antibodies, Sweden) and collagen I (AB6308, Abcam, Worldwide) diluted (1:600, 1:600, 1:800, 1:70, 1:2000 and 1:200 respectively) in Bond Primary antibody diluent (AR9352, Leica Biosystems, Worldwide). After incubation with primary antibodies, the redundant antibodies were washed for 3 x 15 min in phosphate-buffered saline (PBS) and incubated for 90 min at room temperature with an appropriate secondary antibody tagged with different fluorophores [anti-mouse, -rabbit or -goat, Fluorescein IsoThioCyanate (FITC)-, Cyanine 3.5 (Cy3.5) or Cyanine 5 (Cy5) conjugated] diluted 1:200 in Tris/HCL, NaCl Blocking Buffer (TNB) (Perkin Elmer, Poland). After incubation with secondary antibodies, the slides were washed for 3 x 15 min in PBS. Furthermore, slides were

incubated for 10 min in 1% Sudan Black solution (Sigma/Merck, Germany) in 70% ethanol to quench auto fluorescence and mounted in 4', 6-diamidino-2-phenylindole (DAPI)-containing mounting medium (P-36931, Life Technologies, Massachusetts, USA).

Slide scanning microscopy and image analysis (Study IV)

Fluorescence microscope images were acquired on an automated scanning system (VSlide Scanning Platform, MetaSystems GmbH, Alltussheim, Germany) equipped with a CoolCube 2 camera (MetaSystems GmbH, Alltussheim, Germany), 2.5x, 5x, 10x and 20x objectives and filter sets for DAPI (to visualise the cell nuclei in both experiments), FITC (to visualise collagen I and CD3E in experiments 1 and 2 respectively), Cy3.5 (to visualise CD3 and CD72 in experiments 1 and 2 respectively) and Cy5 (to visualise TNF- α and IL-6 in experiments 1 and 2 respectively). Whole microscope slides were scanned at 2.5x and tissue was detected based on the DAPI signal. After generating a position map, all the tissue-covered areas were scanned using a 10x primary

objective (when the signal intensity was not strong enough, 20x was the primary objective chosen). Individual fields of view images were stitched to generate a large four-channel fluorescence image of the entire specimen with microscopic resolution. Fluorescence intensity and the distribution of proteins around different parts of the tendon structure were analysed using ImageJ (ImageJ National Institute of Health Software). The various tissue areas were segmented based on staining patterns of collagen and endothelial cells and information available in the literature (143). However, the evaluation of the tendon biopsies involved each slide that was made, taking account of all the parts of the tendon (epitenon, paratenon and endotenon) as a whole. No separate analyses for each of the different parts of the tendon were made. The size, intensity and distribution of proteins were determined using particle analysis, where the cut-off size and circularity were adjusted accordingly. On each slide, the number of pixels was registered and used in the analyses. All the analyses were made at SciLifeLab (a national centre for molecular biosciences) at Karolinska Institutet in Stockholm, by two experts.

4.5 STATISTICAL METHODS

Studies I & II

Mean (range) values are presented when applicable. For comparisons of dichotomous variables between groups, the chi-square test was used. To compare the three groups in terms of both continuous and non-continuous variables, the Kruskal-Wallis test was used and, if significant, the Mann-Whitney U test was used pairwise. Wilcoxon's signed-rank test was used for comparisons of the pre-operative and post-operative data within the study groups. A p value of < 0.05 was considered statistically significant. All p values are two-tailed.

The primary variable in Studies I & II was the Constant Score. In the power analyses, it was estimated that a 10-point difference in the Constant Score was considered to be of clinical importance. A standard deviation of 15, significance level at $p < 0.05$ and a power level of 80% give an estimated sample size of 36 per group. The study design was planned to include 40 patients in each treatment group. However, since the randomisation process took substantially longer than expected, the study was closed after recruiting 87 patients (OSG $n = 24$, ASG $n = 29$ and PTG $n = 34$).

Study III

Mean (SD) or median (range) values are presented when applicable. For comparisons of the fibril diameter and the TDS, the Mann-Whitney U test was used. A p value of < 0.05 was considered statistically significant. For the correlation analyses, the Pearson test was used. All p values are two-tailed.

The primary variable in the study was the fibril diameter. In the power analyses, it was estimated that a difference of 10 nm in fibril diameter between groups would be of interest to detect. To be on the safe side, it was estimated that the standard deviation would be up to four times the difference between groups. To reach a power of 80%, 252 fibril measurements from each group and from each location were required. To increase the power of the study, 2,000 (800 in the SAIS group and 1,200 in the instability group) fibril diameter measurements were made from each location. This means that a total of 4,000 measurements were made.

Study IV

Mean (SD) or median (range) values are presented when applicable. A p value of < 0.05 was considered statistically significant. All p values are two-tailed. For the comparison of the number of pixels and other parametric variables, the unpaired t-test was used.

The primary variable in the study was the number of pixels for the different inflammatory markers in the biopsies. In the power analyses, it was estimated that it would be of interest to detect a difference of one pixel in mean intensity between the groups. It was estimated that the standard deviation would be up to eight times the difference between groups. To reach a power of 80%, about 1,000 counts from each group were required for each comparison.

4.6 ETHICS

Studies I & II

The study plan was approved by the regional ethical review board in Gothenburg, Dnr 475-95 and Dnr 1077-11.

All patients gave their written consent.

Studies III & IV

The study protocol was approved by the regional ethical review board in Gothenburg, Dnr 076-12.

All patients gave their written consent.

05 RESULTS

5.1 STUDY I

Range of motion

Pre-operatively and at follow-up, there were no significant differences in elevation either between the three groups or within the three groups (page 2185 in publication I, Table 4).

The internal rotation increased over time in all three groups, with no significant difference between groups (page 2185 in publication I, Table 5). The improvement over time within all three groups was significant.

Muscle strength measurement

The active elevation strength revealed no significant difference between the three groups, but within groups it had increased significantly in the OSG but not in the ASG and PTG (page 2185 in publication I, Table 6).

Functional questionnaires

In terms of the Constant Score, there were no significant differences between the groups at follow-up, but within the OSG

and ASG there was a significant increase in the Constant Score (page 2184 in publication I, Table 3).

In terms of the SF-36, no significant differences were found between the three groups before and after intervention. In the OSG, PF, RP and BP had improved significantly at follow-up (page 2186-2187 in publication I, Tables 7-8). In the ASG, BP, VT, SF, RE and MH had improved significantly at follow-up (page 2186-2187 in publication I, Tables 7-8). In the PTG, RP and BP had improved significantly at follow-up (page 2186-2187 in publication I, Tables 7-8).

The Watson and Sonnabend score improved significantly for 12 of 14 questions at follow-up compared with pre-operatively in the OSG (page 2188 in publication I, Table 9). In the ASG, a significant improvement was found for five of 14 questions and, in the PTG, six of 14 questions had improved significantly ($p < 0.02$ OSG vs. ASG, $p < 0.05$ OSG vs. PTG and n.s. ASG vs. PTG).

5.2 STUDY II

Range of motion

Active elevation is presented on page 1401 in publication II, Table 3. At baseline, the groups were comparable, but, at follow-up, patients who underwent surgical treatment were significantly better than the PTG (ASG vs PTG, $p = 0.046$; OSG vs PTG, $p = 0.009$). Patients in the ASG preserved their range of motion over time, while the OSG ($p = 0.05$) and PTG ($p = 0.001$) had

significantly less active elevation at follow-up as compared with pre-intervention. When it came to internal rotation, all three groups had significantly better function at follow-up versus baseline (page 1401 in publication II, Table 4).

Muscle strength measurement

The muscle strength measurement in elevation is presented on page 1402 in publication

I, Table 5. Both surgical treatment groups improved over time, but the improvement was only statistically significant in the OSG ($P = 0.003$). No statistically significant difference over time was seen in the PTG.

Functional questionnaires

The Constant Score before and after intervention is presented on page 1402 in publication II, Table 6. Both surgical groups improved significantly (OSD, $p = 0.003$; ASG, $p = 0.011$). This was not seen in the PTG.

Health status, as measured with the SF-36 for each treatment group before and after the intervention, is presented on pages 1403-1404 in publication II, Tables 7 and 8 respectively. All groups showed an improvement in role physical and bodily pain. Furthermore, the OSG improved in terms of physical functioning; the ASG, for mental health and the PTG, for vitality.

In terms of the Watson and Sonnabend score, no significant difference was found between the groups ($p = 0.14$). The OSG improved significantly in 13 of 14 questions, the ASG in nine and the PTG in nine.

Ultrasound and radiographic evaluation

At follow-up, ultrasound evaluation revealed no significant differences between the three groups and within the groups between the index and contralateral sides regarding full-thickness rotator cuff ruptures, subacromial bursitis and acromion-caput humerus distance (page 1405 in publication II, Table 9).

Likewise, the radiographic examination at follow-up revealed no significant differences in the presence of OA between and within the groups (index side vs contralateral side) (page 1406 in publication II, Table 10).

5.3 STUDY III

The correlation coefficient between age and fibril diameter was $r = -0.20$ for the subscapularis tendon and $r = -0.25$ for the capsule (page 82 in publication III, Figs. 2, 3). The ultrastructural evaluation revealed that the instability patients had more fibrils of large diameter in both the subscapularis tendon and the capsule compared with the SAIS patients ($p < 0.0001$) (page 82 in

publication III, Figs. 4, 5 and page 83, Table 2). Cellularity was significantly higher in the capsule ($p = 0.016$) and the TDS of the capsule was significantly higher ($p = 0.014$) in patients with SAIS compared with the instability patients. The corresponding finding was not made for the subscapularis tendon (page 83 in publication III, Figs. 6, 7 and page 84 Table 3).

5.4 STUDY IV

The amount of IL-6 and TNF- α was significantly higher in the subscapularis tendon of the patients with SAIS compared

with the instability patients. No significant difference was found regarding CD 3 and CD 72 (Table 3).

Table 3. *The mean concentration expressed in pixels of CD 3, CD 72, IL-6 and TNF- α in the subscapularis tendon.*

	CD 3		CD 72		IL-6		TNF- α	
	Mean	SD	Mean	SD	Mean	SD	Mean	SD
SAIS (pixels) Counts	5.7 n=932	6.0	3.3 n=889	2.8	5.8 n=889	13.2	8.5 n=2943	17.4
Shoulder instability (pixels) Counts	5.7 n=2532	16.5	3.1 n=2532	2.6	4.6 n=2532	8.3	7.4 n=5654	12.0
p value	n.s. (p=0.94)		n.s. (p=0.08)		p=0.0015		p=0.0008	

*n.s. = non-significant

In the capsular samples, significantly higher TNF- α and CD 72 were found in patients with SAIS compared with instability patients, as is shown in Table 4. On the other

hand, CD 3 was significantly higher in the instability group. No significant difference was found for IL-6.

Table 4. *The mean concentration expressed in pixels of CD 3, CD 72, IL-6 and TNF- α in the capsule.*

	CD 3		CD 72		IL-6		TNF- α	
	Mean	SD	Mean	SD	Mean	SD	Mean	SD
SAIS (pixels) Counts	5.8 n=3812	11.4	4.2 n=3812	3.5	4.0 n=3812	6.8	7.9 n=7421	12.9
Shoulder instability (pixels) Counts	6.7 n=5767	15.6	3.5 n=5767	3.7	4.3 n=5767	9.3	5.4 n=18908	8.8
p value	p=0.0013		p<0.0001		n.s. (p=0.0992)		p<0.0001	

*n.s. = non-significant

Figure 29 illustrates the protein expression differences between the instability and the

SAIS group patients in the joint capsule and the subscapularis tendon.

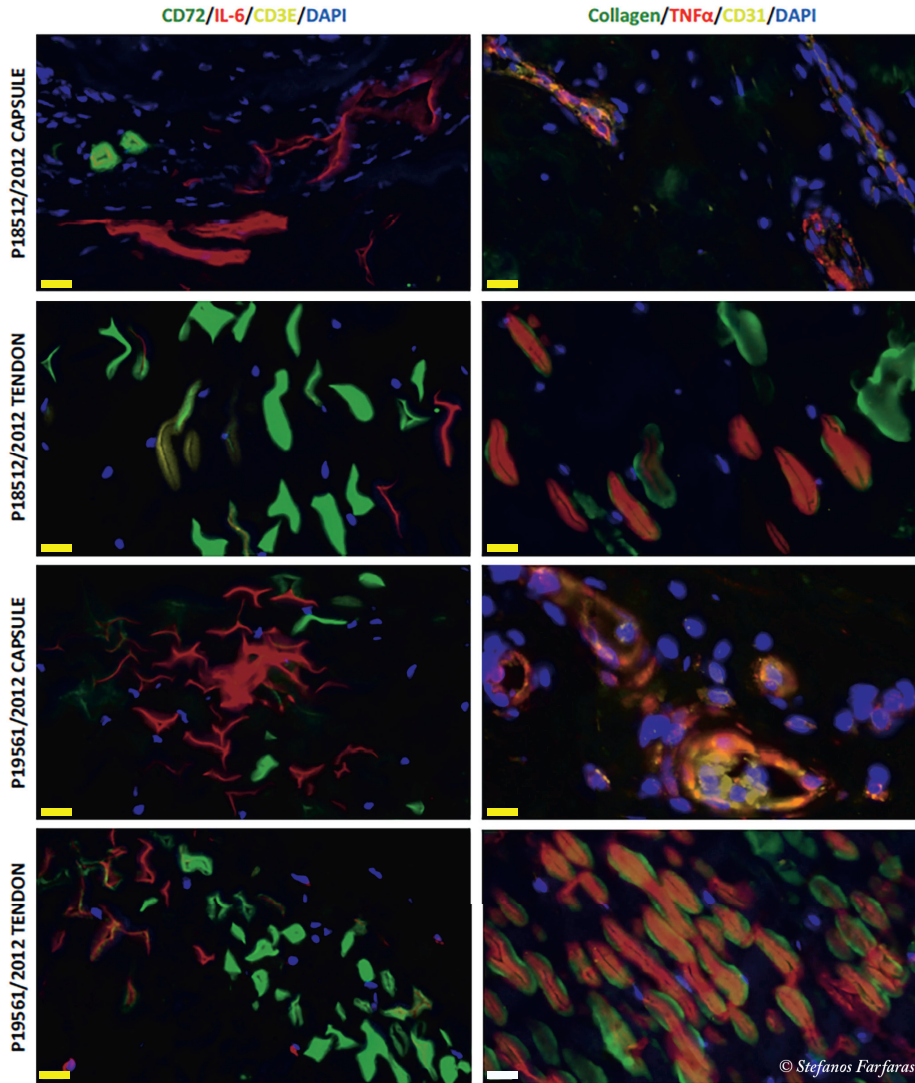


Figure 29. The figure depicts protein expression in capsule and tendon tissue samples from two patients, one from the instability group (P18512/2012) and one from the pain group (P19561/2012). Representative staining is shown for inflammatory molecules TNF- α and IL6, together with T-cell marker CD3E, B-cell marker CD72, endothelial marker CD31 and Collagen I. CD31 and Collagen I were used for orientation purposes and thus not further used in the analyses. A general trend towards more robust signalling for TNF- α , IL6 and CD72 is evident in cells from the “pain” patient (compared with the “instability” patient). Scale bar 5 μ m (yellow bar) and 20 μ m (white bar).

06 DISCUSSION

6.1 CLINICAL OUTCOME IN THE SHORT TERM

The principal finding in Study I was that all three groups (ASG, OSG and PTG) had a similar improvement in terms of clinical assessments, for the Constant Score, the range of motion and the strength evaluation. In addition, no significant difference was found between the three groups, in the short-term follow-up. In this study, Böhmer's physiotherapy programme was used (91, 94). At the time when the study was designed, the treatment algorithm of Böhmer was well established in the catchment area where the study was performed, for the non-surgical rehabilitation of patients with SAIS. However, to our knowledge, the method had not been evaluated in terms of validity and reliability. A discussion about whether or not subacromial decompression is effective, compared with physiotherapy alone, has been going on for many years (11, 87, 92, 113-119). There are contradictory data in the literature; some of the studies show a benefit from subacromial decompression, often with concomitant AC-joint resection, while others show no difference between structured training programmes and surgery, followed by the same training programmes (11, 33, 41, 58, 87, 92, 113-119). This fact raises the question of whether or not the contradictory results in these studies are due to the different study protocols used (different physiotherapy protocols, different follow-up periods etc), which may be a source of bias, or are due to the concomitant AC resection performed in some patients in combination with the acromioplasty. These studies have not

investigated or reported the percentage of concomitant AC resections and it is therefore difficult to interpret these questions with the available data (11, 92, 113-119). Unfortunately, in neither Study I nor Study II was this taken into account.

It is reported that there is an inherent difficulty when using data from different studies. Angst et al. suggested caution when comparing data from different studies, as different versions of scores and different measurement methodologies may lead to problems (144). Furthermore, differences in the studied populations may involve selection bias. This is in line with Kirkley et al., who suggested the use of modern evaluation instruments, which are tested for validity and reliability (145). As a result, it is reasonable to say that the risk of bias is high when comparing the results of different studies and these results should therefore be interpreted with caution.

In Study I, the OSG group had a lower Constant Score compared with the other two groups at baseline, but this difference was not significant. At the follow-up, the Constant Score had increased significantly in the OSG, but the difference between groups was not significant. An increase of 15-24 points in the Constant Score has been found in other studies. However, these studies involved different study groups, such as a specific physiotherapy protocol versus non-specific physiotherapy, arthroscopic versus physiotherapy treatment versus placebo, as well as different follow-up periods (87, 88, 116, 146, 147). Lunsjö et al.

showed that the Constant Score continues to improve up to six years after surgery (112). Biberthaler et al. reported a significant increase of Constant Score in patients older than 57 years compared with younger patients five years after arthroscopic decompression (120). In the same study, this difference was not seen in the PTG. In Study I, age was considered in the randomisation process, but age-dependent subgroup analyses were not possible, due to the small study groups. Dickens et al. compared physiotherapy with a control group waiting for surgery and found that the PTG increased their Constant Score by 20 points after six months (146). Eleven of 45 patients did not require surgery after rehabilitation. This is in line with the results of Study I, where some of the patients randomised to surgery subsequently declined surgery due to the improvement of their symptoms while waiting for surgery. The opportunity to improve shoulder function without surgery is further stressed in a pilot study by Jonsson

et al. who reported a substantial increase in the Constant Score one year after a 12-week eccentric training programme (88). The Constant Score is the most commonly used shoulder score and it has been tested for validity and reliability (132). Even though it is regarded as a universal shoulder score, there are contradictory results in the literature relating to the efficacy of subacromial decompression versus physiotherapy alone (92, 113-116). It appears that the natural course of the syndrome may include a spontaneous improvement in symptoms (119). This raises the question of whether or not this improvement is due to therapy, surgical or non-surgical, or to the body's self-healing ability and whether the subjective improvement may be due to the "adaptation" of the patient's activities and expectations. According to Brox et al., this is not the case, as they found a better outcome in both the surgical and physiotherapy groups compared with placebo, 2.5 years after intervention (113).

6.2 CLINICAL OUTCOME IN THE LONG TERM

The most important finding in Study II was that patients undergoing subacromial decompression for SAIS maintain a good result, regarding the primary outcome variable of the study, the Constant Score. This was not the case for patients treated with physiotherapy 14 years after intervention. The median value of the Constant Score was maintained at a remarkably high level for both surgical groups and had even improved slightly over time, compared with the findings in the same population 2.5 years after intervention, despite the long follow-up period (117). This was not found for the PTG. This finding suggests that subacromial decompression helps to maintain good shoulder function over time. It is important to underline that, in the short-term follow-up of the patients in the present study, the follow-up rate was very low and a potential source of bias should

therefore be considered. These results are in line with other studies, with a substantially shorter follow-up period (112, 148). It is well known that ageing affects the strength and range of motion in the human body and more particularly in the shoulder (132, 149). A worsening of the Constant Score would therefore be expected when patients get older. The mean age at follow-up in the three groups was between 60 and 66 years. Despite increasing age, the Constant Score was significantly better 14 years after intervention than pre-operatively. One possible explanation could be that patients progressively limit their activity level when ageing and thus prevent their shoulder from affecting their ADL to a greater extent. Both Lunsjö et al. and Biberthaler et al. showed that the Constant Score continues to improve six and five years respectively after subacromial decompression (112, 120).

These findings are in line with the results in our study and provide evidence that subacromial decompression has a positive

effect, in terms of shoulder function, in patients with SAIS.

6.3 PROMs IN THE SHORT TERM

The Watson and Sonnabend scale is adapted from the Simple Shoulder Test and evaluates 14 common functions of daily activity (135). In their study evaluating open rotator cuff repair, the majority of the patients were better six months after surgery and, in patients older than 55 years, an even better result was found. In Study I, more of the activities improved in the OSG than in the other two groups, perhaps because the patients in this group were somewhat worse before intervention. For the last two questions on performing usual work and sports activities, about a third to a half of all the patients in the present study replied that these activities were not difficult to perform. Even though an improvement was seen, it is evident that many patients did not return fully to work or their previous sporting activity. This means that, even two to three years after initial treatment, full recovery is

difficult to achieve in patients with SAIS. Östor et al. analysed patients with shoulder pain visiting primary care units and found that 74% were diagnosed as SAIS (150). In their study, all the patients obtained lower scores on the SF-36 in all eight scales, compared with age-matched normative data. However, there were no differences between SAIS and other diagnoses. Comparing the SF-36 values in Study I with Swedish normative data, lower values, especially for the physical scales, were generally found (133). The score for Bodily Pain was, however, significantly higher (e.g. better) in all three groups at follow-up compared with the values before intervention. Chipchase et al. analysed pre-operative health status using the SF-36 in patients with chronic SAIS and presented results similar to those in Study I in terms of the physical scales (151).

6.4 PROMs IN THE LONG TERM

For the Watson and Sonnabend score, the OSG improved in almost all questions, but this was not seen in the ASG and PTG. In their initial study, Watson and Sonnabend reported that patients older than 55 years demonstrated a better outcome six months after surgery (135). In Study II, the mean age of the population at follow-up was well above 60 years of age. The fact that people over 55 years of age appear to have a better outcome after surgery is difficult to interpret. It may also be due to decreased expectations in terms of shoulder function and adaptation in daily activities over time. In terms of the SF-36, results comparable to those in the 2.5-year study were seen. However, in the long-term follow-up, it appears that patients in all groups failed to

maintain the improvement seen shortly after intervention in some aspects of the SF-36. Östor et al. have reported that patients with SAIS have poorer results in terms of the SF-36 compared with age-matched individuals. In a survey from 1998, Sullivan et al. reported the normative data for the SF-36 in a normal Swedish population (133). Comparing the results of Study II with Swedish normative data, lower values were obtained, especially for the physical scales. Furthermore, Östor et al. reported that there was no difference in SF-36 results between SAIS and patients suffering from other shoulder diseases (150). These studies suggest that a ceiling effect might be present for the lower SF-36 results, especially for the physical scales.

6.5 ROTATOR CUFF TEARS IN THE LONG TERM

The ultrasound evaluation did not reveal any differences between the groups at the long-term follow-up. In an RCT comparing patients with SAIS treated with either subacromial decompression or physiotherapy, Ketola et al. found no difference in supraspinatus tendon tear prevalence between the groups, two and five years after intervention (118, 119). This is in line with the

findings in Study II. Subacromial decompression cannot therefore be suggested as a prophylactic procedure for rotator cuff tears, even in the long term. This is also in line with the results of Kartus et al. (12), who reported that 35% of patients with a partial rotator cuff tear proceeded to a full-thickness tear a minimum of five years after subacromial decompression.

6.6 OSTEOARTHRITIS DEVELOPMENT IN THE LONG TERM

On the radiographs, no differences between or within the groups were observed regarding the development of OA, a minimum of 10 years after the initial treatment. It is well known that shoulder pathologies and specifically OA are related to increasing age (152-154). Despite the expected increase in

OA in ageing individuals, the prevalence of OA in the glenohumeral joint was low in the long-term follow-up in both the PT group and the surgical groups. It therefore appears that acromioplasty is not indicated to minimise the risk of OA in the future.

6.7 SOFT-TISSUE DEGENERATION

In Study III, the ultrastructural evaluation revealed significantly larger fibril diameters, indicating less degeneration, in samples from both the subscapularis tendon and the joint capsule in male patients with post-traumatic recurrent shoulder instability compared with male patients with SAIS. Correspondingly, the histological evaluation revealed significantly more degenerative changes in the capsule in male patients with SAIS.

A similar pattern has been reported in tendons with tendinopathy, from other parts of the body, such as the Achilles tendon and the patellar tendon. Pingel and al. showed that fibrils with a small diameter (<50 nm) are significantly increased in Achilles tendinopathy compared with healthy individuals (155). This finding is in line with the results of Study III, indicating that degenerative changes in the form of fibrils with smaller diameters are present in the subscapularis tendon of patients with SAIS. Likewise, Lidén et al. found that fibrils with sizes

from 31 to 90 nm represented up to 90% of fibrils in regenerated patellar tendon, 10 years after reharvesting the patellar tendon for anterior cruciate ligament (ACL) revision reconstruction, whereas only 50% of fibrils of the same size were found in healthy control samples (156). Similar findings in biopsies from the patellar tendon were also reported by Svensson et al. six years after primary harvest (60, 61). They only found fibrils of small diameter (up to 60 nm) in the central part of the previously harvested patellar tendon. A change in the loading capacity of the regenerated tendon is implicated as the reason for this.

It appears that smaller fibrils are more susceptible to failure. Proctor et al. found that the repair tissue in patellar tendons in goats was composed primarily of fibrils with diameters ranging from 50 to 100 nm (157). Furthermore, fibrils with smaller diameters (mostly between 40 and 60 nm) are found, after spontaneous rupture, in human tendons, as shown by Jozsa et al. (158).

Moreover, Magnusson et al. found significantly fewer fibrils with diameters above 60 nm in spontaneously ruptured Achilles tendons in humans (159). These studies indicate that fibrils with smaller diameters may be of poorer quality and less tolerant of load and stress. In line with this, Pingel et al. found increased numbers in cells and smaller collagen fibrils in patients with Achilles tendinopathy (155).

One possible explanation for the findings could be that patients with subacromial impingement experience a chronic process of micro trauma and regeneration, but the procedure fails to rebuild a tendon of the same quality, leading to chronic degeneration and eventually to secondary ruptures in the rotator cuff. Both Svensson et al. and Lidén et al. had long follow-up periods, six and 10 years respectively, in their studies of the patellar tendon (60, 61, 156). However, both investigated tendon alterations after a significant, acute trauma (tendon harvesting per-operatively), which is not the case in patients with a chronic degenerative process, such as patients with SAIS in the present study.

The group with SAIS also had a significantly smaller number of fibrils with large diameters, compared with the instability group, in their capsule samples when analysed in the electron microscope. It is known that a traumatic rupture of the joint capsule occurs when the shoulder dislocates. A change in the appearance of the joint capsule of patients with shoulder instability could therefore be expected, due to repetitive trauma. Although the joint capsule in patients with recurrent shoulder dislocation is strained due to previous trauma, it appears to be in better condition compared with the capsule of patients with SAIS. All patients with shoulder instability were operated on after at least three dislocations. It is therefore reasonable to expect, to some degree, degenerative changes in their capsule compared with healthy individuals.

The light-microscopic analysis revealed increased cellularity and increased TDS in

the capsule of patients with SAIS. Findings similar to those in the present study have been reported in patients with rotator cuff tears. Longo et al. found that the thinning and disorientation of the collagen fibres was more pronounced in biopsies from rotator cuff tears compared with cadaveric samples and that the pathological score for ruptured tendons was poorer in comparison to that of the control cadaver samples (13, 160). Pauly et al. found decreased cell growth and a reduced amount of collagen type I in patients scheduled for rotator cuff repair (161). In this case, however, the examined tendon was already injured. The extent to which the injury itself may have caused these alterations is not known.

Both human and animal studies have demonstrated collagen cell alteration in Achilles tendinopathy. Cho et al. examined an overuse model of the Achilles tendon in rats. The protocol included exercising the right leg for two, four and six weeks. The left leg was used as a control. They found increased cellularity of fibrocytes in the right leg after four and six weeks of exercise (162). This suggests the development of degeneration in a tendon due to overuse activity.

Furthermore, the light microscope revealed an alteration in fibre structure in the capsule in the SAIS group compared with the instability group. These patients tended to have a change in the orientation and shape of their fibres compared with patients with shoulder instability, but it was still not significant. In terms of vascularity and the content of GAGs, both the capsule and the tendon had similar appearances in both groups. The absence of neo-vascularisation and the almost normal alcianophilia indicate no excessive inflammatory activity in these areas. This implies that, even if a significant difference was found in the TDS, this was mostly due to the significant difference in cellularity.

Remarkably enough, the joint capsule appears to be in a better condition in patients with recurrent shoulder dislocation, despite the anticipated strain after shoulder

dislocation. It would therefore have been interesting to compare the joint capsule in patients with dislocations with the capsule in healthy individuals.

As it is impossible for ethical reasons to assign healthy persons to an unnecessary operation and to harvest normal control samples, the use of samples from patients with recurrent shoulder instability appeared to be the most attractive way to study and compare intra-articular degenerative soft-tissue changes. An alternative control group could have comprised patients planned for total shoulder arthroplasty for degenerative joint disease (DJD). A control group of this kind would also have been "matched" in age with the SAIS group, as it is well known that DJD is common in patients above the fifth decade of life (163). However, in a control group like this, probably both the tendon and the capsule would have revealed degenerative changes in the soft tissue as well. In addition, even though the subscapularis tendon and the capsule in the control group (instability patients) can be regarded as affected samples compared with healthy tendon, significantly more degeneration was found in the SAIS group. This implies that a theoretical comparison between tendon and capsule samples from patients with SAIS and completely healthy individuals would have shown at least the same difference as in Study III.

Using MRI, Gyftopoulos et al. reported significant tendinosis changes in the subscapularis mid-portion and caudal portion of patients with shoulder instability compared with controls with other shoulder pathology (164). Moreover, the use of specimens from the subscapularis muscle as controls has previously been reported in the literature (165, 166). Furthermore, Yuan J et al. have reported that there are no alterations in the subscapularis tendon, immunohistochemically, in specimens harvested from patients with recurrent shoulder dislocation (167).

It might be that age itself causes more degeneration. There is limited information

indicating that shoulder degeneration is connected to age. Chillemi et al. found a correlation between tendon chondral metaplasia, bursal neoangiogenesis and patient age (168). On the other hand, signs of greater degeneration in younger patients with different tendon pathologies have been reported. Maffulli et al. examined specimens from patients with a spontaneously ruptured quadriceps tendon and compared them with specimens from healthy individuals (169). They used a pathological score to evaluate the tendon degeneration, similar to the score used in Study III. Even though the patients with a ruptured quadriceps tendon were significantly younger than the controls, the pathological score was significantly higher (poorer) in the group of younger patients with ruptured tendons. Similar results have been reported by Tallon et al. in a study examining patients undergoing surgery for Achilles tendon rupture, Achilles tendon tendinosis and individuals with no history of Achilles tendon disease (170). They also found fewer signs of degeneration in the control group, despite their significantly higher age. Taking account of the fact that only a weak negative correlation between age and fibril diameter was found in the present study, it appears to be the case that a chronic degenerative process occurs in patients with SAIS. Further support for the hypothesis that the syndrome itself is more responsible than age for the degeneration has been reported by Meknas et al., who found significantly more degeneration in the obturator internus tendon in the hip of patients with OA than in patients who had suffered a hip fracture, in spite of the latter being 20 years older (138).

All the patients in the SAIS group had subacromial corticosteroid injections administered prior to referral to surgery. This was not the case for the shoulder instability group. It appears unlikely that these injections could have affected the intra-articular space, since no patients had full-thickness rotator cuff tears.

6.8 SOFT-TISSUE INFLAMMATION

The most important finding in Study IV is the presence of increased levels of pro-inflammatory cytokines both in the subscapularis tendon and in the joint capsule in patients with SAIS compared with patients with shoulder instability. This finding suggests that a more widespread inflammatory process is present in patients with SAIS, affecting not just the subacromial bursa but even structures not directly adjacent to it (joint capsule and subscapularis tendon).

The role of pro-inflammatory cytokines has been demonstrated in the subacromial bursa in patients with both rotator cuff disease and other shoulder conditions. Rahme et al. has demonstrated increased amount of inflammatory cells (mononuclear cells) in bursal biopsies in patients with SAIS (57). Increased levels or expression of TNF- α and IL-6 in the subacromial bursa have been found by Sakai et al. (81), Blaine et al. and Voloshin et al. in patients with rotator cuff tears compared with controls (79, 80, 82). Kanbe et al. have shown an increase in the expression of IL-6 around vascular tissue in patients with frozen shoulder and concomitant SAIS (synovial proliferation during arthroscopy at the rotator interval) (171). It has also been reported by other authors that frozen shoulder may develop secondary to subacromial bursitis (172).

In Study IV, increased levels of pro-inflammatory cytokines (IL-6 and TNF- α) were found in the shoulder joint capsule and subscapularis tendon. This implies that the source of pain may be due to a diffuse inflammatory process which extends beyond the subacromial bursa. As the patients included in this study had no perforating rotator cuff tears, it is unlikely that the increased expression of cytokines in the specimens was due to proliferation/affection from the inflamed subacromial bursa. This finding must therefore be regarded as a local inflammation. Gotoh et al. have demonstrated increased levels of IL-1 β in

the glenohumeral synovia in patients with rotator cuff disease and perforating rotator cuff tears compared with those with non-perforating tears (173). This finding is in line with the results in Study IV, even though the increase in Gotoh's study may be due to the proliferation of cytokines through the perforating tear. Furthermore, in Gotoh's study, no control group with a healthy tendon was analysed.

The exact role of various pro-inflammatory cytokines in the human body is not as yet well investigated. It is known that IL-1 β is expressed in early inflammation stages together with TNF- α and induces the production of IL-6 (140). Furthermore, Tsuzaki et al. have demonstrated that IL-1 β induces IL-6, among other factors, in flexor digitorum profundus specimens in normal controls (174). These data support the findings in Study IV relating to the role of TNF- α and IL-6 in the inflammation of the subscapularis tendon and joint capsule in SAIS patients. It is possible that more cytokines, such as IL-1 or IL-8, may also be increased in SAIS patients. In Study IV, it was, however, decided to determine the cytokines to be analysed in advance and limit the number of analyses made to TNF- α as a pro-inflammatory cytokine and IL-6 which is expressed later in the inflammation cascade process (140) and not to screen for whichever cytokines might be present.

Another finding in the present thesis is the increased amount of CD-72 in the capsule of SAIS patients. CD-72 is a glycoprotein involved in B-cell proliferation and differentiation (175). Furthermore, it is a B-cell receptor (176). This indicates an increase in the activity and proliferation of B-cells in the synovial tissue of the joint. The increased number of pro-inflammatory cytokines and B-cell activators in the subscapularis tendon and joint capsule in the SAIS patients suggests a more comprehensive inflammation than in the subacromial bursa alone.

This may be due to the endocrine action of the cytokines in question or diffusion in the adjacent tissues. It can therefore be assumed that the inflammation that occurs in the subacromial bursa has a distal effect even on the joint capsule.

Subacromial corticosteroid injections and NSAIDs have been used on a wide scale in the management of subacromial impingement (84-86). As it appears that the inflammation is not localised to the

subacromial bursa alone but also spreads to adjacent structures, it might be worth treating these structures as well. A selective and effective factor, such as a cytokine antagonist towards TNF- α and IL-6, may be of interest. This would offer target-specific therapy and would possibly avoid the side-effects of corticosteroid use. To the author's knowledge, no treatment of this kind has so far been applied.

07 STRENGTHS AND LIMITATIONS

Study I

The strengths of Study I relate to its prospective randomised design, the fact that the physiotherapist performing the assessments before intervention and at follow-up was not involved in the rehabilitation and that all three groups were rehabilitated according to the same rehabilitation programme. Furthermore, attempts were made to avoid bias at examination by getting the patients to wear a t-shirt during the examination procedure.

The limitations of the present study relate to the small number of participants. The recruitment process was terminated before the full number of patients was included, due to the time factor and an unfortunate crossover between groups. The intention-to-treat principle was not considered because of its inherent weakness when comparing surgical treatments. This resulted in the exclusion of patients in both surgical groups, who improved with physiotherapy while waiting for surgery and therefore declined surgery. On the other hand, patients in the PTG also had to be excluded because they were not satisfied and therefore underwent surgery. Taken together, there is a substantial risk that the present study suffers from a type II error.

Study II

The strengths of Study II involve its prospective randomised design and the long follow-up period.

The main limitation of the present study is that the follow-up rate was only 76%. A desirable follow-up rate in randomised controlled trials is < 80%. However, taking

account of the long follow-up period and the increased morbidity at such an advanced age, the follow-up rate in the present study is acceptable. Furthermore, the size of the study group was lower than planned, which may involve a substantial risk of a type II error. In addition, the PTG had a slightly higher but non-significant number of patients with a duration of symptoms 36 months before the intervention, which may have accounted for the poorer results in this group. Another limitation is the risk of inter-rater bias, specifically, one physiotherapist and one radiologist performed the baseline assessments, followed by a different physiotherapist and a different radiologist at follow-up. However, the assessments were limited to one evaluator at each time point, thereby lessening the risk. The long rehabilitation period (six months) may also not be generally applicable, owing to low compliance. Further weaknesses involve the radiographic examination conducted before the intervention, which was performed only to exclude patients with OA; as a result, no acromion morphology measurements and no anterior acromion spurring and coraco-acromial ligament ossification evaluations were performed. In line with this, the more comprehensive radiographic evaluation at follow-up also involved no evaluation of coraco-acromial ligament ossification.

Study III

The strength of Study III is that it was performed on living humans with macroscopically intact subscapularis tendons and intact capsules. Most other studies report

the findings in ruptured tendons, animals or in cadaver material (13, 52, 62, 63, 162, 166, 168, 177).

The main limitation of Study III is that using samples from the subscapularis tendon and capsule from patients with recurrent shoulder dislocations as controls can be questioned, as previous injury to the muscle/tendon complex and the joint capsule, due to recurrent dislocations, may exist. A further limitation is that the study was only power calculated for the difference in fibril diameter. Other limitations are that the two groups were small and had differences in terms of age and that female individuals were not examined. This was inevitable due to the instability prevalence (higher in males and younger active individuals).

Study IV

The strength of Study IV is that cytokines were measured in tissue specimens from the affected area and not in the bloodstream and that this was done in humans.

The main limitation of this study was that only male patients were included, due to the risk of bias, because of the fluctuation in cytokine levels in premenstrual females and the difficulty recruiting females with recurrent shoulder instability, as the prevalence in this population is low. The study groups were therefore relatively small. Another limitation is that the method used to determine the levels of cytokines in tissue samples has not yet been validated.

08 CONCLUSIONS

Study I

The primary variable, the Constant Score, as well as other clinical assessments and the subjective health-related quality of life, revealed no significant differences between the OSG, ASG and PTG two to three years after intervention in patients with SAIS. The OSG showed a generally greater improvement over time.

Study II

After a minimum 10-year follow-up, the surgical treatment of SAIS appears to render better clinical results than physiotherapy alone. No significant differences were found between the groups in terms of the

presence of full-thickness rotator cuff ruptures and OA.

Study III

Male patients with subacromial impingement have more histological and ultrastructural degenerative changes in their shoulders compared with patients with post-traumatic recurrent shoulder instability.

Study IV

An extended inflammatory process is present, not just in the subacromial bursa but also in the glenohumeral joint, in male patients with SAIS.

09 FINAL CONSIDERATIONS – FUTURE PERSPECTIVES

The pathophysiology of the syndrome

After the initial approach by Neer and the anatomical explanation of the syndrome, new data show that SAIS is a multifactorial syndrome, which involves anatomical changes, structural changes in the soft tissue around the subacromial bursa and the presence of chronic inflammation. This necessitates a modification of the SAIS approach for both the diagnostic approach and the treatment strategies.

Risk of secondary OA and rotator cuff tears

This thesis failed to show any increased risk of developing OA or rotator cuff tears in patients with SAIS treated non-surgically, in the long term. A prophylactic subacromial decompression cannot therefore be suggested.

Optimal treatment for subacromial impingement syndrome

The optimal treatment for SAIS is still questionable. Some of the patients do well with just physiotherapy, while others require surgical treatment. It seems, however, that subacromial decompression may have small advantages in terms of functional outcome and daily function compared with just physical treatment. At the same time, it is still a surgical procedure, with all the associated risks. The challenge when treating patients with SAIS is to identify in advance which of them may benefit from physical treatment and which of them will not. The present thesis failed to find any such guidelines for patient selection. It appears logical to perform studies to investigate subgroups of the population, such as stratified by age and gender.

Furthermore, is there a bias in the selection of patients when comparing surgical with non-surgical treatment? The common practice today is to treat patients with SAIS initially with physiotherapy and, in some cases, to add local injections. Does this mean that patients who are randomised to either surgery or structured physiotherapy, in most studies, are actually non-responders to therapy? Is this why some studies reveal no significant difference between surgery and structured physiotherapy, while others report a better clinical outcome after surgery?

New perspectives in SAIS treatment

To date, the treatment has been directed toward the subacromial space. Treatment efforts focus on widening the subacromial space by either surgical or non-surgical means.

This thesis provides evidence that there are also structural changes and degeneration in the rotator cuff and the capsule inside the shoulder joint. This indicates a need for a more global treatment approach to the shoulder girdle. The presence of tendinous changes in the subscapularis tendon may indicate that similar changes are also present in other tendons in the rotator cuff. Additional studies are therefore required to assess this question, as this was not investigated in the present thesis.

This thesis also provides evidence of a chronic inflammatory process relatively far away from the subacromial space. It is common practice to apply injections of non-steroidal anti-inflammatory drugs in the subacromial space to relieve pain in patients. The increased number of cytokines in

the subscapularis tendon and the joint capsule raises the question of whether or not the use of NSAID injections should also be tested intra-articularly. Moreover, the role of the increase in cytokine expression in the subscapularis tendon and the joint capsule has not been well investigated. Cytokine-specific blockers may be beneficial in the treatment of the syndrome. Further studies to investigate this issue are therefore necessary.

Taken as a whole

SAIS is a very common syndrome among the general population, especially in individuals after the sixth decade of their lives. Our understanding of the pathophysiology

of the syndrome is increasing with time, but there is still a long way to go. Further studies aiming to investigate the chronic degeneration of the soft tissue and the chronic inflammation around the subacromial space are required. It appears that there is a great deal to learn about the role of local cytokine expression, which may provide additional options in the treatment options for the syndrome. When it comes to the choice of surgical or non-surgical treatment, it appears that subacromial decompression is a well-established, effective alternative to physiotherapy for these patients. There is, however, no evidence that surgery will reduce the risk of OA and rotator cuff tears developing.

10 ACKNOWLEDGEMENTS

Erling Hallström, MD, PhD, my main supervisor, dear friend and colleague, for providing the opportunity to start this thesis. Thank you for the ideas and all the help setting up this thesis, continuing the follow-up of the patients and for support and help during the course of the project.

Lars Ejerhed, Associate Professor, MD, PhD, my co-supervisor, for contributing to significant parts of the thesis, for all your help, support and guidance.

Jüri Kartus, Professor, MD, PhD, my co-supervisor, tutor, dear colleague and friend, for the endless discussions and advice to make the accomplishment of this thesis possible. Thank you for your immense knowledge and answers to all possible queries 24/7 and for the time on Gran Canaria. I hope you will have the honour some day to beat me in a one-on-one basketball game!

Ninni Sernert, Professor, RPT, PhD, my co-supervisor, for all your precious help in important parts of this project, for organising the follow-ups of the patients and helping me accomplish this project. Thank you for all your assistance with administrative details and for the creative time in Barcelona. I owe you an ice-cream ball.

Leyla Roshani, BSc, PhD, for all your assistance collecting and processing the biopsy samples, all your help analysing the results and for the productive time we spent at the Karolinska Institutet in Stockholm.

Helena Brisby, Professor, Chairman of the Department of Orthopaedics, Institute of Clinical Sciences, Sahlgrenska Academy, Gothenburg University, for providing the opportunity to do this research.

Jón Karlsson, Professor, MD, PhD, thank you for being supportive in my work and sharing your exceptional knowledge of sports medicine and research.

Lars Rostgard-Christensen, MD, for your help with assessments of all the radiographs in the studies. You are an ultra-sound star beyond competition.

My friends and colleagues at the Orthopaedic Department at the NU Hospital Group, for all the enjoyable days we have at work and for your patience with my absence during my research project.

My research friends and colleagues, **Ioannis Karikis, Martina Åhlén, Mustafa Ibrahim Ahmad, Olle Månsson, Urban Hedlundh, Sven Stener** and all the others in the **Gran Canaria Research Group**, for inspiring discussions, productive days and training.

Arvin Yarollahi, MD, Head of the Department of Orthopaedics at the NU Hospital Group, for providing the opportunity to perform research alongside my clinical work.

Patrick Eriksson, MD, former Head of the Department of Orthopaedics at the NU Hospital Group, for my employment at the clinic as a resident and all these funny commuting days we had with interesting discussions.

Saga Johansson, administrator at the Department of Research and Development at the NU Hospital Group. For all your assistance with the administration and for arranging follow-up visits for study patients no matter where they might have relocated to and for all assistance during the follow-up of the patients.

Anna-Lena Wennerberg, administrative nurse at the Department of Orthopaedics at the NU Hospital Group, for all administrative help, making it possible to complete this thesis.

Cina Holmer and **Linda Johansson**, research administrators at the Sahlgrenska Academy, for all your assistance with the university administration.

Catarina Kartus, late artist and physiotherapist, for beautiful illustrations. You left us much too early.

Max Kartus, art director, for impeccable work on the illustrations and layout of this thesis.

Jeanette Kliger, language editor, for your help in editing the English language in the published work.

Jenny Sivertsson and **Josefin Ericson** for helping with the illustration of the follow-up procedure for Studies I & II.

To my parents, Ioannis and Victoria and my brother **Thanasis** for all their help and support all of these years. I am thankful that you have been around all this time and for your patience for my absence.

Special thanks also to all my close friends and close persons for their support. Thank you for your patience during these hard years. I hope to be a closer friend in the near future.

11 REFERENCES

1. Bot SD, van der Waal JM, Terwee CB, van der Windt DA, Schellevis FG, Bouter LM, et al. Incidence and prevalence of complaints of the neck and upper extremity in general practice. *Annals of the rheumatic diseases*. 2005;64(1):118-23.
2. Linsell L, Dawson J, Zondervan K, Rose P, Randall T, Fitzpatrick R, et al. Prevalence and incidence of adults consulting for shoulder conditions in UK primary care; patterns of diagnosis and referral. *Rheumatology (Oxford, England)*. 2006;45(2):215-21.
3. Iannotti JP, Gabriel JP, Schneck SL, Evans BG, Misra S. The normal glenohumeral relationships. An anatomical study of one hundred and forty shoulders. *The Journal of bone and joint surgery American volume*. 1992;74(4):491-500.
4. Allman jr fl. Fractures and ligamentous injuries of the clavicle and its articulation. *JBJS*. 1967;49(4):774-84.
5. Ellenbecker TS. *Clinical examination of the shoulder*: Saunders; 2004.
6. Gartner LP, Hiatt JL. *Color atlas and text of histology*: Lippincott Williams & Wilkins; 2012.
7. Jenkins DB. *Hollinshead's Functional Anatomy of the Limbs and Back-E-Book*: Elsevier Health Sciences; 2008.
8. Moore KL, Agur AM, Dalley AF. *Essential clinical anatomy*: Lippincott Williams & Wilkins Philadelphia; 2002.
9. Ralphs J, Benjamin M. The joint capsule: structure, composition, ageing and disease. *Journal of anatomy*. 1994;184(Pt 3):503.
10. Quillen DM, Wuchner M, Hatch RL. Acute shoulder injuries. *American family physician*. 2004;70(10):1947-54.
11. Farfaras S, Sernert N, Rostgard Christensen L, Hallstrom EK, Kartus JT. Subacromial Decompression Yields a Better Clinical Outcome Than Therapy Alone: A Prospective Randomized Study of Patients With a Minimum 10-Year Follow-up. *The American journal of sports medicine*. 2018;46(6):1397-407.
12. Kartus J, Kartus C, Rostgard-Christensen L, Sernert N, Read J, Perko M. Long-term clinical and ultrasound evaluation after arthroscopic acromioplasty in patients with partial rotator cuff tears. *Arthroscopy : the journal of arthroscopic & related surgery*. 2006;22(1):44-9.
13. Longo UG, Franceschi F, Ruzzini L, Rabitti C, Morini S, Maffulli N, et al. Histopathology of the supraspinatus tendon in rotator cuff tears. *The American journal of sports medicine*. 2008;36(3):533-8.
14. Petersson CJ, Gentz CF. Ruptures of the supraspinatus tendon. The significance of distally pointing acromioclavicular osteophytes. *Clinical orthopaedics and related research*. 1983(174):143-8.
15. Neer CS, 2nd, Craig EV, Fukuda H. Cuff-tear arthropathy. *The Journal of bone and joint surgery American volume*. 1983;65(9):1232-44.
16. Gelber JD, Soloff L, Schickendantz MS. *The Thrower's Shoulder*. *The Journal of the American Academy of Orthopaedic Surgeons*. 2018;26(6):204-13.
17. Balke M, Liem D, Greshake O, Hoehner J, Bouillon B, Banerjee M. Differences in acromial morphology of shoulders in patients with degenerative and traumatic supraspinatus tendon tears. *Knee surgery, sports traumatology, arthroscopy*. 2016;24(7):2200-5.
18. Harryman DT, 2nd, Sidles JA, Clark JM, McQuade KJ, Gibb TD, Matsen FA, 3rd.

- Translation of the humeral head on the glenoid with passive glenohumeral motion. *The Journal of bone and joint surgery American volume*. 1990;72(9):1334-43.
19. Ogston JB, Ludewig PM. Differences in 3-dimensional shoulder kinematics between persons with multidirectional instability and asymptomatic controls. *The American journal of sports medicine*. 2007;35(8):1361-70.
 20. Bishop JL, Kline SK, Aalderink KJ, Zuel R, Bey MJ. Glenoid inclination: in vivo measures in rotator cuff tear patients and associations with superior glenohumeral joint translation. *Journal of shoulder and elbow surgery / American Shoulder and Elbow Surgeons*. 2009;18(2):231-6.
 21. Flieg NG, Gatti CJ, Doro LC, Langenderfer JE, Carpenter JE, Hughes RE. A stochastic analysis of glenoid inclination angle and superior migration of the humeral head. *Clinical biomechanics (Bristol, Avon)*. 2008;23(5):554-61.
 22. Badley EM, Tennant A. Changing profile of joint disorders with age: findings from a postal survey of the population of Calderdale, West Yorkshire, United Kingdom. *Annals of the rheumatic diseases*. 1992;51(3):366-71.
 23. Bjelle A. Epidemiology of shoulder problems. *Bailliere's clinical rheumatology*. 1989;3(3):437-51.
 24. Bjelle A, Hagberg M, Michaelson G. Occupational and individual factors in acute shoulder-neck disorders among industrial workers. *British journal of industrial medicine*. 1981;38(4):356-63.
 25. van der Windt DA, Koes BW, Boeke AJ, Deville W, De Jong BA, Bouter LM. Shoulder disorders in general practice: prognostic indicators of outcome. *The British journal of general practice*. 1996;46(410):519-23.
 26. Nygren A, Berglund A, von Koch M. Neck-and-shoulder pain, an increasing problem. Strategies for using insurance material to follow trends. *Scandinavian journal of rehabilitation medicine Supplement*. 1995;32:107-12.
 27. Bergenudd H, Lindgärde F, Nilsson B, Petersson CJ. Shoulder pain in middle age. A study of prevalence and relation to occupational work load and psychosocial factors. *Clinical orthopaedics and related research*. 1988(231):234.
 28. Bodin J, Ha C, Petit Le Manac'h A, Serazin C, Descatha A, Leclerc A, et al. Risk factors for incidence of rotator cuff syndrome in a large working population. *Scandinavian journal of work, environment & health*. 2012;38(5):436-46.
 29. Herberts P, Kadefors R. A study of painful shoulder in welders. *Acta orthopaedica Scandinavica*. 1976;47(4):381-7.
 30. Herberts P, Kadefors R, Andersson G, Petersén I. Shoulder pain in industry: an epidemiological study on welders. *Acta orthopaedica*. 1981;52(3):299-306.
 31. Lin DJ, Wong TT, Kazam JK. Shoulder Injuries in the Overhead-Throwing Athlete: Epidemiology, Mechanisms of Injury, and Imaging Findings. *Radiology*. 2018;286(2):370-87.
 32. Frost P, Andersen JH. Shoulder impingement syndrome in relation to shoulder intensive work. *Occupational and Environmental Medicine*. 1999;56(7):494-8.
 33. Armstrong JR. Excision of the acromion in treatment of the supraspinatus syndrome; report of 95 excisions. *The Journal of bone and joint surgery British volume*. 1949;31b(3):436-42.
 34. Codman EA, Akerson IB. The pathology associated with rupture of the supraspinatus tendon. *Annals of surgery*. 1931;93(1):348-59.
 35. Neer CS, 2nd. Anterior acromioplasty for the chronic impingement syndrome in the shoulder: a preliminary report. *The Journal of bone and joint surgery American volume*. 1972;54(1):41-50.
 36. Neer CS, 2nd. Impingement lesions. *Clinical orthopaedics and related research*. 1983(173):70-7.
 37. Neer CS, 2nd, Marberry TA. On the disadvantages of radical acromionectomy. *The Journal of bone and joint surgery American volume*. 1981;63(3):416-9.
 38. Codman E. *The Shoulder: Rupture of the supraspinatus tendon and other lesions in or about the subacromial bursa*. 1934. G Miller & Co Medical Publishers, Brooklyn, New York Google Scholar.

39. Meyer A. The minuter anatomy of attrition lesions. *Journal of bone and joint surgery*. 1931;13(2):341-60.
40. Hawkins RJ, Kennedy JC. Impingement syndrome in athletes. *The American journal of sports medicine*. 1980;8(3):151-8.
41. Bigliani L. The morphology of acromion and its relationship to rotator cuff tears. *Orthop Trans*. 1988;12:674.
42. Gagey N, Ravaud E, Lassau J. Anatomy of the acromial arch: correlation of anatomy and magnetic resonance imaging. *Surgical and Radiologic Anatomy*. 1993;15(1):63-70.
43. Natsis K, Tsikaras P, Totlis T, Gigis I, Skandalakis P, Appell H, et al. Correlation between the four types of acromion and the existence of enthesophytes: a study on 423 dried scapulas and review of the literature. *Clinical Anatomy*. 2007;20(3):267-72.
44. Hamid N, Omid R, Yamaguchi K, Steger-May K, Stobbs G, Keener JD. Relationship of radiographic acromial characteristics and rotator cuff disease: a prospective investigation of clinical, radiographic, and sonographic findings. *Journal of shoulder and elbow surgery / American Shoulder and Elbow Surgeons*. 2012;21(10):1289-98.
45. Hirano M, Ide J, Takagi K. Acromial shapes and extension of rotator cuff tears: magnetic resonance imaging evaluation. *Journal of shoulder and elbow surgery / American Shoulder and Elbow Surgeons*. 2002;11(6):576-8.
46. Morrison D. The clinical significance of variations in acromial morphology. *Orthop Trans*. 1987;11:234.
47. Nicholson GP, Goodman DA, Flatow EL, Bigliani LU. The acromion: morphologic condition and age-related changes. A study of 420 scapulas. *Journal of shoulder and elbow surgery / American Shoulder and Elbow Surgeons*. 1996;5(1):1-11.
48. Zuckerman JD, Kummer FJ, Cuomo F, Simon J, Rosenblum S, Katz N. The influence of coracoacromial arch anatomy on rotator cuff tears. *Journal of shoulder and elbow surgery / American Shoulder and Elbow Surgeons*. 1992;1(1):4-14.
49. Roidis NT, Motamed S, Vaishnav S, Ebrahimzadeh E, Karachalios TS, Itamura JM. The influence of the acromioclavicular joint degeneration on supraspinatus outlet impingement and the acromion shape. *Journal of orthopaedic surgery (Hong Kong)*. 2009;17(3):331-4.
50. Gerber C, Terrier F, Ganz R. The role of the coracoid process in the chronic impingement syndrome. *The Journal of bone and joint surgery British volume*. 1985;67(5):703-8.
51. Nasca RJ, Salter EG, Weil CE. Current concepts review. Subacromial impingement syndrome (79-A: 1854-1868, Dec. 1997). *The Journal of bone and joint surgery American volume*. 1998;80(12):1852-3.
52. Factor D, Dale B. Current concepts of rotator cuff tendinopathy. *International journal of sports physical therapy*. 2014;9(2):274-88.
53. Hashimoto T, Nobuhara K, Hamada T. Pathologic evidence of degeneration as a primary cause of rotator cuff tear. *Clinical orthopaedics and related research*. 2003(415):111-20.
54. McFarland EG, Maffulli N, Del Buono A, Murrell GA, Garzon-Muvdi J, Petersen SA. Impingement is not impingement: the case for calling it "Rotator Cuff Disease". *Muscles, ligaments and tendons journal*. 2013;3(3):196-200.
55. Takase K, Yamamoto K. Histological and ultrastructural changes in the undersurface of the acromion with subacromial impingement. *Acta orthopaedica*. 2005;76(3):386-91.
56. Tuoheti Y, Itoi E, Pradhan RL, Wakabayashi I, Takahashi S, Minagawa H, et al. Apoptosis in the supraspinatus tendon with stage II subacromial impingement. *Journal of shoulder and elbow surgery / American Shoulder and Elbow Surgeons*. 2005;14(5):535-41.
57. Rahme H, Nordgren H, Hamberg H, Westerberg CE. The subacromial bursa and the impingement syndrome. A clinical and histological study of 30 cases. *Acta orthopaedica Scandinavica*. 1993;64(4):485-8.
58. Rahme H, Solem-Bertoft E, Westerberg CE, Lundberg E, Sorensen S, Hilding S. The subacromial impingement syndrome. A study of results of treatment with special emphasis on

- predictive factors and pain-generating mechanisms. *Scandinavian journal of rehabilitation medicine*. 1998;30(4):253-62.
59. Movin T, Gad A, Reinholt FP, Rolf C. Tendon pathology in long-standing achillogdynia. Biopsy findings in 40 patients. *Acta orthopaedica Scandinavica*. 1997;68(2):170-5.
 60. Svensson M, Kartus J, Christensen LR, Movin T, Papadogiannakis N, Karlsson J. A long-term serial histological evaluation of the patellar tendon in humans after harvesting its central third. *Knee surgery, sports traumatology, arthroscopy*. 2005;13(5):398-404.
 61. Svensson M, Movin T, Rostgard-Christensen L, Blomen E, Hultenby K, Kartus J. Ultrastructural collagen fibril alterations in the patellar tendon 6 years after harvesting its central third. *The American journal of sports medicine*. 2007;35(2):301-6.
 62. Castagna A, Cesari E, Gigante A, Conti M, Garofalo R. Metalloproteinases and their inhibitors are altered in both torn and intact rotator cuff tendons. *Musculoskeletal surgery*. 2013;97 Suppl 1:39-47.
 63. Garofalo R, Cesari E, Vinci E, Castagna A. Role of metalloproteinases in rotator cuff tear. *Sports medicine and arthroscopy review*. 2011;19(3):207-12.
 64. Goutallier D, Postel JM, Van Driessche S, Voisin MC. [Histological lesions of supraspinatus tendons in full thickness tears of the rotator cuff]. *Revue de chirurgie orthopedique et reparatrice de l'appareil moteur*. 2005;91(2):109-13.
 65. Blevins FT. Rotator cuff pathology in athletes. *Sports medicine (Auckland, NZ)*. 1997;24(3):205-20.
 66. Hallstrom E, Karrholm J. Shoulder rhythm in patients with impingement and in controls: dynamic RSA during active and passive abduction. *Acta orthopaedica*. 2009;80(4):456-64.
 67. Nirschl RP. Rotator cuff tendinitis: basic concepts of pathoetiology. *Instructional course lectures*. 1989;38:439-45.
 68. Hallstrom E, Karrholm J. Shoulder kinematics in 25 patients with impingement and 12 controls. *Clinical orthopaedics and related research*. 2006;448:22-7.
 69. Hallstrom E, Karrholm J. Kinematic evaluation of the Hawkins and Neer sign. *Journal of shoulder and elbow surgery / American Shoulder and Elbow Surgeons*. 2008;17(1 Suppl):40S-7S.
 70. Moseley HF, Goldie I. The arterial pattern of the rotator cuff of the shoulder. *The Journal of bone and joint surgery British volume*. 1963;45(4):780-9.
 71. Rothman RH, Parke WW. The vascular anatomy of the rotator cuff. *Clinical orthopaedics and related research*. 1965;41:176-86.
 72. Penny JN, Welsh RP. Shoulder impingement syndromes in athletes and their surgical management. *The American journal of sports medicine*. 1981;9(1):11-5.
 73. Poppen NK, Walker PS. Normal and abnormal motion of the shoulder. *The Journal of bone and joint surgery American volume*. 1976;58(2):195-201.
 74. Post M, Jablon M. Constrained total shoulder arthroplasty. Long-term follow-up observations. *Clinical orthopaedics and related research*. 1983(173):109-16.
 75. Post M, Silver R, Singh M. Rotator cuff tear. Diagnosis and treatment. *Clinical orthopaedics and related research*. 1983(173):78-91.
 76. Rathbun JB, Macnab I. The microvascular pattern of the rotator cuff. *The Journal of bone and joint surgery British volume*. 1970;52(3):540-53.
 77. Jarvholm U, Palmerud G, Herberts P, Hogfors C, Kadefors R. Intramuscular pressure and electromyography in the supraspinatus muscle at shoulder abduction. *Clinical orthopaedics and related research*. 1989(245):102-9.
 78. Jarvholm U, Palmerud G, Karlsson D, Herberts P, Kadefors R. Intramuscular pressure and electromyography in four shoulder muscles. *Journal of orthopaedic research*. 1991;9(4):609-19.
 79. Blaine TA, Cote MA, Proto A, Mulcahey M, Lee FY, Bigliani LU. Interleukin-1beta stimulates stromal-derived factor-1alpha expression in human subacromial bursa. *Journal of orthopaedic research*. 2011;29(11):1695-9.
 80. Blaine TA, Kim YS, Voloshin I, Chen D, Murakami K, Chang SS, et al. The molecular

pathophysiology of subacromial bursitis in rotator cuff disease. *Journal of shoulder and elbow surgery / American Shoulder and Elbow Surgeons*. 2005;14(1 Suppl S):84s-9s.

81. Sakai H, Fujita K, Sakai Y, Mizuno K. Immunolocalization of cytokines and growth factors in subacromial bursa of rotator cuff tear patients. *The Kobe journal of medical sciences*. 2001;47(1):25-34.
82. Voloshin I, Gelinas J, Maloney MD, O'Keefe RJ, Bigliani LU, Blaine TA. Proinflammatory cytokines and metalloproteases are expressed in the subacromial bursa in patients with rotator cuff disease. *Arthroscopy: The Journal of Arthroscopic & Related Surgery*. 2005;21(9):1076. e1- e9.
83. Zhang J-M, An J. Cytokines, inflammation and pain. *International anesthesiology clinics*. 2007;45(2):27.
84. Miranda I, Sanchez-Alepuz E, Lucas FJ, Carratala V, Gonzalez-Jofre CA. Use of platelet-rich plasma in the treatment of rotator cuff pathology. What has been scientifically proven? *Revista espanola de cirugía ortopedica y traumatología*. 2017;61(4):249-58.
85. Cole B, Lam P, Hackett L, Murrell GAC. Ultrasound-guided injections for supraspinatus tendinopathy: corticosteroid versus glucose prolotherapy - a randomized controlled clinical trial. *Shoulder & elbow*. 2018;10(3):170-8.
86. Lin KM, Wang D, Dines JS. Injection Therapies for Rotator Cuff Disease. *The Orthopedic clinics of North America*. 2018;49(2):231-9.
87. Holmgren T, Hallgren HB, Oberg B, Adolfsson L, Johansson K. Republished research: Effect of specific exercise strategy on need for surgery in patients with subacromial impingement syndrome: randomised controlled study. *British journal of sports medicine*. 2013;47(14):908.
88. Jonsson P, Wahlstrom P, Ohberg L, Alfredson H. Eccentric training in chronic painful impingement syndrome of the shoulder: results of a pilot study. *Knee surgery, sports traumatology, arthroscopy*. 2006;14(1):76-81.
89. Kim SH, Park DJ. Effects of diagonal shoulder training in a closed kinematic chain for secondary impingement syndrome: a case study. *Journal of physical therapy science*. 2015;27(6):2019-20.
90. Bernhardsson S, Klintberg IH, Wendt GK. Evaluation of an exercise concept focusing on eccentric strength training of the rotator cuff for patients with subacromial impingement syndrome. *Clinical rehabilitation*. 2011;25(1):69-78.
91. Böhmer AS. Trening ved kroniske degenerative skulderlidelser. *Fysioterapeuten*. 1984;51:192-7.
92. Michener LA, Walsworth MK, Burnet EN. Effectiveness of rehabilitation for patients with subacromial impingement syndrome: a systematic review. *Journal of hand therapy*. 2004;17(2):152-64.
93. Moezy A, Sepehrfar S, Soleymani Dodaran M. The effects of scapular stabilization based exercise therapy on pain, posture, flexibility and shoulder mobility in patients with shoulder impingement syndrome: a controlled randomized clinical trial. *Medical journal of the Islamic Republic of Iran*. 2014;28:87.
94. Böhmer AS, Staff PH, Brox JI. Supervised exercises in relation to rotator cuff disease (impingement syndrome stages II and III): a treatment regimen and its rationale. *Physiotherapy Theory and Practice*. 1998;14(2):93-105.
95. Neer CS, 2nd. Anterior acromioplasty for the chronic impingement syndrome in the shoulder. 1972. *The Journal of bone and joint surgery American volume*. 2005;87(6):1399.
96. Rockwood CA, Lyons FR. Shoulder impingement syndrome: diagnosis, radiographic evaluation, and treatment with a modified Neer acromioplasty. *The Journal of bone and joint surgery American volume*. 1993;75(3):409-24.
97. Mc LH, Asherman EG. Lesions of the musculotendinous cuff of the shoulder. IV. Some observations based upon the results of surgical repair. *The Journal of bone and joint surgery American volume*. 1951;33 a(1):76-86.
98. Burns TP, Turba JE. Arthroscopic treatment of shoulder impingement in athletes. *The American journal of sports medicine*. 1992;20(1):13-6.

99. Haëri GB, Wiley AM. Shoulder impingement syndrome. Results of operative release. *Clinical orthopaedics and related research*. 1982;168):128-22.
100. Burns WC, 2nd, Whipple TL. Anatomic relationships in the shoulder impingement syndrome. *Clinical orthopaedics and related research*. 1993;294):96-102.
101. Soslowsky LJ, An CH, Johnston SP, Carpenter JE. Geometric and mechanical properties of the coracoacromial ligament and their relationship to rotator cuff disease. *Clinical orthopaedics and related research*. 1994;304):10-7.
102. Sarkar K, Taine W, Uthoff HK. The ultrastructure of the coracoacromial ligament in patients with chronic impingement syndrome. *Clinical orthopaedics and related research*. 1990;254):49-54.
103. Uthoff HK, Hammond DI, Sarkar K, Hooper GJ, Papoff WJ. The role of the coracoacromial ligament in the impingement syndrome. A clinical, radiological and histological study. *International orthopaedics*. 1988;12(2):97-104.
104. Kessel L, Watson M. The painful arc syndrome. Clinical classification as a guide to management. *The Journal of bone and joint surgery British volume*. 1977;59(2):166-72.
105. Petersson CJ. Degeneration of the acromioclavicular joint. A morphological study. *Acta orthopaedica Scandinavica*. 1983;54(3):434-8.
106. Watson M. The refractory painful arc syndrome. *The Journal of bone and joint surgery British volume*. 1978;60-b(4):544-6.
107. Bigliani LU, Levine WN. Subacromial impingement syndrome. *The Journal of bone and joint surgery American volume*. 1997;79(12):1854-68.
108. Ellman H. Arthroscopic subacromial decompression: analysis of one- to three-year results. *Arthroscopy : the journal of arthroscopic & related surgery*. 1987;3(3):173-81.
109. Thorpe A, Hurworth M, O'Sullivan P, Mitchell T, Smith A. Rising trends in surgery for rotator cuff disease in Western Australia. *ANZ journal of surgery*. 2016;86(10):801-4.
110. Yu E, Cil A, Harmsen WS, Schleck C, Sperling JW, Cofield RH. Arthroscopy and the dramatic increase in frequency of anterior acromioplasty from 1980 to 2005: an epidemiologic study. *Arthroscopy : the journal of arthroscopic & related surgery*. 2010;26(9 Suppl):S142-7.
111. Klintberg IH, Svantesson U, Karlsson J. Long-term patient satisfaction and functional outcome 8-11 years after subacromial decompression. *Knee surgery, sports traumatology, arthroscopy*. 2010;18(3):394-403.
112. Lunsjo K, Bengtsson M, Nordqvist A, Abu-Zidan FM. Patients with shoulder impingement remain satisfied 6 years after arthroscopic subacromial decompression: a prospective study of 46 patients. *Acta orthopaedica*. 2011;82(6):711-3.
113. Brox JI, Gjengedal E, Uppheim G, Bohmer AS, Brevik JI, Ljunggren AE, et al. Arthroscopic surgery versus supervised exercises in patients with rotator cuff disease (stage II impingement syndrome): a prospective, randomized, controlled study in 125 patients with a 2 1/2-year follow-up. *Journal of shoulder and elbow surgery / American Shoulder and Elbow Surgeons*. 1999;8(2):102-11.
114. Dorrestijn O, Stevens M, Winters JC, van der Meer K, Diercks RL. Conservative or surgical treatment for subacromial impingement syndrome? A systematic review. *Journal of shoulder and elbow surgery / American Shoulder and Elbow Surgeons*. 2009;18(4):652-60.
115. Gebremariam L, Hay EM, Koes BW, Huisstede BM. Effectiveness of surgical and postsurgical interventions for the subacromial impingement syndrome: a systematic review. *Arch Phys Med Rehabil*. 2011;92(11):1900-13.
116. Haahr JP, Ostergaard S, Dalsgaard J, Norup K, Frost P, Lausen S, et al. Exercises versus arthroscopic decompression in patients with subacromial impingement: a randomised, controlled study in 90 cases with a one year follow up. *Annals of the rheumatic diseases*. 2005;64(5):760-4.
117. Farfaras S, Sernert N, Hallstrom E, Kartus J. Comparison of open acromioplasty, arthroscopic acromioplasty and physiotherapy in patients with subacromial impingement syndrome: a prospective randomised study. *Knee*

- surgery, sports traumatology, arthroscopy. 2016;24(7):2181-91.
118. Ketola S, Lehtinen J, Arnala I, Nissinen M, Westenius H, Sintonen H, et al. Does arthroscopic acromioplasty provide any additional value in the treatment of shoulder impingement syndrome?: a two-year randomised controlled trial. *The Journal of bone and joint surgery British volume*. 2009;91(10):1326-34.
 119. Ketola S, Lehtinen J, Rousi T, Nissinen M, Huhtala H, Kontinen YT, et al. No evidence of long-term benefits of arthroscopic acromioplasty in the treatment of shoulder impingement syndrome: Five-year results of a randomised controlled trial. *Bone & joint research*. 2013;2(7):132-9.
 120. Biberthaler P, Beirer M, Kirchoff S, Braunstein V, Wiedemann E, Kirchoff C. Significant benefit for older patients after arthroscopic subacromial decompression: a long-term follow-up study. *International orthopaedics*. 2013;37(3):457-62.
 121. Kuhn JE. Exercise in the treatment of rotator cuff impingement: a systematic review and a synthesized evidence-based rehabilitation protocol. *Journal of shoulder and elbow surgery / American Shoulder and Elbow Surgeons*. 2009;18(1):138-60.
 122. Davis AD, Kakar S, Moros C, Kaye EK, Schepsis AA, Voloshin I. Arthroscopic versus open acromioplasty: a meta-analysis. *The American journal of sports medicine*. 2010;38(3):613-8.
 123. Husby T, Haugstvedt JR, Brandt M, Holm I, Steen H. Open versus arthroscopic subacromial decompression: a prospective, randomized study of 34 patients followed for 8 years. *Acta orthopaedica Scandinavica*. 2003;74(4):408-14.
 124. Faber E, Kuiper JI, Burdorf A, Miedema HS, Verhaar JA. Treatment of impingement syndrome: a systematic review of the effects on functional limitations and return to work. *J Occup Rehabil*. 2006;16(1):7-25.
 125. Ketola S, Lehtinen J, Elo P, Kortelainen S, Huhtala H, Arnala I. No difference in long-term development of rotator cuff rupture and muscle volumes in impingement patients with or without decompression. *Acta orthopaedica*. 2016;87(4):351-5.
 126. Alqunae M, Galvin R, Fahey T. Diagnostic accuracy of clinical tests for subacromial impingement syndrome: a systematic review and meta-analysis. *Archives of physical medicine and rehabilitation*. 2012;93(2):229-36.
 127. Michener LA, Walsworth MK, Doukas WC, Murphy KP. Reliability and diagnostic accuracy of 5 physical examination tests and combination of tests for subacromial impingement. *Archives of physical medicine and rehabilitation*. 2009;90(11):1898-903.
 128. Park HB, Yokota A, Gill HS, El Rassi G, McFarland EG. Diagnostic accuracy of clinical tests for the different degrees of subacromial impingement syndrome. *JBJS*. 2005;87(7):1446-55.
 129. Beaudreuil J, Nizard R, Thomas T, Peyre M, Liotard JP, Boileau P, et al. Contribution of clinical tests to the diagnosis of rotator cuff disease: a systematic literature review. *Joint Bone Spine*. 2009;76(1):15-9.
 130. Gajdosik RL, Bohannon RW. Clinical measurement of range of motion. Review of goniometry emphasizing reliability and validity. *Physical therapy*. 1987;67(12):1867-72.
 131. Constant CR, Gerber C, Emery RJ, Sojbjerg JO, Gohlke F, Boileau P. A review of the Constant score: modifications and guidelines for its use. *Journal of shoulder and elbow surgery / American Shoulder and Elbow Surgeons*. 2008;17(2):355-61.
 132. Constant CR, Murley AH. A clinical method of functional assessment of the shoulder. *Clinical orthopaedics and related research*. 1987(214):160-4.
 133. Sullivan M, Karlsson J. The Swedish SF-36 Health Survey III. Evaluation of criterion-based validity: results from normative population. *J Clin Epidemiol*. 1998;51(11):1105-13.
 134. Ware Jr JE, Sherbourne CD. The MOS 36-item short-form health survey (SF-36): I. Conceptual framework and item selection. *Medical care*. 1992;473-83.
 135. Watson EM, Sonnabend DH. Outcome of rotator cuff repair. *Journal of shoulder and elbow surgery / American Shoulder and Elbow Surgeons*. 2002;11(3):201-11.

136. Rosenberg BN, Richmond JC, Levine WN. Long-term followup of Bankart reconstruction. Incidence of late degenerative glenohumeral arthrosis. *The American journal of sports medicine*. 1995;23(5):538-44.
137. Ahlen M, Liden M, Movin T, Papadogiannakis N, Rostgard-Christensen L, Kartus J. Histological Evaluation of Regenerated Semitendinosus Tendon a Minimum of 6 Years After Harvest for Anterior Cruciate Ligament Reconstruction. *Orthopaedic journal of sports medicine*. 2014;2(9):2325967114550274.
138. Meknas K, Johansen O, Steigen SE, Olsen R, Jorgensen L, Kartus J. Could tendinosis be involved in osteoarthritis? *Scandinavian journal of medicine & science in sports*. 2012;22(5):627-34.
139. Rolf C, Movin T. Etiology, histopathology, and outcome of surgery in achillobodynia. *Foot & ankle international*. 1997;18(9):565-9.
140. Hopkins SJ. The pathophysiological role of cytokines. *Legal medicine (Tokyo, Japan)*. 2003;5 Suppl 1:S45-57.
141. Bernard A, Boumsell L. The clusters of differentiation (CD) defined by the first international workshop on human leucocyte differentiation antigens. *Human immunology*. 1984;11(1):1-10.
142. Subcommittee I-WN. Nomenclature for clusters of differentiation (CD) of antigens defined on human leukocyte populations. *Bulletin of the World Health Organization*. 1984;62(5):809.
143. Kannus P. Structure of the tendon connective tissue. *Scandinavian journal of medicine & science in sports*. 2000;10(6):312-20.
144. Angst F, Schwyzer HK, Aeschlimann A, Simmen BR, Goldhahn J. Measures of adult shoulder function: Disabilities of the Arm, Shoulder, and Hand Questionnaire (DASH) and its short version (QuickDASH), Shoulder Pain and Disability Index (SPADI), American Shoulder and Elbow Surgeons (ASES) Society standardized shoulder assessment form, Constant (Murley) Score (CS), Simple Shoulder Test (SST), Oxford Shoulder Score (OSS), Shoulder Disability Questionnaire (SDQ), and Western Ontario Shoulder Instability Index (WOSI). *Arthritis Care Res (Hoboken)*. 2011;63 Suppl 11:S174-88.
145. Kirkley A, Griffin S, Dainty K. Scoring systems for the functional assessment of the shoulder. *Arthroscopy: the journal of arthroscopic & related surgery*. 2003;19(10):1109-20.
146. Dickens VA, Williams JL, Bhamra MS. Role of physiotherapy in the treatment of subacromial impingement syndrome: a prospective study. *Physiotherapy*. 2005;91(3):159-64.
147. Park SI, Choi YK, Lee JH, Kim YM. Effects of shoulder stabilization exercise on pain and functional recovery of shoulder impingement syndrome patients. *Journal of physical therapy science*. 2013;25(11):1359-62.
148. Bhattacharyya R, Edwards K, Wallace AW. Does arthroscopic sub-acromial decompression really work for sub-acromial impingement syndrome: a cohort study. *BMC musculoskeletal disorders*. 2014;15:324.
149. Yian EH, Ramappa AJ, Arneberg O, Gerber C. The constant score in normal shoulders. *Journal of Shoulder and Elbow Surgery*. 2005;14(2):128-33.
150. Ostor AJ, Richards CA, Prevost AT, Speed CA, Hazleman BL. Diagnosis and relation to general health of shoulder disorders presenting to primary care. *Rheumatology (Oxford, England)*. 2005;44(6):800-5.
151. Chipchase LS, O'Connor DA, Costi JJ, Krishnan J. Shoulder impingement syndrome: preoperative health status. *Journal of shoulder and elbow surgery / American Shoulder and Elbow Surgeons*. 2000;9(1):12-5.
152. Kerr R, Resnick D, Pineda C, Haghghi P. Osteoarthritis of the glenohumeral joint: a radiologic-pathologic study. *AJR American journal of roentgenology*. 1985;144(5):967-72.
153. Nakagawa Y, Hyakuna K, Otani S, Hashitani M, Nakamura T. Epidemiologic study of glenohumeral osteoarthritis with plain radiography. *Journal of shoulder and elbow surgery / American Shoulder and Elbow Surgeons*. 1999;8(6):580-4.
154. Scarlat M, Florescu A. [Shoulder function and scores in 180 asymptomatic individuals

- aged over 75 years]. *Revue de chirurgie orthopedique et reparatrice de l'appareil moteur*. 2005;91(6):502-7.
155. Pingel J, Fredberg U, Qvortrup K, Larsen JO, Schjerling P, Heinemeier K, et al. Local biochemical and morphological differences in human Achilles tendinopathy: a case control study. *BMC musculoskeletal disorders*. 2012;13(1):1.
 156. Liden M, Movin T, Ejerhed L, Papadogiannakis N, Blomen E, Hultenby K, et al. A histological and ultrastructural evaluation of the patellar tendon 10 years after reharvesting its central third. *The American journal of sports medicine*. 2008;36(4):781-8.
 157. Proctor CS, Jackson DW, Simon TM. Characterization of the repair tissue after removal of the central one-third of the patellar ligament. An experimental study in a goat model. *The Journal of bone and joint surgery American volume*. 1997;79(7):997-1006.
 158. Jozsa L, Balint BJ, Reffy A, Demel Z. Fine structural alterations of collagen fibers in degenerative tendinopathy. *Archives of orthopaedic and traumatic surgery*. 1984;103(1):47-51.
 159. Magnusson SP, Qvortrup K, Larsen JO, Rosager S, Hanson P, Aagaard P, et al. Collagen fibril size and crimp morphology in ruptured and intact Achilles tendons. *Matrix biology : journal of the International Society for Matrix Biology*. 2002;21(4):369-77.
 160. Longo UG, Franceschi F, Ruzzini L, Rabitti C, Morini S, Maffulli N, et al. Light microscopic histology of supraspinatus tendon ruptures. *Knee surgery, sports traumatology, arthroscopy*. 2007;15(11):1390-4.
 161. Pauly S, Stahnke K, Klatte-Schulz F, Wildemann B, Scheibel M, Greiner S. Do patient age and sex influence tendon cell biology and clinical/radiographic outcomes after rotator cuff repair? *The American journal of sports medicine*. 2015;43(3):549-56.
 162. Cho NS, Hwang JH, Lee YT, Chae SW. Tendinosis-like histologic and molecular changes of the Achilles tendon to repetitive stress: a pilot study in rats. *Clinical orthopaedics and related research*. 2011;469(11):3172-80.
 163. Millett PJ, Gobeze R, Boykin RE. Shoulder osteoarthritis: diagnosis and management. *American family physician*. 2008;78(5):605-11.
 164. Gyftopoulos S, Carpenter E, Kazam J, Babb J, Bencardino J. MR imaging of subscapularis tendon injury in the setting of anterior shoulder dislocation. *Skeletal radiology*. 2012;41(11):1445-52.
 165. Tillander B, Franzen L, Norlin R. Fibronectin, MMP-1 and histologic changes in rotator cuff disease. *Journal of orthopaedic research*. 2002;20(6):1358-64.
 166. Lundgreen K, Lian OB, Engebretsen L, Scott A. Tenocyte apoptosis in the torn rotator cuff: a primary or secondary pathological event? *British journal of sports medicine*. 2011;45(13):1035-9.
 167. Yuan J, Murrell GAC, Wei AQ, Wang MX. Apoptosis in rotator cuff tendonopathy. *Journal of orthopaedic research*. 2002;20(6):1372-9.
 168. Chillemi C, Petrozza V, Garro L, Sardella B, Diotallevi R, Ferrara A, et al. Rotator cuff re-tear or non-healing: histopathological aspects and predictive factors. *Knee surgery, sports traumatology, arthroscopy*. 2011;19(9):1588-96.
 169. Maffulli N, Del Buono A, Spiezia F, Longo UG, Denaro V. Light microscopic histology of quadriceps tendon ruptures. *International orthopaedics*. 2012;36(11):2367-71.
 170. Tallon C, Maffulli N, Ewen SW. Ruptured Achilles tendons are significantly more degenerated than tendinopathic tendons. *Medicine and science in sports and exercise*. 2001;33(12):1983-90.
 171. Kanbe K, Inoue K, Inoue Y, Chen Q. Inducement of mitogen-activated protein kinases in frozen shoulders. *Journal of orthopaedic science*. 2009;14(1):56-61.
 172. Nobuhara K, Sugiyama D, Ikeda H, Makiura M. Contracture of the shoulder. *Clinical orthopaedics and related research*. 1990(254):105-10.
 173. Gotoh M, Hamada K, Yamakawa H, Yanagisawa K, Nakamura M, Yamazaki H,

- et al. Interleukin-1-induced glenohumeral synovitis and shoulder pain in rotator cuff diseases. *Journal of orthopaedic research*. 2002;20(6):1365-71.
174. Tsuzaki M, Guyton G, Garrett W, Archambault JM, Herzog W, Almekinders L, et al. IL-1 beta induces COX2, MMP-1, -3 and -13, ADAMTS-4, IL-1 beta and IL-6 in human tendon cells. *Journal of orthopaedic research*. 2003;21(2):256-64.
175. Robinson WH, Landolfi MM, Parnes JR. Allele-specific expression of the mouse B-cell surface protein CD72 on T cells. *Immunogenetics*. 1997;45(3):195-200.
176. Ishida I, Kumanogoh A, Suzuki K, Akahani S, Noda K, Kikutani H. Involvement of CD100, a lymphocyte semaphorin, in the activation of the human immune system via CD72: implications for the regulation of immune and inflammatory responses. *International immunology*. 2003;15(8):1027-34.
177. Yamakado K. Histopathology of residual tendon in high-grade articular-sided partial-thickness rotator cuff tears (PASTA lesions). *Arthroscopy : the journal of arthroscopic & related surgery*. 2012;28(4):474-80.