

Influencing factors of orthodontic tooth movement and root resorption, and evaluation of its radiographic diagnostic means

Alexander Dudic

Department of Orthodontics
Institute of Odontology
Sahlgrenska Academy, University of Gothenburg



UNIVERSITY OF GOTHENBURG

Gothenburg 2018

Cover illustration: *'The fact'* by Alexander Dudic

Illustrating components of the studies: The amount of tooth movement measured on superimposed casts, the resorption lacunae on reconstructed micro-CT images, and the apical root resorption visualized on cone-beam CT images.

Influencing factors of orthodontic tooth movement and root resorption, and evaluation of its radiographic diagnostic means

© Alexander Dudic 2018

alexander.dudic@gmail.com

ISBN 978-91-7833-147-5 (PRINT)

ISBN 978-91-7833-148-2 (PDF)

Printed in Gothenburg, Sweden 2018

Printed by BrandFactory

To my family,
Odysia, Alexy and Ilias

CONTENT

CONTENT	1
ABSTRACT	3
SAMMANFATTNING PÅ SVENSKA	4
LIST OF PAPERS.....	7
ABBREVIATIONS.....	9
INTRODUCTION.....	11
Orthodontic tooth movement.....	11
Tissue reaction during orthodontic tooth movement.....	11
Phases of tooth movement.....	11
Molecular players involved in orthodontic tooth movement	12
Variability of tooth movement	13
Factors influencing tooth movement.....	14
Side effects of tooth movement.....	15
Root resorption	16
Incidence	16
The root resorption process	16
Factors influencing root resorption	17
Association between root resorption and tooth movement	18
Radiological methods to detect root resorption clinically	19
Periapical and panoramic radiography	19
Cone-beam computed tomography	19
Micro-computed tomography.....	20
AIM.....	23
PATIENTS AND METHODS.....	25
Patients.....	25
Patients near end of orthodontic treatment sample	25
The experimental patient group.....	25
Sample size estimation	25
Experimental design	27
Standardized experimental orthodontic tooth movement (paper I, II, IV, V) ...	27
Validation of panoramic radiograph – cone-beam CT (paper III)	27
Methods	28
Evaluation of the amount of tooth displacement (paper I, II, V)	28
Micro-CT image acquisition and reconstruction (paper IV, V)	29
Qualitative assessment of apical root resorption (paper IV)	30
Volume assessment of buccal cervical root resorption (paper V).....	31
Periapical radiograph acquisition and film evaluation (paper IV)	32
Panoramic radiograph acquisition and root resorption evaluation (paper III) ..	33
Cone-beam CT image acquisition and root resorption evaluation (paper III) ..	34

Statistical methods (paper I-IV).....	35
Comments	36
Comments on patient selection.....	36
Comments on experimental design.....	36
Comments on methods	36
RESULTS.....	39
Tooth displacement.....	39
Differences in the amount of tooth displacement (paper I).....	39
Factors influencing the amount of tooth movement (paper I).....	40
Root resorption.....	42
Validity of radiological methods of detecting root resorption.....	42
Variability in root resorption after experimental tooth movement (paper V) ...	44
Influencing factors on root resorption (paper V).....	45
DISCUSSION.....	47
Tooth displacement.....	47
Fast movers and slow movers.....	47
Age.....	48
Location	49
Obstacles.....	50
Other factors	50
Root resorption.....	52
Location	52
Obstacles.....	53
Amount of tooth movement.....	53
Other factors	54
Diagnostic means	54
Periapical and panoramic radiography	54
Cone-beam CT.....	55
CONCLUSION	59
FUTURE PERSPECTIVES	61
ACKNOWLEDGEMENT.....	63
REFERENCES	65
APPENDIX	83

ABSTRACT

Aims: To investigate whether patient- or tooth-related factors like jaw location or intra- and interarch obstacles influence the amount of orthodontic tooth movement and orthodontically induced root resorption, and to evaluate if the concept of slow and fast movers is valid in humans. Furthermore, to evaluate the validity of different radiographic methods for detecting root resorption.

Patients and methods: A standardized experimental split mouth model for orthodontic tooth movement was used in 30 subjects, 59 premolars were moved buccally during 8 weeks with the application of 1 N force and 58 contralateral premolars served as controls. The amount of tooth movement was evaluated with digitized superimposed plaster models. At the end of the experimental period the teeth were extracted, scanned in a micro-CT scanner, and a volumetric evaluation of resorption craters at the cervical part of the root was performed. The possible influencing factors studied were age, location (maxilla/mandible), and presence or absence of intra- or interarch obstacles. Standardized periapical radiographs, taken before and after the experiment, were evaluated for apical root resorption and compared with the micro-CT scanned images. In a different sample of 275 teeth in 22 patients near the end of an orthodontic treatment with fixed appliances, apical root resorption was evaluated in panoramic radiographs (OPT) and compared to the corresponding cone-beam CT images (CBCT).

Results: Younger subjects (< 16 years) showed greater amount of tooth displacement compared with older subjects (≥ 16 years): 2.68 mm vs. 1.84 mm ($P < 0.01$). When an intra- or interarch obstacle was present, the amount of tooth movement was significantly less (1.86 mm vs. 2.67 mm) ($P < 0.05$). Teeth moved to a greater amount in the maxilla compared to the mandible but the displacement varied substantially between individuals (0.6 - 5.8 mm) and was highly correlated within the same individual ($R = 0.88$, $P < 0.001$). Higher amount of cervical root resorption was detected in orthodontically moved teeth (0.00055 mm^3) compared to controls (0.00003 mm^3 ; $P < 0.001$). A moderate correlation was found between root resorption in the two experimental teeth within the same individual ($R = 0.42$, $P = 0.02$). Root resorption was greater in the mandible than the maxilla. The amount of root resorption was correlated with the amount of tooth movement ($R = 0.31$, $P = 0.01$). The comparison of the apical radiographs and the micro-CT scanner showed less accuracy in the conventional radiograph. Panoramic radiographs underestimated apical root resorption as compared to the more precise CBCT 3D images.

Conclusions: A wide range of tooth displacement revealed slow and fast movers. Intra- or interarch obstacles decreased the amount of tooth movement. Younger patients showed greater tooth movement velocity than older ones. Application of 1N over 8 weeks may provoke notable root resorption, which varied widely between and within subjects. A part of this variation was attributed to the location and the amount of tooth movement. Conventional radiologic methods underestimated root resorption. CBCT might be a useful complementary diagnostic method to conventional radiography that can be used in cases where diagnostic precision is needed.

SAMMANFATTNING PÅ SVENSKA

Vid tandregleringsbehandling ser man kliniskt att tänder flyttar sig lite fortare på vissa individer än på andra. Rotresorptioner, dvs att tandens rot bryts ner och kortas av, under en tandregleringsbehandling är en känd risk som hos de flesta patienterna inte har någon nämnvärd betydelse. Hos vissa individer kan dock rötterna bli väldigt korta under behandlingen.

Syftena med följande studier var att undersöka faktorer som skulle kunna påverka hastigheten på tandförflyttningen under en tandregleringsbehandling och om dessa faktorer även påverkar omfattningen av rotresorptioner. Det var också meningen att undersöka tillförlitligheten av olika röntgenmetoder vid bedömningen av rotresorptioner.

Två patientgrupper undersöktes i studierna. Den ena, experimentella, gruppen bestod av 30 patienter som senare skulle genomgå en tandregleringsbehandling, där tänder skulle extraheras som del i behandlingen. Femtionio premolarer (främre kindtand) flyttades på ett standardiserat sätt med hjälp av en tandställning i 8 veckor med en kraft på 1Newton. Motsvarande tand på andra sidan fungerade som kontrolltand. Tanderna extraherades efter tandförflyttningen. Tandförflyttningen bedömdes på scannade gipsmodeller från före och efter förflyttningen. Tanderna röntgades före och efter förflyttningen med konventionella apikalröntgenbilder och de extraherade tänderna undersöktes därefter med micro-CT röntgen som på ett exakt sätt kunde visa omfattningen av rotresorptionen. De faktorer som bedömdes i samband med tandförflyttningen var patientens ålder, kön, tandens position (över- eller underkäke) samt förekomst eller avsaknad av fysiska hinder för tandförflyttningen. Den andra patientgruppen bestod av 22 patienter som var i slutet av sin tandregleringsbehandling och där 275 tänder röntgenundersöktes med både panoramaröntgen och skiktröntgen (CBCT).

Resultaten visade att tandförflyttningen blev större på unga individer, på tänder där det inte fanns några fysiska hinder, i överkäken men att det var stora individuella variationer. Rotresorptioner i övre (cervikala) delen av tandroten var mer utbredda på de tänder som flyttades än på kontrolltänderna. Tanderna i underkäken uppvisade mer omfattande cervikala resorptioner och det fanns ett samband mellan omfattningen av tandförflyttning och graden av rotresorption. Det fanns också ett visst samband på graden av rotresorption på de tänder som flyttades inom samma individ. Jämförelsen mellan den exakta micro-CT undersökningen och konventionella röntgenbilder visade att apikala röntgenbilder hade sämre noggrannhet. Resultaten visade också att panoramaröntgen ger en underdiagnostik jämfört med den mer exakta CBCT metoden.

Konklusioner: En stor individuell variation på omfattningen av tandförflyttning bekräftar antagandet att tänder flyttar sig olika fort på olika individer. Fysiska hinder i den riktning tanden skall röra sig minskar omfattningen av tandförflyttning. Tänder rör sig i genomsnitt fortare på yngre individer. Krafter på 1N kan under 8 veckor orsaka tydliga rotesorptioner. Omfattningen av rotesorptioner underskattas på konventionella röntgenbilder samt CBCT ger en korrektare bild av rotesorptioner och kan i vissa fall vara ett värdefullt komplement.

LIST OF PAPERS

This thesis is based on the following studies, which are referenced in the text by their Roman numerals.

- I. **Dudic, A.**, Giannopoulou, C. & Kiliaridis, S. (2013) Factors related to the rate of orthodontically induced tooth movement. *Am J Orthod Dentofacial Orthop*, 143, 616-21.
- II. **Giannopoulou, C.**, Dudic, A., Pandis, N. & Kiliaridis, S. (2016) Slow and fast orthodontic tooth movement: An experimental study on humans. *Eur J Orthod*, 404-8.
- III. **Dudic, A.**, Giannopoulou, C., Leuzinger, M. & Kiliaridis, S. (2009) Detection of apical root resorption after orthodontic treatment by using panoramic radiography and cone-beam computed tomography of super-high resolution. *Am J Orthod Dentofacial Orthop*, 135, 434-7.
- IV. **Dudic, A.**, Giannopoulou, C., Martinez, M., Montet, X. & Kiliaridis, S. (2008) Diagnostic accuracy of digitized periapical radiographs validated against micro-computed tomography scanning in evaluating orthodontically induced apical root resorption. *Eur J Oral Sci*, 116, 467-72.
- V. **Dudic, A.**, Giannopoulou, C., Meda, P., Montet, X. & Kiliaridis, S. (2017) Orthodontically induced cervical root resorption in humans is associated with the amount of tooth movement. *Eur J Orthod*, 1-7.

ABBREVIATIONS

CBCT	Cone-beam computed tomography
CGRP	Calcitonin gene-related peptide
CLSM	Confocal laser scanning microscopy
CT	Computerized tomography
EARR	External apical root resorption
IL-1b	Interleukin-1beta
IL-1RA	Interleukin-1 receptor antagonist
IL-6	Interleukin-6
IL-10	Interleukin-10
IL-11	Interleukin-11
IL-12	Interleukin-12
Micro-CT	Micro-computed tomography
MMPs	Matrix metalloproteinases
OPG	Osteoprotegerin
OPT	Panoramic radiograph
PA	Periapical radiograph
PDL	Periodontal ligament
PGE2	Prostaglandin E2
PTH	Parathyroid hormone
RANK	Receptor activator of nuclear factor kappa-B
RANKL	Receptor activator of nuclear factor kappa-B ligand
SEM	Scanning electron microscopy
TNFa	Tumor necrosis factor alpha

INTRODUCTION

Orthodontic tooth movement

Orthodontic tooth movement (OTM) has been defined as “the result of a biologic response to interference in the physiologic equilibrium of the dentofacial complex by an externally applied force” (Proffit 2007). This change in equilibrium results in a remodeling process occurring in the gingiva, primarily, in the periodontal ligament and the adjacent alveolar bone.

Tissue reaction during orthodontic tooth movement

Mechanical forces are applied to achieve OTM, which initially causes fluid movement within the periodontal ligament (PDL). The distortion of the PDL components (cells, extracellular matrix, and nerve terminals) initiates the release of a multitude of molecules (neurotransmitters, cytokines, growth factors, and arachidonic acid metabolites), leading to alveolar bone remodeling (Krishnan and Davidovitch 2006).

Remodeling activities and ultimately tooth displacement are the consequence of an inflammatory process. Applying prolonged mechanical force induces a change in the connective dental tissues leading to adaptive proliferation and remodeling, mainly in the periodontal ligament and the alveolar bone, demonstrating the capacity of an external physical agent to engender changes at the cellular level (Wehrbein et al. 1994; Ashizawa and Sahara 1998; Verna et al. 1999).

Orthodontic tooth movement involves two interrelated processes: (1) deflection or bending of alveolar bone and (2) remodeling of periodontal tissues (Meikle 2006).

Phases of tooth movement

In 1962 Burstone suggested three phases of tooth movement: (1) an initial phase, (2) a lag phase and (3) a post lag phase.

The *initial phase* of tooth movement occurs immediately after force application and results in a rapid movement of the tooth inside its bony socket. It lasts one or two days (Burstone 1962) and during this time the periodontal ligament undergoes compression on one (compression area) and tension on the other side (tension area) (Reitan 1960). This initial phase is mainly exudative, and typically indicative of an acute inflammatory process.

Introduction

At this time recruitment of osteoblast and osteoclast progenitor cells begins as well as neurotransmitter synthesis and release.

During the subsequent *lag phase*, which lasts 20 to 30 days in humans, the tooth is no longer substantially displaced and the formation and removal of necrotic tissue takes place (Kashyap 2016). In this phase a chronic process replaces the previously acute inflammatory reaction. Various cells are involved, such as fibroblasts, endothelial cells, osteoblasts, and alveolar bone marrow cells. In the compression area the fibers of the periodontal ligament appear distorted and phagocytic cells are recruited to remove the necrotic tissue in the periodontium and the adjacent alveolar bone. In the tension areas a new bone matrix is produced by enlarged osteoblasts.

About 40 days after the initial force application the *post lag phase* begins. At this point the necrotic tissue has been removed and accelerated tooth movement is noticed. During this phase a number of signaling molecules are released (prostaglandins, growth factors, cytokines, extracellular matrix proteins, and neuropeptides). In an ongoing orthodontic treatment during this phase the activation of the orthodontic appliance would take place, which would superimpose an acute inflammation over the ongoing process (Asiry 2018).

It has been hypothesized that during the tooth displacement with physiological light forces, a continuous development and removal of necrotic tissue occurs (Melsen 1999).

Molecular players involved in orthodontic tooth movement

Many different cellular (cells, extracellular matrix, nerve terminals) and molecular components (neurotransmitters, cytokines, growth factors, etc.) are involved in the biological process of orthodontic tooth movement (Krishnan and Davidovitch 2006).

The application of external mechanical force initiates the release of neuropeptides (substance P, vasoactive intestinal polypeptide, calcitonin gene-related peptide CGRP) at nerve endings, which causes migration of blood leukocytes in areas of compression. These leukocytes release signaling proteins (cytokines, growth factors) that affect cells in the periodontium (Henneman et al. 2008).

Mechanical stress influences cells in the periodontium (osteoblasts, fibroblasts, endothelial and bone lining cells) to express cytokines, growth

factors, and cytokine receptors. For example, osteoblasts release IL-1b (autocrine effect, promote osteoclast activity), IL-6 (osteoclast recruitment and differentiation), TNFa (stimulates differentiation osteoclast precursors to osteoclasts), and IL-11 (enhances RANKL expression in osteoblasts). RANKL is a key molecule in osteoclast precursor differentiation (Kouskoura et al. 2017).

In areas of tension, the balance is tipped toward bone formation. PDL cells in these areas produce growth factors and cytokines (osteoprotegerin OPG) that induce apoptosis of osteoclast (Kobayashi et al. 2000). At the compression site fibroblasts produce matrix metalloproteinases (MMPs), responsible for collagen fiber degradation and elimination, permitting tooth movement (Lekic and McCulloch 1996; Cantarella et al. 2006).

Chemotactic cytokines play a key role in the inflammatory process and are important in the mechanically induced bone remodeling (Andrade et al. 2009; Taddei et al. 2012). In general, chemokines induce cellular differentiation and chemotaxis of leukocytes.

Prostaglandins and leukotrienes are arachidonic acid metabolites. Prostaglandin E2 is most widely researched with respect to tooth movement and is produced by PDL fibroblasts and osteoblasts (Kanzaki et al. 2002). PGE2 triggers RANKL expression in osteoblasts, which induces osteoclast activation. Leukotrienes act on the differentiation of osteoclasts through the presence of RANKL (Moura et al. 2014).

Not only the activation of osteoclasts but also their control by inhibitor molecules such as OPG, IL-1RA, IL-12, and IL-10 (inhibiting the RANK osteoclast signaling pathway) is necessary to prevent uncontrolled osteolysis during orthodontic tooth movement (Park-Min et al. 2009).

Variability of tooth movement

In experimental animal studies, differences in the amount of tooth movement have been shown when a standardized force was applied. Substantial variation exists when comparing beagle dogs. While large differences were found in the rate of tooth movement, left and right side tooth movement for a particular dog was highly correlated. It was found that the rate of tooth movement mainly depends on patient characteristics (Pilon et al. 1996). Based on these studies the concept of slow movers and fast movers was introduced. *So far this concept has not been observed in humans.*

Factors influencing tooth movement

The mechanism of orthodontic tooth movement is quite complex and can be affected by a variety of factors. It can be influenced by the character of the mechanical stimulus itself, the level of force applied, external (drugs, diet) and/or internal factors (hormones) acting on signaling pathways, the patient's biologic profile, and local factors like tooth location and interferences (Zainal Ariffin et al. 2011).

Since it has been thought that the level of force might influence the amount of tooth movement, the concept of 'an optimal orthodontic force' was investigated (Ren et al. 2003). It was demonstrated that a wide range of force may be applied to induce tooth movement. After surpassing an initial threshold, the rate of tooth movement increases until a plateau is reached. At that point, further increase of force level does not result in an increase in the rate of tooth movement. A wide range of forces may be identified, all of which lead to a maximum rate of tooth movement. Furthermore, it was observed that maximum rates of tooth movement in humans and dogs are very similar (Ren et al. 2004). Additionally, the dose-response relationship has been studied, with evidence to indicate only in the very low force range was there a positive dose-response relationship (Van Leeuwen et al. 2010). The effect of the force level on the periodontal ligament has been studied. It was found that after 24 hours the remodeling process starts and soon after hyalinization was found. Hyalinization limits tooth movement, and there was no relationship with the force level in beagle dogs (Von Böhl et al. 2004).

The choice of force regime (constant versus intermittent) influenced the amount of tooth movement. A greater amount of tooth movement occurred with constant force, and it was concluded that increased tooth movement was achieved with continuous force compared to interrupted force (Owman-Moll 1995, Weiland 2003). Force regime had a greater influence on the rate of orthodontic tooth movement than the force magnitude (Van Leeuwen et al. 1999).

An increasing number of pharmacological agents have been explored aiming either to accelerate or to inhibit tooth movement during or after orthodontic treatment (Bartzela et al. 2009). In 1982 Yamasaki and coworkers found local administration of prostaglandins E1 or E2 accelerated experimental tooth movement in monkeys (*Macaca fuscata*) (Yamasaki et al. 1982). The major limitation of PGE2 is its short half-life and the potential adverse effect of root resorption. Bisphosphonates inhibit bone resorption and are successfully used for the treatment of osteoporosis. They inhibit the up-regulation of key

components crucial for tooth movement (Krishnan and Davidovitch, 2006). Hormones such as parathyroid hormone PTH enhance both osteoblast and osteoclast activity. They seem to facilitate bone remodeling/turnover and therefore have an accelerating effect on tooth movement (Li et al. 2013). Other means of promoting an inflammatory reaction to accelerate tooth movement with a short-term effect are local surgical interventions like corticotomies (Alfawal et al. 2016).

Clinically, differences in tooth movement within the same patient can be observed. Especially during space closure after previous tooth extraction, differences between or within jaws are noticeable. Therefore, other factors than a patient's biological profile or drugs must influence the amount of tooth movement locally. A histomorphometric analysis on dogs revealed differences in the maxillary and mandibular bone response to orthodontic force, resulting in significant differences in the amount of OTM (Deguchi et al. 2008). Animal studies on rats showed age-related changes in the periodontal ligament during OTM (Ren et al. 2008). Other authors showed that an age-dependent decrease in alveolar bone turnover activity affected the amount of tooth movement (Misawa-Kageyama et al. 2007). *Despite this, there is a lack of robust experimental studies on humans exploring how location (maxilla/mandible) or patient age may influence the degree of OTM.*

Interarch obstacles as occlusal interference with opposing teeth in or out of freeway space may influence, in certain cases, tooth movement depending on the time that the teeth are in contact. Other interferences, such as neighboring touching teeth, seem to influence the amount of tooth movement. These intra-arch obstacles have a kind of billiard effect, where force is transferred to neighboring teeth that must move first. *However, no study has yet investigated the role of such interferences on the rate of tooth displacement.*

Side effects of tooth movement

Orthodontic treatment, like any other treatment, may be associated with unfavorable side effects. Adverse effects arising from orthodontic tooth movement with fixed appliances may include pain, gingivitis, decalcifications, pulpal changes, mucosa lesions, and root resorption (Talic 2011).

Root resorption

External apical root resorption EARR is a common adverse effect of orthodontic treatment.

Incidence

In the literature the incidence of EARR varies between 22 to 100 %, a variation explained by the use of very different techniques for identifying root resorption. In a review article, Killiany found 30 % of treated patients experienced apical resorption of > 3 mm on at least one tooth, while only 5% of the patients had at least one tooth with more than 5 mm of apical root resorption (Killiany 1999). Histologic studies reported a high incidence of resorption, while clinical studies generally showed a varied incidence. The teeth most prone to root resorption after orthodontic treatment are the maxillary incisors, followed by maxillary molars, and canines. Also, the most affected teeth in the lower arch are the incisors. In general, the clinical impact of root resorption resulting from orthodontic treatment for most patients is minor and does not affect the functional capacity or the longevity of the involved teeth in long-term, even in cases with severe root resorption (Remington et al. 1989; Levander and Malmgren 2000; Jönsson et al. 2007). Nevertheless, a limited number of patients are severely affected by the adverse effect of orthodontic treatment (Mirabella and Artun 1995; Baumrind et al. 1996).

The root resorption process

As a consequence of the application of orthodontic force the periodontal ligament undergoes injury and necrosis on the pressure side. During the elimination process of the hyalinized tissue small areas of root resorption are found in histological studies on the compression side. The cells responsible for root resorption, the odontoclasts, have similar characteristics to the osteoclasts (Ten Cate 1989; Bosshardt 2005).

The hyalinized zone is characterized by three stages: (1) degeneration (2) elimination and (3) re-establishment. In studies on humans and animals periodontal hyalinization always precedes root resorption (Von Böhl et al. 2004). The application of a long-lasting orthodontic force results in necrosis of the compressed PDL, leading macrophages and leukocytes (diapedesis) to migrate out of capillaries, which includes osteoclast progenitors that rapidly form multinucleated cells capable of dissolving mineralized tissue. During the process of root resorption, the protective layer of the cementoblasts undergoes apoptosis. As a consequence, odontoclasts are able to dissolve

cementum and dentine. Once the protective layer of cementoids is removed, odontoclasts attack the raw cemental surface (Brudvik and Rygh 1993; Feller et al. 2016).

When the force level drops below a certain value, the active resorption process stops and cementoid fills the resorbed lacunae (Schwartz 1932). The process of repair is the migration of cementoblasts over the resorbed surface, which occurs 35 - 70 days after force application (Lindskog et al. 1987; Sismanidou et al. 1996; Owman-Moll and Kurol 1998). Therefore repair, including smoothing and remodeling of the cemental surface, is achieved after termination of active orthodontic treatment (Copeland and Green 1986).

Factors influencing root resorption

Root resorption occurring in conjunction with conventional orthodontic treatment is described as an idiopathic and multifactorial problem, associated with both patient characteristics and treatment factors (Brezniak and Wasserstein 1993). Scandinavian researchers studied the influence of asthma and allergies as patient-related factors on root resorption (Owman-Moll and Kurol 2000). Furthermore, hormonal imbalances such as hypothyroidism (Poumpros et al. 1994) as well as alcohol or drug consumption (Liu et al. 2004; Villa et al. 2005) were found to influence root resorption. Along with genetic components like familial associations (Harris et al. 1997; Hartsfield et al. 2004), IL-1b polymorphism (Al-Qawasmi et al. 2003), role of ethnicity with Asian patients having less root resorption than Caucasian and Hispanic patients (Sameshima and Sinclair 2001), and the role of abnormal root morphology like pipette-shaped roots or apical bends (Levander and Malmgren 1988; Kjaer 1995) were all discussed as potential factors that might influence root resorption.

Treatment-related factors such as duration of treatment (Taithongchai et al. 1996), apex displacement with cases having 4 premolar extraction treatments showing more resorption than nonextraction cases (Shameshima and Sinclair 2001), type of tooth movement (Parker and Harris 1998) and magnitude of orthodontic force (Owman-Moll et al. 1996) were studied. In order to evaluate the impact of duration of force, the effect of a treatment pause (2-3 months) was discussed (Levander et al. 1994). The effect of the applied force on the amount of root resorption was studied: Most of the studies focused on the amount as well as on the type of the applied force (light versus reasonably heavy and/or constant versus intermittent) (Weiland 2003). In histologic studies the application of light and heavy continuous force (50 vs. 100/200

Introduction

cN) resulted in a similar amount of resorption (Owman-Moll et al. 1995; Owman-Moll 1995).

The influence of local factors like tooth location (maxilla or mandible) has provoked lively debate. Although in one study it was found that the location of teeth (maxillary or mandibular) did not significantly influence the amount of root resorption (Weiland 2003), other studies had different outcomes, showing that maxillary teeth were more prone to root resorption than mandibular teeth (McFadden et al. 1989; Paetyangkul et al. 2009). *Therefore, studies using one standardized, experimental tooth movement may explore possible influence from tooth location or the presence of an obstacle on the amount of root resorption.*

Association between root resorption and tooth movement

A positive association between the amount of tooth movement and root resorption may be expected. Few studies have studied this relationship so far. In adults with fixed appliance treatment, a weak correlation was found between radiographically diagnosed loss of root length and the amount of movement (Baumrind et al. 1996). A different, more recent study found a correlation between linear tooth movement and the volume of root resorption measured with confocal laser scanning microscope (Weiland 2003). In this particular study teeth were moved freely without the possible influence of an obstacle that could impede their movement. *An open question remains: What happens if the force is still present but no movement can happen due to the presence of an obstacle? Employing an experimental set-up may clarify the impact of the presence of an intra- or interarch obstacle on the amount of root resorption.*

Radiological methods to detect root resorption clinically

For many years routine radiographic procedures, such as periapical (PA) and panoramic (OPT) radiography, were the only possible methods of clinically diagnosing root resorption. Recently newer methods like computerized tomography (CT) and cone-beam computed tomography (CBCT) have provided 3D models. However, a degree of root shortening is required, before root resorption is detectable on radiographs. Until now, there has been no gold standard available for the evaluation of these methods of detection of orthodontically induced root resorption.

Periapical and panoramic radiography

Different radiographic methods have been used, but to date the recommended tool for the diagnosis of apical root resorption during orthodontic tooth movement is periapical radiography (Levander et al. 1994; 1998). The big advantage of this technique is reduced image magnification and distortion, especially in the upper incisor region, compared to panoramic imaging, thus providing greater accuracy with a low radiation dose (Taylor and Jones 1995). A certain degree of root resorption is required before being detectable on radiographs. Histological verification revealed early stages of resorption could not be diagnosed accurately by periapicals (Andreasen et al. 1987; Chapnick 1989; Kurol et al. 1996). Other authors claimed that the severity of root resorption of upper incisors could not be accurately judged from radiographs alone (Hemmisdottir et al. 2005).

Clinically, panoramic radiographs are routinely used to examine bone level and root parallelism before and near the end of orthodontic treatment. In a comparison between panoramic and periapical radiographs, it was found that OPTs overestimated root resorption by 20 % (Shameshima and Asgarifar 2001). *The use of these methods has never been validated in evaluating orthodontically induced apical root resorption.*

Cone-beam computed tomography

Cone-beam computed tomography (CBCT) is a radiographic method applicable to different fields such as implant dentistry, oral surgery, endodontics, and examinations of temporomandibular disorders (Danforth 2003; Lascala et al. 2004). This technology has the great advantage of providing high contrast and clear 3D images (Ziegler et al. 2002; Sukovic 2003). In clinical practice, the main advantage of the CBCT technology when

Introduction

compared to conventional computed tomography is the minimization of the radiation dose, scan time, and image artifacts, as well as image accuracy, chair-side image display, and real-time analysis (Scarfe et al. 2006). In the field of orthodontics, the indication of CBCT imaging has been restricted to the visualization of impacted teeth and to the examination of the temporomandibular joint and cleft patients (Holberg et al. 2005; Walker et al. 2005; Wörtche et al. 2006; Liu et al. 2008). The detection of root resorption using CBCT has so far only been reported in case reports (Patel et al. 2007). While some authors recommend CBCT as the standard procedure, replacing conventional lateral cephalograms and panoramic images for comprehensive orthodontic patients (Smith et al. 2011), in 2010 the American Association of Orthodontists concluded in their guidelines that large volume CBCT should not be used routinely for orthodontic diagnosis (American Association of Orthodontists 2010). In a review, Halazonetis discussed the limitations of the CBCT: radiation burden, problems regarding the diagnostic accuracy efficacy (measuring errors of thin structures due to the relatively large voxel size of sometimes >1mm), and incidental findings (Halazonetis 2012). *Despite these limitations CBCT could be employed for comparison with other conventional radiographic methods, to improve the diagnostic ability to detect orthodontically induced apical root resorption, especially since only a tomographic technique is currently able to evaluate slanted root resorption. Although the method was not validated at the time, a very recent study attributed a very high sensitivity and specificity in detecting external root resorption to CBCT (Deliga Schröder et al. 2018).*

Micro-computed tomography

Although root resorption is a 3D phenomenon, it was formerly studied using 2D confocal, light, or scanning electron microscopy (Harry et al. 1982; Owman-Moll 1995; Acar et al. 1999). In his PhD thesis Chan worked on the 3D visualization and volumetric measurement of the resorption craters. He imported stereo scanning electron microscopy images (SEM) into a 3D red-green stereo anaglyph coding of a 3D flight simulation program in order to visualize the root resorption craters (Chan et al. 2004). Using a software program designed for the study, he was able to quantify each individual crater (Chan et al. 2004). Other authors measured 3D images made with a confocal laser-scanning microscope (CLSM) to quantify resorbed areas of previously moved and extracted teeth (Weiland 2003).

Recently, it has been shown that micro-computed tomography (micro-CT) provides rapid and accurately-enhanced visual and perspective assessment of small structures. This method has been mainly used to visualize and quantify

bone architecture and development as well as trabecular structures (Guldberg et al. 2004; Chappard et al. 2006). In dentistry this method was adapted to study high-resolution 3D images of extracted teeth. Micro-CT can be used to visualize and quantify orthodontically induced resorption craters (Harris et al. 2006; Foo et al. 2007). The root resorption craters became clearly visible, and allowing for the identification of even minor resorption spots. A three-dimensional analysis of the craters may therefore be done without performing histological analysis. The advantage of 3D analysis was that resorption craters could be visualized from different perspectives, which was helpful in studying the extent, topography and morphology of the craters. *The use of micro-CT scanning may help us to quantify volume loss in clinical experimental studies, and furthermore may provide a gold standard when making comparisons with other clinical radiographic methods.*

AIM

The overall aim of this thesis was to study the influence of factors on orthodontic tooth movement and orthodontically induced root resorption. Furthermore we aimed to investigate the validity of the normally employed radiologic means to diagnose root resorption.

The specific aims were:

- To study the variations of orthodontically induced tooth movement between and within subjects (paper I, II).
- To investigate the possible influence of subject- and tooth-related factors on tooth displacement (paper I, II).
- To elucidate the importance of intra- or interarch obstacles on the amount of tooth movement (paper I).
- To compare the diagnostic capacity of panoramic radiographs in detection of orthodontically induced apical root resorption in respect to cone-beam CT (paper III).
- To investigate the validity of digitized periapical radiographs in detecting orthodontically induced root resorption (paper IV).
- To explore the variations of orthodontically induced cervical root resorption between and within individuals (paper V).
- To identify factors, such as location of the tooth and the presence of an obstacle that could influence the amount of root resorption (paper V).
- To study potential associations of cervical root resorption with the amount of tooth displacement (paper V).

PATIENTS AND METHODS

Patients

This thesis contains two different patient samples.

Patients near end of orthodontic treatment sample

From a private office in Winterthur, Switzerland 22 patients (8 females, 14 males; mean age 16.7 years; range 12.6 - 37.2 years) were selected for this study (paper III). They were all near the end of their orthodontic treatment with fixed appliance, when they were further referred for study of the proximity of neighboring roots with cone-beam CT, previously seen on panoramic radiographs.

The experimental patient group

Originally 30 patients (20 females, 10 males; mean age 16.7 years; range 11.3 - 43 years) were recruited at the University Clinic in Geneva, Switzerland (paper I, II, V). They were all about to start their orthodontic treatment and required two or four premolar extractions. All patient group members had to fulfill the following selection criteria: (i) good general and dental health; (ii) no restored or endodontically treated teeth (iii) no history of previous dental trauma; (iv) no radiographic evidence of idiopathic resorption; and (v) complete apexification of the premolars.

In paper IV where we examined the validity of the periapical radiographs in detecting apical root resorption we based our evaluation on the first 16 patients of the sample. The sample for this paper consisted of 12 females and 4 males with mean age of 17.7 years (range 11.3 - 43 years).

All subjects signed a written informed consent and the Medical Ethics Committee of the University of Geneva approved the study.

Sample size estimation

The initial sample size estimation was based on the amount of tooth displacement. The number of patients for the experimental tooth movement sample was calculated to be sufficient, especially since we applied a split mouth model comparing experimental teeth to controls.

Patients and Methods

In paper II we used a subsample of 11 patients that met the criterion of having experimental teeth that were free to move without the presence of an obstacle such as neighboring touching teeth or occlusal interferences. This allowed us to exclude obstacles as a confounding variable and permitted us to examine the inter- and intraindividual variation of tooth movement. We performed a post hoc power analysis for this subsample with probability of type I error (alpha) 0.05 and correlation coefficient ≥ 0.88 (www.StatsToDo.com) and found that the power estimation of the study was 0.99.

For the already existing sample of the paper III we performed a post hoc power analysis and found that the power of this study was 0.99.

For paper IV we calculated the needed sample size to be 15 patients. Therefore, we included the first consecutive 16 patients in this study.

Experimental design

Standardized experimental orthodontic tooth movement (paper I, II, IV, V)

In this prospective clinical trial, premolars scheduled to be extracted for orthodontic reasons were randomly allocated to an experimental and a control group. The 59 premolars of the experimental group were moved in a buccal direction for 8 weeks in a standardized way. Using a 019 x 025 TMA sectional wire as a cantilever arm with an initial buccal activation of 1N, the premolars were tipped buccally. The sectional wire was ligatured with a one-point contact to the bracket. A transpalatal bar or lingual arch was placed to reinforce the anchorage. After 4 weeks the activation of the cantilever was readjusted.

To imitate an ordinary clinical situation no precautions were taken to raise the bite in order to avoid inter-occlusal contact during the tooth movement.

In this split mouth design 58 premolars served as controls, which were bonded but not orthodontically moved.

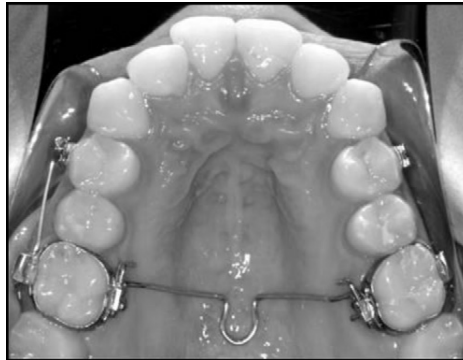

Figure 1. Application of force in the occlusal view.

Validation of panoramic radiograph – cone-beam CT (paper III)

For this retrospective study the original sample was consecutively recruited in order to check for root proximity near the end of ongoing orthodontic treatment (Leuzinger et al. 2010).

Methods

Evaluation of the amount of tooth displacement (paper I, II, V)

The amount of tooth displacement was studied with dental casts taken before and after the experimental period. The models were scanned (600 dpi, 24 gray scale, TIFF format) and superimposed on stable dental structures. The superimpositions and measurements were performed with Adobe Photoshop software (Elements 6, version 6.0, Adobe Systems, San Jose, Calif). We measured actual tooth movement connecting the superimposed centroid points (geometric center) on the occlusal surfaces of the premolars.

We examined the presence or absence of intra- or interarch obstacles using the dental casts. An intra-arch interference was defined as a neighboring tooth situation, and an interarch interference meant an obstacle such as an occlusion-interfering antagonist. The evaluation was done on the dental casts at the molar level by moving them 1 mm apart and checking whether antagonists were interfering at this position.

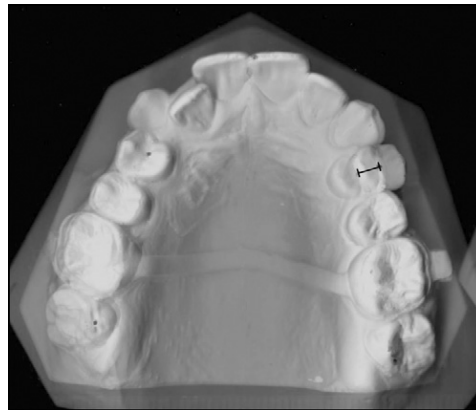


Figure 2. Dental casts made before and after the experimental period were scanned and superimposed to measure actual tooth movement. The centroid point was defined as the geometric center of the tooth in the occlusal plane. On the superimposed cast images, the distance on the line connecting the two centroid points represents estimated tooth movement.

Error of the method

In order to check for random error we used Dahlberg's formula ($Se^2 = \sum d^2 / 2n$) (d is the difference between measurements from the 2 superimpositions) to calculate the reliability coefficient ($CR = 1 - Se^2/S_t^2$) (S_t is the standard deviation of measurements from superimposition 1) (Houston, 1983). The result showed excellent reliability for this method ($CR = 0.997$). The error of the method was $SE = 0.13$ mm.

The process of repeating superimpositions and remeasuring tooth movement for 40 teeth, 2 weeks after initial measurement, was used to evaluate the systematic error of the method. We used a paired t-test to compare differences between the 2 measurements and did not find differences at the 0.05 significance level. Therefore, the probability of a systematic error may be considered very small.

Micro-CT image acquisition and reconstruction (paper IV, V)

At the end of the experimental period (8 weeks after the start of the experiment) experimental and control premolars were carefully extracted. We used a SkyScan 1076 micro-CT scanner (Skyscan, Aartselaar, Belgium) to scan the teeth at a $9\mu\text{m}$ resolution. The images were processed, and cross-sectional images were reconstructed using a classical Feldkamp cone-beam algorithm in the medical imaging software Osirix for 3D reconstructions (version 2.7, open-source DICOM viewer). The Institute of Translational Molecular Imaging of the University of Geneva helped us to perform these procedures.

Qualitative assessment of apical root resorption (paper IV)

In paper IV we used the 3D reconstructions of the micro-scanner images to assess the presence or absence of apical root resorption. We were the two calibrated examiners (AD and CG), who analyzed randomly sequenced movies blindly. When the two examiners disagreed, a consensus was reached through a subsequent collective evaluation.

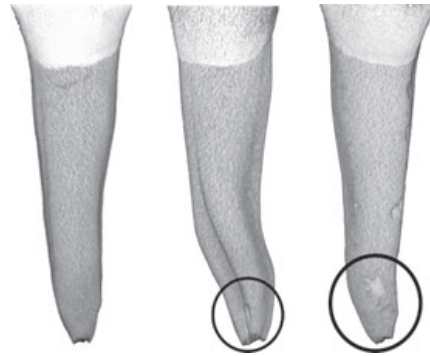

Figure 3. Three-dimensional micro-computed tomography (micro-CT) scanner reconstruction images of the lingual surfaces: absence of apical root resorption (tooth to the left) and presence of apical root resorption varying from moderate (tooth in the middle) to severe (tooth to the right).

Interrater agreement

A calculation of Cohen's Kappa (0.78) for this experiment showed substantial interrater agreement between the two observers when evaluating initially apical root resorption on micro-scanner image reconstructions.

Volume assessment of buccal cervical root resorption (paper V)

The Osirix software was used to assess the volume of the root resorption crater on the buccal side of the cervical part of the root, since we found it impossible to estimate the volume loss at the apical part of the root. In order to quantify the root resorption volume first the hull or outer limit of the resorbed area was defined manually on the corresponding axial slice before setting the upper and lower axial limit of the crater. The software then allowed for subsequent automatic calculation of the total crater volume.

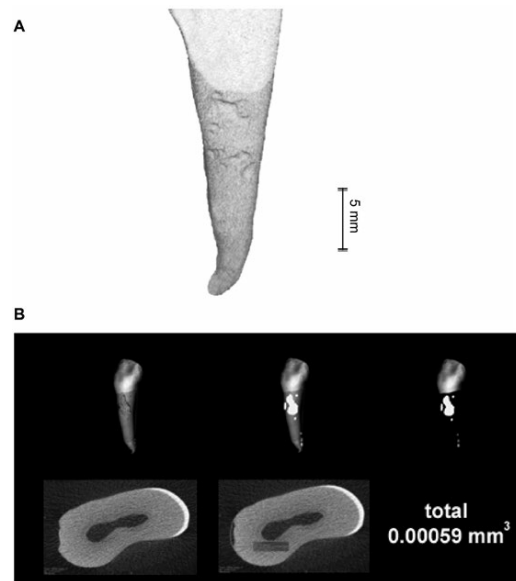


Figure 4. (A) Reconstructed image of a micro-CT scan of an experimentally moved premolar: presence of root resorption craters in the cervical area of the root. (B) Example of the volumetric quantification of the resorption craters of an experimentally moved premolar. CT, computed tomography.

Periapical radiograph acquisition and film evaluation (paper IV)

Periapical radiographs were taken before and after experimental tooth movement. Applying the parallel technique, intra-oral radiographic film was used (Kodak, Eastman Kodak, Rochester, NY, USA; Ultraspeed D, 30x40 mm, 7 mA, 70 kV, 0.20 s) and was subsequently digitized with a radiograph scanner (Epson Expression 1600 Pro; Seiko-Epson Corp., Tokyo, Japan; 600 dpi).

The presence or absence of apical root resorption was evaluated on the digitized radiographs by two calibrated examiners (AD and CG). The assessment was performed separately and blindly in a randomized radiograph sequence. In case of disagreement a final collective evaluation was conducted and a consensus was reached.

Interrater agreement

Interrater agreement was calculated using Cohen's Kappa (= 0.78), with this calculating indicating substantial agreement between the two observers when evaluating apical root resorption on periapical radiographs.

Panoramic radiograph acquisition and root resorption evaluation (paper III)

An orthopantomograph (Cranex Excel, Soredex, Tuusula, Finland) was used to acquire panoramic radiographs (OPT). The images were stored in TIFF format.

The presence or absence as well as degree of apical root resorption were assessed by two calibrated examiners (AD and CG). They evaluated the images separately and blindly using the Levander and Malmgren scoring system. This scoring system classifies root resorption in 5 grades: 0, no root resorption; 1, mild resorption, with the root of normal length and only an irregular contour; 2, moderate resorption, with small areas of root loss and the apex having an almost straight contour; 3, severe resorption, with loss of almost one third of root length; and 4, extreme resorption, with loss of more than one third of the root length (Levander and Malmgren, 1988). In case of disagreement a final and collective evaluation was performed.

Interrater agreement

Cohen's Kappa for this process showed poor agreement with the OPT (value, 0.46).

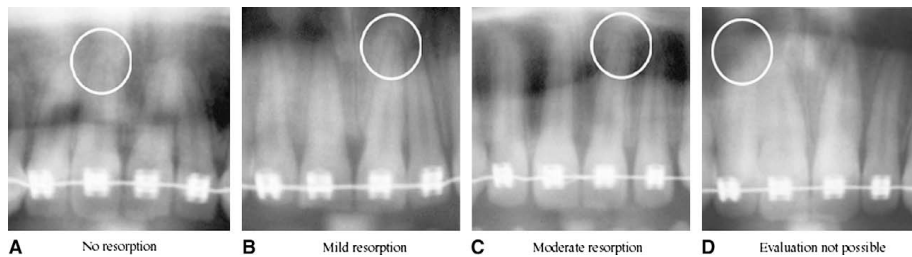


Figure 5. Index for evaluation of root resorption in the OPT: A, 0, no resorption in tooth 11; B, 1, mild resorption in tooth 21; C, 2, moderate resorption in tooth 21; D, evaluation impossible in tooth 12.

Cone-beam CT image acquisition and root resorption evaluation (paper III)

A 3D Accuitomo FPD (J. Morita, Kyoto, Japan) was used to acquire the CBCT images. The images were taken in two area sizes (40 x 40 mm and 60 x 60 mm) with super-high resolution (2.0 line pairs per millimeter; voxel size, 0.125 mm). We used the iDixel software (J. Morita, Kyoto, Japan) to align the primary plane of reconstruction parallel to the long axis of the examined teeth.

Apical root resorption was assessed in the same way as previously described for the periapical radiographs.

Interrater agreement

Cohen's Kappa showed substantial agreement between the 2 observers with the CBCT method (0.63).

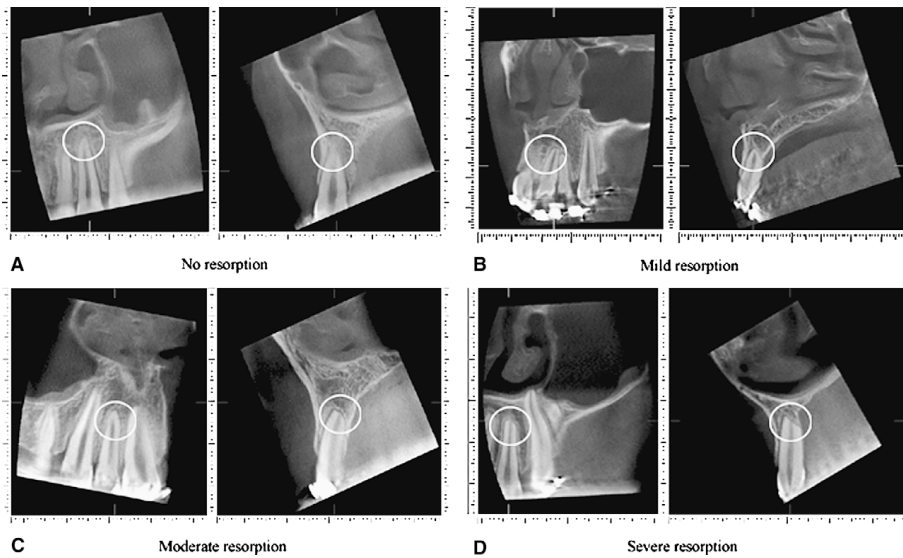


Figure 6. (A) Index for evaluation of root resorption in the CBCT: A, 0, no resorption in tooth 22; B, 1, mild resorption in tooth 21; C, 2, moderate resorption in tooth 12; D, 3, severe resorption in tooth 22.

Statistical methods (paper I-IV)

All statistical analyses were performed with IBM - SPSS Statistics (Release 13.0.0 and 23.0.0, SPSS Inc., an IBM Company, Chicago, Illinois, USA) and Stata 13 (Stata Corp, College Station, Texas, USA). Apart from the statistical tests detailed below, descriptive statistics were calculated for tooth movement and root resorption measurements.

Unpaired t-tests were used when comparing the experimental and control group for differences in tooth displacement and root resorption (paper I, V). Significance was set at the $p < 0.05$ level. A non-parametric Mann-Whitney U test was applied to look for differences in cervical root resorption between experimental and control groups (paper V). The Pearson chi-square test was used to test the qualitative evaluation of apical root resorption on OPT and CBCT images (paper IV).

Within the same individual the influence of tooth location and the presence of an obstacle on the amount of cervical root resorption were tested with a paired t-test (paper V).

In order to test the influence of the factors as age, sex, tooth location, and intra-arch or interarch obstacle on the amount of tooth movement of the experimental teeth, an analysis of variance was performed (ANOVA) (paper I).

For the experimental teeth, the correlation between the severity of root resorption (square root transformation) and the amount of tooth movement, and at the individual level the correlation in matched teeth between the amount of tooth displacement as well as the amount of root resorption were expressed by a Pearson's correlation coefficient (paper II, V).

(Random effects) multiple linear regression analysis was carried out to examine associations between tooth displacement and age, sex, tooth location, and the presence of interference (paper I, II), as well as to determine associations between cervical root resorption (square root transformation) and displacement, and tooth location (paper V).

Comments

Comments on patient selection

Ethical considerations may arise as to why patients had to undergo two radiological exposures in order to compare the validity of OPT versus cone-beam CT detecting root resorption. As explained, the decision for obtaining additional three-dimensional radiological information was taken by a clinician in his private office for the purpose of investigating root proximities previously seen on OPT and if necessary carry out adjustments before finalizing the orthodontic treatment. We studied the existing sample.

Comments on experimental design

We decided to modify the experimental clinical model introduced by Owman-Moll to be able to study the influence of the presence of interference on both actual tooth movement and root resorption. The model was chosen since it allowed extractions of the teeth at the end of the experimental period. This gave us the possibility of quantifying precisely the volume of root resorption. An alternative model to that of vestibular tooth movement might have been to study the bodily movement of canine distalization after premolar extraction. This would have limited the possibilities of quantifying root resorption, unless we would have taken 2 CBCTs as part of the experiment, one before and one after.

Comments on methods

Nowadays, we would apply intraoral scans to improve the precision of tooth displacement measurements. This would exclude possible sources of error starting with alginate impressions, plaster model production and scanning of the models. Nevertheless, the error of our method was sufficiently small for the purposes of our study.

We chose the best-fit method for superimposition, instead of stable palatal structures in the maxilla. The reason for this was that we wanted to apply the same method in the upper and lower arch and the relatively short time frame of the study period (8 weeks).

The displacement of the occlusal centroid obviously also depends on the height of the crown. It does not reflect the tipping movement, which takes place neither at the apical nor at the cervical part of the root.

The use of micro-scanner images allowed us to perform a three-dimensional analysis of the craters without performing histological analysis, which would have been much more time-consuming and most probably less precise. The Osirix Software allowed us to quantify the resorption volume with a known method used for volume quantification in the medical radiological field (i.e. tumor size calculation). We focused on the buccal cervical region in order to quantify the resorption volume. When buccal tipping forces are exerted, the lingual apical and the buccal cervical part are under tension (Reitan 1985). These regions show, due to the high pressure, significantly more resorption than other regions during this type of tooth movement (Chan et al. 2005) and showed a similar resorption volume per unit area (Chan et al. 2006). We were not able to quantify apical root resorption, as no records existed for the initial root length and shape.

The clinical recommendation is to check 6 - 9 months after the start of orthodontic treatment with fixed appliances for root resorption by means of periapical radiographs of the upper incisors. In our study we did not focus on the incisor region, but rather we tested the validity of these radiographs for premolars.

The clinical part of this thesis was planned in 2002, and patient collection took place from 2003 to 2008. After this period the radiology in dentistry experienced an important evolution. Conventional radiology has been replaced fully by digital radiology. Digital sensors have evolved dramatically which is reflected in lower exposure times and dosage, as well as better and more consistent image quality. Furthermore, an important part of this revolution has taken part on the software side. By applying new algorithms, further reduction of exposure, and improved image modification became possible. These improvements affected all types of radiological machines discussed herein. Therefore, our radiological results show limitations and may vary on the application of the latest technology.

RESULTS

Tooth displacement

Differences in the amount of tooth displacement (paper I)

Orthodontically displaced teeth moved significantly more ($2.4 \text{ mm} \pm 1.2 \text{ mm}$) compared to controls ($0.2 \text{ mm} \pm 0.2 \text{ mm}$) ($P < 0.0001$). A large variation in tooth movement may be noted in the experimental group.

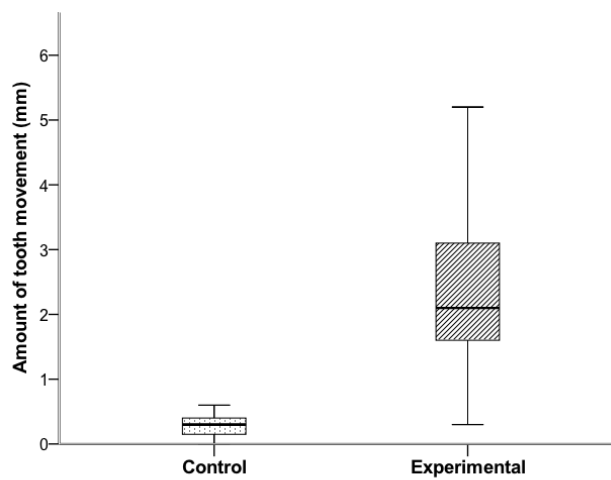


Figure 7. Box plots based on the medians, quartiles, and extreme values for the amounts of tooth displacement of the experimental and control teeth.

Factors influencing the amount of tooth movement (paper I)

Age

The factor of age was found to have a significant impact on tooth displacement. Younger subjects (< 16 years; n = 19; 36 teeth) showed significantly greater tooth movement than older subjects (≥ 16 years; n = 11; 21 teeth) (2.6 ± 1.3 mm vs. 1.8 ± 0.8 mm; $P < 0.007$).

Influence of interference

The presence of an obstacle (intra- or interarch interference) reduced tooth movement significantly. In the experimental group (n = 57), 33 teeth were moved without obstacle and showed a mean displacement of 2.6 mm (± 1.3 mm), while the 24 teeth that met an obstacle during movement showed significantly less movement ($1.8 \text{ mm} \pm 0.8 \text{ mm}$) ($P < 0.017$). More precisely, teeth with an interarch interference (n = 17) showed significantly less movement ($2.0 \text{ mm} \pm 1.3 \text{ mm}$) ($P < 0.041$), while teeth with an intra-arch obstacle (n = 7) moved even less ($1.6 \text{ mm} \pm 0.3 \text{ mm}$) ($P < 0.044$) compared to teeth without an obstacle.

Inter- and intraindividual variation (results adjusted for interferences)

Since the presence of obstacles such as neighboring touching teeth or occlusal interferences influenced the amount of tooth movement as a confounding factor, we decided to select only patients whose teeth could move freely (without any obstacles) in paper II, which focused on inter- and intraindividual variation of tooth movement. 11 patients met this criterion and were selected for this second paper (7 females, 4 males; mean age 15.9 years, range 11.3 - 28.6 years).

After applying force for 2 months, the range of mean tooth movement (calculated from 2 displaced teeth per individual), showed substantial variation between individuals (0.6 - 5.5 mm), with it therefore being possible to identify slow movers and fast movers. Teeth located in the maxilla showed a significant greater amount of tooth movement (3.06 mm) than teeth located in the mandible (1.97 mm). We found a high correlation in the amount of tooth movement of teeth within the same individual ($R = 0.885$) and within jaws ($R = 0.948$).

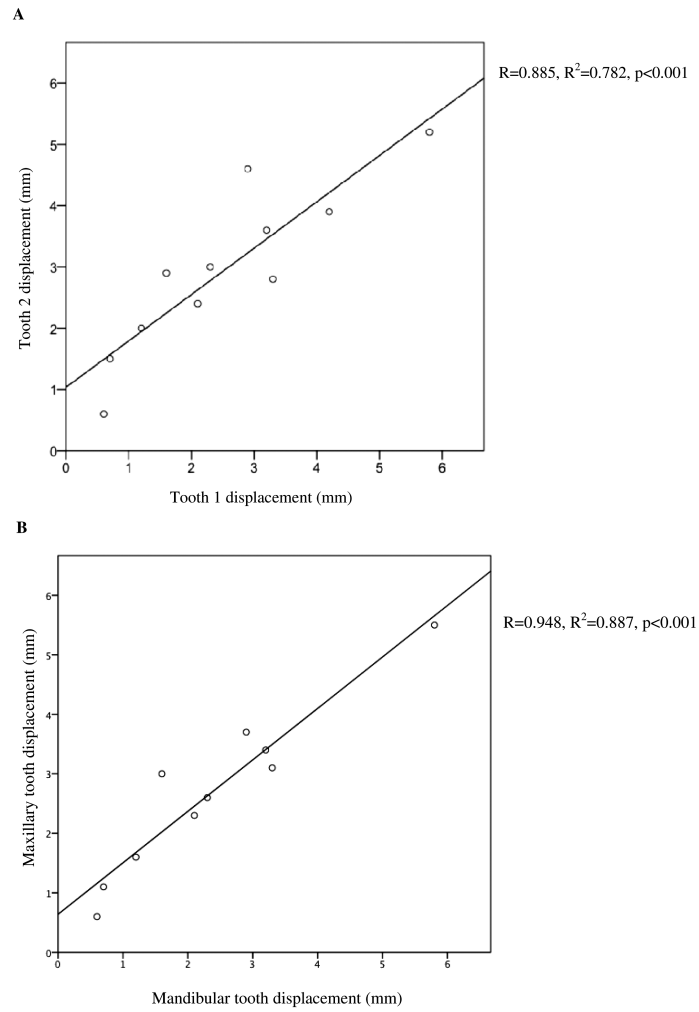


Figure 8. (A) The amount of tooth displacement for both experimentally displaced teeth within the same individual is shown. The fitted line represents the intra-individual correlation of tooth movement within the same subject. ($R = 0.885$, $R^2 = 0.782$, $P < 0.001$). (B) The amount of tooth displacement in the maxilla and mandible within the same individual. The fitted line represents the intra-individual correlation of tooth movement between the maxilla and the mandible ($R = 0.948$, $R^2 = 0.887$, $P < 0.001$).

Root resorption

Validity of radiological methods of detecting root resorption

Panoramic radiography in respect to Cone-beam CT

Significant differences were found between the two methods evaluating different grades of apical root resorption. OPT generally underestimated the amount of root resorption. No resorption: 145 teeth were identified by OPT having no resorption, whereas, by CBCT, only 80 teeth had no resorption. Mild apical resorption: with OPT 92 teeth showed mild resorption, while 128 did with CBCT. Moderate resorption: only 21 teeth showed moderate resorption with OPT, but 48 teeth did with CBCT. Severe resorption: None with OPT, while 2 teeth were identified to have severe resorption, when assessed with CBCT.

The differences in the capacity of the 2 methods to evaluate root resorption were significant for both jaws: Maxilla ($P < 0.001$) and mandible ($P < 0.002$). The maxillary incisors showed the most pronounced differences.

Table 1. Evaluation of apical root resorption in all teeth by OPT and CBCT.

	<i>OPT</i>			<i>Total</i>
	<i>No resorption</i>	<i>Mild resorption</i>	<i>Moderate resorption</i>	
CBCT				
No resorption	62 (24)	16 (7)	0 (0)	80 (31)
Mild resorption	70 (27)	52 (20)	6 (2)	128 (49)
Moderate resorption	12 (5)	21 (8)	15 (6)	48 (19)
Severe resorption	1 (0.5)	1 (0.5)	0 (0)	2 (1)
Total	145 (56.5)	92 (35.5)	21 (8)	258 (100)

Values are expressed as n (%).

The values shown in bold along the diagonal represent the observed frequencies of agreement when evaluating root resorption with both methods.

Periapical radiographs compared to micro-CT

We investigated the presence or absence of apical root resorption when evaluated with periapical radiographs and micro-CT. In this investigation the micro-CT served as the criterion standard test. The specificity and sensitivity of the periapical radiographic method to detect apical root resorption was evaluated: We found a high specificity of 78 % for this method. This means that using digitized periapical radiographs we were able to diagnose the absence of root resorption correctly in 78 % of the teeth. However, the ability of digitized periapical radiographs to correctly identify the presence of root resorption was relatively low. A relatively low sensitivity of 44 % was obtained, which indicates that less than half of the teeth with apical root resorption were identified correctly.

We calculated the positive and negative predictive values of the radiographic method (76 %, respectively 48 %). We found a likelihood ratio for a positive result of 2.1, which means that in a tooth with resorption a positive test result is twice as likely to occur than in one that does not have resorption.

Table 2. Diagnostic accuracy of digitized periapical radiographs compared with the micro-CT criterion standard test.

Periapical radiographs	Micro-CT		
	No resorption	Resorption	Total
No resorption	15 (31.3)	16 (33.3)	31 (64.6)
Resorption	4 (8.3)	13 (27.1)	17 (35.4)
Total	19 (39.6)	29 (60.4)	48 (100.0)

Values are expressed as *n* (%).

Sensitivity = 44 % (95 % CI: 26–62 %).

Specificity = 78 % (95 % CI: 60–97 %).

Positive predictive value = 76 % (95 % CI: 56–96 %).

Negative predictive value = 48 % (95 % CI: 30–65 %).

Likelihood ratio for positive result = 2.1 (95 % CI: 0.5–6.1 %).

Variability in root resorption after experimental tooth movement (paper V)

Similar to the results regarding tooth movement, we found significant differences in the amounts of cervical root resorption between orthodontically moved teeth (n = 57) and controls (n = 56) (0.00055 mm^3 (SD = 0.00037 mm^3) vs. 0.00003 mm^3 (SD = 0.00010 mm^3), $P < 0.001$). The range of cervical root resorption varied substantially in the experimentally moved teeth, after being orthodontically displaced for 8 weeks.

At the same time, we found significant correlation in the amount of cervical root resorption of the experimentally displaced teeth within the same individual ($R = 0.421$, $P = 0.023$).

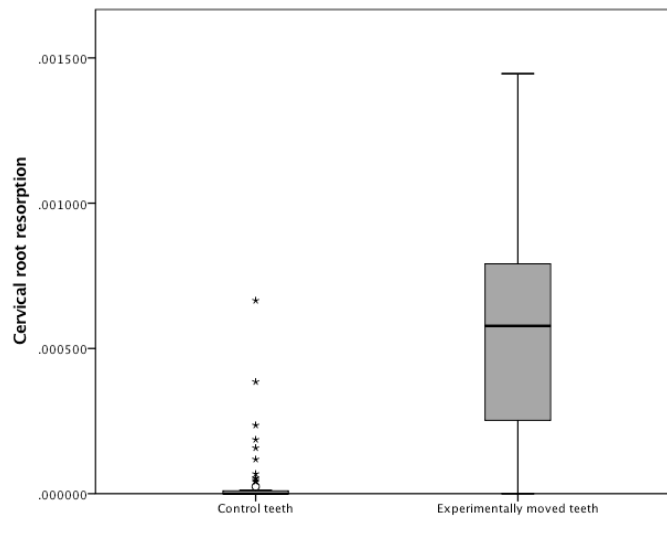


Figure 9. Box plots based on the medians, quartiles, and extreme values for the amounts of cervical root resorption of the experimental and control teeth. The asterisks show extreme values.

Influencing factors on root resorption (paper V)

Location

Similar to the amount of movement, the amount of cervical root resorption was influenced by location (maxilla vs. mandible). Cervical root resorption of teeth located in the mandible was significantly more significant than of those located in the maxilla: 0.00062 mm^3 (SD = 0.00032) versus 0.00047 mm^3 (SD = 0.00042), respectively, $P = 0.046$. In this calculation, we included both teeth with and without an obstacle. Maxilla and mandible were both almost equally affected by the presence of an obstacle.

Obstacle

To investigate the impact of an obstacle we selected 12 patients, who all had one experimental tooth with an obstacle as well as one without an obstacle. The two groups showed no significant difference in the amount of cervical root resorption: 0.00065 mm^3 (SD = 0.00041) versus 0.00075 mm^3 (SD = 0.00043), respectively, $P = 0.499$.

Amount of tooth movement

Examining a possible relationship between the amount of tooth displacement and the amount of cervical root resorption, we included the entire experimental group ($n = 57$) and completed a square root transformation for the root resorption to take this third dimension into account. We found significant correlation between the amount of displacement and the amount of root resorption (square root transformation) ($R = 0.318$, $P = 0.016$). This correlation was slightly higher ($R = 0.382$, $P = 0.026$) when we included only teeth without the presence of an obstacle (confounding variable) ($n = 34$).

In a multiple regression analysis, we included only patients with both experimental teeth moving without obstacles ($n = 11$). We found the amount of cervical root resorption (square root transformation) was associated with both the displacement and location of the moved teeth (maxilla/mandible) (adjusted $R = 0.54$, $P = 0.036$).

DISCUSSION

Using a standardized method of tooth displacement, amounts of tooth movement and root resorption showed high variability; fast and slow movers were found. Additionally, younger patients showed more tooth movement than older ones. Location seemed to have an impact on tooth movement and the root resorption, with there being a greater amount of tooth movement in the maxilla and more resorption in the mandible. Furthermore, the presence of an intra- and interarch obstacle was found to decrease the amount of tooth movement, while it does not seem to slow down the resorption process significantly. Some root resorption may be explained by the amount of tooth movement alone.

Commonly used radiographic methods to diagnose root resorption were found to underestimate root resorption. When comparing periapical radiographs with micro-CT, as a gold standard, the limited accuracy of these images was shown. Furthermore, it was found that CBCT was a powerful tool in detecting apical root resorption, while OPT underestimated apical root resorption.

Tooth displacement

Fast movers and slow movers

We confirmed in our study the great variations in OTM that exist among patients. This is a fact that we experience in our daily clinical work, where we have large differences in tooth movement and treatment time when applying the same treatment technique with different patients. We were able to show that in absence of local or functional obstacles (a confounding factor) large individual variation exists, confirming the previously formulated concept of fast movers and slow movers. To our knowledge, our results confirm, for the first time in humans that was previously only found in studies on beagle dogs (Pilon et al. 1996). Other studies applying 50 g of force in a human experimental model to examine the early tooth movement pattern also found equally considerable individual variations in tooth displacement (Owman-Moll et al. 1995, Lundgren et al. 1996). These variations might be explained by individual differences in bone density, supra-alveolar fibers, structure of collagen fibers, cellular activity, and root surface area (Devlin et al. 1998, Chugh et al. 2013).

Discussion

Our results correspond to the Pilon model, which suggested each individual has their own optimum force to provoke tooth movement. Comparing high versus low forces, it has been shown that force level had little influence, since the rate of OTM showed large individual differences (Von Böhl et al. 2004). A different study group confirmed these results, again applying different force levels in beagle dogs (Owens et al. 2007). These results were also the reasoning why we applied a force level of 100 cN and not 50 cN, like previous studies. Using stainless steel wire, they claimed weekly activation was key to the continuity of the force level (Owman-Moll et al. 1995, Lundgren et al. 1996). In order to prevent force decay, we chose TMA wire due to its superior resilience. This allowed us to readjust the force level of the wire whenever necessary after 4 weeks. Taking into account each individual has an optimal level of force, it may be the case that in our ‘slow movers’ group the optimal level of those individuals was not attained.

We chose to work with constant forces since various studies investigated the influence of a force regime on amount of movement. They concluded a constant force resulted in greater amount of OTM than a dissipating force (Owman-Moll et al. 1995, Weiland 2003). In a study on beagle dogs it had been shown that continuity of force had a greater influence on the rate of OTM than the force magnitude itself (Leeuwen et al. 1999). We found an average tooth movement of 2.4 mm over the 8-week period (1.2 mm/month). These results are in line with previously published data that showed an overall mean velocity of tooth movement of about 1.1 mm/month (Iwasaki et al. 2004).

At the control level, a minor, average displacement of 0.2 mm was measured. This variation may be due to an error of the method as well as occlusal adjustments that happen when opposing teeth are displaced.

Age

We found in our sample, that the amount of tooth displacement was higher in younger patients than in older ones, which is in line with the results of other authors (Iwasaki et al. 2004, Kawasaki et al. 2006). Our findings are supported by biologic facts. Reitan was one of the first authors that described age related differences in the periodontal ligament. He stated that the periodontal ligament in adults was less cellular than in children (Reitan 1961, 1967). These findings were confirmed later in studies on rats, where it was histologically shown that the process of disorganization and subsequent reorganization in the PDL during OTM started earlier and was more prominent in young animals compared to adult ones (Ren et al. 2008).

Animal studies using immunohistochemistry described osteoclast recruitment to be age-related. At the compression side, osteoclast numbers initially increased faster in young than in adult rats, while in a later phase it seems that more osteoclasts are needed to achieve a certain rate of tooth movement in adults (Ren et al. 2005). Other authors have shown in rats that factor age substantially influences PDL cell proliferative activity and subsequently early phase tooth movement (Kyomen et Tanne, 1997).

In humans, tooth movement in individuals who showed evidence of growth during their orthodontic treatment was on average about twice as fast as tooth movement in adult individuals who showed no growth during their treatment (Iwasaki et al. 2004). It was shown that age has an effect on the GCF levels of RANKL and OPT during initial tooth movement. There was an age-related decrease of the RANKL/OPT ratio as well as an age-related decrease of the amount of OTM (Kawasaki et al. 2006).

Location

In our second paper (in the absence of any local or functional interference) we found that teeth located in the maxilla moved on average faster than those located in mandible during the first 8 weeks of tooth movement. These results are confirmed by animal research. In a study on dogs, histomorphometric changes in the maxilla and mandible during OTM were investigated. It had been shown that the maxillary and the mandibular bone react differently to applied force, resulting in significant difference in the amount of tooth movement after 12 weeks. These researchers found faster tooth movement in the maxilla (thin cortical bone), and explained it with a regional acceleratory phenomenon manifested as increased bone turnover in the alveolar process (Deguchi et al. 2008).

We think the reason for differences we found in the buccal tipping movement may be explained on the one hand by differences in bone density and buccal cortical bone thickness in the maxillary and mandibular premolar region and on the other hand by the tipping movement itself. The combination of these two factors resulted in a less pronounced movement in the lower arch due to the thick mandibular cortical bone. Thick cortical bone limits the apical space both on the vestibular and the lingual side within which the root can move. Other studies comparing a different type of tooth movement, mesiodistal tooth bodily movement (similar to canine retraction), found no differences in the amount of movement in the maxilla and the mandible (Owens et al. 2007).

Obstacles

We investigated the influence of functional or local obstacles on the amount of tooth movement. A clinically common situation may occur with a patient are encountered, when during space closure the teeth on one side move faster than on the contralateral side. When examining the reason behind these differences in tooth movement, occlusal interferences can often be detected.

We found that the presence of both, intra- or interarch obstacles reduces the amount of tooth movement significantly. By interarch obstacle we indicate the presence of an occlusal interference, where an antagonist tooth hinders the free movement either in occlusion or in the relaxed position. This creates a boomerang effect where the tooth is involuntarily pressed back to its original position slowing down actual movement. The presence of an intra-arch obstacle represents on the other hand a situation where adjacent teeth absorb part of the applied force, which hinders tooth movement. The actual force is transmitted to adjacent teeth that need to move first before the tooth movement of the actual tooth where the force is applied on can move. The problem itself cannot be looked at in isolation, since clinically both conditions can appear in the same tooth. Clinically, the situation requires space opening, interproximal enamel reduction, or bite rising with bite blocks.

Previous studies used the experimental tooth movement proposed by Owman-Moll applying intraocclusal bite rising, which allowed free tooth movement due to bite blocks. Therefore, our results cannot be compared to theirs. For future studies a more systematic approach with a modified experimental set-up may be desirable.

Other factors

We did not find significant difference in the amount of tooth movement between genders in our sample. However, in animal studies it has been shown that certain hormonal changes do influence the amount of OTM. Ovariectomy in rats increases the amount of OTM significantly (Yamashiro et al. 2001; Sirisoontorn et al. 2011), meaning estrogen deficiency (osteoporosis) increases bone turn over and accelerates tooth movement (Sidiropoulou-Chatzigiannis et al. 2007). In another study, when performing ovariectomy and orchietomy in rats, they concluded that alterations of levels of estrogen, progesterone and testosterone could influence the amount of tooth movement (and resorption). They found generally a significantly higher tooth movement in female rats (Seifi et al. 2015) and increased OTM after

orchiectomy. Other hormonal changes like pregnancy did influence the number of osteoclasts in rats, which were significantly lower in the pregnant group (Ghajar et al. 2013). They also studied the influence of oral contraceptives in rats, finding that the amount of OTM was significantly decreased in the oral contraceptive group (Olyae et al. 2013).

The long-term administration of progesterone was found to reduce the amount of OTM in rabbits (Poosti et al. 2009). In a recent study the application of anabolic androgenic steroids accelerated the biological effects and increased OTM in rats significantly (Karakida et al. 2017). In order to study the effect of Calcitonin CT for anchorage purposes and relapse prevention, CT was injected in rats. A dose-dependent significant decrease of OTM was shown (Guan et al. 2017). The short-term injection of the parathyroid hormone in rats has been shown to increase the amount of OTM by increasing alveolar bone turnover (Li et al. 2013). Local injection of Interferon IFN in mice was observed to be useful in controlling OTM, because of its inhibitory action on excessive osteoclastogenesis (Kohara et al. 2012).

In a systematic review on the influence of medications on the rate of tooth movement, it has been shown that medications affect the rate of OTM substantially. The importance of an up to date patient anamnesis was explained (Bartzela et al. 2009). Since corticosteroid application reduces the bone turnover in rats, it is advised to postpone orthodontic treatment in these patients (Kalia et al. 2004). In a classical experiment Yamasaki and coworkers showed how local administrations of PGE1 or PGE2 could double the rate of OTM in monkeys (Yamasaki et al. 1982). Recently, the influence of life-style drugs has been investigated. Tobacco smoke showed to decrease osteoclast activity and to retard OTM in rats (Nagaie et al. 2014). Furthermore, intake of caffeine seemed to significantly decrease OTM in rats (Shirazi et al. 2017). In another study on rats it has been shown that ethanol decreased the number of osteoclasts and therefore promoted less bone resorption and OTM (De Araujo et al. 2015). Even the influence of carbonated soft drinks was studied and the authors concluded that consumption of carbonated soft drinks decreased OTM in rats (Aghili et al. 2014).

The knowledge discussed above derives mostly from animal research. In most of the animal studies on orthodontic tooth movement the rat was used as a study model. In a critical review of rat studies, careful study of the experimental set-up before generalizing the conclusions has been emphasized (Ren et al. 2004).

Root resorption

In our study we found significant variations in the amount of orthodontically induced cervical root resorption between individuals, and significant correlation for the amount of root resorption within the same individual. We were able to explain part of this variation by the location of the teeth; premolars in the mandible showed significantly more resorption during buccal tipping than maxillary premolars. While the presence of obstacles resulted in a decrease of tooth movement, it did not seem to decrease substantially the amount of root resorption. Finally, the amount of tooth movement was correlated with the amount of resorption.

Our results confirm findings from previous studies that reported large interindividual variations in the amount of orthodontically induced root resorption when standardized forces were applied (Owman-Moll 1995; Weiland 2003).

Location

We found moderate but still significant correlation between the amounts of cervical root resorption for the two experimentally moved teeth of the same individual. Part of this variation was explained by the location of the teeth: Teeth located in the mandible presented significantly more resorption than those located in the maxilla. Ambiguous results were reported in previous studies; neither a study using radiographic evaluation of root resorption (Sameshima and Sinclair 2001), nor other studies using micro-CT scans for volumetric measurements (Cakmak et al. 2014) found significant differences between the two locations. In contrast to our results, Paetyangkul et al. (2009) found that maxillary premolars were more likely to suffer root resorption than mandibular premolars. The differences were attributed to better vascularization and cell recruitment in the maxillary spongy bone, but were based on a small sample of patients ($n = 10$). One explanation of greater resorption in the mandible would be due to differences in the local bone architecture in the premolar region, especially the buccal cortical bone thickness. The influence of the proximity of cortical bone was studied in 30 adult patients who underwent four bicuspid extraction treatments. The amount of root apex movement was positively correlated with the amount of root resorption on the pressure side when evaluated on CBCT images. It was concluded that root apex proximity to the labial and palatal cortical plate was associated with apical root resorption (Nakada et al. 2016). Additionally, when comparing the total root surface area of the mandibular and the maxillary premolars, the mostly single-rooted mandibular premolars absorb a

greater amount of force per unit area than the often two-rooted maxillary premolars, when the same force is applied.

Obstacles

While the presence of an obstacle decreases the amount of tooth movement, it does not seem to decrease the amount of root resorption significantly. We think that the application of force per se may be sufficient to start the process of root resorption, independent of how extensive the tooth movement may be. We found that the amount of root resorption was correlated with the amount of tooth movement in both the presence and absence of an obstacle, which can be explained by the importance of the continuity of force. Previous studies suggested continuity of force plays an important role in the amount of root resorption (Lundgren et al. 1996; Owman-Moll et al. 1995). In a similar set-up, they used weekly wire reactivations to prevent force decay. In our study instead of reactivating the arch wire weekly, we chose a force level of 100 cN to give a greater force decay tolerance margin. The force level has never dropped below 50 cN after measuring, and when necessary readjustments of the force amount were made after 4 weeks. In a study investigating the influence of occlusal trauma by restorative composite buildups, it has been shown that the increase of the vertical dimension by 2 mm for 4 weeks caused root resorption (Cakmak et al. 2014). Another study showed that the influence jiggling forces did not cause significantly different amount of root resorption when compared with continues forces (Eross et al. 2015).

Amount of tooth movement

We were able to explain one part of the variation found in the amount of root resorption by the amount of movement itself. The correlation coefficient we found (0.36) is comparable to those found in previous studies: 0.34 and 0.2 respectively (Baumrind et al. 1996; Weiland 2003). In a model where we excluded the location of teeth as a confounding factor, the correlation even increased (0.54). Previously a metaanalysis of treatment-related factors showed that apical displacement was highly correlated with the apical root resorption ($r = 0.82$) when evaluated on panoramic X-rays or cephalograms (Segal et al. 2004).

Newer orthodontic methods like aligner treatment often claim to cause less root resorption. In a case report showing root resorption after aligner treatment, Brezniak and Wasserstein (2008) demonstrated the complexity of orthodontically induced root resorption. In a split mouth study, it has been

Discussion

shown that the forces produced by aligners had similar effects to light orthodontic force with fixed appliances (Barbagallo et al. 2008). This result was confirmed in a recent study on 372 patients comparing different types of orthodontic appliances used. They found the extent and complexity of incisor apical displacement was associated with an increased risk of root resorption, while no differences with respect to the type of orthodontic appliance used were described (Iglesia-Linares et al. 2017).

Other factors

Other factors influencing the amount of root resorption were mainly studied in animals. The effect of diabetes was studied in a rat model showing that uncontrolled diabetes significantly reduced the amount of orthodontic tooth movement as well as root resorption (Arita et al. 2016). Nicotine exposure promotes odontoclastogenesis and RANKL expression, and aggravates root resorption during OTM in rats (Li et al. 2016). The influence of ovariectomy in rats revealed a more rapid OTM with more severe root resorption (Sirisoontorn et al. 2011). Fluoride may reduce the volume of root resorption craters in rats (Barbagallo et al. 2008).

Surgical procedures like piezocision have been promoted to accelerate the amount of tooth movement. It has been shown in a well-designed split mouth study using micro-CT evaluation, that piezocision increases, on average, the amount of root resorption by about 44 %. In addition in some patients there was noticeable iatrogenic root damage (Patterson et al. 2017). Similar results were reported when the short-term effect of microperforations was studied (Chan et al. 2018).

Diagnostic means

Periapical and panoramic radiography

Validating our findings of periapical radiographs against micro-CT scanner images, we found that periapical radiographs detected more or less half of the apical root resorption confirmed with micro-CT as the gold standard. The calculated sensitivity for periapical radiographs was 44 %. The incidence of apical root resorption in the experimental teeth that we found (86 %) is in line with other studies. They showed that after application of an orthodontic force, small areas of surface resorption always occur when studied histologically or with micro-CT (Owman-Moll et al. 1995; Kurol et al. 1998;

Chan and Darendeliler 2006). In a study looking at the diagnostic capacity of periapical radiographs (PA) when compared to computerized tomography (CT) to detect root resorption on incisors adjacent to ectopically erupting maxillary canines, the sensitivity of intraoral films was considered low with a calculated sensitivity of 0.68 (Ericson and Kuroi 2000).

Several studies investigated the accuracy of conventional versus digital periapical radiographs in detecting external root resorption. They found no significant differences in the accurate detection of root resorption for both types of techniques, independent of the sensor used (Kamburoglu et al. 2008; Mesgarani et al. 2014; Vasconcelos et al. 2017). Digital reconstruction and digital subtraction radiography were introduced in order to overcome the problems of comparison of conventional radiographs. Digital reconstruction is a reliable method of correcting for different projection angles, which allows for the comparison of serial dental radiographs (Reukers et al. 1998). Digital subtraction radiography was found to be significantly superior to conventional radiography. Furthermore, it was able to quantify apical root resorption defects and was therefore used in longitudinal studies (Kravitz et al. 1992; Kreich et al. 2016).

By comparing the near-end treatment OPT findings with those obtained with CBCT, we found that 69 % of the teeth showed apical root resorption, while only 44 % showed apical root resorption on OPT. Since root resorption is a 3D phenomenon, CBCT OPT and apical radiographs were formerly the only means to diagnose root resorption, despite important limitations. One limitation of the OPT method is that incisor proclination during treatment might move the apex out of focal plane and provide a false appearance of root shortening (Armstrong et al. 2006). Other limitations are that a change of angulation might appear as a change in tooth length (Apalajathi et al. 2007), and most importantly OPT images lack reproducibility (Rollin et al. 1991).

Cone-beam CT

At the time when we designed and performed the study, cone-beam computed tomography (CBCT) was a rather new radiographic method, applied in different areas of dentistry as a diagnostic means for implant treatment, oral surgery, and temporomandibular joint imaging (Ziegler et al. 2002; Danfort 2003; Lascala et al. 2004). The great advantage of this technology was that it provided clear 3D images of dental and surrounding structures such as bone (Sukovic 2003). The important advantages of the CBCT technology compared with conventional computed tomography CT, were minimized radiation dose, image accuracy, rapid scan time, fewer image artifacts, and real-time analysis (Scarfe et al. 2006). At that time, CBCT

Discussion

imaging in orthodontics was restricted to impacted teeth, temporomandibular joint visualization, and cleft patients (Hohlberg et al. 2005; Müssig et al. 2005; Liu et al. 2008). The first authors using CBCT for resorption focused on often artificially induced post-traumatic inflammatory root resorption (Alqerban et al. 2009; Liedke et al. 2009; Kamburoglu et al. 2008). A case report was found using CBCT as a diagnostic tool to manage external cervical root resorption (Patel et al. 2007).

At the time we performed our investigation, there were only a very few studies on CBCT and orthodontically induced apical root resorption.

There are many new publications using CBCT for detecting orthodontically induced root resorption. Makedonas and coworkers (2012) followed patients undergoing an orthodontic treatment with fixed appliance by taking CBCT scans after 6 months and at the end of treatment. They found using a modified Malmgren index clinically significant resorption (severe root resorption, > 2 mm) in 25.6 % of the patients at the end of treatment. Since no correlation with resorption was seen after 6 months, the conclusion was that radiographic examination after 3 to 6 months of orthodontic treatment might be too early (Makedonas et al. 2012; 2013). Another prospective study found a high prevalence of some degree of root shortening (91 % of all teeth in 152 patients), but only a few patients showed severe root shortening of more than 4 mm. They concluded that the CBCT technique can provide valid and accurate information about root resorption, especially since only a tomographic technique is able to evaluate slanted root resorption (Lund et al. 2012). In a recent systematic review evaluating orthodontically induced root resorption using CBCT, an overall root loss of 0.8 mm after orthodontic treatment was calculated (Samandara et al. 2018). In a Japanese study including 30 adult patients who underwent four bicuspid extraction treatments, a mean apical root resorption of 1.8 mm was found when diagnoses were carried out with CBCT (Nakada et al. 2016). In a systematic review, the diagnostic accuracy of CBCT was validated against periapical radiographs (PA). The pooled results showed that CBCT had a significantly higher sensitivity (0.89) than PA (0.68) (Yi et al. 2017). A recent study comparing CBCT and periapical radiographs PA using micro-CT as a gold standard, found higher sensitivities and specificities of the two radiographic methods (0.97 vs. 0.78 and 0.97 vs. 0.59). They concluded that CBCT imaging was the best method for the detection of external root resorption (Deliga Schröder et al. 2018). Alamadi et al. compared root resorption diagnosed using CBCT imaging for milk canines that were later extracted with root resorption assessed using conventional radiographs (OPT, PA) using histology as gold standard. They confirmed our result and found that low levels of resorption were accurately assessed only with CBCT and that

PA and OPT underestimated root resorption (Alamadi et al. 2017). The influence of the scan mode was tested on 100 extracted teeth. It has been shown that a high-resolution scan must be acquired when early stages of external root resorption during orthodontic treatment are investigated. The authors remark that not all orthodontic patients should be subjected to high-dose CBCT scans (Sousa Melo et al. 2017). Finally, the accuracy of volumetric measurements on CBCT scans was investigated. They found that they were able to measure rather large resorption cavities larger than 3.47mm^3 and that the method was not accurate enough for small resorption cavities (Wang et al. 2013). This method shows potential and needs to be further studied and developed. In a different study on extracted teeth volumetric measurements on CBCT images, taken with low vs. high resolution, were validated against micro-CT scans. They concluded that high-resolution scans lead to more accurate volumetric quantifications; in this set-up the effect of patient movement during exposure was not considered (Ponder et al. 2013).

CONCLUSION

Younger patients showed greater tooth movement velocity than older patients. A wide range of tooth displacement revealed slow and fast movers. A part of this variation was attributed to the location of the teeth in the mandible or maxilla. An intra- or interarch obstacle decreased the amount of tooth displacement. At the individual level, the rate of tooth movement was highly correlated within the same subject.

Application of 1N over 8 weeks may provoke severe root resorption that is underestimated by conventional radiologic methods. A comparison of the radiographic and micro-CT scanner method shows the limited accuracy of periapical radiographs in detecting apical root resorption. OPT underestimates apical root resorption during orthodontic treatment, while CBCT might be a useful complementary diagnostic method to conventional radiography in certain situations.

A large variation in the amount of cervical root resorption was identified between individuals. A part of this variation was attributed to the location of the teeth in the mandible or maxilla. At the individual level, the amount of root resorption was moderately correlated within the same subject. The amount of root resorption was related to the amount of tooth movement.

FUTURE PERSPECTIVES

For the clinician it is not possible, at present, to predict the risk of development of root resorption with confidence. Neither is it feasible to prevent or reduce its occurrence or even to reverse the volume loss of tooth structure during orthodontic treatment. Especially for patients where severe root resorption occurs during orthodontic treatment, a better understanding of the physiopathologic mechanism would be of great help.

Various studies showed changes in cytokines in the GCF are associated with OTM (Uematsu et al. 1996; Giannopoulou et al. 2006). Observing marker levels changes in the GCF, during OTM it has been shown that the OPG expression levels decreased, while RANKL and RUNX2 increased (Yamaguchi 2009). Similarly, the ratios of two cytokines measured in the GCF can account for 60 % of the variance shown in the velocity of tooth movement. The cytokines measured were interleukin-1, (IL-1), a pro-inflammatory agent involved in many processes including bone resorption, and its naturally occurring competitive antagonist, interleukin-1 receptor antagonist (IL-1RA). Higher IL-1 β /IL-1RA ratios were measured at experimental relative to control sites (Iwasaki et al. 2004).

New methods in the field of molecular biology made it possible to identify genes that control the cellular and extracellular matrix components associated with orthodontic tooth movement. Iwasaki et al. (2006) measured the genotypes of their subjects, and observed that specific interleukin-1 gene cluster polymorphisms were associated with faster tooth movement. Genetic variations between individuals can be the underlying reason for the observation of the inter-individual variation.

Recent research applying molecular biology methods has supplied evidence to support the hypothesis that apart from mechanical factors, patient susceptibility to root resorption is genetically influenced (Al-Qawasmi et al. 2006; Bastos Lages 2009). Only a very few studies exist on the association between blood, saliva or GCF components' level and root resorption during orthodontic tooth movement. In a retrospective case-controlled study markers in blood and saliva were collected. Patients with moderate to severe root resorption showed a significant increase of salivary cytokines such as Interleukin (IL)-7, IL-10, IL-12p70 and interferon-gamma (IFN- γ) levels, as well as a significant decrease of IL-4. The researchers concluded the collection of markers in the saliva might be a more useful way of measuring cytokine expression changes than markers in the blood (Yashin et al. 2017).

Future perspectives

In a pilot study looking at marker changes in the gingival crevicular fluid (GCF) high levels of granulocyte macrophage colony-stimulating factors were detected in mild root resorption cases (Ahuja et al. 2017). GCF marker level changes during experimental tooth movement in correlation to the amount of root resorption require further investigation.

Further research in this field, combining experimental studies with standardized tooth movement and the collection of saliva or GCF components, may help to elucidate if one or a combination of factors may (1) identify patients at risk for extensive root resorption during orthodontic treatment and (2) detect root resorption before radiographic observation, and (3) avoid the use of radiography as a method for diagnostic screening for the presence of root resorption.

ACKNOWLEDGEMENT

This thesis would not have been possible without the support of many people to whom I wish to extend my deepest appreciation. They have all helped me, each in their own individual way, throughout this journey.

I owe immense gratitude to all the members of my research group. First to my mentor and main supervisor, Professor *Stavros Kiliaridis* (Department of Orthodontics, School of Dental Medicine, University of Geneva), who honored me with his unfailing trust and insightful supervision. He has generously provided ideas, advice and critical comments that lay at the origin of this research project, and he has guided its realization with endless enthusiasm. Furthermore, I would like to thank the leading organizer of our research group *Catherine Giannopoulou* (Department of Periodontology, School of Dental Medicine, University of Geneva), who always believed in me and supported me during this entire period. Her positive attitude and great enthusiasm made every minute of this collaboration enjoyable. I remain greatly indebted to both and feel honored to share their friendship.

Associate Professor Dr. *Ken Hansen* (Head of Clinic, Specialists Clinic for Orthodontics, University of Gothenburg) my second supervisor, whose support, motivation and guidance, also made this thesis possible. I am especially thankful for his big help with the manuscript and the translation of the abstract.

This work has benefited from the collaboration of Professor *Xavier Montet*, (Department of Radiology and Medical Informatics, Medical Faculty, University of Geneva) who shared valuable ideas and offered expert help in the reconstruction and analysis of the micro-CT images.

Sincere thanks go to Dr. *Michael Leuzinger* (Private Practice, Winterthur, Switzerland) who has contributed to the third investigation presented in this thesis.

Dr. *Anna Ödman*, whose immense help and practical advise made it possible to shoulder the burden of this long academic journey. I feel lucky to have been able to count on such a serious colleague and dear friend.

A special word of thanks also goes to all faculty members of the Division of Orthodontics for their precious help in the recruitment of patients.

REFERENCES

- Acar, A., Canyurek, U., Kocaaga, M. & Erverdi, N. (1999) Continuous vs. discontinuous force application and root resorption. *Angle Orthod*, 69, 159–64.
- Aghili, H. A., Hoseini, S. M., Yassaei, S., Fatahi Meybodi, S. A., Zaeim, M. H. & Moghadam, M. G. (2014) Effects of carbonated soft drink consumption on orthodontic tooth movements in rats. *J Dent (Tehran)*, 11, 123-30.
- Alamadi, E., Alhazmi, H., Hansen, K., Lundgren, T. & Naoumova, J. A comparative study of cone beam computed tomography and conventional radiography in diagnosing the extent of root resorptions. *Prog Orthod*, 18, 37.
- Alfaqeeh, S. A. & Anil, S. (2011) Osteocalcin and N-telopeptides of type I collagen marker levels in gingival crevicular fluid during different stages of orthodontic tooth movement. *Am J Orthod Dentofacial Orthop*, 139, e553-9.
- Alfawal, A. M., Hajeer, M. Y., Ajaj, M. A., Hamadah, O. & Brad, B. (2016) Effectiveness of minimally invasive surgical procedures in the acceleration of tooth movement: a systematic review and meta-analysis. *Prog Orthod*, 17, 33.
- Al-Qawasmi, R. A., Hartsfield, J. K. Jr., Everett, E. T., Flury, L., Liu, L., Foroud, T. M., Macri, J. V. & Roberts, W. E. (2003) Genetic predisposition to external apical root resorption. *Am J Orthod Dentofacial Orthop*, 123, 242-52.
- Al-Qawasmi, R. A., Hartsfield, J. K. Jr, Everett, E. T., Weaver, M. R., Foroud, T. M., Faust, D. M. & Roberts, W. E. (2006) Root resorption associated with orthodontic force in inbred mice: genetic contributions. *Eur J Orthod*, 28, 13-9.
- Alqerban, A., Jacobs, R., Souza, P. C. & Willems, G. (2009) In-vitro comparison of 2 cone-beam computed tomography systems and panoramic imaging for detecting simulated canine impaction-induced external root resorption in maxillary lateral incisors. *Am J Orthod Dentofacial Orthop*, 136, 764-5.
- American Association of Orthodontists. (2010) Statement on the role of CBCT in orthodontics (26-10H). eBulletin; May 7, 2010. Available at: www.aaomembers.org/Resources/Publications/ebulletin-05-06-10.cfm.
- Andrade, I. Jr., Taddei, S. R., Garlet, G. P., Garlet, T. P., Teixeira, A. L., Silva, T. A. & Teixeira, M. M. (2009) CCR5 down-regulates osteoclast function in orthodontic tooth movement. *J Dent Res*, 88, 1037-41.

References

- Andreasen, F. M., Sewerin, I., Mandel, U. & Andreasen, J. O. (1987) Radiographic assessment of simulated root resorption cavities. *Endod Dent Traumatol*, 3, 21-7.
- Apajalahti, S. & Peltola, J. S. (2007) Apical root resorption after treatment - a retrospective study. *Eur J Orthod*, 29, 408-12.
- Arita, K., Hotokezaka, H., Hashimoto, M., Nakano-Tajima, T., Kurohama, T., Kondo, T., Darendeliler, M. A. & Yoshida, N. (2016) Effects of diabetes on tooth movement and root resorption after orthodontic force application in rats. *Orthod Craniofac Res*, 19, 83-92.
- Armstrong, D., Kharbanda, O. P., Petocz, P. & Darendeliler, M. A. (2006) Root resorption after orthodontic treatment. *Aust Orthod J*, 22, 153-60.
- Ashizawa, Y. & Sahara N. (1998) Quantitative evaluation of newly formed bone in the alveolar wall surrounding the root during the initial stage of experimental tooth movement in the rat. *Arch Oral Biol*, 43, 473-84.
- Asiry, M. (2018) Biological aspects of orthodontic tooth movement: A review of literature. *Saudi Journal of Biological Sciences*, in press.
- Barbagallo, L. J., Jones, A. S., Petocz, P. & Darendeliler M. A. (2008) Physical properties of root cementum: Part 10. Comparison of the effects of invisible removable thermoplastic appliances with light and heavy orthodontic forces on premolar cementum. A microcomputed-tomography study. *Am J Orthod Dentofacial Orthop*, 133, 218-27.
- Bartzela, T., Türp, J. C., Motschall, E. & Maltha, J. C. (2009) Medication effects on the rate of orthodontic tooth movement: a systematic literature review. *Am J Orthod Dentofacial Orthop*, 135, 16-26.
- Bastos Lages, E. M., Drummond, A. F., Pretti, H., Costa, F. O., Lages, E. J., Gontijo, A. I., Miranda Cota, L. O. & Brito, R. B. Jr. (2009) Association of functional gene polymorphism IL-1beta in patients with external apical root resorption. *Am J Orthod Dentofacial Orthop*, 136, 542-6.
- Baumrind, S., Korn, E. L. & Boyd, R. L. (1996) Apical root resorption in orthodontically treated adults. *Am J Orthod Dentofacial Orthop*, 110, 311-20.
- Bosshardt, D. D. (2005) Are cementoblasts a subpopulation of osteoblasts or a unique phenotype? *J Dent Res*, 84, 390-406.
- Brezniak, N. & Wasserstein, A. (1993) Root resorption after orthodontic treatment: Part 1. Literature review. *Am J Orthod Dentofacial Orthop*, 103, 62-6.
- Brezniak, N. & Wasserstein, A. (1993) Root resorption after orthodontic treatment: Part 2. Literature review. *Am J Orthod Dentofacial Orthop*, 103, 138-46.

- Brudvik, P. & Rygh, P. (1993) The initial phase of orthodontic root resorption incident to local compression of the periodontal ligament. *Eur J Orthod*, 15, 249-63.
- Burstone, C. J. (1962) The biomechanics of tooth movement. Kraus, B. S. & Riedel, R. A. (Eds.), *Vistas in Orthodontics*, Lea and Febiger, Philadelphia.
- Cakmak, F., Turk, T., Karadeniz, E. I., Elekdag-Turk, S. & Darendeliler, M. A. (2014) Physical properties of root cementum: part 24. Root resorption of the first premolars after 4 weeks of occlusal trauma. *Am J Orthod Dentofacial Orthop*, 145, 617-25.
- Cantarella, G., Cantarella, R., Caltabiano, M., Risuglia, N., Bernardini, R. & Leonardi, R. (2006) Levels of matrix metalloproteinases 1 and 2 in human gingival crevicular fluid during initial tooth movement. *Am J Orthod Dentofacial Orthop*, 130, 568.e11-6.
- Chan, E. K., Darendeliler, M. A., Petocz, P. & Jones, A. S. (2004) A new method for volumetric measurement of orthodontically induced root resorption craters. *Eur J Oral Sci*, 112, 134-9.
- Chan, E. K. & Darendeliler, M. A. (2004) Exploring the third dimension in root resorption. *Orthod Craniofac Res*, 7, 64-70.
- Chan, E. & Darendeliler, M. A. (2005) Physical properties of root cementum: Part 5. Volumetric analysis of root resorption craters after application of light and heavy orthodontic forces. *Am J Orthod Dentofacial Orthop*, 127, 186-95.
- Chan, E. & Darendeliler, M. A. (2006) Physical properties of root cementum: part 7. Extent of root resorption under areas of compression and tension. *Am J Orthod Dentofacial Orthop*, 129, 504-10.
- Chan, E., Dalci, O., Petocz, P., Papadopoulou, A. K. & Darendeliler, M. A. (2018) Physical properties of root cementum: Part 26. Effects of microosteoperforations on orthodontic root resorption: A microcomputed tomography study. *Am J Orthod Dentofacial Orthop*, 153, 204-213.
- Chapnick, L. (1989) External root resorption: an experimental radiographic evaluation. *Oral Surg Oral Med Oral Pathol*, 67, 578-82.
- Chappard, C., Peyrin, F., Bonnassie, A., Lemineur, G., Brunet-Imbault, B., Lespessailles, E. & Benhamou, C. L. (2006) Subchondral bone microarchitectural alterations in osteoarthritis: a synchrotron micro-computed tomography study. *Osteoarthr Cartil*, 14, 215-23.

References

- Choy, K., Pae, E. K., Park, Y., Kim, K. H. & Burstone, C. J. (2000) Effect of root and bone morphology on the stress distribution in the periodontal ligament. *Am J Orthod Dentofacial Orthop*, 117, 98-105.
- Chugh, T., Jain, A. K., Jaiswal, R. K., Mehrotra, P. & Mehrotra, R. (2013) Bone density and its importance in orthodontics. *Journal of Oral Biology and Craniofacial Research*, 3, 92–7.
- Copeland, S. & Green, L. J. (1986) Root resorption in maxillary central incisors following active orthodontic treatment. *Am J Orthod Dentofacial Orthop*, 89, 51-5.
- Danforth, R. A. (2003) Cone beam volume tomography: a new digital imaging option for dentistry. *J Calif Dent Assoc*, 31, 814-5.
- De Araujo, C. M., Johann, A. C., Camargo, E. S. & Tanaka, O. M. (2014) The effects of binge-pattern alcohol consumption on orthodontic tooth movement. *Dental Press J Orthod*, 19, 93-8.
- Deguchi, T., Takano-Yamamoto, T., Yabuuchi, T., Ando, R., Roberts, W. E. & Garetto, L. P. (2008) Histomorphometric evaluation of alveolar bone turnover between the maxilla and the mandible during experimental tooth movement in dogs. *Am J Orthod Dentofacial Orthop*, 133, 889-97.
- Deliga Schröder, A. G., Westphalen, F. H., Schröder, J. C., Fernandes, A. & Westphalen, V. P. D. (2018) Accuracy of Digital Periapical Radiography and Cone-beam Computed Tomography for Diagnosis of Natural and Simulated External Root Resorption. *J Endod*, 44, 1151-8.
- Devlin, H., Horner, K. & Ledgerton, D. (1998) A comparison of maxillary and mandibular bone mineral densities. *The Journal of Prosthetic Dentistry*, 79, 323-7.
- Ericson, S. & Kurol P. J. (2000) Resorption of incisors after ectopic eruption of maxillary canines: a CT study. *Angle Orthod*, 70, 415-23.
- Eross, E., Turk, T., Elekdag-Turk, S., Cakmak, F., Jones, A. S., Végh, A., Papadopoulou, A. K. & Darendeliler, M. A. (2015) Physical properties of root cementum: Part 25. Extent of root resorption after the application of light and heavy buccopalatal jiggling forces for 12 weeks: A microcomputed tomography study. *Am J Orthod Dentofacial Orthop*, 147, 738-46.
- Feller, L., Khammissa, R. A., Thomadakis, G., Fourie, J. & Lemmer, J. (2016) Apical External Root Resorption and Repair in Orthodontic Tooth Movement: Biological Events. *Biomed Res Int*, 4864195, doi: 10.1155/2016/4864195.

References

- Foo, M., Jones, A. & Darendeliler, M. A. (2007) Physical properties of root cementum: part 9. Effect of systemic fluoride intake on root resorption in rats. *Am J Orthod Dentofacial Orthop*, 131, 34-43.
- Ghajar, K., Olyaei, P., Mirzakouchaki, B., Ghahremani, L., Garjani, A., Dadgar, E. & Marjani, S. (2013) The effect of pregnancy on orthodontic tooth movement in rats. *Med Oral Patol Oral Cir Bucal*, 18, e351-5.
- Giannopoulou, C., Dudic, A. & Kiliaridis, S. (2006) Pain discomfort and crevicular fluid changes induced by orthodontic elastic separators in children. *J Pain*, 7, 367-76.
- Giannopoulou, C., Dudic, A., Montet, X., Kiliaridis, S. & Mombelli, A. (2008) Periodontal parameters and cervical root resorption during orthodontic tooth movement. *J Clin Periodontol*, 35, 501-6.
- Guan, L., Lin, S., Yan, W., Chen, L. & Wang, X. (2017) Effects of calcitonin on orthodontic tooth movement and associated root resorption in rats. *Acta Odontol Scand*, 75, 595-602.
- Guldberg, R. E., Lin, A. S., Coleman, R., Robertson, G. & Duvall, C. (2004) Microcomputed tomography imaging of skeletal development and growth. *Birth Defects Res C Embryo Today*, 72, 250-9.
- Halazonetis, D. J. (2012) Cone-beam computed tomography is not the imaging technique of choice for comprehensive orthodontic assessment. *Am J Orthod Dentofacial Orthop*, 141, 403-7.
- Harris, E. F., Kineret, S. E. & Tolley, E. A. (1997) A heritable component for external apical root resorption in patients treated orthodontically. *Am J Orthod Dentofacial Orthop*, 111, 301-9.
- Harris, D., Jones, A. S. & Darendeliler, M. A. (2006) Physical properties of root cementum: part 8. Volumetric analysis of root resorption craters after application of controlled intrusive light and heavy orthodontic forces: a micro-CT Scan study. *Am J Orthod Dentofacial Orthop*, 130, 639-47.
- Harry, M. R. & Sims, M. R. (1982) Root resorptions in bicuspid intrusion. A scanning electron microscope study. *Angle Orthod*, 52, 235-58.
- Hartsfield, J. K. Jr., Everett, E. T. & Al-Qawasmi, R. A. (2004) Genetic factors in external apical root resorption and orthodontic treatment. *Crit Rev Oral Biol Med*, 15, 115-122.
- Heimisdottir, K., Bosshardt, D. & Ruf, S. (2005) Can the severity of root resorption be accurately judged by means of radiographs? A case report with histology. *Am J Orthod Dentofacial Orthop*, 128, 106-9.

References

- Henneman, S., Von den Hoff, J. W., Maltha, J. C. (2008) Mechanobiology of tooth movement. *Eur J Orthod*, 30, 299-306.
- Holberg, C., Steinhäuser, S., Geis, P. & Rudzki-Janson, I. (2005) Cone-beam computed tomography in orthodontics: benefits and limitations. *J Orofac Orthop*, 66, 434-44.
- Houston, W. J. (1983) The analysis of errors in orthodontic measurements. *Am J Orthod Dentofacial Orthop*, 83, 382-90.
- Iglesias-Linares, A., Sonnenberg, B., Solano, B., Yañez-Vico, R. M., Solano, E., Lindauer, S. J. & Flores-Mir, C. (2017) Orthodontically induced external apical root resorption in patients treated with fixed appliances vs removable aligners. *Angle Orthod*, 87, 3-10.
- Iwasaki, L. R., Crouch, L. D., Reinhardt, R. A. & Nickel, J. C. (2004) The velocity of human orthodontic tooth movement is related to stress magnitude, growth status, and the ratio of cytokines in gingival crevicular fluid. In *Biological Mechanisms of Tooth Movement and Craniofacial Adaptation*. Davidovitch Z and Mah J (eds). Boston, Harvard Society for the Advancement of Orthodontics, 133-43.
- Iwasaki, L. R., Gibson, C. S., Crouch, L. D., Marx, D. B., Pandey, J. P. & Nickel, J. C. (2006) Speed of tooth movement is related to stress and IL-1 gene polymorphisms. *Am J Orthod Dentofacial Orthop*, 130, 698.e1-9.
- Jönsson, A., Malmgren, O. & Levander, E. (2007) Long-term follow-up of tooth mobility in maxillary incisors with orthodontically induced apical root resorption. *Eur J Orthod*, 29, 482-7.
- Kalia, S., Melsen, B. & Verna, C. (2004) Tissue reaction to orthodontic tooth movement in acute and chronic corticosteroid treatment. *Orthod Craniofac Res*, 7, 26-34.
- Kamburoğlu, K., Tsesis, I., Kfir, A. & Kaffe, I. (2008) Diagnosis of artificially induced external root resorption using conventional intraoral film radiography, CCD, and PSP: an ex vivo study. *Oral Surg Oral Med Oral Pathol Oral Radiol Endod*, 106, 885-91.
- Kashyap, S. (2016) Current concepts in the biology of orthodontic tooth movement: a brief overview. *NJDSR*, 1, 28-31.
- Kawasaki, K., Takahashi, T., Yamaguchi, M. & Kasai, K. (2006) Effects of aging on RANKL and OPG levels in gingival crevicular fluid during orthodontic tooth movement. *Orthod Craniofac Res*, 9, 137-42.

-
- Killiany, D. M. (1999) Root resorption caused by orthodontic treatment: an evidence-based review of literature. *Semin Orthod*, 5, 128-33.
- King, G. J., Archer, L. & Zhou, D. (1998) Later orthodontic appliance reactivation stimulates immediate appearance of osteoclasts and linear tooth movement. *Am J Orthod Dentofacial Orthop*, 114, 692-7.
- Krishnan, V. & Davidovitch, Z. (2006) Cellular, molecular and tissue-level reactions to orthodontic force. *Am J Orthod Dentofacial Orthop*, 129, 469e1-32.
- Lascala, C. A., Panelly, J. & Marques, M. M. (2004) Analysis of the accuracy of linear measurements obtained by cone beam computed tomography (CBCT-NewTom). *Dentomaxillofac Radiol*, 33, 291-4.
- Lekic, P. & McCulloch, C. A. (1996) Periodontal ligament cell population: the central role of fibroblasts in creating a unique tissue. *Anat Rec*, 245, 327-41.
- Leuzinger, M., Dudic, A., Giannopoulou, C. & Kiliaridis, S. (2010) Root-contact evaluation by panoramic radiography and cone-beam computed tomography of super-high resolution. *Am J Orthod Dentofacial Orthop*, 137, 389-92.
- Levander, E. & Malmgren, O. (1988) Evaluation of the risk of root resorption during orthodontic treatment: a study of upper incisors. *Eur J Orthod*, 10, 30-8.
- Levander, E. & Malmgren, O. (2000) Long-term follow-up of maxillary incisors with severe apical root resorption. *Eur J Orthod*, 22, 85-92.
- Levander, E., Malmgren, O. & Eliasson, S. (1994) Evaluation of root resorption in relation to two orthodontic treatment regimes. A clinical experimental study. *Eur J Orthod*, 16, 223-8.
- Levander, E., Bajka, R. & Malmgren, O. (1998) Early radiographic diagnosis of apical root resorption during orthodontic treatment: a study of maxillary incisors. *Eur J Orthod*, 20, 57-63.
- Li, F., Li, G., Hu, H., Liu, R., Chen, J. & Zou, S. (2013) Effect of parathyroid hormone on experimental tooth movement in rats. *Am J Orthod Dentofacial Orthop*, 144, 523-32.
- Li, J., Wang, X., Li, N., Zhenga, D., Su, Y. & Zhang, J. (2016) Short-term effects of nicotine on orthodontically induced root resorption in rats. *Angle Orthod*, 86, 199-205.
- Liedke G. S., da Silveira H. E., da Silveira, H. L., Dutra, V. & de Figueiredo J. A. (2009) Influence of voxel size in the diagnostic ability of cone beam tomography to evaluate simulated external root resorption. *J Endod*, 35, 233-5.

References

- Lindskog, S., Blomlöf, L. & Hammarstrom, L. (1987) Cellular colonization of denuded root surfaces in vivo: cell morphology in dentin resorption and cementum repair. *J Clin Periodontol*, 14, 390-5.
- Liu, L., Igarashi, K., Haruyama, N., Saeki, S., Shinoda, H. & Mitani, H. (2004) Effects of local administration of clodronate on orthodontic tooth movement and root resorption in rats. *Eur J Orthod*, 26, 469-73.
- Liu, D. G., Zhang, W. L., Zhang, Z. Y., Wu, Y. T. & Ma, X. C. (2008) Localization of impacted maxillary canines and observation of adjacent incisor resorption with cone-beam computed tomography. *Oral Surg Oral Med Oral Pathol Oral Radiol Endod*, 105, 91-8.
- Long, A., Loescher, A. R. & Robinson, P. P. (1996) A histological study on the effect of different periods of orthodontic force on the innervation and dimensions of cat periodontal ligament. *Arch Oral Biol*, 41, 799-808.
- Lund, H., Gröndahl, K., Hansen, K. & Gröndahl, H. G. (2012) Apical root resorption during orthodontic treatment. A prospective study using cone beam CT. *Angle Orthod*, 82, 480-7.
- Lundgren, D., Owman-Moll, P. & Kurol, J. (1996) Early tooth movement pattern after application of a controlled continuous orthodontic force. A human experimental model. *Am J Orthod Dentofacial Orthop*, 110, 287-94.
- Makedonas, D., Lund, H., Gröndahl, K. & Hansen, K. (2012) Root resorption diagnosed with cone beam computed tomography after 6 months of orthodontic treatment with fixed appliance and the relation to risk factors. *Angle Orthod*, 82, 196-201.
- Makedonas, D., Lund, H. & Hansen, K. (2013) Root resorption diagnosed with cone beam computed tomography after 6 months and at the end of orthodontic treatment with fixed appliances. *Angle Orthod*, 83, 389-93.
- McFadden, W. M., Engstrom, C., Engstrom, H. & Anholm, J. M. (1989) A study of the relationship between incisor intrusion and root shortening. *Am J Orthod Dentofacial Orthop*, 96, 390-6.
- Meikle, M. C. (2006) The tissue, cellular, and molecular regulation of orthodontic tooth movement: 100 years after Carl Sandstedt. *Eur J Orthod*, 28, 221-40.
- Melsen, B. (1999) Biological reaction of alveolar bone to orthodontic tooth movement, *Angle Orthod*, 69, 151-8.
- Mesgarani, A., Haghanifar, S., Ehsani, M., Yaghub, S. D. & Bijani, A. (2014) Accuracy of conventional and digital radiography in detecting external root resorption. *Iran Endod J*, 9, 241-5.

- Mirabella, A. D. & Artun, J. (1995) Prevalence and severity of apical root resorption of maxillary anterior teeth in adult orthodontic patients. *Eur J Orthod*, 17, 93-9.
- Misawa-Kageyama, Y., Kageyama, T., Moriyama, K., Kurihara, S., Yagasaki, H., Deguchi, T., Ozawa, H. & Sahara, N. (2007) Histomorphometric study on the effects of age on orthodontic tooth movement and alveolar bone turnover in rats. *Eur J Oral Sci*, 115, 124-30.
- Moura, A. P., Taddei, S. R., Queiroz-Junior, C. M., Madeira, M. F., Rodrigues, L. F., Garlet, G. P., Souza, D. G., Machado, F. S., Andrade, I. Jr., Teixeira, M. M. & Silva, T. A. (2014) The relevance of leukotrienes for bone resorption induced by mechanical loading. *Bone*, 69, 133-8.
- Müssig, E., Wörtche, R. & Lux, C. J. (2005) Indications for digital volume tomography in orthodontics. *J Orofac Orthop*, 66, 241-9.
- Nagaie, M., Nishiura, A., Honda, Y., Fujiwara, S. & Matsumoto, N. (2014) A comprehensive mixture of tobacco smoke components retards orthodontic tooth movement via the inhibition of osteoclastogenesis in a rat model. *Int J Mol Sci*, 15, 18610-22.
- Nakada, T., Motoyoshi, M., Horinuki, E. & Shimizu, N. (2016) Cone-beam computed tomography evaluation of the association of cortical plate proximity and apical root resorption after orthodontic treatment. *J Oral Sci*, 58, 231-6.
- Kamburoğlu, K., Tsesis, I., Kfir, A. & Kaffe, I. (2008) Diagnosis of artificially induced external root resorption using conventional intraoral film radiography, CCD, and PSP: an ex vivo study. *Oral Surg Oral Med Oral Pathol Oral Radiol Endod*, 106, 885-91.
- Kanzaki, H., Chiba, M., Shimizu, Y. & Mitani, H. (2002) Periodontal ligament cells under mechanical stress induce osteoclastogenesis by receptor activator of nuclear factor kappaB ligand up-regulation via prostaglandin E2 synthesis. *J Bone Miner Res*, 17, 210-20.
- Karakida, L. M., Araujo, C. M., Johann, A. C. B. R., Camargo, E. S., Tanaka, O. M. & Guariza, O.G. Filho. (2017) Interaction of Anabolic Androgenic Steroids and Induced Tooth Movement in Rats. *Braz Dent J*, 28, 504-510.
- Kashyap, S. (2016) Current concepts in the biology of orthodontic tooth movement: a brief overview *NJDSR*, 1, 28-31.
- Killiany, D. M. (1999) Root resorption caused by orthodontic treatment: an evidence-based review of literature. *Semin Orthod*, 5, 128-33.

References

- Kjaer, I. (1995) Morphological characteristics of dentitions developing excessive root resorption during orthodontic treatment. *Eur J Orthod*, 17, 25-34.
- Kobayashi, Y., Hashimoto, F., Miyamoto, H., Kanaoka, K., Miyazaki-Hawashita, Y. & Nakashima, T. (2000). Force-induced osteoclast apoptosis in vivo is accompanied by elevation in transforming growth factor beta and osteoprotegerin expression. *J Bone Miner Res* 15, 1924-34.
- Kohara, H., Kitaura, H., Yoshimatsu, M., Fujimura, Y., Morita, Y., Eguchi, T. & Yoshida, N. (2012) Inhibitory effect of interferon- γ on experimental tooth movement in mice. *J Interferon Cytokine Res*, 32, 426-31.
- Kouskoura, T., Katsaros, C. & von Gunten. S. (2017) The Potential Use of Pharmacological Agents to Modulate Orthodontic Tooth Movement (OTM). *Front Physiol*, 8, 1-9.
- Kravitz, L. H., Tyndall, D. A., Bagnell, C. P. & Dove, S. B. (1992) Assessment of external root resorption using digital subtraction radiography. *J Endod*, 18, 275-84.
- Kreich, E. M., Chibinski, A. C., Coelho, U., Wambier, L. S., Zedebski Rde, A., de Moraes, M. E., de Moraes & L. C. (2016) A posteriori registration and subtraction of periapical radiographs for the evaluation of external apical root resorption after orthodontic treatment. *Imaging Sci Dent*, 46, 17-24.
- Krishnan, V. & Davidovitch, Z. (2006) Cellular, molecular, and tissue-level reactions to orthodontic force. *Am J Orthod Dentofacial Orthop*, 129, 469.e1-32.
- Krishnan, V. & Davidovitch, Z. (2006) The effect of drugs on orthodontic tooth movement. *Orthod Craniofac Res*, 9, 163-71.
- Kurol, J., Owman-Moll, P. & Lundgren, D. (1996) Time-related root resorption after application of a controlled continuous orthodontic force. *Am J Orthod Dentofacial Orthop*, 110, 303-10.
- Kurol, J. & Owman-Moll, P. (1998) Hyalinization and root resorption during early orthodontic tooth movement in adolescents. *Angle Orthod*, 68, 161-5.
- Kyomen, S. & Tanne, K. (1997) Influences of aging changes in proliferative rate of PDL cells during experimental tooth movement in rats. *Angle Orthod*, 67, 67-72.
- Olyae, P., Mirzakouchaki, B., Ghajar, K., Seyyedi, S. A., Shalchi, M., Garjani, A. & Dadgar, E. (2013) The effect of oral contraceptives on orthodontic tooth movement in rat. *Med Oral Patol Oral Cir Bucal*, 18, e146-50.
- Owens, S. E., Buschang, P. H., Cope, J. B., Franco, P. F. & Rossouw, P. E. (2007) Experimental evaluation of tooth movement in the beagle dog with the mini-

-
- screw implant for orthodontic anchorage. *Am J Orthod Dentofacial Orthop*, 132, 639-46.
- Owman-Moll, P. (1995) Orthodontic tooth movement and root resorption with special reference to force magnitude and duration. A clinical and histological investigation in adolescents. *Swedish Dental Journal*, 105, 1-45.
- Owman-Moll, P., Kurol, J. & Lundgren, D. (1995) Continuous versus interrupted continuous orthodontic force related to early tooth movement and root resorption. *Angle Orthod*, 65, 395-402.
- Owman-Moll, P., Kurol, J. & Lundgren, D. (1996) The effects of a four-fold increased orthodontic force magnitude on tooth movement and root resorptions. An intra-individual study in adolescents. *Eur J Orthod*, 18, 287-94.
- Owman-Moll, P., Kurol, J. & Lundgren, D. (1996) Effects of a doubled orthodontic force magnitude on tooth movement and root resorptions. An inter-individual study in adolescents. *Eur J Orthod*, 18, 141-50.
- Owman-Moll, P. & Kurol, J. (1998) The early reparative process of orthodontically induced root resorption in adolescents-location and type of tissue. *Eur J Orthod*, 20, 727-32.
- Owman-Moll, P. & Kurol, J. (2000) Root resorption after orthodontic treatment in high- and low-risk patients: analysis of allergy as a possible predisposing factor. *Eur J Orthod*, 22, 657-63.
- Paetyangkul, A., Türk, T., Elekdağ-Türk, S., Jones, A. S., Petocz, P. & Darendeliler, M. A. (2009) Physical properties of root cementum: part 14. The amount of root resorption after force application for 12 weeks on maxillary and mandibular premolars: a microcomputed-tomography study. *Am J Orthod Dentofacial Orthop*, 136, 492.e1-492.e9.
- Parker, R. J. & Harris, E. F. (1998) Directions of orthodontic tooth movements associated with external apical root resorption of the maxillary central incisor. *Am J Orthod Dentofacial Orthop*, 114, 677-83.
- Park-Min, K. H., Ji, J. D., Antoniv, T., Reid, A. C., Silver, R. B., Humphrey, M. B., Nakamura, M. & Ivashkiv, L. B. (2009) IL-10 suppresses calcium-mediated costimulation of receptor activator NF-kappa B signaling during human osteoclast differentiation by inhibiting TREM-2 expression. *J Immunol*, 15, 183, 2444-55.
- Patel, S. & Dawood, A. (2007) The use of cone beam computed tomography in the management of external cervical resorption lesions. *Int Endod J*, 40, 730-7.

References

- Patterson, B. M., Dalci, O., Papadopoulou, A. K., Madukuri, S., Mahon, J., Petocz, P., Spahr, A. & Darendeliler, M. A. (2017) Effect of piezocision on root resorption associated with orthodontic force: A microcomputed tomography study. *Am J Orthod Dentofacial Orthop*, 151, 53-62.
- Peck, J. L., Sameshima, G. T., Miller, A., Worth, P. & Hatcher, D. C. (2007) Mesiodistal root angulation using panoramic and cone beam CT. *Angle Orthod*, 77, 206-13.
- Pilon, J. J., Kuijpers-Jagtman, A. M., Maltha, J. C. (1996) Magnitude of orthodontic forces and rate of bodily tooth movement. An experimental study. *Am J Orthod Dentofacial Orthop*, 110, 16-23.
- Poosti, M., Basafa, M. & Eslami, N. (2009) Progesterone effects on experimental tooth movement in rabbits. *J Calif Dent Assoc*, 37, 483-6.
- Poumpros, E., Loberg, E. & Engström, C. (1994) Thyroid function and root resorption. *Angle Orthod*, 64, 389-93.
- Ponder, S. N., Benavides, E., Kapila, S. & Hatch, N. E. (2013) Quantification of external root resorption by low- vs high-resolution cone-beam computed tomography and periapical radiography: A volumetric and linear analysis. *Am J Orthod Dentofacial Orthop*, 143, 77-91.
- Proffit, W. R. (2007) Biologic basis of orthodontic therapy. In: Proffit, W. R., Fields, H. W., Sarver, D. M. editors. *Contemporary Orthodontics*, 4th ed. Mosby, St. Louis, 331-58.
- Reitan, K. (1960) Tissue behavior during orthodontic tooth movement. *Am J Orthod Dentofacial Orthop*, 46, 881-90.
- Reitan, K. (1961) Behavior of Malassez' epithelial rests during orthodontic tooth movement. *Acta Odontol Scand*, 19, 443-68.
- Reitan, K. (1967) Clinical and histologic observations on tooth movement during and after orthodontic treatment. *Am J Orthod Dentofacial Orthop*, 53, 721-45.
- Reitan, K. (1985) Biomechanical principles and reactions. In Graber, T. M. & Swain, B. F. (eds.), *Orthodontics: Current Principles and Techniques*. Mosby, Saint Louis, 101-92.
- Remington, D. N., Joondeph, D. R., Artun, J., Riedel, R. A. & Chapko M. K. (1989) Long-term evaluation of root resorption occurring during orthodontic treatment. *Am J Orthod Dentofacial Orthop*, 96, 43-6.
- Ren, Y., Maltha, J. C. & Kuijpers-Jagtman, A. M. (2003) Optimum force magnitude for orthodontic tooth movement: a systematic literature review. *Angle Orthod*, 73, 86-92.

References

- Ren, Y., Maltha, J. C., Van't Hof, M. A. & Kuijpers-Jagtman, A. M. (2004) Optimum force magnitude for orthodontic tooth movement: a mathematic model. *Am J Orthod Dentofacial Orthop*, 125, 71-7.
- Ren, Y., Kuijpers-Jagtman, A. M. & Maltha, J. C. (2005) Immunohistochemical evaluation of osteoclast recruitment during experimental tooth movement in young and adult rats. *Arch Oral Biol*, 50, 1032-9.
- Ren, Y., Maltha, J. C., Stokroos, L., Liem, R. S. & Kuijpers-Jagtman A. M. (2008) Age-related changes of periodontal ligament surface areas during force application. *Angle Orthod*, 78, 1000-5.
- Reukers, E., Sanderink, G., Kuijpers-Jagtman, A. M. & van't Hof, M. (1998) Assessment of apical root resorption using digital reconstruction. *Dentomaxillofac Radiol*, 27, 25-9.
- Rohlin, M., Kullendorff, B., Ahlqwist, M. & Stenström, B. (1991) Observer performance in the assessment of periapical pathology: a comparison of panoramic with periapical radiography. *Dentomaxillofac Radiol*, 20, 127-31.
- Samandara, A., Papageorgiou, S. N., Ioannidou-Marathiotou, I., Kavvadia-Tsatata, S. & Papadopoulos, M. A. (2018) Evaluation of orthodontically induced external root resorption following orthodontic treatment using cone beam computed tomography (CBCT): a systematic review and meta-analysis. *Eur J Orthod*, May 15, doi: 10.1093/ejo/cjy027.
- Sameshima, G. T. & Asgarifar, K. O. (2001) Assessment of root resorption and root shape: periapical vs panoramic films. *Angle Orthod*, 71, 185-9.
- Sameshima, G. T. & Sinclair, P. M. (2001) Predicting and preventing root resorption: Part I. Diagnostic factors. *Am J Orthod Dentofacial Orthop*, 119, 505-10.
- Sameshima, G. T. & Sinclair, P. M. (2001) Predicting and preventing root resorption: Part II. Treatment factors. *Am J Orthod Dentofacial Orthop*, 119, 511-5.
- Scarfe, W. C., Farman, A. G. & Sukovic P. (2006) Clinical applications of conebeamcomputed tomography in dental practice. *J Can Dent Assoc*, 72, 75-80.
- Schwartz, A. M. (1932) Tissue changes incidental to tooth movement. *Int J Orthod*, 18, 331-52.
- Segal, G. R., Schiffman, P. H. & Tuncay, O. C. (2004) Meta analysis of the treatment-related factors of external apical root resorption. *Orthod Craniofac Res*, 7, 71-8.

References

- Seifi, M., Ezzati, B., Saedi, S. & Hedayati, M. (2015) The Effect of Ovariectomy and Orchiectomy on Orthodontic Tooth Movement and Root Resorption in Wistar Rats. *J Dent (Shiraz)*, 16, 302-9.
- Shirazi, M., Vaziri, H., Salari, B., Motahhari, P., Etemad-Moghadam, S. & Dehpour, A. R. (2017) The effect of caffeine on orthodontic tooth movement in rats. *Iran J Basic Med Sci*, 20, 260-64.
- Sidiropoulou-Chatzigiannis, S., Kourtidou, M. & Tsalikis, L. (2007) The effect of osteoporosis on periodontal status, alveolar bone and orthodontic tooth movement. A literature review. *J Int Acad Periodontol*, 9, 77-84.
- Silveira, H. L., Silveira, H. E., Liedke, G. S., Lermen, C. A., Dos Santos, R. B. & Figueiredo, J. A. (2007) Diagnostic ability of computed tomography to evaluate external root resorption in vitro. *Dentomaxillofac Radiol*, 36, 393-6.
- Sirisoontorn, I., Hotokezaka, H., Hashimoto, M., Gonzales, C., Luppapornlarp, S., Darendeliler, M. A. & Yoshida, N. (2011) Tooth movement and root resorption; the effect of ovariectomy on orthodontic force application in rats. *Angle Orthod*, 81, 570-7.
- Sismanidou, C., Hilliges, M. & Lindskog, S. (1996) Healing of the root surface-associated periodontium: an immunohistochemical study of orthodontic root resorption in man. *Eur J Orthod*, 18, 435-44.
- Sjolién, T. & Zachrisson, B. U. (1973) Periodontal bone support and tooth length in orthodontically treated and untreated persons. *Am J Orthod Dentofacial Orthop*, 64, 28-37.
- Smith, B. R., Park, J. H. & Cederberg, R. A. (2011) An evaluation of cone-beam computed tomography use in postgraduate orthodontic programs in the United States and Canada. *J Dent Educ*, 75, 98-106.
- Sousa Melo, S. L., Vasconcelos, K. F., Holton, N., Allareddy, V., Allareddy, V., Tabchoury, C. P. M., Haiter-Neto, F. & Ruprecht, A. (2017) Impact of cone-beam computed tomography scan mode on the diagnostic yield of chemically simulated external root resorption. *Am J Orthod Dentofacial Orthop*, 151, 1073-82.
- Stenvik, A. & Mjör, I. A. (1970) Pulp and dentin reactions to experimental tooth intrusion. A histologic study of the initial changes. *Am J Orthod Dentofacial Orthop*, 57, 370-85.
- Sukovic, P. (2003) Cone beam computed tomography in craniofacial imaging. *Orthod Craniofac Res*, 6, 31-6.

- Taddei, S. R., Queiroz-Junior, C. M., Moura, A. P., Andrade, I. Jr., Garlet, G. P., Proudfoot, A. E., Teixeira, M. M. & da Silva, T. A. (2013) The effect of CCL3 and CCR1 in bone remodeling induced by mechanical loading during orthodontic tooth movement in mice. *Bone*, 52, 259-67.
- Taithongchai, R., Sookkorn, K. & Killiany, D. M. (1996) Facial and dentoalveolar structure and the prediction of apical root shortening. *Am J Orthod Dentofacial Orthop*, 110, 296-302.
- Talic, N. F. (2011) Adverse effects of orthodontic treatment: A clinical perspective. *Saudi Dent J*, 23, 55-9.
- Taylor, N. G. & Jones A. G. (1995) Are anterior occlusal radiographs indicated to supplement panoramic radiography during an orthodontic assessment? *Br Dent*, 179, 377-81.
- Ten Cate, A. R. (1989) In: *Oral histology, development, structure and function*. St. Louis: CV Mosby, pp 111-1122, 259-83.
- Uematsu, S., Mogi, M. & Deguchi, T. (1996) Interleukin (IL)-1 beta, IL-6, tumor necrosis factor-alpha, epidermal growth factor, and beta 2-microglobulin levels are elevated in gingival crevicular fluid during human orthodontic tooth movement. *J Dent Res*, 75, 562-7.
- Van Leeuwen, E. J., Maltha, J. C. & Kuijpers-Jagtman, A. M. (1999) Tooth movement with light continuous and discontinuous forces in beagle dogs. *Eur J Oral Sci*, 107, 468-74.
- Van Leeuwen, E. J., Kuijpers-Jagtman, A. M., Von den Hoff, J. W., Wagener, F. A. & Maltha, J. C. (2010) Rate of orthodontic tooth movement after changing the force magnitude: an experimental study in beagle dogs. *Orthod Craniofac Res*, 13, 238-45.
- Vasconcelos, K. F., Rovaris, K., Nascimento, E. H. L., Oliveira, M. L., Távora, D. M. & Bóscolo, F. N. (2017) Diagnostic accuracy of phosphor plate systems and conventional radiography in the detection of simulated internal root resorption. *Acta Odontol Scand*, 75, 573-6.
- Verna, C., Melsen, B. & Melsen, F. (1999) Differences in static cortical bone remodeling parameters in human mandible and iliac crest. *Bone*, 25, 577-83.
- Villa, P. A., Oberti, G., Moncada, C. A., Vasseur, O., Jaramillo, A., Tobón, D. & Agudelo, J. A. Pulp-dentine complex changes and root resorption during intrusive orthodontic tooth movement in patients prescribed nabumetone. *J Endod*, 31, 61-6.

References

- Von Böhl, M., Maltha, J. C., Von den Hoff, J. W. & Kuijpers-Jagtman, A. M. (2004) Focal hyalinization during experimental tooth movement in beagle dogs. *Am J Orthod Dentofacial Orthop*, 125, 615-23.
- Von Böhl, M., Maltha, J., Von den Hoff, H. & Kuijpers-Jagtman, A. M. (2004) Changes in the periodontal ligament after experimental tooth movement using high and low continuous forces in beagle dogs. *Angle Orthod*, 74, 16-25.
- Walker, L., Enciso, R. & Mah, J. (2005) Three-dimensional localization of maxillary canines with cone-beam computed tomography. *Am J Orthod Dentofacial Orthop*, 128, 418-23.
- Wang, Y., He, S., Guo, Y., Wang, S. & Chen, S. (2013) Accuracy of volumetric measurement of simulated root resorption lacunas based on cone beam computed tomography. *Orthod Craniofac Res*, 16, 169-76.
- Wehrbein, H., Fuhrmann, R. A. & Diedrich, P. R. (1994) Periodontal conditions after facial root tipping and palatal root torque of incisors. *Am J Orthod Dentofacial Orthop*, 106, 455-62.
- Weiland, F. (2003) Constant versus dissipating forces in orthodontics: the effect of initial tooth movement and root resorption. *Eur J Orthod*, 25, 335-42.
- Wörtche, R., Hassfeld, S., Lux, C. J., Müssig, E., Hensley, F. W., Krempien, R. & Hofele, C. (2006) Clinical application of cone beam digital volume tomography in children with cleft lip and palate. *Dentomaxillofac Radiol*, 35, 88-94.
- Yamaguchi, M. (2009) RANK/RANKL/OPG during orthodontic tooth movement. *Orthod Craniofac Res*, 12, 113-9.
- Yamasaki, K., Shibata, Y. & Fukuhara, T. (1982) The effect of prostaglandins on experimental tooth movement in monkeys (*Macaca fuscata*). *J Dent Res*, 61, 1444-6.
- Yamashiro, T. & Takano-Yamamoto, T. (2001) Influences of ovariectomy on experimental tooth movement in the rat. *J Dent Res*, 80, 1858-61.
- Yi, J., Sun, Y., Li, Y., Li, C., Li, X. & Zhao, Z. (2017) Cone-beam computed tomography versus periapical radiograph for diagnosing external root resorption: A systematic review and meta-analysis. *Angle Orthod*, 87, 328-37.
- Zaichner-David, M. (2009) Genetic influences on orthodontic tooth movement. In Kishnan, V. & Davidovitch, Z. (ed.), *Biological Mechanisms of Tooth Movement*. Wiley-Blackwell, Oxford, UK, 1st ed, pp. 54-80.

References

- Zainal Ariffin, S. H., Yamamoto, Z., Zainol Abidin, I. Z., Megat Abdul Wahab, R. & Zainal Ariffin, Z. (2011) Cellular and molecular changes in orthodontic tooth movement. *Scientific World Journal*, 11, 1788-803.
- Ziegler, C. M., Woettche, R., Brief, J. & Hassfeld, S. (2002) Clinical indications for digital volume tomography in oral and maxillofacial surgery. *Dentomaxillofac Radiol*, 31, 126-30.

APPENDIX

- I. **Dudic, A.**, Giannopoulou, C. & Kiliaridis, S. (2013) Factors related to the rate of orthodontically induced tooth movement. *Am J Orthod Dentofacial Orthop*, 143, 616-21.
- II. **Giannopoulou, C.**, Dudic, A., Pandis, N. & Kiliaridis, S. (2016) Slow and fast orthodontic tooth movement: An experimental study on humans. *Eur J Orthod*, 404-8.
- III. **Dudic, A.**, Giannopoulou, C., Leuzinger, M. & Kiliaridis, S. (2009) Detection of apical root resorption after orthodontic treatment by using panoramic radiography and cone-beam computed tomography of super-high resolution. *Am J Orthod Dentofacial Orthop*, 135, 434-7.
- IV. **Dudic, A.**, Giannopoulou, C., Martinez, M., Montet, X. & Kiliaridis, S. (2008) Diagnostic accuracy of digitized periapical radiographs validated against micro-computed tomography scanning in evaluating orthodontically induced apical root resorption. *Eur J Oral Sci*, 116, 467-72.
- V. **Dudic, A.**, Giannopoulou, C., Meda, P., Montet, X. & Kiliaridis, S. (2017) Orthodontically induced cervical root resorption in humans is associated with the amount of tooth movement. *Eur J Orthod*, 1-7.