

Hip range of motion and the prevalence of cam morphology in young athletes

— Clinical and radiological studies

Anna S. Aminoff

Department of Orthopaedics
Institute of Clinical Sciences
Sahlgrenska Academy,
University of Gothenburg



UNIVERSITY OF GOTHENBURG

2020

Layout by Guðni Ólafsson at GO Grafik
Illustrations by Pontus Andersson

Hip range of motion and the prevalence of cam morphology in young athletes

– Clinical and radiological studies

© Anna S. Aminoff, 2020 a.m.k.sward@gmail.com

ISBN: 978-91-8009-116-9 (PRINT)

ISBN: 978-91-8009-117-6 (PDF)

<http://hdl.handle.net/2077/65147>

Correspondence: a.m.k.sward@gmail.com Printed

by Stema Specialtryck AB, Borås

Abstract

Hip and groin pain is common among athletes and the active population, and one important cause for this is femoroacetabular impingement syndrome (FAIS). To meet the diagnosis of FAIS, a combination of radiological findings (cam and/or pincer morphology), hip pain and clinical findings (reduced hip joint range of motion (ROM) and/or positive anterior impingement test (FADIR)) needs to be present. To quantify a cam morphology, the α -angle is often measured, and a cam morphology is usually considered present with an α -angle of $\geq 55^\circ$. Factors that have been associated with the development of cam morphology are genetics, ethnicity and participation in high impact sports during the pubertal growth spurt. Why some individuals develop FAIS and others do not, in the presence of a cam morphology, is still unknown. Therefore, there are still many questions that need to be answered regarding the aetiology, prevalence, impacts of different types of sports and loads, and treatment of cam/pincer and FAIS. Cam-type FAIS has also been associated with early hip osteoarthritis, and therefore this thesis focuses on cam morphology of the hip.

The overall aim of this thesis was to investigate the prevalence of cam morphology, hip ROM, hip pain and FAIS among young elite skiers and football players. Further, to investigate the relationship between hip ROM and cam, and hip ROM and pelvic tilt (with and without cam morphology).

Study 1 is a cross-sectional study, including 87 skiers and 27 non-athletes with a mean age of 17.7 (SD1.4) years, where the aim was to examine the relationship between the clinical examination of the hip and cam morphology. The study population was divided into cam- and no cam-groups depending on the α -angle measured with MRI. The main findings showed that reduced hip joint internal rotation, hip flexion and a positive anterior impingement test were associated with MRI-verified cam.

Study 2 is a cross-sectional study with the aim to investigate the effect of changes in pelvic tilt on hip ROM in individuals with and without cam. The same study population was included as in *Study 1*. The main finding was that dynamic changes in pelvic tilt significantly influenced hip ROM, independent of cam morphology.

Study 3 is a cross-sectional study investigating the prevalence of cam morphology (α -angle $>55^\circ$) in a group of elite Mogul and Alpine skiers, compared with non-athletes and between the sexes. The same study population was included as in *Study 1*. The skiers had a significantly higher prevalence of cam compared with the non-athletes. A significant difference was also found between males and females, with males having a higher prevalence of cam.

Study 4 is a cross-sectional study with the aim to investigate the difference in hip ROM, hip pain, cam morphology and FAIS in young athletes. One-hundred-and-thirty-five athletes (60 male soccer players, 40 male skiers and 35 female skiers) with a mean age of 17.7 (SD 1.2) years were included. For results please see manuscript.

Conclusion

Reduced hip joint internal rotation, hip flexion and a positive anterior impingement test were associated with MRI-verified cam. Hip ROM changes depending on the pelvic tilt and the posture of the lumbar spine. The skiers had a higher prevalence of cam than non-athletes. Male athletes had a higher prevalence of cam morphology than female athletes.

Sammanfattning på svenska

Höft- och lumsbesvär är vanligt bland idrottare och den idrottsaktiva befolkningen, och en orsak till detta är femoroacetabulärt impingement syndrom (FAIS). För att uppfylla kriterierna för FAIS måste det föreligga en kombination av radiologiska förändringar (cam och/eller pincer förändring), höft/ljumsksmärta och kliniska fynd (som regel nedsatt höftörlighet och/eller positivt främre inklämningstest). För att bedöma cam förändringen kan man mäta α -vinkeln, där definitionen är att det föreligger en cam om vinkeln är 55° eller mer.

Faktorer, som har förknippats med utvecklingen av cam är ärftlighet, etnicitet och delaktighet i högintensiv träning under den pubertala tillväxtspurt. Varför vissa individer utvecklar FAIS, medan andra som har en cam förändring inte gör det, är fortfarande oklart. Det finns många obesvarade frågor avseende etiologi, förekomst och påverkan av olika typer av idrotter och belastning, samt behandling av cam/pincer och FAIS. Det har visats att det finns ett samband mellan cam förändring och höftledsartros, vilket gör att denna avhandling är viktig och fokuserar på FAIS orsakad av cam förändring.

Denna avhandling har som ett mål att undersöka förekomsten av cam förändring, höftörlighet, höftsmärta och FAIS hos unga elitsatsande skidåkare och fotbollsspelare. Dessutom förhållandet mellan höftörlighet och cam, och

höftörlighet och bäckenets tippning (med och utan cam).

Studie I är en tvärsnittsstudie, där 87 skidåkare och 27 icke-idrottare med en genomsnittsålder på 17.7 (SD 1.4) år inkluderades. Förhållandet mellan en klinisk undersökning av höftleden och förekomsten av cam (α -vinkeln $\geq 55^\circ$) studerades. Deltagarna delades in i en cam- och en icke-cam-grupp beroende på α -vinkeln, som mättes med hjälp av MRT. Resultaten visade att nedsatt inåtrotation och flexion i höftleden, samt positivt främre inklämningstest korrelerade med cam förändring.

Studie II är en tvärsnittsstudie som undersökte effekten av förändringar av bäckenets tippning på höftörligheten hos individer med eller utan cam. Samma deltagare som i *Studie I* inkluderades. Resultaten visar att dynamiska förändringar av bäckenets tippning signifikant påverkar höftörligheten, oberoende av cam förändring.

Studie III är en tvärsnittsstudie, som undersökte förekomsten av cam hos en grupp unga elitsatsande puckelpist och alpina skidåkare av båda könen, jämfört med en grupp icke-idrottare. Samma deltagare som i *Studie I* inkluderades. Skidåkarna hade en signifikant högre förekomst av cam förändring jämfört med icke-idrottarna. En signifikant skillnad förekom även mellan män och kvinnor, där männen hade en högre förekomst av cam.

Studie IV är en tvärsnittsstudie, som undersökte skillnad och förekomst av cam, nedsatt höfttrörlighet, höftsmärta och FAIS bland unga idrottare. Etthundra-trettiofem idrottare (60 manliga fotbollsspelare, 40 manliga skidåkare och 35 kvinnliga skidåkare) från tre träningscenter i olika länder, med en genomsnittsålder på 17.7 (1.2) år deltog.

Konklusion: Nedsatt inåtrotation och flexion i höftleden, samt ett positivt främre inklämningstest korrelerade med cam förändring. Höft- ledens rörelseomfång påverkades av bäckenets tippning och ländryggens hållning. Skidåkare hade en högre förekomst av cam än icke-idrottare. Manliga idrottare hade en högre förekomst av cam än kvinnliga idrottare.

List of papers

This thesis is based on the following studies, referred to in the text by their Roman numerals.

- I. *Agnvall C, Swärd Aminoff A, Todd C, Jonasson P, Thoreson O, Swärd L, Karlsson J, Baranto A.*
Range of Hip Joint Motion Is Correlated With MRI-Verified Cam Deformity in Adolescent Elite Skiers
Orthopaedic Journal of Sports Medicine. 2017 10.1177/ 2325967117711890
- II. *Swärd Aminoff A, Agnvall C, Todd C, Jónasson P, Sansone M, Thoreson O, Swärd L, Karlsson J, Baranto A.*
The effect of pelvic tilt and cam on hip range of motion in young elite skiers and non-athletes
Open Access Journal of Sports Medicine, 2018, doi.org/10.2147/OAJSM.S162675
- III. *Agnvall C, Swärd Aminoff A, Todd C, Jonasson P, Thoreson O, Swärd L, Karlsson J, Baranto A.*
Young elite Alpine and Mogul skiers have a higher prevalence of cam morphology than non-athletes
Knee Surgery, Sports Traumatology, Arthroscopy, 2020 Apr;28(4):1262-1269
- IV. *Swärd Aminoff A, Abrahamson J, Todd C, Thoreson O, Agnvall C, Laxdal G, Pruna R, Jonasson P, Swärd L, Karlsson J, Baranto A.*
Differences in cam morphology and hip range of motion between young skiers and soccer players
Manuscript

Additional Publications by the author, not included in the thesis

Abrahamson J, Jónasson P, Swärd Aminoff A, Sansone M, Todd C, Karlsson J,

Baranto A. Hip pain and its correlation with cam morphology in young skiers - A minimum 5 years follow-up.

Journal of Orthopaedic Surgery. In press.

Abrahamson J, Swärd Aminoff A, Todd C, Agnvall C, Thoreson O, Jónasson P, Karlsson J, Baranto A.

Adolescent elite skiers with and without cam morphology did change their hip joint range of motion with 2 years follow-up.

Knee Surgery, Sports Traumatology, Arthroscopy. 2019 Oct;27(10):3149-3157. doi: 10.1007/s00167-018-5010-7. Epub 2018 Jun 7.

Thoreson O, Ekström L, Hansson HA, Todd C, Witwit W, Swärd Aminoff A, Jónasson P, Baranto A.

The effect of repetitive flexion and extension fatigue loading on the young porcine lumbar spine, a feasibility study of MRI and histological analyses. Journal of Experimental Orthopaedics.

2017 Dec;4(1):16. doi: 10.1186/s40634-017-0091-7. Epub 2017 May 12.

Witwit WA, Kovac P, Sward A, Agnvall C, Todd C, Thoreson O, Hebelka H, Baranto A.

Disc degeneration on MRI is more prevalent in young elite skiers compared to controls.

Knee Surgery, Sports Traumatology, Arthroscopy. 2018 Jan;26(1):325-332. doi: 10.1007/s00167-017-4545-3. Epub 2017 Apr 13.

Thoreson O, Kovac P, Swärd A, Agnvall C, Todd C, Baranto A.

Back pain and MRI changes in the thoraco-lumbar spine of young elite Mogul skiers.

Scandinavian journal of medicine science in sports. 2017 Sep;27(9):983-989. doi: 10.1111/sms.12710. Epub 2016 Jul 1.

Jónasson P, Thoreson O, Sansone M, Svensson K, Swärd A, Karlsson J, Baranto A.

The morphologic characteristics and range of motion in the hips of athletes and non-athletes.

Journal of Hip Preservation Surgery, Volume 3, Issue 4, October 2016, Pages 325–332, <https://doi.org/10.1093/jhps/hnw023>

Jónasson P, Thoreson O, Sansone M, Svensson K, Swärd A, Karlsson J, Baranto A.

Back pain and MRI changes in the thoraco-lumbar spine of young elite Mogul skiers.

Journal of Hip Preservation Surgery. 2016 Jul 15;3(4):325-332. doi:10.1093/jhps/hnw023. eCollection 2016 Oct.

Todd C, Witwit W, Kovac P, Swärd A, Agnvall C, Jónasson P, Thoreson O, Swärd L, Karlsson J, Baranto A.

Pelvic Retroversion is Associated with Flat Back and Cam Type Femoro-Acetabular Impingement in Young Elite Skiers.

Journal of Spine 5 (2016): 326.

Todd C, Kovac P, Swärd A, Agnvall C, Swärd L, Karlsson J, Baranto A.

Comparison of radiological spino-pelvic sagittal parameters in skiers and non-athletes.

Journal of Orthopedic Surgery and Research. 2015 Oct 17; 10:162. doi: 10.1186/s13018-015-0305-6.

Todd C, Agnvall C, Kovac P, Swärd A, Johansson C, Swärd L, Karlsson J, Baranto A.

Validation of spinal sagittal alignment with plain radiographs and the Debrunner Kyphometer.

Medical research archives 2015;2(1)

Jónasson P, Ekström L, Swärd A, Sansone M, Ahldén M, Karlsson J, Baranto A.

Strength of the porcine proximal femoral epiphyseal plate: the effect of different loading directions and the role of the perichondral fibrocartilaginous complex and epiphyseal tubercle - an experimental biomechanical study.

Journal of experimental orthopaedics. 2014 Dec;1(1):4. doi: 10.1186/s40634-014-0004-y. Epub 2014 Jun 26.

Abbreviations

ASIS	Anterior Superior Iliac Spine
CT	Computerized Tomography
FABER	Flexion Abduction External Rotation
FADIR	Flexion Adduction Internal Rotation
FAIS	Femoroacetabular impingement syndrome
ICC	Intraclass Correlation Coefficient
OA	Osteoarthritis
PT	Pelvic Tilt
PROM	Patient Reported Outcome Measures
PSIS	Posterior Superior Iliac Spine
MRI	Magnetic Resonance Imaging
ROM	Range of Motion
SCFE	Slipped Capital Femoral Epiphysis
SD	Standard Deviation
SI	Sacro-iliac joint
VAS	Visual Analogue Scale

Brief Definitions

Alpha angle

A radiographic measurement to quantify a cam morphology. The angle between a line from the centre of the femoral head through the middle of the femoral neck and a line through a point where the contour of the femoral head-neck junction exceeds the radius of the femoral head.

Anteversión

A forward rotation of an entire organ or part, such as the pelvis rotating forward around the hip joints.

Biological age

Refers to how old a person seems, and takes hormonal (for example the onset of the adolescent growth spurt) and lifestyle factors into consideration.

Cam

An abnormally shaped femoral head-neck junction, causing a non-spherical femoral head.

Cam-type impingement

A type of femoroacetabular impingement where asphericity of the femoral head-neck junction results in the abutment of the aspherical head-neck junction on and/or under the acetabular rim during movement of the hip joint.

Chronological age

Refers to the actual amount of time a person has been alive.

Enchondral ossification

The growth plate, forms bone from hyaline cartilage. This process is affected by genetics, hormones, nutrition and mechanical stress. Most long bones of the body and the spine are formed by enchondral ossification.

Femoroacetabular impingement syndrome (FAIS)

A syndrome of symptoms caused by the impingement of the femoral head-neck junction on and/or under the acetabular rim.

Health-related Patient Reported Outcome Measures

Questionnaire completed by patients to measure perceptions of their general health in relation to a specific illness or condition.

Menarche

First menstrual cycle or bleeding.

Osteoarthritis

A degenerative joint disease that results in the breakdown of the joint cartilage. In primary osteoarthritis the cause is unknown, but in secondary osteoarthritis the underlying cause is known.

Peak height velocity

The peak of time when an individual grows the fastest in height.

Peak bone velocity

The peak of time when the mineralization (growth of bone mass) of the skeleton is the highest.

Pelvic tilt

A positional parameter, i.e. the angle measured from a perpendicular line starting at the centre of the femoral head and extended to the mid-point of the sacral plate.

Physis

The growth plate or epiphyseal plate. The physis is a thin layer of hyaline cartilage, located between the epiphysis and metaphysis in long bones of growing individuals. Most of the growth in length occurs at the physis through enchondral ossification.

Pincer

Focal or global over-coverage of the hip by a prominent acetabular rim.

Range of motion

The measured movement of a joint in degrees.

Reliability

The degree to which a measurement is free from measurement error. The extent to which scores for patients who have not changed are the same for repeated measurement under several conditions; e.g. using different sets of items from the same HRPRO (internal consistency); over time (test-retest); by different persons on the same occasion (interrater); or by the same persons on different occasions (intrarater).

Retroversion

A backward rotation of an entire organ, such as the pelvis rotating backwards around the hip joints.

Validity

The degree to which an instrument measures the construct(s) it purports to measure.

Visual Analogue scale (VAS)

A measurement instrument for subjective phenomena that cannot be directly measured. Agreement level with a statement is indicated by a mark on a continuous line between two endpoints.

Introduction

Anatomy of the hip joint

The hip joint is a ball-and-socket joint consisting of a round femoral head, that articulates with the cup-shaped pelvic acetabulum. The normal orientation of the acetabulum is described as being rotated 20–40° off vertical in the frontal plane, and 20–30° anteriorly ^{1,2}. Females have a greater anterior pelvic tilt (PT) and a more inwardly rotated hip, compared with males ³. The hip joint permits a variety of movement in all directions (flexion, extension, abduction and adduction) including rotation around a central axis ⁴, normally enabling activities such as running, climbing and squatting without osseous conflict between the femoral neck and the acetabulum ⁵.

Forces from different directions are applied to the hip joint, and place both high demands on stability and movement at the same time (Figure 1) ⁵. The joint capsule is reinforced with strong ligaments to enhance stability, but also permit range of motion (ROM) (Figures 2 and 3). Anteriorly, the iliofemoral ligament limits extension, inferiorly the pubofemoral ligament limits abduction and posteriorly the ischiofemoral ligaments stabilizes the hip in extension. All three ligaments limit internal rotation ⁶. The ligamentum fovea extends from the fovea of the femoral head to the acetabular fovea ⁷. The annular ligament is attached to the greater trochanter and runs circumferentially around the femoral neck, further enforcing the capsule posteriorly and is

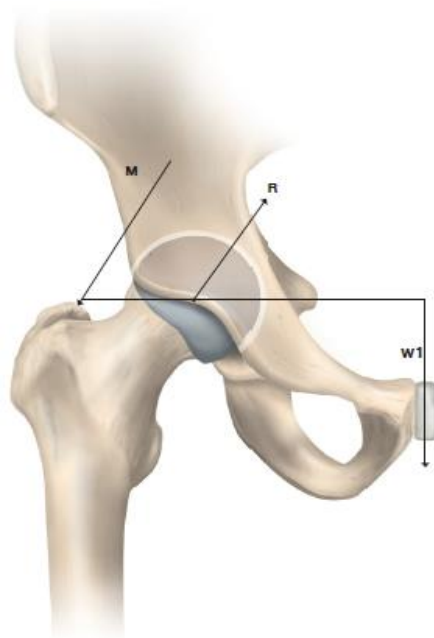


Figure 1. Load on the hip joint when standing. **M** Hip abductor muscle tension force. **R** Joint reaction force applied by the pelvis on the femur. **W** Total body weight. **W1** Fraction of total body weight that is applied.

a key structure for hip stability in distraction ^{8,9}. Ligamentum teres is thought to function as an intrinsic stabilizer of the hip, and is the only intraarticular connection between the pelvis and femur, and runs from the inferior margin of the acetabulum, from the transverse acetabular ligament, and inserts into the fovea capitis (Figure

4) ¹⁰. Other structures that increase the stability of the hip joint is the labrum and the surrounding muscles. The fibrocartilaginous labrum is located at the bony circumference of the acetabulum. Inferiorly, the anterior and posterior portions are connected by the transverse ligament, but superiorly it runs continuously with the acetabular cartilage. The labrum increases the effective

depth of the socket and the coverage of the femoral head; increasing stability and joint congruity ¹¹. Moreover, the labrum appears to prevent fluid from flowing in and out of the intraarticular space ¹². The hip joint is covered by a large muscle envelope with 21 muscles crossing the joint, causing movement, but also stabilizing and maintaining an upright position ⁷.

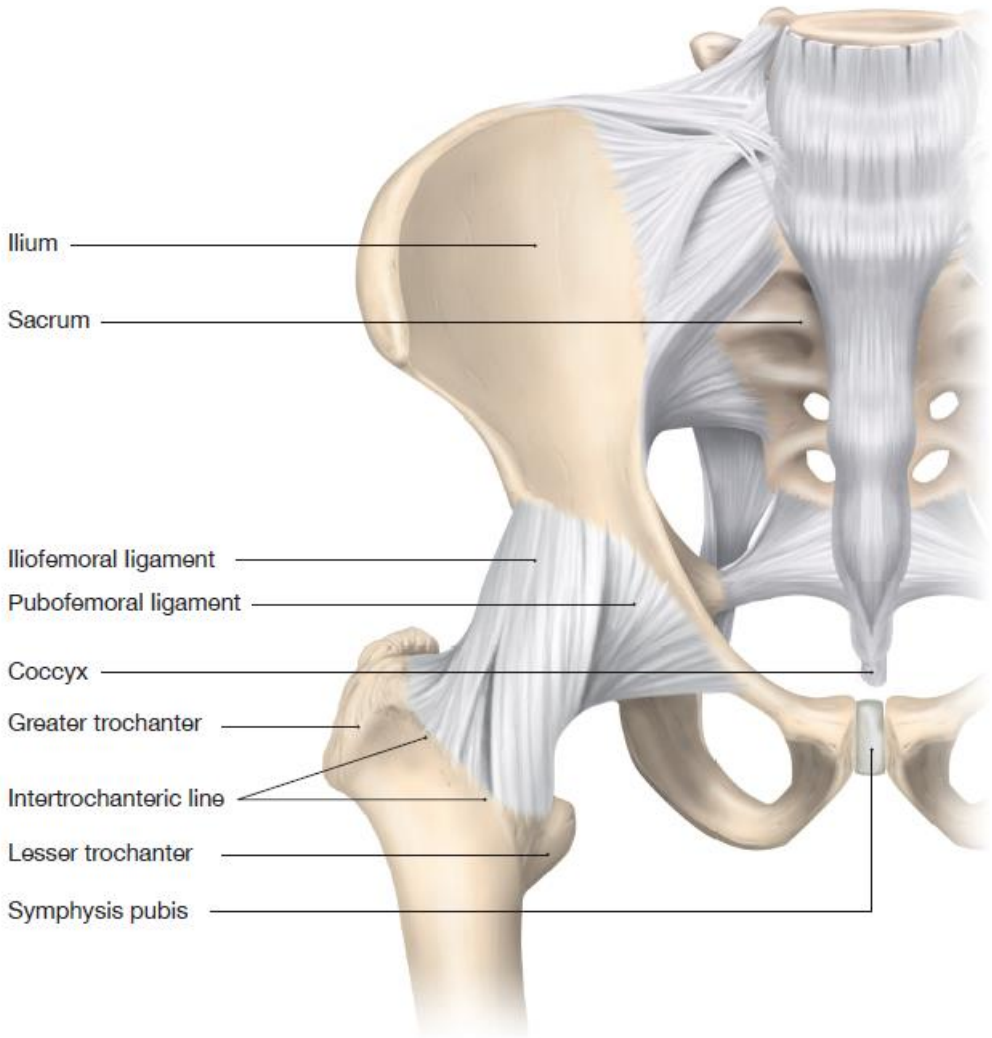


Figure 2. Anterior view of the hip and pelvis.

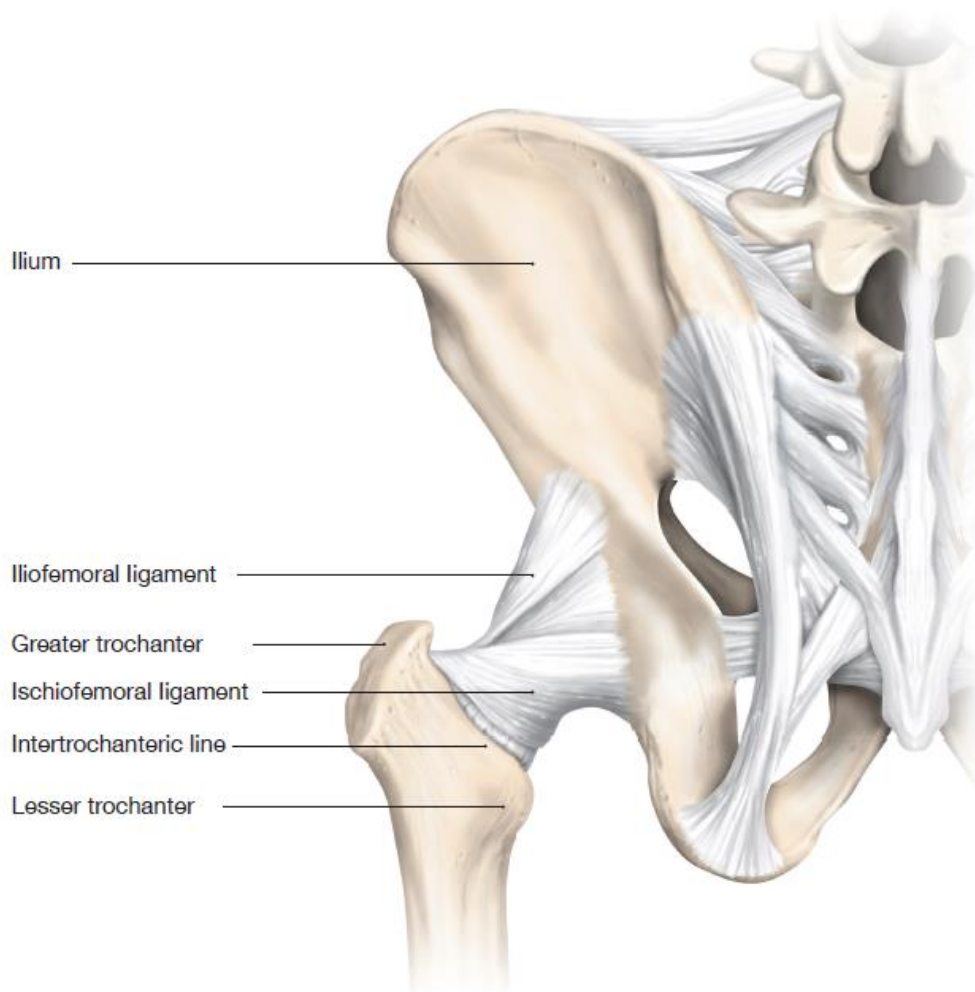


Figure 3. Posterior view of the hip and pelvis.

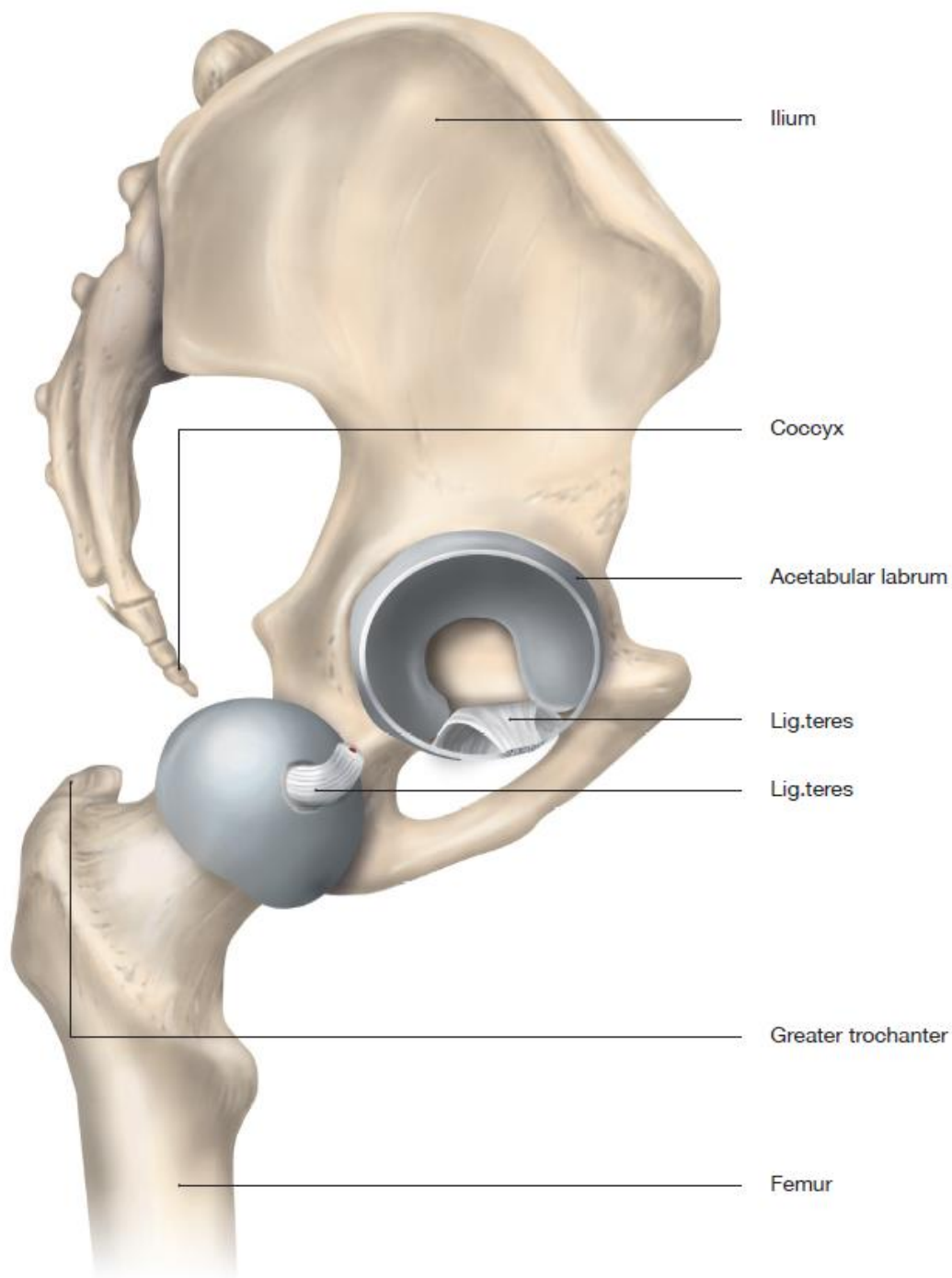


Figure 4. Lateral view of the right hip showing the bony anatomy, the labrum and the teres ligament (cut). The joint capsule has been removed and the femoral head is dislocated posteriorly to show the acetabulum and its anatomy.

Anatomy of the pelvis

The bowl-shaped pelvis consists of the coccyx and two pelvic bones that articulate with each other anteriorly and posteriorly with the sacrum (Figure 2 and 3). The pelvis functions as the base of the trunk, it supports the abdomen and is a mobile link through which the spinal column communicates with the lower extremities¹³. Moreover, the sacroiliac joints and symphysis pubis act as a buffer to decrease forces, acting upon the spine and upper body, caused by contact of the lower limbs with the ground⁶. Pelvic stability is provided by the articular surfaces, the joint capsules, the ligaments that bind the joints together and the muscles that act around them. The sacroiliac joints and symphysis pubis have no muscles that control their movements directly, but they are influenced by the action of the muscles moving the lumbar spine and hip, because many of these muscles attach to the sacrum and pelvis⁶.

The female pelvis tends to be wider and broader than the male, and this is thought to be because of obstetrical demands, differences in growth patterns influenced by sex-specific hormones, or a combination of the two¹⁴.

Anatomy of the lumbar spine, sacrum and coccyx

The lumbar spine consists of five vertebrae, connected to each other by ligaments, in a lordotic curvature (lumbar lordosis) that helps balance the upper body over the pelvis (Figure 5)^{4,15}. The vertebral bodies are separated anteriorly by the intervertebral discs and posteriorly by two facet joints and a vertebral arch. The lumbar spine is connected to the thoracic spine proximally and the sacrum distally. The sacrum consists of five fused vertebrae and is connected to the coccyx, consisting of four fused vertebrae, distally. To support more weight, the lumbar vertebrae are larger and stronger than the cervical and thoracic vertebrae⁴. Moreover, the vertebrae from the different regions (cervical, thoracic and lumbar) differ in other

ways than size, depending on the demands of movement and stress of that specific region.

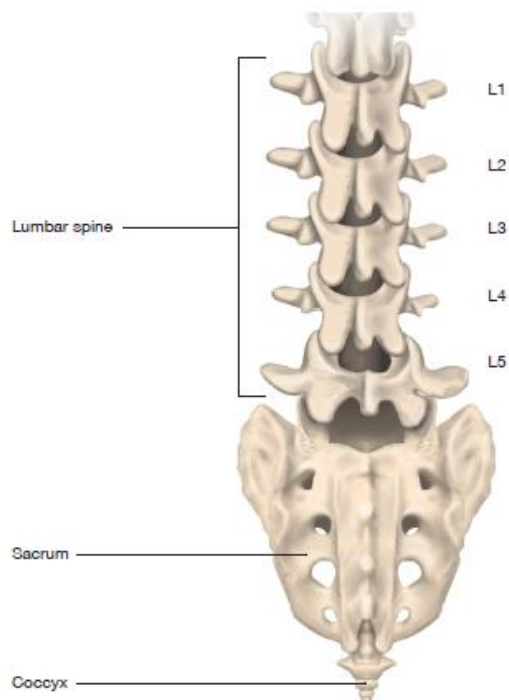


Figure 5. The lumbar spine.

Femoroacetabular impingement syndrome (FAIS)

FAIS is defined as a combination of imaging findings of the hips (abnormal morphology), symptoms and clinical findings¹⁶⁻¹⁸. The abnormal morphology of FAIS can be divided into two categories, occurring in combination or isolated; cam (femoral based) and pincer (acetabular based), (Figure 6)¹⁹⁻²². Cam morphology of the proximal femur refers to an abnormal contour of the femoral head-neck junction, giving an aspherical femoral head and is generally located in the anterosuperior and anterolateral regions of the proximal femur. Pincer is an over-coverage of the acetabulum in relation to the femoral head, and can be either global (bony overgrowth of the acetabulum or a deep socket) or focal (acetabular retroversion).

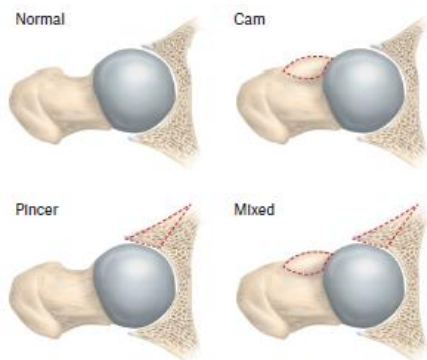


Figure 6. Horizontal view of a left hip showing the different types of femoroacetabular impingement.

Morphology of cam

The cam morphology is quantified by measuring the α -angle; the larger the α -angle, the greater the cam morphology, and in previous studies a threshold of $\geq 55^\circ$ has been considered clinically relevant (Figure 7) ²³⁻²⁵. An overlap between asymptomatic controls and patients with cam-type FAIS has been reported and the diagnostic value of the α -angle has been questioned ^{26,27}. Some studies consider a cut-off value of $50-55^\circ$ to be too low and have suggested $60-63^\circ$ to be more clinically relevant ^{26,28}. In a recent systematic review van Klij et al. found that, based on current available evidence, an alpha angle threshold of $\geq 60^\circ$ would be most appropriate to classify cam morphology ²⁹. It is difficult to determine a cut-off value for the α -angle since FAIS is a multifactorial condition. It has been shown, among females, that even a subtle cam can play significant role in FAIS, and therefore, a lower α -angle cut-off value could be used when diagnosing cam morphology in females ³⁰.

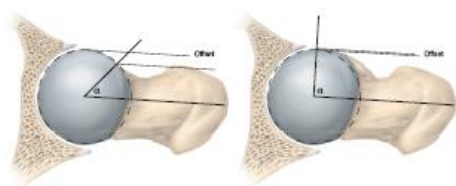


Figure 7. The alpha angle quantifies the cam morphology.

Prevalence

There is great variance between different studies with regards to the prevalence of cam in the general population (5-75%) ^{31,32}. In a recent study, including 200 subjects from the general population in the UK, 47% (56% of men and 37% of women) had cam morphology (α -angle $>60^\circ$) ³³. In a similar study, including 2596 individuals from the US, 25% of men and 10% of females had a cam morphology (α -angle $>60^\circ$) ³⁴. Gosvig et al. reported in their study on 4,151 asymptomatic adults that cam was present in 17% of males and 4% of females ³⁵. Others have reported a prevalence of cam morphology in asymptomatic study populations ranging from 5.2 to 25% (females 5.2–5.4% and males 9–25%) ³⁶⁻⁴⁰. Among symptomatic patients, who underwent surgery for FAIS, 47.6% had cam morphology (55% women, 45% men) ³¹.

Injury mechanism

The mechanism of cam-type impingement is a collision between the abnormally formed femoral neck/head (cam) and the acetabular margin during hip flexion and internal rotation of the hip (Figure 8) ²¹. Repeated impingements can lead to injuries to the articular cartilage and/or acetabular labral tears, and cause pain ^{19-21,25,41}.

Symptoms

Often the symptoms of FAIS are heterogeneous, but symptoms that have been associated with FAIS are motion-related or position-related pain in the hip, groin, back, buttocks or thigh. Clicking, catching, locking, stiffness, restricted range of motion or giving way are other frequently reported symptoms ¹⁸. Typically, the patient with FAIS complains of groin pain that has been exacerbated by intense activity including repetitive hip flexion. Whether a cam morphology, in a person who is not diagnosed with FAIS, results in symptoms is still uncertain ⁴².

Clinical findings

Clinically, the patient with FAIS typically presents with reduced hip ROM and/or a positive

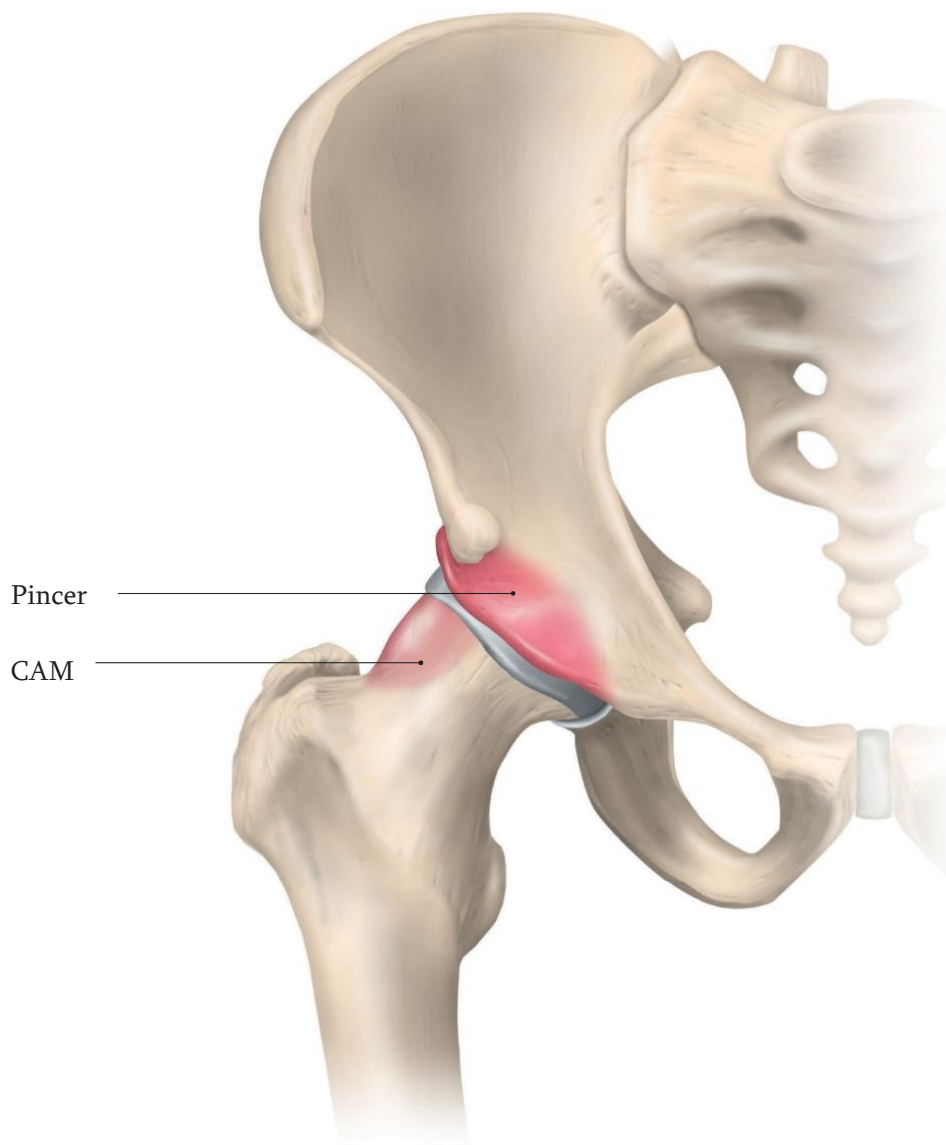


Figure 8. The mechanism of FAIS.

anterior impingement test (FADIR). Research implies that loss of hip ROM imposes higher demands on surrounding structures, increasing the risk of overload injuries⁴³⁻⁴⁶.

Conservative Treatment

Physiotherapy and activity modification with the

goal of a pain-free ROM, without impingement and the strengthening of the core, hip and thigh musculature⁴⁷.

Surgical Treatment

In the past decade, surgeons have developed arthroscopic surgical techniques to treat FAIS.

The rationale is to, with the help of a shaver (and other arthroscopic instruments), restore normal anatomy by resecting cam and pincer morphologies, and repairing cartilage and labral damage with the aim to prevent impingement and relieve symptoms⁴⁸. Initially, surgical treatment was performed using an open technique⁴⁹.

The aetiology of pincer and cam

Pincer Morphology

Pincer morphology can be due to several different formations that deepen the acetabulum globally or locally, for example coxa profunda and protrusion, or acetabular retroversion and ossification of the labrum¹⁹. Compared with cam morphology, no studies have been able to show a causal relationship between sporting activities during growth and the development of pincer⁵⁰.

Cam morphology

The exact mechanism behind the development of the abnormal morphology of cam is still not identified. Previously, cam morphology was believed to be due to a healed sub-clinical slipped capital femoral epiphysis (SCFE), but more recent longitudinal studies have not been able to identify SCFE in cohorts of young athletes, even if cam morphology was present^{23,35}. Factors identified, by recent studies, associated with the development of cam morphology are: genetics, male sex, ethnicity, heavy physical work and participation in high impacts sports during skeletal maturation^{23,24,51-55}. It has been suggested that the cam type morphology is a consequence of an alteration of the open proximal femoral growth plate, and with the help of radiology, it has been possible to visualize an abnormal growth plate extension and/or hypertrophy along the antero-superior femoral neck. The cam morphology is first evident as cartilaginous hypertrophy in individuals as young as ten years⁵⁶, and as the growth plate closes, the abnormal extension ossifies into a bony overgrowth, in other words the cam morphology^{40,56,57}. Cam morphology gradually develops during the pubertal growth period, but after growth plate closure there is

no significant increase in the prevalence of cam^{23,42,58}. Moreover, a significant correlation between the size of the growth plate extension and the alpha angle has been found, giving a greater cam morphology with a greater extension.

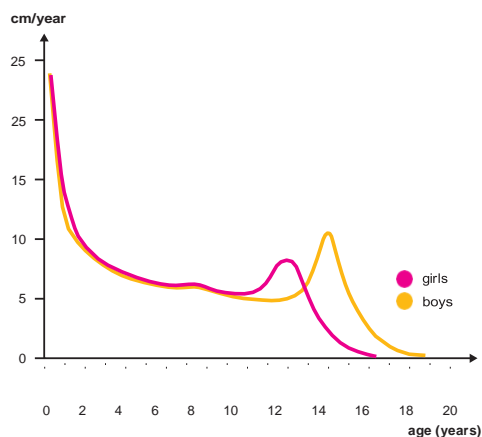


Figure 9. A growth curve, showing the difference of peak height velocity (cm/year) between boys and girls.

The growth spurt

The chronological age does not necessarily reflect the timing and intensity of growth in children (Figure 9). Early and late maturing children, of identical chronological age, can differ by six years developmentally (biological age)⁵⁹. The period of increased growth during the adolescent growth spurt involves first a period of height growth, followed by a period of mineralization of the bone. Bailey et al. showed a significant time difference in peak bone (bone mineral content) velocity between girls (12.5 years) and boys (14.1 years)⁶⁰. The peak height velocity appeared approximately one year earlier than peak bone velocity (girls 11.8 and boys 13.5 years). Some researchers suggest that this lag represents a period of relative weakness during the adolescent growth spurt and activities that impose high load upon the skeleton may be contraindicated during this short period of time^{60,61}. Because of high levels of growth hormone, oestrogen, testosterone and IGF-1, and bone modelling being highly active, the skeleton

is especially responsive to mechanical stimuli during the adolescent growth spurt ⁶¹. Genetics and nutrients also influences skeletal growth ⁶². Moreover, Bailey et al. showed that approximately 26% of final adult bone is accumulated during the two years surrounding peak bone velocity (girls 11.5-13.5 years and boys 13.0-15.0 years) ⁶³. Therefore, it is of great importance to encourage youths to be active during this period of time, preferably in several different sports, to expose the growing skeleton to varying degrees and directions of load.

Biomechanics

The growth plate hyaline cartilage has low resistance to shear stress ⁶⁴ and shear stress promotes

ossification ⁶⁵. Sadeghian et al. found indications, in a finite element model, that the growth plate alternates in a direction, which minimizes shear stress distributed in the growth plate ⁶⁴. Jónasson et al. showed, with the help of a biomechanical model using porcine proximal femurs, that the strength of the proximal femur is weakest through the growth plate ⁶⁶. Moreover, they showed that the growth plate was weakest when exposed to lateral load and strongest when exposed to vertical load. This correlates well with the findings of Roels et al. who showed, with the help of finite element models, that especially heavy loading during hip flexion and/or external rotation of the hip appear to stimulate the development of a cam morphology ⁶⁷.

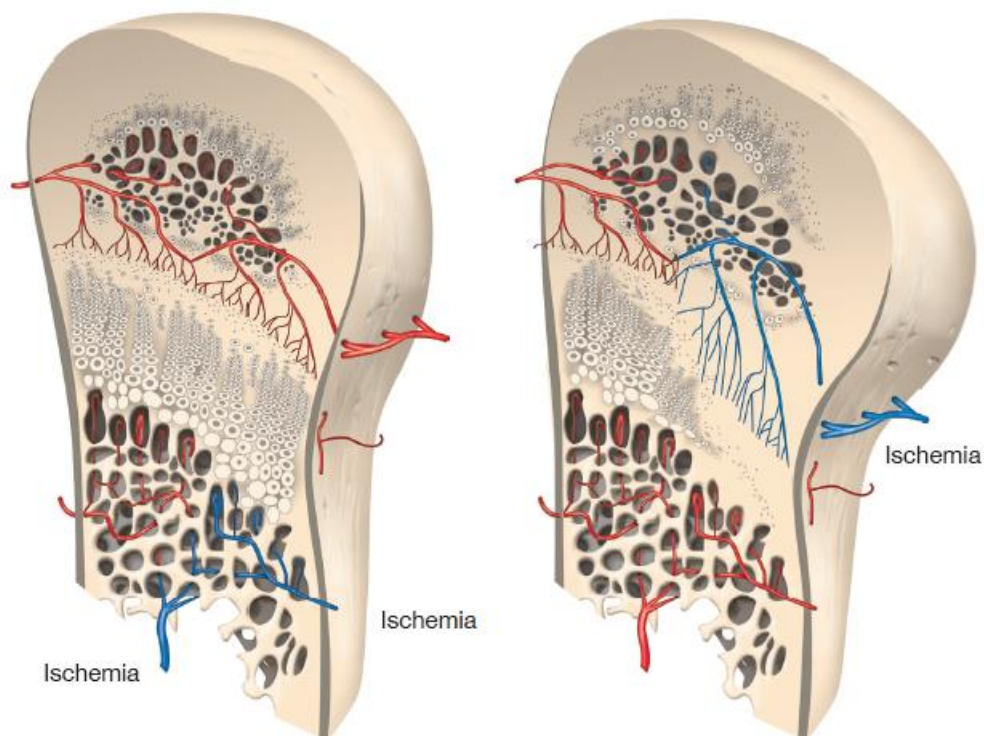


Figure 10. A compromised blood supply on the metaphyseal side (below the physis) causes the continued growth and widening of the physis. If the blood supply is compromised on the epiphyseal side (above the physis) narrowing of the physis and growth cessation occurs.

Adolescents who participate in high levels of sport activity or heavy physical work, can sustain repetitive trauma to the growth plate that could theoretically disrupt the microvascular blood supply to the growth plate and thereby interrupting normal endochondral bone formation (Figure 10) ⁶⁸. Resulting in a growth plate cartilage extension into the metaphysis and followed by failure of normal ossification of the cartilaginous matrix, which might lead to growth plate widening on MRI ^{68,69}. This widening of the growth plate may eventually lead to a delayed growth plate closure ⁷⁰.

Prevalence of cam morphology among athletes

The prevalence of cam morphology among male athletes has, in different studies been reported to range between 41 and 75% ³¹. It has been hypothesized that the morphology of cam is acquired in relation to vigorous sporting activity, with abnormal and repetitive biomechanical stress on the growing hip. Several studies have found a causal relationship between the presence of a cam morphology and participation in sports among young individuals. Soccer, track & fields, ice-hockey, alpine and mogul skiing, and basketball are examples of sports where a high prevalence of cam was found^{23,24,36,40,55,57,71-73}. Tak et al. found a significant dose-response relationship between the frequency of football practice during skeletal growth and the development of a cam morphology, fortifying the relationship between high-load sporting activity during growth and the development of cam ⁷².

Only few studies on the prevalence of cam morphology among female athletes have been published and a lower prevalence of cam (12-48%) compared with male athletes have been reported ⁷⁴⁻⁷⁷. In comparison with this Carter et al. found, in a small study population, that female elite ice hockey players had a comparable prevalence of cam compared to men ⁵⁸. Eighty-two percent of all hips and 92% of all players had cam morphology, and 77% had bilateral cam morphology (alpha angle of $\geq 55^\circ$).



Figure 11. An alpine skier.

Skating and cam

When skiing, both Mogul and Alpine, the body is exposed to great forces (high speed and G-forces) (Figure 11) ⁷⁸⁻⁸⁰. The hips and spine act as important dampers for these forces. During a run the skier is object to several movement types and loadings, and the hips and spine are placed in vulnerable positions in both flexion and extension. In Mogul skiing acrobatic jumps pose a risk of injury in landing and high forces that affect the hips and spine ⁸¹. During a Giant Slalom turn the spine of a world cup skier can have a lateral bending of up to 16° , a rotation of 10° and flexion up to 44° , and an acceleration force almost up to 3 times the body weight. Overuse injuries, among alpine skiers, are most common in the spine, hip and knee, while the traumatic injuries mostly involve the head, lower leg and knee ^{80,82}. Force transfer is dependent on adequate ROM, where joints of adjacent segments interact and their positions affect each other. Not much has been written about the prevalence of cam among skiers, but what has been written indicates that they are at risk of developing cam-type FAIS.



Figure 12. A soccer player.

Soccer and cam

Soccer is one of the most popular sports throughout the world, with more than 240 million players in 2000 (Figure 12)⁸³. It is a sport that uses walking, jogging, running, and sprinting, involving two teams of 11 players who attempt to propel a ball through a set of goals, while preventing the other team from doing the same. The game consists of two 45-minute halves,

with a 15-minute rest between halves. With high performance soccer there is an increased risk of musculoskeletal injury from overuse or traumatic onset. Several studies have investigated the prevalence of cam morphology among soccer players, and they indicate that they are at an increased risk of developing cam compared with non-athletes^{23,36,74,84,85}.

Clinical examination of the hip joint

Hip range of motion (ROM) is affected by many parameters such as age, pain, degenerative changes (osteoarthritis), and hip morphology^{84,86}, and can be measured with the patient sitting, in a prone or supine position⁶.

Flexion of the hip normally ranges between 110-120°, internal rotation between 30-40° and external rotation between 40-60°⁶. Limited passive hip internal rotation has been described as being 25° or less^{6,87}. The mean of a normal total hip rotation (internal and external) has been reported as being 95°, but a lower cut-off has been used among athletes^{45,88}.

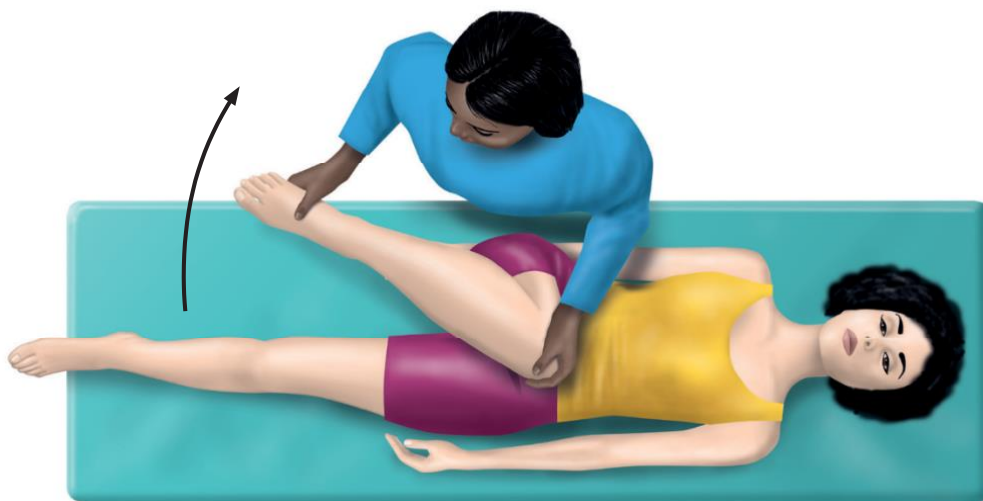


Figure 13. The FADIR test is performed with the patient in the supine position. The hip is flexed to 90°, adducted and internally rotated. The test is positive if it provokes the patient's symptoms.

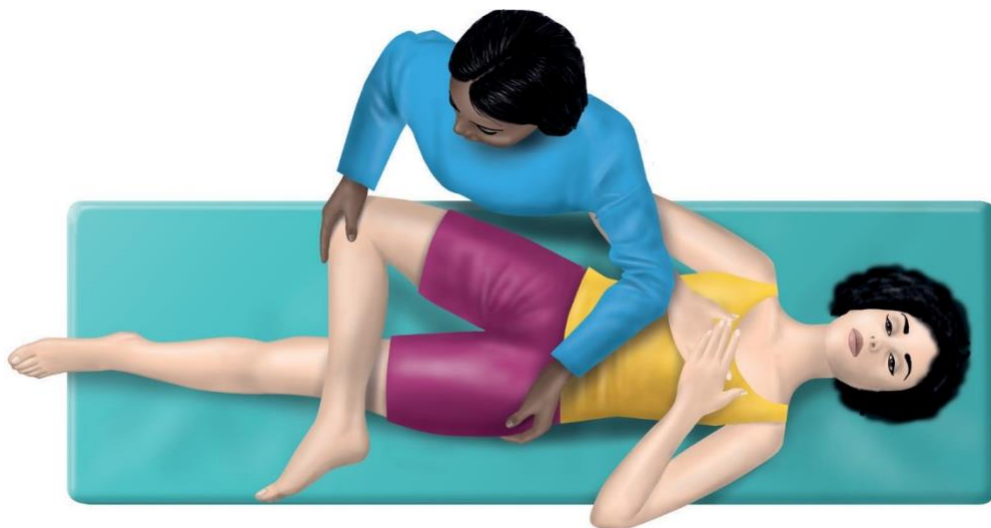


Figure 14. The Faber test is performed with the patient in the supine position. The lateral malleolus of the examined hip is placed superiorly to the patella of the contralateral knee. The hip is then abducted with one hand, while the other hand stabilizes the pelvis. The angle of the abducted knee can be registered as an indication of range of motion.

The most common findings when examining a patient with FAIS is reduced hip ROM, particularly flexion, internal rotation and a positive impingement test (FADIR) (Figure 13)^{18,89}. The FADIR (flexion adduction and internal rotation) impingement test is often positive when FAIS is present, but also often positive when FAIS is not present. FADIR is sensitive, and so are the other tests described to help in the diagnosis of FAIS, but has a low specificity⁹⁰. The FABER test (flexion abduction and external rotation) is also common (Figure 14). Although these tests are often used, there are inconsistent reports whether decreased hip ROM is correlated with cam morphology or not⁹¹. Freke et al.⁹² found limited and conflicting evidence of an association between cam morphology and decreased hip ROM in symptomatic patients. Reimann et al. concluded that only an anterior impingement test and supine flexion internal-rotation are valuable screening tests for FAIS, and Tak et. al debates that the hip/groin pain itself affects hip ROM rather

than the cam morphology^{84,93}. In a recent study van Kilj et al. found an association between cam and decreased internal rotation and/or hip flexion in a cohort of young soccer players, but the differences might not exceed the minimal clinical important difference⁴². Factors that might differ between studies measuring hip ROM are positioning of the subject, accuracy of the measurements, method to evaluate the cam morphology (e.g. type of radiology, cut-off values for measurements), the presence of hip pain and mean age of the included participants. All these factors may affect the outcome of the examination and explain the discrepancy between studies.

Pelvic Tilt

Pelvic Tilt (PT) is a functional parameter that changes with posture. PT measures the angle between a perpendicular line starting at the centre of the femoral head, extending to the mid-point of the sacral plate (Figure 15). A neutral PT is believed to be $11^{\circ} \pm 4^{\circ}$ ⁹⁴, but it decreases when the pelvis is rotated forwards (anteversion) and increases when the pelvis is rotated backwards (retroversion).

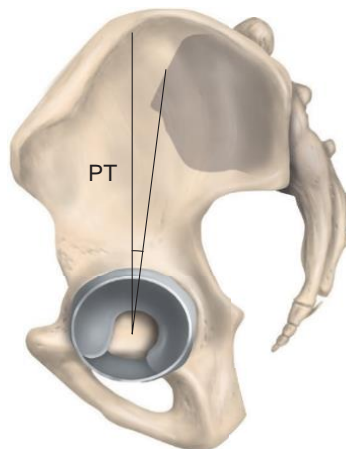


Figure 15. Pelvic tilt (PT).

The PALM Palpation

meter. To determine the angle of PT (pelvic anteversion or retro- version), the angle between the horizontal, and a line drawn from the anterior superior iliac spine (ASIS) and the posterior superior iliac spina (PSIS), was measured using the PALM Palpation meter (Figure 16). Good reliability and moderate to good levels of validity have been shown when using this clinical method^{95,96}.

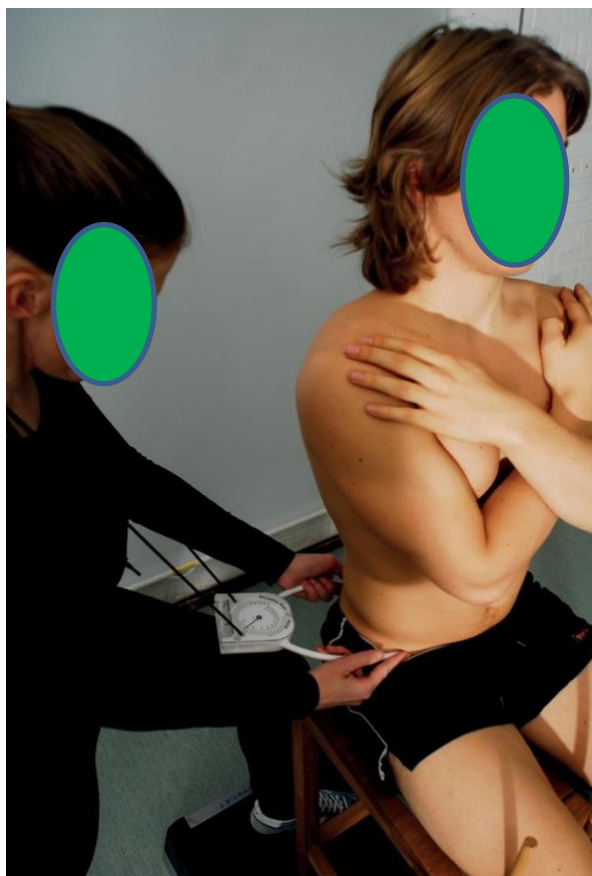


Figure 16. The PALM palpation

Debrunner Kyphometer

The Debrunner Kyphometer (Protek AG, Bern, Switzerland) is a hand-held measuring device, with two movable arms with blocks (Figure 17). By placing the blocks on pre-palpated and

pre-marked anatomical landmarks, movement and position of both the thoracic and lumbar spine can be measured in degrees. Validity measurements comparing the Kyphometer with radiological standard have been shown high validity^{97,98}.

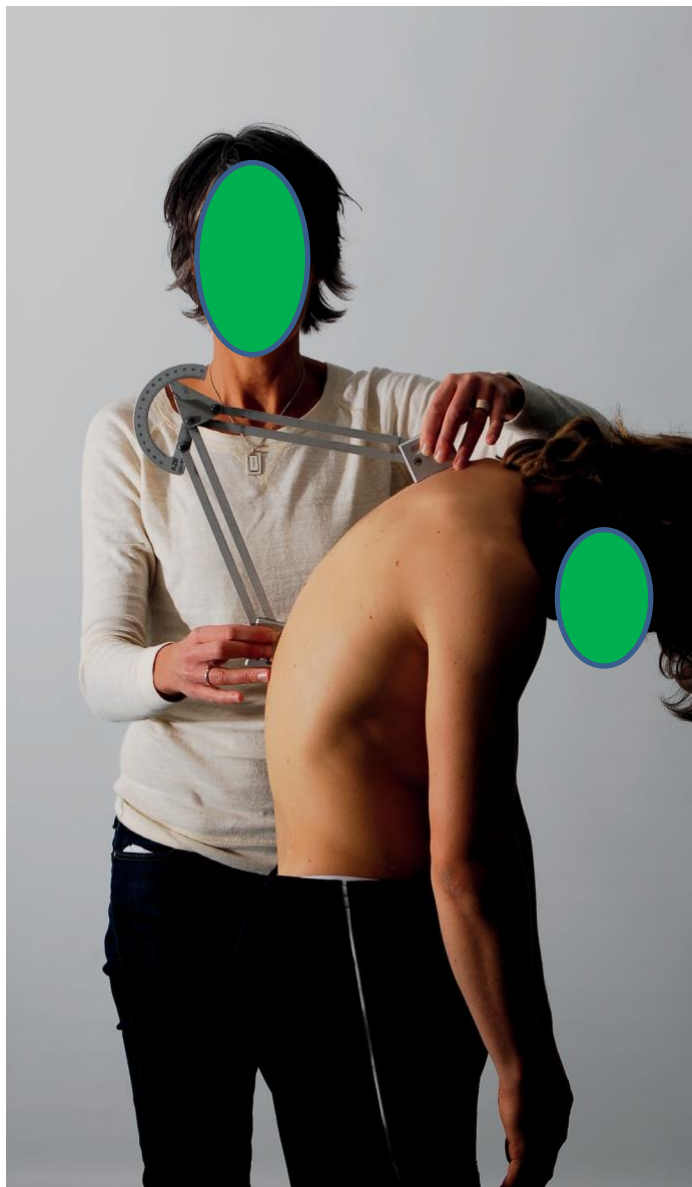


Figure 17. The Debrunner Kyphometer.

The Digital Goniometer

The Goniometer has been used in previous studies of cam-type morphology in athletes^{24,99,100}. The digital goniometer (DG) (HALO medical devices, Australia) functions the same as a universal goniometer, but has laser

beams instead of arms to measure the angle in degrees between to landmarks, when assessing range of motion (Figure 18)⁹⁹⁻¹⁰³. Intra- and interrater reliability and validity have been found to be good to excellent for the DG in healthy subjects^{101,103}.

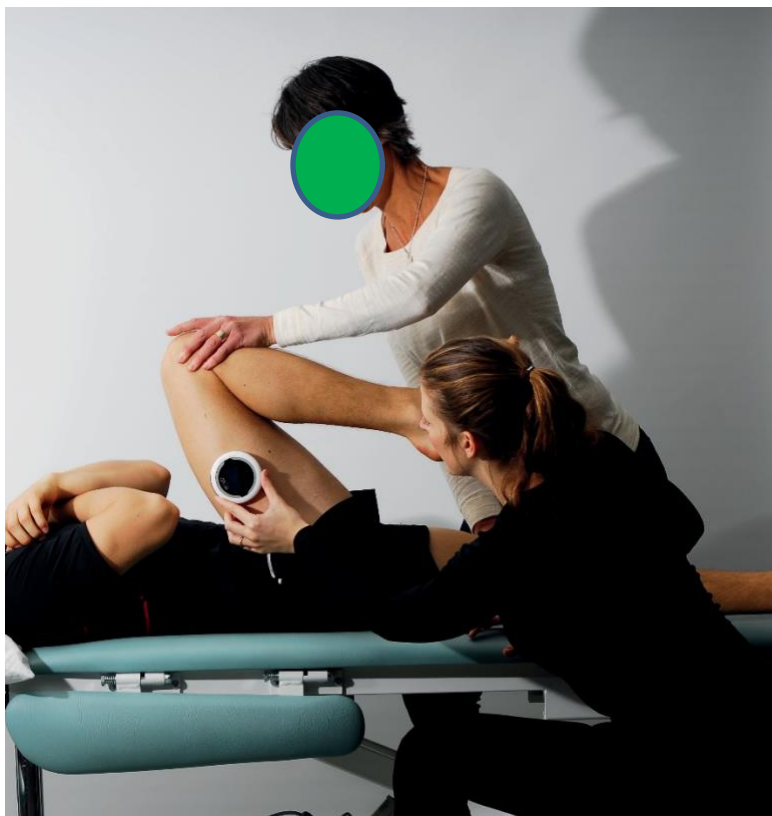

Figure 18. The digital goniometer.

Patient reported outcome measures (PROMS)

Objective measurements such as ROM, radiological images and functional tests are all from the clinician’s point of view. To assess the patient’s point of view, subjective measures such as questionnaires or interviews, can be used. PROMS are questionnaires completed by patients to measure perceptions of their general health in relation to a specific illness, condition or treatment.

Back and hip questionnaire

The hip and back specific questionnaires has been developed and used in several studies by Swärd et al.¹⁰⁴ and Baranto et al.¹⁰⁵, as well as several other studies^{106,107}. It investigates hip pain and low back pain, as well as general health and sporting activity. Pain is self-assessed and graded as mild, moderate or severe. The location, type of pain and the intensity were investigated, and to measure intensity the Visual

Analogue Scale (VAS) was used. Moreover, the questionnaire evaluates the onset and duration of pain, if the pain was correlated to exercise or competition, and if any hip or spine movements aggravate or relieved the pain.

Radiological examination of the hip

A radiographic investigation is needed to establish the diagnosis of FAIS and different methods have been used; computerized tomography (CT), plain radiograph and Magnetic Resonance Imaging (MRI)¹⁰⁸. Using plain radiographs an AP and lateral view can be sufficient, but the Dunn’s view or the Lauenstien view (Figure 19) are believed to visualize the cam deformity better^{109,110}. The alpha angle is used to quantify the cam morphology and the alpha angle can be measured on plain radiographs, CT and MRI (Figure 7)²⁵. The benefit of using MRI for evaluation of young individuals is the avoidance of unnecessary radiation.

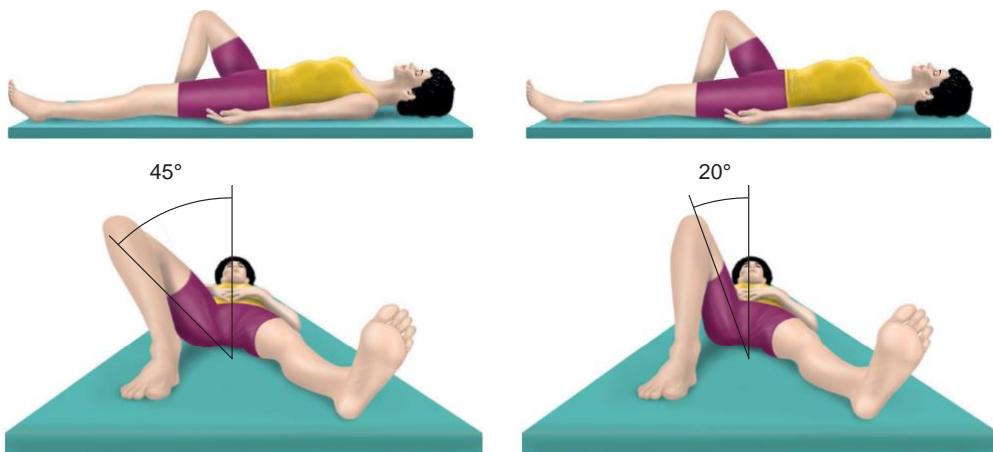


Figure 19. The Dunn view (right) or the modified Lauenstein view (left) are often used to visualise a cam morphology. Both tests are performed with the patient in the supine position, and the knee flexed 45°. The Dunn view is acquired with 20° abduction and the modified Lauenstein with 45° abduction.

Validity of Clinical examinations

Validity and reliability are statistic tools to evaluate the quality of research. Validity calculates

the accuracy of a measure, the extent to which a test measures what it is supposed to measure, and reliability calculates the consistency of a

measure, the correlation and agreement between measurements. The objective structured clinical examination is a common tool to evaluate clinical and practical examination methods. Intraclass correlation coefficient (ICC) is a tool to measure reliability ¹¹¹. ICC is commonly used to quantify the degree of consistency or reproducibility of a measurement made by different examiners, examining the same thing. Interrater reliability is the degree of consistency between examiners, who measure the same group of subjects, and is a score of how much homogeneity there is between the examiners ¹¹¹. Intrarater reliability is the degree of consistency in examinations performed by the same examiner, measuring the same group of subjects, repeated two or more times ¹¹¹. Interrater and intrarater reliability are ways to test validity of an examiner or a measurement. To categorize the level of agreement among ICC values there are different classification systems that can be used. One system proposed by Shrout and Fleiss (1979) categorizes the ICC values as following: less than 0.40 represent poor, values between 0.40 and 0.75 represent fair to good, and values above 0.75 represent excellent reliability ¹¹².

Differential diagnoses

Hip and groin pain is common among athletes and the active population, and the diagnosis is often difficult to establish. When examining a patient with symptoms from the hip or groin it is important to examine, not only the hip and pelvis, but also the lower back and lower extremities. FAIS is a common cause of hip and groin pain, and subjective decreased hip ROM, among athletes ¹¹³. Early hip osteoarthritis is also more common in athletes compared with the general population ¹¹⁴. Other conditions that can give groin pain are referred pain (lumbar spine, sacroiliac joints, pelvic pain) ¹¹⁵, intra-articular causes (labral or chondral injuries, loose bodies, synovitis, avascular necrosis) and extra-articular causes (stress fracture of pelvis or femur, bursitis, piriformis syndrome, hernia). The Doha agreement is a classification system with the aim to divide patients with groin

pain into one out of three categories, making the way for a more structured diagnosis ¹¹⁶; 1. Adductor-related, iliopsoas-related, inguinal-related and pubic-related groin pain. 2. Hip-related groin pain. 3. Other causes of groin pain in athletes. The categories are mainly based on history and clinical examination of the patient.

Association between lumbar spine and hip joint

Young elite athletes are not only at risk of developing FAIS, several studies have displayed that both back pain and spinal abnormalities are common findings in this group. Thoreson et al. ¹⁰⁷ showed that young elite Mogul skiers have significantly greater spinal radiological abnormalities than non-athletes. Witwit et al. ¹¹⁷ showed that young alpine and mogul skiers have significantly more degenerative disc changes than non-athletes. Moreover, a correlation between reported pain in the back and hip has been found among athletes ¹⁰⁶.

The lifetime prevalence of back and hip pain is similar among athletes and non-athletes ¹¹⁸. Skiers have been found to have a greater level of back pain during the past 6 months, with VAS 5.3, compared with VAS 2.4 for non-athletes. These results suggest that many young elite skiers continue to train and compete regularly even with back and/or hip pain.

Several studies have found an association between cam-type FAIS and the motion of the lumbar spine and pelvis. Patients with symptomatic FAIS sit with a more anteriorly tilted pelvis, and achieve sitting with reduced spine flexion and increased hip flexion compared with asymptomatic patients with cam ¹¹⁹. Moreover, they do not squat as low, have a decreased sagittal pelvic range of motion and achieve supine active hip flexion with a more posteriorly tilted pelvis ^{120,121}. Todd et al. ¹²² found that subjects with cam morphology stand with a significantly more retroverted pelvic tilt than subjects without cam. Moreover, they found that flat back (retroverted

Aims

Overall aims

This thesis aims to investigate the prevalence of cam morphology, hip ROM, hip pain and FAIS among young elite skiers and soccer players, and to improve the understanding of who is at risk of developing cam and FAIS. Moreover, to investigate the relationship between hip range of motion and cam, with the aim to contribute to the knowledge of the diagnosis of FAIS, and paving the way for making a more effective diagnosis. Further, to investigate how and if surrounding structures compensate when a cam morphology is present, it was examined how pelvic tilt effects hip ROM (with and without cam morphology).

The main focus was on the cam-type FAIS because it has, in previously studies, been associated with early hip osteoarthritis, and accordingly clinically more relevant.

Specific aims

Study I

To validate how a clinical examination of the hip joint correlates with magnetic resonance imaging (MRI)-verified cam morphology in adolescents.

Study II

To determine the effect of changes in pelvic tilt (PT) on hip ROM, with/without the presence of cam.

Study III

To investigate the prevalence of cam morphology in (1) a group of young elite Mogul and AI- pine skiers compared with non-athletes and (2) between the sexes.

Study IV

To compare the prevalence of cam morphology, hip ROM, hip pain and FAIS in a cohort of young Icelandic soccer players, Swedish male and female alpine and mogul skiers, and young soccer players from FC Barcelona.

Objectives

- To investigate and validate how ROM in a clinical examination correlates to MRI-verified cam morphology in young subjects (Study I).
- To investigate how different postural positions and pelvic tilt affect hip ROM in hips with and without cam (Study II).
- To analyse the prevalence of cam morphology in young athletes compared with a control group of non-athletes, and compare the prevalence of cam between females and males (Studies III).
- To investigate the prevalence of cam morphology, hip pain, decreased hip ROM and FAIS between different groups of athletes (IV).

Patients and methods

Study population

Studies 1-3: All students attending Åre Ski Academy (Grades 1-4, n=76), elite Alpine and Mogul skiers between 16-20 years of age, were invited to participate in these prospective studies. To recruit non-athletes, two of the authors visited several high schools in Östersund, Sweden, and presented the project orally in class. Written information was also distributed amongst participants. The non-athletes invited were all first- year high school pupils and lived in the same area as the skiers. A total of 75 (40 male and 35 female) skiers and 27 (9 male and 18 female) non-athletes agreed to participate in the study.

Study 4: For this study 40 male and 35 female skiers from Åre Ski Academy, Sweden (age range 15-21 years), and 30 young male soccer players from the Icelandic U16 national team (age range 16-18 years), and 30 young male soccer players from FC Barcelona U16 team (age range 15-18 years) participated.

The exclusion criteria for all groups were previously diagnosed hip, spine or pelvic injury, or previous surgery of the hips, spine or pelvis. The inclusion criteria for the non-athletic group was first year high school students who had previously not participated and at present did not participate in any organized sports or physical activity for more than 2 hours per week.

Radiographic examination

All skiers and non-athletes had their MRI examinations at Östersund Hospital, Sweden, and the Icelandic players were examined at the Icelandic Heart Association, Kópavogur, Iceland. Because of logistical problems, the players from Barcelona FC were not examined with MRI. The same identical imaging protocol (MRI of both hips without contrast) was used for all participants. The MRI scanner used in Reykjavik, Iceland, was a Signa Twin-speed; EXCITE 16 channel system 1.5 T (GE Healthcare Bio-Sciences Corp, Piscataway, NJ, USA) and in Östersund, Sweden, a GE Optima 450 Wide 1.5 T (GE Healthcare Bio-Sciences Corp, Piscataway, NJ, USA) was used. Cor T2 Fat Sat and Ax 3D Cube sequences were obtained angled to the femoral neck using a coil surface of HD 8 Channel Cardiac Array (GE Healthcare Bio-Sciences Corp).

Two radiologists, one measured the Swedish skiers and non-athletes, and the other measured the Icelandic soccer players, evaluated the α -angle (Figure 7) and the status of the growth plate. The same senior consultant radiologist guided both. According to Siebenrock et al.⁴⁰, the status of the growth plate was evaluated as being either closed or open. According to Nötzli et al.²⁵, the α -angle was measured (figure 7).

The α -angle was measured at seven locations around the femoral head, from 9 o'clock (posterior) to 3 o'clock (anterior, 180°). If the α -angle was equal to or above 55°, a cam morphology was considered present.

Please see manuscript for intra- and interobserver test results between the radiologists.

Clinical examination

Study 1

The clinical testing of the skiers and non-athletes was carried out at Åre Ski Academy and at the Orthopaedic Department, Östersund Hospital, Sweden. The clinical examination of the Icelandic soccer players was performed at the Icelandic Hearth Association, Kópavogur, Iceland, and the players from FC Barcelona were examined at FC Barcelona's training facilities in Barcelona, Spain.

The clinical examinations were performed in supine and sitting positions. The supine position is most commonly used, and the sitting position was chosen because it made it possible to investigate the relationship between the position of the pelvis and lumbar spine while examining the hip ROM. To increase the reliability of the sitting examination, according to Reichenbach et al., a special chair was constructed to allow participants to sit freely with their legs hanging over the edge (Figure 21)¹³⁵. The chair was useful as it, with the use of four wooden bolsters, fortified the isolation of the movement in the hip by preventing any adduction or abduction of the thighs.

All examinations were performed by co-authors CA and ASA, in a specific order to optimize the accuracy of the measurements. While one examiner examined a participant, the other examiner stabilized, read, and recorded the results. Both CA and ASA performed an intraobserver test, with four months passed between the first and second examination. Both the intra- and interobserver tests included 10 of the skiers. The result of the intraobserver test (ICC analysis) for all physical examinations indicated good to very good agreement (passive hip flexion ICC, 0.77; supine internal rotation ICC, 0.78; external rotation ICC 0.82).

An interobserver test was performed comparing CA and ASA. The examiners were blinded to each other's measurements and the examinations were performed in the same day. The interobserver test (ICC) indicated a good to excellent level of agreement (passive hip flexion ICC, 0.83; supine internal rotation ICC, 0.94; external rotation ICC 0.91).

Functional tests

The standing leg was defined as the leg that felt most natural for the participant to stand on when performing a one-leg activity. To identify the standing leg, the participant was asked to kick a football the way that felt most natural (Figure 22). The participant was then asked to do a pirouette the way that felt most natural and comfortable (Figure 23). The standing leg was not registered if a participant used different legs in the two tests (28 of 89).

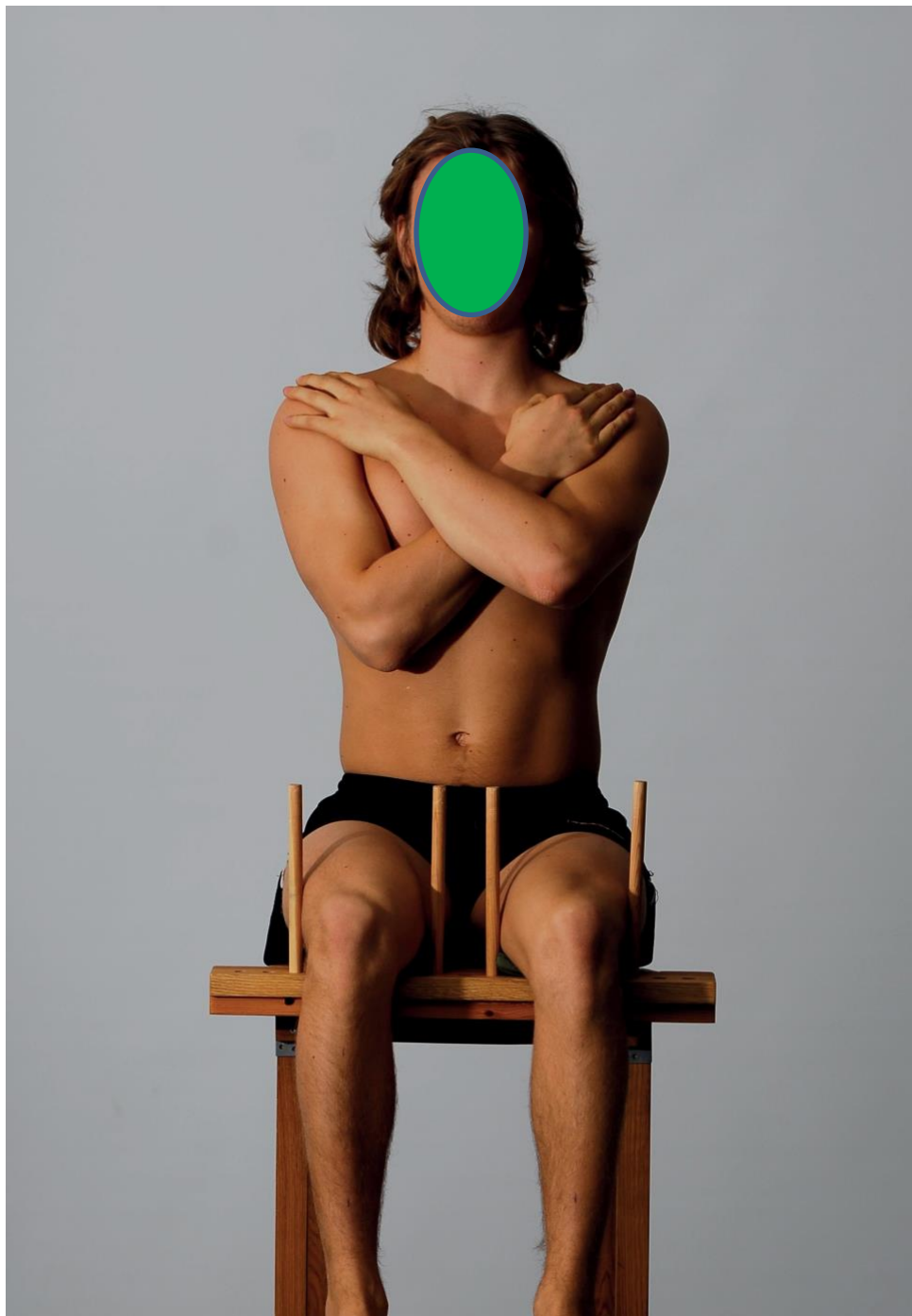

Figure 21. Sitting with a neutral posture, both hips and knees at a 90° angle and the thighs held in position by four wooden bolsters to prevent hip abduction/adduction translation.



Figure 22. Kicking a football, the way that felt most natural.



Figure 23. A pirouette the way that felt most natural and comfortable.

Supine examination

To standardize the supine examination, verbal instructions were given to the participant in the following order; bend your knees, place your feet flat on the bed, raise your pelvis from the bed, lower your hips onto the bed and then straighten your legs. This helped place the participant in a neutral, aligned position prior to the measurements.

Passive hip-joint flexion (Figure 24): A reference line was drawn from the middle of the lateral femoral condyle and the greater trochanter by one examiner. The digital goniometer was initially calibrated and zeroed. It was then held in place, by the same examiner, with its laser beams set along the previously marked line of reference. The other examiner flexed the hip and knee joints. The leg was raised in the sagittal plane, avoiding abduction or adduction of

the hip. The examiner also maintained pressure on the contralateral thigh to minimise pelvic rotation. Passive hip flexion was recorded in degrees. This process was then repeated for the opposite hip.

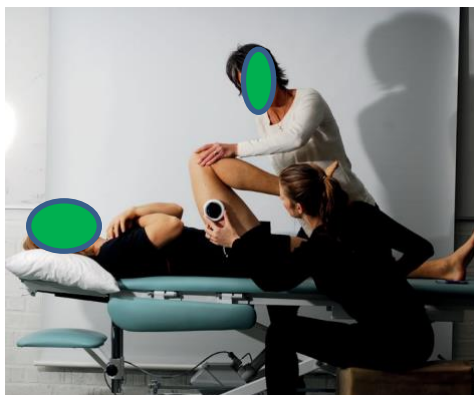

Figure 24. Passive hip joint flexion.

Passive internal rotation of the hip (Figure 25):

Passive flexion, in the sagittal plane, was introduced to the hip and knee joint to 90° by one examiner. The other examiner marked a line of reference from the apex of the patella to mid-way between the lateral and medial malleoli. With the hip and knee held at 90° of flexion, the goniometer was calibrated, zeroed and hand-held with its laser beams set on the previously marked reference line. One examiner's hand was placed around the participant's iliac crest to prevent accessory lumbo-pelvic translation, while the other held the thigh manually in a vertical position. The other examiner held the leg in a horizontal position and internally rotated the hip until the point of initial resistance. The examiner who stabilized the pelvis also noted the first movement of the pelvis, which matched the endpoint of internal rotation felt by the other examiner. In this way, the accuracy of the measured internal rotation was double-checked by both examiners.

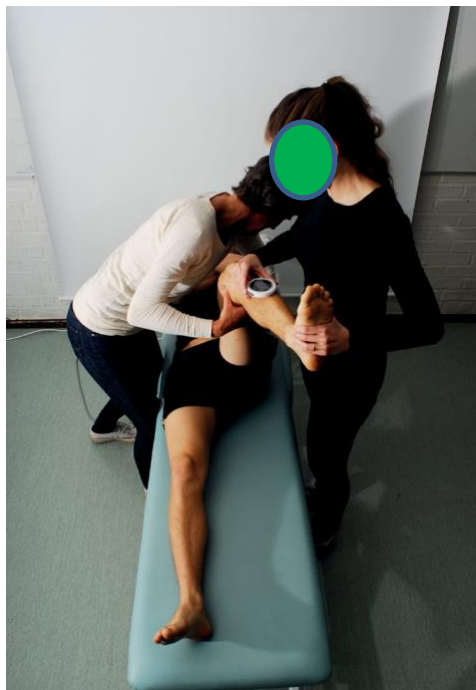


Figure 25. Passive internal rotation of the hip.

Hip anterior impingement test (FADIR) (Figure 26):

With the hip and knee flexed at 90° and maximally internally rotated, the examiner adducted the hip until resistance, according to Klaue et al.¹³⁶. The examiner held this position for a few seconds. This examination was graded with three possible options; no pain, discomfort or pain. In earlier studies, the sensitivity, specificity, positive and negative predictive value have been reported with large variations^{90,93,137}.

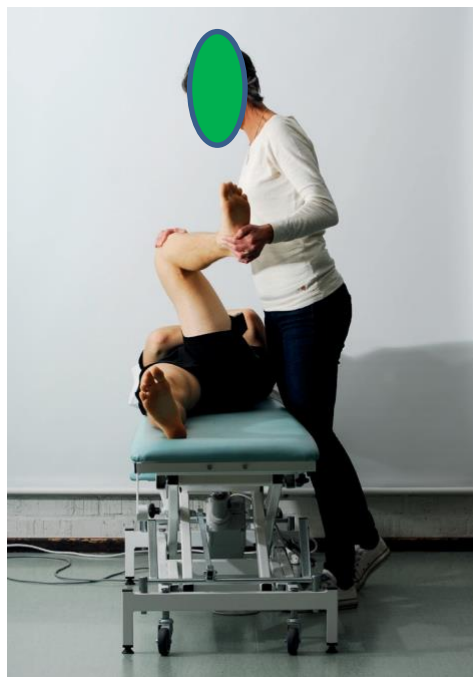


Figure 26. The FADIR test.

Patrick or Faber's test (Figure 27):

This examination was performed as previously described by Ross et al. and Byrd et al., but it included the use of a digital goniometer for quantitative measurements¹³⁸⁻¹⁴⁰. In previous studies, the sensitivity, specificity, positive and negative predictive value of FABER have been reported with large variations^{90,93,137}. The digital goniometer was calibrated and zeroed and held in place, by one examiner, with the laser beams set on the reference line previously marked along the tibia. One examiner

stabilized the pelvis to prevent/minimize accessory lumbo-pelvic rotation and to keep the pelvis in a neutral stabilized position. The other examiner raised one of the participant's legs and placed the participant's ankle superior and lateral to the contralateral knee. This motion creates hip joint flexion, abduction and external rotation. The participants were instructed to relax and lower the tested leg, either to the point of pain or to the end-point of motion. The angle was recorded in degrees. This process was then repeated for the opposite hip in exactly the same manner.

Seated examination

Sitting with both hips and knees placed at a 90° angle and the thighs held in position. Due to the anatomical differences in the thigh circumference distally, a 1 cm thick pad was placed under the distal thighs to ascertain that the femurs

were in a horizontal position. To standardize the sitting position, participants were instructed to focus their eyes on a point straight ahead on the wall and have their arms folded across their chest, hands on opposite shoulders.

Hip-joint internal and external rotation range of motion testing: Measurements of the internal and external rotations of the hip joints were performed using a digital goniometer, calibrated, zeroed and hand-held along the previously marked reference line along the tibia. The reference line made it possible to set and hold the goniometers laser beams in the same position during the measurement.

Internal and external rotations were measured in three different pelvic and lumbar spine positions as follows.

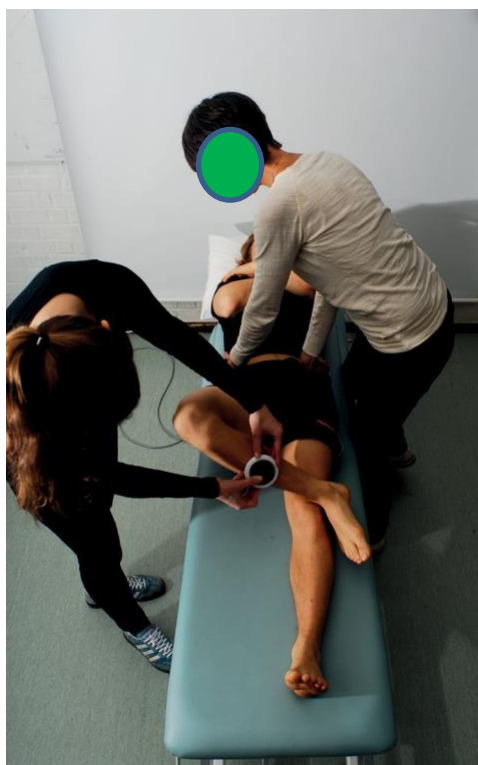


Figure 27. Patrick or Faber's test.

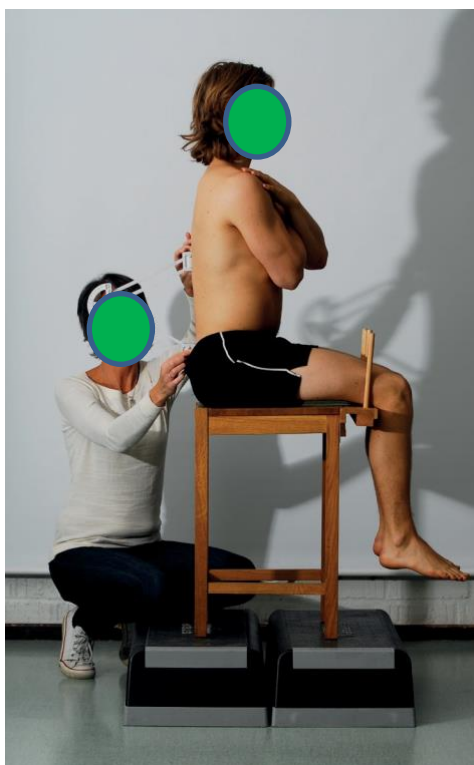


Figure 28. Neutral lumbar position in sitting.

Neutral lumbar position

To measure the lumbar position when sitting in a neutral position, the participant was instructed to sit in a straight position, thus creating a straight, vertical line from his/her shoulder to the hip (Figure 28). Measurements of the pelvic incline for three different pelvic positions (neutral, maximum ante- and maximum retroversion) using the PALM palpation meter (Performance Attainment Associates, St Paul, Minnesota, USA) were carried out as described by Todd et al. and Azevedo et al. (Figure 16) ^{141,142}. Lumbar spinal sagittal positions (neutral, maximum extension and maximum flexion) using the Debrunner Kyphometer (Protek AG, Bern, Switzerland) were recorded, as described by Todd et al. (Figure 17) ¹⁴².

The angle of pelvic incline was measured on both sides and recorded. When measuring the internal and external rotation of the hips, the lumbar spine position was re-evaluated, with the Kyphometer, before changing sides, to ensure the same lumbar position when measuring both hips. One examiner stabilized the thigh and pelvis on the examined side and passive internal rotation was then performed, to the point of initial resistance, by the other examiner. The examiner stabilizing the thigh and pelvis also observed the initial movement of the pelvis, which matched the end-point of internal rotation palpated by the other examiner. In this way, the accuracy of the internal rotation was double-checked. The rotation was recorded in degrees. This process was repeated for the opposite hip and the same procedure was then repeated for the passive external rotation measurement.

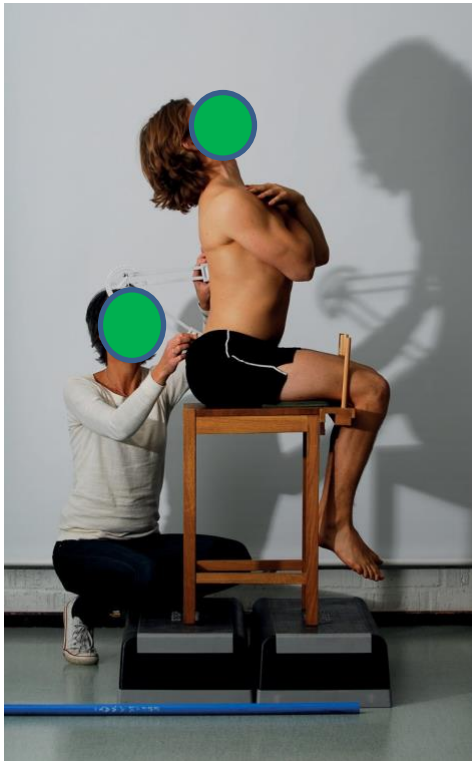


Figure 29. Lumbar spine in maximum extension, in sitting.

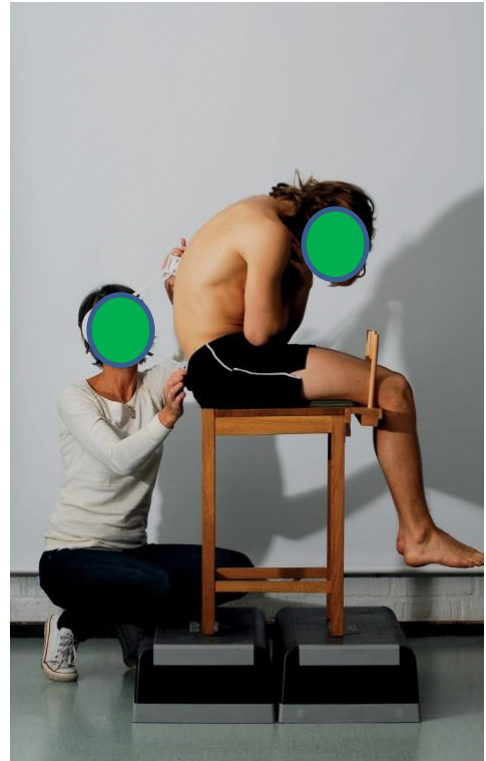


Figure 30. Lumbar spine in maximum flexion (SLUMP position), in sitting.

Lumbar spine in maximum extension

The participants were instructed to arch their lumbar spine and tilt the pelvis forward, thereby increasing the anteversion of the pelvis and lumbar lordosis (Figure 29). The lumbar spine position and the angle of pelvic anteversion were measured, as previously described. In this position, passive internal and external rotations were measured in degrees; the participant was instructed to adopt the neutral position between each test for a short rest and the lumbar spine position was re-measured before measuring the other hip.

Lumbar spine in maximum flexion (SLUMP position)

The participant was instructed to flex his/her lumbar spine and tilt his/her pelvis backwards to the end-point, essentially increasing the retroversion of the pelvis and lumbar kyphosis (Figure 30). The lumbar spine position and the angle of pelvic retroversion were measured as previously described. In this position, passive internal and external rotations were measured in degrees; the participant was instructed to adopt the neutral position between each test for a short rest and the SLUMP position was re-measured before measuring the other hip.

Study II

In Study II the seated examination, previously described for Study I was used. Internal and external hip rotations were measured in three different pelvic and lumbar spine positions; neutral, maximal extension of the lumbar spine and maximal flexion of the lumbar spine.

Study IV

In Study IV the same protocol for the clinical examination was used as previously described for Study I, but only a few of them were used in the final analysis.

Hip and groin pain questionnaires; Study

IV. In Study IV all participants answered the back and hip questionnaire, to assess previous and present levels of hip pain, according to Swärd et al.¹⁰⁴ and Baranto et al.¹⁴⁵. The Swärd-Baranto questionnaire includes three questions related to the prevalence of hip pain.

Statistical analysis; Studies I-IV

All students at the Åre Ski Academy were invited to participate in the present studies and these individuals defined the entire study population and therefore no power analysis was calculated prior to the study. This applies for the soccer teams as well, as all members of the teams were invited to participate. In regards to the non-athletes, the intention was to have a group comparable in size with the skiers, but it turned out to be difficult to recruit non-athletes.

The analyses were carried out using IBM SPSS Statistics, version 26 (IBM Corp). The data in the studies were statistically described in terms of mean and standard deviation (SD) and range, or as number and percentages when appropriate. The normal distribution of the data was tested with a Kolmogorov–Smirnov test. The interrater reliability of the measurements was determined with the intraclass correlation coefficient (ICC, 2,1) (2-way random model, absolute agreement, single measures). To categorize the level of agreement among ICC values, the classification system proposed by Shrout and Fleiss was used (1979). ICC values less than 0.40 represent poor, values between 0.40 and 0.75 represent fair to good, and values above 0.75 represent excellent reliability¹¹².

SEM, a reliability statistic which, quantifies measurement error in the same units as the original measurement was calculated as $SEM=SD$, where SD is the standard deviation of the difference between observations. All tests were two-sided and significance was set at $p<0.05$ for each test.

Study I

An independent t-test and Pearson chi-square test were performed to compare variables (cam vs no-cam). A chi-square test for association was conducted between pain/discomfort of the anterior impingement test, and cam vs no-cam.

Study II

An independent two-sample t-test was used to compare hip ROM, pelvic and lumbar positions between the hips with cam morphology and those without. A dependent t-test for paired samples was used to compare hip ROM dependent on the position of the pelvic and lumbar spine. Pearson chi-square test was performed to evaluate the distribution of cam between the genders.

Study III

Pearson chi-square test was performed to evaluate the distribution of cam between groups.

Study IV

Please see manuscript for further information.

Ethical Considerations

All studies were approved by the Regional Ethical Review Board at The Sahlgrenska Academy, Gothenburg University, Gothenburg, Sweden (ID number: 692-13). Participation, in all studies, were completely voluntary and participation could be withdrawn at any time. Written consent was given by all individuals and, for participants younger than 18 years, written consent was obtained from their parents.

To recruit both skiers and non-athletes, co-authors ASA and CA, with the help of Åke Hamberg, MD, visited high-schools in Jämtland, Sweden and presented the study. After the presentation they placed themselves outside the classroom and the youths who were interested in participation could approach them. Some were not sure, and then ASA or CA would call a week later to discuss participation with the youth and sometimes with their parents. From the Icelandic soccer players, whom were investigated with MRI, written consent was obtained from their parents. From the players from Barcelona, who answered the questionnaire and were examined clinically without an MRI examination, written consent was obtained from the players.

Only one out of 74 pupils from Åre Ski Academy chose not to participate in the studies. We interpreted this high number, as a genuine interest in their own health and their awareness of the high injury prevalence among themselves. It was difficult to control, or know, if there was any amount of peer pressure. The fact that we asked for the parents' consent of all pupils aged under 18, can't eliminate the risk of peer pressure, but it might indicate that the participation was discussed. Another factor that might have influenced the large percent of participation from the Åre Ski Academy was that co-author CA worked as a physiotherapist at their school. She worked there for 10 years, and all the injured pupils visit her for treatment and guidance. The village, Åre, is a small town and Cecilia is a well-known local. This might also have influenced the large number of participants. In terms of the soccer teams, all players were invited, and we cannot know for sure if there was any peer-pressure from players and/ or trainers, that might influence participation or not.

With regards to the control group, there are no ethical considerations related to the recruitment. In the control group there was a noticeable number of drop-outs, indicating that participation was voluntary.

Some questions in the questionnaire, could possibly be regarded as an invasion of privacy. For this reason, the questions were as neutral as possible. No personal information has been or will be published.

All clinical examinations were performed by co-authors AA and CA. The young participants were examined wearing shorts and a sports top. There is a possibility that some youths might have felt exposed and/or embarrassed in this clothing, but we tried to avoid this by minimizing the examiners to only two, and having a direct and humble approach during the examination.

To evaluate cam morphology of the hips, an MRI scanner was used. The MRI scanner is a long tube into which the person being examined is positioned within. There is not much space and this can be uncomfortable, and even frightening for some individuals. Written information was handed out prior to the examination and the participants answered a questionnaire investigating claustrophobia (fear of having no escape and being in closed or small spaces or rooms).

During the examination, the participants, had a bell in their hand and could terminate the examination at any time.

The only risk in our studies was the radiation used for the sagittal X-ray examinations of the spine (these results are not published in this thesis, but in other studies where ASA is co-writer) and therefore this examination was approved by The Radiation Safety Committee at Sahlgrenska University hospital. The examination equalled 0.5 millisievert (mSv) and this is generally believed to be of no significance. The natural background radiation in Sweden is approximately 1 mSv/year. Taking account of different unnatural sources such as medical radiographic imaging, radon in houses, flight trips etc., the mean dose per year to a “normal” Swedish citizen is 4-5 mSv/year. The lifetime risk of developing cancer from radiation is approximately 5-6% per Sievert, but for young people (15-20 years) it is higher, approximately 8-9% per Sievert. This means that the lifetime risk of developing cancer for the young test persons is approximately 0.0045% per X-ray image of the spine, that means 4.5 persons per 100.000)

The skier, and co-authors CA and ASA, have given written consent to published the photos in this thesis.

Summary of Papers and Results

Study I

Range of hip joint motion is correlated with MRI-verified cam deformity in adolescent elite skiers.

Study design: Cross-sectional study.

Aim: To investigate if there is an association between cam morphology and hip range of motion (ROM) among young athletes and non-athletes.

Results: The mean age of the enrolled population was 17.7 (± 1.4) years. The differences in hip ROM between the cam and the non-cam group is presented in Table 2 and 3 in the article. The cam group had reduced range of motion in all clinical ROMs, compared with the non-cam group. Reduced internal rotation in supine and sitting, supine passive hip flexion and the FADIR test, were the only tests where a significant correlation with cam morphology was found. The growth plates of all participants were closed.

Conclusion: The presence of a cam morphology on MRI is associated with reduced internal rotation in supine and sitting positions, passive supine hip flexion, and the FADIR in adolescents. Hip joint tests that are both clinically relevant and statistically significant, can assist in the assessment of subjects with groin pain and facilitate the diagnosis of cam-type FAIS statistically significant, can assist in the assessment of subjects with groin pain and facilitate the diagnosis of cam-type FAIS.

Study II

The effect of pelvic tilt and cam on hip range of motion in young elite skiers and non-athletes.

Study design: Cross-sectional study.

Aim: To determine the effect of changes in PT on hip ROM, and if the presence of a cam morphology further effects the change.

Results: There was a significant between the seated posture (pelvic tilt and the lumbar position) and hip ROM (Table 2 in the article). Internal hip rotation decreased significantly when the subjects sat with an extended posture with maximum anterior PT ($p < 0.0001$). Internal hip rotation increased significantly when the subjects sat with a flexed posture with maximum posterior PT ($p < 0.001$). In an extended posture with maximum anterior PT, the external rotation significantly decreased ($p < 0.0001$), but there was no difference in flexed posture with maximum posterior PT. The hips with cam morphology responded to the changes in position in a similar manner to the hips without cam, but they had reduced internal hip rotation in all three positions (found in Table 3 in the article).

Conclusion: Dynamic changes in PT significantly influence the hip ROM in young people, independent of cam or no-cam morphology. This indicates that it could be possible for an individual to avoid impingement in the hip joint, in the presence of cam, by tilting the pelvis posteriorly. Moreover, it is important to stabilise and minimise movement in the spine and pelvis when examining hip ROM, to achieve correct measurements.

Study III

Young elite alpine and mogul skiers have a higher prevalence of cam morphology than non-athletes

Study design: Cross-sectional study

Aim: To investigate the prevalence of cam morphology in (1) a group of young elite Mogul and Alpine skiers compared with non-athletes and (2) between the sexes.

Results: Cam morphology was significantly more prevalent among the skiers than the non-athletes (found in Table 1 in the article), and the males (61%) compared with the females (21%). Among the skiers there was a significant difference between the sexes, 68% of the males and 28% of the females had cam morphology. This difference between the sexes was not found in the non-athletic group. Between female skiers and female non-athletes, and mogul and alpine skiers, no significant difference was found. The growth plates of all participants were closed.

Conclusion: Young elite skiers were shown to have a higher prevalence of cam morphology of the hips compared with non-athletes, and cam morphology was more prevalent in males.

Study IV

Differences in cam morphology and hip range of motion between young skiers and soccer players

Study design: Cross-sectional study.

Aim

To compare the prevalence of cam morphology, hip ROM, lifetime prevalence of hip pain and cam-type FAIS in a cohort of young Icelandic soccer players, Swedish male and female al- pine and mogul skiers, and young soccer players from FC Barcelona.

Results and Conclusion: Please find results and conclusion in the manuscript.

Discussion

The aims of this thesis were to investigate the prevalence of cam morphology, hip ROM, hip pain and FAIS among young elite skiers and football players. Moreover, to investigate the relationship between hip ROM and cam, and hip ROM and PT, (with and without cam morphology). All studies, in this thesis, investigated the radiological prevalence of cam morphology of the hip. Studies I, II and IV also included a clinical examination, and in study IV a hip-spine questionnaire was answered. The main findings in this thesis are as follows; cam is more prevalent among male soccer players and skiers than in non-athletes and female skiers; clinical examination of the hip joint has low specificity, but it is an important part of diagnosing FAIS. Soccer players have restricted hip ROM compared with skiers, independent of cam morphology; FAIS is more prevalent among skiers, of both sexes compared with soccer players in the presence of cam; hip ROM changes depending on the pelvic tilt and the posture of the lumbar spine, and therefore it is important to develop a standardized protocol that includes stabilizing the spine and pelvis when examining the hip, in order to be able to perform adequate measurements

Who develops cam?

There are still many questions that need to be answered regarding the mechanisms behind the formation of cam morphology. Siebenrock et al. suggest that cam morphology is a consequence of an alteration of the growth plate (extension of the growth plate), and that repetitive and heavy load, during the years associated with the adolescent growth spurt, is a possible cause for the development of cam⁵⁷. Bailey et al. showed that there is a significant time difference in peak bone velocity (bone mineral content accumulation) between girls (12.5 years) and boys (14.1 years)⁶⁰. The peak height velocity appeared approximately 1 year earlier than the peak bone velocity (girls 11.8 and boys 13.5 years). Because of the lag time between the peak height velocity and the peak bone velocity, along with higher hormonal levels, the skeleton is probably more vulnerable during the years accompanying the adolescent growth spurt⁶⁰. The growth plate has been shown to be the most vulnerable part in the growing hip, and biomechanical studies have shown that the growth plate is especially sensitive to heavy loading during hip flexion and/or external rotation^{66,67}. Repetitive microfractures, which could disrupt the arterial blood supply to the growth plate and chondrocytes, could possibly result in a delayed closure of the growth plate and the development of cam morphology^{68,69} (Figure 10). Or maybe it is the properties of the hyaline cartilage of the open growth plate, that reacts on abnormal and repetitive biomechanical stress, resulting in an extension of the growth plate and the cam morphology. Imaging modality, definition of cam morphology, age and sex, may affect the prevalence of cam morphology found in different studies. In the present thesis, we chose MRI to avoid unnecessary radiation of the young participants, and it has been used in several previous studies investigating cam. When the α -angle was above or equal to 55° , a cam morphology was considered present^{21,24,25,40,54,146}. Out of the seven measurement (from 9 o'clock to 3 o'clock), the largest α -angle was measured at 1 o'clock in the antero-superior region of the femoral head–neck junction^{113,147}. All participants in the present thesis had closed growth plates, and as it is believed that cam develops before growth plate closure all participants were considered comparable^{23,54}. In the elite skier's group, there was an equal distribution between the sexes, but in the control group, there was an overrepresentation of females. Unfortunately, there were no female soccer players included in study IV.

There is great variance between different studies in terms of the prevalence of cam in the general population (5-75%)³¹. Gosvig et al. reported in their study on 4,151 asymptomatic adults that cam was present in 17% of males and 4% of females³⁵. Others have reported a prevalence of cam morphology in asymptomatic study populations ranging from 5.2 to 25% (females 5.2–5.4% and males 9–25%)³⁶⁻⁴⁰. In Study I, the prevalence was 19% (females 12% and males 33%). This is slightly higher than in some other studies. We aimed to have a minimum of inclusion and exclusion criteria to minimize the risk of subgroups and selection bias within the groups. The control group in Studies I-III was selected from the same geographical area as the Åre Ski Academy is located. The population in this region is generally active and therefore they might be more active than the average high-school student.

Moreover, it was difficult to recruit controls and the limited cohort size, compared with the skiers, might have affected the results. Especially the male controls are underrepresented in this study and this might have contributed to the relatively high prevalence of cam among the controls. There is still a need for large cohorts investigating the prevalence of cam morphology in the general population and asymptomatic individuals

Sports with high intensity (soccer, track and field, ice hockey, American football and basketball) that place a great degree of loading on the hip joint, particularly during the adolescent growth spurt, are considered a risk factor for the development of cam morphology^{23,24,36,40,54-57,72,73,77}. In Study III a significantly higher prevalence of cam amongst the skiers compared with the non-athletes (49% vs. 19) was shown. In a study by Philippon et al., investigating the prevalence of cam in a relatively small group of male skiers with closed growth plates, they found a lower prevalence of cam among male skiers than in Study III (40% vs 61%). A reason for this could be that they did not specify at which level or type of skiing (Mogul, Alpine, cross-country, etc.) the skiers trained/competed.

Further, in Study III a significantly lower prevalence of cam was found amongst the female subjects compared with the male (22% vs. 61%). This correlates well with previous studies that have shown a higher prevalence of cam morphology among male subjects compared with females^{31,74,76}. Only few studies on females and cam morphology have been published, and there are no previous investigations on the prevalence of cam morphology in female skiers. Other studies have reported a slightly higher prevalence of cam among women than in study III, but the methodology differs between the studies (radiographic method, cut-off for cam morphology measurement, etc.). For example, in a group of female mixed athletes, Kapron et al. found that 48% had cam morphology⁷⁶. In a group of elite female soccer players, Gerhardt et al. found that 50% had cam, compared to 68% in elite male soccer players⁷⁴. In a group of professional ballet dancers, Harris et al. found a lower prevalence than in Study III, with 12% of the female dancers having cam morphology, compared with 57% of the males⁷⁵.

Because females enter the pubertal growth spurt earlier than males, they have an earlier closure of their growth plate of the proximal femur⁶⁰. Carter et al. found a statistically significant positive association between the size of the cam lesion and menarche age⁵⁸. When calculating skeletal maturation (approximately two years following menarche¹⁴⁸), they found that players who reached skeletal maturity earlier had smaller cam morphology compared with those whose growth plates fused at an older chronological age. The discrepancy of cam between the sexes found in different studies could possibly be explained by that when the demands of training and competing increases, the female growth plate is already closed and therefore no, or a smaller cam morphology develops. The both sexes, of the study population of this thesis, train and compete together, making them comparable¹⁴⁹. More studies including female athletes are needed to establish a greater understanding of the development, risk factors and symptoms of cam morphology.

Diagnosing cam-type FAIS

In study I it was found that reduced hip joint internal rotation in the supine and sitting positions is associated with MRI-verified cam morphology. No significant differences were shown between the validity of the three different lumbar and pelvic positions, and for the diagnosis of hip joint cam-type FAIS. In addition to internal rotation, passive supine hip flexion and the anterior impingement test (FADIR), were shown to be significantly associated with MRI-verified cam. This is in accordance with previous studies^{20,89,150}. In a study by Sink et al. they found that 100% of the participants with FAIS had a positive FADIR test. Clohisy et al. presented similar results, with 88% of the symptomatic FAIS hips having a positive FADIR test^{89,150}. In Study I, we found that 82% of the participants with cam morphology of the left hip had a positive FADIR test and 85% on the right side.

Participants with symptomatic FAIS, in a study by Clohisy et al., had a mean hip flexion of 97° and internal rotation of 9°, and among the participants with asymptomatic FAIS a mean hip flexion of 101° and internal rotation of 12° was found⁸⁹. The tendency in Study I is similar to that of Clohisy et al., but the mean values of ROM are higher. However, the participants in the Study I were from a healthy population sample without diagnosed FAIS, and are therefore not entirely comparable with the group in Clohisy 's study. It's tempting to speculate if the small differences in ROM between the cam and non-cam groups, in Study 1, could be the relatively late fusion of the separate centres of ossification that form the bones of the pelvis. There is a complete union of the iliac crest, in all individuals, by the age of 23 years, but partial fusion of the iliac crest can occur from 15 to 22 years of age¹⁵¹. The ischial epiphysis appears between 13 and 16 years of age, and starts to fuse at the superior rim of the epiphyseal surface, and continues to develop into the ramal epiphysis, which will continue to fuse toward the pubic body with complete union by 20 and 21 years of age¹⁵¹. It is possible that the acetabulum permits slight movement before fusion, making it harder to clinically establish the diagnosis of a cam-type morphology of the hip clinically.

Although, the results of Study I were able to show a statistically significant difference between the cam-group and no-cam group, these results must be interpreted with caution, as the mean differences between the cam group and no-cam group were small. Moreover, these results emphasize that a combination of symptoms, positive clinical tests, and imaging findings should all be used for the diagnosis of FAIS¹⁸. At present it appears that a clinical examination alone, is not sufficient to diagnose cam morphology.

In *Study IV*, we used the same standardised protocol as in Study I. The two groups of soccer players had significantly reduced ROM compared with both male and female skiers. Compared with all three groups of males, female skiers had significantly greater hip ROM in nearly all hip ROM. Previously reported hip ROM in athletes varies between studies, and females are known to have a greater joint laxity^{11,40,152,153}. Internal rotation has been reported to range between 11-33° in soccer players^{84,154,155}, and a reduced passive internal rotation of the hip has been reported as being 25° or less^{6,87}. The soccer players in Study IV had reduced ROM compared to other studies^{84,154,155,152,153,156}. One reason for this could be the different methods used when measuring hip ROM^{84,154,155}. In study IV we used both sitting and supine measurements, where

all accessory movements were controlled and stabilised.

In study II it was shown that both hip IR and ER in the sitting position were affected by the PT. It is possible to overestimate ROM if the anatomical structure being evaluated is not stabilised. In Study IV a standardised protocol was followed, and therefore the differences found in hip ROM, between the skiers and soccer players, are most probably due to differences between the sports of soccer and skiing.

In a study of cadaveric human pelvises, Birmingham et al. showed that, when a hip with cam morphology was internally rotated, the motion at the pubic symphysis increased significantly more compared with a hip without cam morphology⁴⁶. This implies that loss of hip ROM puts higher demands on surrounding structures. Decreased hip ROM might increase the risk of injuries⁴³⁻⁴⁵, and therefore the results are clinically relevant. It is of importance to identify a decreased hip ROM as early as possible, not only so that the athlete can be guided during training to prevent overload injuries and pain, but also to investigate the presence of cam morphology.

Questionnaire

An association between the presence of cam morphology and lifetime prevalence of hip pain was only found in male skiers. There are still many questions about the association between cam morphology and hip pain/symptoms^{35,157-161}. Some studies have displayed an association between larger α -angles and hip pain/symptoms¹⁵⁸⁻¹⁶⁰. The soccer players in Study IV reported less hip pain, compared with both male and female skiers. The reason for this is not fully understood, but it might be due to the different demands and exposure of the hips, between the two sports. Or it could be the soccer player's restricted hip ROM, that protects them from impingement in the hip joint.

FAIS

In *Study IV* it was shown that out of all athletes who had cam morphology, both male and female skiers were more prone to fulfil the diagnostic criteria of FAIS, compared with the Icelandic players. An explanation for this could be the different demands of soccer and skiing. In skiing the hips are constantly exposed to both flexion and internal rotation under heavy load⁸⁰.

The biomechanics of soccer and skiing are very different, and might explain the restricted hip ROM found in soccer players. The results of this thesis could indicate that the degree of exposure of the hips, in different sports is important in the development of FAIS in athletes with cam morphology. Moreover, it highlights the complexity of establishing the diagnosis of FAIS, with the female skiers having a greater hip ROM, but more hip pain, compared with the Icelandic soccer players, who had decreased hip ROM but less pain.

Relationship between hip joint, pelvis and lumbar spine.

The most important finding in Study II was that there is a correlation between hip ROM and the position of the pelvis (anterior or posterior tilt) and the lumbar spine (flexed, neutral, ex-tended posture). Hips with cam morphology had reduced internal hip rotation (but not external hip rotation) in all three positions, but they responded to the changes in position the same way that hips without cam did. It was possible to control and minimize any increased movement in the lumbar spine,

pelvis, and hip joints, by testing the internal and external rotation in sitting, making the results more reliable. These results suggest that it is of great importance to stabilize the pelvis and lumbar spine, when examining the hips, to achieve accurate results. In the position with maximum lumbar spine extension and pelvic anteversion, the rotation of the hip joint decreased. With maximum lumbar spine flexion and pelvic retroversion, the hip joint rotation increased. This is in accordance with a study by Ross et al. where they found, with the use of 3-dimensional models, in patients with FAIS, that an increase of 10° in anterior PT resulted in a significant decrease in internal hip rotation in 90° of flexion¹⁶². Further they found that a 10° increase in posterior PT lead to a significant increase in internal hip rotation in 90° of flexion. As mentioned in the introduction there are several studies that have investigated, and found, an association between cam-type FAIS and the motion of the lumbar spine and pelvis. Taking all these results into consideration, there is a possibility that individuals with cam morphology could tilt the pelvis posteriorly to increase ROM and minimize painful impingement in the hip joint¹²⁰.

In a group of patients undergoing total hip arthroplasty, the correlation between back problems and hip ROM has been recognized, where it has been shown that patients with multilevel degenerative disc disease (DDD) sit with significantly more hip flexion than spine flexion compared with patients without DDD¹⁶³. They also stand and sit with an increased posterior PT. Baranto et al.¹⁶⁴ and Thoreson et al.¹⁶⁵ showed that the weakest parts of the growing porcine lumbar spines, when compressed into flexion and extension, were the growth zones. The ring apophysis fuses to the vertebrae as late as the age of 17–25 years, which is several years later than the closure of the proximal femoral growth plate, and the development of cam morphology^{166,167}. Therefore, it may be possible that a reduction in hip ROM caused by cam morphology forces the lumbar spine to a flat back or kyphosis. The heavy loads, on the spine and hips, in elite skiing may increase the anterior load on the open ring apophysis causing overload injuries/growth disturbances of the spine. There is a possible causal correlation between spinal pathologies and hip ROM, and further investigation of the relation-ship is of importance.

This thesis showed, in accordance with other studies, that cam is more prevalent among athletes and especially male athletes. The clinical examination is an essential part in diagnosing FAIS, but alone it is not robust enough to establish the diagnosis of cam morphology. Demands in some sports, for example soccer, appear to restrict hip ROM more compared with other sports, for example skiing. Different sports provide different patterns of exposure to impingement in the hip joint and this seems to be a possible factor affecting who develops FAIS in the presence of a cam morphology. The spino-pelvic-hip complex is a unit affecting each other and this needs to be considered when examining an individual with hip or groin pain. Moreover, there is a possibility that individuals with cam morphology tilt their pelvis posteriorly to minimize impingement and increase hip ROM.

General discussion

The aim of the present thesis was that the research would contribute to the understanding of the aetiology of FAIS, and help preventing young athletes from developing FAIS. Research proposes that the formation of cam morphology is an adaption to heavy high-impact sporting activities during the pubertal growth spurt, and in the meantime specialization in single sports at an early age increases^{40,168,169}. This puts high demands on preventive measures and proper rest if the aim is to

decrease the prevalence of FAIS among athletes. Abrahamson et al. found in their article (personal communication) that almost 3/4 of young elite skiers from the Åre Ski Academy retired from their elite career after finishing high school, with 1/2 of them reporting that it was because of injuries obtained from skiing.

In a recent study, including 200 subjects from the general population in the UK, 47% (56% of men and 37% of women) had cam morphology³³. There is great variance between different studies in terms of the prevalence of cam morphology in the general population (5- 75%)³¹. In Studies III and IV, it was shown that male skiers and soccer players had a higher prevalence of cam compared with age matched non-athletes and female skiers. The general understanding is that cam is more prevalent among certain groups of athletes and also among men compared with females⁷⁷. In a cohort of young cross-country skiers, cam morphology was not more common than in a group of young non-athletes¹⁷⁰. This could indicate that it is the type of training, and not so much the intensity or volume, which is of importance in the development of cam morphology of the hip. Taking this into account, it might be possible to have a longer time perspective and change the training routines of young growing athletes. When the growth plates are closed it would be possible to increase the load put upon the hips and spine during sports. Moreover, it is important to take children's biological age into account, and not the chronological, when planning training routines to minimize the load placed upon the open growth zones (Figure 9). An expert opinion on the matter could be helpful, so that the sport institutions had guidelines to follow when training young growing athletes. Hopefully this would lead to an increase of athletes, who are able to continue to train and compete in their specific sports, after graduation. the question is how to avoid the development of cam morphology (and other overuse injuries, such as spondylolysis of the pars interarticularis) but maintain the athletic skill? Unfortunately, this thesis does not give the answer.

In Study I, we found an association between cam morphology and decreased internal rotation, passive hip flexion and the FADIR test. These results correlate well with previous findings, even if there are inconsistencies between studies, and many tests have a high sensitivity, but a low specificity^{18,42,89,90,171}. In Study I we investigated a group of healthy adolescents, while many other studies have investigated hip ROM in groups of patients with hip and groin symptoms.

In Study IV we aimed to investigate and compare the hip ROM in skiers and soccer players, and found that the soccer players, both from FC Barcelona and the Icelandic U16 team, had significantly reduced hip ROM compared with the skiers. This is probably due to the specific demands of soccer, and is important as the risk of injuries increases with a decreased ROM. Decreased hip ROM has been shown to increase the risk of injuries, such as Anterior Cruciate Ligament (ACL) injuries, groin strains and athletic pubalgia, and Tak et al. found total hip ROM to be the most consistent factor related to groin pain in athletes^{44-46,172}. Only male skiers presented an association between hip pain and cam morphology, and this is in accordance with other studies describing an uncertainty whether cam morphology will result in clinically relevant symptoms⁴².

Moreover, we found that young skiers are at a higher risk of developing FAIS compared with soccer players. Why some individuals develop FAIS and others have an asymptomatic cam morphology is still not fully understood. The different demands and loads on the hip joints, in different sports, may play an important role in if, and when an athlete develops symptoms. Thoreson et. al, and Witwit et al. found in the same group of skiers, as in the present thesis, that the skiers have significantly

greater spinal abnormalities and more degenerative disc changes than non-athletes^{107,117}. Todd et al.¹²² found that the skiers were shown to have significantly less standing and sitting lumbar and pelvic mobility than healthy non-athletes. Moreover, they found that flat back (retroverted pelvis and low lumbar lordosis) is an overrepresented spinal curvature among young skiers in the presence of cam morphology. If the skiers have a high proportion of spinal pathologies, and restricted mobility of the lumbar spine and pelvis, it may be postulated that they cannot compensate effectively when their hip ROM is restricted, and therefore develop symptoms due to the collision inside the hip joint caused by the cam morphology. As a part of understanding the risk factors of developing FAIS in the presence of cam, it would be interesting to investigate in longitudinal studies how many of the study participants will develop FAIS in the medium- to long term follow-up.

Another aspect of FAIS is the increased risk of developing early hip osteoarthritis (OA) in the presence of cam morphology^{20,130}. Do individuals with symptomatic FAIS have a higher risk of developing OA than individuals with an asymptomatic cam morphology? In Study IV, it was shown that the Icelandic soccer players had an equal prevalence of cam morphology as the male skiers, but significantly less prevalence of FAIS. The prevalence of hip OA is high in Iceland, five-fold higher compared with populations in southern Scandinavia, and particularly for those younger than 70 years¹⁷³. Genetic predisposal may play an important role, but it makes it tempting to speculate if the cam morphology, symptomatic or not, is a predictor of hip OA. This further increases the incentive to develop national guidelines on how to train the coming generations in a sustainable way, minimizing the risk of overload injuries.

In Study II, the aim was to investigate the relationship between PT and hip ROM, and how PT might compensate a restricted hip ROM. Pierannunzii et al.¹²⁰ debate that the lumbo-pelvic-femoral complex might compensate hip sagittal ROM restriction by changing the lumbar curvature and PT, keeping the subject asymptomatic despite a cam morphology. Moreover, Todd et al. found that subjects with cam morphology stand with a significantly more retro-verted pelvic tilt than subjects without cam¹²². This correlates well with the finding in Study II, where we found that hip ROM changes depending on the pelvic tilt, indicating that it could be possible to compensate a reduced hip ROM by tilting the pelvic posteriorly.

Why is this thesis needed?

There are not many studies investigating the prevalence of cam morphology among skiers, and especially not female skiers, therefore this group of young athletes needs to be investigated in further detail. The skier's group, in this thesis, is unique because youths of both sexes, train together and are therefore exposed to an amount of load, that is believed to be comparable, over time. Since the first study addressing FAIS, was published in 2003 by Ganz et al, there has been a tremendous interest in this condition²⁰. Different theories about the aetiology have been proposed and the prevalence among different sports have been investigated. The prevalence of cam morphology is highly prevalent in the general population, and even more among athletes. The mechanism behind the formation of cam and which factors that lead to symptomatic FAIS is not well understood. These findings are important in the preventive work of cam-type FAIS, and further research is needed.

If we would understand the aetiology of FAIS better, and if there was a way to train young growing individuals in a more controlled manner, making their bodies last longer, both the individual and the sporting community would gain much. Taking skiing as an example, it is difficult to avoid heavy loading in flexion, as this position is a part of the sport, and even if the youths avoid training with

heavy loads in the gym, there will always be high G-forces (acceleration) during a run down the slopes. Current research highlights the importance for free unstructured play, and participation in a variety of sports during growth to improve diverse motor skill development^{174,175}. Early age specialization increases the risk for burnout, overuse injuries and overtraining. So, guidelines on how and how much a growing individual should train are of major importance. Taking skiing as an example, maybe the youth with open growth zones shouldn't ski every day of the week, but instead focus on other activities, dividing the load on the growth zones over time and improving other skills than skiing.

Before it is possible to create any guidelines, the prevalence of a condition needs to be investigated, and hopefully this thesis can contribute to the overall knowledge of the risks of high impact training on young growing individuals.

Strengths and Limitations

The studies in this thesis are all observatory and therefore have limitations in terms of causal relations by their design. Because the studies are not randomized, the results may be affected by both known and unknown confounders, which we have tried to limit with the use of strict exclusion criteria and a control group consisting of non-athletes for comparison. No pilot study was performed, and therefore no power analysis could be performed. All students at the Åre Ski Academy were invited to participate in Studies I-III and these individuals defined the entire study population. The same applied for the soccer players in Study IV.

Studies I-III included both athletes and non-athletes of both sexes living in the same geographical area, with a medium cohort size. Including the non-athletes is a strength to this study and places the athletes results in perspective. The skiers were equally divided between female and male skiers. A highly relevant strength of the present study is that from early ages, boys and girls train together and are therefore exposed to a similar amount of load in training and competition, even if the male athletes use heavier loads etc. Regardless, the prevalence of cam morphology was shown to be considerably lower amongst the female population. The study groups in all studies were not fully matched according to age and sex, and even if the Icelandic and Swedish skiers came from similar environments, the players from FC Barcelona came from all over the world, which might have affected the internal validity.

The inclusion criteria selected only a healthy population; however, this may have limited the ability to distinguish greater differences in hip ROM in the presence of cam morphology, compared with a group of patients waiting for FAIS surgery. The external validity was strengthened by the different nationalities and the fact that both genders were included in the thesis. However, a larger sample group with equal subgroup participation might have shown greater differences between the skiers and non-athletes, hips with cam and no-cam morphology, but also amongst the skiers divided into female/male and skiing disciplines.

Clinical examination is always dependent on the examiner, but we increased the accuracy by validating the protocol, and limiting the number of examiners to just two and using a standardized method.

Other limitations include the accuracy and interpretation of the radiological measurements, even though the study method was validated - with good results - for the MRI, which strengthens the results. It is believed that the development of cam morphology does not occur once the growth plate

is closed and the skeleton is mature. All the subjects in the present study had closed growth plates of the hip and were in this way comparable. A limitation of Study IV is that the Barcelona players weren't radiologically examined. A greater number of MRI's could possibly have given some clues to the reason of the underlying cause for the restricted hip Rom among the soccer players. The PROMs in Study IV were not validated, and potentially affected by recall and cultural bias. The questionnaires were translated to Icelandic and English. In Spain, the English version was orally translated to Catalan, by the FC Barcelona's team doctor, to those players that did not understand English well. The questionnaire investigating hip pain among the skiers was not recorded directly in conjunction with the hip ROM examinations, which might have affected the outcome. For the other groups the questionnaire and clinical examination was performed in the same day.

It's hard to assess and evaluate the cumulative physical activity, and therefore it's hard to draw any conclusions on what specifically is the cause for cam morphology and larger sample groups would probably increase the regression to mean.

Conclusions

Taken together, the results suggest that young elite skiers and soccer players have a higher prevalence of cam morphology of the hip than non-athletes. This appears to be more prevalent in males.

Although the differences, between the group with cam morphology and the group without cam, were small, the individuals with verified cam morphology (α -angle above or equal to 55°) had significantly reduced internal rotation of the hip in both the supine and sitting positions, as well as passive supine hip flexion, and the FADIR test.

Young male soccer players had significantly reduced hip ROM, compared with male and female skiers. Both male and female skiers with cam morphology were more prone to meet the diagnostic criteria of FAIS compared with Icelandic soccer players.

Changes in pelvic tilt (anterior tilt or posterior tilt) and posture (flexed, neutral, or extended lumbar spine) significantly influence hip ROM in hips with or without cam morphology. The hips with cam morphology had reduced internal hip rotation in general, but the effect of pelvic tilt and posture on hip ROM was the same in hips with and without cam.

Future Perspectives

There is strong evidence that repetitive heavy high-impact sporting activities, especially during the pubertal growth spurt, increases the risk of cam morphology of the hip, which in turn increases the risk of early hip OA.

The prevalence of cam morphology in asymptomatic subjects (non-athletes) varies between studies and therefore this needs to be investigated further in larger cohorts.

It appears that youths participating in high load impact sports such as hockey, soccer and American football, are more prone to develop cam morphology compared with sports with less strain and load impact⁷⁷, but these results must be interpreted with caution as there is a huge number of athletes and sports that haven't been investigated. A Norwegian study investigated the prevalence of cam among elite cross-country skiers and they found that they did not have a higher prevalence of cam compared with non-athletes¹⁷⁰. The results highlight an interesting issue about which type of load that drives the development of cam, but the sample size is small.

Most studies on cam investigate the prevalence among male athletes and in a recent review by Knapik et al. 1,160 males were included, but only 53 females. It is believed that cam is more prevalent in males, but to understand cam-type

FAIS future research needs to focus on large cohorts of different athletes of both sexes, with different training routines, to understand which type of load that growing athletes should avoid.

It appears that young children are specializing in one sport only earlier these days, and thereby probably increase the risk of overuse-injuries due to repetitive load. Moreover, it is of importance to investigate how often and how long a growing athlete needs to rest in-between trainings to minimize the risk of developing cam, and to investigate the importance of being all-round well trained to reduce the load on the joints.

The results from *Study I* indicate that reduced hip ROM can give a hint on whom has or will develop a cam morphology. Further research is needed to establish how the clinical examination can be used in athletic clubs and teams, for early interventions and further examinations when an athlete presents decreased ROM. The clinical examination should also be used to assess which individuals should be passed through to radiological investigations.

It would be interesting to examine the cohort of this thesis, after their pelvic physes have fused, and study whether the difference in the clinical parameters between the cam and non-cam groups is greater compared with the findings in the present study.

The results from *Study IV* indicate that the load and exposure to impingement of the hip, in the presence of a cam morphology, increases the risk to develop pain. Moreover, males and females appear to be at equal risk of developing FAIS, in the presence of cam morphology, when exposed to the same type of sport. It has further been proposed that females develop symptoms in the presence of a smaller cam, but in general it is believed that the greater the alpha angle, the greater the risk of developing symptoms^{30,159,160}. However, whom will develop symptoms and decreased hip ROM (FAIS) in the presence of a cam morphology is still not fully understood and needs to be investigated further. Why is cam morphology often asymptomatic and what are the risk factors for developing FAIS?

The youths of today have a more sedentary lifestyle, compared with previous generations, making them less all-round trained and probably more vulnerable to overuse injuries. The negative effect of a more inactive lifestyle does not only affect the hips, but the whole individual's body and mind. Early specialization, less play, inactive lifestyle with increasing screen time, and early retirement from sport are important factors that the sporting communities around today's children need to address. Another important aspect of the early specialization is the high number of children who do not qualify and are left outside the sporting community, but that is another thesis to write.

Study II showed that hip ROM is affected by the PT and further research is needed to investigate how the spino-pelvic-hip complex affects and is affected by a cam morphology.

There is an increasing interest in terms of surgical treatment of cam and pincer, and the results indicate improved hip function and reduced pain. Longitudinal register data is needed to evaluate the long-term effects of the treatment. Can surgical correction of pincer and cam prevent the hip from being painful (FAIS), and can it slow down or stop the development of OA? At present there are no evidence supporting prophylactic surgery in the presence of an asymptomatic cam morphology, and long-term research is needed¹⁷⁶.

Acknowledgements

A special thanks to Leif Swärd, Associate Professor, MD, PhD, co-author and my father, and Cecilia Agnvall, PT and co-author, whose ideas were the source to this thesis and all the research from the Åre Ski Academy and the soccer teams. You have both inspired me with your professional skill, unique anatomic and biomechanical understanding of the body, and the great humbleness you meet each human with. You are my role models and inspiration.

Adad Baranto, Professor, MD, PhD, supervisor and co-author. Thank you for always being encouraging, kind, helpful, inspiring and optimistic, and for letting me be a part of your research team. Thank you for the fast revisions and irreplaceable help with this thesis.

Jón Karlsson, Professor, MD, PhD, co-supervisor and co-author. Thank you for always answering my emails really fast, the guidance, kindness, and for always being positive and encouraging. Thank you for the fast revisions and irreplaceable help with this thesis.

Olof Thoreson, MD, PhD, co-supervisor and co-author, thank you for the optimism, friendship and encouragement. Without all your help, guidance and annoying accuracy this thesis would have been difficult to write.

Carl Todd, PhD, MSc, DO and co-author. Thank you for all your help when planning the studies, your clever ideas and help with writing articles, and this thesis. Thank you for encouraging me and for your friendship.

Páll Sigurgeir Jónasson, PhD, MD and co-author. Another clever man in this group of researchers, always with a great comment that makes the article 40% better.

Josefin Abrahamson, PT, thank you for your friendship and help with writing Study IV. Also thank you for tireless help with all sorts of questions regarding research and life in general.

Mikael Sansone, MD, PhD, co-author, thank you for your collaboration with Study III.

Gauti Laxdal, MD, co-author, thank you for the help with Study IV, and for the splendid assistance and all practical help when Cecilia, Leif and myself were in Reykjavik for the examinations of the Icelandic soccer players.

Ricard Pruna, MD, PhD, co-author and team doctor for FC Barcelona, thank you for the help with Study IV, and for the splendid assistance when Cecilia, Adad and myself were in Barcelona for the examinations of the FC Barcelona soccer players.

Helena Brisby, MD, PhD, Professor, former head of the department of Orthopedics, thank you for giving me the possibility to conduct this research.

Ola Rolfson, MD, PhD, Professor, current head of the department of Orthopedics, thank you for giving me the possibility to conduct this research.

Christer Johansson, Statistical Consultant, thank you for all the help with converting ideas into statistical calculations. Thanks for explaining when I get things wrong, and for being an enthusiastic and inspiring part of the team.

Cina Holmer, research administrator, thank you for your irreplaceable help with all things academic. When I, quite often, have felt completely lost in the world of Academics, you have always been there to guide and fix everything.

Inci Baranto, for always being so kind and letting me borrow a blouse, when all my luggage disappeared in Rome, and I was one of the speakers at SICOT Orthopaedic World Congress.

Åke Hamberg, MD, thank you for the help with recruiting non-athletes and constructing the remarkable chair.

Flemming Pedersen, MD and Zaid Obady, MD, at the Department of Radiology, Östersunds Hospital, Sweden, for your help with the radiological examinations. Károly Hrabák, MD, Mölndal Hospital, Sweden, for the help with the radiological examinations.

The staff at FC Barcelona's training facilities, Barcelona, Spain, and the staff at the Icelandic Heart Association, Kópavogur, Iceland, for support, help and receiving us with such kindness.

Gudni Ólafsson, thank you for the layout design, it would have been impossible without your help.

Pontus Andersson, thank you for the outstanding illustrations, which greatly improved the pedagogical content of the thesis.

Nina and Carl Bennet for the encouragement and financial support that enabled this thesis.

Göteborgs läkarsällskap for financial support.

FOU Region Jämtland Härjedalen for financial support.

Åre Hälsocentral, for the support and giving me time off to write this thesis.

My parents, Kristina and Leif, for your love and guidance through life. For giving me a solid ground to stand on, a belief in that nothing is impossible and a will to always strive to be better than I was yesterday.

My sister Lovisa and brother Pelle, thank you for always being there and for all the love. You are my closest friends and best babysitters. And thank you Pelle for your sharp mind and good advice when it comes to research.

To my mother-, father- and my sisters-in-law's with their families, thank you for all the love and encouragement through the years and for being such a fun crowd to be part of.

Thank you, Carl, my husband, for your unconditional support and love. Not once did you question if it was a good idea to have three children in 4.5 years, work full time and write this thesis whenever possible. You supported me all the way and made space for the research. To Sigrid, Ragnhild and Edward, you are everything to me.

References

1. Werner CM, Ramseier LE, Ruckstuhl T, et al. Normal values of Wiberg's lateral center-edge angle and Lequesne's acetabular index--a coxometric update. *Skeletal Radiol*. 2012;41(10):1273-1278.
2. Murray DW. The definition and measurement of acetabular orientation. *J Bone Joint Surg Br*. 1993;75(2):228-232.
3. Shultz SJ, Nguyen AD, Schmitz RJ. Differences in lower extremity anatomical and postural characteristics in males and females between maturation groups. *J Orthop Sports Phys Ther*. 2008;38(3):137-149.
4. Shier D, Butler J, Lewis R. *Hole's essentials of human anatomy and physiology*. McGraw-Hill; 2003.
5. Anwander H, Beck M, Büchler L. Influence of evolution on cam deformity and its impact on biomechanics of the human hip joint. *J Orthop Res*. 2018.
6. Magee DJ. *Orthopedic physical assessment*. Sixth edition. ed: St. Louis, Missouri : Elsevier Saunders; 2014.
7. Onyemaechi N, Anyanwu E, Obikili E, Ekezie J. Anatomical basis for surgical approaches to the hip. *Ann Med Health Sci Res*. 2014;4(4):487-494.
8. Ito H, Song Y, Lindsey DP, Safran MR, Giori NJ. The proximal hip joint capsule and the zona orbicularis contribute to hip joint stability in distraction. *J Orthop Res*. 2009;27(8):989-995.
9. Wagner FV, Negrão JR, Campos J, et al. Capsular ligaments of the hip: anatomic, histologic, and positional study in cadaveric specimens with MR arthrography. *Radiology*. 2012;263(1):189-198.
10. Cerezal L, Kassarian A, Canga A, et al. Anatomy, biomechanics, imaging, and management of ligamentum teres injuries. *Radiographics*. 2010;30(6):1637-1651.
11. Ferguson SJ, Bryant JT, Ganz R, Ito K. The influence of the acetabular labrum on hip joint cartilage consolidation: a poroelastic finite element model. *J Biomech*. 2000;33(8):953-960.
12. Ferguson SJ, Bryant JT, Ganz R, Ito K. An in vitro investigation of the acetabular labral seal in hip joint mechanics. *J Biomech*. 2003;36(2):171-178.
13. Rousouly P, Pinheiro-Franco JL. Biomechanical analysis of the spino-pelvic organization and adaptation in pathology. *Eur Spine J*. 2011;20 Suppl 5(Suppl 5):609-618.
14. Lewis CL, Laudicina NM, Khuu A, Loverro KL. The Human Pelvis: Variation in Structure and Function During Gait. *Anat Rec (Hoboken)*. 2017;300(4):633-642.
15. Gruss LT, Schmitt D. The evolution of the human pelvis: changing adaptations to bipedalism, obstetrics and thermoregulation. *Philos Trans R Soc Lond B Biol Sci*. 2015;370(1663):20140063.
16. Yuan BJ, Bartelt RB, Levy BA, Bond JR, Trousdale RT, Sierra RJ. Decreased range of motion is associated with structural hip deformity in asymptomatic adolescent athletes. *Am J Sports Med*. 2013;41(7):1519-1525.
17. Martin HD, Shears SA, Palmer IJ. Evaluation of the hip. *Sports Med Arthrosc*. 2010;18(2):63-75.
18. Griffin DR, Dickenson EJ, O'Donnell J, et al. The Warwick Agreement on femoroacetabular impingement syndrome (FAI syndrome): an international consensus statement. *Br J Sports Med*. 2016;50(19):1169-1176.
19. Beck M, Kalhor M, Leunig M, Ganz R. Hip morphology influences the pattern of damage to the acetabular cartilage: femoroacetabular impingement as a cause of early osteoarthritis of the hip. *J Bone Joint Surg Br*. 2005;87(7):1012-1018.
20. Ganz R, Parvizi J, Beck M, Leunig M, Notzli H, Siebenrock KA. Femoroacetabular impingement: a cause for osteoarthritis of the hip. *Clin Orthop Relat Res*. 2003;417:112-120.
21. Ito K, Minka MA, 2nd, Leunig M, Werlen S, Ganz R. Femoroacetabular impingement and the cam-effect. A MRI-based quantitative anatomical study of the femoral head-neck offset. *J Bone Joint Surg Br*. 2001;83(2):171-176.
22. Pfirrmann CW, Mengiardi B, Dora C, Kalberer F, Zanetti M, Hodler J. Cam and pincer femoroacetabular impingement: characteristic MR arthrographic findings in 50 patients. *Radiology*. 2006;240(3):778-785.
23. Agricola R, Heijboer MP, Ginai AZ, et al. A cam deformity is gradually acquired during skeletal maturation in adolescent and young male soccer players: a prospective study with minimum 2-year follow-up. *Am J Sports Med*. 2014;42(4):798-806.
24. Siebenrock KA, Kaschka I, Frauchiger L, Werlen S, Schwab JM. Prevalence of cam-type deformity and hip pain in elite ice hockey players before and after the end of growth. *Am J Sports Med*. 2013;41(10):2308-2313.

25. Notzli HP, Wyss TF, Stoecklin CH, Schmid MR, Treiber K, Hodler J. The contour of the femoral head-neck junction as a predictor for the risk of anterior impingement. *J Bone Joint Surg Br*. 2002;84(4):556-560.
26. Sutter R, Dietrich TJ, Zingg PO, Pfirrmann CW. How useful is the alpha angle for discriminating between symptomatic patients with cam-type femoroacetabular impingement and asymptomatic volunteers? *Radiology*. 2012;264(2):514-521.
27. Lohan DG, Seeger LL, Motamedi K, Hame S, Sayre J. Cam-type femoral-acetabular impingement: is the alpha angle the best MR arthrography has to offer? *Skeletal Radiol*. 2009;38(9):855-862.
28. Pollard TC, Villar RN, Norton MR, et al. Femoroacetabular impingement and classification of the cam deformity: the reference interval in normal hips. *Acta Orthop*. 2010;81(1):134-141.
29. van Klij P, Reiman MP, Waarsing JH, et al. Classifying Cam Morphology by the Alpha Angle: A Systematic Review on Threshold Values. *Orthop J Sports Med*. 2020;8(8):2325967120938312.
30. Levy DM, Hellman MD, Harris JD, Haugom B, Frank RM, Nho SJ. Prevalence of Cam Morphology in Females with Femoroacetabular Impingement. *Front Surg*. 2015;2:61.
31. van Klij P, Heerey J, Waarsing JH, Agricola R. The Prevalence of Cam and Pincer Morphology and Its Association With Development of Hip Osteoarthritis. *J Orthop Sports Phys Ther*. 2018;48(4):230-238.
32. Dickenson E, Wall PD, Robinson B, et al. Prevalence of cam hip shape morphology: a systematic review. *Osteoarthritis Cartilage*. 2016;24(6):949-961.
33. Dickenson EJ, Wall PDH, Hutchinson CE, Griffin DR. The prevalence of cam hip morphology in a general population sample. *Osteoarthritis Cartilage*. 2019;27(3):444-448.
34. Raveendran R, Stiller JL, Alvarez C, et al. Population-based prevalence of multiple radiographically-defined hip morphologies: the Johnston County Osteoarthritis Project. *Osteoarthritis Cartilage*. 2018;26(1):54-61.
35. Gosvig KK, Jacobsen S, Sonne-Holm S, Gebuhr P. The prevalence of cam-type deformity of the hip joint: a survey of 4151 subjects of the Copenhagen Osteoarthritis Study. *Acta Radiol*. 2008;49(4):436-441.
36. Agricola R, Bessemes JH, Ginai AZ, et al. The development of Cam-type deformity in adolescent and young male soccer players. *Am J Sports Med*. 2012;40(5):1099-1106.
37. Gosvig KK, Jacobsen S, Sonne-Holm S, Palm H, Troelsen A. Prevalence of malformations of the hip joint and their relationship to sex, groin pain, and risk of osteoarthritis: a population-based survey. *J Bone Joint Surg Am*. 2010;92(5):1162-1169.
38. Hack K, Di Primio G, Rakhra K, Beaulé PE. Prevalence of cam-type femoroacetabular impingement morphology in asymptomatic volunteers. *J Bone Joint Surg Am*. 2010;92(14):2436-2444.
39. Reichenbach S, Juni P, Werlen S, et al. Prevalence of cam-type deformity on hip magnetic resonance imaging in young males: a cross-sectional study. *Arthritis Care Res (Hoboken)*. 2010;62(9):1319-1327.
40. Siebenrock KA, Ferner F, Noble PC, Santore RF, Werlen S, Mamisch TC. The cam-type deformity of the proximal femur arises in childhood in response to vigorous sporting activity. *Clin Orthop Relat Res*. 2011;469(11):3229-3240.
41. Clohisy JC, Baca G, Beaulé PE, et al. Descriptive epidemiology of femoroacetabular impingement: a North American cohort of patients undergoing surgery. *Am J Sports Med*. 2013;41(6):1348-1356.
42. van Klij P, Ginai AZ, Heijboer MP, Verhaar JAN, Waarsing JH, Agricola R. The relationship between cam morphology and hip and groin symptoms and signs in young male football players. *Scand J Med Sci Sports*. 2020;30(7):1221-1231.
43. López-Valenciano A, Ayala F, Vera-García FJ, et al. Comprehensive profile of hip, knee and ankle ranges of motion in professional football players. *J Sports Med Phys Fitness*. 2019;59(1):102-109.
44. Tak I, Engelaar L, Gouttebauge V, et al. Is lower hip range of motion a risk factor for groin pain in athletes? A systematic review with clinical applications. *Br J Sports Med*. 2017;51(22):1611-1621.
45. Gomes JL, de Castro JV, Becker R. Decreased hip range of motion and noncontact injuries of the anterior cruciate ligament. *Arthroscopy*. 2008;24(9):1034-1037.
46. Birmingham PM, Kelly BT, Jacobs R, McGrady L, Wang M. The effect of dynamic femoroacetabular impingement on pubic symphysis motion: a cadaveric study. *Am J Sports Med*. 2012;40(5):1113-1118.
47. Öhlin A, Ayeni OR, Swärd L, Karlsson J, Sansone M. Bilateral femoroacetabular impingement syndrome managed with different approaches: a case report. *Open Access J Sports Med*. 2018;9:215-220.
48. Sansone M, Ahldén M, Jonasson P, et al. A Swedish hip arthroscopy registry: demographics and development. *Knee Surg Sports Traumatol Arthrosc*. 2014;22(4):774-780.
49. Ganz R, Gill TJ, Gautier E, Ganz K, Krügel N, Berlemann U. Surgical dislocation of the adult hip a technique with full access to the femoral head and acetabulum without the risk of avascular necrosis. *J Bone Joint Surg Br*. 2001;83(8):1119-1124.
50. Packer JD, Safran MR. The etiology of primary femoroacetabular impingement: genetics or acquired deformity? *J Hip Preserv Surg*. 2015;2(3):249-257.
51. Pollard TC, Villar RN, Norton MR, et al. Genetic influences in the aetiology of femoroacetabular impingement: a sibling study. *J Bone Joint Surg Br*. 2010;92(2):209-216.
52. Van Houcke J, Yau WP, Yan CH, et al. Prevalence of radiographic parameters predisposing to femoroacetabular impingement in young asymptomatic Chinese and white subjects. *J Bone Joint Surg Am*. 2015;97(4):310-317.
53. Rhyu KH, Chun YS, Jung GY, Cho YJ. Age and sex-related distribution of alpha angles and the prevalence of the cam morphology of the hip in Asians do not differ from those of other ethnicities. *Knee Surg Sports Traumatol Arthrosc*. 2019;27(10):3125-3132.

54. Philippon MJ, Ho CP, Briggs KK, Stull J, LaPrade RF. Prevalence of increased alpha angles as a measure of cam-type femoroacetabular impingement in youth ice hockey players. *Am J Sports Med.* 2013;41(6):1357-1362.
55. Byrd JW. Femoroacetabular impingement in athletes: current concepts. *Am J Sports Med.* 2014;42(3):737-751.
56. Palmer A, Fernquest S, Gimpel M, et al. Physical activity during adolescence and the development of cam morphology: a cross-sectional cohort study of 210 individuals. *Br J Sports Med.* 2018;52(9):601-610.
57. Siebenrock KA, Behning A, Mamisch TC, Schwab JM. Growth plate alteration precedes cam-type deformity in elite basketball players. *Clin Orthop Relat Res.* 2013;471(4):1084-1091.
58. Carter CW, Campbell A, Whitney D, et al. Characterizing cam-type hip impingement in professional women's ice hockey players. *Phys Sportsmed.* 2020:1-4.
59. Malina RM, Bouchard C, Bar-Or O. *Growth, maturation, and physical activity.* Human kinetics; 2004.
60. Bailey DA, McKay HA, Mirwald RL, Crocker PR, Faulkner RA. A six-year longitudinal study of the relationship of physical activity to bone mineral accrual in growing children: the university of Saskatchewan bone mineral accrual study. *J Bone Miner Res.* 1999;14(10):1672-1679.
61. MacKellvie KJ, Khan KM, McKay HA. Is there a critical period for bone response to weight-bearing exercise in children and adolescents? a systematic review. *Br J Sports Med.* 2002;36(4):250-257; discussion 257.
62. Mirtz TA, Chandler JP, Evers CM. The effects of physical activity on the epiphyseal growth plates: a review of the literature on normal physiology and clinical implications. *J Clin Med Res.* 2011;3(1):1-7.
63. Bailey DA. The Saskatchewan Pediatric Bone Mineral Accrual Study: bone mineral acquisition during the growing years. *Int J Sports Med.* 1997;18 Suppl 3:S191-194.
64. Sadeghian SM, Lewis CL, Shefelbine SJ. Predicting growth plate orientation with altered hip loading: potential cause of cam morphology. *Biomech Model Mechanobiol.* 2020;19(2):701-712.
65. Carter DR, Wong M. Modelling cartilage mechanobiology. *Philos Trans R Soc Lond B Biol Sci.* 2003;358(1437):1461-1471.
66. Jonasson PS, Ekstrom L, Sward A, et al. Strength of the porcine proximal femoral epiphyseal plate: the effect of different loading directions and the role of the perichondrial fibrocartilaginous complex and epiphyseal tubercle - an experimental biomechanical study. *J Exp Orthop.* 2014;1(1):4.
67. Roels P, Agricola R, Oei EH, Weinans H, Campoli G, Zadpoor AA. Mechanical factors explain development of cam-type deformity. *Osteoarthritis Cartilage.* 2014;22(12):2074-2082.
68. Laor T, Wall EJ, Vu LP. Physeal widening in the knee due to stress injury in child athletes. *AJR Am J Roentgenol.* 2006;186(5):1260-1264.
69. Shih C, Chang CY, Penn IW, Tiu CM, Chang T, Wu JJ. Chronically stressed wrists in adolescent gymnasts: MR imaging appearance. *Radiology.* 1995;195(3):855-859.
70. Peterson HA. *Physeal injury other than fracture.* Springer Science & Business Media; 2012.
71. Nepple JJ, Vigdorichik JM, Clohisey JC. What Is the Association Between Sports Participation and the Development of Proximal Femoral Cam Deformity? A Systematic Review and Meta-analysis. *Am J Sports Med.* 2015;43(11):2833-2840.
72. Tak I, Weir A, Langhout R, et al. The relationship between the frequency of football practice during skeletal growth and the presence of a cam deformity in adult elite football players. *Br J Sports Med.* 2015.
73. Lahner M, Bader S, Walter PA, et al. Prevalence of femoroacetabular impingement in international competitive track and field athletes. *Int Orthop.* 2014;38(12):2571-2576.
74. Gerhardt MB, Romero AA, Silvers HJ, Harris DJ, Watanabe D, Mandelbaum BR. The prevalence of radiographic hip abnormalities in elite soccer players. *Am J Sports Med.* 2012;40(3):584-588.
75. Harris JD, Gerrie BJ, Varner KE, Lintner DM, McCulloch PC. Radiographic Prevalence of Dysplasia, Cam, and Pincer Deformities in Elite Ballet. *Am J Sports Med.* 2016;44(1):20-27.
76. Kapron AL, Peters CL, Aoki SK, et al. The prevalence of radiographic findings of structural hip deformities in female collegiate athletes. *Am J Sports Med.* 2015;43(6):1324-1330.
77. Knapik DM, Gaudiani MA, Camilleri BE, Nho SJ, Vojs JE, Salata MJ. Reported Prevalence of Radiographic Cam Deformity Based on Sport: A Systematic Review of the Current Literature. *Orthop J Sports Med.* 2019;7(3):2325967119830873.
78. Heinrich D, van den Bogert AJ, Nachbauer W. Relationship between jump landing kinematics and peak ACL force during a jump in downhill skiing: a simulation study. *Scand J Med Sci Sports.* 2014;24(3):e180-187.
79. Kurpiers N, McAlpine PR, Kersting UG. Perspectives for comprehensive biomechanical analyses in Mogul skiing. *Res Sports Med.* 2009;17(4):231-244.
80. Sporri J, Kroll J, Haid C, Fasel B, Muller E. Potential Mechanisms Leading to Overuse Injuries of the Back in Alpine Ski Racing: A Descriptive Biomechanical Study. *Am J Sports Med.* 2015;43(8):2042-2048.
81. Randjelovic S, Heir S, Nordsletten L, Bere T, Bahr R. Injury situations in Freestyle Ski Cross (SX): a video analysis of 33 cases. *Br J Sports Med.* 2014;48(1):29-35.
82. Fröhlich S, Helbling M, Fucentese SF, Karlen W, Frey WO, Spörri J. Injury risks among elite competitive alpine skiers are underestimated if not registered prospectively, over the entire season and regardless of whether requiring medical attention. *Knee Surg Sports Traumatol Arthrosc.* 2020.
83. Keller CS, Noyes FR, Buncher CR. The medical aspects of soccer injury epidemiology. *Am J Sports Med.* 1987;15(3):230-237.
84. Tak I, Glasgow P, Langhout R, Weir A, Kerkhoffs G, Agricola R. Hip Range of Motion Is Lower in Professional Soccer Players With Hip and Groin Symptoms or Previous Injuries, Independent of Cam Deformities. *Am J Sports Med.* 2016;44(3):682-688.

85. Johnson AC, Shaman MA, Ryan TG. Femoroacetabular impingement in former high-level youth soccer players. *Am J Sports Med.* 2012;40(6):1342-1346.
86. Manning C, Hudson Z. Comparison of hip joint range of motion in professional youth and senior team footballers with age-matched controls: an indication of early degenerative change? *Phys Ther Sport.* 2009;10(1):25-29.
87. Holla JF, van der Leeden M, Roorda LD, et al. Diagnostic accuracy of range of motion measurements in early symptomatic hip and/or knee osteoarthritis. *Arthritis Care Res (Hoboken).* 2012;64(1):59-65.
88. Boone DC, Azen SP. Normal range of motion of joints in male subjects. *J Bone Joint Surg Am.* 1979;61(5):756-759.
89. Clohisey JC, Knaus ER, Hunt DM, Leshner JM, Harris-Hayes M, Prather H. Clinical presentation of patients with symptomatic anterior hip impingement. *Clin Orthop Relat Res.* 2009;467(3):638-644.
90. Tjissen M, van Cingel R, Willemsen L, de Visser E. Diagnostics of femoroacetabular impingement and labral pathology of the hip: a systematic review of the accuracy and validity of physical tests. *Arthroscopy.* 2012;28(6):860-871.
91. Diamond LE, Dobson FL, Bennell KL, Wrigley TV, Hodges PW, Hinman RS. Physical impairments and activity limitations in people with femoroacetabular impingement: a systematic review. *British Journal of Sports Medicine.* 2015;49(4):230-242.
92. Freke MD, Kemp J, Svege I, Risberg MA, Semciw A, Crossley KM. Physical impairments in symptomatic femoroacetabular impingement: a systematic review of the evidence. *Br J Sports Med.* 2016;50(19):1180.
93. Reiman MP, Goode AP, Cook CE, Holmich P, Thorborg K. Diagnostic accuracy of clinical tests for the diagnosis of hip femoroacetabular impingement/labral tear: a systematic review with meta-analysis. *Br J Sports Med.* 2015;49(12):811.
94. Hagins M, Brown M, Cook C, et al. Intratester and intertester reliability of the palpation meter (PALM) in measuring pelvic position. *Journal of Manual & Manipulative Therapy.* 1998;6(3):130-136.
95. Petrone MR, Guinn J, Reddin A, Sutlive TG, Flynn TW, Garber MP. The accuracy of the Palpation Meter (PALM) for measuring pelvic crest height difference and leg length discrepancy. *J Orthop Sports Phys Ther.* 2003;33(6):319-325.
96. Gajdosik R, Simpson R, Smith R, DonTigny RL. Pelvic tilt. Intratester reliability of measuring the standing position and range of motion. *Phys Ther.* 1985;65(2):169-174.
97. Greendale GA, Nili NS, Huang MH, Seeger L, Karlamangla AS. The reliability and validity of three non-radiological measures of thoracic kyphosis and their relations to the standing radiological Cobb angle. *Osteoporos Int.* 2011;22(6):1897-1905.
98. Korovessis P, Petsinis G, Papazisis Z, Baikousis A. Prediction of thoracic kyphosis using the Debrunner kyphometer. *J Spinal Disord.* 2001;14(1):67-72.
99. Gajdosik RL, Bohannon RW. Clinical measurement of range of motion. Review of goniometry emphasizing reliability and validity. *Phys Ther.* 1987;67(12):1867-1872.
100. Holm I, Bolstad B, Lutken T, Ervik A, Rokkum M, Steen H. Reliability of goniometric measurements and visual estimates of hip ROM in patients with osteoarthritis. *Physiother Res Int.* 2000;5(4):241-248.
101. Carey MA, Laird DE, Murray KA, Stevenson JR. Reliability, validity, and clinical usability of a digital goniometer. *Work.* 2010;36(1):55-66.
102. Forde C, Johnston L. Intra and inter-rater reliability of the HALO digital goniometer and the tractograph in a podiatric setting: a comparative study.
103. Furness J, Johnstone S, Hing W, Abbott A, Climstein M. Assessment of shoulder active range of motion in prone versus supine: a reliability and concurrent validity study. *Physiotherapy Theory and Practice.* 2015;31(7):489-495.
104. Swärd L, Hellstrom M, Jacobsson B, Péterson L. Back pain and radiologic changes in the thoraco-lumbar spine of athletes. *Spine (Phila Pa 1976).* 1990;15(2):124-129.
105. Baranto A, Hellstrom M, Nyman R, Lundin O, Sward L. Back pain and degenerative abnormalities in the spine of young elite divers: a 5-year follow-up magnetic resonance imaging study. *Knee Surg Sports Traumatol Arthrosc.* 2006;14(9):907-914.
106. Jonasson P, Halldin K, Karlsson J, et al. Prevalence of joint-related pain in the extremities and spine in five groups of top athletes. *Knee Surg Sports Traumatol Arthrosc.* 2011;19(9):1540-1546.
107. Thoreson O, Kovac P, Sward A, Agnvall C, Todd C, Baranto A. Back pain and MRI changes in the thoraco-lumbar spine of young elite Mogul skiers. *Scand J Med Sci Sports.* 2016.
108. Beall DP, Sweet CF, Martin HD, et al. Imaging findings of femoroacetabular impingement syndrome. *Skeletal Radiol.* 2005;34(11):691-701.
109. Clohisey JC, Nunley RM, Otto RJ, Schoenecker PL. The frog-leg lateral radiograph accurately visualized hip cam impingement abnormalities. *Clin Orthop Relat Res.* 2007;462:115-121.
110. Barton C, Salineros MJ, Rakhra KS, Beaulé PE. Validity of the alpha angle measurement on plain radiographs in the evaluation of cam-type femoroacetabular impingement. *Clin Orthop Relat Res.* 2011;469(2):464-469.
111. Koo TK, Li MY. A Guideline of Selecting and Reporting Intraclass Correlation Coefficients for Reliability Research. *J Chiropr Med.* 2016;15(2):155-163.
112. Shrout PE, Fleiss JL. Intraclass correlations: uses in assessing rater reliability. *Psychol Bull.* 1979;86(2):420-428.
113. Siebenrock KA, Wahab KH, Werlen S, Kalhor M, Leunig M, Ganz R. Abnormal extension of the femoral head epiphysis as a cause of cam impingement. *Clin Orthop Relat Res.* 2004(418):54-60.
114. Goutteborge V, Inklaar H, Backx F, Kerkhoffs G. Prevalence of osteoarthritis in former elite athletes: a systematic overview of the recent literature. *Rheumatol Int.* 2015;35(3):405-418.
115. Thorborg K, Reiman MP, Weir A, et al. Clinical Examination, Diagnostic Imaging, and Testing of Athletes With Groin Pain: An Evidence-Based Approach to Effective Management. *J Orthop Sports Phys Ther.* 2018;48(4):239-249.

116. Weir A, Brukner P, Delahunt E, et al. Doha agreement meeting on terminology and definitions in groin pain in athletes. *Br J Sports Med*. 2015;49(12):768-774.
117. Witwit WA, Kovac P, Sward A, et al. Disc degeneration on MRI is more prevalent in young elite skiers compared to controls. *Knee Surg Sports Traumatol Arthrosc*. 2017.
118. Todd C, Aminoff AS, Agnvall C, et al. No difference in prevalence of spine and hip pain in young Elite skiers. *Knee Surg Sports Traumatol Arthrosc*. 2018;26(7):1959-1965.
119. Fader RR, Tao MA, Gaudiani MA, et al. The role of lumbar lordosis and pelvic sagittal balance in femoroacetabular impingement. *Bone Joint J*. 2018;100-b(10):1275-1279.
120. Pierannunzi L. Pelvic posture and kinematics in femoroacetabular impingement: a systematic review. *J Orthop Traumatol*. 2017;18(3):187-196.
121. Lamontagne M, Kennedy MJ, Beaulé PE. The effect of cam FAI on hip and pelvic motion during maximum squat. *Clin Orthop Relat Res*. 2009;467(3):645-650.
122. Todd C TO, Swärd L, Karlsson J, Baranto A, et al. . doi: Pelvic Retroversion is Associated with Flat Back and Cam Type Femoro- Acetabular Impingement in Young Elite Skiers. *J Spine* (2016);5(326).
123. Woolf AD, Pfleger B. Burden of major musculoskeletal conditions. *Bull World Health Organ*. 2003;81(9):646-656.
124. Hoy D, March L, Brooks P, et al. The global burden of low back pain: estimates from the Global Burden of Disease 2010 study. *Ann Rheum Dis*. 2014;73(6):968-974.
125. Reginster JY. The prevalence and burden of arthritis. *Rheumatology*. 2002;41(suppl_1):3-6.
126. Lespasio MJ, Sultan AA, Piuze NS, et al. Hip Osteoarthritis: A Primer. *Perm J*. 2018;22:17-084.
127. Ferguson RJ, Palmer AJ, Taylor A, Porter ML, Malchau H, Glyn-Jones S. Hip replacement. *Lancet*. 2018;392(10158):1662-1671.
128. Elmslie RC. Remarks on AETIOLOGICAL FACTORS IN OSTEO-ARTHRITIS OF THE HIP-JOINT. *Br Med J*. 1933;1(3757):1-46.41.
129. Agricola R, Waarsing JH, Arden NK, et al. Cam impingement of the hip: a risk factor for hip osteoarthritis. *Nat Rev Rheumatol*. 2013;9(10):630-634.
130. Agricola R, Heijboer MP, Bierma-Zeinstra SM, Verhaar JA, Weinans H, Waarsing JH. Cam impingement causes osteoarthritis of the hip: a nationwide prospective cohort study (CHECK). *Ann Rheum Dis*. 2013;72(6):918-923.
131. Sankar WN, Nevitt M, Parvizi J, Felson DT, Agricola R, Leunig M. Femoroacetabular impingement: defining the condition and its role in the pathophysiology of osteoarthritis. *J Am Acad Orthop Surg*. 2013;21 Suppl 1:S7-s15.
132. Agricola R, Heijboer MP, Roze RH, et al. Pincer deformity does not lead to osteoarthritis of the hip whereas acetabular dysplasia does: acetabular coverage and development of osteoarthritis in a nationwide prospective cohort study (CHECK). *Osteoarthritis Cartilage*. 2013;21(10):1514-1521.
133. Leunig M, Casillas MM, Hamlet M, et al. Slipped capital femoral epiphysis: early mechanical damage to the acetabular cartilage by a prominent femoral metaphysis. *Acta Orthop Scand*. 2000;71(4):370-375.
134. Thomas GE, Palmer AJ, Batra RN, et al. Subclinical deformities of the hip are significant predictors of radiographic osteoarthritis and joint replacement in women. A 20 year longitudinal cohort study. *Osteoarthritis Cartilage*. 2014;22(10):1504-1510.
135. Reichenbach S, Juni P, Nuesch E, Frey F, Ganz R, Leunig M. An examination chair to measure internal rotation of the hip in routine settings: a validation study. *Osteoarthritis Cartilage*. 2010;18(3):365-371.
136. Klau K, Durnin CW, Ganz R. The acetabular rim syndrome. A clinical presentation of dysplasia of the hip. *J Bone Joint Surg Br*. 1991;73(3):423-429.
137. Pacheco-Carrillo A, Medina-Porqueres I. Physical examination tests for the diagnosis of femoroacetabular impingement. A systematic review. *Phys Ther Sport*. 2016;21:87-93.
138. Ross MD, Nordeen MH, Barido M. Test-retest reliability of Patrick's hip range of motion test in healthy college-aged men. *J Strength Cond Res*. 2003;17(1):156-161.
139. Byrd JW. Evaluation of the hip: history and physical examination. *N Am J Sports Phys Ther*. 2007;2(4):231-240.
140. Martin HD, Kelly BT, Leunig M, et al. The pattern and technique in the clinical evaluation of the adult hip: the common physical examination tests of hip specialists. *Arthroscopy*. 2010;26(2):161-172.
141. Azevedo DC, Santos H, Carneiro RL, Andrade GT. Reliability of sagittal pelvic position assessments in standing, sitting and during hip flexion using palpation meter. *J Bodyw Mov Ther*. 2014;18(2):210-214.
142. Todd C. Clinical Spino-Pelvic Parameters in Skiers and Non-Athletes. *J Sport Med*. 2016;3(3):022.
143. Todd CM, Agnvall C, Kovac P, et al. Validation of spinal sagittal alignment with plain radiographs and the Debrunner Kyphometer. *Medical Research Archives*. 2015;2(1).
144. Ohlen G, Spangfort E, Tingvall C. Measurement of spinal sagittal configuration and mobility with Debrunner's kyphometer. *Spine (Phila Pa 1976)*. 1989;14(6):580-583.
145. Baranto A, Hellström M, Cederlund C-G, Nyman R, Swärd L. Back pain and MRI changes in the thoraco-lumbar spine of top athletes in four different sports: a 15-year follow-up study. *Knee Surgery, Sports Traumatology, Arthroscopy*. 2009;17(9):1125-1134.
146. Agricola R, Waarsing JH, Thomas GE, et al. Cam impingement: defining the presence of a cam deformity by the alpha angle: data from the CHECK cohort and Chingford cohort. *Osteoarthritis Cartilage*. 2014;22(2):218-225.
147. Rakhra KS, Sheikh AM, Allen D, Beaulé PE. Comparison of MRI alpha angle measurement planes in femoroacetabular impingement. *Clin Orthop Relat Res*. 2009;467(3):660-665.
148. Cheung JPY, Luk KD. Managing the Pediatric Spine: Growth Assessment. *Asian Spine J*. 2017;11(5):804-816.

149. Ruiz JR, Ortega FB, Martínez-Gómez D, et al. Objectively measured physical activity and sedentary time in European adolescents: the HELENA study. *Am J Epidemiol*. 2011;174(2):173-184.
150. Sink EL, Gralla J, Ryba A, Dayton M. Clinical presentation of femoroacetabular impingement in adolescents. *J Pediatr Orthop*. 2008;28(8):806-811.
151. Berge C. Heterochronic processes in human evolution: an ontogenetic analysis of the hominid pelvis. *Am J Phys Anthropol*. 1998;105(4):441-459.
152. Abrahamson J, Aminoff AS, Todd C, et al. Adolescent elite skiers with and without cam morphology did change their hip joint range of motion with 2 years follow-up. *Knee Surg Sports Traumatol Arthrosc*. 2019;27(10):3149-3157.
153. Czuppon S, Prather H, Hunt DM, et al. Gender-Dependent Differences in Hip Range of Motion and Impingement Testing in Asymptomatic College Freshman Athletes. *Pm r*. 2017;9(7):660-667.
154. Jónasson P, Thoreson O, Sansone M, et al. The morphologic characteristics and range of motion in the hips of athletes and non-athletes. *J Hip Preserv Surg*. 2016;3(4):325-332.
155. Mosler AB, Crossley KM, Thorborg K, et al. Hip strength and range of motion: Normal values from a professional football league. *J Sci Med Sport*. 2017;20(4):339-343.
156. Roach KE, Miles TP. Normal hip and knee active range of motion: the relationship to age. *Phys Ther*. 1991;71(9):656-665.
157. Frank JM, Harris JD, Erickson BJ, et al. Prevalence of Femoroacetabular Impingement Imaging Findings in Asymptomatic Volunteers: A Systematic Review. *Arthroscopy*. 2015;31(6):1199-1204.
158. Guler O, Isyar M, Karataş D, Ormeci T, Cerci H, Mahirogulları M. A retrospective analysis on the correlation between hip pain, physical examination findings, and alpha angle on MR images. *J Orthop Surg Res*. 2016;11(1):140.
159. Khanna V, Caragianis A, Diprimio G, Rakhra K, Beaulé PE. Incidence of hip pain in a prospective cohort of asymptomatic volunteers: is the cam deformity a risk factor for hip pain? *Am J Sports Med*. 2014;42(4):793-797.
160. Larson CM, Sikka RS, Sardelli MC, et al. Increasing alpha angle is predictive of athletic-related "hip" and "groin" pain in collegiate National Football League prospects. *Arthroscopy*. 2013;29(3):405-410.
161. Mosler AB, Weir A, Serner A, et al. Musculoskeletal Screening Tests and Bony Hip Morphology Cannot Identify Male Professional Soccer Players at Risk of Groin Injuries: A 2-Year Prospective Cohort Study. *Am J Sports Med*. 2018;46(6):1294-1305.
162. Ross JR, Nepple JJ, Philippon MJ, Kelly BT, Larson CM, Bedi A. Effect of changes in pelvic tilt on range of motion to impingement and radiographic parameters of acetabular morphologic characteristics. *Am J Sports Med*. 2014;42(10):2402-2409.
163. Esposito CI, Miller TT, Kim HJ, et al. Does Degenerative Lumbar Spine Disease Influence Femoroacetabular Flexion in Patients Undergoing Total Hip Arthroplasty? *Clin Orthop Relat Res*. 2016.
164. Baranto A, Ekstrom L, Hellstrom M, Lundin O, Holm S, Sward L. Fracture patterns of the adolescent porcine spine: an experimental loading study in bending-compression. *Spine (Phila Pa 1976)*. 2005;30(1):75-82.
165. Thoreson O, Ekstrom L, Hansson HA, et al. The effect of repetitive flexion and extension fatigue loading on the young porcine lumbar spine, a feasibility study of MRI and histological analyses. *J Exp Orthop*. 2017;4(1):16.
166. Edelson JG, Nathan H. Stages in the natural history of the vertebral end-plates. *Spine (Phila Pa 1976)*. 1988;13(1):21-26.
167. Matsumoto M. [Radiological and histological studies on the growth of lumbar vertebra]. *Nihon Seikeigeka Gakkai Zasshi*. 1988;62(4):331-343.
168. DiFiori JP, Benjamin HJ, Brenner J, et al. Overuse injuries and burnout in youth sports: a position statement from the American Medical Society for Sports Medicine. *Clin J Sport Med*. 2014;24(1):3-20.
169. Feeley BT, Agel J, LaPrade RF. When Is It Too Early for Single Sport Specialization? *Am J Sports Med*. 2016;44(1):234-241.
170. Sveen SA, Martin K, Alhaug E, Engbretsen L. CAM-type femoroacetabular impingement in male elite junior cross-country skiers and non-athlete controls: a cross-sectional MRI study. *BMJ Open Sport Exerc Med*. 2019;5(1):e000530.
171. Mosler AB, Agricola R, Thorborg K, et al. Is Bony Hip Morphology Associated With Range of Motion and Strength in Asymptomatic Male Soccer Players? *J Orthop Sports Phys Ther*. 2018;48(4):250-259.
172. Arnason A, Sigurdsson SB, Gudmundsson A, Holme I, Engbretsen L, Bahr R. Risk factors for injuries in football. *Am J Sports Med*. 2004;32(1 Suppl):5s-16s.
173. Ingvarsson T, Hägglund G, Lohmander LS. Prevalence of hip osteoarthritis in Iceland. *Ann Rheum Dis*. 1999;58(4):201-207.
174. Myer GD, Jayanthi N, DiFiori JP, et al. Sports Specialization, Part II: Alternative Solutions to Early Sport Specialization in Youth Athletes. *Sports Health*. 2016;8(1):65-73.
175. Myer GD, Jayanthi N, DiFiori JP, et al. Sport Specialization, Part I: Does Early Sports Specialization Increase Negative Outcomes and Reduce the Opportunity for Success in Young Athletes? *Sports Health*. 2015;7(5):437-442.
176. Collins JA, Ward JP, Youm T. Is prophylactic surgery for femoroacetabular impingement indicated? A systematic review. *Am J Sports Med*. 2014;42(12):3009-3015.