

Dynamic ultrasound investigation of clubfeet in children, 0-4 years of age, with normal controls

Clubfoot is one of the most common congenital deformities. The Ponseti method is widely accepted as the method of choice for the treatment of clubfeet. The treatment starts soon after birth. The deformities are corrected by manipulations and serial castings, usually for six to ten weeks. The majority of the feet require tenotomy of the Achilles tendon. After the correction of the deformities, the treatment continues with orthoses to the age of four years to prevent recurrences. At this age, the foot skeleton is not fully ossified and is therefore not visible on conventional radiographs. Ultrasonography (US) is a radiation-free dynamic image modality which visualises the cartilaginous parts of the infant foot skeleton.

This thesis consists of four studies. The first three studies aimed to develop reliable measurement variables for evaluations of ultrasonographic images of feet during the first four years of life. In the fourth study, 20 children with 30 clubfeet and a control group of 29 healthy children were followed by repeated ultrasonography of the feet from newborn to the age of four years. The correction of the deformities during the first months of treatment, as well as remaining differences between clubfeet and controls persisting throughout the whole study period, were visualised using US. This enables an increased understanding of what happens in clubfeet during treatment and growth, which may contribute to further improvement in the field of clubfoot care.

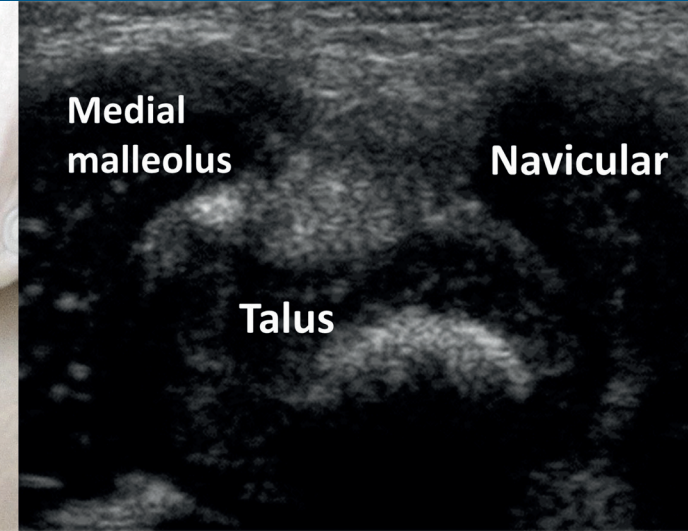
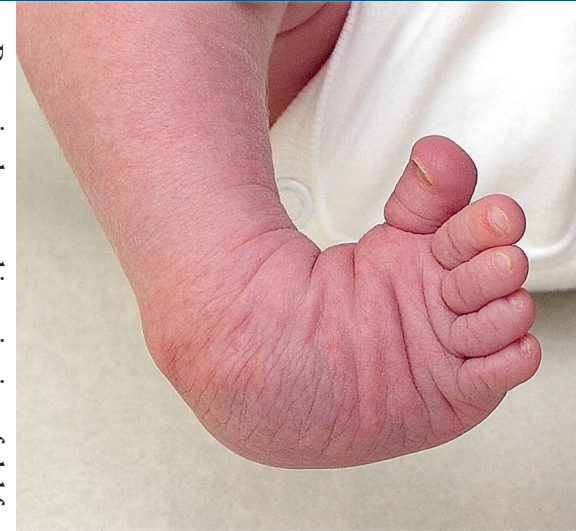

Arne Johansson, MD
Orthopedic Surgeon

ISBN 978-91-8009-052-0 (PRINT)
ISBN 978-91-8009-053-7 (PDF)
<http://hdl.handle.net/2077/66394>

Printed by Stema Specialtryck AB, Borås

Dynamic ultrasound investigation of clubfeet in children, 0-4 years of age, with normal controls | Arne Johansson



Dynamic ultrasound investigation of clubfeet in children, 0-4 years of age, with normal controls

Arne Johansson

SAHLGRENKA ACADEMY
INSTITUTE OF CLINICAL SCIENCES

