Orbital floor fractures
- aspects of
diagnostic methods, treatment and sequelae

Lena Folkestad

Department of Otorhinolaryngology, Head & Neck Surgery,
The Sahlgrenska Academy, Göteborg university
Göteborg, Sweden

2006

Correspondence to:

Dr Lena Folkestad
Department of Otorhinolaryngology, Head and Neck Surgery
Institute of Clinical Sciences, Göteborg University
Sahlgrenska University Hospital
SE- 413 45 Göteborg
Sweden

To
Andreas, Lovisa and Fredrik

Orbital floor fractures
– aspects of diagnostic methods, treatment and sequelae

Lena Folkestad

MD

Department of Otorhinolaryngology and Head & Neck Surgery,
The Sahlgrenska Academy,
Göteborg University,
Göteborg, Sweden

Abstract

Despite surgical intervention, orbital floor fractures are associated with risks of persisting sensibility disturbances, enophthalmos and diplopia. Cheek asymmetry and trismus may result when the zygoma is dislocated. In evaluating the surgical results patients' experiences of the outcomes have to be investigated.

To investigate sequelae a questionnaire was sent to 107 patients previously treated for an orbital floor fracture (Paper I). Visual analogue scales (VASs) were used in a prospective study (Papers II and III) to assess patients' experiences of persisting signs and symptoms. The possibility of using electronystagmography (ENG) equipment, normally employed in vestibular testing in ENT practice, for measuring bilateral vertical eye motility was investigated in a methodological study (Paper IV).

Fractures were mainly due to assaults and falls. Sequelae were common (83%). A high frequency of diplopia (36%) was associated with antral packing. When stable floor implants replaced this technique, the subsequent prospective study revealed absence of severe cases of diplopia as well as a lower occurrence of diplopia (9.5%).

Patients and doctors agreed on the presence of 'objective' signs (affected physical appearance and diplopia). Sensibility disturbances and reduced mouth opening capacity were not sufficiently reflected by the diagnostic assessment methods used, and these symptoms were underestimated by the clinicians.

Surgery of the internal orbit involves risks. For this reason, operations for purely diagnostic purposes must be avoided. However, 21% of the orbital floor operations in the present study were performed for purely diagnostic purposes. Surgeons did not apprehend the CT scans as being representative of the fracture. No test is at present available that can objectively establish entrapment of soft tissues as a cause of diplopia, although this is an absolute indication for surgery.

However, vertical electro-oculography (vEOG) was shown to (i) objectively measure vertical eye motility; (ii) detect and verify mechanical restriction of vertical eye motility; and (iii) distinguish patients experiencing vertical diplopia from healthy test subjects with 'normal' eye motility.

Both recognition of patients' experiences and prolonged follow-ups in selected cases are important for treatment feedback, and are prerequisites for improvement of future surgical outcomes. Current diagnostic methods appear to be insufficient. Vertical electro-oculography is suggested as a simple, objective and non-invasive eye motility test with the potential of helping predict which patients will benefit or not benefit from orbital floor surgery.

Key words: orbital floor fracture, sequelae, patients' experience, diplopia, entrapment, vertical eye motility, vertical electro-oculography (vEOG)

ISBN-91-628-6813-6 Göteborg, 2006

Original papers

This thesis is based on the following publications, which will be referred to in the text by their Roman numerals:

I. Folkestad L, Westin T.
Long-term sequelae after surgery for orbital floor fractures
Otolaryngology and Head & Neck Surgery 1999, vol 120, no 6, p 914-21

II. Folkestad L, Granström G.
A prospective study of orbital fracture sequelae after change of surgical routines
J Oral Maxillofac Surg 2003, vol 61 : 1038-44

III. Folkestad L, Åberg-Bengtsson L, Granström G.
Recovery from orbital floor fractures: a prospective study of patients' and doctors' experiences
Int J Oral MaxFac Surg 2006, available on line at www.sciencedirect.com

IV. Folkestad L, Lindgren G, Möller C, Granström G
Diplopia in orbital fractures: a simple method to evaluate eye motility
Accepted for publication in Acta Oto-laryngologica

Contents

ORIGINAL PAPERS ..... **V**

ABBREVIATIONS ..... **VIII**

DEFINITIONS ..... **VIII**

ERRATA ..... **IX**

PAPER I IX
PAPER II IX
PAPER III IX

1. INTRODUCTION **1**

1.1 EPIDEMIOLOGY 2
1.2 ANATOMY OF THE ORBIT 4
1.3 FRACTURE CLASSIFICATIONS 6
1.4 SYMPTOMS AND SIGNS OF AN ACUTE ORBITAL FLOOR FRACTURE 8
1.5 DIAGNOSTIC METHODS 11
1.5.1 Imaging *12*
1.5.2 Functional tests *13*
1.6 TREATMENT 18
1.6.1 Surgical methods *20*
1.6.2 Materials for osteosynthesis and implants *22*
1.7 SEQUELAE 25
1.7.1 Physical appearance *25*
1.7.2 Vision *26*
1.7.3 Sensibility *27*
1.7.4 Mouth opening and occlusion *27*
1.7.5 Patients' experiences of sequelae *28*
1.8 CLINICAL PROBLEMS 28
1.9 PREVIOUS RESEARCH 29

2. AIMS OF THIS THESIS **31**

Paper I (retrospective study) *31*
Paper II (prospective study) *31*
Paper III (prospective study) *31*
Paper IV (methodological study) *32*

3. MATERIALS AND METHODS **33**

3.1 STUDY POPULATIONS 33
3.2 METHODS 34
3.2.1 Questionnaires *34*
3.2.2 The visual analogue scale *37*
3.2.3 Electrophysiology in electro-oculography *39*
3.3 STATISTICAL METHODS 40
3.3.1 SAMPLE SIZE 40
3.3.2 Statistical methods used *41*

4. RESULTS **43**

4.1. PAPER I 43
4.2. PAPER II 43

4.3. PAPER III 45
4.4. PAPER IV 46
4.5 EXCLUDED PATIENTS AND DROPOUTS 50
4.5.1 Paper I *50*
4.5.2 Papers II and III *51*
4.6. CONCLUDING SUMMARY OF THE RESULTS 52

5. DISCUSSION 55

5.1. ASPECTS OF THE MAIN RESULTS 55
Paper I *55*
Paper II *58*
Paper III *61*
Paper IV *62*
5.2. METHODOLOGICAL CONSIDERATIONS 65
5.2.1 The questionnaires *66*
5.2.2 The investigator *66*
5.2.3 The investigated *67*
5.3 CLINICAL CONSEQUENCES 69

6. CONCLUSION 71

7. AIMS FOR FUTURE RESEARCH 73

REFERENCES 75

ACKNOWLEDGEMENTS 83

APPENDIX 1: QUESTIONNAIRE PAPER I

APPENDIX 2: QUESTIONNAIRE PAPER III

APPENDIX 3: PROTOCOL PAPER III

TABLES

TABLE 1: EXAMPLES OF IMPLANTS USED IN ORBITAL FLOOR REPAIR

FIGURES

FIGURE 1: INCIDENCE OF FRACTURES OF SKULL AND FACIAL BONES
FIGURE 2 A: ANATOMY OF THE BONY ORBIT
FIGURE 2 B-C: THE EXTRAOCULAR MUSCLES
FIGURE 3 A: ZYGOMATICO-ORBITAL FRACTURE
FIGURE 3 B: TETRAPOD FRACTURE
FIGURE 3 C: BLOW-OUT FRACTURE
FIGURE 4: PERIORBITAL SWELLING
FIGURE 5 A: CT OF ORBITAL FLOOR TRAPDOOR FRACTURE
FIGURE 5 B: INCARCERATED SOFT TISSUE
FIGURE 5 C: AFTER RELEASE OF SOFT TISSUE
FIGURE 6:THE FORCED DUCTION TEST
FIGURE 7: THE STUDIES OF THE THESIS
FIGURE 8 A-C: ROC CURVES
FIGURE 9: QUOTIENTS
FIGURE 10: PATIENTS OF STUDY I
FIGURE 11: PATIENTS OF STUDY II/III
FIGURE 12: ANTRAL PACKING

Abbreviations

AUC	Area under the curve
BSV	Binocular Single Vision
CT	Computerized Tomography
ENT	Ear, Nose & Throat
EOG	Electrooculography
ICD	International Classification of Diseases
MRT	Magnetic Resonance Tomography
OMF	Oral and Maxillofacial
ORL-HNS	Otorhinolaryngology and Head & Neck Surgery
SF-36	Short-Form-36; general questionnaire
TMJ	Temporomandibular joint
US	Ultra Sound technique
VAS	Visual Analogue Scale
vEOG	Vertical electro-oculography

Definitions

Blow-out fracture	isolated fracture of the orbital floor, rims not involved
Diplopia	here: double image in binocular vision; binocular double vision
Entrapment	impingement of orbital soft tissue in the floor fracture
Orbital floor fracture	any fracture of the orbital floor
Tetrapod fracture	simple fracture of the zygoma along the adjacent bones
Zygomatico-orbital fracture	equal to ‘orbital floor fracture’

Errata

Paper I

p. 914; right column; fifth paragraph; second line: ‘prevalence’ should be ‘occurrence’

p. 918; right column; second paragraph; ninth line: ‘12%’ should read ‘13%’

Paper II

p.1041; left column; second paragraph; ninth line: ‘at the outer parts of the visual field’ should be ‘at farthest gaze’

p. 1041; Figure 1: box farthest right; ‘(0%)’ should be ‘(-)’

p. 1042; right column; fifth line: ‘orbital floor fractures’ should be ‘orbital floor explorations’

Paper III

p. 893; Table 3B; line ‘Incision scar’; ‘[a]’ missing in column for pre-operative measures

p.893; No legend table 2. Frequencies as reported by the patients

1. Introduction

Orbital floor fractures (zygomatico-orbital fractures) merit specific clinical attention for a number of reasons. Failure to recognize and treat them early may result in severe sequelae, which must be prevented. However, despite surgical intervention, orbital floor fractures are associated with risk of persisting sensibility disorders, enophthalmos and permanent diplopia (Biesman et al 1996, De Man & Bax 1988, Manson, Clifford et al. 1986, Manson, Grivas et al. 1986; Mathog 1991, Rosbe et al. 1997, Vriens et al. 1998). Trismus, malocclusion and flattened cheek prominence due to an often associated dislocation of the zygoma may also constitute long-term problems (Rohrich et al. 1992). For the purpose of reducing the occurrence of sequelae, numerous studies have established the importance of proper surgical techniques, exact repositioning and rigid fixation (Glassman et al. 1990; Goldberg et al. 1993; Manson 1990; Nguyen & Sullivan 1992; Rohrich et al. 1992).

Determining which patients will benefit from an operation is a difficult matter. Surgery on the internal orbit comes with a risk, and consequently orbital floor explorations for diagnostic purposes alone must be avoided (Burnstine 2002; Burnstine 2003; Liu 1994). Ideally, diagnosis must fully reflect the status of the injury and provide all the information necessary for making a robust treatment decision.

Currently, the diagnostic procedure is based on a clinical examination followed by a radiological examination, foremost a computerized tomography (CT) scan (Freund et al. 2002). The presence of diplopia in association with an orbital floor fracture has a great impact on the decision whether to operate or not. It can motivate acute surgery within hours (Burnstine 2003; Sires et al. 1998; Wachler & Holds 1998), but in cases of intra-orbital soft tissue swelling, diplopia may resolve spontaneously with time (Burnstine 2003; Iliff et al. 1999; Putterman et al. 1974). However, an objective diagnostic method for distinguishing between these conditions that cause diplopia is currently lacking.

As the relative value of surgical treatment options varies (Hartstein & Roper-Hall 2000; Putterman et al. 1974; Strong et al. 2004; Zingg et al. 1992), surgical techniques and implant materials change (Baumann et al. 2002; Converse & Smith 1960; Dietz et al. 2001; Goldberg et al. 1993; Guerra et al. 2000; Nguyen & Sullivan 1992) and surgeon-related factors are not invariable, the long-term results have to be subjected to recurrent investigation. What are the long-term results? Will a nice cosmetic result and good function persist even after the final routine assessment?

To appropriately evaluate the risks in handling orbital floor fractures, it is imperative to be closely familiar with the outcome of treatment options. Advantages and disadvantages must be weighed and the final benefits from the patient's perspective considered. Consequently, the patients' experience of the outcome has to be recognized by clinicians as an important matter in the evaluation of the treatment.

In conclusion, the major overall question is: How will surgeons select for surgery only those patients who will benefit from it and preclude unnecessary surgical intervention in others?

1.1 Epidemiology

According to official nationwide statistics from The Swedish Board of Health and Welfare (available at their website, www.sos.se), during the last decade approximately 110,000–120,000 people in Sweden were hospitalized each year for physical injuries. The major cause was falls in elderly people. In the municipality of Göteborg comprising approximately 500,000 inhabitants, around 3,000 men and 3,000 women per year have been hospitalized for injuries since 1991. Approximately 300 of these injuries have been fractures to the skull or facial bones (incidence as displayed in Figure 1), of which 10–15% have been injuries to the eye globe or orbit (The Swedish Board of Health and Welfare 2006). This corresponds to an incidence of injuries to the eye globe or orbit of approximately 0.04‰.

The main causes of facial fractures are motor vehicle accidents, assaults, falls and sports injuries (Baumann et al. 2002; Ellis et al. 1985; Jungell & Lindqvist 1987; Kontio et al. 2005; Tadj & Kimble 2003; Winstanley 1981). In a Swedish retrospective study investigating the injuries before the introduction of the seatbelt law in 1975, the main cause of zygomatico-orbital injuries was motor vehicle accidents (Afzelius & Rosen 1979); however, similar, more recent studies have established assault as the main reason (Kontio et al. 2005; Tadj & Kimble 2003; Tong et al. 2001). Airbags, on the contrary, have been reported to cause ocular injuries. Lehto et al. (2003) report in their study a 2.5% frequency of ocular injuries, but a low risk of severe eye injury from airbags (0.4%).

Young men 20–30 years old usually dominate in number (generally accounting for 70–80%) among the injured (Baumann et al. 2002; Biesman et al. 1996; Ellis et al. 1985; Tadj & Kimble 2003; Tong et al. 2001; Winstanley 1981). This is illustrated by the diagram in Figure 1 displaying the separate incidences of skull and facial fractures in men and women. In Sweden injuries due to assault are the most common reason for hospital care due to physical trauma among 25–44-year-olds independently of gender (The Swedish Board of Health and Welfare 2006).

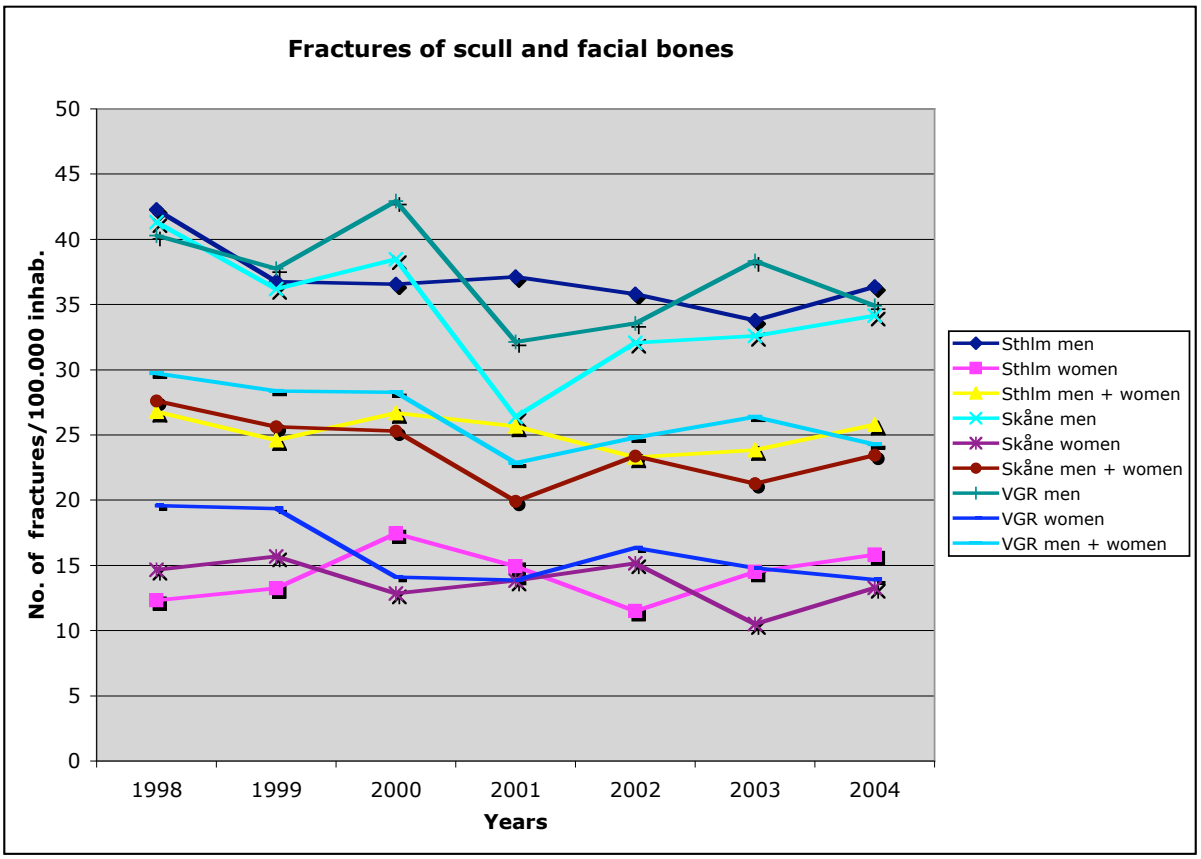

Figure 1. *Incidence of skull and facial fractures in the three big city regions of Sweden (number of fractures per 100,000 inhabitants). (Source: The Swedish Board of Health and Welfare). Sthlm = region of Stockholm, capital of Sweden (1.9 million inhabitants); VGR = region of Västra Götaland (1.5 million inhabitants) including Göteborg (almost 500,000 inhabitants); Skåne = region of Skåne (1.15 million inhabitants).*

1.2 Anatomy of the orbit

As described by Whitnall in 1932, 'the orbit is a pear-shaped bony cavity whose stalk is the optic canal' (Hötte 1970; Kanski 1989 p. 22). It is made up of two walls, a roof and a floor (Figure 2). The floor is made up of three bones; the zygomatic (Figure 2B:b) and maxillary (Figure 2B:a) bones, which also constitute the maxillary sinus roof, and the palatine bone (Figure 2B:c). The medial walls are parallel in the sagittal plane and the lateral walls form a 90º angle with each other. The orbital floor is the weakest of the orbital walls, with an average thickness of 0.27 mm medial to the inferior sulcus, and is therefore most vulnerable to trauma (Ilankovan et al. 1991; Kanski 1989). The orbital shape varies with age, gender and race and between

individuals, but the volume is usually 29–30 cm^3 (Hartstein & Roper-Hall 2000; Hötte 1970; Lee & Chiu 1993).

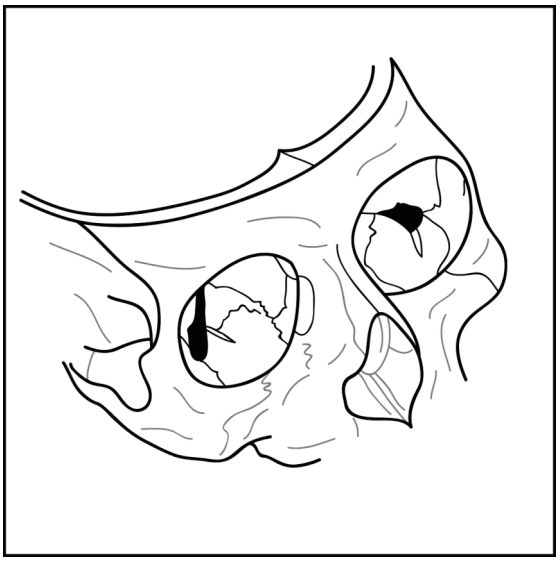

Figure 2A. *Bony orbits.*

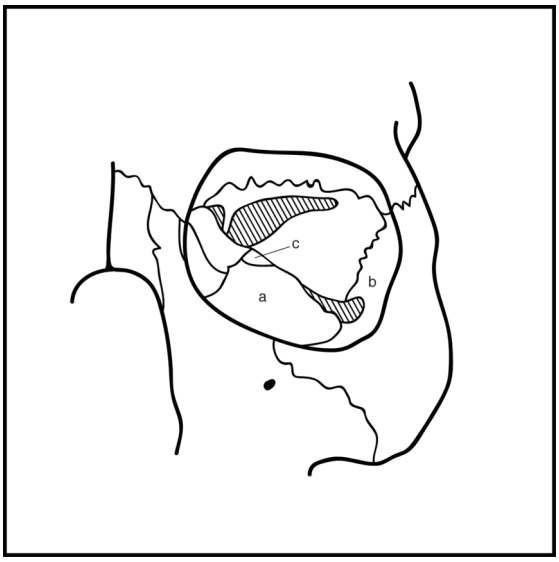

Figure 2B. *Frontal view of left orbit.*

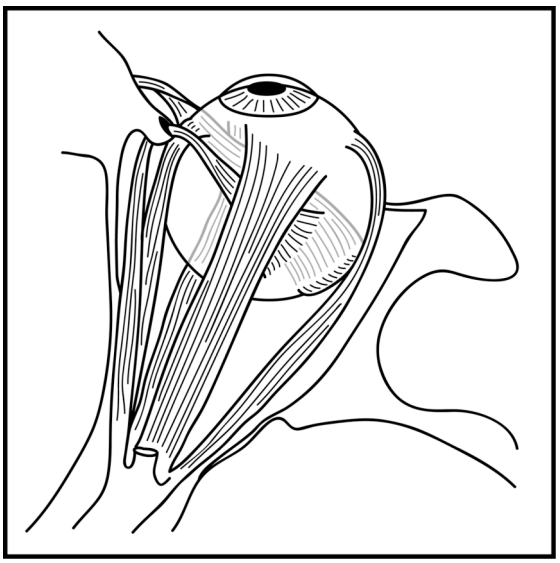

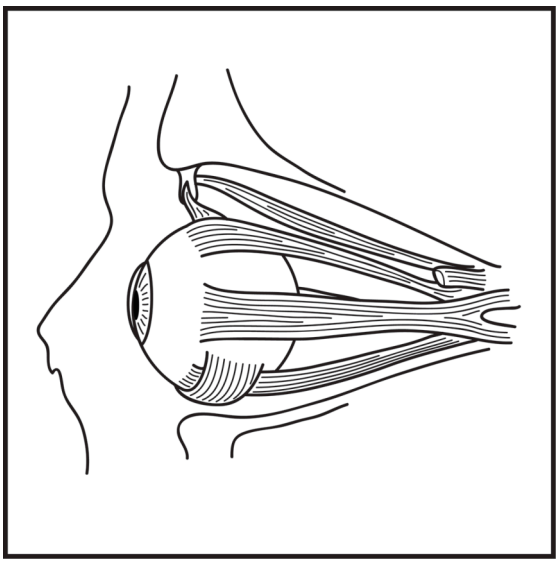

Figure 2C - D. *Extrinsic muscles of the right orbit seen from above (C). Lateral view of left orbit (D).*

The eyeball is moved by the six extra-ocular eye muscles (Figure 2C-D) which, except for the inferior oblique, have their origin near the orbital apex (the annulus of Zinn). They attach to the eye globe in Tenon's capsule and thus form the 'muscle cone', in the centre of which runs the optical nerve towards its insertion at the eye globe.

Despite the location of the inferior oblique muscle close to the orbital floor it is unusual for any extra-ocular eye muscle other than the inferior rectus to cause eye motility dysfunction due to an orbital floor fracture (Mathog 1991; Spector 1993).

The eye globe is embedded in a suspensory system consisting, apart from the extra-ocular muscles, of ligaments, fasciae, membranes and interspaces of orbital fat (Iliff et al. 1999). The importance of this system, not least in orbital trauma, has been pointed out by Koornneef (1982). Connective septae surround the eyeball and anchor it and its eye muscles to the orbital walls, via the common muscle sheaths at the eyeball level and the peri-orbit coating the inner walls of the bony orbit. The arrangement of septae and the interspacing orbital fat and hyaluronic acid are a prerequisite for the sophisticated eye motility. For this reason, impingement of orbital fat and septae in an orbital floor fracture may also prevent normal function of the inferior rectus muscle. Furthermore, intrinsic damage to the connective tissue apparatus caused by haemorrhage and oedema affects motility, and scarring may prevent septae from sliding against one another and thus impairing eye motility (Koornneef 1982).

1.3 Fracture classifications

The term 'zygomatico-orbital fractures' (Ellis et al. 1985; Rohrich et al. 1992; Zingg et al. 1992) excludes other zygomatico-maxillary fractures, such as isolated fractures of the zygomatico-temporal arch and any fracture of the zygoma or maxilla not involving the orbit.

Fracture classification systems are redundant (Hötte 1970; Zingg et al. 1992) and may even be confusing, which makes comparisons between studies difficult. In the present thesis the term 'orbital floor fracture' is used to mean the same as 'zygomatico-orbital fracture'. These terms are used to include any fracture involving the orbital floor irrespective of the degree of extension into the adjacent zygoma/maxilla (Figure 3) (Rohrich et al. 1992; Zingg et al. 1992). Therefore, two specific entities of orbital floor fractures are (i) tetrapod fractures with a linear

fracture along the orbital floor (Figure 3B); and (ii) pure blow-out fractures of the floor not involving the infra-orbital rim (Figure 3C-D). This classification agrees with that used by Smith et al. in 1962 (Hötte 1970).

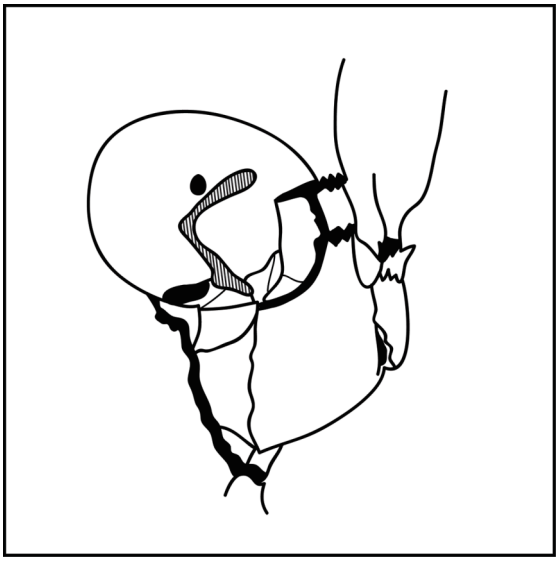

Figure 3A. *Zygomatico-orbital fracture (multi-fragment) on the left side.*

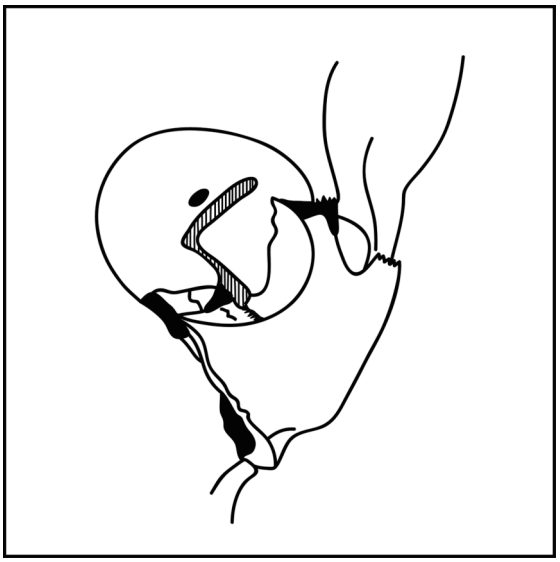

Figure 3B. *Tetrapod fracture on the left side.*

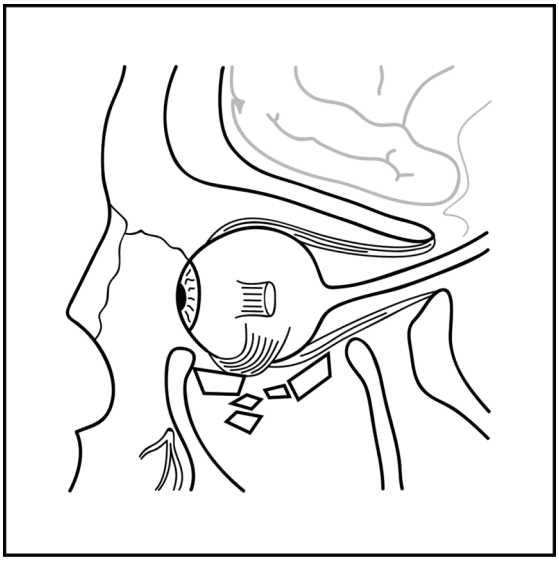

Figure 3C. *Blow-out fracture on the right side.*

Figure 3D. *Left blow-out, lateral view*

1.4 Symptoms and signs of an acute orbital floor fracture

The acute stage of orbital trauma is often associated with a peri-orbital haematoma and swelling, more or less making opening of the eye impossible without manual assistance (Figure 4). The orbital rims and malar prominence are unaffected in pure blow-out fractures, while in other zygomatico-orbital fractures the cheek contour is often flattened to varying degrees owing to dislocation of the zygomatic bone. The flattening may, however, be concealed by the swelling. Mouth opening capacity and occlusion may be affected when a dislocation of the zygoma is present, because of its close location to the temporo-mandibular joint (TMJ) and the masseter and temporalis muscles (Celic et al. 2003).

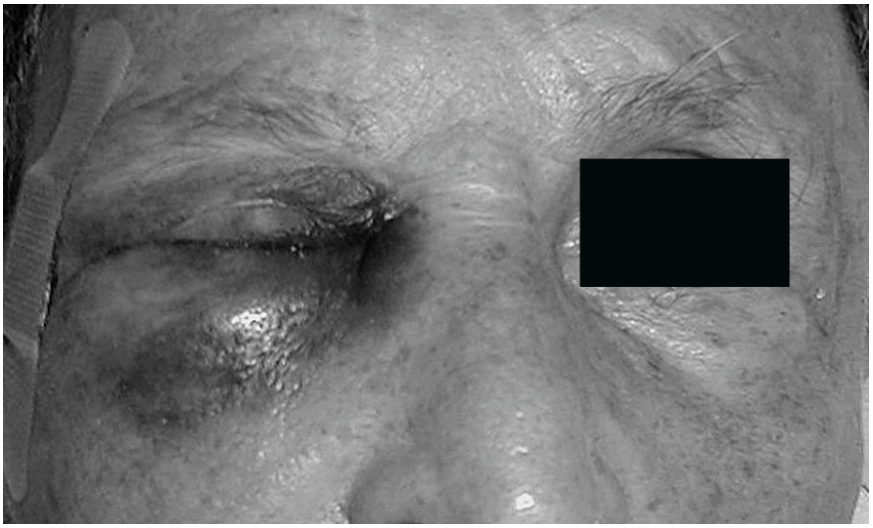

Figure 4. *Peri-orbital swelling covering the right eye.*

The infra-orbital nerve runs along the orbital floor in the infra-orbital sulcus and enters the cheek after passing the infra-orbital foramen. Consequently, this nerve is often affected in orbital floor fractures, giving rise to disturbed sensibility in the cheek, nose, upper lip and gum/teeth of varying degrees on the ipsilateral side of the face (Vriens et al. 1998).

Hypophthalmos or enophthalmos may be caused by displacement of the eye globe due to an enlargement of the bony orbit (Manson, Clifford et al. 1986). It has been shown that a 0.8–1 ml increase of bony orbital volume corresponds to 1 mm on the Hertel exopthalmometer (Lee & Chiu 1993; Ploder et al. 2002). Accordingly, an increase in the bony orbital volume of 1.5–2 ml will cause clinically evident enophthalmos (≥2 mm) (Ploder et al. 2002). Enophthalmos may be temporarily concealed and compensated for by haematoma and oedema. Likewise, exophthalmos may result from a reduced orbital volume or a swelling of intra-orbital soft tissues, or a combination of the two factors.

A ‘sunken eye’ in the acute stage may be caused by the so-called ‘retraction syndrome’, an entrapment of the inferior rectus muscle causing the superior rectus muscle to exert a strong inward pull on the eye bulb as a reaction to the entrapped antagonist (Hötte 1970; Kanski 1989).

Diplopia may be caused by displacement of the eye globe, as the two eyes are no longer in line with the same visual axis (Cogan 1969). According to Manson, Grivas et al. (1986), diplopia may occur when the enophthalmos is ≥5 mm. In such cases eye motility may still be unimpaired. Diplopia may also be caused by a temporary paresis (Converse & Smith 1960; Hötte 1970; Mauriello et al. 1996; Metz et al. 1974), when the eye of the injured orbit does not show normal motility. The inferior branch of the third cranial nerve (oculomotor nerve) can be affected in an orbital floor fracture and cause a combination of pupillary paralysis and weakness of the inferior and medial recti and the inferior oblique muscles (Helveston 1977; Putterman 1987; Spector 1993). This is, however, rare since the nerves are well protected and lie on the side of the muscle opposite to the fracture (Putterman 1987).

Another cause of diplopia is mechanical restriction of the motility of an extra-ocular eye muscle. In orbital floor fractures the infra-orbital rectus muscle may be swollen or entrapped in the fracture, and may cause restricted vertical eye motility (Converse & Smith 1960; Iliff et al. 1999; Mauriello et al. 1996; Putterman et al. 1974; Remulla et al. 1995).

The ‘orbital floor trap door’ fracture that occurs in children and adolescents is an example of the latter. The fracture is characterized by the features of the young elastic skeletal bone (Burnstine 2003; Sires et al. 1998; Wachler & Holds 1998). Orbital soft tissue/the inferior rectus muscle becomes tightly entrapped in the fracture, leading to ischaemia, and if not treated in time, fibrosis and permanent diplopia may develop. The symptoms and signs in the acute stage of an ‘orbital floor trap door’ fracture can be misleading and are often mistaken for those of cerebral concussion. The usual ‘black eye’ may be missing (the condition is also called the ‘white-eyed’ blow-out fracture). The patient suffers from pain and nausea and sometimes from vomiting, bradycardia and syncope (oculocardiac reflex) (Sires et al. 1998). In these cases, acute surgery to release the entrapped tissue is urgent if serious complications, such as permanent diplopia, are to be prevented (Figure 5).

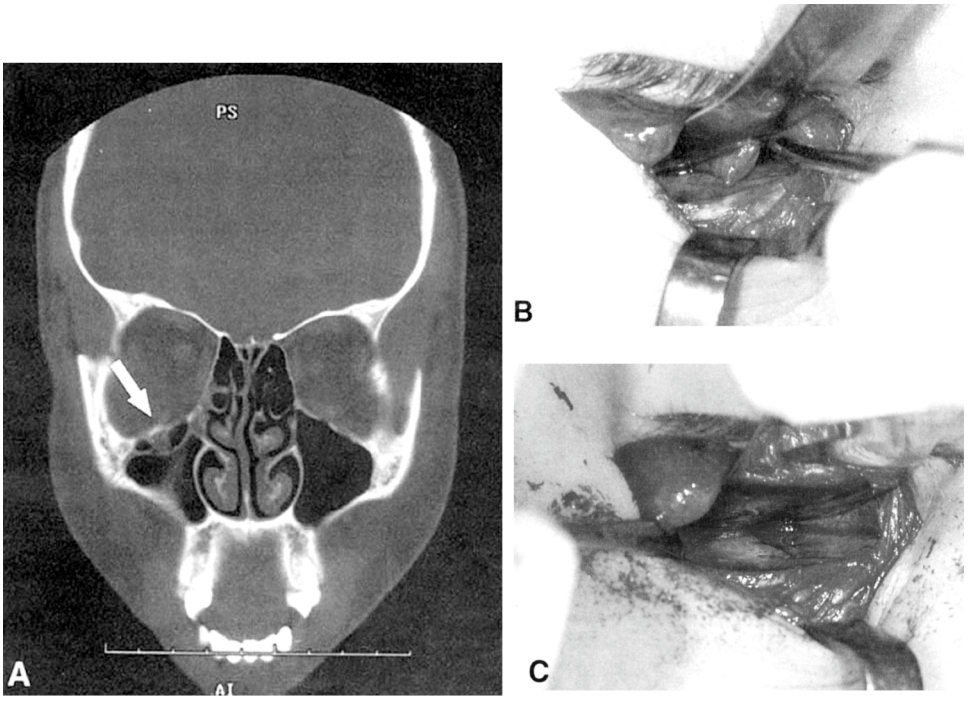

Figure 5. *Orbital floor trap door.* ***A*** *Pre-operative CT: no discontinuity of the orbital floor, right side.* ***B*** *Intra-operatively, soft tissue can be seen tightly tethered in the undislocated floor fracture.* ***C*** *Soft tissue is released and the orbital floor is thereafter realigned.*

1.5 Diagnostic methods

Thorough clinical examination in facial fractures is important. At any suspicion regarding vision, occlusion and/or mouth opening in association with the trauma, both an ophthalmologist and an oral and maxillofacial (OMF) surgeon must be consulted. Detailed information about the fracture features is obtained from CT scans - in the 1990s from horizontal and coronal views (Freund et al. 2002; Ilankovan et al. 1991).

Reliable diagnostic methods that reflect the true circumstances concerning anatomy and functioning after a facial trauma are essential to make a well-founded decision about whether to operate or not. However, the commonly used expression 'orbital floor *exploration*' indicates that the surgical intervention is used for diagnostic purposes, which raises the question whether routine pre-operative diagnostic methods are sufficient.

In trying to differentiate between patients who need acute surgical intervention and patients not needing an operation (see 1.4) great demands are put on the accuracy of the diagnostic methods; not least when it comes to evaluating eye motility in cases where diplopia is present.

Dislocation of bone fragments, the size of the fracture, enophthalmos and herniation of intra-orbital soft tissue are established by means of the radiologic examination. However, at present no objective test is available for assessing the functional aspect of eye motility.

1.5.1 Imaging

In the early 1990s plain X-rays were still widely used in facial fracture diagnostics. However, since CT scanning has become increasingly available, this has been the method of choice (Ilankovan et al. 1991; Manson 1999).

Imaging techniques have developed rapidly and compared with plain X-ray films, CT examinations provide more detailed information about the bony structures. The volume of the bony orbital volume can be calculated and the risk of enophthalmos development predicted (see 1.4) (Lee & Chiu 1993; Ploder et al. 2002). Surface coil CT offers the possibility of subsequent converting views in any direction (Rake et al. 2004). Three-dimensional (3D) CT has proved to be helpful in planning treatments such as facial reconstructive surgery, providing more information without additional radiation to the patient (Gellrich et al. 2002). Magnetic resonance tomography (MRT), however, has the advantage of displaying the status of the soft tissues with great accuracy (Freund et al. 2002; Ilankovan et al. 1991). This is important in orbital floor fractures, giving the possibility of visualizing entrapped soft tissues. Only, MRT is insufficient in assessing the bony structures and therefore needs to be combined with CT (Freund, Hähnel et al. 2002).

Abràmoff et al. (2001) have presented a method of studying soft tissue motions in the orbit by means of cine MRT; patients (enucleated or with Grave's orbitopathy)

were instructed to hold fixation for 15 seconds in different directions of gaze, 8° apart, to produce a sequence of images which together described motion of the tissues. The authors concluded that further exploration of the method in clinical use was considered worth while. In its present form Cine MRT does not capture the dynamics; the velocity of eye motility. MRT is yet not commonly available and it is expensive, time-consuming, claustrophobic to some and contraindicated in patients with pacemakers, arterial clips and metal implants.

The ultrasound (US) technique has also been evaluated for use in orbital floor fracture diagnostics (Jank et al. 2004). Comparing the diagnostic value of US with that of CT Jank et al. showed that there are no statistically significant differences, provided a skilled and experienced operator perform the US examination. However, both Us and CT give false-negative and false-positive results (Jank et al. 2004),

1.5.2 Functional tests

Essential functions at risk in orbital floor fractures involve eyesight and the mouth opening capacity. Disturbed sensibility in the distribution area of the infra-orbital nerve is frequent, but has commonly been regarded as an inferior problem (Hötte 1970). Methods used to assess these functions are described in the following section.

1.5.2.1 Methods of assessing affected eye motility and diplopia

As previously stressed, it is crucial to establish whether or not diplopia in association with an orbital floor fracture is caused by entrapment of soft tissues (Burnstine 2003; Sires et al. 1998; Wachler & Holds 1998). Entrapment causes restricted eye motility, but as CT scans and MRT only provide stills, the clinician can no more than guess the presence of entrapment. Eye motility can only be demonstrated by a functional test.

A number of tests are available to assess whether diplopia is present and whether eye motility is affected. They include the forced duction test, the forced generation

test, the Hess screen or Lee screen test, the Goldmann or the Humphrey perimeters and the prism and alternate cover test (Hötte 1970; Kanski 1989; Metz 1976; Putterman et al. 1974; Spector 1993). Often, however, eye motility is tested simply by asking the patient to fixate and follow the movement of a penlight in the nine cardinal directions of gaze while the examiner observes the movement of the eyes (Cogan 1969; Spector 1993). No test available at present objectively measures bilateral vertical motility of the eyes. Below, some of the tests that are currently available are described.

(i) The *forced duction test* (Figure 6) is used to establish mechanical restriction and is inconvenient to the patient when performed pre-operatively under local anaesthesia. The test is not objective; it relies entirely on the examiner, and assessment may be difficult even in experienced hands, particularly when the eye cannot be visualized due to peri-orbital swelling (Metz 1976). Stiffness caused by haematoma or oedema of an extra-ocular eye muscle or the orbital connective tissue apparatus in the adjacent orbital fat can be hard to distinguish from entrapment (Putterman 1987). In other words, the forced duction test can be positive for reasons other than entrapment. Also, there is a possibility of unintentional inward pressure against the bulb during forced duction testing, which may give a false impression of full rotation (Metz 1976; Spector 1993). Accordingly, the test does not automatically provide justification for surgery (Metz et al. 1974). Furthermore, there is the opinion among clinicians that the test procedure may harm the delicate connective tissue apparatus and subsequently cause even worse damage and risk permanent motility disturbances (Crewe 1981). An even more serious consequence is that manipulating the extra-ocular muscles by traction might trigger the oculocardiac reflex (McNab 2001) and give rise to bradycardia and even cardiac arrest.

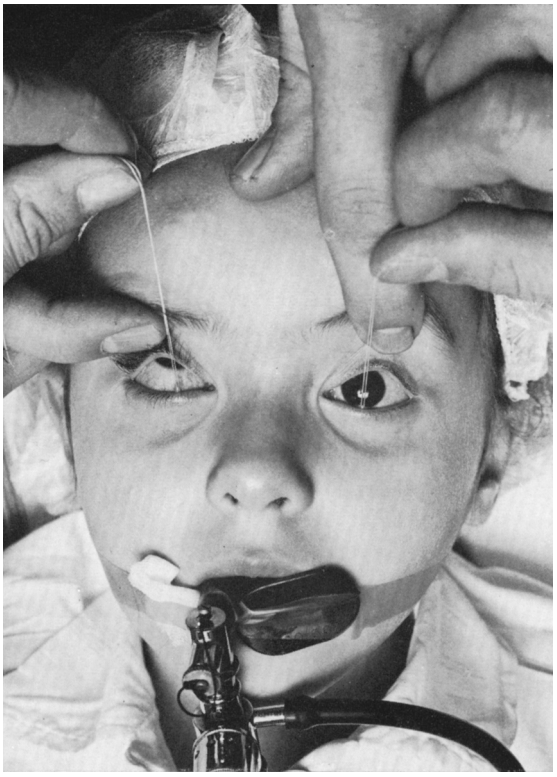

Figure 6. *Forced duction test. (Source: Hötte 1970, 'Orbital fractures'. Published by permission from Royal Van Gorcum BV, Assen, The Netherlands.)*

(ii) The forced generation test (Metz 1976) requires a co-operative, awake patient and an experienced examiner who can sense and assess the pull of the muscle on the forceps (Metz 1976). The development of the Scott forceps has made it possible to measure the force generated by the examined muscle; however, at the risk of tearing the cornea (Metz 1976; Spector 1993). A method for carrying out quantitative forced duction and forced generation tests by using a suction cup contact lens placed on the eye bulb has been described, but may cause intra-ocular hypertension (Collewijn et al. 1975; Spector 1993). The instrumentation is advanced and the suction cup lens technique is used primarily for research purposes in investigations of the oculomotor and visual systems.

(iii) The *saccadic velocity test* has been shown to distinguish a paretic eye muscle from restriction in blow-out fractures (Metz et al. 1974). The test provides information about the active force available for moving the eye globe (Metz 1976). The saccadic velocity test is objective. One eye at a time is measured and measurement of the

upward saccade is used as the control in the case of suspected inferior rectus muscle affection. Velocities are normal in restriction but show limited range; in case of paresis, velocities are diminished (Baloh et al. 1975; Metz et al. 1974). The usefulness of the saccadic velocity test has been displayed in patients with thyroid-associated ophthalmopathy, as restrictive ocular motility disturbances are very common among this group of patients (Tian et al. 2003). In these patients recovery after medical treatment could be verified by means of improved saccadic velocities.

The mechanism of voluntary saccades bears close resemblance to the optokinetic reflex. Also, smooth pursuit belongs to the group of *visual following reflexes*. The neurophysiological mechanisms are, however, not the same as for the saccadic movements (Leigh & Zee 1983), as the function consists of smooth tracking eye movements with continuous foveation of a moving object rather than refixations of a moving object.

(iv) *Perimetric methods* are used to examine the visual fields. The success of these methods depends on the patient's subjective response to a visual stimulus (Kanski 1989) and bilateral vision is a prerequisite. The procedure is performed manually in case of the Goldmann perimeter while the Humphrey perimeter is computerized. The manual test procedure is time-consuming and can be tiring for the patient.

A Goldmann chart scoring template for establishing the fields of binocular single vision (BSV) was developed and described by Woodruff et al. in 1987. Using the template, the scores of the areas of the greatest importance in performing daily activities such as reading and walking on stairs are emphasized. This scoring system proved to be consistent with the patients' assessments of their disabilities.

(v) The *prism and alternate cover test* belongs to the group of strabismus tests. A prism compensates for the deviation and gives the angle of deviation which is read from the strength of the prism. The test measures the extent of diplopia but does not measure motility.

(vi) The *Maddox rod test* requires bilateral eyesight and is used primarily in strabismus diagnosis. It measures vertical and horizontal deviations by intentionally giving the images from each eye a different shape or colour (Kanski 1989; Spector 1993). The amount of dissociation between the two images in diplopia is measured by means of prisms.

(vii) The *Hess screen* (using red-green filter goggles) and *Lee screen test* (using a mirror) examine the patient's perception of a dot of light, which is marked on a cross-ruled chart, in different directions of gaze (Kanski 1989). One square on the chart corresponds to approximately 5º (Spector 1993). These tests require bilateral eye sight. The two charts obtained, one from each eye, are compared. In the case of unilateral restriction of the inferior rectus muscle caused by an orbital floor fracture, the chart would typically show a smaller field on the ipsilateral chart (Hartstein & Roper-Hall 2000; Hötte 1970).

In summary, all these tests and methods used to assess affected eye motility and diplopia require either bilateral eyesight, or are difficult or impossible to perform and evaluate when a peri-orbital swelling is present. An objective test that can simultaneously measure vertical smooth pursuit eye motility in the two eyes, even when visual input to the injured eye is obstructed, is still lacking but desirable.

1.5.2.2 Mouth opening

Mouth opening capacity is measured with a millimetre ruler as the distance between the upper and lower front teeth. In clinical tradition, if the inter-incisal distance is ≥40 mm, this has been considered acceptable although there has been some discussion on the topic (Agerberg 1974; Celic et al. 2003). Maximal mouth opening capacity is generally achieved by adding the overbite to the inter-incisal distance (Agerberg 1974). Specific callipers are obtainable, but have not proved superior to using a millimetre ruler (Celic et al. 2003). Agerberg suggests using three fingers' breadth as the normal span for the single individual (Agerberg 1974).

1.5.2.3 Sensibility

In clinical practice the sensibility in the distribution area of the infra-orbital nerve is normally tested bilaterally, and the injured side is compared with the uninjured (Westermark et al. 1992; Vriens et al. 1998). Generally, cotton wool and a needle are used to test for blunt and sharp touch. Two-point discrimination tests by means of a specific device, as well as cold sensation may also be tested (Vriens et al. 1998).

1.5.2.4 Patient-reported symptoms

To assess patients' experience of diplopia Holmes et al. (2005) have recently developed a questionnaire to test patients' suffering from diplopia due to neuro-ophthalmologic disease or thyroid-associated ophthalmopathy. The questionnaire has been validated against the Goldmann perimeter findings (testing BSV). The questionnaire is completed during a structured interview, with the examiner asking the questions, and filling in the patient's response.

A mandibular function impairment questionnaire has been tested for TMJ osteo-arthritis and head and neck oncology patients (Dijkstra et al. 2006), but to the best of our knowledge, a questionnaire that is valid and reliable in the context of problems related to mouth opening in zygomatico-maxillary complex fractures is still lacking.

Finally, visual analogue scales (VASs) have been widely used and tested for patients' self-assessment of varying degrees of pain in different contexts (Collins et al. 1997; McCormack et al. 1988).

1.6 Treatment

Treating facial fractures is normally a matter of collaboration between specialists. Zygomatico-orbital fractures are often treated by ears, nose and throat (ENT) surgeons in teamwork with OMF surgeons, while plastic surgeons and neurosurgeons are usually involved in more extensive and less common, high-energy facial injuries (Gewalli et al. 2003).

Facial fracture treatment aims at full restitution of physical appearance and function. The first operation of a facial fracture must be regarded as the one and only opportunity to achieve an optimal result (Manson, Clifford et al. 1986; Yaremchuk 1992). This involves an exact reposition of bone and soft tissues, rigid fixation of the fracture and an orbital floor implant where necessary. Concerning zygomatico-orbital fractures, facial symmetry and no visible scarring, and normal vision and eye motility need to be attained, as well as normal mouth opening and restored sensibility in the distribution area of the infra-orbital nerve.

In the majority of orbital floor fractures, surgery within 2 weeks is recommended (Burnstine 2002; Courtney et al. 2000; Hakelius & Ponten 1973; Hartstein & Roper-Hall 2000; Hawes & Dortzbach 1983), as delayed surgery may be complicated by scarring and shrinking of soft tissues (Iliff et al. 1999; Koornneef 1982; Manson, Clifford et al. 1986; Yaremchuk 1992).

Two main strategies for how to treat orbital floor fractures, and blow-out fractures in particular, have been put forward (Hakelius & Ponten 1973; Putterman et al. 1974; Rohrich et al. 1992; Shumrick et al. 1997). The diversity in opinions may be an illustration of the lack of sufficient pre-operative diagnostic information. In cases of fractures not meeting the absolute criteria for surgery (see 1.6.1) the two main strategies have been (i) to perform diagnostic orbital floor explorations; or (ii) to 'wait and see' and rely on clinical assessments and close follow-up (Burnstine 2003; Koornneef 1982; Putterman et al. 1974), with any surgical intervention being postponed until signs or symptoms (diplopia and/or enophthalmos) appear and motivate surgery.

Both these strategies have disadvantages. Diagnostic explorations routinely performed carry the risk of a number of patients being submitted to 'unnecessary' operations, and subsequent risks of complications. Waiting for the diplopia to subside may be hazardous in cases where the condition is caused by tight entrapment in a 'trap door' fracture, which is an indication for acute surgery within a

few hours of the trauma (see 1.4) (Burnstine 2003; Sires et al. 1998; Wachler & Holds 1998).

However, the widespread opinion among facial fracture surgeons seems to be to use a mixture of these strategies, treatment being individually considered for each patient (Burnstine 2002; Hartstein & Roper-Hall 2000; Shumrick et al. 1997). In the presence of diplopia without any other evident indications for surgery, a common guideline has been to 'wait and see' for 2 weeks after the trauma (Burnstine 2002; Hartstein & Roper-Hall 2000). If diplopia still remains after 2 weeks, surgery is performed. By contrast, no such time limits have been set for the treatment of enophthalmos.

1.6.1 Surgical methods

There are several surgical treatment options, but primarily the surgeon has to consider whether surgical criteria are met and whether surgery is at all indicated. The literature provides some clear-cut guidelines (Burnstine 2002; Hartstein & Roper-Hall 2000; Hawes & Dortzbach 1983). Absolute indications for surgery are a dislocated fracture that affects appearance and/or function; enophthalmos; entrapment; an orbital floor fracture that extends over ≥50% of the floor area; and herniation of soft tissue of ≥1.5 ml. However, some authors report that as long as the peri-orbit is intact, a floor fracture even larger than 50% may heal without sequelae, without surgical treatment (Converse & Smith 1960; Hartstein & Roper-Hall 2000; Putterman et al. 1974). The presence of diplopia as such is no absolute indication for surgery (Helveston 1977; Remulla et al. 1995).

1.6.1.1 Closed reduction

Closed reduction is usually used for tetrapod fractures and isolated fractures of the zygomatic arch. Common methods for closed reduction are the Gillie's procedure via a temporal incision, or a transcutaneous hook inserted through the skin next to the fracture site. When the reduced fracture is stable and the forced duction test is negative, no further surgery is required (Kovacs et al. 2001; Zingg et al. 1992).

1.6.1.2 Open reduction

Unstable fractures and comminuted zygomatico-orbital fractures usually require open reposition and fixation (Burnstine 2003; De Man & Bax 1988; Westermark et al. 1992; Zingg et al. 1992). One or two skin incisions and an intra-oral incision may be necessary to obtain access to all fracture sites. To obtain access to the orbital floor, a subciliary incision or a transconjunctival incision is commonly used (Appling et al. 1993). Fractures may need rigid fixation and a floor defect may need covering by a floor implant.

1.6.1.3 Endoscopic reduction

Endoscopic reduction is a surgical method mainly used as an adjuvant to open surgery in blow-out fractures and is rarely used on its own (Woog et al. 1998), even if this has been attempted in recent years (Strong et al. 2004). The endoscope is introduced into the maxillary sinus through the nose or, more commonly, via a maxillary sinus antrostomy (Strong et al. 2004; Woog et al. 1998). Reduction of herniated orbital soft tissue can be verified. Skin incisions may be avoided entirely by repositioning the orbital soft tissues from beneath and inserting an orbital floor implant via an antrostomy (Strong et al. 2004) or by supporting the fracture with a gauze tampon or balloon catheter (Hinohira et al. 2005). However, with this technique there is a risk of iatrogenic complications caused by bone fragments pushed into vessels, the inferior rectus muscle, connective tissue septae or the optic nerve (Converse & Smith 1960; Manson 1990; Strong et al. 2004). The number of studies published indicates a great interest in the method and a potential for development and improvement.

1.6.1.4 Optical navigation systems in computer-aided maxillofacial surgery

Computer-aided surgery is a new technique undergoing rapid progress. An optical navigation system is used for pre-operative planning, intra-operative navigation and postoperative control in treatments such as ablative tumour surgery, orthognatic

surgery and orbital and mid-face reconstruction (Gellrich et al. 2002) with the aim to improve precision.

Irrespective of the surgical method used, a postoperative radiologic examination (plain X-ray or CT) is advocated as a routine measure to check bone alignment and implant position (Manson 1999).

1.6.2 Materials for osteosynthesis and implants

Materials for osteosynthesis and implants develop continuously, improving the chance of achieving excellent aesthetic and functional results.

Micro- and miniplates are used to line up and fixate the fracture fragments. Plates are generally made of titanium, but in recent years resorbable materials have become available (Waris et al. 2004).

Support for an orbital floor fracture can be provided either from beneath, by packing the maxillary sinus (antral packing) using the Caldwell-Luc approach, or by placing a floor implant to cover the fracture/defect through an orbital approach. Serious negative side effects from packing the maxillary sinus have been reported, as previously mentioned (see 1.6.1.3) (Hötte 1970; Manson 1990; Rosbe et al. 1997; Strong et al. 2004). Orbital floor implants are used to cover a defect and prevent reherniation of soft tissue, or merely to smooth a rough area or a small defect. Large defects require stable implants, while in the case of small fractures a soft inlay may be sufficient (Putterman 1987). Examples of implant materials are listed in Table 1 (Baumann et al. 2002; Converse & Smith 1960; Courtney et al. 2000; Dietz et al. 2001; Ellis & Tan 2003; Glassman et al. 1990; Goldberg et al. 1993; Guerra et al. 2000; Nguyen & Sullivan 1992; Rosbe et al. 1997; Rubin et al. 1994; Waris et al. 2004; Yaremchuk 1992; Zingg et al. 1992). Autogenous tissues are often preferred; however, they also have disadvantages (Table 1) (Goldberg et al. 1993; Nguyen & Sullivan 1992). It should be noted that if orbital floor surgery is performed through a subciliary incision, prolonged operation time and donor site morbidity are prevented

if an alloplastic or biodegradable material is chosen (Baumann et al. 2002; Dietz et al. 2001; Ellis & Tan 2003; Glassman et al. 1990; Goldberg et al. 1993; Guerra et al. 2000; Nguyen & Sullivan 1992; Rubin et al. 1994).

Table 1. *Examples of implant materials used in orbital floor repair.*

Implant material	**Advantage**	**Disadvantage**	**Studies** **(level of evidence)**
Membranous bone	Autogenous	Morbidity at donor site Extended operation time Resorption unpredictable	Converse et al. 1967 (retrospective case series) Nguyen & Sullivan 1992 (review, experience) Yaremchuk 1992 (experience) Goldberg et al. 1993 (review)
Cartilage	Autogenous	Morbidity at donor site Extended operation time Resorption unpredictable	Zingg et al. 1992 (retrospective case series)
(Lyodura)/Lyoplant*	Easy to shape and handle Biocompatible	Soft, unstable Not suitable for large defects	Guerra et al. 2000 (retrospective case series)
Titan	Biocompatible Stable	Foreign material that remains in the body Combination with bone recommended	Ellis et al. 1985 (retrospective case series) Glassman et al. 1990 (experience)
Porous polyethylene sheets	Easy to shape and handle Biocompatible Stable	Foreign material that remains in the body	Goldberg et al. 1993 (review) Rubin et al. 1994 (prospective case series)
Resorbable implants	Stable at first Disintegrates in the course of weeks	Foreign body reactions Cyst formation Insufficient support in large defects	Waris et al. 2004 (review of randomized clinical trials (RCT)) Dietz et al. 2001 (RCT) Baumann et al. 2002 (retrospective study)
Antral packing, usually combined with floor implant	None since the introduction of a variety of stable implant materials	Inconvenient to patient Risk of infection, with fracture site exposed to the outside via the nose cavity Risk of blindness Non-anatomical shape	Rosbe et al. 1997 (case reports) Hötte 1970 (review, experience) Manson 1990 (review, experience)
Silastic sheet (Teflon)	Easy to shape and handle	Foreign body reaction and extrusion common	Zingg et al. 1992 (retrospective case series) Courtney 2000 (review) Goldberg et al. 1993 (review)

*Because of mad cow disease Lyodura was replaced by Lyoplant (collagen from New Zealand cattle) in 1998.

1.7 Sequelae

Long-term signs and symptoms after orbital floor fractures are common despite the wide range of treatment options available (Afzelius & Rosen 1979; Burnstine 2002; Hötte 1970; Jungell & Lindqvist 1987; Mathog et al. 1991; Nguyen & Sullivan 1992; Rohrich et al. 1992; Tadj & Kimble 2003; Yaremchuk 1992). The effort to prevent or reduce sequelae must have high priority as the face is so important in interpersonal communication, and because of the fact that the facial skeleton houses essential basic functions such as eyesight and mouth opening.

Although it has to be kept in mind that the selection of patients and treatment often differs between studies, and accordingly, that any comparison must be made with great caution, the results of other outcome studies are interesting. Reported frequencies of different sequelae after orbital floor fractures will be presented in the following section.

1.7.1 Physical appearance

Before the advancement of surgical techniques and implant materials it was difficult to prevent cosmetic sequelae, such as flattened cheek prominence or enophthalmos. The importance of exact repositioning and rigid fixation as well as the use of orbital floor implants in restoring orbital volume and preventing facial asymmetry, enophthalmos and diplopia is widely acknowledged (Manson, Clifford et al. 1986; Mathog et al. 1989). Incision techniques and the choice of incision sites causing as little scarring as possible have also been in focus for improvements (Appling et al. 1993; Manson et al. 1987; Rohrich et al. 2003).

Cosmetic complaints from persisting visible incision scars have been reported in 2–30% of patients when the subciliary incision has been used (Afzelius & Rosen 1979; Appling et al. 1993; Guerra et al. 2000; Tadj & Kimble 2003). Flattening of the cheek prominence after surgery for zygomatico-orbital fractures has been reported in 3–20% (Afzelius & Rosen 1979; De Man & Bax 1988; Tadj & Kimble 2003) and

enophthalmos in 2–7% (Hawes & Dorzbach 1983; Guerra et al. 2000; Tadj & Kimble 2003).

1.7.2 Vision

Diplopia is a severe and disabling handicap when present in, or close to, primary position. Diplopia within 20–30º of vertical up or down gaze is considered disabling (Hawes & Dortzbach 1983; Putterman et al. 1974; Van Eeckhoutte et al. 1998; Woodruff et al. 1987), particularly in down gaze, which may render difficulties in reading and walking on stairs. To some extent the patient can make up for a vertical deviation by depressing or elevating the chin. Suppression, an 'active neglect' of the vision in the deviating eye, may develop over the course of time (Leigh & Zee 1983). Some of these cases may be treated with prism glasses or eye muscle surgery (Kushner 1995).

Studies of the outcome of zygomatico-orbital fractures have revealed an occurrence of between 5% and 37% of diplopia (Afzelius & Rosen 1979; Biesman et al. 1996; Tadj & Kimble 2003). This range in occurrence may be influenced by dissimilarity in patient selection. As an illustration of this, in a 10-year retrospective study of 199 patients Tong et al. (2001) noted that diplopia at presentation was considerably more common in blow-out fractures (72%) than in other zygomatico-orbital fractures (34%). They suggested this to be explained by the latter fracture type being less prone to muscle or soft tissue entrapment (Tong et al. 2001).

Blindness rarely occurs in association with the trauma, and is seldom caused by orbital floor surgery (Ilankovan et al. 1991; Liu 1994; Rosbe et al. 1997). Levin and Kademani have reported a 0–8% incidence of blindness due to the orbital trauma (Levin & Kademani 1997). In a study by Wilkins et al. (1982) blindness due to the surgical procedure occurred in 1/1,500 orbital explorations. Increased orbital pressure and retrobulbar haematoma, compromising the function of the optic nerve, have the

potential of causing blindness, as has bone spicule impingement on the optic nerve (Liu 1994).

1.7.3 Sensibility

Long-term sensibility disturbances are reported in 5–54% of cases (Afzelius & Rosen 1979; De Man & Bax 1988; Guerra et al. 2000; Hawes & Dortzbach 1983; Jungell & Lindqvist 1987; Kovacs et al. 2001; Putterman et al. 1974; Tadj & Kimble 2003; Tong et al. 2001; Westermark et al. 1992; Vriens et al. 1998). Rigid fixation of fractures has proved favourable in reducing sensibility problems (Westermark et al. 1992) but some studies have indicated the opposite, reporting that manipulation of the fracture may cause an increase in these symptoms (Peltomaa & Rihkanen 2000). Again, it is probable that this can be explained by differences in the patient populations studied. Putterman et al., studying non-surgically treated blow-out fractures, noted a 9% occurrence of remaining sensibility disturbances (Putterman et al. 1974). Vriens et al. found serious sensibility problems among 10% of non-surgically treated fractures (with minimal dislocation) of the zygomatico-orbital complex (Vriens et al. 1998).

A common opinion expressed by Hötte in 1970 is that sensibility disorders due to an orbital fracture are a ‘minor complaint’, which are ‘never disabling’ and ‘never an indication for surgery’. Twenty years later, in opposition to this opinion, sensibility was discussed as a primary indication for surgery (Boush & Lemke 1994; Hötte 1970; Tengtrisorn et al. 1998). A suggestion to treat sensibility disturbances with corticosteroids in selected cases (Vriens et al. 1998) also reflects the acknowledgement of and increased concern about this kind of symptom.

1.7.4 Mouth opening and occlusion

Maximal mouth opening can be temporarily hindered due to muscle trauma, and permanently hindered if dislocated bone fragments that interfere with jaw functioning are not properly repositioned (Boyd et al. 1991; Celic et al. 2003; Zingg et al. 1992).

The arch of the zygomatic bone (and temporal bone) protects the TMJ and functions as the insertion for the masseter muscle. Also, as it lies lateral to the temporalis muscle, it is obvious that inadequate repositioning of fractures involving the zygomatico-maxillary complex can compromise mouth opening and affect the occlusion. Consequently, it may make biting, chewing and yawning difficult and may even impede speech and laughing (Dijkstra et al. 2006). Afzelius and Rosen noted a 9% frequency of persisting reduced mouth opening capacity at long-term follow-up after surgery (Afzelius & Rosen 1979).

1.7.5 Patients' experiences of sequelae

Only a few studies have investigated patients' opinions of the final outcome after facial fractures, and they have often focused on one single outcome variable such as the cosmetic outcome or remaining sensibility disorders (Afzelius & Rosen 1979; Gewalli et al. 2003; Vriens et al. 1998). No validated or reliability-tested, diagnosis-specific questionnaire has been available for investigating patients' experience of the outcome after orbital floor fractures. Nevertheless, patients' experiences of the outcome must be recognized as an important concern in evaluation of the treatment. Accordingly, this information must be sought. Estimating instruments for assessing patients' experiences of diplopia and jaw function, for clinical conditions other than zygomatico-orbital fractures, have recently been presented, examples of which are given above (see 1.5.3).

1.8 Clinical problems

As surgery is not risk-free, conducting orbital floor explorations solely for diagnostic purposes is not satisfactory (Burnstine 2002). The diagnostic problem is particularly urgent in assessing eye motility and establishing whether entrapment of soft tissues is the cause of diplopia, which sometimes has to be treated immediately with surgery (see 1.4 and 1.5).

In spite of a series of available diagnostic methods, one major question remains: How do surgeons distinguish those patients who will benefit from surgery from those who are best handled non-surgically? In many cases the decision is obvious: either the patients need surgery as they meet the absolute criteria for surgery, or they do not since they have no symptoms and the fracture is undislocated. Difficulties arise particularly when a floor fracture does not meet the absolute operation criteria, but the patient nevertheless suffers from restricted eye motility and diplopia.

An accurate and reliable diagnostic method for making an objective evaluation of the eye motility is therefore needed. Imaging with CT or MRT cannot establish the active eye motility function. For this purpose, a functional test is required. The forced duction test and the forced generation test are both difficult to perform and evaluate and both are not objective. Neither are they useful in the acute stage of an orbital floor fracture when a peri-orbital swelling is usually present. Consequently, a functional objective test of vertical eye motility to provide evidence for or against surgery is still lacking.

1.9 Previous research

Clinical studies of zygomatico-orbital fractures mainly consist of uncontrolled, non-comparative retrospective case series (Burnstine 2002). Current clinical knowledge very much relies on experience and large case series presented by experienced clinicians in review articles (Burnstine 2002; Courtney et al. 2000; Ellis et al. 1985; Glassman et al. 1990; Hartstein & Roper-Hall 2000; Iliff et al. 1999; Koornneef 1982; Kushner 1995; Manson 1999; McNab 2001; Nguyen & Sullivan 1992; Putterman et al. 1974; Rohrich et al. 1992; Yaremchuk 1992; Zingg et al. 1992). Conclusions from this experience were published in the guidelines for diagnostics and treatment presented in the previous sections of this thesis.

Studies evaluating treatment of zygomatico-orbital fractures are limited for ethical reasons and are difficult to standardize and randomize owing to the varying

characteristics of the fractures which are, moreover, often not established until surgery. This difficulty is illustrated by the fact that only one randomized controlled study concerning orbital floor fractures is to be found in MEDLINE and the Cochrane library, a comparison of two different kinds of orbital floor implants in blow-out fractures (Dietz et al. 2001). Another twelve controlled studies were found in the literature, mainly presenting comparisons of imaging techniques (Ilankovan et al. 1991; Jank et al. 2004). Controlled prospective studies have also been used to study the influence of steroid treatment on traumatic swelling (Flood et al. 1999). Different types of incisions are compared in a controlled study by Holtmann et al. (1981).

Previous Swedish studies report retrospective investigations of fracture frequencies and different aspects of sequelae (Afzelius & Rosen 1979; Hakelius & Ponten 1973; Lundin et al. 1973; Nathanson et al. 1992; Westermark et al. 1992).

No conclusive study has been found within this field, that has focused on experiences and consequences from the patient's point of view. How to identify which patients need early surgical intervention and which will benefit from non-surgical treatment is another unresolved matter (Burnstine 2002; Burnstine 2003; Courtney et al. 2000). One way towards reaching an answer may be to find a method of objectively assessing eye motility to distinguish entrapment from other causes of restricted motility, and to find out patients' opinions on the outcome.

2. Aims of this thesis

The general aims of this thesis were (i) to investigate the long-term quality aspects of the present treatment practice of orbital floor fractures; and (ii) to suggest improvements in the diagnosis of diplopia by presenting and evaluating a method of measuring vertical eye motility.

The specific aims of the studies were as follows:

Paper I (retrospective study)

- to investigate the cause of orbital floor fractures and the frequency and type of long-term sequelae among patients subjected to orbital floor surgery at a university hospital clinic according to the surgical methods used at the time (1991–1995).

Paper II (prospective study)

- to study the underlying causes of an increase in the number of orbital floor explorations noted during the second half of the 1990s.

- to study whether the change in surgical routines, with a stable orbital floor implant replacing the antral packing technique, has affected the frequency and type of sequelae.

Paper III (prospective study)

- to study the development of residual signs/symptoms during the year following an orbital floor fracture.

- to investigate remaining signs/symptoms during the year after the orbital floor fracture.

- to investigate patients' and doctors' perceptions of the presence of symptoms and signs and whether these perceptions differ.

Paper IV (methodological study)

- to investigate whether vertical eye motility can be measured by means of vertical electro-oculography (vEOG).

- to investigate whether vEOG can detect unilateral mechanical restriction of eye motility.

- furthermore, to investigate whether vEOG can distinguish a patient with vertical diplopia from a healthy test subject.

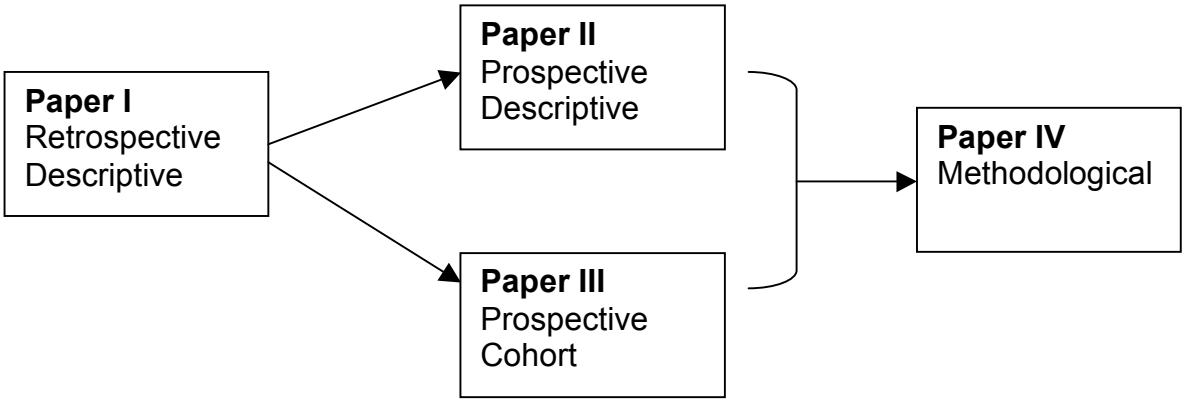

Figure 7. *The order of appearance of and the relationship between the studies.*

3. Materials and methods

3.1 Study populations

The participants of the retrospective study (Paper I) comprised all patients who underwent an orbital floor exploration or who were hospitalized at Sahlgrenska University Hospital (in the municipality of Göteborg, Sweden) for an orbital floor fracture in 1991–1995. Only in-patients were routinely registered by diagnosis at the time of this study. It was therefore impossible to establish the number of out-patients who did not qualify for surgery or supervision at the ENT ward. An inventory of the records for diagnosis codes and operation codes was made retrospectively from 1995 until at least 100 patients were included. The 107 patients included correspond to the number of patients registered over 5 years.

The subsequent prospective study (Paper II) aimed to include all patients examined at the ENT clinic with a fracture of the orbital floor over 1 year (September 1998 – September 1999). By this time also an out-patient diagnosis code register was in use. Among 69 patients, out-patients included, 51 met the criteria for inclusion.

Paper III used the same study population as in Paper II. Whereas in Paper II we describe the demographics and descriptive results, Paper III focuses on the prospectively collected data concerning patients' and doctors' perceptions of persisting symptoms during the year following the trauma.

Paper IV is based on a methodological study of measurements of vertical eye motility. The participants were seven patients known to have vertical diplopia after an orbital floor fracture (from Paper I) and twelve healthy test subjects.

Inclusion criteria for study I	Having an orbital floor fracture, being an in-patient
Inclusion criteria for studies II and III	Having a fracture of the orbital floor
Exclusion criteria for studies II and III	Having an isolated arch fracture
	Declining participation in the study
	Not being able to understand and complete the questionnaire
	Having been diagnosed with a psychiatric disorder, dementia and/or severe drug abuse
	Not being Swedish-speaking

3.2 Methods

In the retrospective study (Paper I) a protocol was used to standardize the collection of data from the medical records. In the prospective studies (Papers II and III) two protocols were used to standardize the collection of (i) the surgical data; and (ii) the doctors' clinical assessments. In the methodological study (Paper IV) a short protocol to document basic data (including medication, smoking habit, vision, direction of diplopia) of patients and test subjects was used.

3.2.1 Questionnaires

In clinical research, investigators often develop their own questionnaires to be used in surveys of patients' views and experiences, possibly because it is necessary to ask diagnosis-specific questions, and because of the lack of an available diagnosis-

specific questionnaire tested for validity and reliability (Fitzpatrick 1991b). A questionnaire that has been validated for one clinical condition is not automatically valid when applied to a different clinical entity (Bellamy 1993). This implies that use of an already established questionnaire in a new context involves a new procedure for testing validity and reliability in the population in question. Constructing a diagnosis-specific questionnaire may take years of meticulous work that involves a series of stipulated processes. The development of the questionnaire which was constructed, tested and evaluated in the present study may be seen as a first step.

Before the start of the retrospective study the 36-item short form health survey (SF-36) was tested in five patients with known long-term sequelae (distressing facial asymmetry, and enophthalmos). All five found the questions irrelevant and difficult to relate to and consequently this questionnaire was considered too general to give the information sought after. As presenting each patient with two questionnaires would have taken too much time and would furthermore have drawn the focus from the aim of the study, the SF-36 questionnaire was discarded. Other reasons were that response rates have been shown to be significantly lower with questionnaires exceeding four pages compared with smaller questionnaires (Streiner & Norman 2003). Moreover, when patients' experiences are studied it has been shown to be more adequate to ask specific questions relevant to the specific context than to ask general questions (Carr-Hill 1992; Fitzpatrick 1991b).

3.2.1.1 The questionnaire of the retrospective study

A valid and reliable diagnosis-specific questionnaire was not available at the time the first study was initiated. We consequently performed a search of the literature (including Afzelius & Rosen 1979; Converse & Smith 1960; Hakelius & Ponten 1973; Hawes & Dortzbach 1983; Hötte 1970; Manson 1990; Mathog 1991; Nguyen & Sullivan 1992; Putterman et al. 1974; Rohrich et al. 1992; Zingg et al. 1992) and after a series of discussions with senior colleagues, all consultants with more than 15 years' experience at a regional clinic regularly handling facial fractures, we constructed a

questionnaire containing 'yes/no' and open-ended questions (Appendix 1). For any relevant problems or experiences not covered in the questions, we provided space for additional comments (Fitzpatrick 1991b). This questionnaire and a covering letter providing information about the study were then sent to ten patients (random patients from the surgical register of 1993–1995) who had undergone orbital floor surgery 1 year or more previously. A stamped and addressed envelope was enclosed to make it easier for the patients to return the questionnaire, either completed or with a marked statement indicating that they did not want to take part in the study. As per the letter, each patient was contacted by telephone within 2 weeks unless further contact had been declined. All ten patients agreed to participate and were interviewed about the questionnaire.

In the analysis we concluded (i) that the questions were relevant; (ii) that no aspect of importance to the patients had been left out; and (iii) that the questions were easy to understand and the questionnaire took only a few minutes to complete. Another issue of ethical importance was that the interviewed patients did not perceive it as upsetting or troublesome to have received a questionnaire that brought back memories of the trauma, nor did they consider any of the questions offending. Consequently, as no adjustments were necessary the questionnaire was sent to all 107 patients in the retrospective study. For the purpose of the study, this was considered sufficient validation (face validity, content validity) (see Hodgson Phillips 2002) of the questionnaire (Appendix 1).

3.2.1.2 The questionnaire of the prospective study

To enable ranking of patient data in the prospective study (Paper III) the results and experience gained from the retrospective study were used to condense the questionnaire to four main items and VASs were added to provide ordinal data. The same questionnaire was used at all five stipulated appointments during the 1-year follow-up after the trauma (Appendix 2; contents given in English in Figure 1 of Paper III).

Estimation methods are relatively easy to design. Furthermore, they require little pre-testing and are easily understood (Bellamy 1993; McCormack et al. 1988; Streiner 2003). There are several direct estimation methods (Streiner & Norman 2003) and among these are VASs. Many different variants of VASs have been described (Bellamy 1993). The VAS questionnaire used in the prospective study (Paper III) should be seen as a preliminary instrument to gain an understanding of the development of signs and symptoms during the year following an orbital floor fracture operation and, more importantly, patients' experience of these signs and symptoms.

Clinician-based symptom ratings were collected by means of a protocol (Appendix 3; contents displayed in English in Figure 1 of Paper III) which was completed at all five follow-up appointments. In this protocol the absence or presence of the listed signs and symptoms was indicated by putting a tick in the adjacent 'yes' or 'no' box. Diplopia was indicated in a grid illustrating the nine cardinal directions of gaze, and maximal mouth opening in millimetres was given in cases of fractures involving the zygoma. An adjectival scale was provided for grading the peri-orbital haematoma.

3.2.2 The visual analogue scale

Measuring a feeling or an experience is a challenge and may be found difficult as a subjective feeling cannot be expected to keep constant and one person cannot be expected to be able to rate another person's experience (McCormack et al. 1988). Nevertheless, VASs have proved to be highly reliable and valid, and are known to have good responsiveness and be more sensible to changes than is the Likert scale (Bellamy 1993; Huskisson et al. 1976; McCormack et al. 1988). This makes the VAS a suitable instrument for measuring changes in the course of time, both intra-individually and between groups on different occasions; in the latter case a group mean is calculated for each occasion (Bellamy 1993).

It is recommended to use a 100 mm, horizontal-line VAS. The highest value is set at the right end-point and the lowest on the left (Bellamy 1993). The VAS used in the prospective study had descriptors at intermediate positions ('Never'–'Sometimes'–'Often'–'Always') as this was considered to be an advantage in the subsequent interpreting procedure and analysis (Dexter & Chestnut 1995). According to Streiner and Norman (2003), this agrees with an adjectival scale, which bears close resemblance to the VAS. Adjectival scales use descriptors along a continuum as opposed to only labelling the end-points; additional descriptors are introduced at intermediate positions. Downie et al. (1978) proved the correlation between the usual VAS and one with intermediate positions to be substantial (see also Streiner & Norman 2003). One advantage of the labelled subdivisions of the VAS used in the prospective study was that both the responder and the investigator were familiar with and could agree about what a certain marking stood for, for example 73 mm being somewhere between 'often' and 'always'. This made it easier to reveal and interpret a clinically relevant change in symptoms.

Whether data from the VAS are ordinal, interval or ratio data has been discussed. There is agreement within the literature that VASs provide ordinal data that can be ranked (Bellamy 1993; McCormack et al. 1988). However, evidence has been provided for handling VAS scores at group level as interval data (McCormack et al. 1988; Streiner & Norman 2003). Dexter has shown that parametric tests, the *t*-test and analysis of variance (ANOVA) can be used for statistical analysis even if the data are not normally distributed, provided that the distribution of scores is not severely skewed. Also, Streiner and Norman (2003) supports the claim that data from rating scales can be analysed as if they were interval data without introducing severe bias (Bellamy 1993).

Introducing ordinal values on an interval scale may be considered a problem. The distance between 'often' and 'always' is not by nature equal to the distance between 'never' and 'sometimes'. However, according to Streiner and Norman (2003), among

others, this causes only an insignificant and therefore negligible bias (Bellamy 1993; Dexter & Chestnut 1995).

Sometimes symptoms are better scored as a function of time than as one of intensity (Streiner & Norman 2003). 'Worst thinkable' intensity of a symptom will have a different end-point, being dependent on the imagination of the respondent. Also, it is difficult for the respondent to know whether the symptom has reached the point of 'worst thinkable'. It may be easier to say whether a symptom is troublesome 'sometimes' or 'always'.

All patients were verbally informed how to complete the questionnaire. The questionnaire was handed over in connection with each clinical appointment and time was assigned to completing it before seeing the doctor. Patients' subjective data (i.e. patient-reported outcomes) should if possible not be presented without being related to objective measurements. No such valid external criterion of change over time was available other than in the form of the clinical assessment and measures, as presented in Paper III (clinician-based outcome). As the examiner could not be expected to grade patients' experience the 'doctor's protocol' only included (dichotomous) alternatives as to the presence or absence of signs and symptoms (Appendix 3).

3.2.3 Electrophysiology in electro-oculography

The test procedure of the methodological study was strictly standardized, as described in detail in the Methods section of Paper IV. The ENG (electronystagmography) equipment normally used in vestibular testing in daily ENT practice was used in a different context namely, studying vertical eye motility. According to Thell and Ödqvist (1988), the most common errors in measuring eye motility by means of electrodes tend to appear in the patient equipment contact, i.e. the electrodes. Preparation of the skin and using electrodes with electrolyte paste are

necessary protocol elements. These demands were met in the methodological study (see Paper IV).

The eye bulb constitutes a dipole with an electrical potential of approximately 1 mV between the positive (cornea) and negative (retina) pole. Strong light should be avoided before testing as this affects (i.e. lowers) the corneo-retinal potential. As the eye (the cornea) during smooth pursuit moves closer or further from the electrodes this gives rise to a change in polarity, which is detected by the electrodes, and recorded. Usually a low-pass electronic filter is used to prevent the noise from the masseter and temporalis muscles from affecting the recordings. The eye muscles are sensitive to drugs such as sedatives, alcohol and smoking (Cogan 1969), which should be avoided before testing.

3.3 Statistical methods

3.3.1 Sample size

The size of the study population in the retrospective study (Paper I) was based on data from previous studies of zygomatico-orbital fractures, in which frequencies of sequelae were high enough to allow 100 subjects to be sufficient for inclusion in the planned study (Afzelius & Rosen 1979; Biesman et al. 1996; Converse et al. 1967; De Man & Bax 1988; Ellis et al. 1985; Hakelius & Ponten 1973; Jungell & Lindqvist 1987; Putterman et al. 1974; Zingg et al. 1992). This number turned out to agree with all patients over 5 years, from 1991 to 1995 (n = 107).

The prospective study (Papers II and III) aimed to more closely study patients' experiences of persisting signs and symptoms during the postoperative year. As sequelae had proved to be common we decided that it would be both practical and sufficient to include all patients presenting with an acute fracture of the orbital floor during 1 year for the subsequent 1-year follow-up.

In the methodological study (Paper IV) we took advantage of the fact that we knew that 14 patients from the retrospective study had persisting diplopia still 1 year or more after the trauma (Paper I). By the time of the study one patient had died and three had declared themselves recovered: ten patients and a corresponding number of test subjects (n = 12) were recruited for the study.

Deciding on the number of participants in studies like the present one means finding a balance between what is acceptable from a statistic and scientific point of view and what is possible in terms of the clinical reality. It is often a matter of compromise and 'take what you can get'. For this reason, there may be findings that fail to appear due to the relatively small number of patients available (type II error), although the positive findings that are revealed are undoubtedly true. This, however, was not considered reason enough not to carry out these investigations as the results can be related to other, similar materials.

3.3.2 Statistical methods used

In Papers I and II we report descriptive data and accordingly only frequencies and quotients were calculated. Descriptive statistics were calculated afterwards. As the confidence intervals were found to overlap regarding the occurrence of diplopia in relation to the surgical methods used for orbital floor repair, Fisher's exact test was used and p-values were calculated.

In Paper III categorical variables in cross-tabs were examined using Pearson's chi-2 or Fisher's exact test, while *t*-tests were used to compare means of VAS variables. According to Dexter & Chestnut (1995), the *t*-test or ANOVA is suitable for calculating the statistical significance of changes in VAS scores between groups. Changes over time were also calculated by means of the non-parametric Wilcoxon's signed-rank test, and found significant. All tests were two-tailed and a 5% significance value was used.

The mean values of VAS scores at group level were used to study changes over time. Since on some of the scoring occasions a major part of the patients had no troubling symptoms in several of the measured variables, the median was an unsuitable indicator of central tendency. Consequently, means, standard deviations (SDs) and ranges were chosen to describe progress over time for the VASs. However, due to the skewness of the data, these data should be regarded as an outline of trends and as mainly complementing verbal descriptions of distributions.

In Paper IV, due to small samples, non-parametric tests were used to test statistical significance of differences between groups. We used Fisher's permutation test and Fisher's test for pair comparison.

4. Results

4.1. Paper I

In 1991–1995 assault was the main cause of orbital floor fractures. The male:female ratio was 2.2:1 and the mean age of patients was 40 years (range 10–88 years). A mean of 19 orbital floor operations a year were performed during the period (range 18–23 per year). An ophthalmologist was consulted in 85% of the cases. The reason for restricted vertical eye motility and the subsequent diplopia was not established, but it was suggested to be either swelling or entrapment of the inferior rectus muscle. A pre-operative forced duction test was not performed in any of the 107 cases nor was it performed routinely at surgery (but at termination of surgery in 30%). Long-term sequelae were frequent despite surgery (83%; response rate 77%), sensibility disturbances being the most common (55%) followed by affected vision (48%) and cosmetic complaints (44%). Diplopia was common (36%) among patients given antral packing as a support for the fractured orbital floor (not significant (n.s.) at the 5% level). This raised the overall frequency of diplopia from 13% to 17%. Two patients who had not experienced diplopia pre-operatively ended up with permanent diplopia after treatment with antral packing. Diplopia was pronounced in some of the patients and this could be verified clinically when these patients were contacted and examined in the methodological study of eye motility (Paper IV); four (4/13; 31%) had great difficulties in daily living and had either started claiming a disablement pension or had had to change to a profession in which they did not depend on binocular single vision.

4.2. Paper II

With the introduction of stable floor implants the antral packing technique became unnecessary and the latter was abandoned in 1996.

In Paper II the male:female ratio was 2.2:1 and the mean age, 43 years (range 16–90 years). High falls in young men contributed to increasing the frequency of falls as a cause of orbital floor fractures, so that the incidence of fractures due to falls (35%) became higher than that of fractures due to assault (33%). Thirty-nine orbital floor operations were performed during the year of the investigation. Forced duction testing was performed at termination of surgery in 45% of the orbital floor operations.

A high occurrence of sequelae (78%; response rate 86%) was revealed 1 year after surgery. The frequency of sensibility disturbances was 53%, while that of affected physical appearance was 45% and of eye symptoms, 26%, diplopia included (9.5%). No patient suffered from disabling diplopia. Enophthalmos was established in six patients.

Despite a pre-operative CT scan in 88% of the cases and a pre-operative examination by an ophthalmologist in 78%, several patients (21%) underwent surgery of the internal orbit only to assess the fracture of the orbital floor. All but one (1/8 with a blow-out fracture) were plain tetrapod fractures. In none of these cases did any further measures have to be taken, such as the release of soft tissues, reduction of herniated tissue or use of a floor implant. In Paper II we reported that 17% of performed orbital floor explorations (8/47; 47 being the total number of operations, closed reductions included) had possibly not been necessary. Actually it would be more adequate to make that 21% (8/39), the number of 'unnecessary' orbital floor operations related to the total number of orbital floor operations performed. One of these had had diplopia ('mild'; 14 mm on the VAS) before surgery. One year after surgery, three of these patients suffered from a showing subciliary scar and four from impaired sensibility (unpublished data).

In the operation protocol the operating surgeon was faced with one specific question about how the intra-operative impression of the fracture agreed with the pre-operative CT imaging results (response rate 19/39; 49%). In the majority of cases the

surgeon thought that the CT scans had not provided a true representation of the fracture (13/19; 68%).

4.3. Paper III

Patients' experiences of the result and outcome are presented in Paper III. The response rate on the five occasions was ≥70%. There was no tendency of clustering around the VAS markings but the patients seemed to use the whole length of the scale. It was possible to follow and analyse changes at group level.

Impaired sensibility, mouth opening capacity, physical appearance and eye function all significantly improved ($p \leq 0.05$ at group level) mainly during the first month after surgery. Scleral show was common (41%) at the 1-month examination and 14% suffered from ectropion. After 1 year 29% and 4%, respectively, suffered from these conditions. Enophthalmos (n = 6) became apparent later in the postoperative period and was not diagnosed until the 6-month appointment, and at the time still overlooked by half the affected patients. Reasons for an unsatisfactory outcome was primarily due to other complaints concerning the physical appearance, such as malar flattening or a visible scar (see below).

There was agreement between patients' and doctors' opinions as to the presence of objective signs and measurable symptoms, especially with regard to an affected appearance such as visible scarring, permanent scleral show (29%) or a flattened cheek (17%), and the presence of diplopia (9.5%), as verified by an ophthalmologist.

In the prospective study we included all patients with any kind of fracture of the orbital floor. This by definition also included the tetrapod fractures, which made questioning also about jaw function relevant and important. The results showed that in most cases doctors estimate maximal mouth opening capacity to have recovered by 1 month following surgical repositioning while patients did not experience resolution until after 6 months. A maximal mouth opening capacity of ≥40 mm could not be generalized as 'recovered' as for some patients, anything less than 60 mm was

experienced as a restriction. Patients' experience of improvement with time (estimated on the VAS) was objectively verified by an increase in mouth opening capacity, as measured in millimetres.

Sensibility problems, even when serious, could pass undetected by the doctors. Ten per cent of the patients in study III ended up with constantly troubling sensibility affection (VAS = 100 mm); however, these were all recognized as having affected sensibility.

4.4. Paper IV

The male:female ratio among the healthy test subjects was 1:1, and 2.5:1 among the patients. The mean age was 31 years and 36 years, respectively. The motility of both eyes was recorded simultaneously, which provided the possibility of using the uninjured eye as the reference for each individual. As the motility of the eyes is normally synchronized a difference causing diplopia was expected to show in the recordings. The results indicated that vertical eye motility can be measured by means of vEOG even when the restricted eye is covered. This instrument enables us (i) to differentiate a patient with vertical diplopia from a healthy test subject ($p<0.05$); and (ii) to detect and verify unilateral mechanical restriction ($p<0.001$). The test proved to provide reproducible recordings when repeated during the same test session.

Receiver-operating characteristic (ROC) curves were constructed by an authorized statistician (unpublished data). The area under the ROC curves regarding elevation, downward movement and the presence of a 'plateau' as recorded by the vEOG test were calculated to illustrate the vEOG findings suitable as cut-off variables (Figure 8A–C). The presence of a 'plateau' clearly separated the patients with manifest diplopia from the test subjects (Figure 8A: area under the ROC curve 1.0). Also, the difference between the two eyes in downward movement (Figure 8B: area under the ROC curve 0.93) and in elevation (Figure 8C: area under the ROC curve 0.83) proved to be useful in distinguishing 'normal' from limited eye motility.

A.

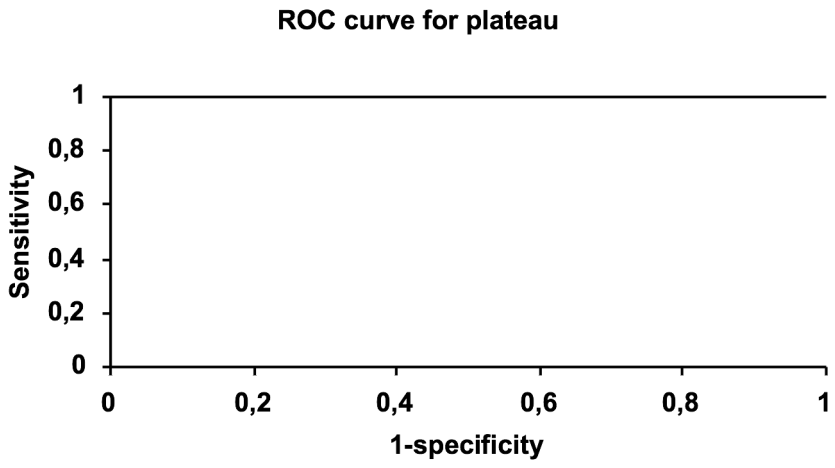
ROC curve for plateau
Sensitivity
1
0,8
0,6
0,4
0,2
0
0
0,2
0,4
0,6
0,8
1
1-specificity

B.

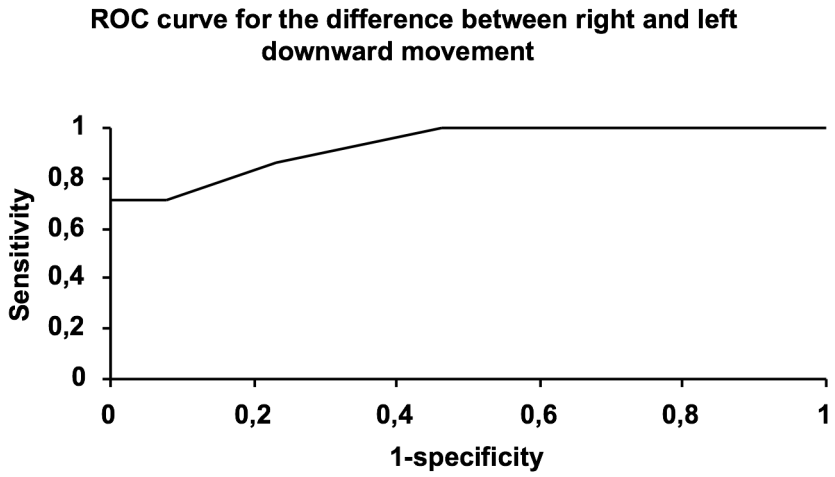
ROC curve for the difference between right and left downward movement
Sensitivity
1
0,8
0,6
0,4
0,2
0
0
0,2
0,4
0,6
0,8
1
1-specificity

C.

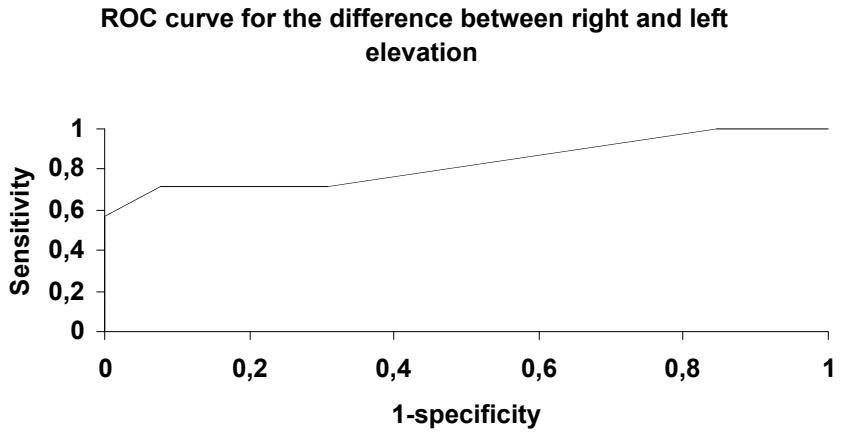

Figure 8 A: *Receiver-operating characteristic (ROC) curve illustrating the presence of a 'plateau' on the vEOG recordings as a finding clearly distinguishing patients suffering from vertical diplopia from test subjects.* ***B*** *and* ***C:*** *Receiver-operating characteristic curves illustrating the intra-individual differences (i.e. between the two eyes) in downward movement (B) and elevation (C) as important variables in verifying unilateral mechanical restriction. (Sensitivity: true-positive rate. 1-specificity: false-positive rate.)*

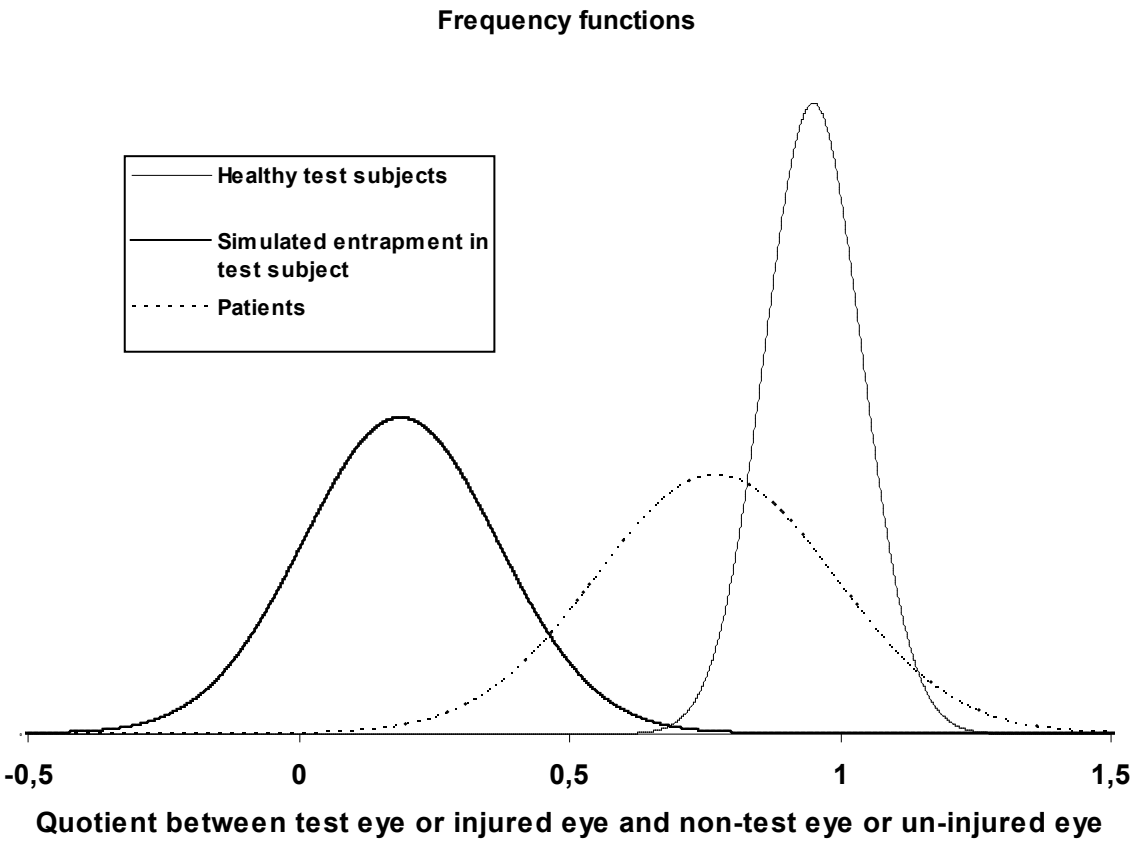

Figure 9. *The mean (m) values and standard deviations (SDs) of the quotients between the restricted eye and the 'normal' eye were calculated for (i) 'normal', free smooth pursuit in healthy test subjects (m = 0.95, SD = 0.09); (ii) induced mechanical restriction in test subjects (m = 0.19, SD = 0.18); and (iii) smooth pursuit in patients (m = 0.77, SD = 0.09).*

Figure 9 demonstrates the distinction found, as a result of the vEOG tests in Paper IV, between 'normal' vertical eye motility in the test subjects and unilateral restricted vertical eye motility as induced during the experiment. The dotted line representing the patients illustrates that only a few of the patients studied had an eye motility disorder as severe as in the test subjects when mechanical restriction was induced, which well agreed with the anamnestic information.

4.5 Excluded patients and dropouts

4.5.1 Paper I

In the first retrospective study 25 of the 107 patients did not complete the questionnaire and therefore their reports of persisting signs/symptoms could not be obtained. Twelve had moved and their address was unknown, two had died and eleven did not answer the questionnaire despite repeated send-outs. Accordingly, the frequency of sequelae would at most have been 87%; 68 patients who had reported remaining signs/symptoms plus a maximum of 25 more. Correspondingly, the minimum frequency of sequelae, if none of the non-respondents had sequelae, would have been 64%, i.e. 68/107 patients (see Figure 10). Basic data from the medical records were, however, collected and analysed in all cases.

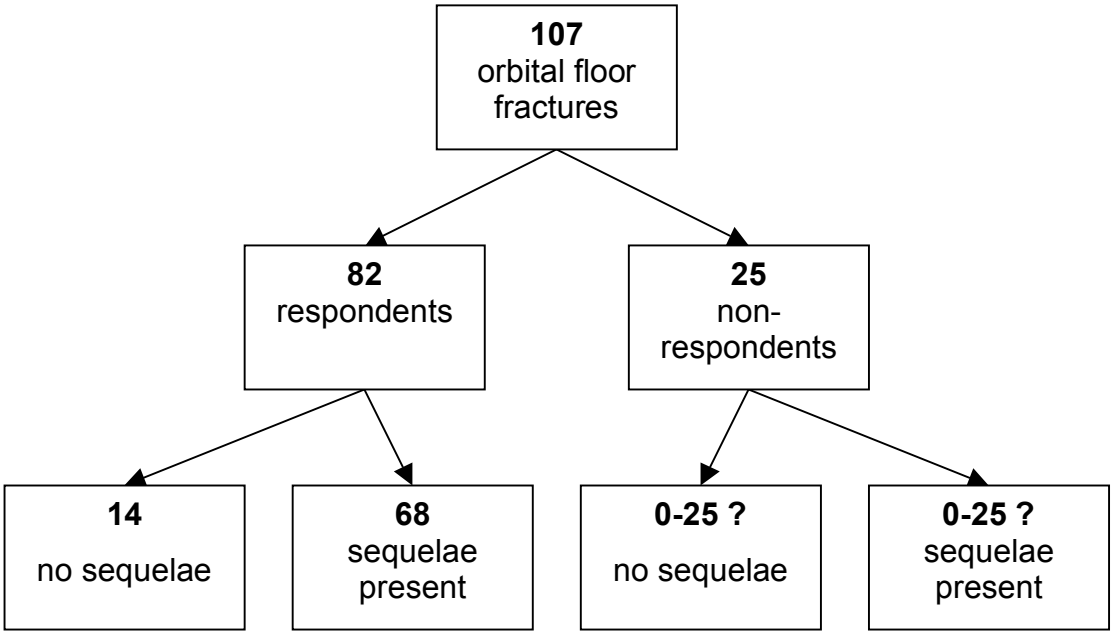

Figure 10. *Patients in study I. Respondents to the questionnaire. Frequency of sequelae = 83% (68/82) (95% confidence interval (CI) 73–91%).*

4.5.2 Papers II and III

In order to check whether all patients meeting the inclusion criteria had been included in the prospective study (Papers II and III), both the in-patient and the out-patient registers were examined for the period in question. Eighty-three patients were found to have been registered as zygomatico-maxillary fractures (ICD-10 codes S02.3, S02.8 and S02.4) with the corresponding operation codes CAC00, CAC10, EEC30 and EEC35. Fifty-one patients met the inclusion criteria of the study. Forty-six of these patients participated in the study, while five were lost to follow-up (Figure 11).

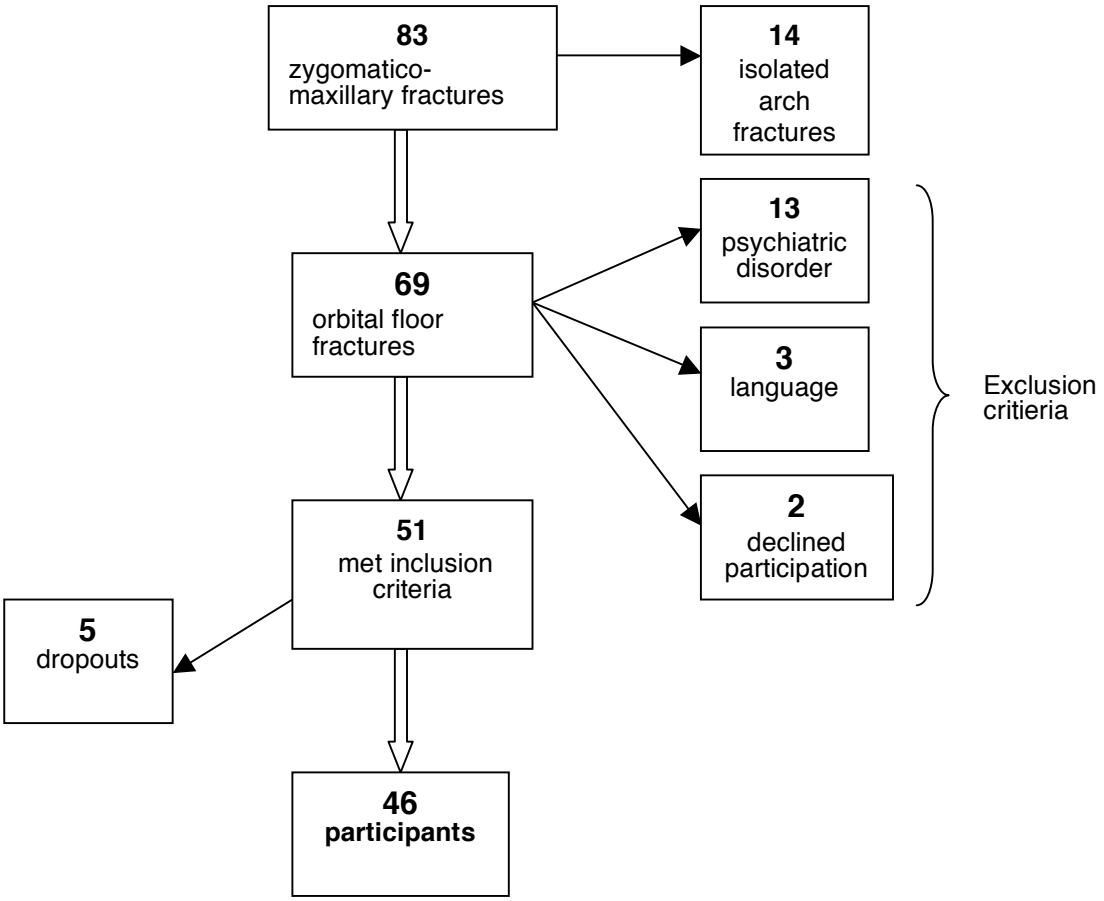

Figure 11. *Participants of studies II and III.*

Eighteen of the patients considered for the prospective study, who had a fracture that met the inclusion criteria, at the same time also met some of the exclusion criteria (see 3.1). The male:female ratio among these patients was 1.8:1 and the mean age was

higher, viz. 64 years (range 18–90, median 69). The reasons for injury were falls (53%), assault (40%) and traffic accidents (7%). Five did not undergo surgery, two were subjected to closed reduction only, and in the remainder of patients the fractures were explored.

The five dropouts in the prospective study were mainly men (80%). They had a mean age of 36 years and high falls (60%) or assault (40%) had caused the trauma. All except one, who was subjected to closed reduction only, underwent orbital floor surgery and were provided with an orbital floor implant. It was, however, possible to find out from the medical records that one of these patients suffered from severe trismus (10 mm) postoperatively and follow-up was continued at the OMF clinic. A further two patients from this group had long-term problems with sensibility disturbances and one had visible scarring after the subciliary incision still 5 months after surgery.

4.6. Concluding summary of the results

As a conclusion to this chapter the results and how they meet the aims of the present studies can be summarized as follows:

- Orbital floor fractures were mainly due to assaults or falls. Sequelae after surgery for orbital floor fractures were common (Paper I).

- The number of orbital floor explorations performed for diagnostic purposes indicates that pre-operative diagnostic methods are insufficient (Paper II).

- The results, though not statistically significant, indicate that the antral packing technique may be inferior to the use of stable floor implants with regard to persistent diplopia (Papers I and II).

- Enophthalmos was not apparent and diagnosed until the appointment 6 months after surgery. This indicates the need for follow-up also after 6 months in selected cases in order to establish an adequate evaluation of the surgical outcome (Paper III).

- Patients' experiences of symptoms and signs are important indicators that need to be appropriately assessed in order for the underlying causes to be evaluated and treated where possible (Paper III).

- The clinical methods testing the presence of symptoms did not correspond to the patients' subjective experiences regarding impaired sensibility and reduced mouth opening capacity, which were underestimated by the doctors (Paper III).

The results of the methodological study (Paper IV) indicate that:

- vertical EOG can be used to measure vertical eye motility and the uninjured eye can be used as the reference eye.

- vertical EOG can also be used to discover and verify discrepancy in amplitude and velocity of the eye motility between the two eyes and to objectively verify restricted eye motility, as a cause of diplopia, even when the restricted eye is covered.

- furthermore, vEOG as an objective, non-invasive, harmless, quick and inexpensive eye motility test has the potential to help predict which patients will benefit, or not benefit from orbital floor surgery.

5. Discussion

The study populations of the present thesis (Papers I and II/III) seem to be representative of patients with zygomatico-orbital fractures. It is therefore likely that the results can be generalized to similar groups of patients. The descriptive data from both the retrospective (Paper I) and the prospective studies (Papers II and III) regarding aetiology, age and gender of the patients agree with data from other studies of orbital floor fractures, performed in the 1980s as well as more recently (Baumann et al. 2002; Biesman et al. 1996; Ellis et al. 1985; Jungell & Lindqvist 1987; Kontio et al. 2005; Kovacs et al. 2001; Tadj & Kimble 2003).

On the one hand, it can be argued that the studied populations are to be regarded as *total* populations, not samples, and in that respect, the results are significant. On the other hand, generalizations to the population in wider terms, i.e. of that comprising *all* patients with these kinds of injuries, must be made with caution and the results must be seen as indicators rather than as statistically significant.

Most differences between studies concern differences in the definition of the severity of the fractures, diagnostic coding and treatment-related factors. Consequently conclusions from comparisons with similar studies have to be interpreted with caution. The following discussion should be read in the light of this reservation.

5.1. Aspects of the main results

Paper I

In this study long-term sequelae despite surgery were reported by 83% of the patients. Such a high frequency at an average of 3 years after the trauma, when full restitution, compensation mechanisms and adaptation should have occurred, is noteworthy. Furthermore, it indicates that a closer look at the kind of sequelae reported is needed.

Diplopia as a persisting symptom has in comparable studies been reported in 5–7% of patients (Hawes & Dortzback 1983; Tadj & Kimble 2003). In comparison to this figure, the occurrence of diplopia in the retrospective study was high (17%) while the reported frequency of enophthalmos (7%) was similar to that reported elsewhere (2–7%) (Guerra et al. 2000; Hawes & Dortzbach 1983; Tadj & Kimble 2003). However, frequencies of diplopia and enophthalmos are particularly difficult to compare between studies since the severity of zygomatico-orbital fractures and the proportions of pure blow-out fractures in the populations are not always clearly distinguished or stated. In studies reporting populations with blow-out fractures only, the occurrence of diplopia has often been reported to be higher (27–37%) (Biesman et al. 1996; Putterman et al. 1974). Putterman et al. (1974) report a 36% occurrence of enophthalmos in their study of non-surgically treated blow-out fractures.

Visible incision scarring due to a subciliary incision has been reported to occur in 28–30% (Appling et al. 1993; Tadj & Kimble 2003) and in the present study (Paper I) was reported by 19% of patients.

Flattening of the cheek prominence has been reported in 3–20% of patients (Afzelius & Rosen 1979; De Man & Bax 1988; Tadj & Kimble 2003), and the occurrence among the patients of study I was 10%. It has to be borne in mind, however, that the inclusion criterion for this study was ‘orbital floor fractures’, which means that some tetrapod fractures were included as they were diagnosed as ‘orbital floor fractures’, just because they had been subjected to an ‘orbital floor exploration’. Consequently, tetrapod fractures subjected to closed reduction only, and the facial asymmetries possibly resulting from these, were not taken into account.

The frequency of persisting sensibility disturbances varies widely between studies (range 9–62%). The long-term outcome after all zygomatico-orbital fractures has not been reported to be poorer than the outcome after pure blow-out fractures (Afzelius

& Rosen 1979; De Man & Bax 1988; Guerra et al. 2000; Jungell & Lindqvist 1987; Kovacs et al. 2001; Putterman et al. 1974; Vriens et al. 1998).

Vriens et al., studying patients' experience of sensibility disturbances, report a 5–62% occurrence depending on both fracture type and the subsequent treatment ranging from no surgery in minimally dislocated fractures to open reduction, fixation and orbital exploration in the more extensive fractures (Vriens et al. 1998). It is possible that in their study the fact that patients were specifically asked about the presence of sensibility affection yielded a higher, but truer, frequency than just testing the sensibility for sharp and blunt touch. This may have been the case also in the retrospective study of this thesis, in which as many as 55% of patients reported affected sensibility. This observation by Vriens et al. (1998), that sensibility testing alone does not seem to reflect patients' true experiences of this symptom, was noted also by Tadj & Kimble (2003).

A high frequency of diplopia (36%) was reported by the patients who had been provided with antral packing as a temporary support for the orbital floor. However, statistical significance could not be established ($p = 0.11$) to support a causal link between the antral packing technique and diplopia. Possibly the antral packing technique was used primarily for repairing the more extensive floor fractures, which would explain, or at least have contributed to, the poorer outcome. Irrespective of the cause, i.e. it being an inferior technique or there having been a selection of large fractures, the antral packing technique was obviously insufficient for the fracture repairs in question.

This retrospective descriptive study generated two main hypotheses, namely (i) that patients have more problems after orbital floor fracture surgery than is recognized by the clinicians; and (ii) that the antral packing technique is associated with an increased risk of permanent diplopia. The first hypothesis was tested in the prospective study (Paper III). With regard to the second hypothesis it was considered unethical to test this in a prospective study. Apart from the obvious

difficulties in designing a randomized controlled trial (matching for age, gender and comparable fracture characteristics, blinding, having an unbiased choice of treatment, as well as surgeon-related factors, etc), the risk of severe complications such as blindness, caused by antral packing (Liu 1994; Manson 1990; Rosbe et al. 1997), and the considerable inconvenience to the patient (Figure 12) is not acceptable, especially when the treatment is compared with that of using a well-documented alloplastic stable orbital floor implant, without the further problems of donor site morbidity.

Figure 12. *Antral packing (Foley balloon catheter) used to support a right orbital floor fracture for 4 weeks.*

Paper II

Interestingly, falls were as common as assault as a cause of fractures in this prospective study. The main reason for this appeared to be some cases of high falls in young men, which was an uncommon cause in the retrospective study (Paper I).

Persisting signs and symptoms proved common also in Paper II (78% at final assessment). Sensibility disturbances (53%) and cosmetic complaints (45%) were reported to the same extent as in the previous study. However, affected vision was reported by 26% of patients; and diplopia by 9.5%. Although the retrospective and prospective studies can only be compared with caution this was an interesting difference from 48% and 17%, respectively, in the former study. The antral packing technique had been completely replaced by use of stable orbital floor implants (consisting of porous polyethylene) and parallel to this change the frequency of diplopia had decreased. Therefore, though there was no evidence for statistical significance in the retrospective study, the clinical relevance of a possible correlation between the antral packing technique and persistent diplopia could not be disregarded. Also, the absence of severe cases of permanent diplopia after abandoning the method would suggest that the antral packing technique is inferior, or at least insufficient in selected cases.

Negative side effects of the antral packing method have been observed in studies by Westermark et al. (1992) and Rosbe et al. (1997) and include a high occurrence of infra-orbital nerve hypo-aesthesia (74%) and compromised vision (Rosbe et al. 1997; Westermark et al. 1992). As an authority in the field of facial fracture surgery, Manson has clearly stated his disapproval of this surgical method (Manson 1990), favouring an intra-orbital approach and the use of a stable floor implant, preferably a bone graft. However, some surgeons even use the antral packing technique for reducing the floor fracture by filling the balloon, and claim excellent results with this approach when used for large defects (Koide et al. 2003; Hinohira et al. 2005). In the light of the observed severe complications due to increased intra-orbital pressure and to bone spicules being pushed into vessels, the eye muscle or optic nerve, this approach cannot be expected to be commonly adopted (Hötte 1970; Liu 1994; Manson 1990; Rosbe et al. 1997; Strong et al. 2004).

Data from the surgical registers showed that the number of orbital floor explorations in Sweden almost doubled during the second half of the 1990s (unpublished data). Whether this was due to an increased number of injuries or an increased tendency of surgical treatment remains unclear since the number of unoperated patients with a diagnosed fracture of the orbital floor before 1997 is not documented.

In this context it is interesting to note that 21% of the orbital floor explorations appeared to have been performed for purely diagnostic purposes. This must be avoided as surgery on the internal orbit is not risk-free (Burnstine 2003; Liu 1994). Before the introduction of CT imaging, diagnostic explorations were commonly done, and motivated, as a routine measure (Hakelius et al. 1973; Rohrich et al. 1992). However, although imaging techniques have developed and advanced immensely since the 1980s, intra-orbital surgery as a diagnostic procedure is still widely used. This indicates that the pre-operative information obtainable is not sufficient.

Also, though this study population was too small to reach any far-reaching conclusion, the indication that the surgeons did not consider the pre-operative CT images as providing a true representation of the fractures is noteworthy. Ilankovan et al. and Jank et al. have shown that neither CT, nor MRT nor US findings perfectly agree with the intra-operative findings (Ilankovan et al. 1991; Jank et al. 2004).

In conclusion, these descriptive data of the prospective study generated two hypotheses, namely (i) that stable implants are superior to the antral packing technique with regard to the occurrence of persistent diplopia; and (ii) that available diagnostic tests are insufficient. For the reasons previously mentioned, the first hypothesis could not be considered for a controlled study. The second hypothesis led to study IV, the methodological study which aimed to find a simple method to objectify and evaluate vertical eye motility.

Paper III

The hypothesis generated in the retrospective study (Paper I) was tested and verified in this part of the prospective study (cohort). The patients had more problems from persisting signs and symptoms than was recognized by the doctors.

What is regarded as a problem from the patient's point of view may not be seen as such from the clinician's perspective, and vice versa. As an example, a discrete eyelid shortening a scleral show was often experienced as troublesome from the patient's viewpoint but surprisingly, enophthalmos when present could be overlooked by the patient. Accordingly, it would be considered worse to perform an 'unnecessary' orbital floor exploration and risk a showing scar, apart from the more severe side effects of surgery, than risk development of enophthalmos, which is only evident to the trained eye.

This experience, of some of the affected patients overlooking clinically obvious enophthalmos, has been previously described (Dietz et al. 2001; Hartstein & Roper-Hall 2000; Koornneef 1982). Consequently, for this reason, using only a questionnaire was insufficient, and the clinical follow-up was necessary to reveal the true frequency of enophthalmos among the patients in question.

Obvious dissatisfactory outcomes such as affected physical appearance were readily recognized by the examining doctor, and this was true also for complaints of double vision which could be verified by an ophthalmologist. By contrast, the presence of sensibility disturbances and reduced mouth opening capacity was often troublesome to the patients but underestimated by the doctors. For example, mouth opening measures even within the clinically 'normal' range could be perceived as restricted by the individual patient and obviously 40 mm or even 45 mm could not be generalized as 'normal' mouth opening capacity (Agerberg 1974; Celic et al. 2003). Obviously this capacity also depends on body size and varies between gender, the average maximal mouth opening in men yielding the highest mean measures (Agerberg 1974). As the normal range of maximal mouth opening before the trauma

was not known for the individual, reduced mouth opening capacity could, from a clinical point of view, only be understood in retrospect when (and if) the patient had regained his or her normal function. Patients' estimation of recovery was reflected and verified by increasing inter-incisal measures at follow-up (unpublished data).

From this perspective the VAS (self-assessment) questionnaire seemed to make an important contribution to the assessment of patients' symptoms, not least by attracting attention to the presence of a problem and the need for treatment. If problems such as sensibility disturbances and reduced mouth opening capacity were recognized many patients could be offered active treatment also for these conditions, without delay and with a possibility of speeding up recovery. For example, there is support for corticosteroids being useful in some cases of sensibility disturbances (Vriens et al. 1998) and for jaw exercises to enhance recovery from muscle-related trismus (Boyd et al. 1991).

Paper IV

Diplopia as a symptom seen in association with orbital floor fractures is not automatically an indication for surgery (see 1.4). Only diplopia caused by entrapment is (Helveston 1977; Remulla et al. 1995). However, when diplopia due to restricted eye motility is present, there is no test available that can objectively verify or refute the suspicion of entrapment of orbital soft tissue.

Tong et al. report that in their study, entrapment was present in 21% of the orbital floor fractures; most commonly it was associated with pure blow-out fractures (32%), compared with 16% in the remainder (Tong et al. 2001). Sixteen per cent of the patients in Paper II displayed restrained eye motility as assessed by an ophthalmologist, but whether entrapment was the cause was not established.

Fracture diagnosis largely relies on CT imaging but this is not sufficient when it comes to evaluating diplopia in association with an acute fracture. Concomitant diplopia is an important symptom that has great impact on the decision of surgical

versus non-surgical treatment, but establishing the cause is a recurrent problem. Computerized tomography and MRT only give stills and whether the eye motility is restricted cannot be established from an image. It is obvious that an objective, non-invasive test of eye motility is worth aiming at (Burnstine 2002); that is, a test not only to ascertain whether diplopia is present, but to objectify and evaluate vertical eye motility to establish whether entrapment is causing the diplopia.

The forced duction and forced generation tests are the only two clinical tests that can give any indication of entrapment, albeit with the significant drawbacks previously discussed (see 1.5.2.1). In no cases during the time period of the present studies (Papers I–III) was the forced duction test performed to provide this diagnostic information prior to surgery. This is understandable as the value of the test can be questioned; the test is unpleasant for the patient (Figure 7) and it is difficult to perform and evaluate even for an experienced examiner (Metz 1976; Spector 1993). Furthermore, it is hard to carry out when a peri-orbital swelling/haematoma conceals the eye.

Paper IV reports how to objectively record and measure bilateral vertical eye motility by use of vEOG of smooth pursuit. In clinical practice when the examiner observes the smooth movement of the eyes in the nine cardinal directions of gaze, ocular motility is subjectively tested (see 1.5.2.1.) (Cogan 1969; Spector 1993). Using the vEOG the vertical eye movements of this procedure can be objectified and made accessible for close study and measurement.

Even though the number of test subjects and patients in Paper IV was small, the differences in results seem consistent and reliable. The results indicate that the uninjured eye can be used as the reference eye and that any discrepancy in amplitude and velocity of the eye motility (configuration of the curve) between the two eyes can be used to objectively verify restricted eye motility if present, as a cause of diplopia.

There is evidence that the amplitude and velocity of the eye movements are sensitive to eye muscle affection (Baloh et al. 1975). According to Spector, any difference between the two eyes, whether in speed or range of motility, produces diplopia (Spector 1993). Our results may be supported by findings by Metz et al., who suggest that in blow-out fractures normal saccadic velocity of downward saccades could be a method to verify a functioning muscle even if a forced duction test indicates restriction (Metz et al. 1974). These findings suggest that diplopia in this case was caused by swelling of intra-orbital soft tissues, with the chance of spontaneous recovery of diplopia when swelling subsided (Metz et al. 1974). To assess the function of the inferior (and superior) rectus muscle, saccadic velocity tests were performed unilaterally at 23º of abduction (see Figure 3B) to compare upward saccadic velocities with downward velocities. These refixations in saccadic eye movements can only be performed in a seeing eye and consequently this test is prevented in cases of peri-orbital swelling.

Strangely, no subsequent studies have been found that have further developed the saccadic velocity test in this context, and no studies of bilateral, vertical smooth pursuit recordings of eye motility in orbital floor fractures have been found in the literature. The reason for this may be that ophthalmologists generally seek information for purposes other than assessing diplopia due to restricted vertical eye motility in orbital floor fractures, such as in planning eye muscle surgery in strabismus.

In eye muscle correction surgery it is essential to establish which muscle has to be corrected, and to what extent. In this context assessment is a matter both of deciding in what directions of gaze diplopia occurs and of establishing the extent of dissociation between the images. Diagnosing diplopia in association with an orbital floor fracture does not involve establishing which eye and which extra-ocular eye muscle is affected. The side of the fracture is known and the crucial matter is to find out whether the inferior rectus muscle of the injured orbit is tethered or not.

Consequently there is no need to examine whether the superior rectus muscle is paretic or to separately assess the left and right inferior rectus muscles, which would require unilateral recordings at 23º of abduction, which subsequently would make simultaneous measuring of both eyes impossible. Comparing the simultaneous vertical eye motility of the two eyes to establish any difference in configuration of the recorded vEOG curves (ascribing a difference as induced by the floor fracture) provides the possibility to assess eye motility even during the acute stage of a blow-out fracture, when a peri-orbital swelling is commonly present. A unilateral test requiring visual input to the injured eye cannot do this.

5.2. Methodological considerations

Within this field of clinical research many questions as yet remain unanswered if we bear in mind that we are committed to a high scientific standard. As in other surgical specialities, retrospective studies and case series have been the most reasonable way to gain knowledge about surgical outcomes and the risks of developing sequelae (Macauley & Best 2002). It is neither possible nor ethical to study patients with a facial fracture using the set-up of a randomized controlled trial, i.e. withdrawing half the number of injured patients from treatment or subjecting them to an inferior or untried surgical method. The number of patients in question is usually relatively small and already the randomizing procedure would be hard. It is difficult to match one fracture to another as features vary, and at the same time match patients according to basic factors such as age, gender, type of trauma, and swelling. Surgeon-related factors are likewise hard, not to say impossible, to standardize. Furthermore, details of how to treat the fracture are often a decision made during surgery, such as the need for plating for stability and the use of an orbital floor implant, soft or stable. This further makes randomization most difficult. The fact that only one randomized controlled study within this field is to be found in the Cochrane library illustrates these difficulties (Dietz et al. 2001) (see 1.9).

5.2.1 The questionnaires

From (i) the answers received in the prospective study (Paper III); and (ii) developments in methods and questionnaire construction during the last decade we conclude that it would be an advantage in subsequent studies to include questions related to specific situations in daily living that can be troublesome due to the symptom in question. For instance, mouth opening capacity may restrict taking a bite from an apple; or diplopia may be present in primary position or may be revealed only when the patient is tired, reads or walks on stairs; or a remaining operation scar may be experienced as troublesome each time the patient looks in the mirror. An important overall question to add would be whether consequences of the trauma have led to a change in lifestyle.

An optimal diagnosis-specific questionnaire regarding orbital floor fractures would, because of the variety of long-term problems described, probably involve questions from several different questionnaires that have been tested for validity and reliability for other diagnoses (Dijkstra et al. 2006; Holmes et al. 2005). Constructing a specific scoring instrument for zygomatico-orbital fractures as a help in diagnosis and treatment and in predicting outcome would be a project for further research.

5.2.2 The investigator

In this study the operating surgeon often saw her or his own patient at the 1-week and sometimes the 1-month appointment after surgery. At 6 months and 1 year after surgery all patients were assessed by the investigator (the author, LF). This has to be considered a bias but there is evidence that an examiner independent of the treatment given (i.e. the operation) is preferable, and also, that preferably one and the same examiner should be used for all subjects at all times (Hodgson Phillips 2002). When the operating surgeon answers questions on the results there is evidence that present postoperative problems are underestimated (Devereaux et al. 2005).

Accordingly, the presence of persisting signs/symptoms from the doctor's point of view may have been underestimated at some of the 1-week and the 1-month appointments. However, since all these patients were assessed on the earlier occasion also by the investigator (LF) this cannot explain why enophthalmos was not observed until the 6-month appointment.

In this particular context of noting sequelae, the advantages of the investigator's possible 'over-attentiveness' outweigh the disadvantages. The risk of noting remaining signs that are not present could be regarded as practically non-existent; and it is likely that the extra attention of the 'independent' examiner reduces the risk of missing any remaining signs and symptoms. This may be illustrated by the higher frequency of sensibility disturbances reported by the doctor at the final appointment (63%) compared with those reported by the patients themselves (53%). Some patients scored 0 mm on the VAS, but answered 'yes' to the question whether sensibility was affected. We interpreted this to mean that these patients did indeed have disturbed sensibility but that they tolerated it and did not regard it as a major problem. This might be a matter of the individual patient's coping capacity, which was not studied further within the scope of the present thesis, but has been shown to have an important impact on morbidity (Surtees et al. 2003).

5.2.3 The investigated

Prospective studies have the advantage of avoiding some selection bias by identifying the population before the event (in this case the operation). However, there will be a bias due to some patients choosing to take part in the study and others declining to participate or dropping out. Low participation for these reasons was, however, no major problem in the present study. Excluding the patients with severe drug abuse and psychiatric disorders or dementia was unfortunately inevitable. Consequently, no information about these patients' experiences of the

facial injury could be obtained, which may be seen as a shortcoming (Papers II and III).

Sitzia and Wood (1997) have described determinants of patient satisfaction to be based on (i) expectations; (ii) patient characteristics such as gender, marital status, level of education and age; and (iii) psychosocial considerations, such as some patients being reluctant to complain for fear of unfavourable treatment (the Hawthorne effect). Older age, male gender and low education are factors that have been noted to be associated with less criticism and more moderate expectations of health care (Sitzia & Wood 1997). The fact that a considerable percentage of the total number of the injured fit into these categories would be reason to believe that the overall outcome presented in Paper III would have been 'better', i.e. sequelae would have been accepted to a larger extent and would have been less frequently reported, if it had been possible to include all these patients. However, this acceptance from a patient's perspective does not necessarily denote better outcomes from a clinical point of view.

A few of the patients in the prospective study (Paper III) reported a 'sunken eye' without showing clinical signs of any cosmetic sequelae. This illustrates what may be an effect of some patients being 'over-attentive' to and extra observant of all possible negative side effects to any postoperative signs and symptoms merely as a consequence of taking part in this study (Sitzia & Wood 1997). Other patients may feel comfortable and well taken care of just by taking part in a study: they may not want to disappoint the doctor and tend to overlook any side effects of the treatment, or they believe complaints would involve the risk of being given an inferior treatment (the Hawthorne effect; see above) (Sitzia & Wood 1997).

It is interesting that in almost any study of patient satisfaction approximately 80% report themselves content (Carr-Hill 1992; Fitzpatrick 1991a, 1991b; Sitzia & Wood 1997), which also agrees with the findings of the present study. Sitzia and Wood

therefore suggested a deeper analysis of patient dissatisfaction as a more fruitful source of finding clues for improved outcomes (Sitzia & Wood 1997).

5.3 Clinical consequences

The results of this thesis, as summarized in section 4, contribute to the following recommendations concerning diagnosis, treatment and outcomes:

– As a complement to the clinical assessment and pre-operative CT examination of orbital floor fractures, vEOG can make a valuable contribution by objectifying restricted vertical eye motility. The equipment required for vEOG is generally available at most ENT (elecronystagmography (ENG) equipment) and ophthalmology clinics (EOG).

– To optimize surgical outcome, surgical activities should be subjected to continuous quality control concerning surgical methods used and surgical skills and training among the surgeons. Postoperative radiographic examinations should be a routine measure in all cases to provide immediate feedback on the result of reposition and implant position.

– Postoperative information given to patients should include instructions to conduct vertical eye lid massage to prevent permanent scleral show after subciliary incision (Appling et al. 1993) and eye motility exercises (Putterman et al. 1974) and jaw exercises in order to improve and speed up recovery from diplopia and reduced mouth opening capacity, respectively (Boyd et al. 1991).

– An extra examination at 6 months after surgery should be performed in cases of difficult or extensive fractures to evaluate the outcome and give feedback to the surgeon.

– Patient-reported outcomes comprising patients' subjective experiences of treatment and subsequent outcomes should be obtained in order to improve future surgical results.

6. Conclusion

In conclusion, the present thesis highlights the importance of conducting systematic research on orbital floor fractures, not least concerning (i) surgical practice and outcomes; and (ii) patients' experience of treatment and its results and consequences, both of which areas yet appear to be under-researched. As demonstrated in this thesis, conducting research involving follow-up of out-patients of the categories described (see sections 4.5. and 5.2.3) is associated with problems and consequences, making it difficult to meet all the criteria of strictly controlled studies. However, the results are still useful to help guide in patient management, and the alternative, i.e. not conducting this kind of research due to the circumstances described, is not seen as an option.

As overall concluding remarks to the present thesis we would like to state the following:

Investigating the patient-reported outcomes is necessary to recognize patients' subjective problems from persisting signs and symptoms in general and mouth opening capacity and sensibility disturbances in particular, as the latter are not sufficiently reflected by the diagnostic tests in common clinical use. Accordingly, a valid and reliability-tested, diagnosis-specific questionnaire would make it possible to obtain an extensive and continuous evaluation of the treatment effects and the subsequent outcomes.

As diplopia and enophthalmos can develop after the final routine clinical follow-up appointment at 1 month after surgery, in selected cases a clinical examination at 6 months or later should be conducted in order to appropriately assess the final outcome of the surgical treatment.

Patients' experienced problems from visible incision scars and facial asymmetry indicate the necessity for further improvement of surgical techniques. To reduce the

risk of improper surgical realignment of the fracture passing undetected, a routine postoperative CT/X-rays should be recommended to confirm reposition. Furthermore, mouth opening problems for several months after surgery may indicate the need for postoperative jaw exercises. Adequate assessment of sensibility disturbances may likewise indicate the need for active treatment in some cases.

The number of orbital floor explorations that are being performed for diagnostic purposes signify insufficient pre-operative diagnostic methods. The presence of diplopia is a key symptom that tend to lead to surgical intervention. Vertical diplopia due to entrapment is an absolute indication for orbital floor surgery. Methods to reliably establish this pre-operatively could prevent explorative surgery. The vertical eye motility test, vEOG, that has been described and evaluated in this thesis proves to have the potential of being a simple, objective, non-invasive, harmless, quick and inexpensive test to help predict which patients will benefit from orbital floor surgery. Vertical electro-oculography (i) objectively measures vertical eye motility; (ii) detects and verifies mechanical restriction of vertical eye motility; and (iii) distinguishes patients who experience vertical diplopia from healthy test subjects with 'normal' eye motility.

7. Aims for future research

Future research on the subject should aim to:

– investigate whether vEOG can be used to establish restricted eye motility as a cause of diplopia in patients with acute blow-out fractures and, furthermore, whether entrapment can be distinguished; and

– investigate the influence on vEOG, of the peri-orbital swelling in the acute stage of an orbital floor fracture.

The fact that blow-out fractures are the least inhomogeneous type of orbital floor fractures makes them suitable for a study of patients with an acute injury. The increased distance between the electrodes and the cornea, which is dependent on the thickness of the peri-orbital haematoma, is expected to suppress the recording; however, it needs to be further investigated to what extent the recording is suppressed.

Previous vEOG electrode settings should be supplemented with more electrodes so that a combination of recordings can be used to draw conclusions about the impact that the increased distance to the cornea has on the registered curve, its amplitude and velocity. The size and thickness of the haematoma will be measured in routine horizontal CT scans.

To study whether entrapment can be distinguished from other causes of restricted eye motility, a multi-centre study is required to obtain enough patients for power. Only eight to ten blow-out fractures are treated at the university clinic each year, and entrapment can be expected to be present in only up to approximately 30% of these cases (Tong et al. 2001).

Future research should furthermore aim to:

– construct a diagnosis-specific score to enhance the evaluation of the quality of current treatment policies;

– construct a diagnosis-specific questionnaire that can be used for early detection of cases that require jaw exercises, eye movement exercises and surgical or medical treatment (in case of a progressing sensibility disorder) to speed up recovery. The quality aspects of the treatment are important and require continuous evaluation of the results and outcomes. A valid and reliable scoring instrument would be of help in this work.

– evaluate the prognostic value of oblique sagittal CT reformattations of the orbit in floor fracture diagnostics; such as the possibility to evaluate whether the periorbit is preserved as a potential reason for obviating surgical intervention; and

– evaluate 3D CT in preparing facial fracture surgery.

The present ICD system (ICD-10) provides two codes which can easily be mixed up in diagnosis coding of orbital floor fractures (S 02.3 and S 02.8), and fractures of the maxilla and zygoma are unselectively collected under the same code (S 02.4). This is unfortunate. To enhance future quality studies of facial fracture treatment and outcomes an ICD coding should be provided which separates the diagnosis codes for zygomatico-orbital fractures, blow-out fractures, tetrapod fractures and arch fractures. This subdivision should agree with the clinical diversities and the relevant factors for dealing with them, such as differences in diagnostic procedures, treatment and planning for surgery in terms of operation time and materials that have to be available for fixation or for an implant.

References

Abràmoff MD. Objective measurement of motion in the orbit. Thesis 2001. University Medical Center Utrecht, the Netherlands. Retreived 2006 at http:// bij.isi.uu.nl/downloads/thesis.72dpi.pdf.

Afzelius LE, Rosen C. Fractures of the malar bone. Follow-up study based upon a questionnaire. ORL J Otorhinolaryngol Relat Spec 1979; 41 (4):227-33.

Agerberg G. Maximal mandibular movements in young men and women. Sven Tandlak Tidskr 1974b; 67 (2):81-100.

Appling WD, Patrinely JR, Salzer TA. Transconjunctival approach vs subciliary skin-muscle flap approach for orbital fracture repair. Arch Otolaryngol Head Neck Surg 1993; 119 (9):1000-7.

Baloh RW, Konrad HR, Sills AW et al. The saccade velocity test. Neurology 1975; 25 (11):1071-6.

Baumann A, Burggasser G, Gauss N et al. Orbital floor reconstruction with an alloplastic resorbable polydioxanone sheet. Int J Oral Maxillofac Surg 2002; 31 (4):367-73.

Bellamy N. Musculoskeletal Clinical Metrology. Dordrecht, Boston, London: Kluwer Academic Publishers; 1993.

Biesman BS, Hornblass A, Lisman R et al. Diplopia after surgical repair of orbital floor fractures. Ophthal Plast Reconstr Surg 1996; 12 (1):9-16; discussion 7.

Boush GA, Lemke BN. Progressive infraorbital nerve hypesthesia as a primary indication for blow-out fracture repair. Ophthal Plast Reconstr Surg 1994; 10 (4):271-5.

Boyd SB, Karas ND, Sinn DP. Recovery of mandibular mobility following orthognathic surgery. J Oral Maxillofac Surg 1991; 49 (9):924-31.

Burnstine MA. Clinical recommendations for repair of isolated orbital floor fractures: an evidence-based analysis. Ophthalmology 2002; 109 (7):1207-10; discussion 10-1; quiz 12-3.

Burnstine MA. Clinical recommendations for repair of orbital facial fractures
Clinical recommendations for repair of isolated orbital floor fractures: an evidence-based analysis. Curr Opin Ophthalmol 2003; 14 (5):236-40.

Carr-Hill RA. The measurement of patient satisfaction. J Public Health Med 1992; 14 (3):236-49.

Celic R, Jerolimov V, Knezovic Zlataric D et al. Measurement of mandibular movements in patients with temporomandibular disorders and in asymptomatic subjects. Coll Antropol 2003; 27 Suppl 2:43-9.

Cogan DG. Neurology of the ocular muscles. Second edition, forth printing 1969 ed: Charles C Thomas Publisher; 1956.

Collewijn H, van der Mark F, Jansen TC. Precise recording of human eye movements. Vision Res 1975; 15 (3):447-50.

Collins SL, Moore RA, McQuay HJ. The visual analogue pain intensity scale: what is moderate pain in millimetres? Pain 1997; 72 (1-2):95-7.

Converse JM, Smith B. Blowout fracture of the floor of the orbit. Trans Am Acad Ophthalmol Otolaryngol 1960; 64:676-88.

Converse JM, Smith B, Obear MF et al. Orbital blowout fractures: a ten-year survey. Plast Reconstr Surg 1967; 39 (1):20-36.

Courtney DJ, Thomas S, Whitfield PH. Isolated orbital blowout fractures: survey and review. Br J Oral Maxillofac Surg 2000; 38 (5):496-504.

Crewe TC. Facts and fallacies of orbital floor injuries. Int J Oral Surg 1981; 10 (Suppl 1):225-8.

De Man K, Bax WA. The influence of the mode of treatment of zygomatic bone fractures on the healing process of the infraorbital nerve. Br J Oral Maxillofac Surg 1988; 26 (5):419-25.

Devereaux PJ, Bhandari M, Clarke M et al. Need for expertise based randomised controlled trials. Bmj 2005; 330 (7482):88.

Dexter F, Chestnut DH. Analysis of statistical tests to compare visual analog scale measurements among groups. Anesthesiology 1995; 82 (4):896-902.

Dietz A, Ziegler CM, Dacho A et al. Effectiveness of a new perforated 0.15 mm poly-p-dioxanon-foil versus titanium-dynamic mesh in reconstruction of the orbital floor. J Craniomaxillofac Surg 2001; 29 (2):82-8.

Dijkstra PU, Huisman PM, Roodenburg JL. Criteria for trismus in head and neck oncology. Int J Oral Maxillofac Surg 2006; 35 (4):337-42.

Downie WW, Leatham PA, Rhind VM et al. Studies with pain rating scales. Ann Rheum Dis 1978; 37 (4):378-81.

Ellis E, 3rd, el-Attar A, Moos KF. An analysis of 2,067 cases of zygomatico-orbital fracture. J Oral Maxillofac Surg 1985; 43 (6):417-28.

Ellis E, 3rd, Tan Y. Assessment of internal orbital reconstructions for pure blowout fractures: cranial bone grafts versus titanium mesh. J Oral Maxillofac Surg 2003; 61 (4):442-53.

Fitzpatrick R. Surveys of patients satisfaction: I--Important general considerations. Bmj 1991b; 302 (6781):887-9.

Fitzpatrick R. Surveys of patient satisfaction: II--Designing a questionnaire and conducting a survey. Bmj 1991a; 302 (6785):1129-32.

Flood TR, McManners J, el-Attar A et al. Randomized prospective study of the influence of steroids on postoperative eye-opening after exploration of the orbital floor. Br J Oral Maxillofac Surg 1999; 37 (4):312-5.

Freund M, Hahnel S, Sartor K. The value of magnetic resonance imaging in the diagnosis of orbital floor fractures. Eur Radiol 2002; 12 (5):1127-33.

Gellrich NC, Schramm A, Hammer B et al. Computer-assisted secondary reconstruction of unilateral posttraumatic orbital deformity. Plast Reconstr Surg 2002; 110 (6):1417-29.

Gewalli F, Sahlin P, Guimaraes-Ferreira J et al. Orbital fractures in craniofacial trauma in Goteborg: trauma scoring, operative techniques, and outcome. Scand J Plast Reconstr Surg Hand Surg 2003; 37 (2):69-74.

Glassman RD, Manson PN, Vanderkolk CA et al. Rigid fixation of internal orbital fractures. Plast Reconstr Surg 1990; 86 (6):1103-9; discussion 10-1.

Goldberg RA, Garbutt M, Shorr N. Oculoplastic uses of cranial bone grafts. Ophthalmic Surg 1993; 24 (3):190-6.

Guerra MF, Perez JS, Rodriguez-Campo FJ et al. Reconstruction of orbital fractures with dehydrated human dura mater. J Oral Maxillofac Surg 2000; 58 (12):1361-6; discussion 6-7.

Hakelius L, Ponten B. Results of immediate and delayed surgical treatment of facial fractures with diplopia. J Maxillofac Surg 1973; 1 (3):150-4.

Hartstein ME, Roper-Hall G. Update on orbital floor fractures: indications and timing for repair. Facial Plast Surg 2000; 16 (2):95-106.

Hawes MJ, Dortzbach RK. Surgery on orbital floor fractures. Influence of time of repair and fracture size. Ophthalmology 1983; 90 (9):1066-70.

Helveston EM. The relationship of extraocular muscle problems to orbital floor fractures: early and late management. Trans Sect Ophthalmol Am Acad Ophthalmol Otolaryngol 1977; 83 (4 Pt 1):660-2.

Hinohira Y, Yumoto E, Shimamura I et al. Endoscopic endonasal reduction of blowout fractures of the orbital floor Otolaryngol Head Neck Surg 2005; 133 (5):741-7.

Hodgson Phillips L. Methodology in research. In, translator and editor Evidence-based sports medicine. London: BMJ Books; 2002.

Holmes JM, Leske DA, Kupersmith MJ. New methods for quantifying diplopia. Ophthalmology 2005; 112 (11):2035-9.

Huskisson EC, Jones J, Scott PJ. Application of visual-analogue scales to the measurement of functional capacity. Rheumatol Rehabil 1976; 15 (3):185-7.

Hötte HH. Orbital fractures. Assen, The Netherlands: Royal Van Gorcum Ltd; 1970. Chapter XV; p 334 p.

Ilankovan V, Hadley D, Moos K et al. A comparison of imaging techniques with surgical experience in orbital injuries. A prospective study. J Craniomaxillofac Surg 1991; 19 (8):348-52.

Iliff N, Manson PN, Katz J et al. Mechanisms of extraocular muscle injury in orbital fractures. Plast Reconstr Surg 1999; 103 (3):787-99.

Jank S, Emshoff R, Etzelsdorfer M et al. Ultrasound versus computed tomography in the imaging of orbital floor fractures. J Oral Maxillofac Surg 2004; 62 (2):150-4.

Jungell P, Lindqvist C. Paraesthesia of the infraorbital nerve following fracture of the zygomatic complex. Int J Oral Maxillofac Surg 1987; 16 (3):363-7.

Kanski JJ. Clinical Opthalmology. Second ed. Oxford: Butterwort-Heinemann Ltd; 1989. 1 vols.

Koide R, Ueda T, Takano K et al. Surgical outcome of blowout fracture: early repair without implants and the usefulness of balloon treatment. Jpn J Ophthalmol 2003; 47 (4):392-7.

Kontio R, Suuronen R, Ponkkonen H et al. Have the causes of maxillofacial fractures changed over the last 16 years in Finland? An epidemiological study of 725 fractures. Dent Traumatol 2005; 21 (1):14-9.

Koornneef L. Current concepts on the management of orbital blow-out fractures. Ann Plast Surg 1982; 9 (3):185-200.

Kovacs AF, Ghahremani M, Shumrick KA et al. Minimization of zygomatic complex fracture treatment Int J Oral Maxillofac Surg 2001; 30 (5):380-3.

Kushner BJ. Management of diplopia limited to down gaze. Arch Ophthalmol 1995; 113 (11):1426-30.

Lee JW, Chiu HY. Quantitative computed tomography for evaluation of orbital volume change in blow-out fractures. J Formos Med Assoc 1993; 92 (4):349-55.

Lehto KS, Sulander PO, Tervo TM. Do motor vehicle airbags increase risk of ocular injuries in adults? Ophthalmology 2003; 110 (6):1082-8.

Leigh RJ, Zee DS. The Neurology of Eye Movement. Philadelphia: F A Davis Company; 1983. (Contemporary Neurology Series).

Levin LM, Kademani D. Clinical considerations in the management of orbital blow-out fractures. Compend Contin Educ Dent 1997; 18 (6):593, 6-8, 600; quiz 2.

Liu D. Blindness after blow-out fracture repair. Ophthal Plast Reconstr Surg 1994; 10 (3):206-10.

Lundin K, Ridell A, Sandberg N et al. One thousand maxillo-facial and related fractures at the ENT-clinic in Gothenburg. A two-year prospective study. Acta Otolaryngol 1973; 75 (4):359-61.

Macauley D, Best TM. Evidence-based medicine critical appraisal, what to look for in an article. In, translator and editor Evidence-based sports medicine. London: BMJ Books; 2002.

Manson PN. Computed tomography use and repair of orbitozygomatic fractures. Arch Facial Plast Surg 1999; 1 (1):25-6.

Manson PN. Facial injuries. In: JG McCarthy, editor, translator and editor Plastic Surgery. Vol. 2, The Face, part I. Philadelphia: Saunders; 1990; p. 867-1141.

Manson PN, Clifford CM, Su CT et al. Mechanisms of global support and posttraumatic enophthalmos: I. The anatomy of the ligament sling and its relation to intramuscular cone orbital fat. Plast Reconstr Surg 1986a; 77 (2):193-202.

Manson PN, Grivas A, Rosenbaum A et al. Studies on enophthalmos: II. The measurement of orbital injuries and their treatment by quantitative computed tomography. Plast Reconstr Surg 1986b; 77 (2):203-14.

Manson PN, Ruas E, Iliff N et al. Single eyelid incision for exposure of the zygomatic bone and orbital reconstruction. Plast Reconstr Surg 1987; 79 (1):120-6.

Mathog RH. Management of orbital blow-out fractures. Otolaryngol Clin North Am 1991; 24 (1):79-91.

Mauriello JA, Jr., Antonacci R, Mostafavi R et al. Combined paresis and restriction of the extraocular muscles after orbital fracture: a study of 16 patients. Ophthal Plast Reconstr Surg 1996; 12 (3):206-10.

McCormack HM, Horne DJ, Sheather S. Clinical applications of visual analogue scales: a critical review. Psychol Med 1988; 18 (4):1007-19.

McNab AA. Orbital and optic nerve trauma. World J Surg 2001; 25 (8):1084-8.

Metz HS. Forced duction, active force generation, and saccadic velocity tests. Int Ophthalmol Clin 1976; 16 (3):47-73.

Metz HS, Scott WE, Madson E et al. Saccadic velocity and active force studies in blow-out fractures of the orbit. Am J Ophthalmol 1974; 78 (4):665-70.

Nathanson A, Matthis SP, Tengvar M. Diagnosis and treatment of fractures of the orbital floor. A ten-year retrospective study. Acta Otolaryngol Suppl 1992; 492:28-32.

Nguyen PN, Sullivan P. Advances in the management of orbital fractures. Clin Plast Surg 1992; 19 (1):87-98.

Peltomaa J, Rihkanen H. Infraorbital nerve recovery after minimally dislocated facial fractures. Eur Arch Otorhinolaryngol 2000; 257 (8):449-52.

Ploder O, Klug C, Voracek M et al. Evaluation of computer-based area and volume measurement from coronal computed tomography scans in isolated blowout fractures of the orbital floor. J Oral Maxillofac Surg 2002; 60 (11):1267-72; discussion 73-4.

Putterman AM. Discussion. Ophthalmology 1987; 94 (6):686-7.

Putterman AM, Stevens T, Urist MJ. Nonsurgical management of blow-out fractures of the orbital floor. Am J Ophthalmol 1974; 77 (2):232-9.

Rake PA, Rake SA, Swift JQ et al. A single reformatted oblique sagittal view as an adjunct to coronal computed tomography for the evaluation of orbital floor fractures. J Oral Maxillofac Surg 2004; 62 (4):456-9.

Remulla HD, Bilyk JR, Rubin PA. Pseudo-entrapment of extraocular muscles in patients with orbital fractures. J Craniomaxillofac Trauma 1995; 1 (4):16-29.

Rohrich RJ, Hollier LH, Watumull D. Optimizing the management of orbitozygomatic fractures. Clin Plast Surg 1992; 19 (1):149-65.

Rohrich RJ, Janis JE, Adams WP, Jr. Subciliary versus subtarsal approaches to orbitozygomatic fractures. Plast Reconstr Surg 2003; 111 (5):1708-14.

Rosbe KW, Meredith SD, Holmes DK. Complication of maxillary sinus Foley balloon placement for orbital floor support. Otolaryngol Head Neck Surg 1997; 117 (6):S148-50.

Rubin PA, Bilyk JR, Shore JW. Orbital reconstruction using porous polyethylene sheets. Ophthalmology 1994; 101 (10):1697-708.

Shumrick KA, Kersten RC, Kulwin DR et al. Criteria for selective management of the orbital rim and floor in zygomatic complex and midface fractures. Arch Otolaryngol Head Neck Surg 1997; 123 (4):378-84.

Sires BS, Stanley RB, Jr., Levine LM. Oculocardiac reflex caused by orbital floor trapdoor fracture: an indication for urgent repair. Arch Ophthalmol 1998; 116 (7):955-6.

Sitzia J, Wood N. Patient satisfaction: a review of issues and concepts. Soc Sci Med 1997; 45 (12):1829-43.

Spector RH. Vertical diplopia. Surv Ophthalmol 1993; 38 (1):31-62.

Streiner DL, Norman GR. Health measurement scales - a practical guide to their development and use. Third ed. Oxford: Oxford University Press; 2003

Strong EB, Kim KK, Diaz RC. Endoscopic approach to orbital blowout fracture repair. Otolaryngol Head Neck Surg 2004; 131 (5):683-95.

Surtees P, Wainwright N, Luben R et al. Sense of coherence and mortality in men and women in the EPIC-Norfolk United Kingdom prospective cohort study. Am J Epidemiol 2003; 158 (12):1202-9.

Swedish Board of Health and Welfare 2006. www.sos.se/epc/par

Tadj A, Kimble FW. Fractured zygomas. ANZ J Surg 2003; 73 (1-2):49-54.

Tengtrisorn S, McNab AA, Elder JE. Persistent infra-orbital nerve hyperaesthesia after blunt orbital trauma. Aust N Z J Ophthalmol 1998; 26 (3):259-60.

Thell J, Odkvist LM. Artifacts in electronystagmographic recordings. Acta Otolaryngol Suppl 1988; 455:62-6.

Tian S, Lennerstrand G, Nishida Y et al. Eye muscle force development and saccadic velocity in thyroid-associated ophthalmopathy. Graefes Arch Clin Exp Ophthalmol 2003; 241 (9):740-6.

Tong L, Bauer RJ, Buchman SR. A current 10-year retrospective survey of 199 surgically treated orbital floor fractures in a nonurban tertiary care center. Plast Reconstr Surg 2001; 108 (3):612-21.

Wachler BS, Holds JB. The missing muscle syndrome in blowout fractures: an indication for urgent surgery. Ophthal Plast Reconstr Surg 1998; 14 (1):17-8.

Van Eeckhoutte L, De Clippeleir L, Apers R et al. A protocol for extraocular muscle surgery after orbital floor fracture ("blow-out"). Binocul Vis Strabismus Q 1998; 13 (1):29-36.

Waris E, Konttinen YT, Ashammakhi N et al. Bioabsorbable fixation devices in trauma and bone surgery: current clinical standing. Expert Rev Med Devices 2004; 1 (2):229-40.

Westermark A, Jensen J, Sindet-Pedersen S et al. Zygomatic fractures and infraorbital nerve disturbances. Miniplate osteosynthesis vs. other treatment modalities Oral Surg Oral Diagn 1992; 3 (3):27-30.

Wilkins RB, Havins WE. Current treatment of blow-out fractures. Ophthalmology 1982; 89 (5):464-6.

Winstanley RP. The management of fractures of the zygoma. Int J Oral Surg 1981; 10 (Suppl 1):235-40.

Woodruff G, O'Reilly C, Kraft SP. Functional scoring of the field of binocular single vision in patients with diplopia. Ophthalmology 1987; 94 (12):1554-61.

Woog JJ, Hartstein ME, Gliklich R. Paranasal sinus endoscopy and orbital fracture repair. Arch Ophthalmol 1998; 116 (5):688-91.

Vriens JP, van der Glas HW, Moos KF et al. Infraorbital nerve function following treatment of orbitozygomatic complex fractures. A multitest approach. Int J Oral Maxillofac Surg 1998; 27 (1):27-32.

Yaremchuk MJ. Changing concepts in the management of secondary orbital deformities. Clin Plast Surg 1992; 19 (1):113-24.

Zingg M, Laedrach K, Chen J et al. Classification and treatment of zygomatic fractures: a review of 1,025 cases. J Oral Maxillofac Surg 1992; 50 (8):778-90.

Acknowledgements

I wish to express my sincere gratitude to all those who in different ways and so generously have contributed to this thesis.

I would particularly like to express my thanks to:

The patients, test subjects, colleagues and staff of the Otorhinolaryngology and Head & Neck Surgery (ORL-HNS) and Audiology clinics, without the co-operation of whom this thesis would have been impossible to carry through.

My supervisor and Head of the Department of ORL, at the Institution of the Clinical Sciences, Göteborg University, Professor Gösta Granström, for supporting me through the years and for letting me take leave of absence to write this thesis.

Eva Jensen, department secretary, for encouraging support and for assistance with administrative matters.

Thomas Westin, Associate Professor of ORL-HNS, for introducing me to the field of facial fractures.

My inspiring co-authors, Claes Möller, Professor at the Department of Audiology, Göteborg University; Dr. Gun Lindgren, M.D., Ph.D. at the Department of Ophthalmology, Göteborg University; and Lisbeth Åberg-Bengtsson, Associate Professor at the Department of Education and Educational Research, Göteborg University, for professional co-operation, for generously sharing their broad knowledge, and for many a fruitful discussion.

My brother, Anders Åkerlund, M.D., Ph.D. of ORL, Astra-Zeneca, for invaluable guidance and support.

Mats Bende, Professor at the Department of ORL, Göteborg University, for enthusiastic encouragement and constructive criticism.

Magnus Ruth, Associate Professor of ORL, Astra-Zeneca, for thorough reviewing and valuable comments.

Göran Karlsson, Professor at the Department of ORL, for constructive advice.

Helena Johansson, M.Sc. in Statistics, for calculating, and pedagogically and patiently explaining the statistics to me.

Jan Persson, photographer at the ORL-HNS clinic, for computer support and for always turning up at short notice whenever asked to, to take excellent photographs of the patients.

Caterina Finizia, Associate Professor at the Department of Otorhinolaryngology and Head & Neck Surgery, for advice, support and a never-ending belief in my capacity.

Ann Hermansson, Associate Professor at the Department of Otorhinolaryngology and Head & Neck Surgery at Lund University, and faculty opponent, for actually reading my thesis.

Last but not least, my endless gratitude goes to:

Family and friends, for never-ending support and for patiently staying around although I have not been much company for some time,

and a special thank to

My husband Göran for guidance on the structure of the thesis and thorough reviewing,

My eldest son, Andreas, technical design student at Chalmers University of Technology, for his meticulous work in measuring all the vEOG curves and for producing the beautiful illustrations in this thesis.

These studies were supported by grants from: the Trygg-Hansa Research Foundation, the CTRF Cancer and Traffic Victims Campaign, the Local Research and Development Counsil of Gothenburg and Southern Bohuslän, the Göteborg Medical Association and *Acta Oto-laryngologica*.

The criterion of a good result is when the patient
is pleased with the outcome