

On immediate/early loading of implant-supported prostheses in the maxilla

Kerstin Fischer



**Department of Biomaterials
Institute of Clinical Sciences
Sahlgrenska Academy
Göteborg University, Sweden**

Göteborg 2008

This thesis represents number 38 in a series of investigations on implants, hard tissue and the locomotor apparatus originating from the Department of Biomaterials/Handicap Research, Institute for Clinical Sciences at Sahlgrenska Academy, Göteborg University, Sweden.

1. **Anders R Eriksson DDS, 1984.** Heat-induced Bone Tissue Injury. An in vivo investigation of heat tolerance of bone tissue and temperature rise in the drilling of cortical bone. Thesis defended 21.2.1984. Ext. examin.: Docent K.-G. Thorngren.
2. **Magnus Jacobsson MD, 1985.** On Bone Behaviour after Irradiation. Thesis defended 29.4.1985. Ext. examin.: Docent A. Nathanson.
3. **Fredrik Buch MD, 1985.** On Electrical Stimulation of Bone Tissue. Thesis defended 28.5.1985. Ext. examin.: Docent T. Ejsing-Jørgensen.
4. **Peter Kålebo MD, 1987.** On Experimental Bone Regeneration in Titanium Implants. A quantitative microradiographic and histologic investigation using the Bone Harvest Chamber. Thesis defended 1.10.1987. Ext. examin.: Docent N.Egund.
5. **Lars Carlsson MD, 1989.** On the Development of a new Concept for Orthopaedic Implant Fixation. Thesis defended 2.12.1989. Ext. examin.: Docent L.-Å. Broström.
6. **Tord Röstlund MD, 1990.** On the Development of a New Arthroplasty. Thesis defended 19.1.1990. Ext. examin.: Docent Å. Carlsson.
7. **Carina Johansson Techn Res, 1991.** On Tissue Reactions to Metal Implants. Thesis defended 12.4.1991. Ext. examin.: Professor K. Nilner.
8. **Lars Sennerby DDS, 1991.** On the Bone Tissue Response to Titanium Implants. Thesis defended 24.9.1991. Ext. examin.: Dr J.E. Davis.
9. **Per Morberg MD, 1991.** On Bone Tissue Reactions to Acrylic Cement. Thesis defended 19.12.1991. Ext. examin.: Docent K. Obrant.
10. **Ulla Myhr PT, 1994.** On Factors of Importance for Sitting in Children with Cerebral Palsy. Thesis defended 15.4.1994. Ext. examin.: Docent K. Harms-Ringdahl.
11. **Magnus Gottlander MD, 1994.** On Hard Tissue Reactions to Hydroxyapatite-Coated Titanium Implants. Thesis defended 25.11.1994. Ext. examin.: Docent P. Aspenberg.
12. **Edward Ebramzadeh MScEng, 1995.** On Factors Affecting Long-Term Outcome of Total Hip Replacements. Thesis defended 6.2.1995. Ext. examin.: Docent L. Linder.
13. **Patricia Campbell BA, 1995.** On Aseptic Loosening in Total Hip Replacement: the Role of UHMWPE Wear Particles. Thesis defended 7.2.1995. Ext. examin.: Professor D. Howie.
14. **Ann Wennerberg DDS, 1996.** On Surface Roughness and Implant Incorporation. Thesis defended 19.4.1996. Ext. examin.: Professor P.-O. Glantz.
15. **Neil Meredith BDS MSc FDS RCS, 1997.** On the Clinical Measurement of Implant Stability and Osseointegration. Thesis defended 3.6.1997. Ext. examin.: Professor J. Brunski.
16. **Lars Rasmusson DDS, 1998.** On Implant Integration in Membrane-Induced and Grafted Bone. Thesis defended 4.12.1998. Ext. examin.: Professor R. Haanaes.
17. **Thay Q Lee MSc, 1999.** On the Biomechanics of the Patellofemoral Joint and Patellar Resurfacing in Total Knee Arthroplasty. Thesis defended 19.4.1999. Ext. examin.: Docent G. Nemeth.
18. **Anna Karin Lundgren DDS, 1999.** On Factors Influencing Guided Regeneration and Augmentation of Intramembraneous Bone. Thesis defended 7.5.1999. Ext. examin.: Professor B. Klinge.
19. **Carl-Johan Ivanoff DDS, 1999.** On Surgical and Implant Related Factors Influencing Integration and Function of Titanium Implants. Experimental and Clinical Aspects. Thesis defended 12.5.1999. Ext. examin.: Professor B. Rosenquist.

20. **Bertil Friberg DDS MDS, 1999.** On Bone Quality and Implant Stability Measurements. Thesis defended 12.11.1999. Ext. examin.: Docent P. Åstrand.
21. **Åse Allansdotter Johnsson MD, 1999.** On Implant Integration in Irradiated Bone. An Experimental Study of the Effects of Hyperbaric Oxygenation and Delayed Implant Placement. Thesis defended 8.12.1999. Ext. examin.: Docent K. Arvidsson-Fyrberg.
22. **Börje Svensson DDS, 2000.** On Costochondral Grafts Replacing Mandibular Condyles in Juvenile Chronic Arthritis. A Clinical, Histologic and Experimental Study. Thesis defended 22.5.2000. Ext. examin.: Professor Ch. Lindqvist.
23. **Warren Macdonald BEng, MPhil, 2000.** On Component Integration in Total Hip Arthroplasty: Pre-Clinical Evaluations. Thesis defended 1.9.2000. Ext. examin.: Dr A.J.C. Lee.
24. **Magne Røkkum MD, 2001.** On Late Complications with HA Coated Hip Arthroplasties. Thesis defended 12.10.2001. Ext. examin.: Professor P. Benum.
25. **Carin Hallgren Höstner DDS, 2001.** On the Bone Response to Different Implant Textures. A 3D analysis of roughness, wavelength and surface pattern of experimental implants. Thesis defended 9.11.2001. Ext. examin.: Professor S. Lundgren.
26. **Young-Taeg Sul DDS, 2002.** On the Bone Response to Oxidised Titanium Implants: The role of microporous structure and chemical composition of the surface oxide in enhanced osseointegration. Thesis defended 7.6.2002. Ext. examin.: Professor J.-E. Ellingsen.
27. **Victoria Franke Stenport DDS, 2002.** On Growth Factors and Titanium Implant Integration in Bone. Thesis defended 11.6.2002. Ext. examin.: Associate Professor E. Solheim.
28. **Mikael Sundfeldt MD, 2002.** On the Aetiology of Aseptic Loosening in Joint Arthroplasties, and Routes to Improved cemented Fixation. Thesis defended 14.6.2002. Ext. examin.: Professor N Dahlén.
29. **Christer Slotte DDS, 2003.** On Surgical Techniques to Increase Bone Density and Volume. Studies in the Rat and the Rabbit. Thesis defended 13.6.2003. Ext. examin.: Professor C.H.F. Hämmerle.
30. **Anna Arvidsson MSc, 2003.** On Surface Mediated Interactions Related to Chemo-mechanical Caries Removal. Effects on surrounding tissues and materials. Thesis defended 28.11.2003. Ext. examin.: Professor P. Tengvall.
31. **Pia Bolind DDS, 2004.** On 606 retrieved oral and cranio-facial implants. An analysis of consecutively received human specimens. Thesis defended 17.12. 2004. Ext. examin.: Professor A. Piattelli.
32. **Patricia Miranda Burgos DDS, 2006.** On the influence of micro-and macroscopic surface modifications on bone integration of titanium implants. Thesis defended 1.9. 2006. Ext. examin.: Professor A. Piattelli.
33. **Jonas P Becktor DDS, 2006.** On factors influencing the outcome of various techniques using endosseous implants for reconstruction of the atrophic edentulous and partially dentate maxilla. Thesis defended 17.11.2006. Ext examin: Professor K. F. Moos
34. **Anna Göransson DDS, 2006.** On Possibly Bioactive CP Titanium Surfaces. Thesis defended 8.12. 2006 Ext examin: Prof B. Melsen
35. **Andreas Thor DDS, 2006.** On platelet-rich plasma in reconstructive dental implant surgery. Thesis defended 8.12. 2006. Ext examin Prof E.M. Pinholt.
36. **Luiz Meirelles DDS MSc, 2007.** On Nano Size Structures For Enhanced Early Bone Formation. Thesis defended 13.6.2007. Ext examin:Professor Lyndon F. Cooper.
37. **Pär-Olov Östman DDS, 2007.** On various protocols for direct loading of implant-supported fixed prostheses. Thesis defended 21.12.2007. Ext examin: Prof B Klinge
38. **Kerstin Fischer DDS, 2008.** On immediate/early loading of implantsupported prostheses in the maxilla. To be defended 8.2.2008. Ext examin:Professor Kristina Arvidson Fyrberg

ABSTRACT

Background: The original treatment protocol for osseointegrated implants prescribed an unloaded healing period of 3 to 6 months before connection of the prosthetic superstructure. During the last years shortened healing time and rapid loading have become more frequently used. Clinical follow-up studies have reported positive clinical outcomes. However, there are few controlled studies of immediate/early loading in the maxilla.

Aims: The aim of this thesis is to test the hypothesis that immediate/early loading of dental implants in the maxilla results in the same clinical outcomes as when using delayed loading.

Material and Methods: *Papers I, II and III* compared the treatment outcome of early and delayed loading of moderately roughened implants (SLA) in 24 patients for support of a fixed bridge in the totally edentulous maxilla after one, three and five years, respectively. The patients were randomly allotted to either early (n=16, test group) or delayed loading (n=8, control group).

Paper IV evaluated the clinical outcomes and development of implant stability with resonance frequency analysis (RFA) of 53 moderately rough implants (oxidized) in 32 patients when subjected to immediate (single tooth, n=16) or early loading (partial bridge, n=16) in their partially edentulous maxilla during one year.

Paper V investigated in the relation between implant stability measurements and marginal bone loss measurements after three and five years of function in the edentulous maxilla in the same 24 patients as in Papers I, II and III.

Results: *Papers I, II and III.* In total, 142 implants were placed and 139 were loaded with full-arch prostheses: 94 in the test group and 45 in the control group. One test and two control implants were lost before loading. Another four failures were observed in the test group at the five-year follow-up giving a survival rate of 94.7 % for the test and 95.7 % for the control group, respectively (ns). The test group showed significantly better sulcus bleeding index and plaque index scores than the control group after one year. At the 3-year follow-up there were no significant differences between the groups. At the 5-year follow-up more test than control patients presented with plaque. A higher proportion of patients as well as implants in the control group had pocket depths > 3 mm. The average bone loss was greater for test than for control implants during five years, 0.8 (SD 1.2) mm vs 0.3 (SD 1.1) mm ($p < 0.05$). However, the bone level was situated more coronally for the test implants during the study period ($p < 0.05$). Technical complications were mainly resin-related.

Paper IV. One single tooth implant was lost, given an overall survival rate of 98.1 % (93.8 % for single and 100% for partial bridges) after one year. The average bone loss during the period was 1.1 (SD 1.0) mm (1.5 mm (SD 1.0) in single tooth and 0.9 (SD 1.0) mm in partial cases). A statistically significant increase of implant stability with, on average, 3.3 (SD 5.0) ISQ units was observed for both single tooth and partial bridge implants.

Paper V. RFA measurements after three and five years correlated with marginal bone levels as measured in intraoral radiographs. RFA measurements registered at three years could not predict implant failures at the five-year follow-up.

Conclusion: It is concluded that immediate /early loading of dental implants in the maxilla results in the same clinical outcomes as for delayed loading.

Keywords: dental implant, clinical study, randomized study, immediate loading, early loading, resonance frequency analysis

ISBN: 978-91-628-7363-9

Correspondence: Kerstin Fischer, Strandvagen 54, SE-791 42 Falun, Sweden, e-mail: kerstin.fischer@swipnet.se

List of papers

This dissertation is based on the following papers, which will be referred to in the text by their Roman numerals (papers reprinted by kind permission of journal editors):

- I. **Fischer K & Stenberg T.** Early loading of ITI implants supporting a maxillary full-arch prosthesis: 1-year data of a prospective, randomized study. *Int J Oral Maxillofac Impl* 2004; **19**: 374-381.
- II. **Fischer K & Stenberg T.** Three-year data from a randomized, controlled study of early loading of single-stage dental implants supporting maxillary full-arch prostheses. *Int J Oral Maxillofac Impl* 2006; **21**: 245-252.
- III. **Fischer K, Stenberg T, Hedin M and Sennerby L.** Five-year results from a randomized, controlled trial on early and delayed loading of implants supporting full-arch prosthesis in the edentulous maxilla. *Clin Oral Impl Res* 2008; *In press*.
- IV. **Fischer K, Bäckström M and Sennerby L.** Immediate and early loading of oxidized tapered implants in the partially edentulous maxilla. A one-year prospective clinical, radiographic and resonance frequency analysis study. *Clin Implant Dent Rel Res* 2008; *In press*.
- V. **Fischer K, Stenberg T, Billström C and Sennerby L.** Influence of marginal bone level on implant stability measurements using resonance frequency analysis (RFA). *In manuscript*.

Contents

INTRODUCTION	7
BIOLOGICAL ASPECTS	7
CLINICAL ASPECTS OF THE SURGICAL PROCEDURE	13
CLINICAL ASPECTS OF IMMEDIATE / EARLY LOADING	16
Summary of viewpoints on rapid loading	24
AIMS	25
MATERIAL AND METHODS	26
Papers I, II and III	26
Paper IV	32
Paper V	35
STATISTICS	36
RESULTS	37
Papers I-III	37
Paper IV	44
Paper V	46
DISCUSSION	49
EVIDENCE BASED METHOD	49
IMPLANT SUCCESS / SURVIVAL	50
IMPLANT SURFACES	51
RADIOGRAPHIC EXAMINATION and BONE LEVEL	52
RESONANCE FREQUENCY ANALYSIS (RFA)	53
OUTCOME OF PROSTHESES	55
CONCLUSION	57
Acknowledgements	58
REFERENCES	60
Papers I-V	76

INTRODUCTION

One of the most important significant scientific breakthroughs in clinical dentistry was undoubtedly the introduction, of osseointegrated implants for anchorage of fixed bridges 40 years ago. Today this is an established clinical routine with predictable outcomes. Until the advent of implants, the only treatment alternative was to replace missing teeth with tooth-supported crowns and bridges, or removable dentures. Although fixed appliances may be well accepted, not all patients can adapt successfully to removable dentures and in many cases experience functional and / or psychological problems (Trulsson et al 2002).

Based on the initial concept of osseointegration, many new implant systems have been developed and variations in materials and treatment protocols have been introduced. The original treatment protocol for osseointegrated implants prescribed an unloaded healing period of 3 to 6 months before connection of the prosthetic superstructure and functional loading (Brånemark et al 1969, Albrektsson et al 1981).

Although most treatment routines still include a healing period between implant insertion and loading with a prosthetic superstructure, research during the last 10 years has increasingly focused on loading immediately, or very soon after implant placement. The use of so called immediate/ early loading protocols has obvious advantages for the patients. Only one surgical procedure is required. Both function and aesthetics can be immediately restored with a temporary crown or bridge. However, concerns have been raised about the possibility of increased failure rates.

Today, histology from experimental and clinical studies has demonstrated that functional loads do not impair osseointegration (Piattelli et al 1998, Rocci et al 2003). Moreover, with respect to mandibular implants, clinical follow-up studies of one-stage implants have reported similar positive clinical outcomes as for two-stage procedures. However, there are few controlled studies of maxillary implants (Attard & Zarb 2005).

BIOLOGICAL ASPECTS

The use of osseointegrated implants for treatment of totally edentulous patients was first described by Brånemark et al (1969). The term “osseointegration” was defined as a direct contact between the surface of an implant and the surrounding bone (Brånemark et al 1977). Schroeder et al used the term “functional ankylosis” for the same condition (Schroeder et al 1981). Later, osseointegration was defined as, -”a process whereby clinically asymptomatic rigid fixation of alloplastic materials is achieved, and maintained, in bone during functional loading” (Albrektsson and Zarb 1993).

Titanium

Titanium is element number 22 in the periodic table and was discovered in Cornwall, England in 1791 by an amateur geologist, William Gregor. In 1795 a German chemist, Martin Klaproth (Fig. 1), rediscovered the element and named it for the Titans of Greek mythology. When titanium is exposed to air, a surface oxide is rapidly formed (Kasemo 1983). Thus, the oxide layer and not the bulk metal is exposed to the host tissue and it is this layer which determines the biological response. An important characteristic of titanium is that it can osseointegrate, a property which was discovered by chance over 40 years ago. In the 1960's tooth root analogues were made of titanium by Brånemark and collaborators in Gothenburg.



Fig.1. Klaproth

Bone tissue

Bone is a connective tissue consisting of cells and a mineralized extracellular matrix. It comprises about 65% mineral (mostly hydroxyapatite), 25% organic matrix and 10% water. There are two macro architectural forms – trabecular (cancellous or spongy) and cortical bone (compact or cortex), which are found in various proportions and structural patterns to form the individual bones of the body. In total, the skeleton consists of around 80 % cortical and 20 % trabecular bone. Bone has an outer dense compact layer (cortex), covered by periosteum. The interior of bone is a trabecular bone marrow. The trabeculae are oriented predominantly according to stress.

Bone is constantly resorbed and formed by two processes known as modelling and remodelling. Bone modelling starts during fetal life and continues to the end of the second decade of life, while bone remodelling continues throughout life, replacing old bone with new, maintaining equilibrium between bone deposition and resorption. The bones are remodelled to an ideal shape that best withstands mechanical stress, thereby adapting to functional loading. Load on bone can affect bone quality and quantity and it seems that muscles exert influence on bone mineral content (BMC) as well as on bone mineral density (BMD). The membrane covering the outer surface of the bone is the periosteum . It comprises an outer fibrous layer of dense irregular connective tissue with blood and lymphatic vessels and nerves. The periosteum is involved in bone growth and can form an extra callus during fracture healing.

Bone healing

Bone healing in jaws resembles that of intramembranous bone formation. Bone is unique, being able to heal with regenerated tissue of equally high structural organization, without leaving a scar at least under ideal conditions. There are two stages of healing, an initial primary repair stage, (indirect) and a secondary remodelling stage (direct) (Simmons 1985, Schenk

1994). A hemorrhage occurs at the site of the injury. Granulocytes, monocytes and lymphocytes migrate into the wound, accompanied by mesenchymal pluripotent stem cells. An exudate is produced, containing cytokines and inflammatory mediators. Various factors are released which stimulate cell differentiation and proliferation to e.g. osteoblasts. The bone formation phase always starts with deposition of an osteoid, which later mineralizes.

Based on the orientation of the collagen fibrils, three types of bone tissue are distinguished: woven, lamellar and an intermediate type. Woven bone is the least mineralized form and contains randomly oriented collagen fibrils. In the second stage of bone healing, the woven bone is replaced by lamellar bone, which is characterized by several layers of parallel collagen fibrils. Woven bone is more rapidly formed than lamellar bone: 1 to 3 days compared to 10 days. Remodelling of woven bone to lamellar bone improves the quality of the tissue, both mechanically and metabolically (Aubin and Kahn 1996). The resorption phase of the remodelling process is the function of the osteoclast, a cell derived from circulating monocytes. The mechanism regulating the remodeling process has yet to be clarified.

Integration of turned titanium implants in bone

The structure of the bone-titanium interface was described by Sennerby et al (1993a, 1993b). In rabbit cortical bone, the healing process around screw-shaped implants of commercially pure titanium was observed 3 days after insertion. The process starts with migration of mesenchymal cells and macrophages from the marrow into a hemorrhage which occupies the entire bone-titanium interface. In this rabbit model, bone formation was first observed on day 7 at the endosteal surface of the original cortex, as a lattice of trabecular woven bone approaching the implant and as solitary woven bone formation near the implant surface. The latter type of bone serves as a base for the production of an osteoid seam. With time the two types of bone fuse and fill the implant threads. Thus the increased bone-titanium contact is a result of ingrowth of bone from the surroundings and does not start at the implant surface. Calcification of the interface is seen as an accumulation of scattered hydroxyapatite crystals in the collagen matrix.

In clinically retrieved implants, the ultra structure of the mineralized bone-titanium interface was very similar to that seen in rabbit (Fig 2). In general, a non-mineralized amorphous layer, less than 0.5 μm thick, borders the mineralized bone with an electron dense lamina limitans-like line (50nm thick). Multinuclear cells fill out the sites on the implant surface not covered by bone (Piattelli et al 1996).

Biomechanical tests such as removal torque measurements have commonly been used to evaluate osseointegration. Johansson and Albrektsson (1987) demonstrated an increased resistance to torque forces with time,

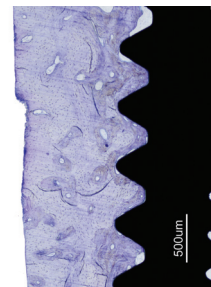


Fig.2. Light micrograph of the bone-titanium interface.

parallel with an increasing degree of bone-implant contact. Sennerby (1991) found a relationship between the amount of compact bone in the interface of the threaded implants and the removal torque when unscrewing the turned implants after 6 weeks, 3 and 6 months. On unscrewing the implant, rupture occurred close to the implant, with no fractures of the bone. This led to the conclusion that the stability of threaded turned titanium implants is due to mechanical interlocking.

Different implant surfaces

It is recognized that the characteristics of the implant surface are critical determinants of successful osseointegration (Albrektsson et al 1981). The original studies on osseointegration were conducted on implants with turned surfaces. Enhanced implant surface technology was introduced to improve the predictability, rate and degree of osseointegration. The aim was to attain a greater surface area for bone attachment. The implant surface was modified through additive or subtractive techniques. Surface roughness was demonstrated to be effective in enhancing the biomechanical properties of bone-anchored implants: it was shown that the amount of bone in contact with an implant surface is greater around moderately rougher than around smooth implant surfaces and that moderately rough surface implants have stronger bone-to-implant bonds.

A number of studies have compared implants with different surfaces in terms of the hard tissue-to-implant interface. Carlsson et al (1986) compared removal torques and bone-to-implant contact, measured by histomorphometry, around polished and rough commercially-pure titanium implant screws six weeks after insertion in the condyles of rabbit tibiae and femurs. The study demonstrated a positive correlation between increasing roughness of the implant surface and the extent of the bone-implant interface. The data demonstrated that the rough-surfaced implants had significantly higher removal torque than had the smooth-surfaced implants. In a direct comparison of surface characteristics of similarly-shaped implants, rougher implant surface had greater bone-to-implant contact than smoother surfaces (Buser et al 1991). The titanium-plasma-sprayed (TPS) surface is obtained by thermal spraying of titanium onto the titanium implant. The sandblasted, large grit, acid-etched (SLA) surface is produced by a large grit sand-blasting process with corundum particles, which produces macro-roughness of the titanium surface. The sand-blasting is followed by immersion for several minutes in a strong acid-etching bath of HCl/H₂SO₄ at elevated temperature. This produces 2-4 μm micropits superimposed on the rough-blasted surface. The surface is not microporous thereby allegedly preventing harbouring of trapped bacteria. TPS surfaces is rougher than SLA surfaces.

A study by Wennerberg and Albrektsson (1995) evaluated screws blasted with 25 μm particles of titanium and 75 μm particles of aluminium oxide, respectively. These implants demonstrated higher removal torque and interfacial bone contact than turned titanium implants. Ellingsen (1998) found that compared to titanium controls, fluoride treated titanium implants improved the bone response 3-4 fold in rabbit ulnae after four and eight weeks of healing,

measured by a push out technique. In a study of implants, Suzuki et al (1997) showed in rabbit femur that the increased bone volume of moderately rough-surfaced titanium implants is due to less remodelling activity during the early stage after implantation compared with the smooth-surfaced implants. To allow comparison of the results of surface roughness studies in different implant systems it is important that a standard procedure is adopted (Wennerberg and Albrektsson 2000). In summary, the effects of the implant surface on bone healing have been extensively investigated, both *in vitro* and *in vivo*. Based on experimental results, clinical studies were conducted to evaluate the effect of loading SLA implants after a reduced healing period of only 6 weeks. After follow-up of 5 years the success rate was shown to be greater than 99 % (Bornstein et al 2005).

Besides surface topography, surface chemistry is another key factor for bone-implant apposition, since it influences the degree of contact with the physiologic environment. For example, increased wettability enhances interaction between the implant surface and the biological environment (Kilpadi and Lemons 1994). Recently, a chemically modified titanium surface was shown to achieve stronger bone anchorage at the early stages of bone healing, thereby presumably allowing earlier loading without impairing implant survival (Ferguson et al 2006). A modified sand-blasted acid etched (SLActive) titanium surface was produced: after sand-blasting and acid-etching, the implants were rinsed in NaCl under N₂ protection and stored in an isotonic NaCl solution to preserve the surface conditions until implant placement. It was shown that the modified SLActive surface enhanced bone apposition during the early stages of bone regeneration compared to SLA controls. The underlying mechanism may be the establishment of stable contact between the surface and the early blood clot and fibrin network. This facilitates migration of pre-cursor cells, differentiation and finally bone formation at the surface (Buser et al 2004; Cooper et al 2005).

Anodic oxidation resulted in increased thickness of the oxide layer and the formation of a porous surface structure (Schüpbach et al 2005). Evaluation of removal torque values showed that the characteristics of the oxidized implant influenced the bone tissue response. Two mechanisms were proposed for osseointegration: mechanical interlocking through bone growth into pores/other surface irregularities and biomechanical bonding (Sul et al 2002). A histologic study in human jawbone demonstrated significantly higher bone response for anodic oxidized titanium implants than for implants with a turned surface (Ivanoff et al 2003). In another study (Sul et al 2005), two groups of different titanium oxidized implants were inserted in rabbit bone. One of the implant groups had magnesium ions incorporated in the surfaces. After six weeks of follow-up, this group showed a significantly higher mean peak of removal torque than the group of oxidized implants. In conclusion, in the great majority of published studies, moderately rough surfaces have demonstrated stronger bone responses than minimally rough, machined surfaces.

Implant design

With respect to initial stability, screw-shaped implants are superior to cylindrical ones (Carlsson et al 1988, Gotfredsen 1992). Threads have advantages as they engage the implant site during insertion, depending on press-fit as well as on an axial compression of the bone between the threads and the coronal part of the implant. Most implants used today are self-tapping.

An implant with double threads was developed to allegedly enable faster installation (Mark IV Nobel Biocare). The implant body is slightly tapered for better engagement of the cortical layer. The idea is to enhance primary stability in poor bone quality by inserting a tapered implant into a standard parallel-sided hole. This implant was compared to Brånemark standard implants in a multi-center study by Åstrand et al (2003). No differences between the two implant designs could be shown. O'Sullivan et al (2000) investigated in five different designs of dental implants in a human cadaver study. All implants were placed in the maxillary bone less than 48 hours post-mortem with most being tested within 30 hours. The Mark IV implants appeared to maintain a high primary stability even in bone quality 4. However, this was not verified in a clinical multi center study by Friberg et al (2003), comparing a prototype of the Mark IV implant and standard Brånemark implants in jaw regions of Type 4 bone.

In another study by O'Sullivan et al (2004) primary and secondary stability were evaluated in an animal study, comparing a dental implant with 1° of taper and a standard Brånemark implant. For placement of the implants the tapered implant needed a significantly higher insertion torque and a higher value was recorded on resonance frequency analysis. It was concluded that implants with 1° of taper showed enhanced primary stability. In a three-dimensional finite-element model of a posterior mandible with two different bone densities Petrie et al (2005) studied the crestal strain gradient for implants of varying diameter, length and taper. To minimize peri-implant strain in the crestal alveolar bone, a wide and relatively long and untapered design was most favourable. Narrow, short implants with taper in the crestal region should be avoided, especially in low-density bone.

It is proposed that microthreads on the coronal portion at the implant neck help to stabilize the marginal bone (Hansson 1999). A 3-year follow-up by Lee et al (2007) evaluated the effect of microthread on the maintenance of marginal bone level. The results indicated that microthreads might have an effect in maintaining the marginal height against loading.

CLINICAL ASPECTS OF THE SURGICAL PROCEDURE

There are several factors determining the achievement of osseointegration (Albrektsson 1981). These include:

- Biocompatibility of the implant material
- Implant design
- Implant surface conditions
- The host bed
- Surgical technique
- Implant loading conditions

In the original Brånemark technique, an implant with a turned machined surface was submerged into the jaw-bone and depending on bone density, allowed to heal for 3 to 6 months before loading. Maxillary implants required a longer healing period than mandibular implants. The two-stage procedure was considered necessary to ensure implant stability, by minimizing the risk of infection and allowing undisturbed bone formation and remodelling, prior to loading, since implants are more stable after bone formation and remodelling. It was believed that premature loading could lead to fibrous tissue encapsulation (Albrektsson et al 1981). The recommended healing period of 3 – 6 months was empirical and not supported by evidence-based studies.

In a collaborative project between the University of Bern, Switzerland, and the Institute Straumann AG, a one-stage approach was developed, using an implant with a rough surface and a non-submerged technique (Schroeder et al 1976, 1981). This technique allowed the implants to be loaded after 12 weeks of healing, in either the maxilla or the mandible. Provided the clinical protocol was closely adhered to, the one-stage approach was found to achieve complication-free tissue integration with a high predictability. Successful use of one-stage (non-submerged) procedures with healing periods of 3-6 months was documented by Buser et al (1991). Two studies of non-submerged implants in the maxillae of monkeys showed the development of a circular ligament of densely packed collagen fibres and inflammatory cells running parallel around the implant (Ruggeri et al 1992). The two-stage procedure as well as the one-stage technique relied on healed jaw-bone and implants were not placed in extraction sockets.

Studies in monkeys (Gotfredsen 1990) and dogs (Ericsson 1996) found no difference in bone response between submerged and non-submerged implants. These results were confirmed by Ericsson et al (1994, 1997) in a split-jaw clinical study of mandibular Brånemark implants. Furthermore, a study by Becker et al (2000) comparing one- and two-stage titanium screw-shaped implants with one-stage plasma-sprayed solid-screw implants showed similar cumulative survival rates, but more bone resorption of the implants with plasma sprayed surface.

The short term results (one year follow-up) of a study by Heydenrijk et al (2002) indicated that two-part implants inserted in a one-stage procedure were as predictable as those inserted in a two-stage procedure. Today it is evident that an early connection between the oral cavity and the jaw bone during healing need not jeopardize osseointegration .

Implant stability

Successful clinical outcomes depend on the establishment and maintenance of implant stability. The degree of primary implant stability after installation depends on factors related to the implant, bone and surgical technique. The biomechanical properties of bone are determined by the ratio of cortical and trabecular bone at the implant site. Cortical bone is more rigid than trabecular bone and offers better support for an implant. Firm primary stability reduces the risk of micromotion and negative responses such as formation of fibrous scar tissue at the bone-implant interface.

Implant stability is also influenced by surgical technique, such as the choice of drill diameters, the depth of preparation and whether pretapping is used or not. The implant design, including the shape of the threads, also impacts on primary stability. Early implant failure due to lack of osseointegration was reported to be more frequent in jaw bone of low density (Sennerby and Roos 1998) and high failure rates have been reported for implants placed in soft bone (Engquist et al 1988, Jaffin & Berman 1991 and Jemt 1993).

Radiographs yield information about anatomical characteristics and offer the potential to assess the composition of compact and cancellous bone. Brånemark (1985) did not recommend radiographs immediately after implant placement due to his fear of potential radiographic side-effects. Lekholm and Zarb (1985) proposed a jaw bone classification by rating the bone quality from 1 to 4, depending on the amount of compact and cancellous bone present. Class I bone is predominantly cortical as in the mandibular anterior region, while Class 4 bone is almost all trabecular, as often found in the maxillary posterior region. Lekholm and Zarb stressed it is not always possible to determine bone quality from radiographic assessment alone, as the cortical layer may obscure the quality of the internal bone. They suggested that it is first during explorative drilling in implant sites that the true bone quality of the jaw can be determined. However, this assessment is subjective and based on the surgeon's personal experience. The accuracy of this classification was questioned in a study by Lindh et al (1996) as the interobserver and the intraobserver evaluations varied greatly. These authors recommended a new classification with reference images for assessing the trabecular pattern in periapical radiographs before implant treatment. Despite the shortcomings, the Lekholm & Zarb index is probably the most commonly used system for grading of bone quality.

Assessment of implant stability

A method was described by Johansson and Strid (1994) whereby torque is registered by an electric current during low-speed tapping. This registration reflected the bone quality, expressed as the energy needed to cut out a specific amount of bone material with the tool. The measurement torque consisted of two parts, the true cutting resistance and the friction. Special computer software was used. A specially prepared motor hand piece was developed to eliminate differences in hand pressure on the screw tap as well as deviations of the screw tap from the axis of the prepared bone site, which could influence the measurement. According to Friberg et al (1995) this was found to be a reliable technique for identifying variations in bone density. In another study Friberg et al (1999a) reported a statistically significant difference in cutting torque values of maxilla and mandible and also a tendency toward declining values from anterior to posterior regions in the maxilla. Furthermore, significant correlations were found between values of cutting torque and bone quality. One disadvantage with the technique is that the measurement of the bone density is determined first during low-speed threading of implant placement.

Periotest is a non-invasive, electronic device which provides a measurement of the reaction of the periodontium to a defined impact load. Percussion is applied by an electronically controlled tapping head and a value is calculated and displayed as a Periotest value (PTV). The reading represents an objective indication of the extent of periodontal bone loss. Tricio et al (1995) showed significant correlations between PTV and insertion torque as well as bone density. In a comparison of different implant diameters, lower PTV values were associated with wider implants (Aparicio and Orozco 1998). The Periotest device is operator sensitive and its clinical value has been questioned (Meredith et al 1998). In biomechanical tests by Ivanoff et al (1997) the peak torque required to loosen an implant was assessed. A statistically significant increase of removal torque was shown with increasing implant diameter.

Resonance frequency analysis (RFA) is a non-invasive diagnostic technique developed by Meredith and coworkers (1994, 1996, 1997). Bone formation around an implant is studied by measuring the resonance frequency of a small transducer attached to an implant. The first and second generation transducers had their own fundamental resonance frequency. This has been corrected in the Osstell system, which comprises transducers calibrated by the manufacturer. The measurement is presented in a new unit, the Implant Stability Quotient (ISQ). The transducer comprises a modified cantilever beam to which two piezoceramic elements are attached. The beam vibrates by exciting one of the piezoelectric elements with a sinusoidal signal of increasing frequencies from 5 to 15 kHz by means of a frequency response analyzer and a computer.

Friberg et al (1999b) evaluated the correlation between cutting torque measurements and resonance frequency analyses in Brånemark implants placed in edentulous maxillae. Measurements were taken at implant placement, at abutment connection and after one year of loading. The values increased with time, irrespective of bone quality and primary stability.

On the other hand, in a study comparing maxillary and mandibular implants from placement up to 6 months of loading, implants with low primary stability showed a marked increase while implants with very high primary stability showed no changes or even decreased values (Sennerby et al 2000).

The RFA technique has been applied in a number of in vitro and in vivo studies to assess implant healing in various situations. In an animal study using RFA measurements, the use of a barrier membrane at exposed implant threads did not contribute to implant stability and the stability of implants placed 3–4 months after Le Fort I osteotomy with interpositional cortico-cancellous bone grafts seemed to increase with time (Rasmusson et al 1998). Hallman et al (2005) showed that the stability of dental implants placed in grafted maxillas and measured with RFA after three years of functional loading was similar to the stability of implants placed in non-grafted maxillary bone. Low primary stability, measured with RFA, indicates a risk for implant failure in the grafted maxilla. Sjöström et al (2007) therefore proposed that the ISQ value at the time of placement can probably serve as an indicator of level of risk for implant failure. ISQ values of 50–80 after implant placement are considered to reflect good primary stability: the lower values are typical of softer bone *e.g.* the maxilla and the higher values typical for the mandible. A value below 45 indicates poor prognosis. The length of the implant protruding above the marginal bone level has a pronounced influence on the measurement. This fact needs to be taken into account when comparing ISQ values and different implant systems. During bone healing a significant increase in ISQ was observed, related to the increase in rigidity. This is of practical relevance when comparing ISQ values of the same implant over time, in cases where there is doubt as to whether or not the implant should be loaded RFA may help in the decision the most appropriate time-to-load: immediate, early or delayed.

CLINICAL ASPECTS OF IMMEDIATE / EARLY LOADING

Definitions

A healing period of 3 to 6 months before loading was originally considered essential. Long-term follow-ups of implants with turned, machined surfaces, using a submerged technique and delayed loading protocols, showed survival rates around 95 % in all indications over a 5-year period of time (Esposito et al 1998, Berglundh et al 2002). However, over the last 10 years the conventional treatment protocol has been questioned and there are now numerous studies reporting the outcomes of different loading protocols.

Terminology for the timing of implant loading

The terminology for different loading protocols remains confusing, despite several attempts to reach consensus on definitions. Aparicio et al (2003) reported from a conference on immediate and early loading in Spain at which the following definitions were suggested:

Immediate loading: The prosthesis is attached to the implants on the same day as the implant surgery

Early loading: The prosthesis is attached as a separate, later procedure, but earlier than the conventional healing period of 3 to 6 months; time of loading should be stated in days/weeks

Delayed loading: The prosthesis is attached as a second procedure after a conventional healing period of 3 to 6 months.

Terminology for implant loading

Occlusal loading: The crown/bridge is in contact with the opposing dentition in centric occlusion

Nonocclusal loading: The crown/bridge is not in contact in centric occlusion with the opposing dentition in natural jaw positions

In 2004 at an ITI Consensus Conference in Gstaad the following terminology was proposed for immediate and early loading (Cochran et al 2004).

Immediate restoration: A restoration inserted within 48 hours of implant placement but not in occlusion with the opposing dentition

Immediate loading: A restoration placed in occlusion with the opposing dentition within 48 hours of implant placement

Conventional loading: The prosthesis is attached in a second procedure after a healing period of 3 to 6 months

Early loading: A restoration in contact with the opposing dentition and placed at least 48 hours after implant placement but not later than 3 months afterward

Delayed loading: The prosthesis is attached in a second procedure that takes place some time later than the conventional healing period of 3 to 6 months.

The outcome of short loading times is dependent on

- The amount of primary bone contact
- The quality of bone at the implant site
- The rapidity of bone formation around the implant
- The experience of the operator

The ultimate loading protocol would be the immediate one, especially from the dentist's perspective. Immediate loading was first described for the completely edentulous mandible. In the anterior mandible, where bone is typically very dense, there is extensive primary bone contact, giving the implant immediate stability. Combined with a rigid connection of the implants, this provides for adequate immediate stability of the implants. In this setting, the early loading protocol can be very successful, but the quality of the bone is a major determinant. Where the quality of bone is less than ideal, the ability to stimulate bone formation is important. Under these conditions, early loading is more likely to be successful than immediate loading (Ericsson et al 2000a).

Foreshortened loading protocols are perceived to be operator sensitive. Clinical studies are generally conducted under controlled conditions, with well-defined inclusion criteria. There are few clinical studies evaluating the outcome of implants with reduced healing time under routine general practice conditions. In a field study by Cochran et al (2007) 86 investigators treated 509 patients with 990 implants. The implants were predominantly placed in the mandible (73%) and loaded within 63 days. The cumulative survival rate was 99 % at 3 years and 97 % at 5 years.

Evidence of immediate and early loading of dental implants

The effect of immediate loading is not clearly understood as it relates to the timeline of osseointegration. It is clear however, that under functional loading, the processes of osseous remodelling and osseointegration occur simultaneously. The interaction of these biological and mechanical forces would seem to be critical to the successful integration of the implant. Initial stability and continued stability during the healing phase are necessary for osseointegration and splinting together of implants improves the likelihood of success.

Cameron et al (1973) found that micromotion amounting to about 200 μ m at the bone-to-implant interface results in invasion by fibrous tissue which prevents bone-to-implant contact. Brunski et al (1999) proposed that micromotion of about 100 μ m is tolerated for turned, machined surfaces. According to Søballe et al (1993) the threshold level for porous hydroxy-coated implants was 50 - 150 μ m. If micromovement at the bone-implant interface is minimal during osseointegration, immediate loading of implants could become a successful intervention, with a resulting gradual reduction of the healing period.

Immediate loading including occlusal contact with the opposing teeth was reported as early as 1979 in a case presentation by Ledermann et al (1979) showing that immediate loading of TPS implants in the mandible could support overdentures. The first report on immediate loading of Brånemark implants with fixed prostheses was presented by Schnitman et al (1990). There are now numerous published clinical studies of the outcomes of different loading protocols. However, the limited number of subjects in each trial is usually too small to allow extrapolation of conclusions, due to lack of statistical power.

The Cochrane Oral Health Group aims to produce systematic reviews which primarily include randomised controlled trials (RCTs). In one such review, the clinical performance of implants loaded at different times was evaluated 6 months to 1 year after loading (Esposito et al 2007). The main outcome assessed in these type of studies is the success of the prosthesis; implant loss may not necessarily jeopardize prosthesis success. Eleven RCTs were included: six trials compared immediate versus conventional loading, three trials early versus conventional loading and two trials immediate versus early loading. In total 790 implants were originally placed in 300 patients. Mandibular implants predominated; about a third were maxillary implants. Sixty-four of the maxillary implants were loaded immediately, 132 were loaded early and 90 were conventionally loaded. The inclusion criteria were very strict and only patients known to be ideal candidates for implant treatment were recruited. In addition, the operators were highly experienced. When the different loading regimens were compared, no statistical differences emerged with respect to prosthesis success, implant success or marginal bone levels. The number of trials and patients included might be insufficient to draw definitive conclusions. It was concluded that while immediate or early loading can be successful in selected patients, not all clinicians may achieve optimal results with immediate loading.

In the Cochrane review several studies were excluded because they failed to meet all the inclusion criteria. However, these studies may offer relevant clinical information. In general, the success rate was very high (Roccuzzo et al 2001; Testori et al 2003; Salvi et al 2004; Lindeboom et al 2006; Turkyilmaz et al 2006a; Cannizzaro et al 2007). Most of these studies used techniques to increase torque values at implant placement and it can be concluded that a high degree of primary stability at implant insertion is a key factor for successful immediate or early loading. Another aspect to be considered is whether the immediate loading was non-occlusal or occlusal, i.e. a temporary restoration is placed on the implant but kept out of contact with the opposite dentition, or the restoration is in full occlusal contact with the opposite dentition, a true immediate loading procedure.

Randomized studies of shortened loading protocols in the maxilla

To date there are no published randomized controlled trials comparing immediate and conventional loading of maxillary implants. However, in a randomized study by Hall et al (2007) 14 immediately (4 hours) restored single tooth implants were compared with 14 two-stage implants restored 26 weeks after surgery and followed for one year. The implants were surface modified tapered implants. One control implant failed at abutment connection. There were no statistically significant differences between the groups with regard to failure or marginal bone loss.

Immediate loading in the edentulous maxilla

Bergkvist et al (2005) studied the survival rate of immediately loaded SLA implants in 28 patients treated for maxillary edentulism. A fixed provisional prosthesis was provided within 24 hours of implantation. After a mean interval of 15 weeks, the permanent fixed prosthesis was inserted. Of 168 implants, three were lost during the healing period. Bergkvist et al emphasised the importance of splinting the implants immediately after placement. Degidi et al (2005) followed 43 patients with a total of 388 implants immediately loaded with cross-arch acrylic provisional restorations. At the 5 year follow-up the survival rate was 98 %. All failures had occurred within 6 months of loading. The authors also reported a higher risk of failure associated with implants of wider diameter. Balshi et al (2005) evaluated immediate loading of Brånemark System implants in 55 patients treated for maxillary edentulism; a mean number of 10 implants was placed in each patient. After 5 years follow-up the survival rate was 98 %. Van Steenberghe et al (2004) used flapless surgery in a multi-centre study in which 24 patients were followed for 1 year. The implants were immediately loaded using computer-assisted techniques based on a CT scan. A survival rate of 100 % was achieved.

A cohort study by Östman et al (2006) analysed immediately loaded implants in the edentulous maxilla. One hundred and twenty-six immediately loaded implants were compared to 120 submerged implants treated with a conventional loading protocol. Resonance Frequency Analysis showed a tendency toward steeper increase and higher secondary stability for the immediately loaded implants than for those with a 6-month healing period. In addition, a tendency towards less marginal bone resorption was observed.

Early loading in the edentulous maxilla

Olsson et al (2003) treated 10 patients with provisional fixed full-arch bridges 1 to 9 days after implant placement. One patient lost all implants after 10 weeks of loading, due to an infection. Nordin et al (2007) investigated the outcome of early loading of implants passively fitted with abutment-free permanently fixed full maxillary dentures. In all, 116 implants with SLA surfaces were inserted. Sixty-six per cent of the implants were inserted into fresh extraction sockets. All were loaded within 14 days. After 2-3 years of follow-up, two implants were lost due to framework fracture. Early functional loading of SLA implants passively fitted with a permanent fixed complete denture was found to be a reliable treatment. However, the authors emphasised the importance of early splinting of the implants.

Immediate loading in the partially edentulous maxilla

Few reports can be found in the literature regarding immediate loading in the partially edentulous maxilla. It is difficult to draw conclusions from studies with short follow-up times and grouping of different types of prostheses. Almost all the available literature relates to

immediate restoration rather than immediate loading. In the posterior region of the jaws the implants are often placed in a straight line, which is considered unfavourable, especially in view of the heavier biting forces exerted in the posterior region compared to the anterior region. In addition the bone in the maxillary molar and premolar regions is usually softer than in the anterior region.

Calandriello et al (2003) evaluated immediate loading of Brånemark System implants. Of a total of 50 implants, 16 were placed in the partially edentulous maxilla and supported by temporary partial dentures in light occlusion on the same day as surgery was performed. No cantilevers were used. After 5 months the final restorations were made. The overall survival rate in the study was 98 % and none of the implants supporting a partial denture was lost.

In a study by Drago and Lazzara (2004) 93 Osseotite implants were placed in 38 partially edentulous patients, with immediate provisional restoration. There is no information as to whether these were maxillary or mandibular implants. The survival rate after 18 months was 97.4 %.

Luongo et al (2005) presented a multicenter one-year follow up study of an immediate/early loading protocol in the posterior maxilla and mandible. Inclusion in the study required that 2 implants should support either 2 splinted crowns or a 3 unit bridge. In total, eighty-two ITI sandblasted, acid-etched (SLA) implants in 40 patients were loaded between 0 and 11 days after implant placement. A temporary prosthesis in full occlusion was fitted on the same day as surgery in 25 % of the patients. However, only 10 out of the eighty-two implants were placed in the maxilla. At 1 year, the overall survival rate of the implants was 98.8%.

Östman et al (2007) and Albrektsson et al (2007) evaluated respectively 115 and 492 immediately loaded one-piece implants with the TiUnite surface and tapered design (Nobel Direct® and Nobel Perfect®). Forty-eight patients provided with 115 implants showed a mean marginal bone loss of 2.1 mm (SD1.3) after 1 year in function. Fifty-eight (11.8%) out of 492 immediately loaded implants were lost after an average follow-up time of 1 year. The reason for the poor results may be attributed to the particular concept with the combined use of a one-piece implant, flap-less surgery, *in situ* high-speed grinding, direct loading and a rough oxidized surface in contact with the mucosa.

Immediate loading of single implants in the maxilla

Immediate loading of single implants in the aesthetic zone is a strong challenge to the clinician. While immediate loading of single-tooth implants has rarely been reported, numerous authors have evaluated the survival and success rates of immediately restored implants. Kan et al (2003) followed 35 cases in which a tooth was extracted, an implant immediately inserted and restored with a temporary crown. The permanent crown was provided after 5 months. The implants used were hydroxyapatite-coated and tapered implants (Replace, Nobel Biocare). All 35 implants were stable after 1 year of function.

Ericsson and coworkers (2000b) performed a prospective study on single tooth replacements with artificial crowns retained to implants installed according to an immediate loading protocol, compared to the conventional 2-stage concept. The immediate loading group comprised 14 implants, of which 11 were maxillary. The 2-stage control group comprised 8 implants, of which 7 were maxillary. For inclusion in the study the patients were required to be non-smokers and have sufficient bone to harvest a 13 mm implant of regular platform, *i.e.* 3.75 mm. In the immediately loaded group, a temporary crown was connected to the implant within 24 h of implant installation. Six months later this crown was replaced with a permanent one. In the 2 stage group the surgical and prosthetic treatments followed the standard protocol. Of the 11 maxillary implants in the immediately loaded group, 2 were lost up to 5 months in function. No implants were lost in the 2-stage group. The analyses of the radiographs of both groups showed a mean change of bone support of about 0.1 mm at 12-months follow-up.

Another prospective clinical study by Hui and et al (2001) comprised 24 patients who underwent single-tooth implant replacement of maxillary anterior teeth according to an immediate provisional protocol. Thirteen of the 24 patients had immediate implant placement after tooth extraction. Within the follow-up period of 1-15 months, all fixtures in the 24 patients were stable. Norton (2004) evaluated 28 Astra Tech ST implants in 25 patients. After abutment connection immediately after surgery, a temporary autopolymerized acrylic resin crown was fabricated over the coping. The temporary crowns were carefully contoured and polished to achieve proper emergence profiles. Permanent restorations were provided after a mean interval of 4.5 months. One implant was lost at the 1-month review, yielding a survival rate of 96.4 %.

Rocci and co-workers (2003) evaluated 97 Brånemark System Mk IV implants placed with a flap-less technique and immediate loading. Twenty-seven implants were single tooth replacements. Nine implants in 8 patients failed during the first 8 weeks of loading. Five of the 8 patients lost single-tooth implants, of which two had been inserted into fresh extraction sites. The survival rate for implants in single restorations was 81% after 3 years of prosthetic loading. The marginal bone resorption was on average 1.0 mm during the first year of loading, 0.4 mm during the second year and 0.1 mm during the third year.

Lorenzoni et al (2003) evaluated the clinical outcomes of immediately loaded frialit-2 Synchro implants 12 months after placement in the maxillary incisor region. The implants were inserted with an increasing torque up to 45 Ncm. All implants were immediately restored with unsplinted acrylic resin provisional crowns and the patients provided with occlusal splints. No implant failed up to 12 months after insertion, resulting in a 100% survival rate. The authors reported that coronal bone resorption assessed on radiographs at 6 and 12 months was even less than that for implants placed in a standard two-stage procedure.

Glauser et al (2005) reported a study of 20 patients who received single-tooth Brånemark TiUnite implants, predominantly placed in soft bone. The fixed prosthetic reconstructions were connected on the day of implant insertion. Three maxillary implants in one patient were removed at the 8-week follow-up. There was no further implant loss, giving a cumulative implant success rate of 97.1 % after 4 years in function.

Early loading in the partially edentulous maxilla

Cochran et al (2002) presented a prospective, multicenter study on 383 SLA implants, 46 of which were maxillary implants. The mean healing time was 49 days for implants in Class 1-3 bone and 105 days in Class 4 bone. The survival rate after 1 year follow-up was 99.1%. In a multicenter field study by Cochran and coworkers (2007) a total of 590 patients and 990 implants met the inclusion criteria, including placement of an abutment and provisional restoration within 63 days of surgical placement. The purpose of the study was to determine whether the reduced healing times could be achieved under more realistic practice conditions where patient selection was not as restrictive and technique and monitoring were controlled less stringently. Twenty-seven percent were maxillary implants. The cumulative survival rate for all implants was 99.26 at 5 years. Data from this prospective, multicenter study demonstrated that implants with the SLA surface can be restored under private-practice conditions within 6 to 8 weeks, with predictable results.

Roccuzzo and Wilson (2002) evaluated the efficacy of a modified surgical protocol followed by loading at 6 weeks. The material comprised 36 SLA implants placed in the posterior maxilla. Drilling was limited to a minimum and most of the site preparation was done with osteotomes. Abutment connection was undertaken after 43 days and the implants were loaded with a temporary bridge in infra-occlusion. After a further 6 weeks the permanent prostheses were inserted. One implant failed, giving a survival rate of 97.2% after one year of loading.

Nordin and coworkers (2004) presented a prospective study with in total 54 patients treated with an early loading protocol. Fifty-nine implants with a sandblasted acid-etched surface were used to treat partial maxillary edentulism in 19 patients. The fixed prostheses were inserted after a mean interval of 9 days. One implant was lost during the 1-year follow-up. Marginal bone loss ranged from 0 to 3.5 mm.

Vanden Bogaerde et al (2004) included 31 consecutive patients in a multicenter study. A total of 111 implants with a TiUnite surface were inserted, 69 of which were inserted in partially edentulous maxillae. Bruxism and uncontrolled periodontal disease were exclusion criteria. Temporary prostheses were generally provided within 9 days but not later than 16 days after implant placement. The occlusion was adjusted to light centric contacts, avoiding any lateral or protrusive contacts. Permanently fixed prostheses were inserted after 3 to 6 months. The patients were observed for 18 months. One maxillary implant failed. All prostheses remained stable and free of complications. The prosthesis survival was 100%. The radiographs were readable for 81% of the implants at baseline, 84% at placement of the final prosthesis, and 88% at 1 year after placement of the final prostheses. The marginal bone resorption from readable x-rays was 0.8 mm.

Achilli and coworkers (2007) investigated whether there is a difference between immediate and early loading in premolar and molar areas. 120 tapered implants (Replace Select Tapered) were placed in the posterior regions of the jaws. Thirty-two implants were

placed in maxillary first or second molar regions. Each patient received a temporary restoration within 24 hours. The prostheses had flat occlusal surfaces to reduce lateral contacts. All patients were followed for 1 year. No implant failure occurred.

Bornstein et al (2007) reported a 3 year follow-up of SLA implants in the aesthetic zone. While immediate loading of single-tooth implants has rarely been reported, outcomes of 151 posterior wide-body implants with sandblasted acid-etched surfaces. The implants were loaded with cemented crowns or fixed partial dentures after a healing period of 6 to 8 weeks, or 10 to 14 weeks; the latter when bone augmentation was performed. Forty-four were maxillary implants. During healing, one maxillary implant had to be removed due to a peri-implant infection. The average crestal bone level changed less than 0.5 mm for 129 implants.

Early loading of single implants in the maxilla

A study by Andersen and coworkers (2002) evaluated the success rate of single tooth ITI implants with solid plasma-sprayed surface (TPS) in the anterior maxilla. Eight implants were loaded after one week with a temporary acrylic resin restoration which was replaced after six months with a permanent restoration. No implants were lost during the 5-year observation period.

Nineteen patients were treated with 26 Brånemark System Mark III TiUnite maxillary implants, which were restored with single crowns 6 weeks later. Both implant and prosthesis success rates were 94% after 3 years. The average marginal bone loss was 0.97 mm (Turkyilmaz 2006b). Long-term follow-up of Astra Tech maxillary anterior implants using an early functional loading protocol was reported by Cooper et al (2007). The implants were restored 3 weeks after one-stage surgery. Three of 54 implants failed within the first year. Peri-implant bone levels were stable for the 3-year period following implant placement. No abutment screw loosening or fracture occurred.

Summary of viewpoints on rapid loading

Although there are numerous published reports of the clinical outcomes of various immediate/early loading protocols in both jaws, immediate/early loading of maxillary implant-supported prostheses is less extensively reported. Moreover, few randomized clinical trials could be found in the literature.

AIMS

General aim:

To test the hypothesis that immediate/early loading of dental implants in the maxilla results in the same clinical outcomes as when using delayed loading.

Specific aims:

1. To compare the clinical treatment outcomes of early and delayed loading of dental implants with a moderately roughened surface (sandblasted, acid-etched SLA) for support of a fixed bridge in the totally edentulous maxilla after one year (**Paper I**).
2. To compare the clinical and technical treatment outcomes of early and delayed loading of dental implants (SLA) for support of a fixed bridge in the totally edentulous maxilla after three years (**Paper II**).
3. To compare the clinical and technical treatment outcomes of early and delayed loading of dental implants (SLA) for support of a fixed bridge in the totally edentulous maxilla after five years (**Paper III**).
4. To evaluate the clinical treatment outcomes and development of implant stability of moderately rough (oxidized) implants when subjected to immediate or early loading in the partially edentulous maxilla to support a partial bridge or a single tooth replacement during one year (**Paper IV**).
5. To investigate the relation between implant stability and marginal bone loss measurements after three and five years of function in the maxilla (**Paper V**).

MATERIAL AND METHODS

Papers I, II and III

The subjects comprised 24 patients (16 females and 8 males, mean age 64 years) with completely edentulous maxillae. Each patient underwent placement of 5 or 6 dental implants with sandblasted, large-grit, acid-etched (SLA) surfaces, (Esthetic Plus, Straumann Dental Implant System, Institute AG, Basel, Switzerland). The follow-up time was five years.

The patients were selected from consecutive referrals to the Department of Oral and Maxillofacial Surgery, County Hospital, Falun, Sweden and the Department of Prosthodontics, Specialist Centre for Oral Rehabilitation, Falun, Sweden between April 1999 and September 2000. An initial evaluation was conducted to determine whether a patient met the study inclusion criteria and to exclude patients with systemic and/or local contraindications. The evaluation included a clinical examination, taken an appropriate medical history and details of any medication.

Inclusion criteria

- Totally edentulous maxilla
- The expectation of good occlusion
- Bone quality and quantity to support 5 or 6 implants

Exclusion criteria (systemic and local)

- General health conditions not permitting implant surgery
- Smoking more than 10 cigarettes per day
- Unhealed extraction sites
- The use of GBR procedures at implant sites

Ethic approval and Randomization procedure

The study protocol was approved by the research ethics committee at County Hospital, Falun, Sweden in December 1998. Informed consent was obtained from all patients. A randomisation schedule was prepared by the sponsor and kept in sealed, consecutively numbered envelopes (1-24). After the patient had signed the informed consent, the envelopes were opened serially. Thus, neither the surgeon nor the patients was aware of which group the patient was going to be allotted to until surgery was performed. The patients were randomly allotted to one of two groups, test or control, in a 2:1 ratio.

Radiographic examination

The radiographic examinations included an orthopantomogram (OPG), a lateral cephalogram and a computerized tomography (CT) for assessment of the intended surgical areas, including any pathologic condition. CT was used to evaluate the width and height of the crestal bone.

Clinical examination

The opposing dentition was assessed, including any abnormal occlusion that the implant-supported prosthesis might encounter. The quality of the mucosa and the intermandibular relationship were also determined. Data of the opposing dentition are presented in Table 1. Impressions were taken of both jaws and a wax bite record was obtained. A mounted diagnostic cast was fabricated and the location of possible implant sites was determined, taken also into account occlusion, articulation and future restoration design. An acrylic stent was fabricated and 5 mm diameter steel ball bearings were affixed to the stent with sticky wax in the desired implant positions. With the stent in position, a panoramic radiograph was taken to evaluate the anatomy of each implant site. If the analysis indicated sufficient space for the implant, the stent was perforated at the site of the steel balls. The steel balls were adjusted when necessary. The location of the perforations was marked on the mucosa at the time for surgery. Preoperative oral hygiene instruction was given.

Surgery

Preoperative oral sedation with Midazolam (Midazolam Alpharma, Stockholm, Sweden) was given to all patients. Antibiotics, penicillin 1g (Kåvepenin, Astra, Södertälje, Sweden), were given one hour preoperatively. For the next seven days following surgery 3 g penicillin was given. In one patient with penicillin-allergy clindamycin 150 mg (Dalacin, Pharmacia, Stockholm, Sweden) was given one hour preoperatively and followed by 150 mg three times daily for 7 days. Surgery was performed under local infiltration using approximately 10 ml 2 % lidocaine with 12.5 µg epinephrine (Xylocaine-Adrenalin, Astra, Södertälje, Sweden). Surgical procedures followed the guidelines in the standard ITI instruction manual related to bone preparation and placement of the implants. Prior to the incision, the acrylic resin stent was used to mark the implant site on the mucosa with a sterile pen.

Implants and abutments

Solid screw implants, 4.1 mm diameter, with a sand-blasted large grit acid-etched (SLA) surface (Esthetic Plus®) and Octa® abutments plus all associated components were supplied by Straumann Institute AG, Basel, Switzerland (Fig 3). The implants were placed

from maxillary left second premolar to the right second premolar. In the test group the Octa[®] abutment were preassembled at factory. The intention was to eliminate insertion forces when connecting the abutment to the implant. In the control group, Esthetic Plus[®] implants were used, except for the first patient in this group who received standard implants. Abutments were placed on the implants at the time of impression taking. In all, 142 implants were placed. All implants were 8 to 12 mm in lengths and 4.1 mm in diameter. The distribution between the groups is shown in Fig 4. The implants were placed without pretapping. In the test group, Octa[®] transfer copings were placed before suturing the flap. In the control group healing cups were attached to the implants. All surgery was undertaken by one surgeon (KF), who also evaluated the bone quality according to the classification described by Lekholm and Zarb. The percentage of test and control implants in each group is shown in Fig 5. The patients were instructed not to brush in the upper jaw and rinsing with chlorhexidine twice daily was prescribed.



Fig. 3. Test and control implants

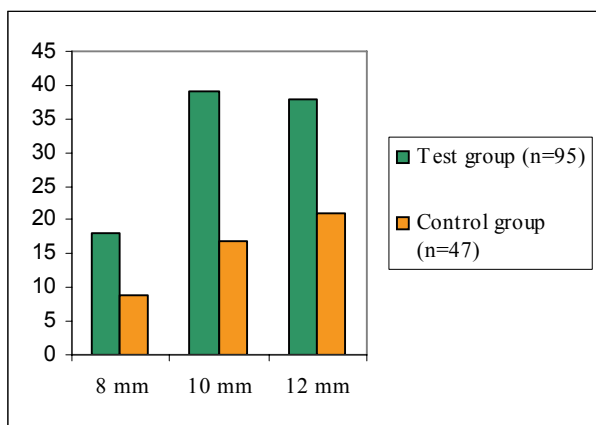


Fig. 4. Distribution of 4.1 diameter implants by length

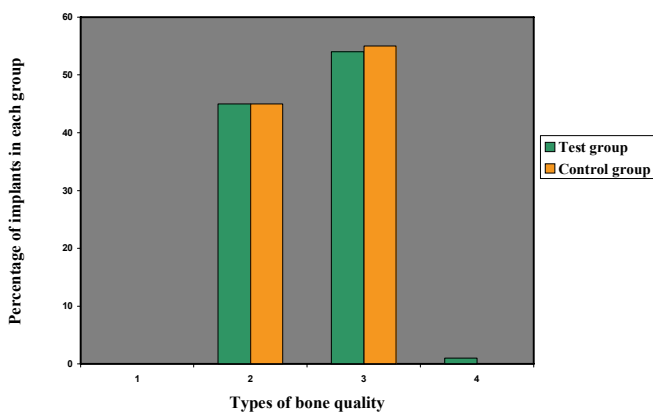


Fig. 5. Percentage of test and control implants in different types of bone quality

Prosthetic procedure

The prosthetic procedure differed between the test and control groups.

- **Test group**

Maxillary and mandibular impressions were taken immediately after surgery. Octa® titanium copings were placed on the abutments in the canine regions and centric relation was recorded using a silicone putty material. Protective caps were placed on the abutments and patients were instructed not to use their maxillary denture. One prosthodontist (TS) carried out all prosthetic procedures and all prostheses were undertaken by the same dental technician. Casts of the maxillary and mandibular arches were fabricated and within a few days, the wax-up was tried in. A rigid titanium framework was then fabricated. The full arch prosthesis was completed with acrylic teeth. After a mean interval of 13 days the prosthesis was attached to the abutments using SCS titanium occlusal screws.

- **Control group**

The sutures were removed approximately nine days after surgery. At the same time the maxillary dentures were relined and delivered to the patient. Octa® abutments were connected to the implants. Impressions were taken and the same procedure was followed as for the test group. The full dentures were inserted after a mean interval of 3.7 months.

Distal extensions of cantilevers of the prostheses for both groups are shown in Table 1.

Table 1. Distal cantilevers of the cross-arch

	Left		Right	
	mm (mean)	range	mm (mean)	range
Test group	7.56	2-13	8.94	3-14
Control group	9.25	5-15	10.0	5-16

CLINICAL EVALUATION

All patients were recalled after one, three and five years for clinical and radiographic evaluations. The results from each follow-up were compared between the two groups and statistically analysed.

Implants

At the one year follow-up the stability of the full-arch prostheses was assessed manually. At the three and five year follow-ups the fixed prostheses were removed to allow access to each individual implant. The mobility of each implant was assessed manually. Resonance frequency measurements were made and the implant stability quotient was recorded according to Meredith and coworkers 1997. The instrument used was the Osstell™ (Instrument Device Integration Diagnostics AB, Gothenburg, Sweden). At the three years follow-up the transducer was attached to the implants and measurements were taken in one direction, perpendicular to the alveolar crest (bucco-lingual). However, at the five years follow-up the implant stability quotient measurements were taken in two directions with the beam perpendicular to the alveolar crest and also parallel to the crest (mesio-distal).

Soft tissue health

Oral hygiene and width of keratinized gingival were assessed. Sulcus bleeding index and plaque index were measured according to the scale shown in Table 2.

Table 2. Sulcus Bleeding and Modified Plaque Index

Sulcus Bleeding Index

- 0= No bleeding
- 1= Isolated bleeding
- 2= Blood forms redline on margin
- 3= Heavy or profuse bleeding

Modified Plaque Index

- 0= No plaque
- 1= Plaque seen on running probe
- 2= Plaque seen by naked eye
- 3= Abundance of soft matter

Technical complications and Maintenance

At every follow-up the full-arch prostheses were checked for any technical problems. Special effort was made to access all patient case records to determine the number and reason for dental appointments during the follow-up period. Resin-related and metal-related adverse events were recorded separately. The number of times the bridge was removed and replaced was counted separately. Special attention was paid to evidence of bruxism. Patients showing signs of bruxism were either provided with either a removable resilient mandibular occlusal splint or a lingual gold bar in the maxillary anterior region.

Marginal bone loss

Periapical radiographs were taken using a standard paralleling technique so that the cervical implant threads were clearly visible. Care was taken to obtain an optimal image of the implant threads and most implants were imaged on at least two films. The distance from the

implant shoulder to the crestal bone was measured with a scale loupe (Peak, Tokyo, Japan). The point measured on the crestal bone was the most coronal bone-to-bone implant contact point. If a vertical bony pocket was observed, the deepest level of the pocket was measured. The known distance between two threads was used for calibration of each radiograph (Fig 6). A mean bone level value was calculated for each implant based on corrected mesial and distal measurements. Marginal bone loss was calculated as the difference in bone level between baseline and follow-ups. All radiographs were evaluated by a specialist in oral radiology: the same radiologist evaluated the radiographs from the one and three year follow-ups and the five year follow-up was evaluated by one of the authors of Paper III (MH).

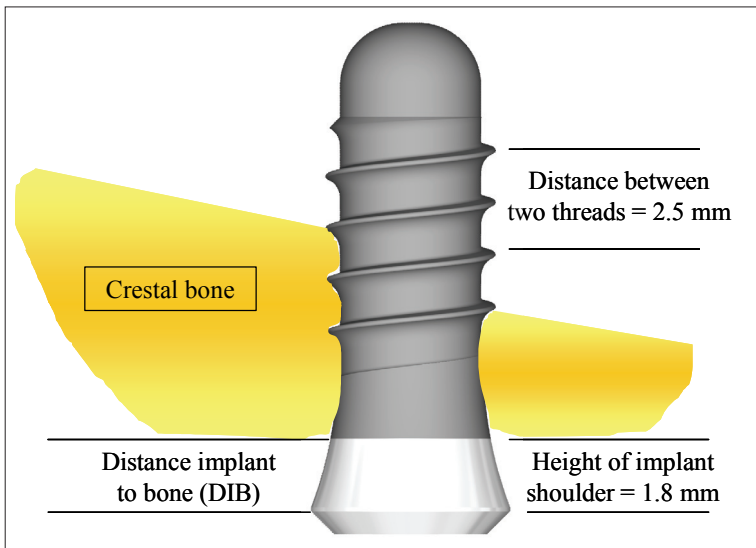


Fig. 6. Schematic picture of implant used in Papers I,II,III and V.

Patient satisfaction and Esthetics

Comfort, ability to chew and ability to taste and general satisfaction were graded by the patient into four different levels,

- **Excellent**
- **Good**
- **Fair**
- **Poor**

The same grading was applied by the prosthodontist to subjectively grade the esthetic outcome.

Paper IV

This study included a total of 32 patients.

- Sixteen patients (9 females and 7 males, mean age 54 years) were treated with one implant for a maxillary single-tooth replacement.
- Another sixteen patients (9 females and 7 males, mean age 65 years) were provided with two or three implants each in their partially edentulous maxillas for support of a fixed partial bridge. In total 37 implants were placed.

The patients were consecutively selected from the waiting list of patients requiring implant treatment for a partially edentulous maxilla at a private dental clinic in Falun, Sweden (MB). Patients were enrolled in the study from June 2003 to May 2005 and followed for one year after loading of the dental implants.

Ethical approval

The protocol for the study was approved by the Ethics Committee of the Faculty of Medicine, Uppsala University, Sweden and informed consent was obtained. The patients were included if general and local health permitted oral surgery and a sufficient amount of bone was available for placement of dental implants.

Implants

Replace Select Tapered implants with anoxidized surface (TiUnite) (Nobel Biocare AB, Gothenburg, Sweden) were used in the study. The sites of the implants in the maxilla are shown in Fig 7a and 7b. The length and diameter of the implants are presented in Table 3.

Table 3. Implant diameters and lengths used in the study.

		SINGLE IMPLANTS (n=16)	PARTIAL BRIDGES (n=16)
Diameter (mm)	Length (mm)	Placed	Placed
5,0	10	1	5
5,0	13	2	2
5,0	16	0	1
4,3	10	1	5
4,3	13	7	12
4,3	16	5	12
TOTAL		16	37

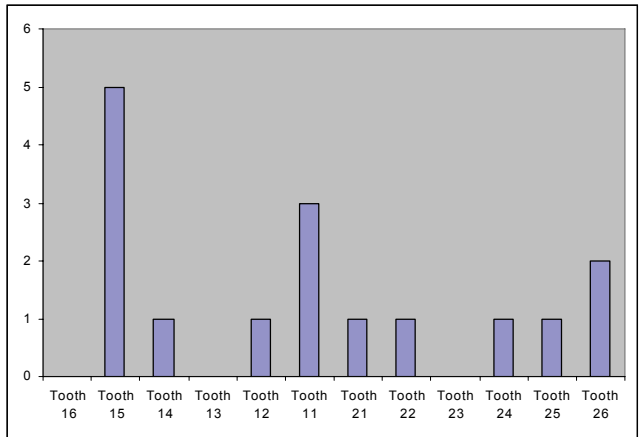


Fig. 7a. Number of implants in different tooth positions for single implants in the maxilla (n= 16)

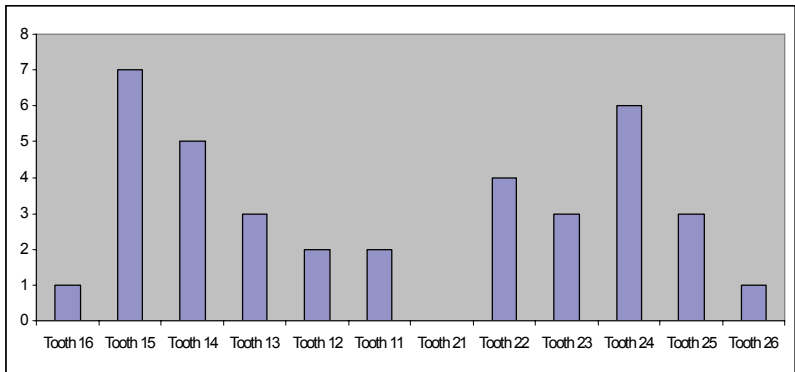


Fig. 7b. Number of implants in different tooth positions for partial bridges in the maxilla (n= 37)

Surgery

Prophylactic antibiotics were administered orally to all patients 1 hour prior to surgery. The implants were inserted without pretapping. The surgeon determined the bone quality according to Lekholm and Zarb’s criteria (1985) (Table 4). Before suturing the mucoperiosteal flap impression copings were attached to the implants. One surgeon (KF) performed all surgery.

Table 4a. Bone quality at implant sites for single implants according to Lekholm and Zarb. (n=16).

Quality	1	2	3	4
Implants	0	9	6	1

Table 4b. Bone quality at implant sites for partial bridges according to Lekholm and Zarb. (n=37).

Quality	1	2	3	4
Implants	1	20	14	2

Prosthetic procedure, Single Implants

One dentist (MB) undertook all the prosthodontic treatment. Immediately after surgery impressions (Impregum Penta®, 3M ESPE Dental AG, Seefeld, Germany) were taken. Healing abutment was placed on the implant. The single provisional crowns were fabricated by a dental laboratory and delivered within 6 hours and placed in light occlusion and with light interproximal contacts and articulation to minimize lateral forces. After a mean interval of 3 months and 10 days (range 2 m and 27 d to 4 m and 15 d) a permanent crown was delivered from the laboratory. The crown was screw-retained and tightened to 35 Ncm. The abutments were all Goldadapt (Nobel Biocare AB, Gothenburg, Sweden). For the partial bridges the permanent construction was delivered after a mean interval of 16 days (range 14 to 24 d). Healing abutments were attached to the implants during this time.



Fig. 8. Schematic picture of implant used in Paper IV.

Implant stability

The subjective primary implant stability was graded as 1 = poor, 2 = good, 3 = excellent. The objective implant stability quotient (ISQ) measurements were recorded for each implant as described by Meredith and coworkers (1997). The instrument used was the Osstell™ instrument (Integration Diagnostics AB, Gothenburg, Sweden). The resonance frequency measurements were taken at implant placement, at installation of the permanent crown and at 3, 6 and 12 months follow-up. The cover screw was removed and a transducer (type F13L5) for the electronic device was attached in a bucco-lingual direction, perpendicular to the bone, by screw attachment to the top of the implant, using a metallic hex screwdriver. The measurement was taken, and the ISQ value was recorded. Only those measurements that exhibited graphs with a distinct resonance peak were included and analyzed.

Radiographic examination

Radiographs were taken at implant placement, at installation of the permanent crown and at 12 months follow-up. The method for taking intraoral radiographs was not standardized. Digital films were exposed with a paralleling technique such that the cervical implant threads were visible. Marginal bone level was measured by an independent specialist in oral radiology (Fig 8).

Paper V

This study comprised the patients presented in Papers II and III. Since no clinical differences were presented all implants placed in the twenty-four patients were used in the present study as one group. Twenty-four patients received in total 142 implants. Three implants were lost before loading and four implants were found to be non-integrated at the five year follow-up. All 24 patients attended the three year follow-up and one patient failed to attend the 5 year follow-up, giving in total 139 implants analyzed at the 3 year follow-up and 129 after five years.

Implant stability measurement

The correlation between implant stability quotient measurements (ISQ) at three and five year follow-ups and marginal bone loss as measured on periapical radiographs was recorded. At the 3 and 5 year follow-ups ISQ measurements were taken using an Osstell™ (Instrument Device Integration Diagnostics AB, Gothenburg, Sweden). At the 3 year follow-up measurements were taken with the Osstell™ transducer attached to the implant perpendicular to the crest and at the 5 year follow up RFA measurements were taken in two directions, perpendicular as well as parallel to the crest.

Radiographic examination

The periapical radiographs were taken using a paralleling technique so the cervical implant threads were shown on at least two films. The distance from the implant shoulder to the most coronal bone-to-bone implant contact point was measured with a scale loupe (x 7 magnification, Peak, Tokyo, Japan) in tenths of a millimetre. The known distance between two threads was used for calibration of each radiograph. The ratio of the absolute values versus the measurements observed on radiographs was calculated using a validated algorithm. A mean bone level value was calculated for each implant based on corrected mesial and distal measurements.

STATISTICS

Papers I and II

The test and control groups were compared using the Kolmogorov-Smirnov test, the Mann-Whitney test and the MANOVA model using a SPSS statistical package (SPSS Inc, Chicago, Illinois, USA) and an ML (Multiprocess Multilevel Modeling from EconWare, Los Angeles, California, USA). A significant difference was considered when $p < 0.05$.

Paper III

The test and control groups were compared with regard to survival rate, marginal bone level, and marginal bone resorption and implant stability using the implant as unit. The Student's t-test, The Mann-Whitney test and the Kolmogorov-Smirnov test were applied using a SPSS statistical package (SPSS Ltd, Chicago, USA). A significant difference was considered when $p < 0.05$.

Paper IV

The Wilcoxon Sign Rank test was used for evaluation of possible differences in implant stability and marginal bone level over time. The Spearman correlation test was used to find possible correlations between implant stability. A statistically significant change or correlation was considered if $p < 0.05$.

Paper V

Non-parametric correlation analyses were used to measure the relationship between the variables and using the implant as the unit.

RESULTS

Papers I-III

Comparative outcomes of early and delayed loading protocols for implants supporting maxillary full dentures: clinical and radiographic findings, resonance frequency measurements and technical complications.

Clinical results

Implant and Prosthesis survival

All patients were followed for five years except one patient in the control group, who did not attend the last follow-up. Of the 142 implants with a sand-blasted large grit acid-etched (SLA) surface, 139 were loaded with full-arch prostheses: 94 in the test group and 45 in the control group. One test patient is shown in Fig. 9. Three failures occurred prior to loading, one in the test and two in the control group. Based on clinical findings, all the loaded implants were successful at 1 and 3 year follow-ups. Four late failures were observed in the test group after 5 years. The overall failure rates were 5.3% in the test group and 4.3 % in the control group. The difference was not statistically significant. A life-table of implants over five years is shown in Table 5. Despite these implant failures, all prostheses remained stable during the five year follow-up.

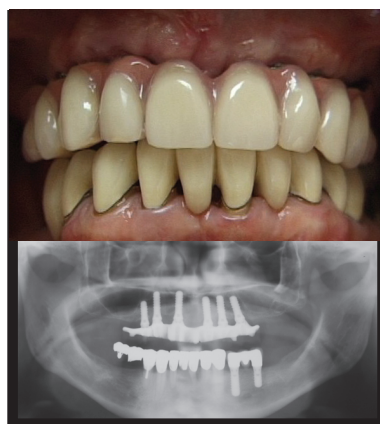

Fig. 9. Clinical photograph and panoramic radiograph of a patient at the 5 year follow-up

Implant failures

One test implant with poor primary stability was lost the day after insertion. The first early failure in the control group occurred after 52 days: the patient was a smoker with a history of periodontitis. A second control implant which failed after 4.5 months had been placed in an area of poor bone density. The four late failures showed extensive marginal bone resorption and signs of peri-implantitis of which three are shown in Fig. 10.

Table 5. Life-tables of implants in the study. There was no statistically significant difference between test and control implants.

Interval	Test implants	Failures (Implants/patients)	Drop-outs (Implants/patients)	Survival rate (%)
Placement-loading	95	1 / 1	0	98.9%
Loading – 1y	94	0	0	98.9%
1y – 2 y	94	0	0	98.9%
2y – 3 y	94	0	0	98.9%
3y – 4y	94	0	0	98.9%
4y – 5y	94	4 / 2	0	94.7%
5 y -	90	-	-	-

Interval	Control implants	Failures (Implants/patients)	Drop-outs (Implants/patients)	Survival rate (%)
Placement-loading	47	2 / 2	0	95.7%
Loading – 1y	45	0	0	95.7%
1y – 2 y	45	0	0	95.7%
2y – 3 y	45	0	0	95.7%
3y – 4y	45	0	0	95.7%
4y – 5y	45	0	6 / 1	95.7%
5 y -	39	-	-	-

Interval	All implants	Failures (Implants/patients)	Drop-outs (Implants/patients)	Survival rate (%)
Placement-loading	142	3 / 3	-	97.9
Loading – 1y	139	0	-	97.9
1y – 2 y	139	0	-	97.9
2y – 3 y	139	0	-	97.9
3y – 4y	139	0	-	97.9
4y – 5y	139	4/2	6 / 1	95.1
5y -	129	-	-	-

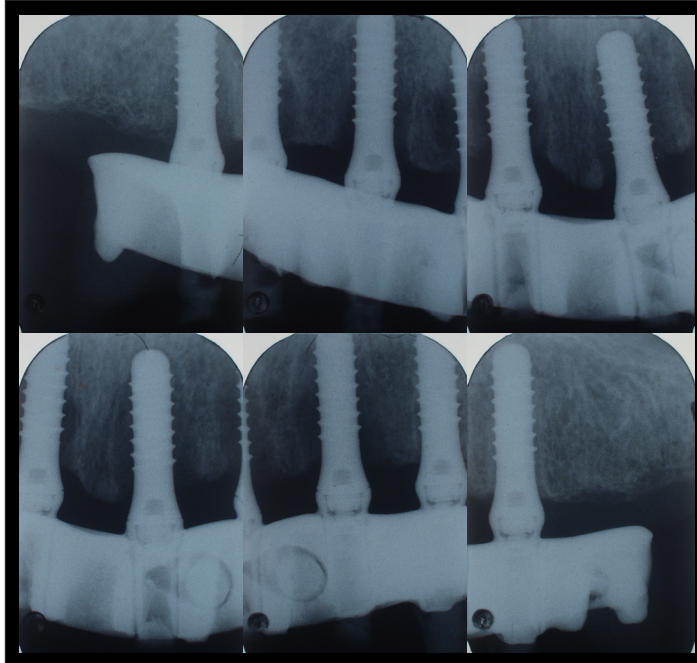


Fig. 10. Implants showing extensive bone loss at the 5 year follow-up.

Soft tissue

At the one-year follow-up, there were significant differences between test and control groups with respect to Sulcus Bleeding Index, Plaque Index and the width of keratinized gingiva: the test group had lower scores for Sulcus Bleeding Index and Plaque Index and less keratinized gingival mucosa than the control group. At 3-year follow-up there were no significant differences ($P > .05$ in all cases) between the groups with respect to any of the above variables or oral hygiene, gingival level, probing depth width of attached mucosa midfacial of implant, attachment level, esthetics, opposing dentition or patient satisfaction.

At the 5-year follow-up more test than control patients presented with plaque (Table 6). However, the control group had more bleeding on probing, at both patient and implant levels (Table 7) and a higher proportion of patients as well as implants in the control group had pocket depths > 3 mm (Table 8).

Radiographic findings

At all time points, the marginal bone level was located significantly more coronally for test than control implants (Table 9). After five years, the average marginal bone level was 2.9 mm (SD1.1) below the implant shoulder for test implants and 3.7 mm (SD1.2) for the controls. Over this period, the average bone loss was observed for test and control implants 0.8 mm (SD1.2) and 0.3 mm (SD1.0) respectively ($p > 0.05$) (Table 10).

A similar proportion of patients had one or more implants with >2 mm bone loss (Table 11a). More patients and implants in the test group showed >3 mm bone loss over 5 years (Table 11b).

Table 6. Plaque index at the 5th annual check-up.

Score	Test		Control	
	Patients	Implants	Patients	Implants
0	8 (50 %)	67 (74.4 %)	5 (71.4 %)	29 (74.3 %)
1	3 (18.8 %)	8 (8.9 %)	1 (14.3 %)	4 (10.3 %)
2	5 (31.2 %)	15 (16.7 %)	1 (14.3 %)	6 (15.4 %)
3	-	-	-	-
Σ	8	23	2	10
1+2+3	(50 %)	(25.6 %)	(28.6 %)	(25.6 %)

Table 7. Bleeding index at the 5th annual check-up.

Score	Test		Control	
	Patients	Implants	Patients	Implants
0	8 (50%)	62 (68.9 %)	1 (14.3 %)	20 (51.3)
1	6 (37.5 %)	20 (22.2 %)	5 (71.4 %)	13 (33.3 %)
2	2 (12.5 %)	8 (8.9 %)	1 (14.3 %)	6 (15.4 %)
3	-	-	-	-
Σ	8	28	6	19
1+2+3	(50 %)	(31.1 %)	(85.7 %)	(48.7)

Table 8. Results from probing depth measurements at the 5th annual check-up.

Probing depth	Test		Control	
	Patients	Implants	Patients	Implants
> 3mm	5 (31.3 %)	12 (13.2 %)	3 (42.8 %)	6 (15.4)

Table 9. Levels of the marginal bone in relation to the upper part of the implant shoulder for test and control implants.

	Test Bone level mm (SD)	Control Bone level mm (SD)	p-value
Baseline	2.1 (0.7)	3.5 (1.1)	0.00
1 year	2.5 (0.7)	3.3 (0.9)	0.00
3 year	2.7 (1.4)	3.5 (1.2)	0.001
5 year	2.9 (1.1)	3.7 (1.2)	0.001

Table 10. Loss of marginal bone from baseline to the 5th annual check-up for test and control implants.

	Test	Control	p-value
Baseline to 5 years	-0.8 (1.2)	-0.3 (1.0)	0.006

Table 11a. Incidences of 2 and 3 mm bone loss during 5 years on patient level.

Bone loss	Test group			Control group		
	1 year (n=16)	3 years (n=16)	5 years (n=16)	1 year (n=8)	3 years (n=8)	5 years (n=7)
> 2 mm	0 (0 %)	3 (18.8 %)	5 (31.3%)	0 (0 %)	2 (25 %)	2 (28.6%)
> 3 mm	1 (6.3 %)	1 (6.3 %)	3 (18.8 %)	0 (0 %)	1 (12.5 %)	0 (0 %)

Table 11b. Incidence of 2 and 3 mm bone loss during 5 years on implant level.

Bone loss	Test group			Control group		
	1 year (n=94)	3 years (n=93)	5 years (n=90)	1 year (n=45)	3 years (n=45)	5 years (n=39)
> 2 mm	1 (1.1 %)	8 (8.6 %)	8 (8.9 %)	0 (0 %)	3 (6.6 %)	2 (4.4 %)
> 3 mm	1 (1.1 %)	3 (3.2 %)	4 (4.4 %)	0 (0 %)	1 (2.2 %)	0 (0 %)

Technical complications

Technical complications associated with the acrylic superstructure were more frequent in control than in test patients, 1.1 versus 1.5 events / prosthesis over 5 years (Table 12). The occurrence of adverse events after treatment with resilient bite plane and gold onlays is shown in Table 13. Gold onlay treatment was effective in preventing technical complications, irrespective if test or control group (Table 14). A gold onlay is shown in Fig 11.

Table 12. Number and type of technical complications during 5 years.
Number of complications per bridge within brackets.

TYPE of COMPLICATION	Test	Control
Resin related / Tooth fracture	18 (1.1)	12 (1.5)
Metal-related / Loose assembly screw	1 (0.06)	-

Table 13. Type and number of measures taken in conjunction with technical complications.

TYPE OF TREATMENT	1 YR		2 YRS		3 YRS		5 YRS	
	TEST (N=16)	CONT ROL (N=8)	TEST (N=16)	CONTR OL (N=8)	TEST (N=16)	CONTR OL (N=8)	TEST (N=16)	CONTR OL (N=7)
BRIDGE ON AND OFF	6	3	1	2	2	1	1	1
GOLD ONLAY	4		1	1	1			
RESILIENT MOUTH GUARD	3	1		2			2	1
RECEMENTATION OR REPLACEMENT OF TOOTH	5	2	1	2	2	1	6	2
FILLING WITH RESIN MATERIAL	3	2		1	2	1	3	5
ASSEMBLY SCREW TIGHTENING					1			
FLAP OPERATION		1				1		1

Table 14. Occurrence of technical complications after treatment with resilient bite plane and gold onlay

Resilient bite plane (n=9)			Gold onlay (n=7)		
Patient Number/ Test or Control	Technical complication		Patient Number/ Test or Control	Technical complication	
	Yes	no		Yes	No
1 / Test	x		7 / Test		x
5 / Control	x		8 / Test	x	
8 / Test	x		13 / Test		x
10 / Control	x		16 / Test		x
13 / Test	x		20 / Control		x
14 / Test	x		22 / Test		x
15 / Test	x		24 / Test		x
18 / Control	x				
20 / Control		x			

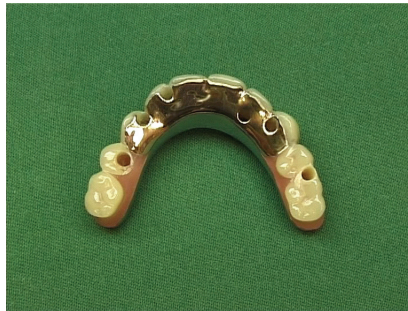

Fig. 11. Gold onlay

Resonance Frequency Measurements (RFA)

The mean ISQ value for all implants, measured in bucco-palatal direction, was 55.7 (SD6.0) after three years and 56.6 (SD6.9) after five years ($p < 0.05$). The mesio-distal ISQ value was 66.1 (SD6.0) after five years, significantly higher than for the bucco-palatal direction. There were no significant differences between implants with early and delayed loading (Table 15).

Table 15. Results from RFA measurements at the five-year examination

	Test group	Control group	Statistics
Buccal-palatal	56.7 (7.1)	56.2 (6.6)	NS
Mesial-distal	66.6 (6.1)	65.0 (5.6)	NS

Paper IV

Evaluation of clinical and radiographic outcomes of immediate and early loading of dental implants in the partially edentulous maxilla.

Clinical results

One implant was lost, giving an overall survival rate of 98.1% after one year. This implant belonged to the single tooth group which showed a survival rate of 93.8%. For the partial prosthesis group, the survival rate was 100 %. The failed implant had been inserted in quality 4 bone in the right second premolar region. Primary stability was poor (ISQ 56); the implant was found to be mobile and removed 7 weeks after installation and prior to loading with a permanent crown.

Radiographic findings

For all implants, the marginal bone level was located 0.7 mm (SD1.1) above the reference point at baseline and 0.5 mm (SD 1.2) below the reference point after one year in function: the average bone loss during this period was 1.1 mm (SD 1.0). For single tooth replacements, the marginal bone level at baseline was 0.5 mm (SD 0.7) above the reference point and 1.0 mm (SD 0.9) below the reference point after one year. The corresponding values for implants supporting partial prosthesis were 0.7 mm (SD 1.1) and 0.2 (SD 1.2) at baseline and one year, respectively. Thus, the average marginal bone loss during the first year was 1.5 mm (SD 1.0) and 0.9 (SD1.0) for single crown and partial prosthesis implants respectively. The change was statistically significant ($p < 0.001$). The proportions of implants showing > 2 mm bone loss after one year were 18 % (all implants): 25% (single crown) and 14.7 % (partial prosthesis). The corresponding proportions of implants with >3 mm resorption were 6% (all implants) 6.3% (single crown) and 5.9% (partial prosthesis) (Table 16).

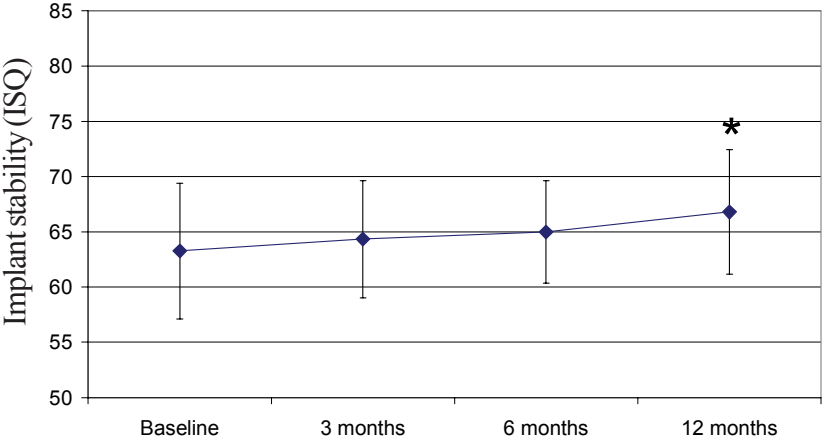
Resonance frequency analyses findings

Implant stability expressed as RFA improved over time, with no differences between implants supporting single crowns and those supporting partial prosthesis (Fig. 12). For all implants, the mean ISQ was 63.3 (SD 6.1) at baseline and 64.3 (SD 5.3), 65.0 (SD 4.6) and 66.8 (SD 5.6) after 3, 6 and 12 months, respectively. The average change from baseline to one year was 3.3 ISQ (SD 5.0) and statistically significant ($p < 0.05$).

Table 16. Marginal bone levels and bone loss for immediately or early loaded Replace Select tapered implants in the maxilla when used for single tooth replacements or partial bridges.

	Single	Partial	All
Bone level baseline	0.5 (0.7)	0.7 (1.1)	0.7 (1.1)
Bone level 1 year	-1.0 (0.9)	-0.2 (1.2)	-0.5 (1.2)
Mean bone loss	-1.5 (1.0)	-0.9 (1.0)	-1.1 (1.0)
> 2 mm	25 %	14.7 %	18 %
> 3 mm	6.3 %	5.9 %	6 %

Single tooth replacements



Partial bridges

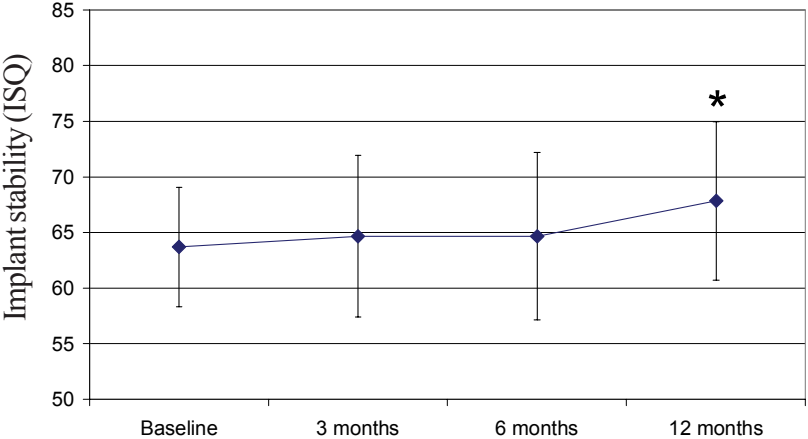


Fig. 12. Results from RFA measurements. * = p< 0.05 compared with baseline.

Paper V

Influence of marginal bone level on implant stability measurements

The mean marginal bone level was 3.0 mm (SD1.4) below the reference point after three years and 3.1 mm (SD1.2) after 5 years ($p < 0.05$). A transducer attached to an implant is shown in Fig 13. There was a statistically significant correlation between marginal bone levels and ISQ values after three and five years (Fig. 14a-c). No correlation was found between marginal bone loss and changes of ISQ values from three to five years (Table 17). Furthermore, no correlation was found between ISQ measurements after three years and failures after five years. However, a correlation was seen for marginal bone level (Table 18) (Fig.15-16).

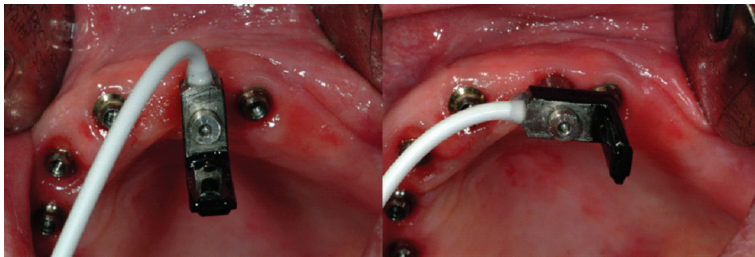


Fig. 13. Showing RFA measurements of a maxillary implant with the transducer perpendicular (buccal-palatal) and parallel (mesial-distal) with the bone crest.

Table 17. Correlation between ISQ changes and marginal bone level changes from three to five years.

	ISQ CHANGE 3 TO 5 YEARS
Bone Level Change 3 to 5 Years	$p = 0.385$

Table 18. Correlation between implant status (survival or failure) and RFA values and bone levels at three year visit.

	IMPLANT STATUS (SURVIVAL OR FAILURE)
ISQ 3 Year	$p = 0.430$
Bone Level 3 Year	$p = 0.003^*$

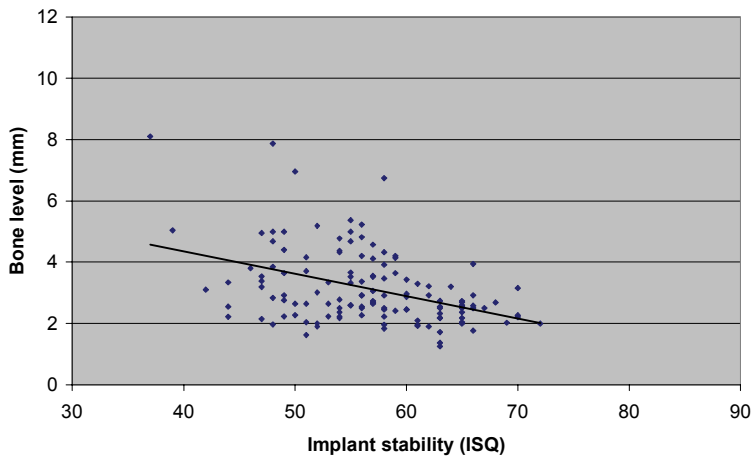


Fig.14a.

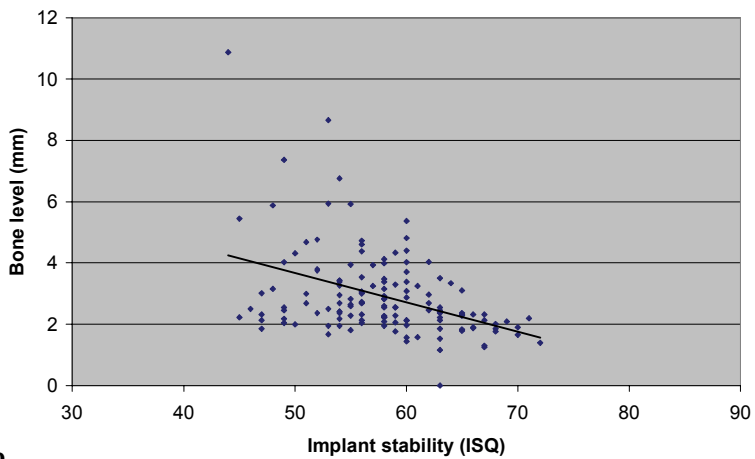


Fig.14b.

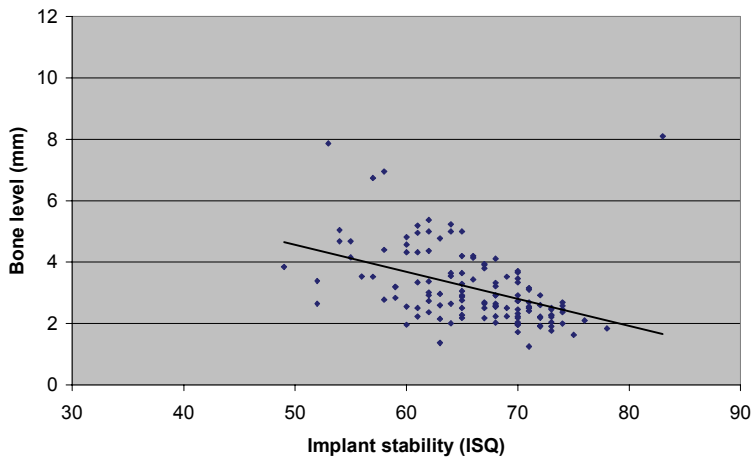


Fig.14c.

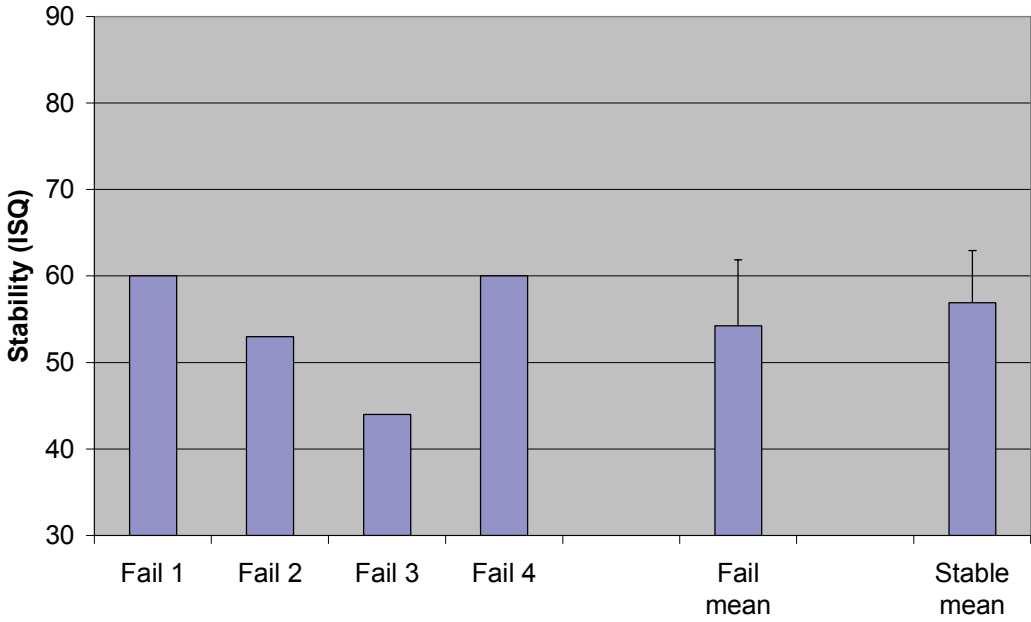


Fig. 15. Graph showing the three-year ISQ values (single and mean) for the four implants that failed after five years and the mean three-year values for the remaining stable implants.

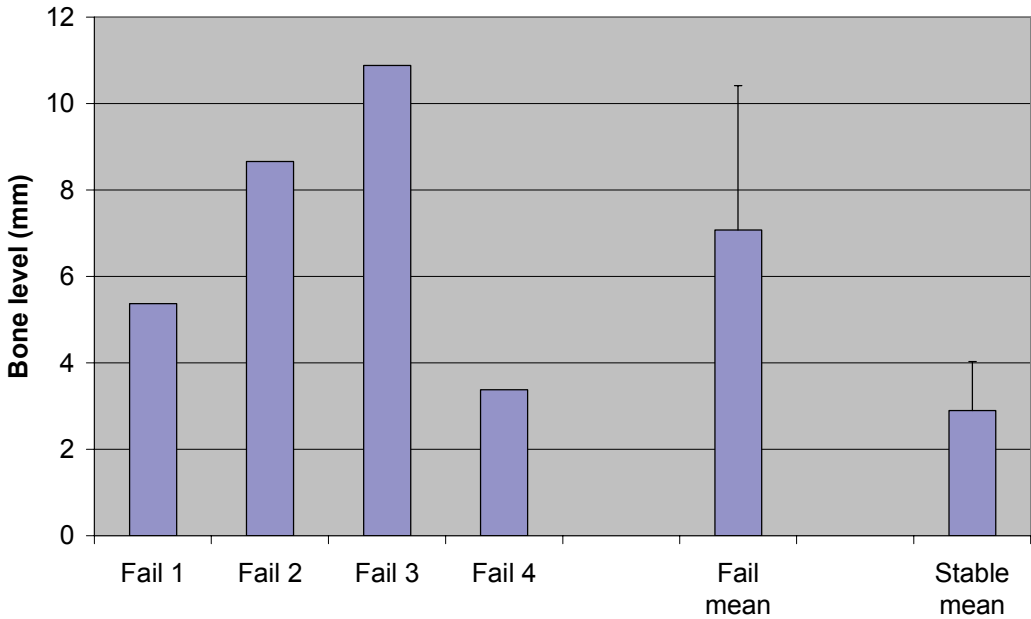


Fig. 16. Graph showing the three-year marginal bone levels (single and mean) for the four implants that failed after five years and the mean three-year values for the remaining stable implants.

DISCUSSION

The clinical work on which this thesis is based spanned over 10 years. The hypothesis tested in the thesis is that immediate/early loading of dental implants in the maxilla results in the same outcomes as for delayed loading. In this context, the studies on which this thesis is based support the hypothesis since good clinical and radiographic outcomes were obtained following immediate/early loading of two different dental implant systems in the maxilla after a follow-up period from one to five years. According to the present studies, there is no long-term negative impact of early loading on the outcome of implant treatment in the edentulous maxilla: after 5 years of follow-up the clinical and radiographic outcomes were comparable with those of a conventional loading protocol. Comparison of different loading protocols over long-term is therefore probably of limited value. However, it has been suggested that a proper evaluation of an implant system or procedure requires at least five years of follow-up (Albrektsson et al 1986).

EVIDENCE BASED METHOD

Ethical considerations

All new treatment concepts in implant dentistry require careful examination before application in general dental practice. Several authors have stressed the necessity of prospective, longitudinal randomized clinical trials (Cochran et al 2004; Gapski et al 2003) and also the need to summarize the results in systematic reviews (Esposito et al 2001a, 2001b). At the time of initiation of the first clinical study of the present thesis, the documentation of immediate/early loading consisted mainly of a few case reports. Today, this is a well-documented technique in the mandible but there are few long-term clinical studies evaluating the outcome of maxillary implants (Attard & Zarb 2005; Nkenke & Fenner 2006).

Ethical approval is essential before commencing research projects on human subjects, as stated in the declaration of Helsinki. The present studies were approved by ethic committees according to Swedish law and regulations.

Randomization

In an article outlining the determinants of correct clinical reporting, Albrektsson and Zarb (1998), stated that prospective studies are preferable to retrospective ones, and that if different patients are used for control and test procedures, proper randomization of these patients must be carried out. The importance of clearly adequate randomization and

concealment of allocation to test or control group has also been stressed in an article on the quality assessment of randomized controlled trials of oral implants (Esposito et al 2001a, 2001b). These criteria have partly been fulfilled in the present study (Paper I, II, III and V). Patients were consecutively randomized, but it should be noted that the inclusion criteria stipulated that only patients with sufficient height and width of maxillary bone, assessed radiographically, could be included. This may have influenced the treatment outcome. However, the same patient selection criteria as used in clinical routine at this time period (1999) for treatment of the totally edentulous maxilla were applied. Randomization procedures were done prior to the start of the study: group allocation was concealed from both surgeon and patient until the time of the surgical procedure. Professional statisticians were used for planning of the study. The number of patients was partially determined by the availability of patients at the time for the study. Although the total number of patients was limited, the two groups were well-balanced with respect to gender and age. The distribution of number of implants and implant length was also similar for the two groups. Kinsel and Liss (2007) reported reduced implant length as a sole significant predictor of failure. The radiographic examinations in the present studies could have been blinded, but this was not the case.

IMPLANT SURVIVAL

The one- to five-year clinical outcomes in Papers I, II and III demonstrated no differences in survival rate between early and delayed loading of one-stage SLA implants in the totally edentulous maxilla. Throughout the follow-up period, all patients successfully retained their fixed bridges. However, prior to loading, three implants were lost, of which two were in the control group. Thus, a higher failure rate, although not statistically significant, was seen for delayed loaded implants (4.3 % vs 1.1 %). It is possible that the early failures in the control groups indicate unfavourable loading of the one-stage implants with an overdenture as also discussed by Friberg et al (1999c). After five years, four late implant failures occurred in two patients in the test group. One of these two patients was comparatively young and was edentulous even in the mandible. It was not possible to conclusively determine the reason for this total loss of teeth before the age of 40 years, but it was most probably attributable to periodontal disease. It is unlikely that the early loading protocol had an effect on post-loading implant failures in the test group. It is more likely that failure was associated with smoking and poor hygiene, as concluded by Quirynen et al (2002), DeLuca and Zarb (2006a, 2006b) and Jemt and Häger (2006). In a study by Jansson et al (2005), smoking and positive IL-1 genotype were reported to have a synergistic effect on implant loss. In a recently published study by Roos-Janaker et al (2006) a nine- to fourteen-year follow-up of two hundred and ninety-four patients was presented. The overall survival rate was 95.7 % and implant losses appeared as clusters in a few patients. Early failures were more common than late failures.

Moreover it was concluded that individuals with a history of periodontitis and those who smoke are more likely to develop peri-implant lesions

One patient in the control group failed to complete the study (Paper III). An isolated drop-out should not influence the outcome of a study, because it can be compensated for in the life-table. Since the implants in this particular patient were known not to have failed, the results of the study are not affected by the drop-out. However, if the drop-out patient had been the one who experienced failure of four implants, the study outcome would have been affected.

In Paper IV, one tapered implant supporting a single tooth replacement was lost seven weeks after surgery. The temporary crown was still in place, the permanent crown had not yet been provided. In this case, the absence of osseointegration is attributed primarily to the very low-density trabecular bone, assessed at surgery as bone quality 4, contributing to poor primary stability. This is in accordance with a report by Jaffin et al (1991). Because of the poor bone quality, delayed loading should probably have been considered for this single implant crown. However, the only inclusion criteria of at least 32 Ncm insertion torque was fulfilled in spite of the unfavourable conditions. In Paper IV, no implant was lost when an early loading protocol was used for partial bridges, which indicate that splinting is favourable for integration of early loaded implants.

IMPLANT SURFACES

In the present thesis, dental implants with moderately roughened surfaces, SLA and TiUnite surfaces, were used in the clinical studies. In a review article focusing on clinical knowledge Albrektsson & Wennerberg (2004a) summarized that SLA surface implants showed survival rates from 97.5 to 100% in studies with follow-ups from 1 to 3 years and TiUnite surface implants showed 93.4% to 100% survival after follow-up times of 6 to 12 months. Studies using both rapid and delayed loading protocols were reviewed in that study. The present studies demonstrated an overall implant survival of 95.1 % in the edentulous maxilla after five years and 93.8 % and 100 % for single crown and partial cases respectively, after one year which correspond well to the findings by Albrektsson & Wennerberg (2004b).

Dental implants with moderately roughened implant surfaces have previously shown predictable results with respect to reduced healing times (Cochran et al 2002; Rocuzzo and Wilson 2002; Testori et al 2002; Vanden Bogaerde et al 2004; Cooper et al 2001). With respect to implant survival, Papers I and II of the present thesis disclosed no differences between early and delayed loading after one and three years of follow-up. After five years (Paper III) four implants were lost, all in the test group. However, it is not likely that the early loading protocol had an effect on late failures but that other explanations are more plausible. One patient in the test group lost three of six implants. This patient had been assessed as having good bone quality and quantity at surgery. Moreover, there was no obvious overload

situation: the lower jaw was edentulous and no denture was used. However, this patient exhibited a combination of other negative factors: smoking, poor oral hygiene and history of periodontitis. The three implants were lost due to ongoing marginal bone loss and another 2 implants which were stable after 5 years showed extensive bone loss.

In a one year follow-up, Åstrand et al (2000) investigated 28 patients with edentulous maxillae, who were rehabilitated with four to eight implants with titanium plasma sprayed surfaces (TPS), loaded about 7 months postoperatively. In total 167 implants were inserted. Twelve implants, 10 prior to and 2 after loading, were lost, giving a survival rate of 92.8 %. Nine implants were lost in two patients. Eight of the remaining stable implants had bone loss exceeding 8 mm. Several factors were seen as possible explanations for the outcome after one year: the rough surface, the influence of dentures during the healing period and the fact that fifty percent of the included patients were smokers. The TPS surface is rougher than the SLA surface, hence the TPS surface is regarded as more susceptible to peri-implant lesions than moderately roughened surfaces.

Recently, Östman et al (2007) and Albrektsson et al (2007) reported failure rates of 5.2% and 11.8% with immediately loaded one-piece implants with the same implant surface (TiUnite) as used in Paper IV. Albrektsson et al concluded that the recommended clinical handling procedures for these one-piece implants, including a punch procedure, grinding down *in situ* and loading directly, resulted in unusually high failure rates. The tapered implants used in Paper IV were handled in a flap procedure. There was no grinding *in situ* and immediate or early loading was performed.

RADIOGRAPHIC EXAMINATION and BONE LEVEL

The outcomes of implant treatment are commonly based on both clinical and radiographic parameters. However, the accuracy of radiographic measurements has been a controversial subject in the literature. The quality of radiographs may differ in respect to projection and radiographic density. According to some authors, early signs of integration failures are subtle and hence often not discernible on radiographs (Zarb and Schmitt 1990). A report by Grunder et al (1993) found that metric underestimation of horizontal and vertical bone loss on radiographs resulted in overestimation of the prevailing bone attachment. Assessment of bone level changes over time requires methods with a high degree of precision and the measurements obtained should be similar when repeated either by the same or another observer. Although the radiographs in the present study were taken without stents, attention was paid to standardize the imaging procedures. The periapical films should show undistorted images of the implant threads and every implant was imaged on at least two films. A study by Gröndahl et al (1998) evaluated inter- and intraobserver variability in radiographic bone level assessment of Brånemark fixtures. The results showed a small interobserver variation (0.14 mm) with the intraobserver variation (0.08 mm) as its largest component. The radiographic

density and the degree of bone loss showed the strongest influence on the intraobserver variation.

The radiographs in the present study were examined by two specialists in oral radiology, one at the 1 and 3 yr follow-ups and another at the five year follow-up. The time of loading was selected as the baseline for radiographic evaluation in Papers I, II and III, *i.e.* after 9 to 18 days for the test group and after 2.1 to 5.1 months for the control group. This intergroup difference in the interval between implant insertion and initial radiographic evaluation has implications with respect to the stage of osseointegration and comparison of the radiographs as discussed below.

The radiographic evaluations in Papers I, II and III showed some differences between the groups, which in part can be explained by different insertion depths. The baseline bone levels were located 2.1 mm and 3.5 mm below the implant shoulder for test and control implants, respectively. It is generally anticipated that the marginal bone cannot stabilize at a smooth vertical surface (Quirynen et al 1992; Malevez et al 1996), and it is possible that the bone loss for the test group was due to the fact that about 30 % of test implants showed baseline bone levels above 1.8 mm, *i.e.* at the machined collar. None of the control implants had the marginal bone levels at the machined collar. Hänggi et al (2005) reported that bone remodelling and bone loss were most pronounced during healing of the same type of implant as used in the present study. About 1 mm of bone was lost during healing in that study. In the present study, the baseline radiographs were taken at delivery of the bridge and, thus some initial bone loss may have occurred during healing of the control implants. If anticipating that 1 mm of bone was lost during healing of the control implants in the present study, the marginal bone may have been at a similar level after placement. If so, the overall bone loss was less at the test implants. The control implants had the marginal bone at a more coronal level throughout the study which may indicate less bone resorption. However, due to the fact that no radiographs were taken after placement of the control implants, this cannot be proven. Other studies on the same implant design have reported similar bone levels as in the present study (Nordin et al 2004; Bornstein et al 2005).

RESONANCE FREQUENCY ANALYSIS (RFA)

Implant stability

Resonance frequency measurements expressed in ISQ (implant stability quotient) units were used to assess implant stability in Papers II, III and IV. At the time of the start of the first study and the 1st annual check-up (Paper I), the RFA technique was not commercially available. The routine at the Falun clinic at this time for evaluating the stability of the implants was to apply bending (by hand) and percussion tests (mirror handle) to the whole prosthetic construction. The value of this procedure can be questioned. The RFA technique was used at

the three year follow-up as presented in Paper II. The recommendations from the manufacturer and the literature were to measure with the transducer beam placed in a bucco-palatal direction. In paper III, measurements were taken in both mesial-distal and bucco-palatal directions. Interestingly, the bucco-palatal measurements were some 10 ISQ units lower than the mesio-distal readings, which is in accordance with the findings of Veltri et al (2007). The RFA technique measures stability as a function of interface stiffness and the results indicate a higher stiffness in mesio-distal direction, which can be explained by the fact that the bone is thinner at the buccal and palatal aspects of the implants. However, the manufacturers' recommendation to make measurements perpendicular to the jaw bone which may give a false impression of low stability. The new generation RFA instrument utilizes a wireless technique to measure the RF of a peg that is attached to the implant (Osstell Mentor) (Valderrama et al 2007). According to the manufacturer, both the highest and lowest ISQ value can be detected from one measurement if there is a distinct difference. In contrast to the old technique, measurements are not forced in a special direction but are done in 360 degrees, which probably give more accurate measurements.

Marginal bone level

Paper V investigated the relationship between marginal bone level, measured on radiographs, and RFA. The RF is related to the stiffness of the bone-implant interface and, consequently, implants placed in bone of low density will show a low RF and implants in dense bone a high RF (Friberg et al 1999b, Östman et al 2006). Moreover, changes of the stiffness of the bone-implant interface due to healing, remodelling or failure may be detected as a change in RF over time (Friberg et al. 1999c). The RF value is also determined by the distance from the transducer to the first bone contact which means that it is sensitive to changes of the marginal bone level (Meredith et al 1996, Meredith et al 1997, Sennerby et al 2005, Turkyilmaz et al 2006c). This is in accordance with the findings in paper V, showing a correlation between RFA measurements after three and five years, with marginal bone levels as measured in intraoral radiographs. Thus, the RFA technique seems to be a sensitive tool for monitoring the clinical performance of implants and may be useful for identifying implants at risk of failure due to gradual loss of integration and/or continuous marginal bone resorption. However, in the present study, the RFA measurements at three years did not clearly identify the implants with severe bone loss. The fact that measurements were made in buccal-palatal directions only may have had an impact. Moreover, RFA measurements could not be used to predict implant failures observed at the five years follow-up.

In a review of different biomechanical testing techniques, Aparicio et al (2006) concluded that the prognostic value of RFA to detect loss of stability has yet to be established in prospective clinical studies. Consequently, the value of the RFA technique to predict implant failure and to identify implants with ongoing marginal bone resorption is at present not well documented.

OUTCOME OF PROSTHESES

One single crown in Paper IV was removed due to instability of the implant after 7 weeks. All remaining original prosthetic constructions were *in situ* at the final check-up. Early splinting in a rigid, fixed construction may protect the implants from unfavorable and uncontrolled loading and improve healing conditions (Bergqvist et al 2005). This was performed in the test group in Papers I, II and III and moreover in the partially edentulous group of patients in Paper IV. For single tooth replacement the presence of rotation forces is seen as a clear risk factor for failure (Ericsson et al 2000a). In the present study, the temporary crown was placed in light occlusion in an attempt to reduce the rotational forces. However, passive forces from lips, chins and active forces during chewing of food can probably not be avoided.

In a study by Gervais and Wilson (2007) the importance of retrievability of fixed, implant-supported prostheses was emphasized. All prostheses in this thesis are retrievable. In the present study the cumulative success rate (CSR) of the cast titanium frameworks was 100 %. The corresponding figure for cast frameworks made of Type III gold alloy was 95.9 % (Jemt 1994). In a 10-year follow-up study of titanium frameworks made by laser welded prefabricated titanium components according to an old and a new protocol, the five-year CSR was 91.4 and 97.8 % respectively (Örtorp & Jemt 2006). Thus the cast titanium framework is a viable treatment alternative to gold alloy. The biological, mechanical and physical properties of titanium, laser welding technique and the conventional casting technique to make titanium frameworks are described by Örtorp (2005). Resin-related complications caused the most problems over the five years of follow-up in Paper III. This is in accordance with results obtained in several other studies (Johansson et al 1990; Jemt 1994; Berglundh et al 2002). No metal-related complications were found. However, in one patient two assembly screws had to be retightened. In order to reduce the incidence of resin-related complications due to mechanical fatigue, the patients were either provided with a resilient mouth guard in the mandible or a lingual gold onlay in the front area. These two therapies have been used in other studies (Jemt 1994; Göthberg et al 2003; Lindfors et al. 2006). The results obtained in paper III showed that a lingual gold onlay is the therapy of choice to prevent resin-related complications.

Occlusal factors and masticatory function are thought to be related and have an impact on the outcome of the prosthetic construction, in general prosthetic treatment as well as in implant treatment. The status of the opposing dentition is accordingly of importance. No differences were found in the opposing mandibular dentition between the examinations in Paper I and Paper II. However, at the five years follow-up one patient in the test group had been provided with an implant-retained overdenture.

The most important benefits from rehabilitation with implant-supported prostheses are the improvement in quality of life and increased utility. However, it is not only the initial costs of a treatment that are of importance when evaluating it from an economic point of view. The frequency of various complications and the need for supplementary and

maintenance treatment must also be taken into account (Göthberg 2003). Several reports have addressed these aspects (Johansson and Palmqvist 1990; Jemt 1994, Walton 1998; Pjetursson et al 2004; Kreissl et al 2006). At the five years follow-up all case records were retrospectively scrutinized and the number and type of measures are reported in Paper III.

The option of selecting an immediate or early loading protocol in appropriate cases may be of importance to both patient and dentist. Conventional loading protocols are associated with unnecessary delays in treatment and are therefore less beneficial than early loading protocols.

CONCLUSIONS

The results from the studies in the present thesis support the hypothesis that immediate/early loading of dental implants in the maxilla results in the same clinical outcomes as for delayed loading.

1. Similar treatment outcomes can be achieved with early and delayed implant loading in the totally edentulous maxilla after one year in function. Better PI and SBI scores and more coronal bone levels are seen for early loaded implants. The early loading method enables patients to be provided with a full arch implant-supported fixed prosthesis in approximately 2 weeks instead of 3–4 months (delayed). **(Paper I)**.
2. No differences in clinical and technical outcomes are seen after three years of loading of a complete implant-supported fixed prosthesis in the maxilla when using early or delayed loading protocols. Early loaded implants show a more coronal bone level than delayed loaded ones after three years. **(Paper II)**.
3. Early and delayed loading of implants in the edentulous maxilla for support of a complete fixed prosthesis results in similar survival rates and implant stability after five years of loading. Early loaded implants show more coronal bone levels and more bone loss than delayed loaded implants after five years. Technical complications are mainly resin-related and can be reduced by the use of a lingual gold onlay. **(Paper III)**.
4. Immediate/early loading in the partially edentulous maxilla results in good clinical and radiographic outcomes after one year. Implant stability at placement correlates with bone quantity and quality and increases with time as measured with RFA, indicating a favourable bone tissue response to the loaded implants. **(Paper IV)**.
5. RFA measurements of implants after three and five years of function in the maxilla correlate with marginal bone levels as measured in intraoral radiographs. RFA measurements after three years of function cannot be used to predict implant failures observed at the five-year check-up. **(Paper V)**.

ACKNOWLEDGEMENTS

Göteborg den 8 februari, 2008

Den mätta dagen, den är aldrig störst.
Den bästa dagen är en dag av törst.
Nog finns det mål och mening i vår färd –
men det är vägen, som är mödan värd. *Karin Boye*

Under resan mot detta mål har flera människor på olika sätt inspirerat, uppmuntrat och även utmanat mig. Många arbetskamrater har under längre eller kortare tid varit engagerade i det kliniska arbetet. Trots att projektet det senaste året upptagit det mesta av min tid vid sidan av det vanliga heltidsarbetet så finns min familj på något underligt sätt kvar.

Först av alla vill jag tacka min handledare, professor **Lars Sennerby**. Det var Lars som för fem år sedan uppmanade mig att bli doktorand och det är Lars som nu finns med när detta arbete närmar sig sitt slut. Tack Lars för att du delat med dig av din kunskap och erfarenhet, för att du svarat på alla mina mail och dessutom för att du alltid tänkt på att man arbetar lättare när man inte är hungrig.

En lika betydelsefull person för detta projekt har **Torsten Stenberg** varit. Jag tackar Torsten för hans stora intresse av att fortsätta uppföljningen av patienterna i arbete I, II, III och V, trots en tillvaro som pensionär. Jag tackar också Torsten för hans lika osvikliga tro på att få detta projekt i mål och för all uppmuntran under de senaste tre åren. Tack också för att du alltid hade kaffet klart när jag kom.

Professor **Tomas Albrektsson** tackar jag för värdefulla synpunkter i arbetets slutfas och för hans förmåga att skapa en positiv atmosfär.

Mats Bäckström tackar jag för möjligheten att genomföra en forskningsstudie i hans privata tandläkarpraktik och för en rå men hjärtlig arbetsstämning.

Måns Hedin vill jag tacka för hans alltid pålitligt positiva inställning till forskning.

Ett stort tack till **Eva Helin** för optimalt tagna röntgenbilder.

Tack **Liza Hallin** för att du hade kontroll över uppföljningen av patienterna i studierna I, II, III och V.

Tord Rådberg tackar jag för det tandtekniska arbetet på samtliga (!) patienter.

Camilla Billström vill jag tacka för statistiska konsultationer.

Tack till **Ulf Wahlström** för initiativet till den studie som kom att bli denna avhandlings huvudstudie. Tio år går fort och känns likafullt som en oändligt lång tid.

Maria Hoffman vill jag tacka för arbetet med bokens layout. Det är din förtjänst att korrekturet blev färdigt i tid.

Jag vill också tacka mina djupt saknade föräldrar, **Ingrid och Henry**, för att de alltid framhöll vikten av att tala sanning och

allra mest tackar jag min egen älskade familj, **Folke, Sara and Filip**. Det är mycket viktigt för mig att ni finns. Folke min älskade, jag lovar att från och med i morgon så skall jag då och då lämna skrivbordet och datorn och följa med på träning. Jag vet en god hälsa är viktigare än alla implantat i världen. Sara och Filip, glöm aldrig att livet går i direktsändning och att ett visst mått av envishet kan vara en tillgång för att nå ett mål.

Forskningsstöd har erhållits från:

Kerstin Fischer AB

Straumann AG, Nobel Biocare AB

Hjalmar Svenssons forskningsfond, Wilhelm och Martina Lundgrens forskningsfond

Vetenskapsrådet, Sylvan's Foundation

REFERENCES

Achilli A, Tura F, Euwe E. Immediate/early function with tapered implants supporting maxillary and mandibular posterior fixed partial dentures. Preliminary results of a prospective multicenter study. *J Prosth Dent* 2007;97:S52-58

Albrektsson T, Brånemark PI, Hansson HA, Lindström J. Osseointegrated titanium implants. Requirements for ensuring a long-lasting, direct bone to implant anchorage in man. *Acta Orthop Scand* 1981;52:155-170.

Albrektsson T, Zarb G, Worthington P, Eriksson AR. The long-term efficacy of currently used dental implants: a review and proposed criteria of success. *Int J Oral Maxillofac Implants* 1986;1:11-25.

Albrektsson T, Zarb GA. Current interpretations of the osseointegrated response: Clinical significance. *Int J Prosthodont* 1993;6:95-105.

Albrektsson T, Zarb GA. Determinants of correct clinical reporting. *Int J Prosthodont* 1998;11:517-521.

Albrektsson T, Wennerberg A. Oral implant surfaces: Part I- Review focusing on topographic and chemical properties of different surfaces and in vivo responses to them. *Int J Prosthodont* 2004a;17:536-543.

Albrektsson T, Wennerberg A. Oral implant surfaces: Part 2- Review focusing on clinical knowledge of different surfaces. *Int J Prosthodont* 2004b;17:544-564.

Albrektsson T, Gottlow J, Meirelles L, Östman PO, Rocci A, Sennerby L. Survival of NobelDirect implants:an analysis of 550 consecutively placed implants at 18 different clinical centers. *Clin Implant Dent Rel Res* 2007;2:65-70.

Andersen E, Haanaes HR, Knutsen BM. Immediate loading of single-tooth ITI implants in the anterior maxilla: a prospective 5-year pilot study. *Clin Oral Impl Res* 2002;13:281-287

Aparicio C, Orozco P. Use of 5-mm-diameter implants:Periotest values related to an clinical and radiographic evaluation. *Clin Oral Impl Res* 1998;9:398-406.

Aparicio C, Rangert B, Eng M, Sennerby L. Immediate/Early loading of dental implants: a report from the Sociedad Espanola de implantes World Congress Consensus meeting in Barcelona, Spain, 2002. *Clin Implant Dent Rel Res* 2003;5:57-60.

Aparicio C, Lang NP, Rangert B. Validity and clinical significance of biomechanical testing of implant/bone interface. *Clin Oral Implants Res* 2006;17 Suppl 2:2-7.

Attard, N.J. & Zarb, G.A. Immediate and early implant loading protocols: a literature review of clinical studies. *J Prosth Dent* 2005;94:242-258.

Aubin JE, Kahn A. An osteoblastic lineage, embryologic origin and the differentiation sequence. In Favus MJ ed. *Primer on the metabolic bone diseases and disorders of mineral metabolism*. Philadelphia, pA:Lippicott-Raven 1996,35-38.

Balshi SF, Wolfinger GJ, Balshi TJ. A prospective study of immediate functional loading, following the Teeth in a Day protocol: a case series of 55 consecutive edentulous maxillas. *Clin Implant Dent Relat Res* 2005;1:24-31.

Becker W, Becker BE, Ricci A, Bahat O, Rosenberg E, Rose LF, Handelsman M, Israelson H. A prospective multicenter clinical trial comparing one- and two-stage titanium screw-shaped fixtures with one-stage plasma-sprayed solid-screw fixtures. *Clin Implant Dent Relat Res* 2000;3:159-65.

Bergkvist G, Sahlholm S, Karlsson U, Nilner K, Lindh C. Immediately loaded implants supporting fixed prostheses in the edentulous maxilla: A preliminary clinical and radiologic report. *Int J Oral Maxillofac Implants* 2005;20:399-405.

Berglundh T, Persson L, Klinge B. A systematic review of the incidence of biological and technical complications in implant dentistry reported in prospective longitudinal studies of at least 5 years. *J Clin Periodontol* 2002;29:197-212.

Bornstein M, Schmid B, Belser U, Lussi A, Buser D. Early loading of non-submerged titanium implants with a sandblasted and acid-etched surface. 5-year results of a prospective study in partially edentulous patients. *Clin Oral Impl Res* 2005;16:631-8.

Bornstein M, Harnisch H, Lussi A, Buser D. Clinical performance of wide-body implants with a sandblasted and acid-etched (SLA) surface: results of a 3-year follow-up study in a referral clinic. *Int J Oral Maxillofac Implants* 2007;22:631-638.

Brunski J. In vivo bone response to biomechanical loading at the bone/dental implant interface. *Adv Dent Res* 1999;13:99-119.

Brånemark P-I, Adell R, Breine U, Hansson Bo, Lindström J, Ohlsson A. Intraosseous anchorage of dental prostheses. I. experimental studies. *Scand J Plast Reconstr Surg* 1969;3:81-100.

Brånemark P-I, Hansson BO, Adell R, et al. Osseointegrated implants in the treatment of the edentulous jaw. Experience from a 10-year period. *Scand J Plast Reconstr Surg* 1977;16:1-32.

Brånemark PI, Zarb GA, Albrektsson T (eds). *Tissue-Integrated Prostheses: Osseointegration in Clinical Dentistry*. Chicago: Quintessence, 1985;199-209.

Buser D, Schenk RK, Steinemann S, Fiorellini JP, Fox CH, Stich H. Influence of surface characteristics on bone integration of titanium implants. A histomorphometric study in miniature pigs. *J Biomed Mater Res* 1991;25:889-902.

Buser D, Broggini N, Wieland M, Schenk R, Denzer AJ, Cochran D, Hoffmann B, Lussi A, Steinemann SG. Enhanced bone apposition to a chemically modified SLA titanium surface. *J Dent Res* 2004;83:529-533.

Calandriello R, Tomatis M, Rangert B. Immediate functional loading of Brånemark System Implants with enhanced initial stability: A prospective 1-to 2- year clinical and radiographic study. *Clin Implant Dent Relat Res* 2003;Suppl1:10-20.

Cameron H, Pilliar RM, Macnab I. The effect of movement on the bonding of porous metal to bone. *J Biomed Mat Res* 1973;7:301-311.

Cannizzaro G, Leone M, Consolo U, Ferri V, Esposito M. Immediate functional loading of implants placed with flapless surgery versus conventional implants in partially edentulous patients. A 3-year randomized controlled clinical trial. *Int J Oral Maxillofac Implants* 2007;22:87-95.

Carlsson L, Röstlund T, Albrektsson B, Albrektsson T, Brånemark PI. Osseointegration of titanium implants. *Acta Orthop Scand* 1986;4:285-289.

Carlsson L, Röstlund T, Albrektsson B, Albrektsson T. Implant fixation improved by close fit. Cylindrical implant-bone interface studied in rabbits. *Acta Orthop Scand* 1988;3:272-275.

Cochran D, Buser D, Bruggenkate C, Weingart D, Taylor T, Bernard J-P, Peters F, Simpson J. The use of reduced healing times on ITI® implants with a sandblasted and acid-etched (SLA) surface: Early results from clinical trials on ITI® SLA implants. *Clin Oral Impl Res* 2002;13:144-153.

Cochran DL, Morton D, Weber H-P. Consensus statements and recommended clinical procedures regarding loading protocols for endosseous dental implants. Proceedings of the third ITI consensus conference. *Int J Oral Maxillofac Implants* 2004;19:109-113.

Cochran D, Oates T, Morton D, Jones A, Buser D, Peters F. Clinical field trial examining an implant with a sand-blasted, acid-etched surface. *J Periodontol* 2007;6:974-82.

Cooper L, Felton DA, Kugelberg CF, Ellner S, Chaffee N, Molina AL, Moriarty JD, Paquette D, Palmqvist U. A multicenter 12-month evaluation of single-tooth implants restored 3 weeks after 1-stage surgery. *Int J Oral Maxillofac Implants* 2001;16:182-92.

Cooper LF, Deporter D, Wennerberg A, Hämmerle C. What physical and/or biochemical characteristics of roughened endosseous implant surfaces particularly enhance their bone-implant contact capability? *Int J Oral Maxillofac Implants* 2005;2:307-312.

Cooper LF, Ellner S, Moriarty J, Felton DA, Paquette D, Molina A, Chaffee N, Asplund P, Smith R, Hostner C. Three-year evaluation of single-tooth implants restored 3 weeks after 1-stage surgery. *Int J Oral Maxillofac* 2007;5:791-800.

Degidi M, Piatelli A. Comparative analysis study of 702 dental implants subjected to immediate functional loading and immediate non-functional loading to traditional healing periods with a follow-up of up to 24 months. *Int J Oral Maxillofac Implants* 2005;20:99-107.

DeLuca S and Zarb G. The effect of smoking on osseointegrated dental implants. Part I: Implant survival. *Int J Prosthodont* 2006a;19:491-498.

DeLuca S and Zarb G. The effect of smoking on osseointegrated dental implants. Part II: Peri-implant bone loss. *Int J Prosthodont* 2006b;19:560-566.

Drago CJ, Lazzara RJ. Immediate provisional restoration of Osseotite implants: A clinical report of 18-month results. *Int J Oral Maxillofac Implants* 2004;19:534-541

- Ellingsen JE. Surface configurations of dental implants. *Periodontology* 2000. 1998;1:36-46.
- Ellingsen JE, Johansson C, Wennerberg A, Holmén A. Improved retention and bone-to-implant contact with fluoride-modified titanium implants. *Int J Oral Maxillofac Implants* 2004;19:659-666.
- Engquist B, Bergendal T, Kallus T, Linden U. A retrospective multicenter evaluation of osseointegrated implants supporting overdentures. *Int J Oral Maxillofac Implants* 1988 ;2:129-34.
- Ericsson I, Randow K, Glantz PO, Lindhe J, Nilner K. Clinical and radiographical features of submerged and nonsubmerged titanium implants. *Clin Oral Implants Res* 1994;3:185-9.
- Ericsson I, Nilner K, Klinge B, Glantz PO. Radiographical and histological characteristics of submerged and nonsubmerged titanium implants. An experimental study in the laboratory dog. *Clin Oral Implants Res* 1996;1:20-6.
- Ericsson I, Randow K, Nilner K, Petersson A. Some clinical and radiographical features of submerged and non-submerged titanium implants. A 5-year follow-up study. *Clin Oral Impl Res* 1997;5:422-6.
- Ericsson I, Nilson H, Lindh T, Nilner K, Randow K. Immediate functional loading of Branemark single tooth implants. An 18 months' clinical pilot follow-up study. *Clin Oral Impl Res* 2000a;11:26-33.
- Ericsson I, Randow K, Nilner K, Peterson A. Early loading of Brånemark dental implants: 5 year clinical follow-up study. *Clin Implant Dent Relat Res* 2000b;2:70-77.
- Esposito M, Hirsch J-M, Lekholm U, Thomsen P. Biological factors contributing to failures of osseointegrated oral implants (II). Etiopathogenesis. *Eur J Oral Sci* 1998;106:721-764.
- Esposito M, Worthington H, Coulthard P. In search of truth: The role of systematic reviews and meta-analyses for assessing the effectiveness of rehabilitation with oral implants. *Clin Impl Dent Relat Res* 2001a;16:62-78.
- Esposito M, Coulthard P, Worthington HV, Jokstad A. Quality assessment of randomized controlled trials of oral implants. *Int J Oral Maxillofac Implants* 2001b;16:783-792.

Esposito M, Grusovin MG, Willings M, Coulthard P, Worthington HV. Interventions for replacing missing teeth: different times for loading dental implants. The Cochrane Database of Systematic Reviews. The Cochrane Library 2007;2:1-25.

Ferguson SJ, Broggini N, Wieland M, de Wild M, Rupp F, Geis-Gerstorfer J, Cochran D, Buser D. Biomechanical evaluation of the interfacial strength of a chemically modified sandblasted and acid-etched titanium surface. *J Biomed Mater Res* 2006;78:291-297.

Friberg B, Sennerby L, Roos J, Johansson P, Strid K-G, Lekholm U. Evaluation of bone density using cutting resistance measurements and microradiography. An in vitro study in pig ribs. *Clin Oral Impl Res* 1995;6:164-171.

Friberg B, Sennerby L, Gröndahl K, Bergström C, Bäck T, Lekholm U. On cutting torque measurements during implant placement: A 3-year clinical prospective study. *Clin Implant Dent Relat Res* 1999a;1:75-83.

Friberg B, Sennerby L, Meredith N, Lekholm U. A comparison between cutting torque and resonance frequency measurements of maxillary implants. A 20-months clinical study. *Int J Oral Maxillofac Surg* 1999b;28:297-303.

Friberg B, Sennerby L, Linden B, Gröndahl K, Lekholm U. Stability measurements of one-stage Brånemark implants during healing in mandibles. A clinical resonance frequency analysis study. *Int J Oral Maxillofac Surg* 1999c;28:266-72.

Friberg B, Jisander S, Widmark G, Lundgren A, Ivanoff CJ, Sennerby L, Thoren C. One-year prospective three-center study comparing the outcome of a "soft bone implant" (prototype MkIV) and the standard Branemark implant. *Clin Implant Dent Relat Res* 2003;5:71-77.

Gapski R, Wang H-L, Mascarenhas P, Lang NP. Critical review of immediate implant loading. *Clin Oral Impl Res* 2003;14:515-527.

Gervais M, Wilson P. A rationale for retrievability of fixed, implant-supported prostheses: a complication-based analysis. *Int J Prosthodont* 2007;20:13-24.

Glauser R, Ruhstaller P, Windisch S, Zembic A, Lundgren AK, Gottlow J, Hämmerle C. Immediate occlusal loading of Brånemark System TiUnite implants placed predominantly in soft bone: 4-year results of a prospective clinical study. *Clin Implant Dent Relat Res* 2005;Suppl 1:52-59.

Gotfredsen K, Hjorting-Hansen E, Budtz-Jørgensen E. Clinical and radiographic evaluation of submerged and nonsubmerged implants in monkeys. *Int J Prosthodont.* 1990;5:463-9.

Gotfredsen K, Nimb L, Hjorting-Hansen E, Jensen JS, Holmen A. Histomorphometric and removal torque analysis for TiO₂-blasted titanium implants. An experimental study on dogs. *Clin Oral Impl Res* 1992;3:77-84.

Grunder U, Hürzeler MB, Schüpbach P, Strub JR. Treatment of ligature-induced peri-implantitis using guided tissue regeneration: a clinical and histologic study in the beagle dog. *Int J Oral Maxillofac Implants* 1993;3:282-93.

Gröndahl K, Sundén S, Gröndahl HG. Inter- and intraobserver variability in radiographic bone level assessment at Brånemark fixtures. *Clin Oral Impl Res* 1998;9:243-250.

Göthberg, C, Bergendal, T. & Magnusson, T. Complications after treatment with implant-supported fixed prostheses: a retrospective study. *Int J Prosthodont* 2003;16: 201-207.

Hall JAG, Payne AGT, Purton DG, Dip Tech BTNH, Duncan WJ, De Silva RK. Immediately restored, single-tapered implants in the anterior maxilla: prosthodontic and aesthetic outcomes after 1 year. *Clin Implant Dent Relat Res* 2007;1:34-45.

Hallman M, Mordenfeld A, Strandkvist T. A retrospective 5-year follow-up study of two different titanium implant surfaces used after interpositional bone grafting for reconstruction of the atrophic edentulous maxilla. *Clin Implant Dent Relat Res* 2005;3:121-6.

Hansson S. The implant neck: smooth or provided with tension elements. A biomechanical approach. *Clin Oral Impl Res* 1999;5:394-405.

Heydenrijk K, Raghoobar GM, Meijer HJ, Van Der Reijden WA, Van Winkelhoff AJ, Stegenga B. Two-part implants inserted in a one-stage or a two-stage procedure. A prospective comparative study. *Clin Periodontol* 2002;10:901-9.

Hui E, Chow J, Li D, Liu J, Wat P, Law H. Immediate provisional for single-tooth implant replacement with Branemark system: preliminary report. *Clin Implant Dent Relat Res* 2001;3:79-86

Hänggi MP, Hänggi DC, Schoolfield JD, Meyer, Cochran D, Hermann JS. Crestal bone changes around titanium implants. Part I: A retrospective radiographic evaluation in humans comparing two non-submerged implant designs with different machined collar lengths. *J Periodont* 2005;76:791-802.

- Ivanoff C-J, Sennerby L, Johansson C, Rangert B, Lekholm U. Influence of implant diameter on the integration of screw implants. An experimental study in rabbits. *Int J Oral Maxillofac Surg* 1997;26:141-148.
- Ivanoff C-J, Widmark G, Johansson C, Wennerberg A. Histologic evaluation of bone response to oxidized and turned titanium micro-implants in human jaw-bone. *Int J Oral Maxillofac Implants* 2003;3:341-348.
- Jaffin, RA. & Berman, CL. The excessive loss of Branemark fixtures in type IV bone. a five-year analysis. *J Periodontol* 1991;62:2-4.
- Jansson H, Hamberg K De Bruyn H, Bratthall G. Clinical consequences of IL-1 genotype on early implant failures in patients under periodontal maintenance. *Clin Implant Dent Relat Res.* 2005;1:51-9.
- Jemt T. Implant treatment in resorbed edentulous upper jaws. *Clin Oral Impl Res* 1993;4:187-194.
- Jemt, T. Fixed implant-supported prostheses in the edentulous maxilla. *Clin Oral Impl Res* 1994;5:142-147.
- Jemt, T. & Häger, P. Early complete failures of fixed implant-supported prostheses in the edentulous maxilla: A 3-year analysis of 17 consecutive cluster failure patients. *Clin Impl Dent Relat Res* 2006;8:77-86.
- Johansson C, Albrektsson T. Integration of screw implants in the rabbit: A 1-year follow-up of removal torque of titanium implants. *Int J Oral Maxillofac Impl* 1987;2:69-75.
- Johansson, G. Palmqvist, S. Complications, supplementary treatment, and maintenance in edentulous arches with implant fixed prostheses. *Int J Prosthodont* 1990;3:89-92.
- Johansson P, Strid K-G. Assessment of bone quality from cutting resistance during implant surgery. *Int J Oral Maxillofac Impl* 1994;9:279-288.
- Kan J, Rungcharassaeng K, Lozada J. Immediate placement and provisionalization of maxillary anterior single implants: 1-year prospective study. *Int J Oral Maxillofac Implants* 2003;18:31-39
- Kasemo B. Biocompatibility of titanium implants: surface science aspects. *J Prosthet Dent* 1983;49:832-837.

Kilpadi DV, Lemons JE. Surface energy characterization of unalloyed titanium implants. *J Biomed Mater Res* 1994;28:1419-1425.

Kinsel RP and Liss M. Retrospective analysis of 56 edentulous dental arches restored with 344 single-stage implants using an immediate loading fixed provisional protocol: statistical predictors of implant failure. *Int J Oral Maxillofac Impl* 2007;5:823-830.

Kreissl M, Gerds T, Muche R, Heydecke G, Strub J. Technical complications of implant-supported fixed partial dentures in partially edentulous cases after an average observation period of 5 years. *Clin Oral Impl Res* 2007;18:720-726.

Ledermann PD. Stegprothetische versorgung des zahnlosen unterkiefers mit hilfe plasmabeschichteten titanschraubimplantaten. *Deutsche Zahnärztliche Zeitung* 1979;34:907-911.

Lee D-W, Choi Y-S, Park K-H, Kim C-S, Moon I-S. Effect of micro thread on the maintenance of marginal bone level: a 3-year prospective study. *Clin Oral Impl Res* 2007;18:465-470.

Lekholm U, Zarb GA. Patient selection and preparation. In: Brånemark PI, Zarb GA, Albrektsson T (eds). *Tissue-Integrated Prosthesis: Osseointegration in Clinical Dentistry*. Chicago: Quintessence, 1985;199-209.

Lindeboom JA, Frenken JW, Dubois L, Frank M, abbink I, Kroon FH. Immediate loading versus immediate provisionalization of maxillary single-tooth replacements: a prospective randomized study with BioComp implants. *Int J Oral Maxillofac Surg* 2006;6:936-942.

Lindfors, E., Magnusson, T. & Tegelberg, Å. Interocclusal appliances- Indications and clinical routines in general dental practise in Sweden. *Swedish Dental Journal* 2006;30:123-134.

Lindh C, Petersson A, Rohlin M. Assessment of the trabecular pattern before endosseous implant treatment diagnostic outcome of periapical radiography in the mandible. *Oral Surg Oral Med Oral Pathol Oral radiol Endod* 1996;82:335-343.

Lorenzoni M, Pertl C, Zhand K, Wimmer G, Wegscheider WA. Immediate loading of single-tooth implants in the anterior maxilla. Preliminary results after one year. *Clin Oral Impl Res* 2003;14:180-187.

Luongo G, Di Raimondo R, Filippini P, Gualini F, Paoleschi C. Early loading of sandblasted, acid-etched implants in the posterior maxilla and mandible: a 1-year follow-up report from a multicenter 3-year prospective study. *Int J Oral Maxillofac Implants* 2005;20:84-91.

Malevez CH, Herman M, Daelemans PH. Marginal bone levels at Brånemark system implants used for single tooth restoration. The influence of implant design and anatomical region. *Clin Oral Impl Res* 1996;7:162-169.

Meredith N, Crawley P, Alleyne D. The application of modal vibration analysis to study bone healing in-vivo. *Journal of Dental research* 1994;73:793.

Meredith N, Alleyne D, Crawley P. Quantitative determination of the stability of the implant-tissue interface using resonance frequency analysis. *Clin Oral Impl Res* 1996;7:261-267.

Meredith N, Book K, Friberg B, Jemt T, Sennerby L. Resonance frequency measurements of implant stability in vivo. A cross-sectional and longitudinal study of resonance frequency measurements on implants in the edentulous and partially dentate maxilla. *Clin Oral Impl Res* 1997;8:226-233.

Meredith N, Friberg B, Sennerby L, Aparicio C. Relationship between contact time measurements and PTV values when using the Periotest to measure implant stability. *Int J Prosthodont* 1998;11:269-275.

Nkenke E and Fenner M. Indications for immediate loading of implants and implant success. *Clin Oral Impl Res* 2006;17 (Suppl2):19-34.

Nordin T, Nilsson R, Frykholm A, Hallman M. A 3-arm study of early loading of rough-surfaced implants in the completely edentulous maxilla and in the edentulous posterior maxilla and mandible: Results after 1 year of loading. *Int J Oral Maxillofac Implants* 2004;19:880-886.

Nordin T, Graf J, Frykholm A, Helldén L. Early functional loading of sand-blasted acid-etched (SLA) Straumann implants following immediate placement in maxillary extraction sockets. *Clin Oral Impl Res* 2007;4:441-451.

Norton MR. A short-term clinical evaluation of immediately restored maxillary TiOblast single-tooth implants. *Int J Oral Maxillofac Implants* 2004;19:274-281

Olsson M, Urde G, Andersen J, Sennerby L. Early loading of maxillary fixed cross-arch dental prostheses supported by six or eight oxidized titanium implants: results after 1 year of loading, case series. *Clin Impl Dent Relat Res* 2003;5(Suppl1):81-87.

O'Sullivan D, Sennerby L, Meredith N. Measurements comparing the initial stability of five designs of dental implants: a human cadaver study. *Clin Impl Dent Relat Res* 2000;2:85-92.

O'Sullivan D, Sennerby L & Meredith N. Influence of implant taper on the primary and secondary stability of osseointegrated titanium implants. *Clin Oral Impl Res* 2004;4:474-480.

Petrie CS and Williams JL. Comparative evaluation of implant designs: influence of diameter, length, and taper on strains in the alveolar crest. *Clin Oral Impl Res* 2005;486-494.

Piattelli A, Scarano A, Corigliano M, Piatelli M. Presence of multinucleated giant cells around machined, sandblasted and plasma-sprayed titanium implants: a histological and histochemical time-course study in rabbit. *Biomaterials* 1996;21:2053-2058.

Piattelli A, Corigliano M, Scarano A, Costigliola G, Paolantonio M. Immediate loading of titanium plasma-sprayed implants: an histologic analysis in monkeys. *J Periodontol* 1998;69: 321-7.

Pjetursson BE, Tan K, Lang NP, Brägger U, Egger M, Zwahlen M. A systematic review of the survival and complication rates of fixed partial dentures (FPDs) after an observation period of at least 5 years. *Clin Oral Implants Res* 2004;15:625-42.

Quirynen M, Naert I, van Steenberghe D. Fixture design and overload influence marginal bone loss and fixture success in the Brånemark system. *Clin Oral Impl Res* 1992;3:104-111.

Quirynen M, De Soete M, van Steenberghe D. Infectious risks for oral implants: a review of the literature. *Clin Oral Impl Res* 2002;13:1-19.

Rasmusson L, Meredith N, Kahnberg KE, Sennerby L. Stability assessments and histology of titanium implants placed simultaneously with autogenous onlay bone in the rabbit tibia. *Int J Oral Maxillofac Surg* 1998;27:229-235

Rocci A, Martignoni M, Gottlow J. Immediate loading of Brånemark system® TiUnite™ and machined-surface implants in the posterior mandible: a randomized open-ended clinical trial. *Clin Implant Dent Relat Res* 2003;5:57-63.

Roccuzzo M, Bunino M, Prioglio F, Bianchi SD. Early loading of sandblasted and acid-etched (SLA) implants: a prospective split-mouth comparative study. *Clin Oral Impl Res* 2001;12:572-578.

Roccuzzo M and Wilson T. A prospective study evaluating a protocol for 6 weeks' loading of SLA implants in the posterior maxilla: one year results. *Clin Oral Impl Res* 2002;5:502-507.

Roos-Jansaker AM, Renvert H, Lindahl C, Renvert S. Nine-to fourteen-year follow-up of implant treatment. Part 1: implant loss and associations to various factors. *J Clin Periodontol* 2006;33:283-289.

Ruggeri A, Franchi M, Marini N, Trisi P, Piatelli A. Supracrestal circular collagen fiber network around osseointegrated nonsubmerged titanium implants. *Clin Oral Implants Res* 1992;4:169-75

Salvi G, Gallini G, Lang N. Early loading (2 or 6 weeks) of sandblasted and acid-etched (SLA) ITI® implants in the posterior mandible. *Clin Oral Impl Res* 2004;15:142-149.

Schenk R. Bone regeneration. Biologic basis. In Buser, Dahlin and Schenk (eds) *Guided bone regeneration in implant dentistry*. Quintessence Publ Co, Inc; Chicago. 1994:49-100.

Schnitman PA, Wohrle PS, Rubenstein JE. Immediate fixed interim prostheses supported by two-stage threaded implants: methodology and results. *J Oral Implantol* 1990;2:96-105.

Schroeder A, Pohler O, Sutter F. Gewebsreaktion auf ein Titan-Hohlzylinderimplantat mit Titan-Spritzschichtoberfläche. *Schweiz Monatsschr Zahnheilkd* 1976;86:713-727.

Schroeder A, van den Zypen E, Stich H, Sutter F. The reaction of bone, connective tissue and epithelium to endosteal implants with titanium-sprayed surfaces. *J Maxillofac Surg* 1981;9:15-25.

Schüpbach P, Glauser R, Rocci A, Martignoni M, Sennerby L, Lundgren AK, Gottlow J. The human bone-oxidized titanium implant interface: A light microscopic, scanning electron microscopic, back-scatter scanning electron microscopic, and energy-dispersive X-ray study of clinically retrieved dental implants. *Clin Implant Dent Relat Res* 2005;7 Suppl 1:36-43.

Sennerby L. On tissue response to titanium implants. Thesis. Dept of Biomaterials/Handicap Research, Göteborg University, Sweden. 1991.

Sennerby L, Thomsen P, Ericson LE. Early tissue response to titanium implants inserted in rabbit cortical bone. Part I Light microscopic observations. *J Mater Sci Mater Med* 1993a;3:240-250.

Sennerby L, Thomsen P, Ericson LE. Early tissue response to titanium implants inserted in rabbit cortical bone. Part II Ultrastructural observations. *J Mater Sci Mater Med* 1993b;5:494-502.

Sennerby L, Roos J. Surgical determinants of clinical success of osseointegrated oral implants: a review of the literature. *Int J Prosthodont* 1998;5:408-20.

Sennerby L, Friberg B, Lindén B, Jemt T, Meredith N. A comparison of implant stability in mandibular and maxillary bone using RFA. Resonance frequency analysis symposium. Gothenburg, Sweden. 2000.

Sennerby L, Persson LG, Berglundh T, Wennerberg A, Lindhe J. Implant stability during initiation and resolution of experimental periimplantitis: an experimental study in the dog. *Clin Implant Dent Relat Res* 2005;3:136-40.

Simmons DJ. Fracture healing perspectives. *Clin Orthop Rel Res* 1985;200:100-113.

Sjöström M, Sennerby L, Nilson H, Lundgren S. Reconstruction of the atrophic edentulous maxilla with free iliac crest grafts and implants: a 3-year report of a prospective clinical study. *Clin Implant Dent Relat Res* 2007;1:46-59.

Søballe K, Hansen ES, Brockstedt-Rasmussen H, Bünger C. Hydroxyapatite coating converts fibrous tissue to bone around loaded implants. *J Bone Joint Surg Br* 1993;2:270-8.

Sul YT. On the bone response to oxidized titanium implants. Thesis. Dept of Biomaterials/ Handicap Research, Göteborg University, Sweden. 2002.

Sul YT, Johansson C, Wennerberg A, Cho LR, Chang BS, Albrektsson T. Optimum surface properties of oxidized implants for reinforcement of osseointegration: surface chemistry, oxide thickness, porosity, roughness, and crystal structure. *Int J Oral Maxillofac Implants* 2005;3:349-59.

Suzuki K, Aoki K, Ohya K. Effects of surface roughness of titanium implants on bone remodelling activity of femur in rabbits. *Bone* 1997;21:507-514

Testori T, Del Fabbro M, Feldman S, Vincenzi G, Sullivan D, Rossi R Jr, Anitua E, Bianchi F, Francetti L, Weinstein RL. A multicenter prospective evaluation of 2-months loaded Osseotite implants placed in the posterior jaws: 3-year follow-up results. *Clin Oral Implants Res.* 2002;2:154-61.

Testori T, Bianchi F, Del Fabbro M, Schumker-Moncler S, Francetti L, Weinstein RL. Immediate non-occlusal loading vs early loading in partially edentulous patients. *Pract Procedures and Aesthetic Dentistry* 2003;15:787-794.

Tricio J van Steenberghe D, Rosenberg D, Duchateau L. Implant stability related to insertion torque force and bone density: An in vitro study. *J Prosthet Dent* 1995;74:608-612.

Trulsson, M. The tooth as a sensor in the masticatory system. *The Journal of the SDA* 2006;98:30-38.

Turkyilmaz I, Sennerby L, Tumer C, Yenigul M, Avci M. A 2-year clinical report of patients treated with two loading protocols for mandibular overdentures: Early versus conventional loading protocols. *J Periodontol* 2006a;77:1998-2004.

Turkyilmaz I. A 3-year prospective clinical and radiologic analysis of early loaded maxillary dental implants supporting single-tooth crowns. *Int J Prosthodont* 2006b;4:389-90.

Turkyilmaz I, Sennerby L, Tumer C, Yenigul M, Avci M. Stability and marginal bone level measurements of unsplinted implants used for mandibular overdentures: a 1-year randomized prospective clinical study comparing early and conventional loading protocols. *Clin Oral Implants Res* 2006c;17:501-505.

Valderrama P, Oates TW, Jones AA, Simpson J, Schoolfield JD, Cochran DL. Evaluation of two different resonance frequency devices to detect implant stability: a clinical trial. *J Periodontol* 2007;78:262-72.

Vanden Bogaerde L, Pedretti G, Dellacasa P, Mozzati M, Rangert B, Wendelhag I. Early function of splinted implants in maxillas and posterior mandibles, using Branemark System Tiunite implants: an 18-month prospective clinical multicenter study. *Clin Implant Dent Relat Res* 2004;6:121-9.

van Steenberghe D, Molly L, Jacobs R, Vandekerckhove B, Quirynen M, Naert I. The immediate rehabilitation by means of a ready-made final fixed prosthesis in the edentulous mandible: a 1-year follow-up study on 50 consecutive patients. *Clin Oral Implants Res* 2004;3:360-5.

Veltri M, Balleri P, Ferrari M. Influence of transducer orientation on Osstell stability measurements of osseointegrated implants. *Clin Implant Dent Relat Res* 2007;9:60-64.

Walton, T. The outcome of implant-supported fixed prostheses from the prosthodontic perspective: proposal for a classification protocol. *Int J Prosthodont* 1998;11:595-601.

Wennerberg A, Albrektsson T, Andersson B, Krol JJ. A histomorphometric and removal torque study of screw-shaped titanium implants with three different surface topographies. *Clin Oral Impl Res* 1995;1:24-30.

Wennerberg A and Albrektsson T. Suggested guidelines for the topographic evaluation of implant surfaces. *Int J Oral Maxillofac Implants* 2000;3:331-344.

Zarb GA, Schmitt A. The longitudinal clinical effectiveness of osseointegrated dental implants: the Toronto study. Part I: Surgical results. *J Prosthet Dent* 1990;63:451-7.

Zarb GA, Schmitt A. The longitudinal clinical effectiveness of osseointegrated dental implants: the Toronto Study. Part II: The prosthetic results. *J Prosthet Dent* 1990;64:53-61.

Zarb GA, Schmitt A. The longitudinal clinical effectiveness of osseointegrated dental implants: the Toronto study. Part III: Problems and complications encountered. *J Prosthet Dent* 1990;64:185-94.

Åstrand P, Anzén B, Karlsson U, Sahlholm S, Svärðström P, Hellem S. Nonsubmerged implants in the treatment of the edentulous upper jaw: a prospective clinical and radiographic study of ITI implants-results after 1 year. *Clin Implant Relat Res* 2000;3:166-174.

Åstrand P, Billström C, Feldmann H, Fischer K, Henricsson V, Johansson B, Nyström E, Sunzel B. Tapered implants in jaws with soft bone quality: A clinical and radiographic 1-year study of the Brånemark system Mark IV fixture. *Clin Implant Dent Relat Res* 2003;5:213-218

Örtorp A, Jemt T. Clinical experiences with laser-welded titanium frameworks supported by implants in the edentulous mandible: a 10-year follow-up study. *Clin Implant Dent Relat Res* 2006;8:198-209.

Örtorp A. On titanium frameworks and alternative impression techniques in implant dentistry. Thesis, Göteborg University, 2005.

Östman P-O, Hellman M, Wendelhag I, Sennerby L. Resonance frequency analysis measurements of implants at placement surgery. *Int J Prosthodont* 2006;19:77-83.

Östman PO, Hellman M, Albrektsson T, Sennerby L. Direct Loading of Nobel Direct® and Nobel Perfect® One-Piece Implants: A 1-Year Prospective Clinical and Radiographic Study. *Clin Oral Implants Res* 2007;4:409-18.